

Undergraduate Diagnostic Imaging Fundamentals

Undergraduate Diagnostic Imaging Fundamentals

Brent Burbridge, MD, FRCPC

Evan Mah, BSc (Kin)

UNIVERSITY OF SASKATCHEWAN, DISTANCE EDUCATION UNIT
SASKATOON, SK, CANADA



Undergraduate Diagnostic Imaging Fundamentals by Brent Burbridge is licensed under a [Creative Commons Attribution-NonCommercial-ShareAlike 4.0 International License](https://creativecommons.org/licenses/by-nc-sa/4.0/), except where otherwise noted.

All images in this work, unless otherwise stated by a specific copyright statement, are courtesy of Dr. Brent Burbridge, MD, FRCPC, University Medical Imaging Consultants, College of Medicine, University of Saskatchewan, and fall under the CC copyright license of this open book.

Contents

Foreword	1
CC BY-NC-SA (Attribution NonCommercial ShareAlike)	
Abbreviations	2
CC BY-NC-SA (Attribution NonCommercial ShareAlike)	
Acknowledgements	8
CC BY-NC-SA (Attribution NonCommercial ShareAlike)	
Chapter 1 – Introduction	
1. Online DICOM Image Viewer (ODIN): An Introduction and User Manual	10
CC BY-NC-SA (Attribution NonCommercial ShareAlike)	
2. CanMEDS Roles	32
CC BY-NC-SA (Attribution NonCommercial ShareAlike)	
3. CAR – Diagnostic Imaging Referral Guidelines	35
CC BY-NC-SA (Attribution NonCommercial ShareAlike)	
4. ACR – Appropriateness Criteria	36
CC BY-NC-SA (Attribution NonCommercial ShareAlike)	
5. Choosing Wisely – Canada	39
CC BY-NC-SA (Attribution NonCommercial ShareAlike)	
6. Image Gently	43
CC BY-NC-SA (Attribution NonCommercial ShareAlike)	
7. Introduction – References	44
CC BY-NC-SA (Attribution NonCommercial ShareAlike)	
Chapter 2 – Principles of Radiation Biology and Radiation Protection	
8. Introduction	46
CC BY-NC-SA (Attribution NonCommercial ShareAlike)	
9. Radiation in Medical Imaging: The x-ray Tube	47
CC BY-NC-SA (Attribution NonCommercial ShareAlike)	
10. Ionizing Radiation: Basic Concepts	54
CC BY-NC-SA (Attribution NonCommercial ShareAlike)	

11. Radiation Interaction with Biological Matter	56
CC BY-NC-SA (Attribution NonCommercial ShareAlike)	
12. Classification of Radiation Damage	57
CC BY-NC-SA (Attribution NonCommercial ShareAlike)	
13. Radiation Protection for Healthcare Workers	59
CC BY-NC-SA (Attribution NonCommercial ShareAlike)	
14. Radiation Protection for Patients	61
CC BY-NC-SA (Attribution NonCommercial ShareAlike)	
15. Ionizing Radiation: Fetus and Neonate	62
CC BY-NC-SA (Attribution NonCommercial ShareAlike)	
16. Appropriateness of Imaging Guidelines	64
CC BY-NC-SA (Attribution NonCommercial ShareAlike)	
17. Principles of Radiation Biology and Radiation Protection – References	65
CC BY-NC-SA (Attribution NonCommercial ShareAlike)	

[Chapter 3 – Principles of Imaging Techniques](#)

18. Introduction	67
CC BY-NC-SA (Attribution NonCommercial ShareAlike)	
19. X-rays	75
CC BY-NC-SA (Attribution NonCommercial ShareAlike)	
20. Mammography	91
CC BY-NC-SA (Attribution NonCommercial ShareAlike)	
21. Fluoroscopy	97
CC BY-NC-SA (Attribution NonCommercial ShareAlike)	
22. Angiography	102
CC BY-NC-SA (Attribution NonCommercial ShareAlike)	
23. Computed Tomography (CT)	106
CC BY-NC-SA (Attribution NonCommercial ShareAlike)	
24. Ultrasound (US)	124
CC BY-NC-SA (Attribution NonCommercial ShareAlike)	
25. Magnetic Resonance Imaging (MRI)	137
CC BY-NC-SA (Attribution NonCommercial ShareAlike)	
26. Nuclear Medicine	144
CC BY-NC-SA (Attribution NonCommercial ShareAlike)	
27. Principles of Imaging Techniques – References	152
CC BY-NC-SA (Attribution NonCommercial ShareAlike)	

[Chapter 4 – Contrast Media in Radiology](#)

28. Contrast Media in Radiology	154
CC BY-NC-SA (Attribution NonCommercial ShareAlike)	

Chapter 5 – Approach to Reviewing X-ray Imaging

29. <u>General Approach to Reviewing x-ray Imaging</u> CC BY-NC-SA (Attribution NonCommercial ShareAlike)	168
30. <u>Approach to the Chest x-ray (CXR)</u> CC BY-NC-SA (Attribution NonCommercial ShareAlike)	173
31. <u>Approach to the Abdominal x-ray (AXR)</u> CC BY-NC-SA (Attribution NonCommercial ShareAlike)	188
32. <u>Approach to Bone and Joint x-rays</u> CC BY-NC-SA (Attribution NonCommercial ShareAlike)	201

Chapter 6 – Brain and Spine

33. <u>Intracranial Hemorrhage – Traumatic</u> CC BY-NC-SA (Attribution NonCommercial ShareAlike)	210
34. <u>Ischemic Stroke</u> CC BY-NC-SA (Attribution NonCommercial ShareAlike)	218
35. <u>Tumours of the Brain</u> CC BY-NC-SA (Attribution NonCommercial ShareAlike)	223
36. <u>Hydrocephalus</u> CC BY-NC-SA (Attribution NonCommercial ShareAlike)	231
37. <u>Low Back Pain</u> CC BY-NC-SA (Attribution NonCommercial ShareAlike)	237
38. <u>Spine Fracture</u> CC BY-NC-SA (Attribution NonCommercial ShareAlike)	244
39. <u>Brain and Spine – References</u> CC BY-NC-SA (Attribution NonCommercial ShareAlike)	250

Chapter 7 – Breast

40. <u>Introduction to Breast Imaging</u> CC BY-NC-SA (Attribution NonCommercial ShareAlike)	252
41. <u>Palpable Breast Mass</u> CC BY-NC-SA (Attribution NonCommercial ShareAlike)	260
42. <u>BI-RADS</u> CC BY-NC-SA (Attribution NonCommercial ShareAlike)	265
43. <u>Breast – References</u> CC BY-NC-SA (Attribution NonCommercial ShareAlike)	266

Chapter 8 – Cardiovascular

44. <u>Normal, Labelled, Chest x-ray, with Cardiovascular Structures</u> CC BY-NC-SA (Attribution NonCommercial ShareAlike)	268
45. <u>Enlarged Cardiac Silhouette</u> CC BY-NC-SA (Attribution NonCommercial ShareAlike)	270

46. Aortic Dissection and Aneurysm	274
CC BY-NC-SA (Attribution NonCommercial ShareAlike)	
47. Congestive Heart Failure	281
CC BY-NC-SA (Attribution NonCommercial ShareAlike)	
48. Cardiovascular – References	286
CC BY-NC-SA (Attribution NonCommercial ShareAlike)	

Chapter 9 – Chest

49. Normal, Labelled, Chest x-ray	288
CC BY-NC-SA (Attribution NonCommercial ShareAlike)	
50. Tubes and Catheters	290
CC BY-NC-SA (Attribution NonCommercial ShareAlike)	
51. Atelectasis	300
CC BY-NC-SA (Attribution NonCommercial ShareAlike)	
52. Lobar and Lung Collapse – Suspected Lung Malignancy	307
CC BY-NC-SA (Attribution NonCommercial ShareAlike)	
53. Pleural Effusion	312
CC BY-NC-SA (Attribution NonCommercial ShareAlike)	
54. Pneumonia	322
CC BY-NC-SA (Attribution NonCommercial ShareAlike)	
55. Pneumothorax	330
CC BY-NC-SA (Attribution NonCommercial ShareAlike)	
56. Emphysema	340
CC BY-NC-SA (Attribution NonCommercial ShareAlike)	
57. Solitary Lung Nodule	348
CC BY-NC-SA (Attribution NonCommercial ShareAlike)	
58. Multiple Lung Nodules	352
CC BY-NC-SA (Attribution NonCommercial ShareAlike)	
59. Pulmonary Thromboembolism	355
CC BY-NC-SA (Attribution NonCommercial ShareAlike)	
60. Chest – References	367
CC BY-NC-SA (Attribution NonCommercial ShareAlike)	

Chapter 10 – Gastrointestinal and Abdominal

61. Cholecystitis	369
CC BY-NC-SA (Attribution NonCommercial ShareAlike)	
62. Intestinal Perforation- Pneumoperitoneum	374
CC BY-NC-SA (Attribution NonCommercial ShareAlike)	
63. Ileus	382
CC BY-NC-SA (Attribution NonCommercial ShareAlike)	
64. Intestinal Obstruction	390
CC BY-NC-SA (Attribution NonCommercial ShareAlike)	

65. Appendicitis	398
CC BY-NC-SA (Attribution NonCommercial ShareAlike)	
66. Diverticulitis	405
CC BY-NC-SA (Attribution NonCommercial ShareAlike)	
67. Toxic Megacolon	410
CC BY-NC-SA (Attribution NonCommercial ShareAlike)	
68. Liver Tumour	415
CC BY-NC-SA (Attribution NonCommercial ShareAlike)	
69. Jaundice	419
CC BY-NC-SA (Attribution NonCommercial ShareAlike)	
70. Gastrointestinal and Abdominal – References	423
CC BY-NC-SA (Attribution NonCommercial ShareAlike)	

[Chapter 11 – Gynecology and Obstetrics](#)

71. Benign and Malignant Tumours of the Female Reproductive System	425
CC BY-NC-SA (Attribution NonCommercial ShareAlike)	
72. Normal Pregnancy	436
CC BY-NC-SA (Attribution NonCommercial ShareAlike)	
73. Ectopic Pregnancy	440
CC BY-NC-SA (Attribution NonCommercial ShareAlike)	
74. Placenta Previa	444
CC BY-NC-SA (Attribution NonCommercial ShareAlike)	
75. Gynecology and Obstetrics – References	448
CC BY-NC-SA (Attribution NonCommercial ShareAlike)	

[Chapter 12 – Head and Neck](#)

76. Thyroid – Palpable Nodule	450
CC BY-NC-SA (Attribution NonCommercial ShareAlike)	
77. Facial Trauma	455
CC BY-NC-SA (Attribution NonCommercial ShareAlike)	
78. Sinusitis/Mastoiditis	463
CC BY-NC-SA (Attribution NonCommercial ShareAlike)	
79. Retropharyngeal Abscess – Child	472
CC BY-NC-SA (Attribution NonCommercial ShareAlike)	
80. Epiglottitis – Child	476
CC BY-NC-SA (Attribution NonCommercial ShareAlike)	
81. Head and Neck – References	479
CC BY-NC-SA (Attribution NonCommercial ShareAlike)	

[Chapter 13 – Interventional / Vascular \(Invasive\)](#)

82. Percutaneous Biopsy	481
CC BY-NC-SA (Attribution NonCommercial ShareAlike)	

83. Percutaneous Fluid Drainage	485
CC BY-NC-SA (Attribution NonCommercial ShareAlike)	
84. Venous Access	492
CC BY-NC-SA (Attribution NonCommercial ShareAlike)	
85. Inferior Vena Cava Filter	499
CC BY-NC-SA (Attribution NonCommercial ShareAlike)	
86. Interventional/Vascular – References	504
CC BY-NC-SA (Attribution NonCommercial ShareAlike)	

[Chapter 14 – Musculoskeletal](#)

87. Clavicle Fracture	506
CC BY-NC-SA (Attribution NonCommercial ShareAlike)	
88. Acromioclavicular Joint Separation	510
CC BY-NC-SA (Attribution NonCommercial ShareAlike)	
89. Rotator Cuff	516
CC BY-NC-SA (Attribution NonCommercial ShareAlike)	
90. Glenohumeral Dislocation – Anterior and Posterior	520
CC BY-NC-SA (Attribution NonCommercial ShareAlike)	
91. Elbow Fractures	527
CC BY-NC-SA (Attribution NonCommercial ShareAlike)	
92. Hand and Wrist Fractures	536
CC BY-NC-SA (Attribution NonCommercial ShareAlike)	
93. Pelvic Fracture	543
CC BY-NC-SA (Attribution NonCommercial ShareAlike)	
94. Hip Fracture – Femoral Neck Fracture	547
CC BY-NC-SA (Attribution NonCommercial ShareAlike)	
95. Knee Trauma – Acute Fractures	552
CC BY-NC-SA (Attribution NonCommercial ShareAlike)	
96. Ankle Trauma, Fractures	558
CC BY-NC-SA (Attribution NonCommercial ShareAlike)	
97. Degenerative Joint Diseases – Hip	563
CC BY-NC-SA (Attribution NonCommercial ShareAlike)	
98. Erosive Arthritic Condition – RA	567
CC BY-NC-SA (Attribution NonCommercial ShareAlike)	
99. Musculoskeletal Radiology – References	571
CC BY-NC-SA (Attribution NonCommercial ShareAlike)	

[Chapter 15 – Pediatric](#)

100. Non-Accidental and Accidental Trauma	574
CC BY-NC-SA (Attribution NonCommercial ShareAlike)	
101. Foreign Body Ingestion/Aspiration	587
CC BY-NC-SA (Attribution NonCommercial ShareAlike)	

102. Urinary Tract Infection and Suspected Vesico-Ureteral Reflux	596
CC BY-NC-SA (Attribution NonCommercial ShareAlike)	
103. Pyloric Stenosis	601
CC BY-NC-SA (Attribution NonCommercial ShareAlike)	
104. Tumors Unique to Children – Wilms Tumour	606
CC BY-NC-SA (Attribution NonCommercial ShareAlike)	
105. Pediatric – References	611
CC BY-NC-SA (Attribution NonCommercial ShareAlike)	

[Chapter 16 – Urogenital](#)

106. Urinary Tract Calculus	613
CC BY-NC-SA (Attribution NonCommercial ShareAlike)	
107. Renal Tumour	617
CC BY-NC-SA (Attribution NonCommercial ShareAlike)	
108. Hematuria	621
CC BY-NC-SA (Attribution NonCommercial ShareAlike)	
109. Testicular Tumour	625
CC BY-NC-SA (Attribution NonCommercial ShareAlike)	
110. Testicular Torsion	629
CC BY-NC-SA (Attribution NonCommercial ShareAlike)	
111. Urogenital – References	634
CC BY-NC-SA (Attribution NonCommercial ShareAlike)	

[Chapter 17 – Normal, Reference Images, Unlabelled and Labelled](#)

112. Head and Neck	636
CC BY-NC-SA (Attribution NonCommercial ShareAlike)	
113. Chest	669
CC BY-NC-SA (Attribution NonCommercial ShareAlike)	
114. Abdomen	682
CC BY-NC-SA (Attribution NonCommercial ShareAlike)	
115. Pelvis	697
CC BY-NC-SA (Attribution NonCommercial ShareAlike)	
116. Musculoskeletal	708
CC BY-NC-SA (Attribution NonCommercial ShareAlike)	
117. Pediatric	726
CC BY-NC-SA (Attribution NonCommercial ShareAlike)	
Permissions	732
CC BY-NC-SA (Attribution NonCommercial ShareAlike)	

Foreword

We have created this resource to provide basic content in Diagnostic Imaging (Radiology, Medical Imaging). Hopefully, learners who find this encounter interesting will use this resource as a stepping stone to further their education in this area.

Throughout, you will find normal images and images of different abnormalities. The images displayed are simple, static, JPEG files, and although they will help you learn, they do not accurately represent the imaging that clinicians would use in their practice. To do so, you require a Picture Archiving and Communication System (PACS), which allows clinicians to interact with the images by zooming, changing level and window, annotating, and scrolling through sets of images. If these terms are unfamiliar, you will be more acquainted with them after reading the [Principles of Imaging Techniques](#) section of this eBook.

To help you better appreciate normal and abnormal images, you can view images in the Online Dicom Image Navigator (ODIN), which provides images in a PACS-like format. Access to the full image sets is provided by clicking the links to ODIN cases. Please take advantage of these links to enhance your learning experience.

The structure and content of this work has been guided by the curricula developed by the [European Society of Radiology](#), the [Royal College of Radiologists](#), the [Alliance of Medical Student Educators in Radiology](#), with guidance and input from Canadian Radiology Undergraduate Education Coordinators, and the [Canadian Heads of Academic Radiology \(CHAR\)](#).

We hope that you will find our work interesting and useful. We will gratefully accept any constructive comments, or suggestions, you may have that will help to enhance the quality and usefulness of our efforts.

Email contact: brent.burbridge@usask.ca

Abbreviations

Commonly Used Abbreviations

Abbreviation	Description
ACR	American College of Radiology
ALARA	As Low As Reasonably Achievable
AP	Antero-Posterior (<i>view</i>)
CAR	Canadian Association of Radiologists
CT	Computed Tomography
CTA	Computed Tomography Angiography
CWC	Choosing Wisely – Canada
CXR	Chest X-Ray
C+	Post-Contrast Injection
Gy	Gray (<i>unit</i>) – the absorbed dose of radiation
Hu	Hounsfield Units
Hx	History
IV	Intravenous
LLQ	Left Lower Quadrant
LUQ	Left Upper Quadrant
MR	Magnetic Resonance (<i>also MRI</i>)
MRI	Magnetic Resonance Imaging (<i>also MR</i>)
MSK	Musculoskeletal
PA	Postero-Anterior (<i>view</i>)
PACS	Picture Archiving and Communication Systems
PET	Positron Emission Tomography
PE	Pulmonary Embolus
RLQ	Right Lower Quadrant
RUQ	Right Upper Quadrant
Sv	Sievert (<i>unit</i>) – the effective dose of radiation
US	Ultrasound (<i>also U/S</i>)
U/S	Ultrasound (<i>also US</i>)

Abbreviations

*(**Bold** abbreviations appear in the Commonly Used list)*

Abbreviation	Description
AAA	Abdominal Aortic Aneurysm
AC Joint	Acromioclavicular Joint
ACR	American College of Radiology
AHT	Abusive Head Trauma
AKI	Acute Kidney Injury
ALARA	As Low As Reasonably Achievable
AP	Antero-Posterior (<i>view</i>)
AVM	Arteriovenous Malformation
AVN	Avascular Necrosis
AXR	Abdominal X-Ray
BE	Barium Enema
BI-RADS	Breast Imaging Reporting and Data System
CAR	Canadian Association of Radiologists
CAT	Computed Axial Tomography
CDU	Colour Doppler Ultrasound
CES	Cauda Equina Syndrome
CIN	Contrast Induced Nephrotoxicity
COPD	Chronic Obstructive Pulmonary Disease
CSF	Cerebrospinal Fluid
CT	Computed Tomography
CTA	Computed Tomography Angiography (<i>CT Angiography</i>)
CT-PA	Computed Tomography – Pulmonary Angiography
CTR	Cardio-Thoracic Ratio
CTU	Computed Tomography Urography
CWC	Choosing Wisely – Canada
CXR	Chest X-Ray
C+	Post Contrast Injection
C1	Atlas (<i>first cervical vertebrae</i>)
C2	Axis (<i>second cervical vertebrae</i>)
DDx	Differential Diagnosis
DMSA	99mTc Dimercaptosuccinic Acid Scintigraphy
DSA	Digital Subtraction Angiography

DVT	Deep Venous Thrombosis
ECT	Electrocardiogram
ER	Emergency Room
ET	Endotracheal Tube
FNH	Focal Nodular Hyperplasia
GBCA	Gadolinium-Based Contrast Agents
GCS	Glasgow Coma Scale
GER / GERD	Gastroesophageal Reflux (<i>disease</i>)
Gy	Gray (<i>unit</i>) – the absorbed dose of radiation
HCC	Hepatocellular Carcinoma of the Liver
HCG	Human Chorionic Gonadotropin (<i>hormone</i>)
HPS	Hypertrophic Pyloric Stenosis
HRCT	High Resolution Computed Tomography
HU	Hounsfield Units
Hx	History
IIH	Idiopathic Intracranial Hypertension
IM	Intramuscular
IV	Intravenous
IVC	Inferior Vena Cava
LBP	Low Back Pain
LLQ	Left Lower Quadrant
LMWH	Low-Molecular Weight Heparin
LUQ	Left Upper Quadrant
L1	First lumbar vertebrae
MCP	Metacarpal-Phalangeal Joint
MEN	Multiple Endocrine Neoplasia
MR	Magnetic Resonance (<i>also MRI</i>)
MRI	Magnetic Resonance Imaging (<i>also MR</i>)
MRT	Medical Radiation Technologist
MSK	Musculoskeletal
NSF	Nephrogenic Systemic Fibrosis
OA	Osteoarthritis
OAR	Ottawa Ankle Rules

PA	Postero-Anterior (view)
PACS	Picture Archiving and Communication Systems
PET	Positron Emission Tomography
PE	Pulmonary Embolus
PICC	Peripherally Inserted Central Vein Catheter
RA	Rheumatoid Arthritis
RIS	Radiology Information System
RLQ	Right Lower Quadrant
RUQ	Right Upper Quadrant
SDH	Subdural Hematoma
SUV	Standardized Uptake Value
SVC	Superior Vena Cava
Sv	Sievert (unit) – the effective dose of radiation
TAS	Transabdominal Sonography
TC	Toxic Colitis
TIA	Transient Ischemic Attack
TM	Toxic Megacolon
t-PA	Tissue Plasminogen Activator
TVS	Transvaginal Sonography
UGI (<i>tract</i>)	Upper Gastrointestinal (<i>tract</i>)
US	Ultrasound (also U/S)
U/S	Ultrasound (also US)
UTI	Urinary Tract Infection
VTE	Venous Thromboembolism
VUR	Vesico-ureteric Reflux
WT	Wilms Tumor
99mTc	Technetium 99m (<i>also known as Tc-99m</i>)

Acknowledgements

This e-Book was inspired by our desire to provide an opportunity for Undergraduate students to find a local resource they could use to enhance their knowledge of Diagnostic Radiology (Imaging).

We wish to acknowledge the support of the Gwenna Moss Teaching Centre and the Distance Education Unit of the University of Saskatchewan for their involvement in this project. In particular, Heather Ross and JR Dingwall provided valuable guidance and greatly facilitated the development of this teaching resource.

Additionally, the genesis of this project began years ago due to the generosity and vision of the Royal University Hospital Foundation, the SaskTel Corporation, and the College of Medicine. We greatly appreciate having the opportunity to enhance teaching and learning through their support.

I would personally like to thank Evan Mah, who has worked diligently to make this e-Book a reality. His work ethic and enthusiasm were greatly appreciated. His perspective as a keen learner of the health sciences has helped this project take shape.

Dr. Anurag Dalai assisted us by proof-reading the eBook. We thank him for his thorough work.

We also wish to acknowledge the love and friendship of our families and friends who have supported us on our journey along the path of higher learning.

The cover page of this book pays homage to the first diagnostic radiograph of the hand, created by Dr. William Conrad Röntgen in his seminal work introducing a new and mysterious light – x-rays. We are thankful for his ingenuity and curiosity.

Chapter 1 – Introduction

Online DICOM Image Viewer (ODIN): An Introduction and User Manual

Throughout this eBook you will find images of normal anatomy, normal scans, and images of abnormalities. These static images are simple JPEG files, and although they will be helpful to you in learning the content, they do not accurately represent the imaging that clinicians would use in their practice. To do so, one would require a Picture Archiving and Communication System (PACS), which allows clinicians to interact with the image by zooming, changing level and window, annotate with circles, arrows and text, and scroll through image data sets.

To help fully appreciate normal anatomy and pathology, you have access to an Online Dicom Image Navigator (ODIN), which gives you access to a more extensive imaging database, in a PACS-like format. They additional images associated with a case are available by clicking the ODIN Link. It will enrich your imaging experience if you take advantage of the additional learning material in the ODIN image repository.

ODIN is not a fully functional PACS software suite but it will give you the chance to view the images with some enhanced features that simulate a PACS. The only images that you can change the level and window for are CT images. You can pan, zoom, scroll, through image data sets. You are also able to annotate, and save, the images in the database for your own teaching and learning strategies. The links to the ODIN content are provided below the thumbnail image(s) in the eBook.

You are also able to search and view other cases in ODIN, to help improve your understanding and exposure to the various imaging techniques and abnormalities. There are many other interesting cases in ODIN.

ODIN User's Guide – Laptop or Desktop Web Browser

Version 1.4 – June 1,2017

ODIN (Online Dicom Image Navigator) is a server based, HTML5, DICOM image viewer that displays cases created in the U of S MIRC Teaching File. The cases displayed are images without text or reports. The images are anonymized to protect patient confidentiality. **Do not use Internet Explorer as your browser.** We suggest Firefox, Goggle Chrome, or Safari.

ODIN images can also be accessed specifically by using their case specific urls. These urls can be embedded in a slide, document, or pdf.

ODIN Link for ODIN Home/Search page: <https://mistr.usask.ca/odin/>

Table of Contents – ODIN

1. ODIN Search Page
2. General Image Display
3. General Toolbar
4. Image Annotation Tools / Colour Palette Tool
5. Angle Measurement Tool
6. Unselect the “Annotation Tool”
7. Download Image and Annotations Tool
8. Image Sets with Multiple Stacked Images (CT, MR, US)
9. Looping Speed Tool
10. Move/Pan Tool
11. Zoom Tool
12. Reset Image (*window values, zoom, position (pan), rotation, etc.*) Tool
13. Directory / Open a New Teaching Case Tool
14. Image Layout Tool
15. Toggle Text Overlay Tool
16. View Metadata Tool
17. Use the Window Tool
18. Set Window Center and Width Values Tool
19. Vertical Flip Tool
20. Horizontal Flip Tool
21. Rotate Image Left (*counter clockwise*), Rotate Image Right (*clockwise*) Tool

1. ODIN Search Page

If you access ODIN via the home page or search page you must search for a case using the search tool that appears.

There are multiple libraries available in MIRC that can be searched, as a whole, or one can select specific libraries for searching. You can toggle the libraries on or off and you can select specific libraries by using the radio buttons. Enter your search criteria in the search box and hit the return key or the “Search” radio button. You can curtail your search by keywords and the pull down menus next to the “Search” button.

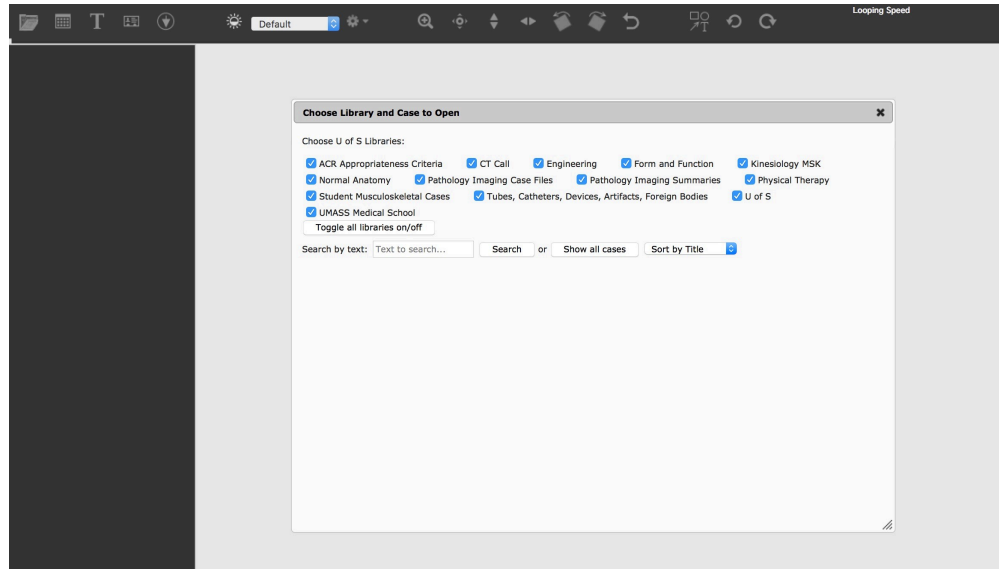


Figure 1.1 ODIN Search Page.

This viewer can also be activated when you click on a link in the U of S BlackBoard Learn LMS if your class has incorporated imaging links into the course content. If you select a link in BlackBoard Learn you will be directed to the case specifically, bypassing the case directory in ODIN. A new page will open in your web browser displaying the images for the case you selected while in BlackBoard Learn.

2. General Image Display

All of the images available in the case are displayed as thumbnails on the left when the case first opens. The default image view is a single image filling the viewing pane.

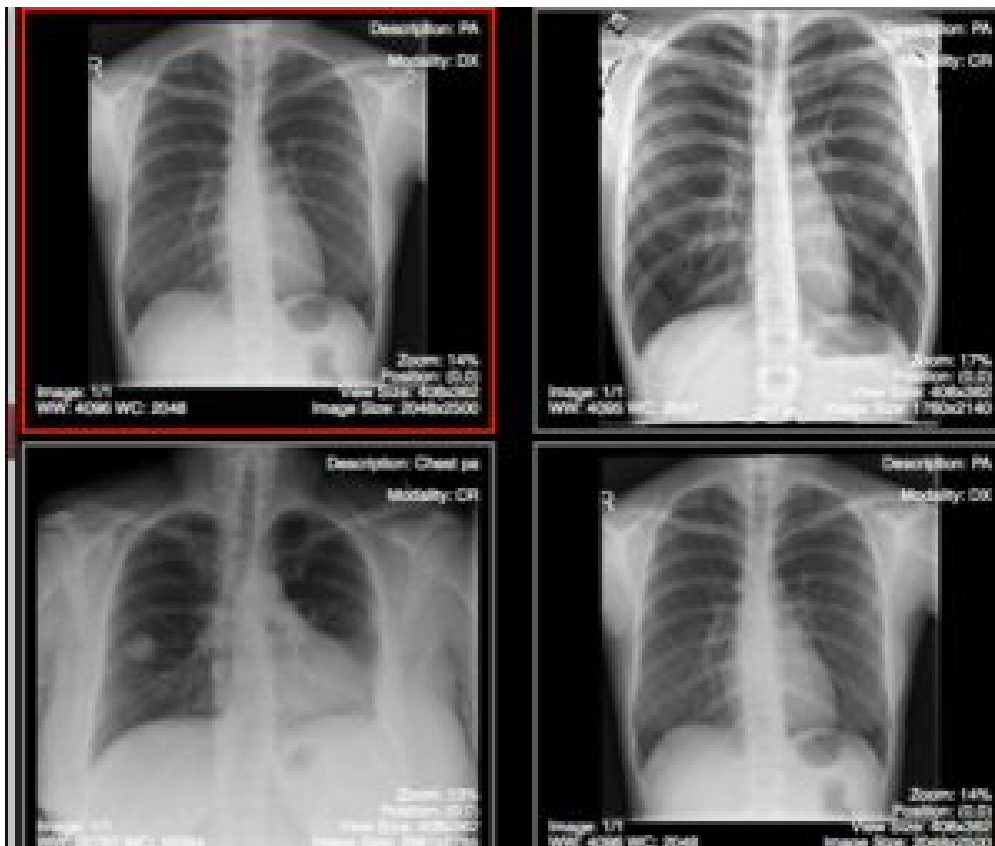


Figure 1.3 ODIN, Selecting an Image

You can left click the other thumbnail images to activate them in the main image viewer.

You can view and alter the appearance of the displayed images but it is not possible for you to alter, damage, erase, or destroy the cases stored in the ODIN viewer.

If necessary, you can export any image that you have altered or annotated. These images you have created can be used for teaching, examinations, learning, or research purposes. If you use any images for these purposes please acknowledge the source in your work.

3. General Toolbar

There is a tool bar across the top of the window. This has a variety of image viewing features. If you hover your pointer over the icon a pop-up box will identify the task this icon will execute.




Figure 1.4 ODIN General Toolbar

4. Image Annotation Tools/Color Palette Tool

The Image Annotation icon allows you to select the line, arrow, circle, box, text tool, and angle measurement tool.

The line tool also acts as a ruler and there is an angle measurement tool as well.

The color panel next to this tool allows you to select a color for your annotation activities. Different colors can be displayed on the same image.

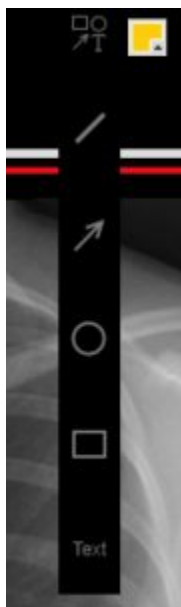

Figure 1.5 ODIN Image Annotation Toolbar

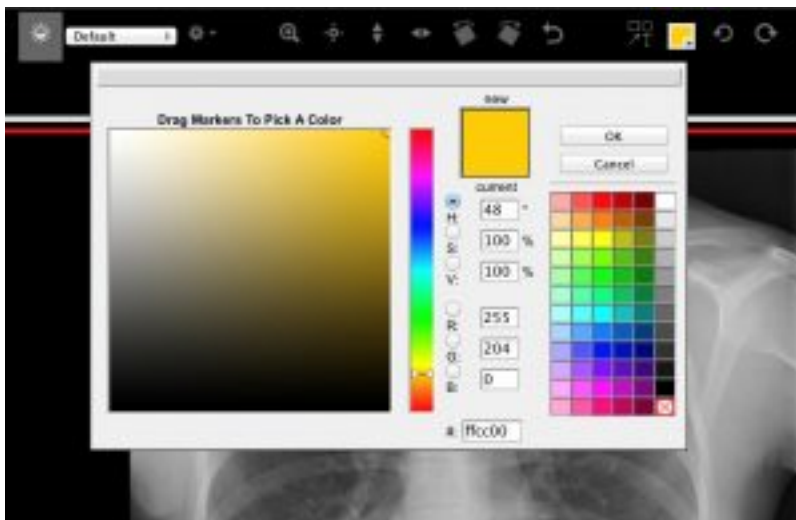

Figure 1.6 ODIN Colour Palette Toolbar

5. Angle Measurement Tool

This tool allow you to measure angles. To use, activate the tool in the pull down menus, click on the first anchor point and drag to the next anchor point, release the mouse button, then move your mouse to the next anchor point and click. An angle, with the numerical measurement will be displayed.

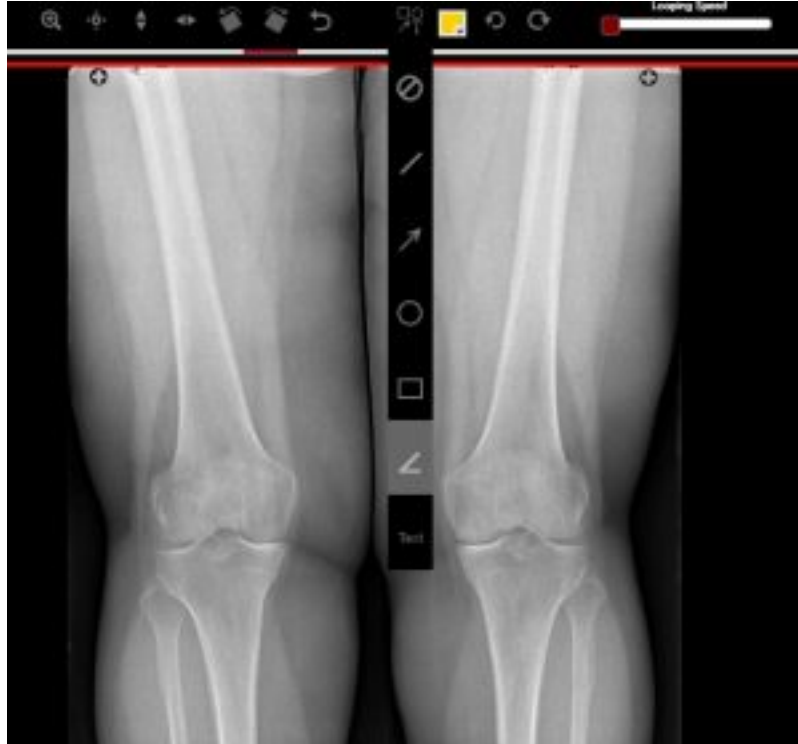

Figure 1.7a ODIN Angle Measurement Tool

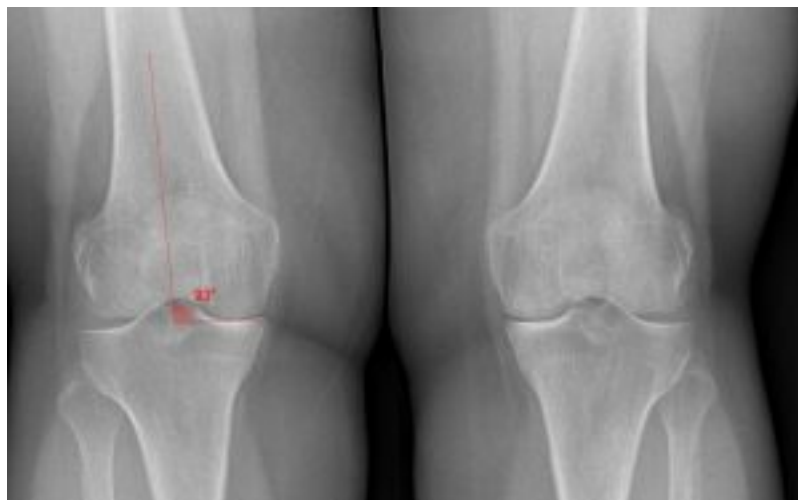

Figure 1.7b ODIN Angle Measurement Tool (closeup)

6. Unselect the “Annotation Tool”

In order to deactivate or unselect the Annotation tool you currently have in use the “Unselect Annotation” tool.

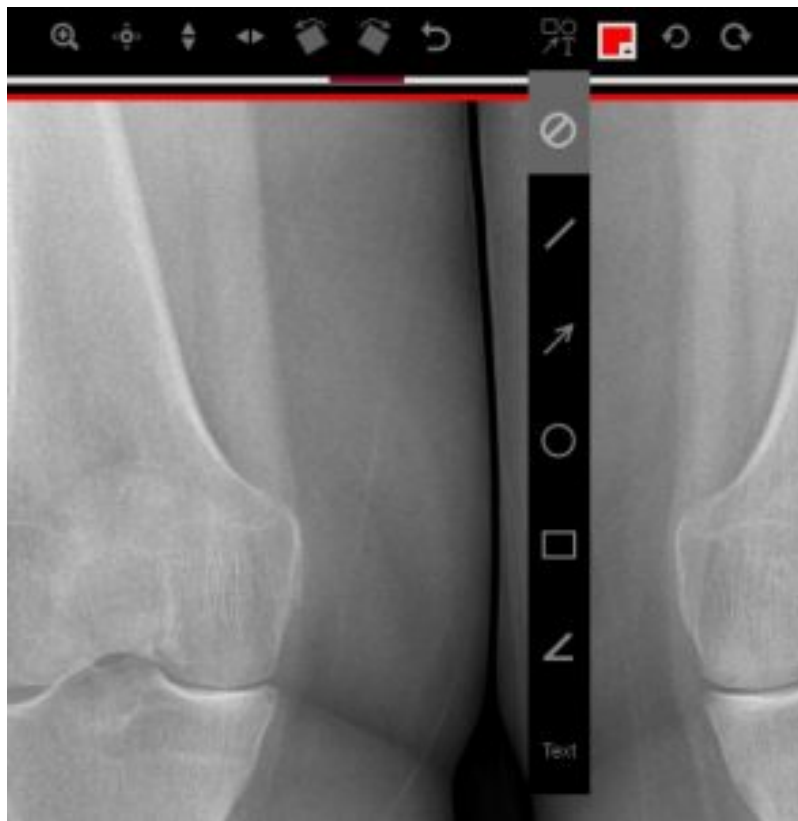

Figure 1.8 ODIN “unselect” annotation tool

7. Download Image and Annotations Tool

The downward pointing arrowhead in the tool bar allows you to download the displayed image for use in lectures, PowerPoint talks, and for assignments. This will be used when you have completed the annotation of an assignment image and wish to download it to save and send to the instructor for grading.



Figure 1.9 ODIN Download Image with Annotations

After you left click this icon you will be presented with the following instructions for downloading the image in the viewer pane.

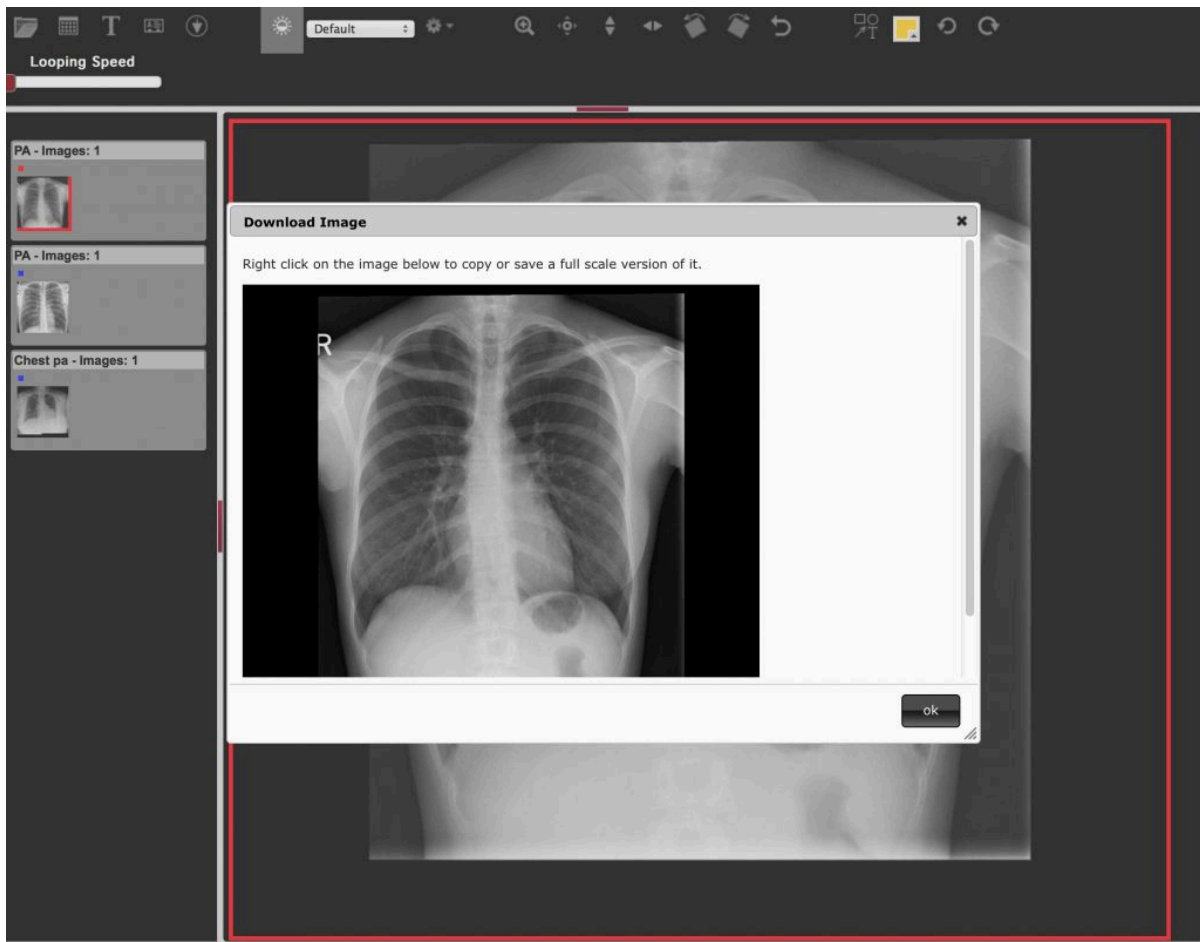


Figure 1.10 ODIN Download Image Instructions Pane

8. Image Sets with Multiple Stacked Images (CT, MR, US)

If a case has stacked images you will see the full image set in the thumbnail list as multiple small boxes. At the bottom of these stacked, small, boxes, you will see three larger thumbnails. These represent the first, the middle, and the last image in the stack. You can click on them to move to these images. You will see in the small box display that the currently viewed image is highlighted with a small red box. The middle and last images are small blue boxes. You can select any one of the small boxes to go directly to that image in the stack.

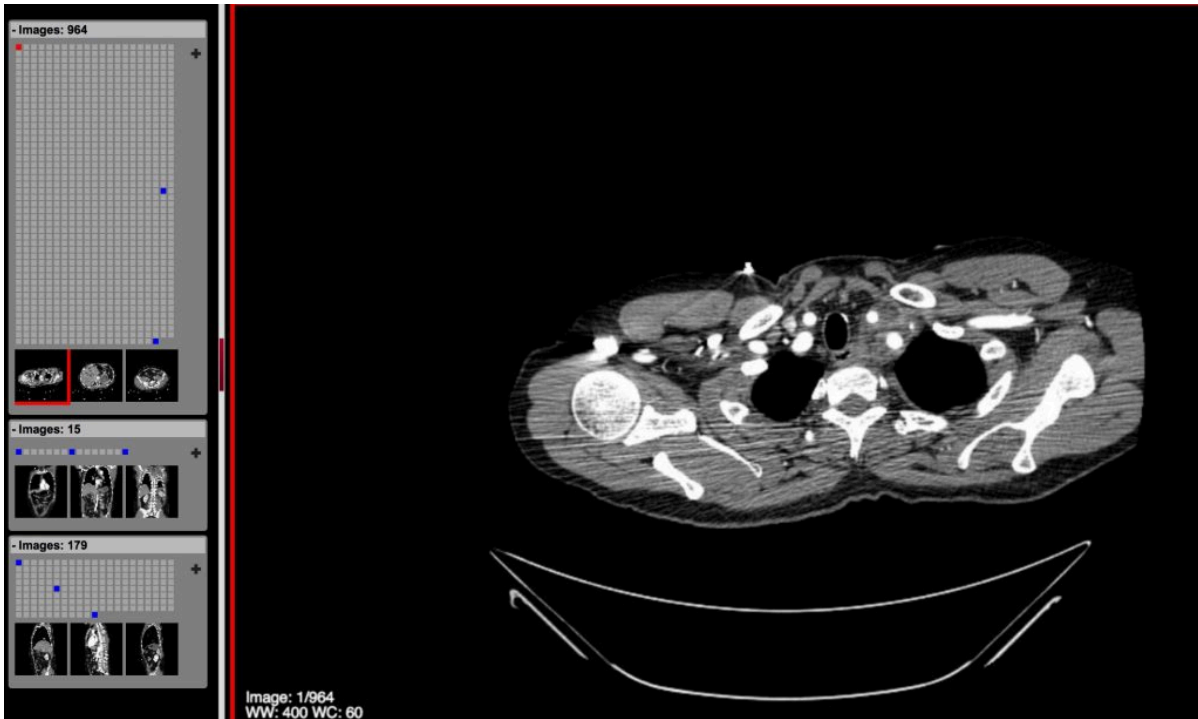

Figure 1.11 ODIN Image Stack

9. Looping Speed Tool

If you are viewing a image data set that is a stacked image series i.e. sequential images anatomically stacked from cranial to caudal or right lateral to left lateral, you can view these like a cine movie clip. This is something that could be an option for sequential MRI, Ultrasound, CT, or Angiography images. To activate this function slide the red button on the Looping Speed Tool to the right and adjust the speed to suit yourself. To stop looping, slide the red button back to the far left and release it. **Do not try and stop the Looping Tool by reloading the web page as this will generate an error and you will need to restart your browser. Crashing on reload happens with Mac Safari but not with Firefox.**

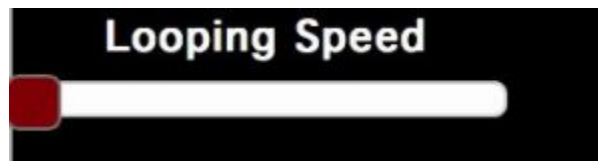

Figure 1.12 ODIN Looping Speed Tool

10. Image Set Scroll Bar

When an image set is available that allows for scrolling you will also see a scroll bar on the right side of the image pane in the viewing window. You left click, hold, and drag this red slider tool to scroll through the image set. This is important for viewing sets of CT, Ultrasound, MRI, and Angiography images if they have been saved as a cine type image set.

11. Move/Pan Tool

The Move or pan icon allows you to move the zoomed image in the viewing pane to see different regions of the image in the magnified format.

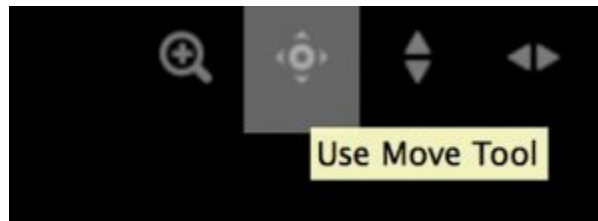


Figure 1.13 ODIN Image Move/Pan Tool

12. Zoom Tool

The image Zoom tool allows you to magnify the image in the viewing pane.



Figure 1.15 ODIN Zoom Tool

Below, you will see the zoomed appearance of the heart shadow zoomed from the original image in this case. Due to the nature of the image format being displayed, it is possible to zoom the image quite substantially without losing image detail.

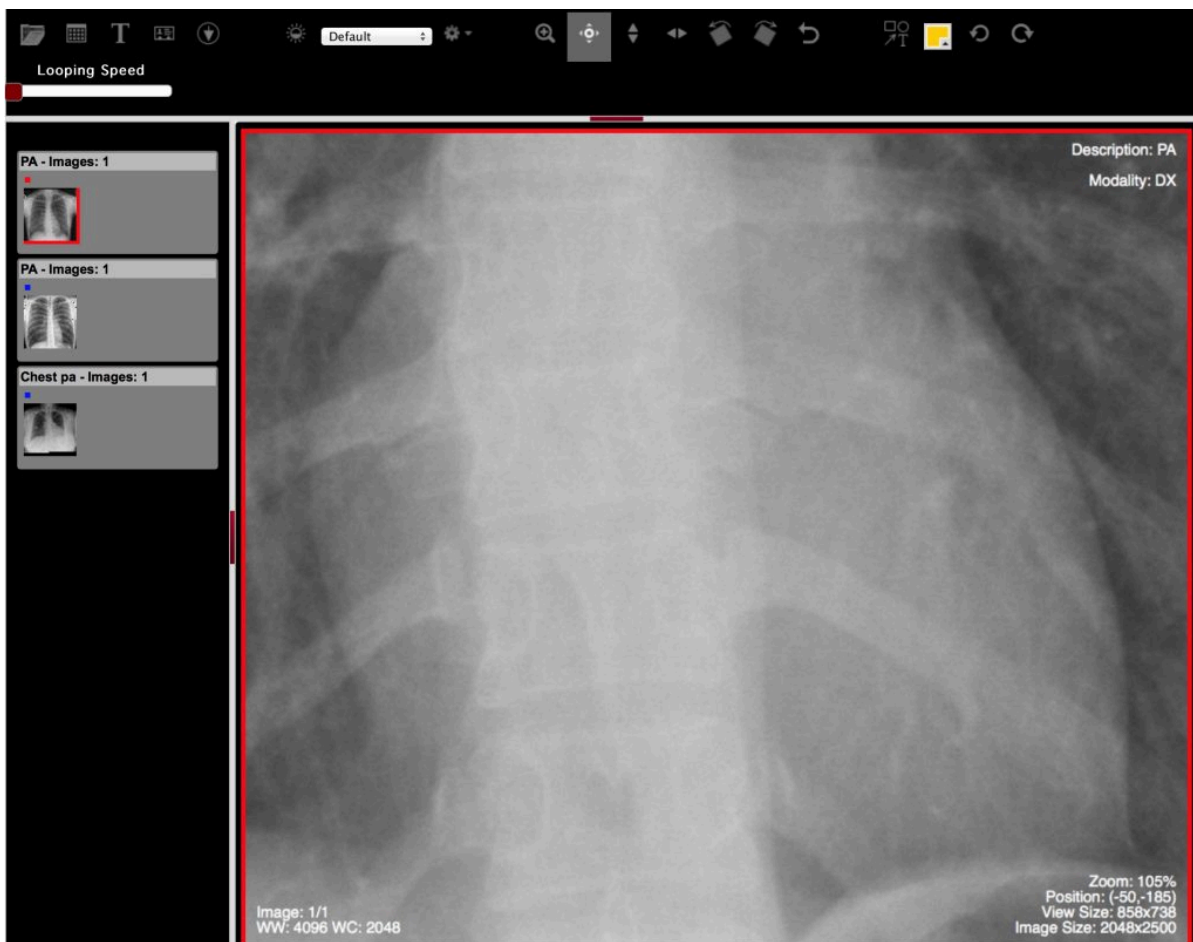


Figure 1.16 ODIN Zoomed In Image View

13. Reset Image (Window Values, Zoom, Position (Pan), Rotation, etc.) Tool



Figure 1.17 ODIN Reset Image Tool

As the tool name implies, this will reset the image to the native state of the original case.

14. Directory/Open a New Teaching Case Tool

If you accidentally close the ODIN web page you can retrieve it by clicking the link in the BlackBoard Learn page you were on. However, you will have lost any image changes you made using the tool bar icons unless you saved them as downloaded images. The ODIN case always reverts back to the native state of the case saved in the server.

You can see the other cases stored in the ODIN directory by left clicking the file folder icon on the top left of the toolbar. You will be presented with the Search Tool to look for other cases of interest.

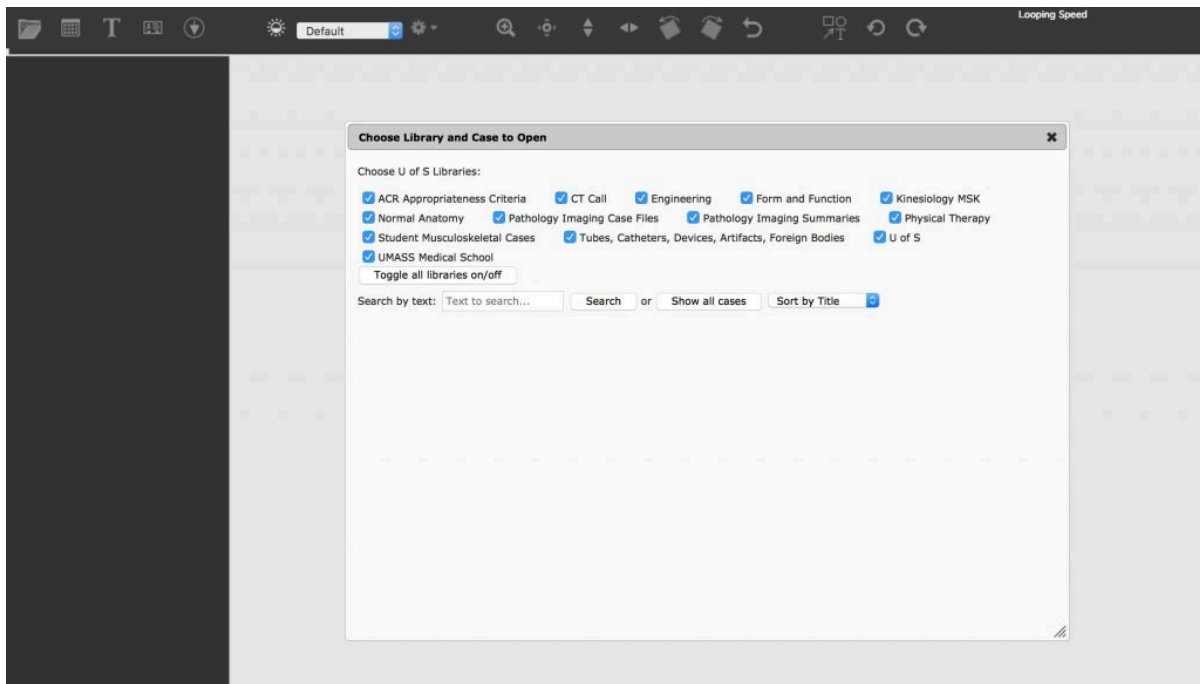


Figure 1.18 ODIN Directory Tool

15. Image Layout Tool

The default image layout is a single image filling the viewing pane. You can adjust how many images are displayed in the main image pane, left click the second icon in the upper tool bar. This icon allows you to change the layout of the main image viewing pane. A box will appear over the image viewing pane that allows you to select the image tile formation.

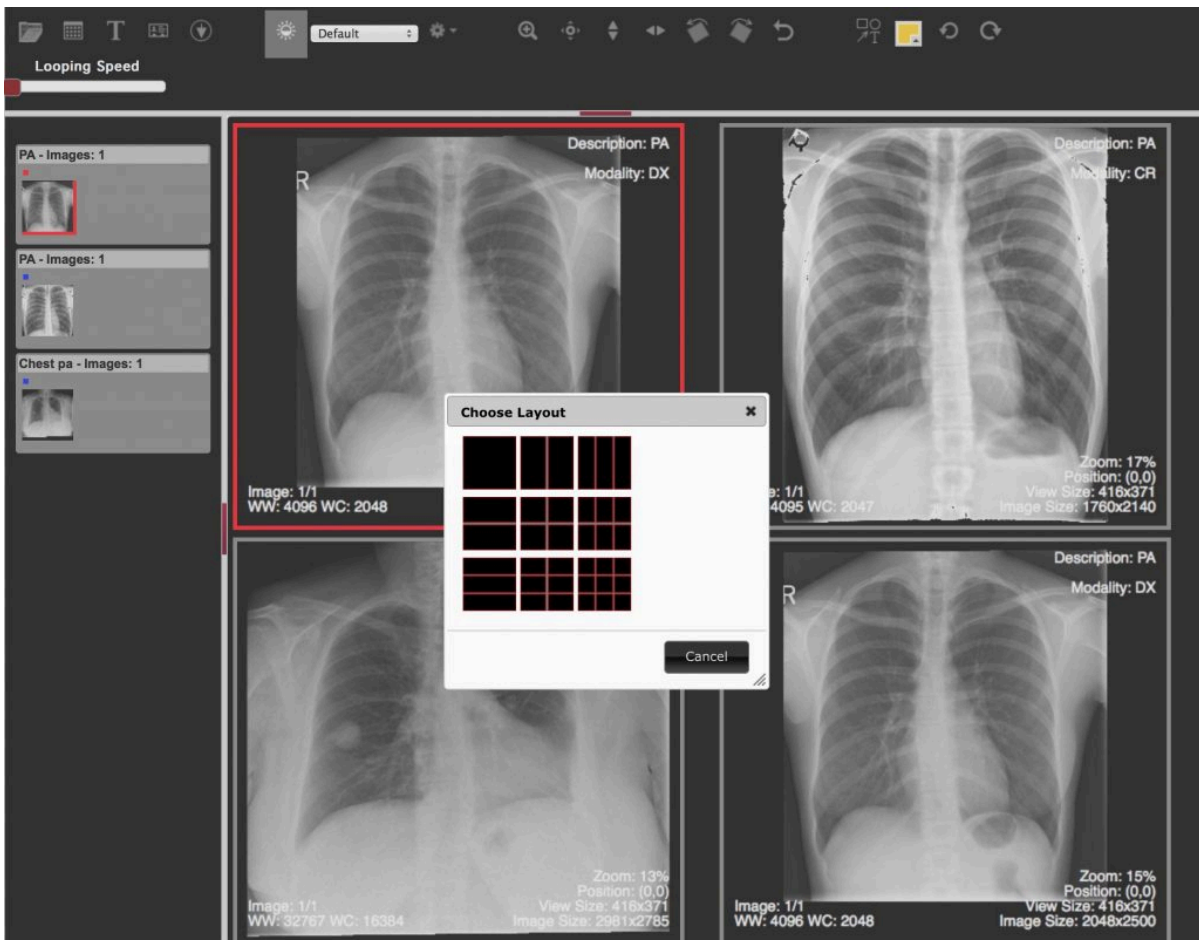


Figure 1.19a ODIN Image Layout Tool (multiple)

For example, if you left click on the top left, single active image in the thumbnail list will be displayed one at a time in the viewing pane, as shown below. To see the next thumbnail image in a single plane, left click that thumbnail.

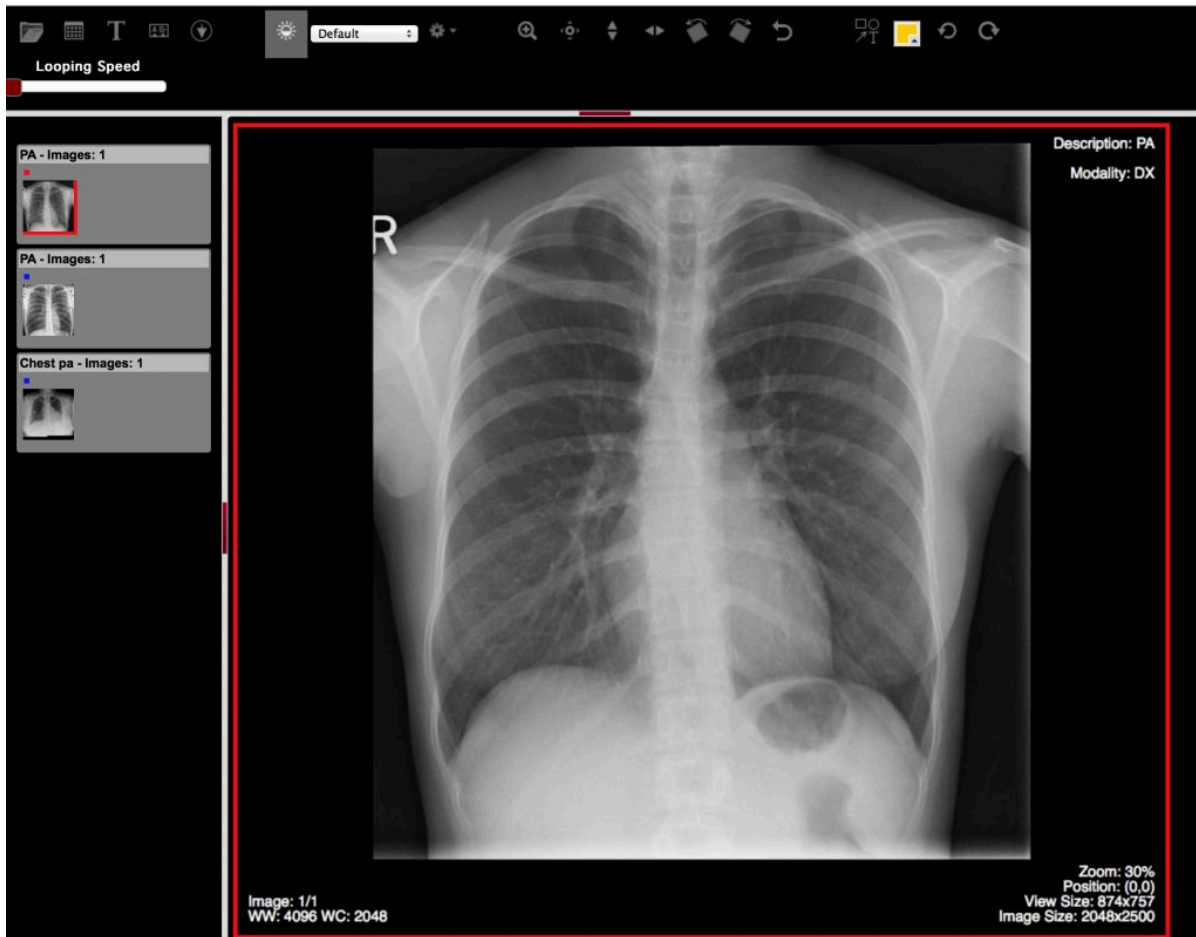


Figure 1.19b ODIN Image Layout Tool (single)

16. Toggle the Text Overlay Tool

Left clicking the “T” icon in the toolbar will toggle the text elements of the image off and on as seen below.

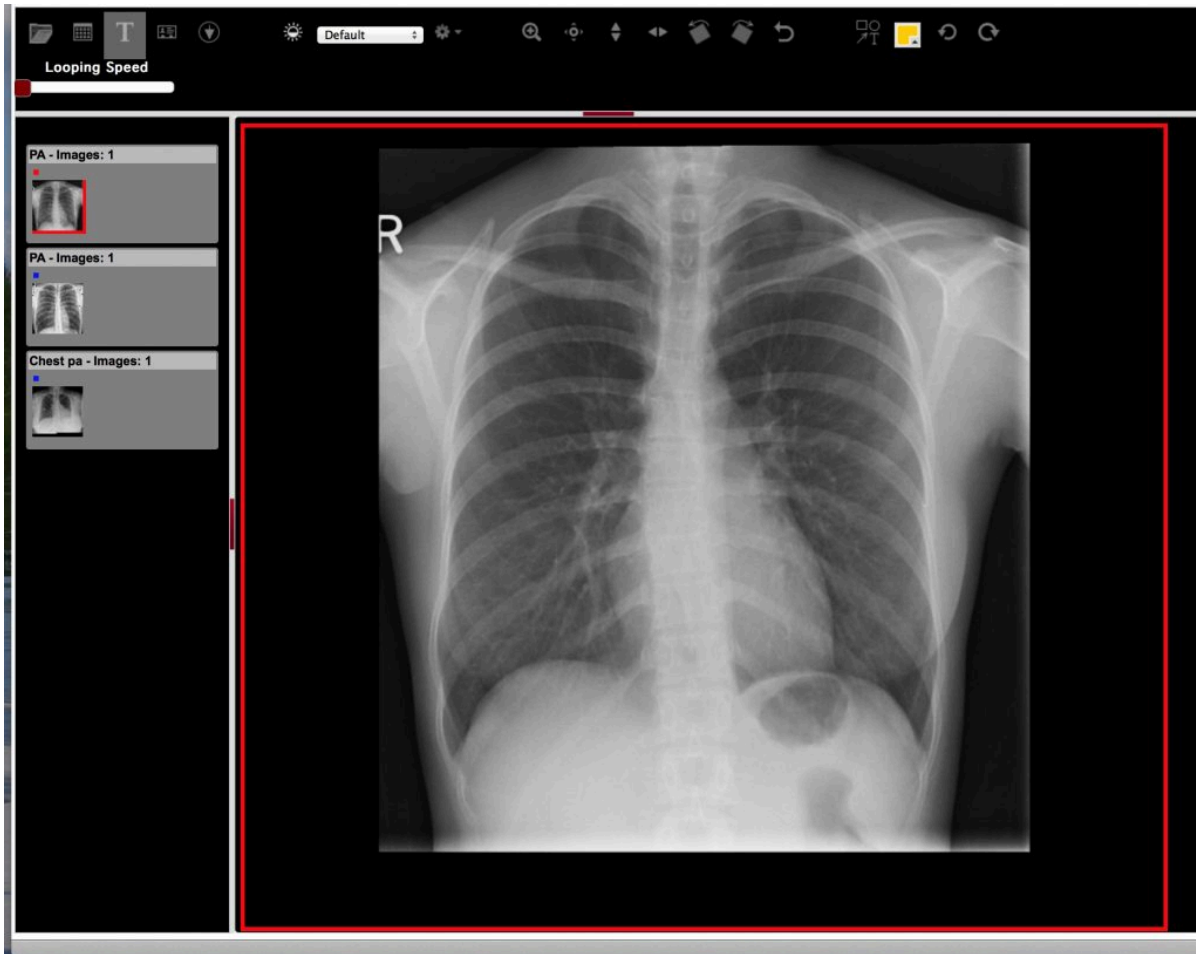


Figure 1.20 ODIN Text Overlay Tool

17. View Metadata Tool

If you wish to view all of the available, textual, metadata for the image being displayed, left click the metadata icon and the background metadata will be displayed.

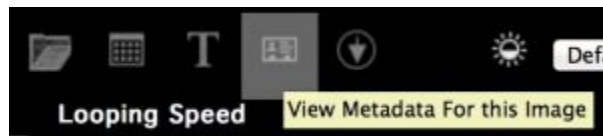


Figure 1.21a ODIN View Metadata Tool (button)

The available metadata is displayed in a separate box overlying the image.

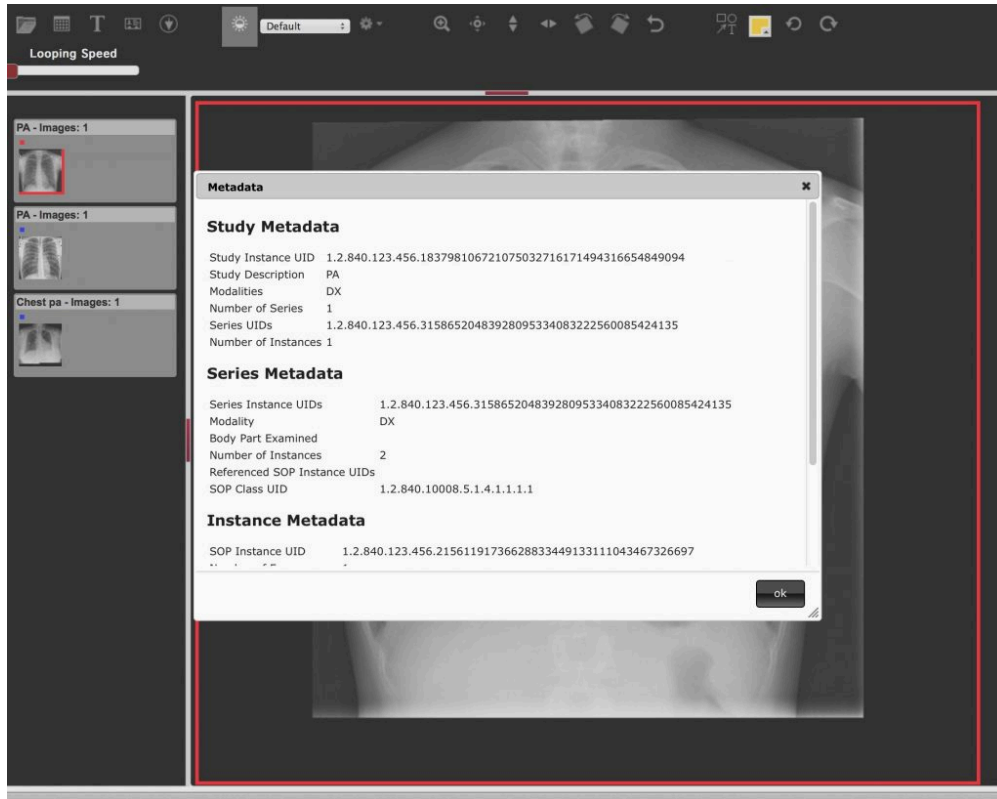


Figure 1.21b ODIN View Metadata Tool (dialog box)

18. Use the Window Tool

All of the images displayed are presented with the window/level (brightness/contrast) optimally displayed for the type of image being viewed i.e. ultrasound, x-ray, etc. Left clicking this icon will allow you to change the window/level of the image being viewed using the pull down menu to the right of this icon once you activate this feature.



Figure 1.22a ODIN Use the Window Tool (button)

This is only pertinent for Computed Tomography (CT), as the image window/level for these types of images can be altered to optimally view different anatomic content i.e. bones, lungs, etc. The pull down menu allows you to select the features you wish to accentuate on the active window view pane.



Figure 1.22b ODIN Use the Window Tool (drop menu)

19. Set Window Center and Width Values Tool

If you feel that it would be optimal to manually adjust the window/level, you can enter in numerical units that will alter the image appearance to suit your purposes.



Figure 1.23a ODIN Window Center and Width Tool (button)

The dialogue box below will appear allowing you to adjust the image as you see fit.

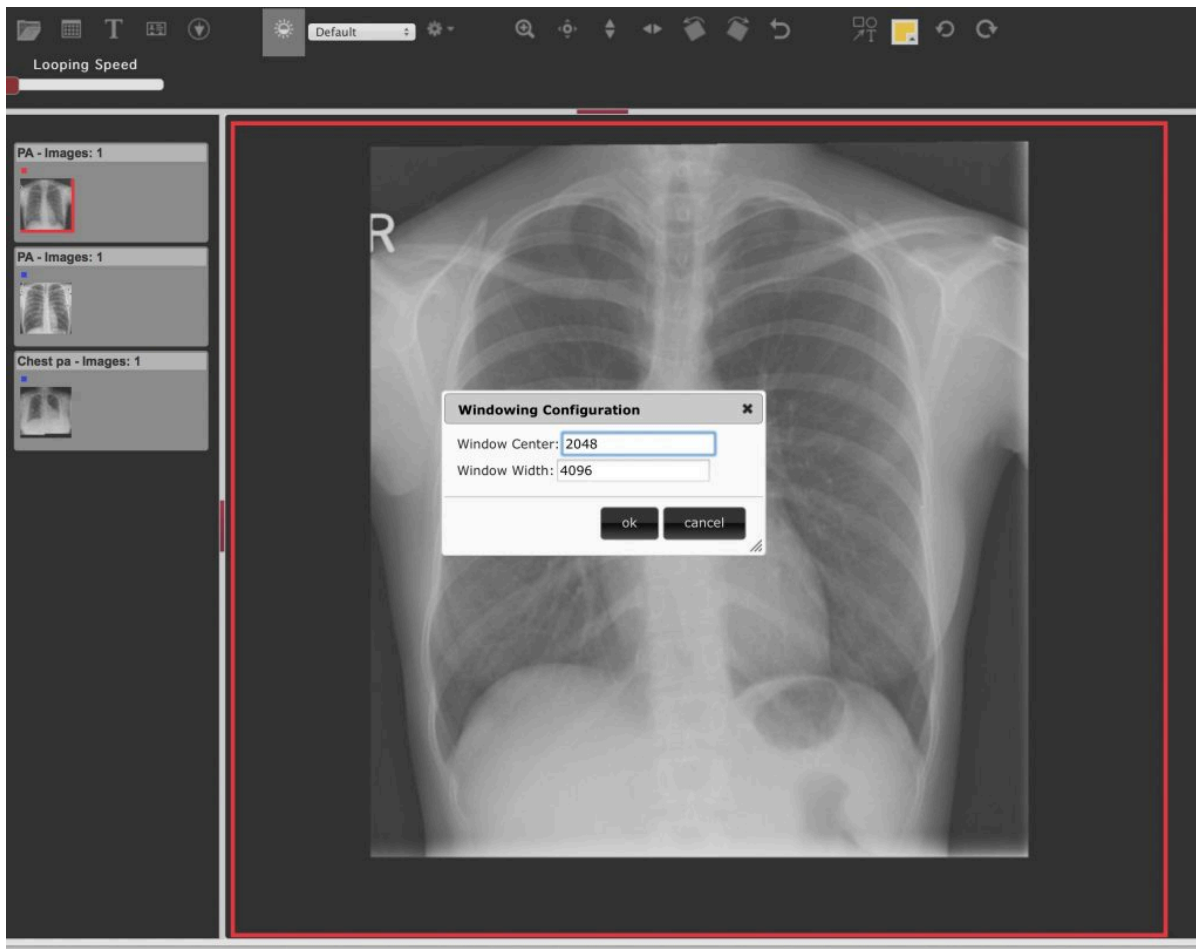


Figure 1.23b ODIN Window Center and Width Tool (dialogue)

20. Vertical Flip Tool

The two arrowheads pointing up and down allow you to flip the image in the vertical plane.

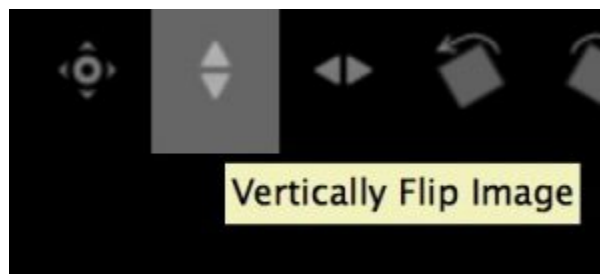

Figure 1.24a ODIN Vertical Flip Tool (button)

See below:

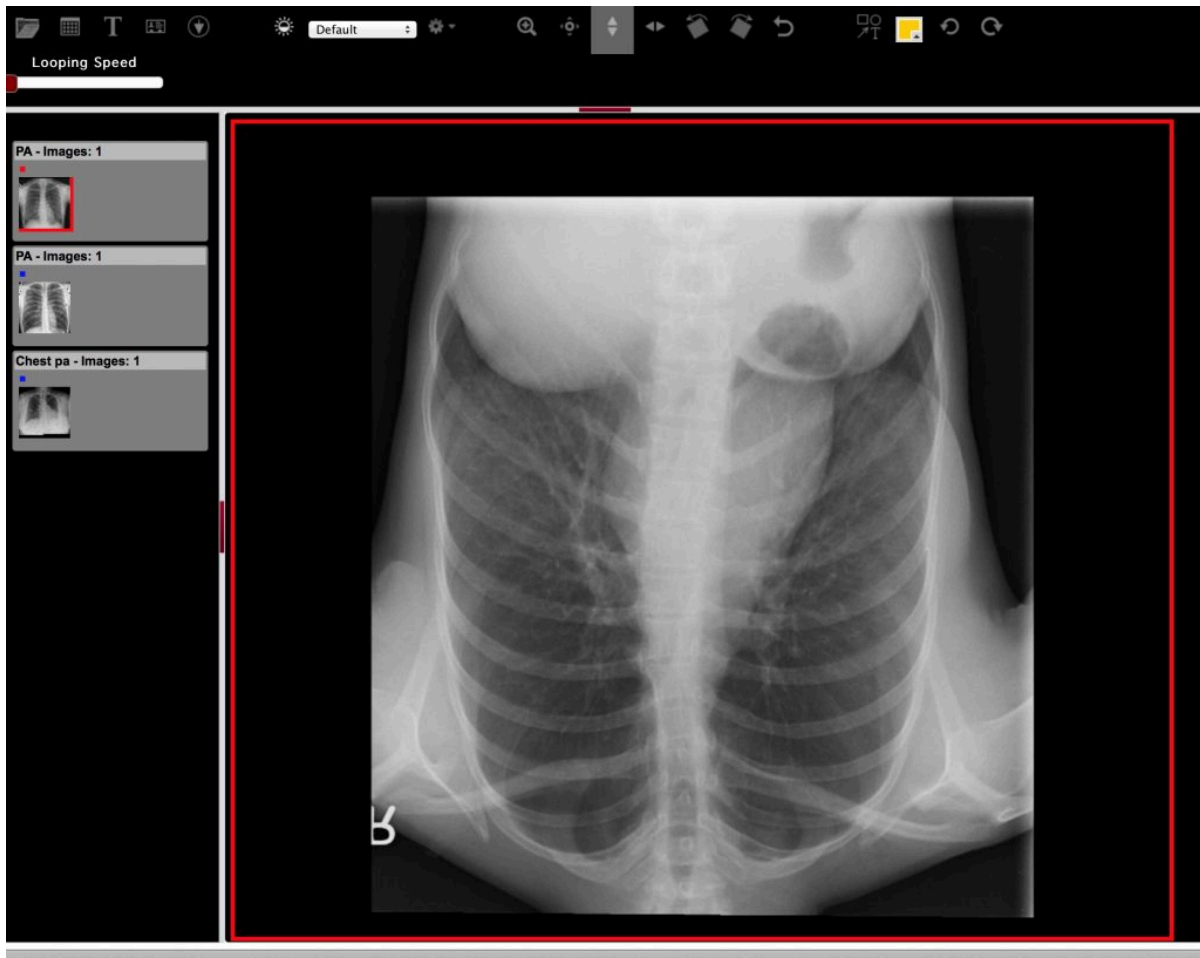


Figure 1.24b ODIN Vertical Flip Tool (result)

21. Horizontal Flip Tool

The two arrowheads pointing left and right allow you to flip the image on the horizontal plane.

See below.

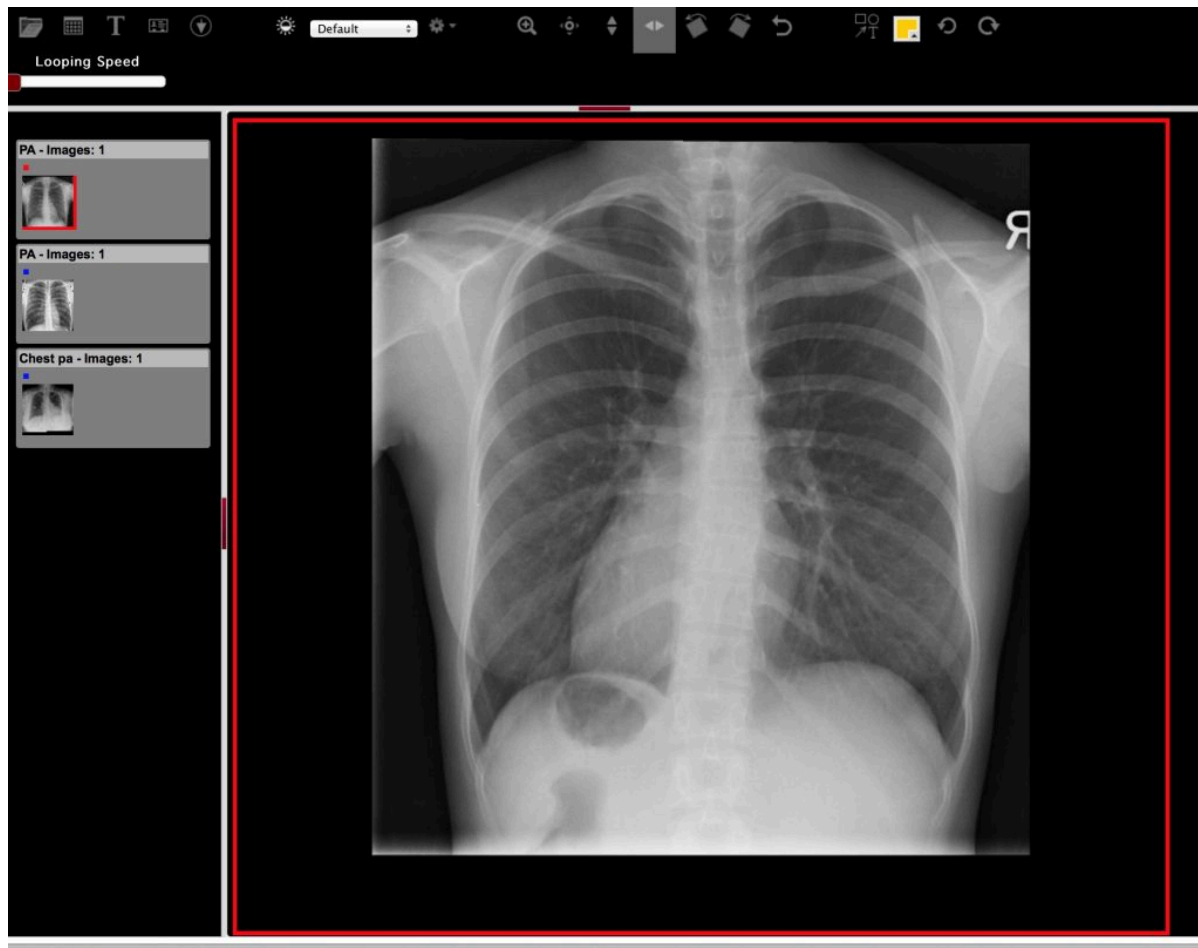


Figure 1.25 ODIN Horizontal Flip Tool.

22. Rotate Image Left (Counter Clockwise), Rotate Image Right (Clockwise) Tool

The grey boxes with the circular arrows over them allow you to rotate the image in the direction identified in 90 degree increments, you can rotate the image through the 360 degree circle. See below.

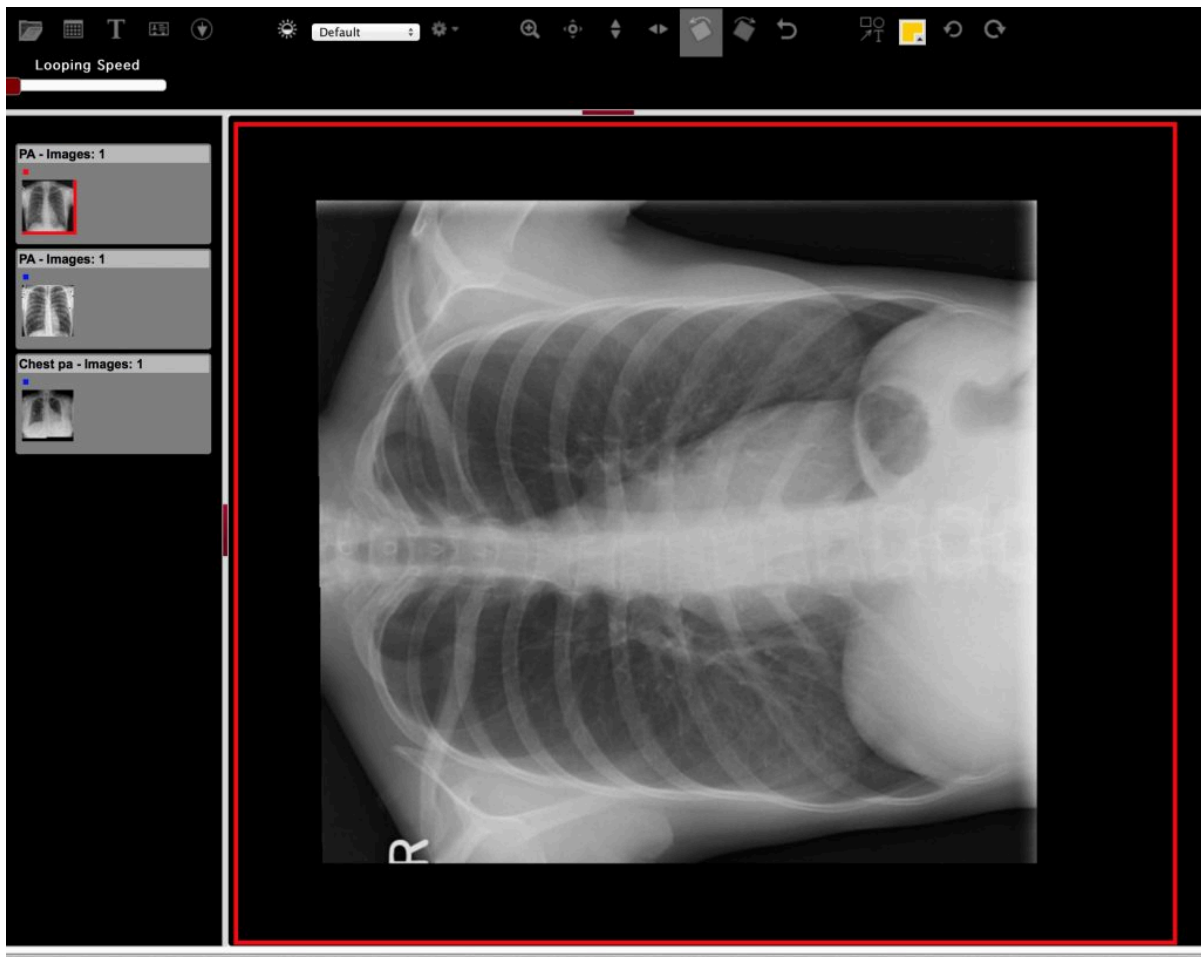


Figure 1.26a ODIN Rotate Image Tool (counter clockwise)

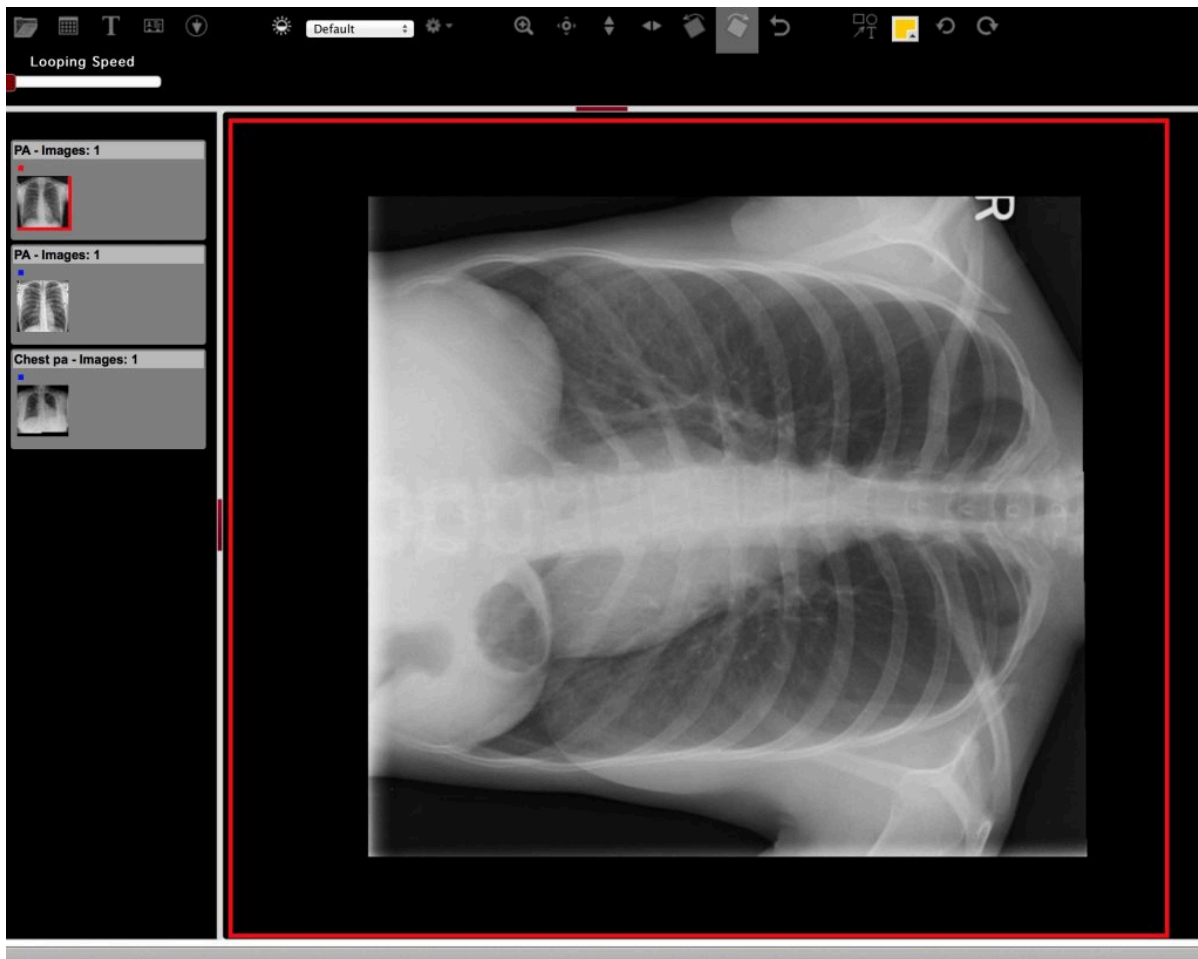


Figure 1.26b ODIN Rotate Image Tool (clockwise)

Attributions

All images in this chapter by Dr. Brent Burbridge MD, FRCPC, University Medical Imaging Consultants, College of Medicine, University of Saskatchewan is used under a [CC-BY-NC-SA 4.0](https://creativecommons.org/licenses/by-nc-sa/4.0/) license.

CanMEDS Roles

CanMEDS Roles Pertinent to Undergraduate Medical Education

In the 1990s the Royal College of Physicians and Surgeons of Canada began to develop the “Canadian Medical Education Directives for Specialists” (CanMEDS) to identify the roles and competencies of physicians in order to improve patient care. The latest iteration of CanMEDS was released in 2015. This framework identifies the following seven central roles, which can be applied to undergraduate radiology education:

1. Medical Expert

The Practitioner will:

- After patient assessment, formulate a care plan that may include requesting imaging examinations
- Know the imaging resources available in their community and how to access them
- Have general knowledge of the indications for imaging examinations based upon guidelines, and other sources of evidence
- Be familiar with guidelines for imaging created and distributed by organizations such as, the Canadian Association of Radiologist (CAR) and the American College of Radiology (ACR)
- Have a general understanding of the strengths and weaknesses of different imaging modalities
- Have knowledge of the relative radiation exposure of different imaging modalities
- Consult with a radiologist if they are uncertain about the best examination to request after clinical assessment
- Apply knowledge of anatomy to the review of imaging examination

2. Communicator

The Practitioner will:

- Explain to the patient the rationale behind ordering imaging examinations

- Explain to the patient, in general terms, what to expect when the imaging examination is performed
- Ensure that a completed request for a medical imaging examination will be sent to the most appropriate imaging centre
- Ensure that the request includes relevant clinical information, and specifies the most likely diagnosis, to facilitate optimal image acquisition and interpretation
- Convey the degree of urgency for the imaging examination when submitting the imaging request
- Provide information about imaging examinations already completed when referring a patient for care elsewhere
- Communicate with an imaging specialist, who can assist in determining the best examination, or arranging alternative examinations, if necessary
- Communicate with an imaging specialist if the interpretation of an imaging examination is urgent or if the interpretation provided is not concordant with the clinical assessment
- Communicate the results of the imaging examinations to patients and their families (if consent for this has been obtained)

3. Collaborator

The Practitioner will:

- Establish, and maintain, positive, collaborative working relationships with members of the imaging team to facilitate patient examinations and results
- Utilize the human resources and infrastructure in their work environment to facilitate and expedite imaging investigations and the conveyance of results to the patient

4. Leader

The Practitioner will:

- Adopt the strategies of quality assurance and patient safety to enhance patient care
- Ensure that optimal management strategies are in place to receive the results of imaging examinations personally, or via an office setting, particularly when the practitioner works from multiple clinical settings
- Adopt information technologies that enhance access to images and reports that can be shared with patient, and their families

5. Health Advocate

The Practitioner will:

- Advocate on behalf of their patient with honesty and integrity
- Determine if a patient's clinical situation deteriorates, warranting more urgent imaging, and notify the appropriate imaging facility
- Promote access to the most appropriate imaging technology available within their scope of practice
- Take into consideration the radiation dose of imaging technologies available with a general understanding of radiation protection/radiobiology

6. Scholar

The Practitioner will:

- Undertake to have knowledge of epidemiology, biostatistics, and decision analysis, that are integral in applying evidence based decisions in healthcare
- Be aware of current guidelines for imaging examinations and appropriateness criteria will be applied when available
- Engage in maintenance of competence activities that enhance knowledge about utilization of imaging
- Critically evaluate current literature to shape decision making
- Facilitate the learning of patients, families, students, residents, other health professionals, and staff about pertinent imaging related topics that may effect health, safety and clinical care

7. Professional

The Practitioner will:

- Exhibit appropriate professional behaviors in practice, including honesty, integrity, commitment, compassion, respect and altruism
- Manage conflicts of interest
- Appreciate the professional, legal and ethical codes of practice pertinent to imaging

CAR – Diagnostic Imaging Referral Guidelines

The *2012 CAR Diagnostic Imaging Referral Guidelines* were introduced with the aim of assisting referring health-care workers in making decisions pertaining to more appropriate imaging studies for specific cases.

- These Referral Guidelines were not intended to restrict the clinical decision making process.
- The Referral Guidelines are evidence-informed and are based on expert opinion or case studies.
- The guidelines are not meant to prevent the ordering of imaging examinations as the referring health-care provider has the ultimate responsibility for what they feel is in the patient’s best interest.
- Discussion between the radiologist and the healthcare team, particularly during multidisciplinary team meetings, must always take precedence over guidelines.
- The guidelines were last revised in 2012.

For More Information:

CAR Imaging Referral Guidelines Website – <http://www.car.ca/en/standards-guidelines/guidelines.aspx>

ACR – Appropriateness Criteria

The American College of Radiology (ACR) Task Force on Appropriateness Criteria was established in 1993 and began to develop scientifically-based guidelines to assist referring physicians in making appropriate imaging decisions for a given patient clinical condition in order to provide the College’s perspective on how to best use limited health care resources.

The American College of Radiology (ACR) Appropriateness Criteria® are evidence-based guidelines that have been developed to assist healthcare providers in making the most appropriate imaging decision for a clinical condition. There are 230 topics with over 1,100 variants in the 2017 release. Use of the guidelines will enhance quality of care and contribute to the most efficacious use of imaging.

The guidelines offer advice on the appropriateness of imaging examinations for specific clinical conditions. The imaging is stratified from a score of 9 for the most appropriate imaging examination to 1 for the least appropriate imaging modality. The guidelines also take radiation exposure into account. The suggested imaging is supported by validated scientific evaluation of the current literature and is accompanied by narrative and reference sections.

The guidelines were developed by experts working on panels with committee members representing diagnostic imaging, interventional radiology, radiation oncology, and other medical specialties pertinent to the clinical condition.

There is a process of annual review of selected guideline and revisions are performed on a regular basis. Hence, static images of the guidelines were not provided as they will not adequately reflect any revisions made. Links provided will allow for inclusion of any updates made to the specific Appropriateness guideline you are reviewing.

ACR Imaging Appropriateness Clinical Scenarios

Not all clinical scenarios have dedicated ACR Appropriateness guidelines. Some common clinical scenarios will be presented in this e-Book. Some of these clinical conditions have unique ACR Guidelines associated with them. Table 1.1 highlights the ACR Guidelines that are available for some of the clinical conditions that will be discussed.

Body Region	ACR Appropriateness Criteria Guideline
Brain and Spine	Headache – Sudden – Severe
	Cerebrovascular Ischemia
	Low Back Pain
Breast	Breast Cancer Screening
	Palpable Breast Mass
Cardiovascular	Acute Pain – Suspected Aortic Dissection
	Dyspnea – Suspected Cardiac Cause
Chest	Acute Pain – Suspected Pulmonary Embolism
	Radiologically Detected Solitary Pulmonary Nodule
	Acute Respiratory Illness in Immunocompetent Patient
	Chronic Dyspnea – Suspected Pulmonary Origin
Gastrointestinal / Abdominal	Right Lower Quadrant Pain – Suspected Appendicitis
	Left Lower Quadrant Pain – Suspected Diverticulitis
	Suspected Bowel Obstruction
	Liver Lesion – Initial Imaging Characterization
	Jaundice
Gynecological / Obstetric	Assessment of Adnexal / Pelvic Mass
	Assessment of Fetal Well Being
	Second and Third Trimester Bleeding
Head and Neck	Neck Mass / Adenopathy
Invasive	Infected Fluid Collections
	Management of Inferior Vena Cava Filters
MSK	Acute Hand and Wrist Trauma
	Acute Shoulder Pain
	Acute Knee Pain
	Acute Hip Pain
	Acute Ankle Trauma
	Chronic Extremity Joint Pain

Pediatric	Suspected Non-Accidental Trauma
	Urinary Tract Infection
	Vomiting in Infants up to 3 Months of Age
Urologic	Acute Flank Pain – Suspected Urolithiasis
	Acute Scrotal Pain, Without Trauma
	Indeterminate Renal Mass
	Hematuria

Table 1.1 ACR Appropriateness Criteria Guidelines Pertinent to the current Curriculum

For More Information:

ACR Appropriateness Criteria Guidelines – <https://acsearch.acr.org/list>

This is a tabulation of all of the current guidelines with a search tool provided to expedite finding the most relevant information for your clinical situation.

Choosing Wisely – Canada

Choosing Wisely Canada (CWC) was developed to help clinicians and patients engage in conversations about unnecessary tests and treatments and make smart and effective choices to ensure high-quality care.

Unnecessary tests and treatments do not add value to patient care. They take away from care by potentially exposing patients to harm, lead to testing to investigate false positives, and contribute to patient stress. Unnecessary tests and treatments put increased strain on the resources of our health care system.

Canadian national specialty societies participating in the campaign, representing a broad spectrum of clinicians, were asked to develop lists of “Five Things Clinicians and Patients Should Question.” These lists identify tests and treatments commonly used in each specialty, but are not supported by evidence, and/or could expose patients to unnecessary harm.

In conjunction with CWC, the Canadian Association of Radiology (CAR) identified the following five recommendations, pertinent to imaging utilization, as significant clinical situations where clinicians should re-think the use of imaging for their patients.

1 – Don’t do imaging for lower-back pain unless red flags are present.

Red flags include suspected epidural abscess or hematoma presenting with acute pain, but no neurological symptoms (urgent imaging is required); suspected cancer; suspected infection; cauda equina syndrome; severe or progressive neurologic deficit; and suspected compression fracture. In patients with suspected uncomplicated herniated disc or spinal stenosis, imaging is only indicated after at least a six-week trial of conservative management and if symptoms are severe enough that surgery is being considered.

2 – Don’t do imaging for minor head trauma unless red flags are present.

Red flags include Glasgow Coma Scale (GCS) less than 13; GCS less than 15 at 2 hours post-injury; a patient aged 65 years or older; obvious open skull fracture; suspected open or depressed skull fracture; any sign of basilar skull fracture (e.g., hemotympanum, raccoon eyes, Battle’s Sign, CSF otorrhorrhea); retrograde amnesia to the event lasting 30 minutes or longer after the event; “dangerous” mechanism (e.g., pedestrian struck by motor vehicle, occupant ejected from motor vehicle, or fall from higher than 3 feet or down more than 5 stairs); and Coumadin use or bleeding disorder.

3 – Don't do imaging for uncomplicated headache unless red flags are present.

Red flags include recent onset, rapidly increasing frequency and severity of headache; headache causing the patient to wake from sleep; associated dizziness, lack of coordination, tingling or numbness, new neurologic deficit; and new onset of a headache in a patient with a history of cancer or immunodeficiency.

4 – Don't do computed tomography (CT) for the evaluation of suspected appendicitis in children until after ultrasound has been considered as an option.

Although CT is accurate in the evaluation of suspected appendicitis in the pediatric population, ultrasound is nearly as good in experienced hands. Since ultrasound will reduce radiation exposure, ultrasound is the preferred initial imaging examination in children. If the results of the ultrasound exam are equivocal, it may be followed by CT. This approach is cost-effective, reduces potential radiation risks and has excellent accuracy, with reported sensitivity and specificity of 94 percent.

5 – Don't do an ankle x-ray series in adults for minor injuries.

X-rays are only indicated if there is pain in the malleolar zone, bone tenderness at the posterior edge or tip of either malleolus, or inability to bear weight for four steps immediately after the trauma and in the emergency department.

5 Things Clinicians and Patients Should Question:

1. Don't do imaging for lower-back pain unless red flags are present
2. Don't do imaging for minor head trauma unless red flags are present
3. Don't do imaging for uncomplicated headache unless red flags are present
4. Don't do computed tomography (CT) for the evaluation of suspected appendicitis in children until after ultrasound has been considered as an option
5. Don't do an ankle x-ray series in adults for minor injuries

For More Information:

Five Things Physicians and Patients Should Question – Radiology: <https://choosingwiselycanada.org/radiology/>

Medical Students and Trainees – General Choosing Wisely Guiding Principles

1. Don't suggest ordering the most invasive test or treatment before considering other less invasive options.

There are often diagnostic approaches and treatment options that result in the same clinical outcome but are less invasive. Examples include the use of ultrasound instead of computed tomography (CT) scanning to diagnose

acute appendicitis in children, or the use of an oral antibiotic that has similar oral bioavailability as its intravenous counterpart. Taking time to consider the diagnostic sensitivity and specificity of less invasive tests or the therapeutic effectiveness of less invasive treatments can minimize unnecessary patient exposure to harmful side effects of more invasive tests or treatments.

2. Don't suggest a test, treatment, or procedure, that will not change the patient's clinical course.

When ordering tests, it is important to always consider the diagnostic characteristics such as sensitivity, specificity and predictive value in light of the patient's pre-test probability. Patients who are at very low baseline risk often do not require an additional test to rule out the diagnosis. Furthermore, evidence suggests that in such low-risk patients, diagnostic tests do not reassure patients, decrease their anxiety, or resolve their symptoms. Examples include the use of computed tomography (CT) scanning in low-risk patients to rule out pulmonary embolism, or pre-operative cardiac testing for patients prior to low risk surgery. Evaluation of baseline risk and the use of decision support tools wherever possible, along with a 'how will this change my management' approach, can help to avoid unnecessary 'rule out' testing in patients.

3. Don't miss the opportunity to initiate conversations with patients about whether a test, treatment or procedure is necessary.

Patient requests sometimes drive overuse. For example, a parent might request antibiotics for his or her child who likely has viral sinusitis, or a patient might request magnetic resonance imaging (MRI) for low-back pain. Often patients are unaware of the benefits, side-effects and risks of tests and treatments. Taking time to explore a patient's concerns, and counseling them about the relative benefits and risks of tests or treatments represents a patient-centered approach to ensuring the appropriate use of resources.

4. Don't hesitate to ask for clarification on tests, treatments, or procedures that you believe are unnecessary.

Unfortunately, in some learning environments, a hierarchy exists between supervisors and students that makes it difficult for students to feel comfortable speaking up. As a result, students might observe unnecessary care, but avoid saying anything for fear of potential consequences. Supervisors need to encourage students to feel free to question whether tests or treatments are truly necessary without fear of repercussion. The clinical training environment should be one where students feel safe to ask questions.

5. Don't suggest ordering tests or performing procedures for the sole purpose of gaining personal clinical experience.

The clinical training years in medical school represent an important opportunity for students to translate what was learned in the classroom to the bedside. This can be a challenging time of great uncertainty for students. Students may order tests excessively due to a lack of clinical experience, or recommend investigations in order to build upon their personal experience.

6. Don't suggest ordering tests or treatments pre-emptively for the sole purpose of anticipating what your supervisor would want.

A “hidden curriculum” pervasive in the academic environment encourages medical students to search for zebras through extensive (and often unnecessary) diagnostic workups. Because restraint is often discouraged, students adopt the belief that faculty expect an exhaustive diagnostic approach, and feel that they need to demonstrate their knowledge, thoroughness and curiosity through test ordering. Students can overcome this practice by articulating why they chose not to order a specific test.

Medical Students and Trainees:

1. Don't suggest ordering the most invasive test or treatment before considering other less invasive options.
2. Don't suggest a test, treatment, or procedure that will not change the patient's clinical course.
3. Don't miss the opportunity to initiate a conversation with patients about whether a test, treatment or procedure is necessary.
4. Don't hesitate to ask for clarification on tests, treatment, or procedures that you believe are unnecessary.
5. Don't suggest ordering tests or performing procedures for the sole purpose of gaining personal clinical experience.
6. Don't suggest ordering tests or treatments pre-emptively for the sole purpose of anticipating what your supervisor would want.

For More Information:

Choosing Wisely Canada – <https://choosingwiselycanada.org/>

Image Gently

This organization is an alliance of healthcare providers that have developed strategies and policies aimed at utilizing imaging in children in a safer and most responsible manner.

The Mission Statement of the alliance is:

“Through advocacy, to improve safe and effective imaging care of children worldwide.”

This alliance was initiated in 2006 as a committee of the Society of Pediatric Radiology and has grown in into a worldwide entity led by a Steering committee of eminent scholars and clinicians. The goal of the group is to, “change practice” in regards to the use of ionizing radiation related to examinations ranging from dental radiography, angiography, computed tomography and nuclear medicine to name only a few modalities.

For a broader discussion of the activities of the alliance please access their online presence at, <http://www.image-gently.org/>

Introduction – References

- 1) Royal College of Physicians and Surgeons of Canada, CanMEDS Framework. <http://www.royalcollege.ca/rcsite/canmeds/canmeds-framework-e> Last accessed July 31, 2017.
- 2) American College of Radiology, Appropriateness Criteria. <https://www.acr.org/Quality-Safety/Appropriateness-Criteria> Last accessed July 31, 2017.
- 3) Canadian Association of Radiologists, Referral Guidelines. <http://www.car.ca/en/standards-guidelines/guidelines.aspx> Last accessed July 31, 2017.
- 4) Choose Wisely Canada, Radiology. <https://choosingwiselycanada.org/radiology/> Last accessed July 31, 2017.

Chapter 2 – Principles of Radiation Biology and Radiation Protection

Introduction

Purpose:

Our aim is to provide a focused discussion pertaining to diagnostic radiation usage and safety, with a focus on imaging modalities that use of x-rays.

Medical schools throughout the world emphasize radiological examination interpretation, but little is taught on the science behind these examinations and the potential harm from exposure to radiation.

We live in a world where everyone, and everything, is constantly exposed to non-ionizing and ionizing radiation. Ionizing radiation is electromagnetic energy that is capable of displacing electrons from the orbital rings of atoms, creating an ion. Ionizing radiation may arise from man-made activities or from natural sources. Natural sources of radiation include cosmic rays, isotopes in the ground, water, food (uranium, radium), or as a gas (radon).

X-rays for medical imaging:

It is generally accepted that patients are being exposed to more radiation today than in the past due to advances in imaging technologies and the broader application of imaging in healthcare. For example, there are many more indications for CT now than in the past i.e. CT pulmonary embolism studies and CT angiography for cardiac, cerebral, or peripheral arterial imaging. Also, it seems that diagnosis and treatment are more intricately tied to the results of imaging examinations than in the past.


Alpha, beta, and gamma radiation emitted from within the patient due to the administration of a radioactive pharmaceutical is the second major type of radiation that patients will be exposed to. We will limit the focus our current discussion to x-rays generated for the acquisition of medical images.

Radiation in Medical Imaging: The x-ray Tube

The X-ray Tube:

X-ray tubes are found in a wide variety of imaging devices, Computed Tomography (CT), portable x-ray machines, mammography machines, fixed position x-ray machines, fluoroscopy units, and c-arm x-ray machines.

Medical x-rays are produced in a glass enclosed vacuum tube. (See Figure 2.1 and 2.2) A high voltage differential is applied across a gap in a vacuum tube between a cathode and an anode. The anode is the target for the electrons that are accelerated across the vacuum and the anode is usually made of a metal, often tungsten. When the voltage differential results in an electron crossing over the gap and impacting the metallic anode the electron slows down and liberates energy as heat and x-rays. The majority of the energy is liberated as heat. This type of interaction that results in x-ray generation, has been called by the “braking of the electron”, the bremsstrahlung effect.



X-rays

Anode

Cathode

TYPE 9806
NR. 206 11102
673 919
PHILIPS
150 kV
MADE IN GERMANY

Fig 2.1) This image demonstrates a full-length view of a glass x-ray tube with the cathode and anode illustrated.




Fig 2.2) This magnified image focuses upon the relationship between the cathode and the anode.

X-ray tubes are usually associated with apparatus that allows for the physical positioning of a patient for an examination and an x-ray detection system that collects transmitted x-rays and transforms them into images. (Figure 2.3)




Fig. 2.3) A ceiling mounted x-ray tube is seen. The x-rays are collimated and emitted from the end of the housing that is resting on the x-ray table. The x-ray detector is below the surface of the table.

The x-ray tube has physical features that allow for the cooling of the components related to the heat produced and for focusing and directing of the x-rays towards the target (the patient). The x-rays created are collimated by the lead housing of the x-ray tube and by mobile metallic plates in the x-ray tube which results in the x-rays being emitted from a small aperture in the x-ray tube housing. (Figure 2.4)




Fig. 2.4) This is an overhead view of the same x-ray tube seen in Figure 2.3. The electrical cables associated with the cathode and the anode are seen. The glass x-ray tube is inside the lead housing. The cooling fan is seen projecting from the top of the x-ray tube housing.

The x-rays emitted from the x-ray tube have three possible fates when encountering human anatomy:

- a) They are transmitted through the patient to interact with the x-ray detector on the opposite side of the entry site, resulting in an image;
- b) They are absorbed by the patient's tissues and the energy is dissipated;
- c) They are scattered by the patient's tissues and leave the body in another direction from the entry site. These scattered x-rays may interact with the detector or they may enter the physical space surrounding the patient.

Different tissues absorb x-rays differently based upon their molecular structure i.e. bone vs. fat and upon the density and the thickness of the tissue. This differential absorption of the incident x-ray beam results in the differential detection of the x-ray beam after exposure of the detector and hence is directly responsible for the varying intensities seen on the gray scale of the resulting image.

Attributions

Fig. 2.1 – Full-length view of a glass x-ray tube with the cathode and anode by Dr. Brent Burbridge MD, FRCPC, University Medical Imaging Consultants, College of Medicine, University of Saskatchewan is used under a [CC-BY-NC-SA 4.0](#) license.

Fig 2.2 – Magnified image focuses upon the relationship between the cathode and the anode by Dr. Brent Burbridge MD, FRCPC, University Medical Imaging Consultants, College of Medicine, University of Saskatchewan is used under a [CC-BY-NC-SA 4.0](#) license.

Fig 2.3 – A ceiling mounted x-ray tube by Dr. Brent Burbridge MD, FRCPC, University Medical Imaging Consultants, College of Medicine, University of Saskatchewan is used under a [CC-BY-NC-SA 4.0](#) license.

Fig. 2.4 – overhead view of the same x-ray tube seen in Figure 2A by Dr. Brent Burbridge MD, FRCPC, University Medical Imaging Consultants, College of Medicine, University of Saskatchewan is used under a [CC-BY-NC-SA 4.0](#) license.

Ionizing Radiation: Basic Concepts

Measurement of Radiation

Radiation exposure can be measured and monitored. The exposure measurement, using the Systeme International (SI) units, is determined by the Coulombs/kilogram (C/kg). However, this is a measurement of the administered dose when all of the x-rays are stopped by air not by human tissues.

In an attempt to correlate the biologic effects of the radiation absorbed in human tissues one can use an assessment of absorbed dose per unit of mass called the gray. One gray = 1 Joule/kilogram of absorbed radiation. This absorbed dose is different for different tissues in the body i.e. fat absorbs less of the administered x-ray dose than bone.

As tissues absorb x-rays differentially and human tissues have different potential for experiencing damage from x-rays i.e. the gonadal tissues are more at risk for radiation damage than are muscle cells, Thus, the concept of dose equivalency has been developed. The most common derived unit of ionizing radiation that can be used to assess the health effects of radiation on the human body is the Sievert (Sv). This unit of measurement has been called an Effective Dose Equivalent as it attempts to correlate the dose of the x-rays administered with the radiosensitivity of different tissues i.e. gonads have a higher sensitivity to radiation vs. muscle.

The measurement of radiation exposure using the Sievert, the effective dose, follows the Stochastic school of thought in regard to the potential adverse effects of radiation. Using the linear, no-threshold, model for radiation injury it has been estimated that 1 Sievert of radiation carries a 5.5% risk of developing a future cancer. (1)

Radiation Exposure

The comparison of the dose of radiation that one receives from an imaging examination to the equivalent number of days of exposure to background radiation is an excellent way to conceptualize the quantity of radiation administered to a patient for diagnostic purposes. (1)

(Table 2.1) Exposure equivalent to background ionizing radiation for common imaging examinations

Examination	Radiation Dose from the Procedure (Effective in mSv)	Background Radiation from Other Sources – sun, isotopes, radon, etc.
Chest x-ray	0.1	10 days
Mammography	0.7	3 months
Fluoroscopy – Upper GI	2	8 months
Lower Leg x-ray	4	16 months
Computed Tomography (CT)		
CT Head	2	8 months
CT Chest	8	32 months
CT Abdomen	10	36 months
CT Spine	10	36 months

Radiation Interaction with Biological Matter

When x-rays or gamma rays interact with human tissue, we must consider the mechanisms of interactions that take place, and what the detriment is to the tissue. To begin that conversation, we must lay down some ground work for the discussion. This includes, among many things, the understanding that human tissue is comprised of many millions of cells, containing organic and inorganic compounds comprised of water, minerals, proteins, nucleic acids, and lipids.

Also, the human body is exposed to and has reparative strategies in place to deal with damage to tissue from radiation exposure. It has been estimated that our bodies respond to approximately 15,000 radiation damage events every second due to natural sources of radiation. (3)

The biological effects of radiation result mainly from damage to the DNA, which is the most critical target within the cell; however, there are also other sites in the cell that, when damaged, may lead to cell death. (3)

Direct and indirect radiation interactions

Direct:

The radiation interacts directly with the critical target in the cell. The atoms of the target itself may be ionized or excited through Coulomb interactions, leading to the chain of physical and chemical events that eventually produce biological damage.

Indirect:

The radiation interacts with other molecules and atoms (mainly water, since about 80% of a cell is composed of water) within the cell to produce free radicals, which can, through diffusion in the cell, damage the critical target within the cell.

Degree of Potential Radiation Injury:

Lethal damage, which is irreversible, irreparable and leads to cell death.

Sublethal damage, which can be repaired in hours unless additional sublethal damage is added that eventually leads to lethal damage.

Potentially lethal damage, which can be manipulated by repair when cells are allowed to remain in a non-dividing state.

Classification of Radiation Damage

Non-Stochastic (Deterministic):

The potential for adverse effects is related to total dose i.e. if a threshold is surpassed there is a significant risk of negative effects of the radiation. This does not mean that there is not damage at the cellular level it only means that no clinically evident damage is evident. This theory is most evident related to skin burns secondary to fluoroscopy but can also be noted related to temporary sterility in males and females and the delayed formation of cataracts in the eye.

Threshold levels for tissue damage have been elucidated. Observable thresholds for deterministic effects are widely variable depending upon the type of effect, the degree of severity used to characterize what is observable and the population group exposed. Some examples of deterministic effects and the typical (photon) thresholds at which they occur include:

– Irradiation of the gonads:	Condition	Radiation Dose
	Temporary sterility (male)	0.15 Gy
	Permanent sterility (male)	3.5 to 6 Gy
	Permanent sterility (female)	2.5 to 6 Gy
– Irradiation of the eyes:		
	Cataracts	2 to 10 Gy
– Irradiation of red bone marrow:		
	Loss of bone marrow function	0.5 Gy
– Whole body irradiation		
	Death (LD50/60*)	3 to 5 Gy

{* The survival-dose relationship is often described using the LD50/60 (i.e., the dose at which half the exposed individuals would be expected to die within 60 days). The principal cause of death being loss of bone marrow function. (3)

Stochastic (Probabilistic):

There is no threshold that must be reached i.e. injury can occur with even the smallest exposure. This theory is applicable to genetic mutations and cancers suspected to be related to radiation exposure (leukemia, lymphoma). In reality the adverse effects seen associated with this theory are also dose related.

There have been no true, longitudinal, randomized, trials that have attempted to determine the potential adverse effects of radiation in a large population. Most data on large populations is related to variable exposure to radiation for a group involved in a military deployment of radiation or in an industrial accident. Suffice it to say, the complexity and longevity of such a research venture makes it very unlikely that it will ever be performed.

The benefits to patient health outcomes and management of diseases detected using ionizing radiation are substantial, widespread, and have considerably altering the well-being and treatment of patients over the 100 years radiation has been in use clinically. However, one should always consider the risk vs. benefit of imaging with ionizing radiation and balance this against the clinical situation of the patient in question.

Radiation Protection for Healthcare Workers

The International Commission on Radiological Protection (ICRP) and other organizations have worked diligently to investigate and educate scientific and regulatory agencies about the benefits and risks of ionizing radiation. The guidelines and recommendations created by the ICRP form the basis for radiological protection in Canada and most other developed countries. Exposure to ionizing radiation is monitored for healthcare workers and rules and regulations have been established that guide the use of protective clothing, shielding, and the safe acquisition of images for workers and patients. (4)

Facilities that administer radiation for diagnosis are regulated by provincial and federal agencies that oversee the safe and appropriate use of this diagnostic tool. These rules and regulations govern the assessment and maintenance of equipment, the radiation dose administered by this equipment, the monitoring of radiation exposure for patients and medical staff, and the proper protection of patients and staff from ionizing radiation.

The greatest exposure to radiation during an imaging procedure occurs at the source of the x-ray beam. Therefore, one should not stand in, or insert, any of their anatomy directly into the x-ray beam.

There is also radiation in the vicinity of the patient as a result of stray photons emitted by the x-ray tube or from radiation scattered during interaction with the patient's anatomy. Increasing the distance from the source of the radiation will significantly reduce the quantity and the intensity of this in scattered radiation. The reduction in radiation intensity is related to the concept of the inverse square law i.e. the intensity of the radiation is inversely proportional to the square of the distance from the x-ray source. All medical staff must stand well back from the imaging equipment during exposures unless their direct attendance to the patient is required.

Personal protective equipment is very important. Barriers, shields, thyroid collars, aprons, leaded glass, leaded eyewear, etc. should be used in all situations where personnel may be exposed to radiation. Medical staff must wear protective lead garments to reduce their exposure to radiation.

Walls and doors of rooms that use radiation must be lined with lead. There must be appropriate signage identifying rooms or areas that deploy ionizing radiation. It is also required that warning lights are visible and lit when the x-ray machine behind the leaded door is emitting radiation to prevent inadvertent entry into the room without wearing radiation protection.

The annual exposure to radiation for medical staff must be monitored and reported. If staff exceed their annual

limit for radiation exposure their duties must be adjusted to prevent any further exposure to radiation during the year.

If you are concerned about your exposure to radiation or how to protect yourself, you should contact the Head Medical Radiation Technologist of the medical facility you are working in or contact the local Radiation Safety and Protection Officer.

Radiation Protection for Patients

Patients should be appropriately shielded from direct and scattered radiation for all imaging examinations.

It is in the best interest of the patient and for the betterment of society that patients receive as little radiation as possible for diagnostic purposes.

The use of radiation should be justifiable i.e. the benefits outweigh the risks. Radiation dose should be minimized as best as possible without limiting the diagnostic utility of the examination. Attention should be paid to the cumulative amount of radiation that a patient is exposed to during healthcare encounters over the long term.

ALARA

As defined in Title 10, Section 20.1003, of the Code of Federal Regulations (10 CFR 20.1003), ALARA is an acronym for “as low as (is) reasonably achievable,” which means making every reasonable effort to maintain exposures to ionizing radiation as far below the dose limits as practical, consistent with the purpose for which the licensed activity is undertaken, taking into account the state of technology, the economics of improvements in relation to state of technology, the economics of improvements in relation to benefits to the public health and safety, and other societal and socioeconomic considerations, and in relation to utilization of nuclear energy and licensed materials in the public interest. (5)

Ionizing Radiation: Fetus and Neonate

The potential effects of ionizing radiation on the fetus are dependent upon the stage of development of the fetus and the radiation dose administered.

Stages of Fetal Development:

- Pre-implantation (day 1 to 10)
- Organogenesis (day 11 to 42)
- Growth stage (day 43 to birth)

The potential for fetal demise is greatest in the pre-implantation and early implantation phase of pregnancy. Harm to the fetus at this stage is considered to be all or nothing i.e. fetal demise or normal development.

The subsequent phase of organogenesis or embryogenesis is critical for the development of organs. Congenital malformations may develop as a result of radiation exposure. The most common abnormality seen related to excessive radiation exposure at this stage is growth retardation.

Nervous system anomalies are the most common manifestation of excessive radiation during the growth phase with fetal deformities such as microcephaly, intellectual impairment, and other central nervous system abnormalities.

Later in fetal development the risk for catastrophic events related to radiation exposure diminishes, but one must remember that the long-term effects of genetic mutation during the life time of the child. Radiation exposure for late gestation fetuses and neonates should be judiciously utilized.

Most radiographic imaging techniques result in low fetal exposures, below 50 mGy, where significant increases in risk to the fetus have not been observed. However, some imaging examinations deliver a substantial radiation dose to the mother and fetus and should best be avoided. For example, a single abdominal x-ray delivers a dose of 2 – 2.5 mGy to the fetus while a CT of the abdomen will be associated with a fetal dose of 2 – 26 mGy depending upon the parameters used for the CT i.e. slice thickness, kVp and ma settings, and the number of images captured during the examination.

As in all medicine, the risks and benefits of each diagnostic procedure should be assessed on a case-by-case basis. In addition, an understanding of the doses involved in radiological investigations should be evaluated and con-

sidered prior to imaging. The American Congress of Obstetricians and Gynecologists (ACOG) states that fetal risk is minimal with doses under 50 mGy, and that doses over 100 mGy may result in malformation of 1% above background incidence. (6)

Organizations such as Image Gently Alliance have recently been established to sensitize healthcare providers and families to the risks and benefits of diagnostic radiation. They began as a sub-committee of the Pediatric Radiology Society and have grown into a multi-organization, world-wide movement with a stated group mission of, "... providing safe, high quality pediatric imaging worldwide. The primary objective of the Alliance is to raise awareness in the imaging community of the need to adjust radiation dose when imaging children." (7)

Appropriateness of Imaging Guidelines

The ACOG and Imaging Gently Alliance guidelines can be supplemented by the use of a wide variety of resources that will facilitate the appropriate use of imaging. (6, 7)

Most professional imaging associations have created and disseminated scientifically validated, peer-reviewed guidelines that provide assistance in ordering the most appropriate imaging test while avoiding less useful, or non-contributory, tests that could unnecessarily expose the patient to ionizing radiation. These guidelines also will provide information about the relative radiation exposure that can be expected for one examination vs. another.

If possible, the use of imaging modalities that do not use ionizing radiation (ultrasound and MRI) should be considered.

Hence, it is hoped that fewer examinations will be requested and the most useful and appropriate examination will be performed, reducing the use of inappropriate ionizing radiation. Also, if an examination with radiation is required the dose experienced by the patient can be justified with the argument that the most useful, appropriate, diagnostic examination has been utilized limiting the total radiation dose experienced by the patient. (8 – 11)

Principles of Radiation Biology and Radiation Protection – References

- 1) Medical Imaging Primer, with a focus on x-ray usage and safety, Canadian Associate of Radiologists. 2013. https://car.ca/wp-content/uploads/CAR-guide_radiation_primer.pdf
Accessed Sep. 3, 2018.
- 2) Sievert. Wikipedia. <https://en.wikipedia.org/wiki/Sievert> Accessed Sep. 3, 2018
- 3) Radiation Safety Review, Jeff Sanderson. Cancer Care Manitoba, 2001. <https://www.cancercare.mb.ca/Research/medical-physics/radiaion-protection-services/index.html>
- 4) ICRP, 2007. ‘The 2007 Recommendations of the International Commission on Radiological Protection’. ICRP Publication 103. Ann. ICRP 37 (2-4).
(see <http://www.icrp.org/publication.asp?id=ICRP%20Publication%20103>) Last accessed Feb. 12, 2019.
- 5) United States Nuclear Regulatory Commission. <https://www.nrc.gov/reading-rm/basic-ref/glossary/alara.html>
Last accessed February 5, 2019.
- 6) Guidelines for Diagnostic Imaging During Pregnancy and Lactation ACOG October 2017 e210; 130(4):e210 – e216.
- 7) Image Gently Alliance. <https://www.imagegently.org/> Last accessed February 6, 2019.
- 8) American College of Radiology. ‘ACR appropriateness criteria.’ Radiology, 2000; 215 (Suppl): 1-1511.
- 9) ACR Appropriateness Criteria List. <https://acsearch.acr.org/list> Last accessed Feb. 13, 2019.
- 10) The Royal Australian and New Zealand College of Radiologists. Imaging Guidelines. 4th edn. Surrey Hills: National Library of Australia Cataloguing-in-Publication Data, 2001.
- 11) Canadian Association of Radiologists – Referral Guidelines <https://car.ca/patient-care/referral-guidelines/>
Last accessed Feb. 13, 2019.

Chapter 3 – Principles of Imaging Techniques

Introduction

Learning Objectives

Knowledge

- Be able to describe the major components of an X-ray unit and explain the process of X-ray generation
- For the following modalities; X-ray, mammography, fluoroscopy, digital subtraction angiography (DSA), CT, Ultrasound, MRI, and Nuclear Medicine, the Student should:
 - Be able to describe the physical principles of image formation
 - Describe the positioning of the patient for common radiographic techniques (e.g. chest x-ray)
 - Recognize factors affecting image quality related to X-ray dose in radiography and fluoroscopy
 - Describe the principles of the Doppler effect in ultrasound
 - Understand the concepts of spatial, temporal, and contrast resolution
 - Describe the Hounsfield Unit (HU) scale and the principle of window level and width
 - Relate the contraindications and safety issues for imaging modalities, including the MR environment, with regard to patients and staff
- Explain the basic infrastructure of imaging informatics, including Picture Archiving and Communication Systems (PACS) and Radiology Information Systems (RIS) in the jurisdiction that you work in

Competencies

- Recognize the technological elements displayed when encountering an image (AP chest X-ray, lung level/window for CT, etc.)
- Recognize optimal and sub-optimal image quality in radiography and fluoroscopy
- Identify normal anatomy on radiography, fluoroscopy, DSA, ultrasound, CT, MRI
- Communicate the diagnostic value of imaging modalities for common indications to the patient

- Describe the common processes related to imaging examinations to the patient
- Communicate the risks and benefits of various imaging examinations (including radiography, fluoroscopy, DSA, ultrasonography, CT, MRI, and Nuclear Medicine) to patients and their families

Diagnostic Radiology (Diagnostic Imaging, Medical Imaging, Radiology) is a medical sub-specialty that is overseen by the Royal College of Physicians and Surgeons of Canada and is subject to specialty certification by this organization.

The Diagnostic Radiology Residency is a multi-modality, body system structured, training program that introduces the trainee to all of the major modalities and anatomic regions in preparation for the resident to challenge the national specialty examinations in Diagnostic Radiology, and to have the skills and knowledge to be a knowledgeable general radiologist.

Diagnostic Radiology encompasses a wide variety of modalities, anatomic regions, and clinical conditions. The major imaging modalities that will be discussed in later sections of this chapter, include:

1. [X-rays \(radiographs\)](#)
2. [Mammography](#)
3. [Fluoroscopy](#)
4. [Angiography](#)
5. [Computed Tomography \(CT\)](#)
6. [Ultrasound](#) (with Doppler)
7. [Magnetic Resonance Imaging \(MRI\)](#)
8. [Nuclear Medicine](#) (PET/CT)

The first five modalities utilize x-rays generated via an x-ray tube. The mechanical and technical features of the imaging modalities are very different but they all use ionizing radiation administered to the patient from a standardized distance and rely upon the differential absorption of the incident x-rays to create an image.

Ultrasound utilizes high frequency (inaudible) sound while MRI employs magnetic fields and radio waves.

Nuclear Medicine images rely upon the administration of a radioactive pharmaceutical agent that emits alpha, beta, or positron radiation that is captured by external radiation detectors. The anatomic detail of Nuclear Medicine images is very limited but the pharmaceuticals can be designed to concentrate in specific tissues of the body, focusing the bulk of the administered radioactive substance and maximizing the usefulness of the examination, e.g. bone scans are acquired by injecting Technetium 99m (^{99m}Tc) bound to diphosphonate. This radio-pharma-

ceutical is preferentially concentrated in metabolically active bone and maximizes the radiation that is emitted from bone minimizing the background radiation coming from adjacent soft tissues (muscle, fat, etc.).

Resolution of Imaging Modalities

Spatial resolution – This is a measure of the ability of an imaging modality to differentiate objects from each other when the objects are in close proximity. It is also a description of image blur. A standard method of determining the resolution of an x-ray based imaging technology is the line pair detection standard. If lines are created by interposing a radiopaque substance (lead) with a radiolucent substance (air), how many pairs of lines can be distinctly identified per millimeter? CT has a line-pair resolution of 0.7 line-pairs/mm while mammography resolves 7 line-pairs/mm. Image spatial resolution using x-rays can be effected by a wide variety of parameters including some of the following: the incident x-ray dose; the focal spot of the x-ray source; scattering of the incident x-ray beam; the detector array used to detect the transmitted x-rays; and the quality of the viewing monitor.

Spatial resolution of Ultrasound and Magnetic Resonance is more complex due to the physics of these imaging modalities.

Of all the above modalities Nuclear Medicine has the lowest spatial resolution with PET/CT having a resolution of 2 mm.

Contrast resolution – Contrast resolution relates to the viewer's ability to differentiate between different intensities displayed on an image. The Computed Tomography (CT) Hounsfield Unit (HU) is an absolute contrast density system with the density value of water fixed at 0 HU. Contrast resolution in MRI is not fixed and is highly dependent upon the sequence acquisition parameters established by the operator, hence the phenomenon of black CSF and white CSF on MR on different MRI sequences. MR has the best contrast resolution of all of the common modalities currently utilized.

Temporal resolution – This refers to the duration of image acquisition in reference to an active or dynamic imaging sequence such are gated cardiac CT or MR. i.e. the faster the image can be acquired at the optimal time in the cardiac cycle the better. A general rule is that improvements in temporal resolution have a negative impact upon spatial resolution i.e. if time period for the gathering of transmitted radiation is too short there will be less data to be used to form the imaging for viewing.

Resolution in Imaging

Term	Definition
Spatial Resolution	Measure of the ability to differentiate objects from one another on imaging, when the objects are within close proximity
Contrast Resolution	Ability to differentiate between different intensities on an image
Temporal Resolution	The precision of a measurement with respect to time

Table 3.1 Definitions of three resolutions in medical imaging

Patient Safety in Diagnostic Radiology

Radiation exposure

Earlier in this publication there was guidance regarding the current thinking about using radiation wisely, and cautiously, in medicine and the need for not only being aware of the radiation experienced by the patient for a single imaging examination but to be cognizant of the cumulative radiation burden the patient is exposed to during a period of hospitalization, an acute illness, and over their life time. This is particularly important for CT scanning as this modality has expanded in utilization and the cumulative radiation dose for CT has increased markedly over the last 15 – 20 years.

One is again reminded to keep the As Low as Reasonably Achievable (ALARA) x-ray dosing principles in mind, attempt to follow professional society guidelines for imaging, and attempt to employ the “Imaging Wisely” and “Imaging Gently” recommendations in order to provide optimal patient care and minimize radiation exposure.

Workers in the Diagnostic Imaging field are protected from radiation by leaded equipment and clothing (aprons, collars, gloves, shields, and eyeglasses) to minimize their personal radiation exposure during their work. There are annual established limits for radiation exposure that are monitored by personal radiation detectors that workers are required to wear.

Environmental Safety

Equipment – Patients must be supervised and protected from potential injuries related to the equipment used to gather images while in the imaging department. For example, there are no rails on x-ray machines to prevent patients from falling to the floor. Some x-ray examinations require the patient to stand, therefore, imaging protocols must be modified for patients who are dizzy, obtunded, intoxicated, or have a medical condition that prevents them from standing safely. Care and attention must be paid to identifying these individuals and preventing fall related injuries.

Some imaging equipment is heavy and cumbersome and there is potential for inadvertently bumping the patient or crushing digits or limbs while positioning tabletops and mobile equipment.

Some patient become anxious, dizzy, or syncopal and may faint or lose consciousness during procedures that they are unfamiliar with or are causing them pain. Care must be taken to predict these potential complications and protect the patient.

Infection control – Imaging department are a central hub in busy hospitals and clinics and there is a rapid turnover of large numbers of patient through a limited amount of imaging rooms and equipment. Patient may be actively infected or be carriers of infectious disease, some antibiotic resistant. A high degree of cleanliness and appropri-

ate cleaning techniques must be employed to prevent the spread of infections i.e. table tops, ultrasound probes, railings, bathrooms, etc.

Vascular and Interventional Radiology – There are a wide variety of imaging procedures that are invasive and expose the patient to risks of bleeding, infection, cardiovascular collapse, limb ischemia, etc. This area of the department must be staffed and equipped to monitor and manage these patient’s acute medical needs and there must be enough space available in the procedure rooms for medical, radiological, and nursing staff to be present during an acute care situation. Appropriate recovery facilities must be available to monitor this patient group for delayed complications.

Contrast agents – These substances may be administered to alter or enhance an imaging study. They will be discussed in detail in Chapter 4. These substances may cause anaphylactoid type reactions or effect renal function. They may be harmful if injected into extra-vascular and extra-luminal tissues, or spaces. They must be administered by trained physicians or technologists in consultation with the patient’s medical team.

Magnetic fields – Magnetic Resonance Imaging (MRI) relies upon high strength magnetic fields to obtain diagnostic images. These magnetic forces may be dangerous to patients who have implanted medical devices that contain ferromagnetic components such as, cardiac pacemakers, surgical staples, etc. Movement of these ferromagnetic components may cause serious harm or death i.e. metallic aneurysm clip. In addition, medical monitoring devices, stretchers, instruments, etc. may be actively drawn into the magnetic field injuring staff, technologists, patients, or their family members. All individuals entering into the MRI magnetic field must be screened to prevent adverse events related to encounters with the magnet.

Trips, slips, falls, and back injuries – Busy departments are crowded with beds, stretchers, wheelchairs, gurneys, monitoring devices, cords, tubes, etc. All of these are potential sources for patient and healthcare worker injury. Back injuries incurred related to moving ill patients from their stretcher or bed onto the imaging table are common and account for substantial time lost due to leaves for back injuries. Educational programs and adequate lifting apparatus are essential to minimize these types of work related injury.

Patient Safety Considerations:

- Radiation Exposure
- Environmental Exposures
 - Equipment (size, weight, handling)
 - Infections
 - Contrast Agents
 - Magnetic Fields (implanted devices, staples, etc.)
 - Trips, Slips, Falls, Injuries

Picture Archive and Communication System (PACS)

The patient images, acquired for clinical use, must be identified, stored, and be retrievable for same day and future use. As most images acquired are in the digital format there must be software and hardware solution available to digitally transport, save, and archive images for retrieval and viewing. This is what PACS is designed for. PACS is more often than not a proprietary solution provided to the imaging centre by a large Information Technology (IT) vendor such as Philips, General Electric, Agfa, etc.

The patient images must be stored in a manner that protects the patient's confidentiality and thus these systems are secured within complex IT networks with stringent security. Qualified members of the healthcare team, with an approved username and password, can access the images for the purpose of engaging in the care of the patient. Access to the PACS is controlled by local IT staff and via secured networks. In order for you to be actively engaged in image utilization you must apply for access to PACS via the IT department of your facility.

The PACS offers a methodology for searching for patients and their imaging studies. This is usually done using a unique patient identifier such as a hospital number and/or a provincial health number. Thus, one can find new and old imaging studies by searching the PACS database and having them displayed on a PACS compatible viewing station with appropriate monitor resolution for accurate image interpretation. A PACS image review station is depicted in Figure 3.1.

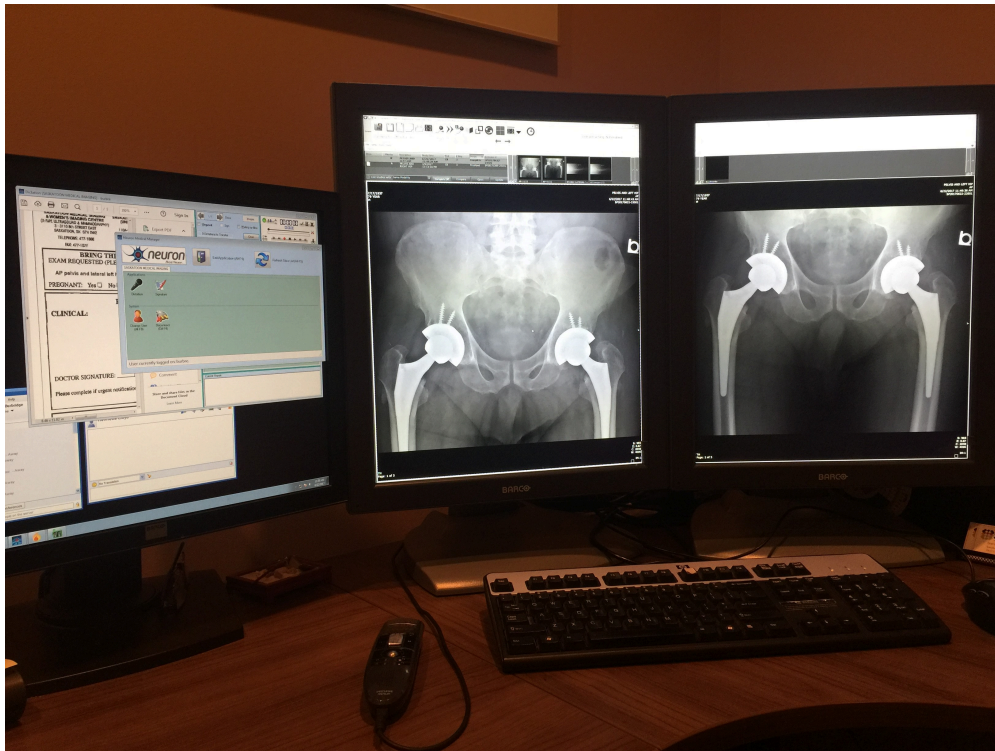

Figure 3.1 PACS Imaging Viewing Station (Workstation)

Radiology Information System (RIS)

The software and hardware required to generate requests for patient imaging, schedule imaging studies and reviewing the radiologist interpretation of the imaging studies is usually handled via the RIS. This system is integrally linked to PACS and also requires username and password credentialing to protect patient confidentiality. Clinicians most often use this system to request imaging examinations and to review the reports of previous imaging studies.

Requesting Imaging

The RIS used at your local health care facilities will have a mechanism for requesting imaging examinations. It may be a digital, software driven, online, order entry module that facilitates the requisition of imaging examinations or it may rely upon some other form of communication with the scheduling component of the system e.g. facsimile, hand-written requests, postal service, etc. Most facilities will have established standardized request forms for specific types of procedures i.e. MRI, PET/CT, etc. Figure 3.2 provides an example of a MRI request form.

The image shows a detailed MRI Consultation Form. It is divided into several sections for data entry:

- Top Section:** Includes fields for 'Ref. Physician', 'Ref. Specialty', 'Physician's Pk #', 'Physician's Fax #', 'Ref's Hospital', and 'Fax #'. There are also checkboxes for 'Health Plan #', 'RUSH', 'SOH', and 'GPI'.
- Procedure Section:** Contains checkboxes for 'Orthopedic', 'Stroke', 'Neurology', and 'Mechanical LBP'. It also has fields for 'Examiner: Hospital', 'Ward', 'Ward Pk #', and 'Examination (include body part) Requested'.
- History Section:** Labeled 'Relevant History: (History must support priority)', it includes a section for 'Relevant Previous Imaging' with a table for 'EXAM', 'Y', 'N', and 'LOCATION OF FILMS'. The table lists 'CT', 'Angio', 'Echo', 'MRA/MRCP', 'LIS', and 'MR Head'.
- Screening Section:** A large section titled 'FOR THE PATIENT'S SAFETY THE MRI EXAMINATOR WILL NOT BE LOOKING AT THE SCREENING SECTION IS COMPLETED!!'. It asks 'What is the clinical priority of this examination?' (Urgent, Emergent) and 'For this patient's SAFETY THE MRI EXAMINATOR WILL NOT BE LOOKING AT THE SCREENING SECTION IS COMPLETED!!'. It lists 'PATIENT HAS' with checkboxes for: Cardiac Pacemaker or pacing leads, abnormal renal function or ? renal disease, metal implanted devices (pacemakers, implants, etc), metallic Foreign Body, metallic Vascular Clips, a known history of metal fragments in the body, and 'the ability to lie perfectly still for a min. of 1 hour'. It also asks 'If no, is sedation/anesthesia required?' (Y/N).
- Demographic Section:** Includes 'Sex', 'Patient weight (kg)', 'Patient height (cm)', and 'Other concerns regarding MRI compatibility/safety:'.
- Bottom Section:** 'FOR DEPARTMENT USE ONLY' includes 'Date/Time Received', 'Approved', 'Revised', 'New information required', 'PMS', 'Contract Required', 'Reason Requested', 'Booked time and date', 'Radiologist', 'Priority Rating', 'Reservation number', 'MR Check #', and 'RAD/RES Signature'.

Figure 3.2 – MRI Request Form

In addition, local imaging facilities will have established policies surrounding the mechanism to be used for requesting elective, urgent, or emergency, imaging studies. Some of the above strategies work well for non-emergent imaging but usually urgent or emergent examinations should be requested by contacting the resident(s), or

radiologist(s) on duty for that modality. The identity of the radiologist(s) on duty is known by the hospital switchboard and the Diagnostic Radiology Department.

As a healthcare provider it is your responsibility to ascertain the methods used for requesting imaging studies in your jurisdiction and understand how to contact the appropriate imaging facilities, and personnel, in your area.

Attributions

Fig 3.1 PACS Imaging Viewing Station (Workstation) by Dr. Brent Burbridge MD, FRCPC, University Medical Imaging Consultants, College of Medicine, University of Saskatchewan is used under a [CC-BY-NC-SA 4.0](#) license.

Fig 3.2 Sample MRI Request Form by Dr. Brent Burbridge MD, FRCPC, University Medical Imaging Consultants, College of Medicine, University of Saskatchewan is used under a [CC-BY-NC-SA 4.0](#) license.

X-rays

X-rays are electromagnetic radiation produced in an evacuated glass tube (Figure 3.3 – Evacuated Glass Bottle). A spinning tungsten anode is the target for high velocity electrons that are accelerated across the vacuum in the tube by a large voltage differential between the cathode and the anode. When the electrons strike the anode, x-rays are liberated along with heat. X-rays are only produced when there is a voltage differential applied across the cathode and anode, therefore, the x-ray tube is dormant until activated by the Medical Radiation Technologist (MRT). This physical, on/off, arrangement is used for all modalities that employ x-rays for imaging (X-ray, CT, Fluoroscopy, Angiography). (Figure 3.3)

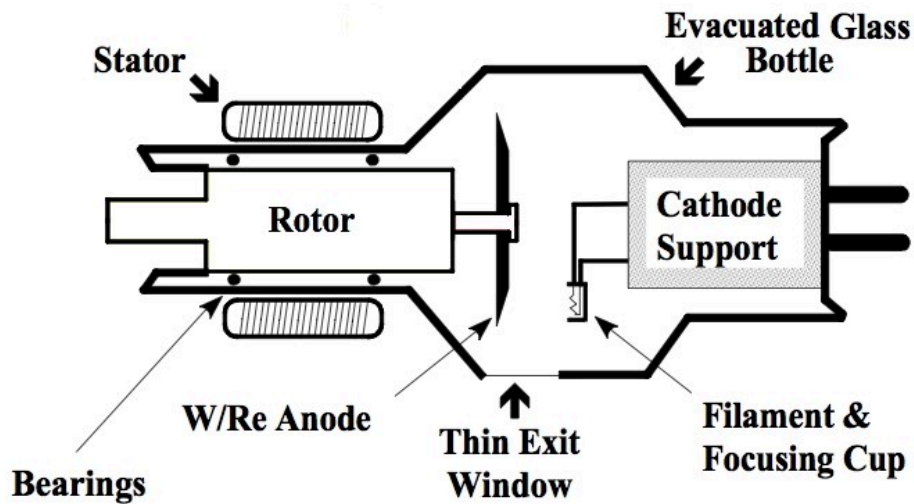


Figure 3.3 X-ray Tube, Schematic

The x-rays that result from the electron bombardment of the anode are constrained within a heavy lead housing that contains circulating oil to cool the tube. The dispersal of the x-ray beam is limited to a small port in the lead housing of the x-ray tube and by mechanical metal filters that collimate the x-ray beam and prevent the uncontrolled, dissemination of x-rays. Therefore, the emitted x-rays expose only the desired region of the patient's anatomy in a controlled manner. The limitation of the x-rays by the lead housing and the collimation filters is

how small part x-rays, i.e. wrist, scaphoid bone, can be done, as well as, large field x-rays such as a full field chest x-ray. (*Figure 3.4*)



Figure 3.4 X-ray Tube, Lead Housing with Portal for x-ray emission, bench top image

The quantity and energy of the x-rays produced is controlled by the parameters set on the machine by the MRT. Every effort is made to optimize the exposure parameters to minimize the radiation dose, but there are times when the patient receives too few, or too many, x-rays resulting in a poor quality image. Often, this can be managed by adjusting the contrast and brightness of the display monitor during viewing, but rarely some images must be repeated in order for them to be of diagnostic quality.

Historically, x-rays were photo-emulsion embedded in plastic sheets that required development in a processor of developer and fixer solutions after exposure to diagnostic x-rays. The dried radiographic images were stored as hard-copies for viewing. The image detectors used today rely on complex electronic systems that converts x-rays into electrical signals that then results in pixels of different intensity on the monitor of a digital display system.

The radiographic (x-ray) image has been described by Dr. Lucy Squire as a, “summation shadowgram”, highlighting the fact that the final image is a summation of all the interactions between the anatomy of the patient and the original x-ray beam prior to the beam reaching the x-ray detector. The x-ray beam is altered by absorption and scattering, during the interaction with the patient, before it finally reaches the x-ray detector. The resulting image ranges between bright white to dark black with hundreds of shades of grey in between. The blackest region of the x-ray image is related to the larger number of x-rays that reached the detector in that region. This phenomenon is analogous to black and white photographic emulsion as those areas with more light exposure are blacker on the photograph. The digital image creation process is depicted in *Figure 3.5*.

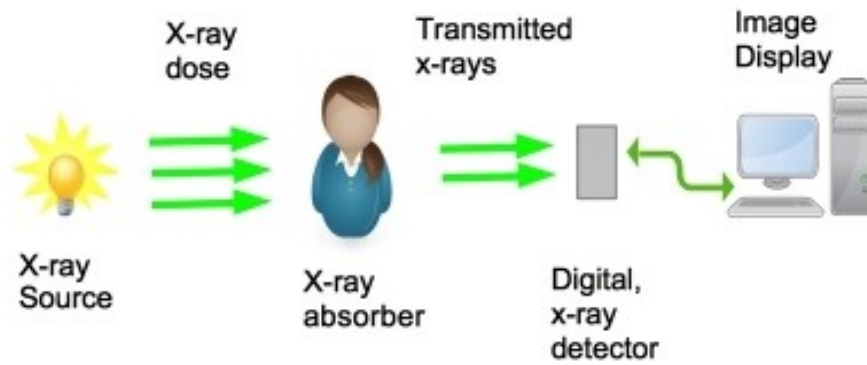


Figure 3.5 X-ray Image Creation and Display

Figure 3.6 (A-D) depict two common types of x-ray imaging devices, one is a static wall mounted unit in an x-ray room and the second, portable units that can be moved to the patient.

Fixed, Wall, x-ray Detector



Figure 3.6A A standard, fixed location, wall, x-ray detector used for upright chest and abdomen x-rays

Portable x-ray Machine



Figure 3.6B A Portable x-ray Machine

Portable x-ray Machine, tube extended

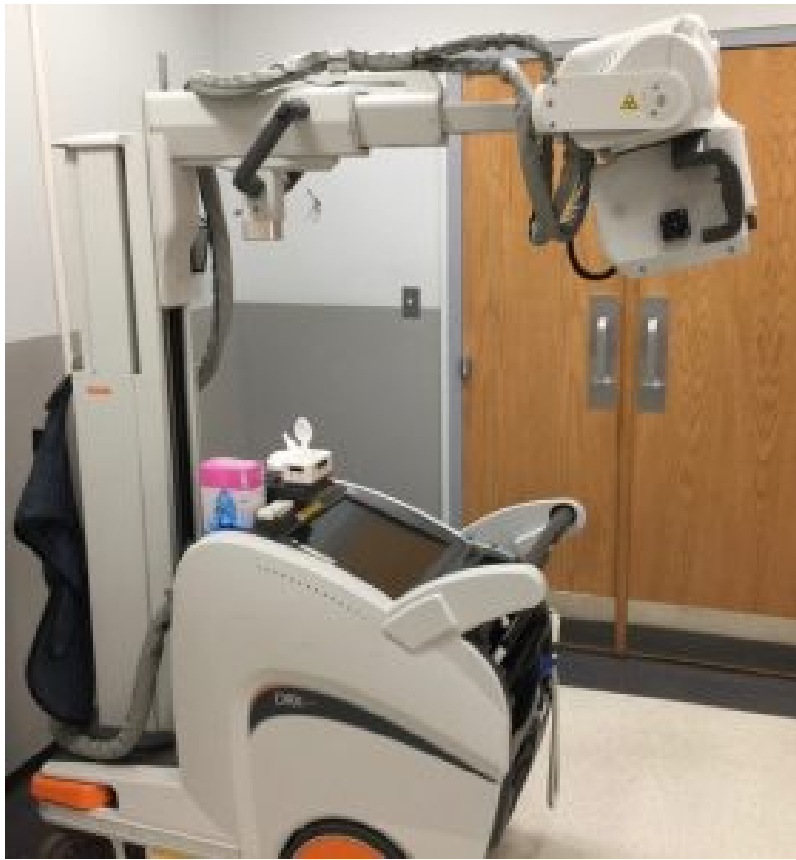

Figure 3.6C The portable machine with the x-ray tube extended for use.

Portable C-arm x-ray machine

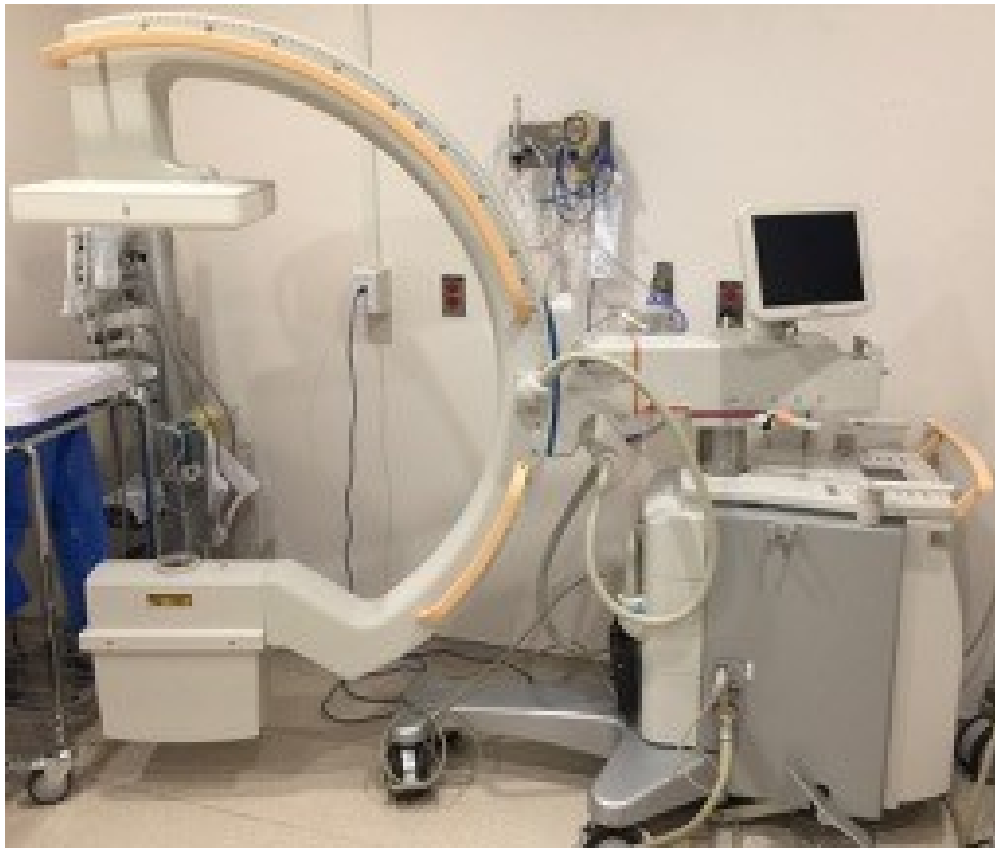

Figure 3.6D A Portable, Mini, C-Arm x-ray unit

Image Appearance

There are *five 'basic' opacities in x-ray imaging*, related to differential x-ray absorption capabilities – **air**, **fat**, **soft tissue**, **bone**, and **metal**. Air has a simple molecular structure, allowing a large proportion of the incident x-ray beam to pass through and reach the image detector, resulting in a dark region on x-ray images. Metal, on the other hand, is a dense structure with heavier atomic weights among the atoms of the metal. Conversely, metal absorbs, or scatters, a large proportion of the incident x-ray beam. Metal is depicted on images as bright white. Metal absorbs more of the incident x-rays than bone (*cortical and medullary bone*) and therefore, is whiter than bone on the resulting image.

Figure 3.7 demonstrates the appearance of an image with the five boxes representing the relative image opacity. From left to right the opacities are air, fat, soft tissue, bone, and metal.

X-ray gray-scale

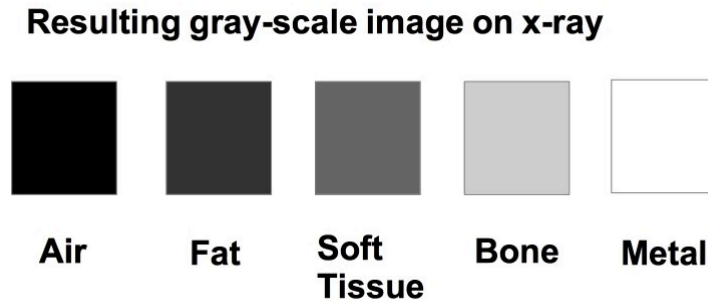


Figure 3.7 Appearance of different entities on x-rays

Opaque (opacity) – an area of the patient that absorbed, or scattered, a large amount of the incident x-ray beam prior to it reaching the detector, i.e. the tissues in question block the x-rays from reaching the detector (whiter on the x-ray image). For example, one would describe metal as opaque on x-ray imaging.

Lucent (lucency) – an area of the image where a larger amount of the x-ray beam passed through unimpeded to reach the detector (blackier on the x-ray image). For example, one would describe air as lucent on x-ray imaging.

A clinical example of the different absorption spectra seen on x-rays is provided in *Figure 3.8*. This is an image of a patient with a knife embedded in his left shoulder.

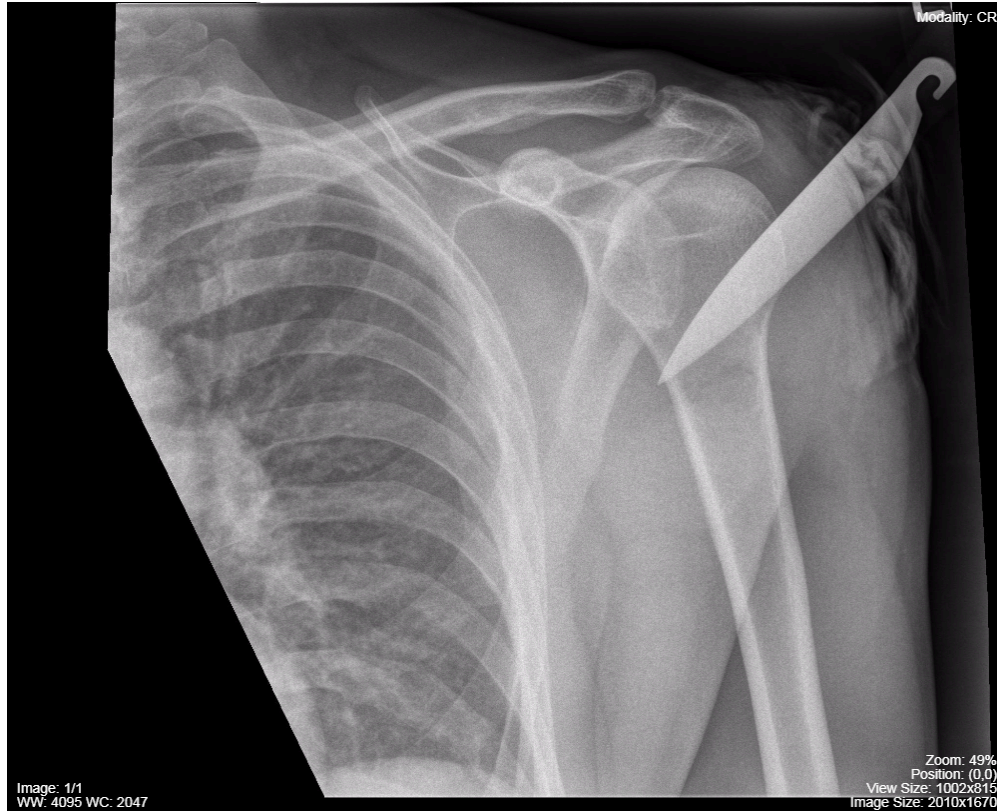


Figure 3.8 Left Shoulder x-ray

ODIN Link for Shoulder x-ray, Figure 3.8: <https://mistr.usask.ca/odin/?caseID=20160214201450302>

- The x-ray (summation shadowgram) of the shoulder reveals a very opaque (white) object consistent with the metallic blade of a knife.
- The handle of the knife is made of plastic and was very lucent compared to the metal. The metal knife blade is embedded in the bone of the proximal humerus.
- Note the differential opacity of the cortical bone vs. the medullary bone, The cortical bone is more compact and opaque as it has more calcium than the medullary bone which has marrow containing fat (more lucent).
- The air external to the patient is very lucent (black) as a large amount of the original x-rays reached the detector.
- The lung (seen on the left side of the image) has a low density but is more dense than the surrounding air due to the summation of all the other anatomy from dorsal to ventral in the chest, however, it is still quite lucent compared to other regions of the image.
- One can see tissue planes between the muscles of the arm, in particular the bicep and deltoid muscles, as there is fat in between these muscles and fat is more lucent than muscle.
- Note the contrast between the density of fat between the muscles and gas trapped in the dressing applied to the entry site of the knife. The air is darker (more lucent).

Thickness of the imaged anatomy also effects x-ray absorption. This is depicted in *Figure 3.9*.

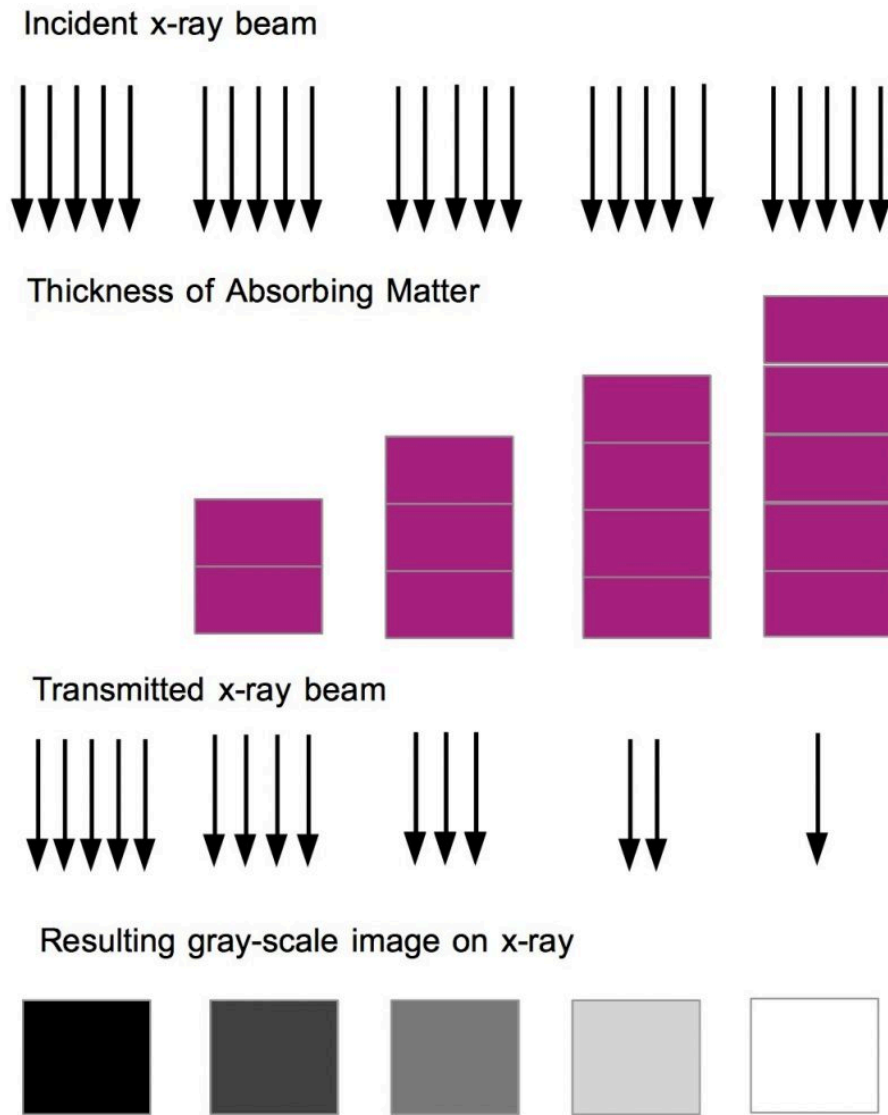


Figure 3.9 Effect of tissue thickness on x-ray appearance

This is depicted on a quality control image taken for x-ray tube calibration. *Figure 3.10* shows an x-ray of a Lucite plastic plate with variable depth holes drilled into it causing the appearance of the circles. The circles become more lucent as the thickness of the Lucite diminishes. The vertical stripes are progressively thicker layers of aluminum that has been applied to the Lucite.




Figure 3.10 Common x-ray Test Object, Lucite Plastic Board

X-ray Image Appearance:

- 5 Basic Opacities (Air, Fat, Soft Tissue, Bone, and Metal)
- **Opaque** (*opacity*) – an area that absorbs or scatters a large amount of x-ray beams before they reach the detector. Appear whiter on an x-ray
- **Lucent** (*lucency*) – an area where x-ray beams pass through without interference to reach the detector. Appear blacker on an x-ray
- Thickness of tissue also effects x-ray absorption

Patient Positioning for x-ray images

Most x-ray equipment has a relatively fixed positions of the x-ray tube and the x-ray detector. In order to acquire images in different anatomic projections the patient must be moved and be positioned. This may require the image detector to be on a wall or table mounted apparatus or the detector may be in a hand-held cassette. The patient may need to be quite mobile for some images i.e. they need to lie on their side or stand upright.

A basic tenet of plain x-rays is to **obtain at least two views of the anatomy in question**, usually taken 90 degrees apart from each other (orthogonal). One of the images is usually obtained in anatomic position and the second image is 90 degrees to the original anatomic position. Therefore, the minimum two views are usually a anterior-posterior (AP) and a lateral. If the x-rays enter the patient from the posterior anatomic side the image will be called a posterior-anterior (PA) view.

Some anatomy is better assessed by obtaining additional views i.e. odontoid view for the high cervical spine, axillary view of the shoulder, skyline view of the patella. These special views must be requested at the time of completing the original request form in order for them to be included with the standard image set. Some special views take advantage of the fact that air rises in any space and fluid falls with gravity, i.e. gas in the peritoneal space and mobile pleural fluid on the decubitus chest x-ray. Also, taking an image in expiration can facilitate the detection of a pneumothorax due to the elastic recoil of the lung on expiration and a reduction in gas within the lung at full expiration.

It may be difficult to obtain quality images, if the patient is unconscious, traumatized, in pain, or uncooperative. This must be kept in mind when requesting x-ray examinations.

Examples of PA and Lateral chest x-ray positioning are shown in Figure 3.11A and 3.11B while a left side up Decubitus, Abdomen x-ray is seen in Figure 3.11C.

Posterior-Anterior Chest x-ray

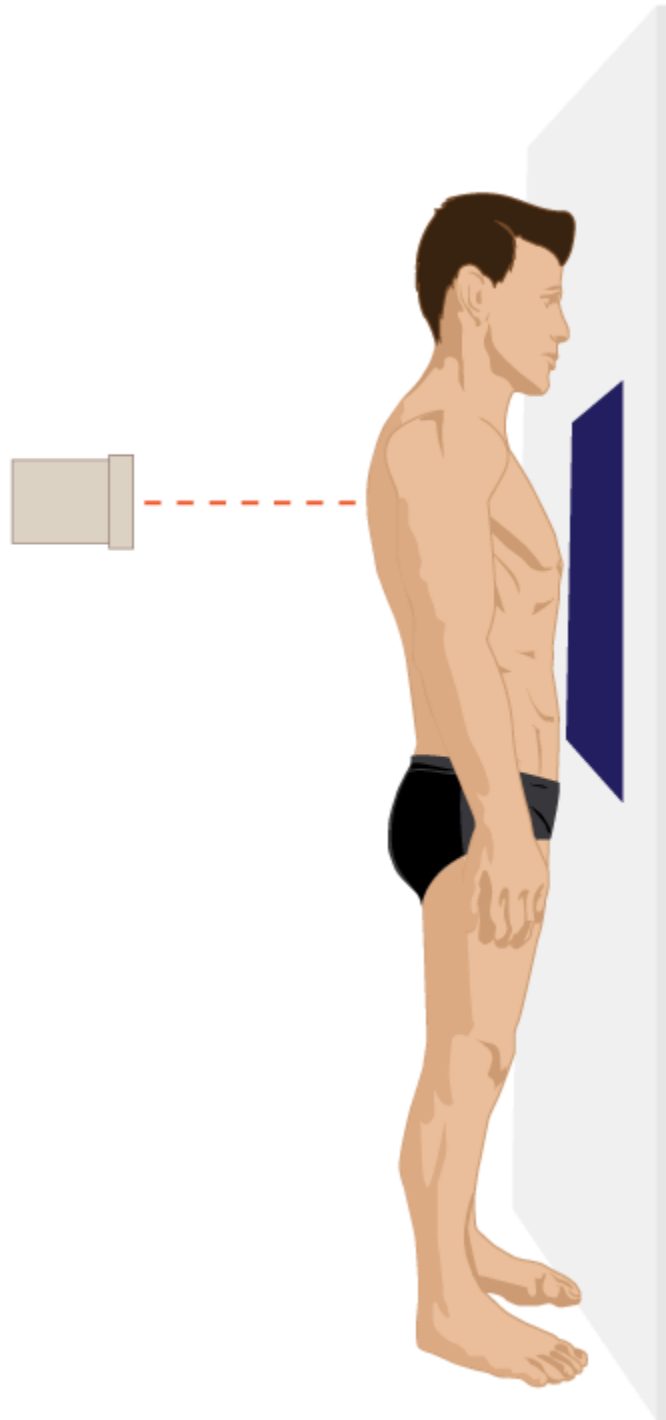


Figure 3.11A Posterior-anterior, upright, chest x-ray positioning.

Lateral Chest x-ray

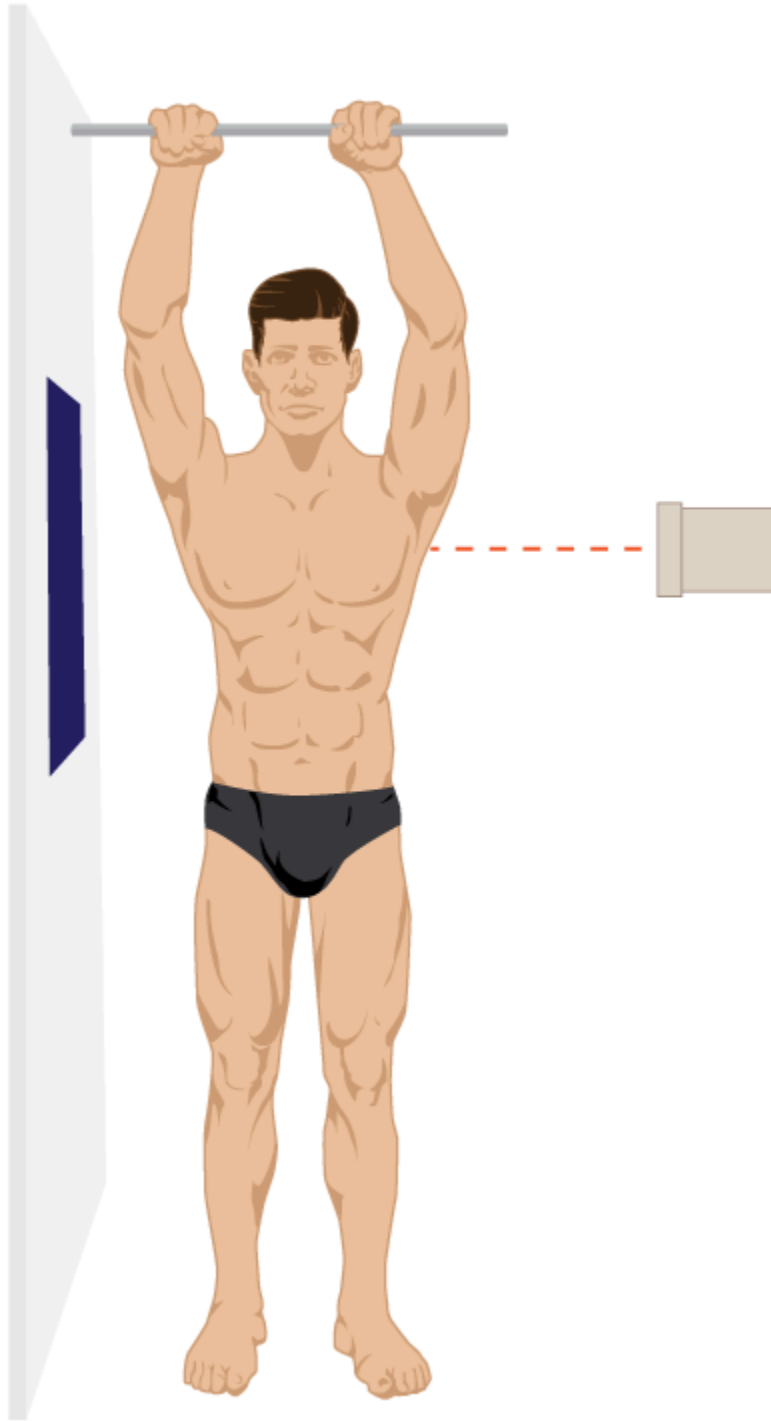


Figure 3.11B Lateral, upright, chest x-ray positioning.

Decubitus x-ray

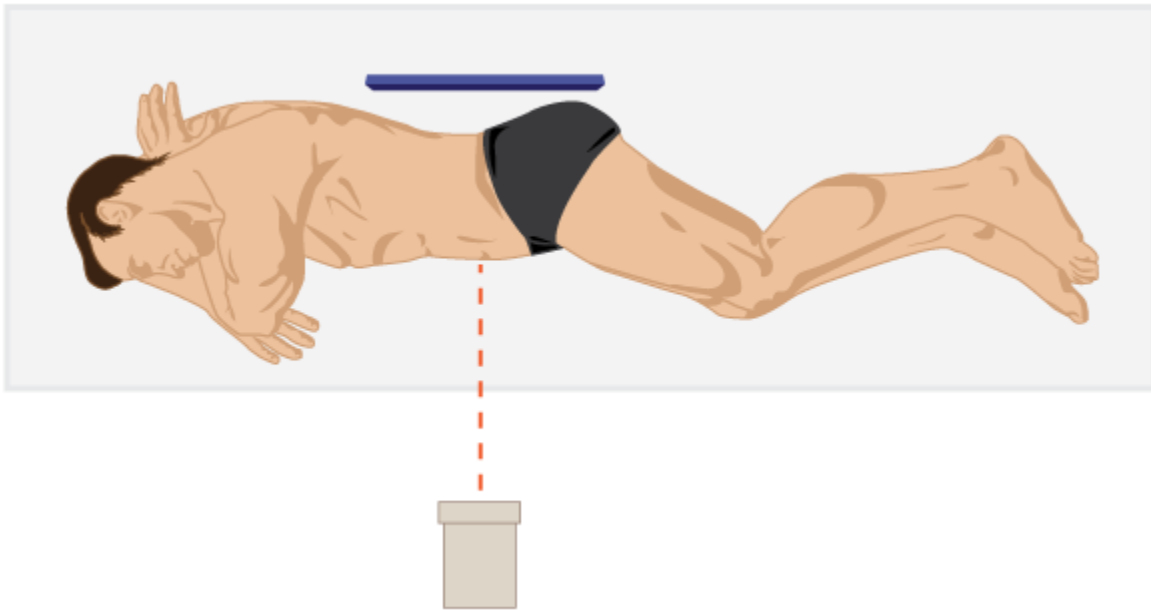


Figure 3.11 Decubitus positioning for a chest or abdomen x-ray.

Radiation Exposure: X-rays

X-rays are ionizing radiation. Thus, x-rays can cause tissue ionization and this can result in genetic alterations. The majority of the genetic alterations that occur do not lead to cellular damage and lead to no adverse genetic events or genetic mutation. However, it is practical, and appropriate, to minimize radiation exposure whenever possible. The, *As Low As Reasonably Achievable* approach (the *ALARA principle*) is an excellent strategy to employ in order to reduce the exposure of patients to x-rays. In addition, Appropriateness Guidelines (CAR, ACR, ESR), and strategies such as, “Choosing Wisely” and , “Imaging Gently” are also geared towards minimizing x-ray utilization if not clinically safe, appropriate. or helpful in managing the patient’s medical condition.

Attributions

Fig 3.3 [X-ray Tube by Kieranmaher](#) is in the Public Domain.

Fig 3.4 [X-ray Tube](#). Lead Housing with Portal for x-ray Emission, bench top image by [Rschiedon](#) is available under a [CC-BY-SA 3.0 Unported](#) License.

Fig 3.5 X-ray Image Creation and Display by Dr. Brent Burbridge MD, FRCPC, University Medical Imaging Consultants, College of Medicine, University of Saskatchewan is used under a [CC-BY-NC-SA 4.0](#) license.

Fig 3.6A A standard, fixed location, wall x-ray detector used for upright chest and abdomen x-rays by Dr. Brent Burbridge MD, FRCPC, University Medical Imaging Consultants, College of Medicine, University of Saskatchewan is used under a [CC-BY-NC-SA 4.0](#) license.

Fig 3.6B A Portable x-ray Machine by Dr. Brent Burbridge MD, FRCPC, University Medical Imaging Consultants, College of Medicine, University of Saskatchewan is used under a [CC-BY-NC-SA 4.0](#) license.

Fig 3.6C The Portable x-ray machine with the x-ray tube extended for use by Dr. Brent Burbridge MD, FRCPC, University Medical Imaging Consultants, College of Medicine, University of Saskatchewan is used under a [CC-BY-NC-SA 4.0](#) license.

Fig 3.6D A Portable, Mini, C-Arm x-ray Unit by Dr. Brent Burbridge MD, FRCPC, University Medical Imaging Consultants, College of Medicine, University of Saskatchewan is used under a [CC-BY-NC-SA 4.0](#) license.

Fig 3.7 Appearance of different entities on x-rays by Dr. Brent Burbridge MD, FRCPC, University Medical Imaging Consultants, College of Medicine, University of Saskatchewan is used under a [CC-BY-NC-SA 4.0](#) license.

Fig 3.8 Left Shoulder x-ray by Dr. Brent Burbridge MD, FRCPC, University Medical Imaging Consultants, College of Medicine, University of Saskatchewan is used under a [CC-BY-NC-SA 4.0](#) license. Accessible from <https://mistr.usask.ca/odin/?caseID=20160214201450302>

Fig 3.9 Effect of tissue thickness on x-ray appearance by Dr. Brent Burbridge MD, FRCPC, University Medical Imaging Consultants, College of Medicine, University of Saskatchewan is used under a [CC-BY-NC-SA 4.0](#) license.

Fig 3.10 Common x-ray Test Object, Lucite Plastic Board by Dr. Brent Burbridge MD, FRCPC, University Medical Imaging Consultants, College of Medicine, University of Saskatchewan is used under a [CC-BY-NC-SA 4.0](#) license.

Fig 3.11A Posterior-anterior, upright, chest x-ray positioning, by the Distance Education Unit, University of Saskatchewan, is published using a [CC-BY-NC-SA 4.0 International License](#).

Fig 3.11B Lateral, upright, chest x-ray positioning, by the Distance Education Unit, University of Saskatchewan, is published using a [CC-BY-NC-SA 4.0 International License](#).

Fig 3.11C Decubitus x-ray positioning, by the Distance Education Unit, University of Saskatchewan, is published using a [CC-BY-NC-SA 4.0 International License](#).

Mammography

Mammography images are created by the process of x-rays passing through breast tissue and interacting with a digital detector. The anode in the x-ray tube used for mammography is made of molybdenum, or rhodium, rather than tungsten which is commonly used in general x-ray tubes. For more information about x-ray formation see the previous section (X-rays).

This physical change to the x-ray tube anode results in a different spectrum of x-rays that are better suited to assessing the fat, connective tissue, and mammary tissue found in the breast. This allows for very detailed images of soft tissues using x-rays as the source of radiation. This imaging modality is predominantly used to image the female breast tissue but it is also capable of imaging male breast tissue for assessment of a palpable nodule or mass. A standard, digital, mammography unit is seen in Figure 3.12.

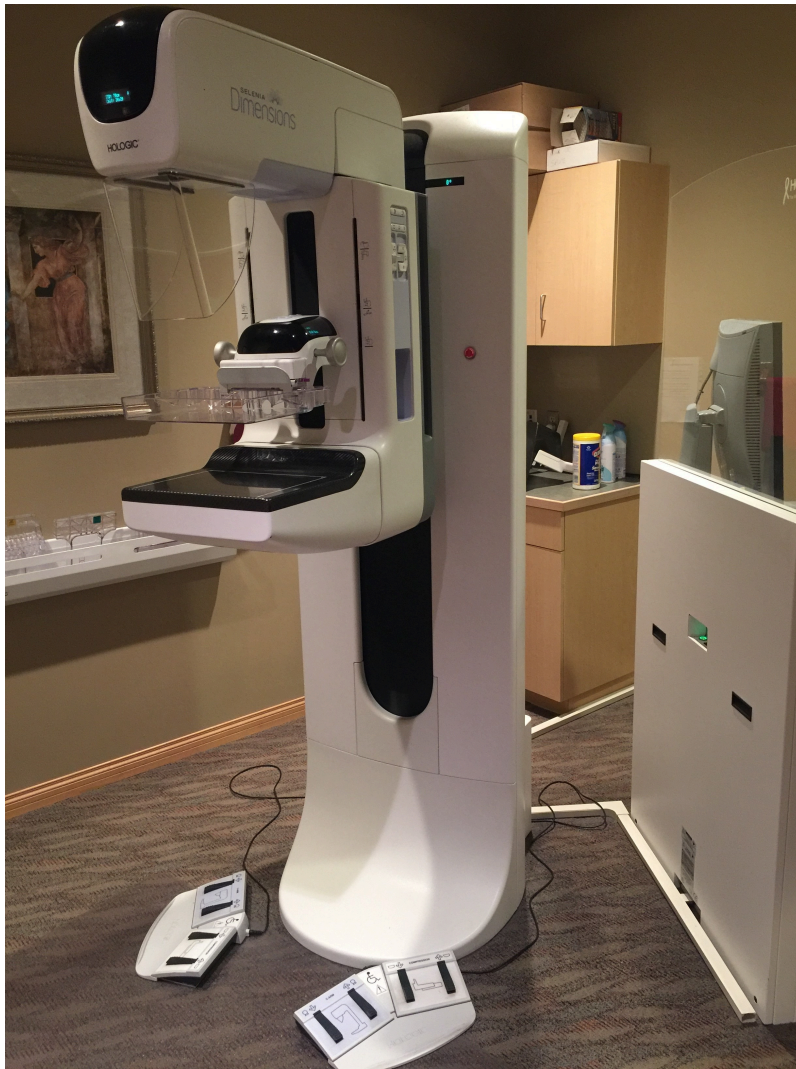

Figure 3.12 Mammography x-ray Machine

The standard positions for image acquisition in mammography is the cranial-caudal view and an oblique view. Additional mammographic positions, such as the lateral view, are used to problem solve complex abnormalities. The mammographic x-ray tube and detector are able to rotate along the coronal axis of the machine to allow for image acquisition in various planes to maintain stable patient positioning without the need for the patient to lean or tip in any particular direction. Newer mammography machines routinely obtain images as the x-ray tube and the detector plate rotate resulting in a process called tomosynthesis.

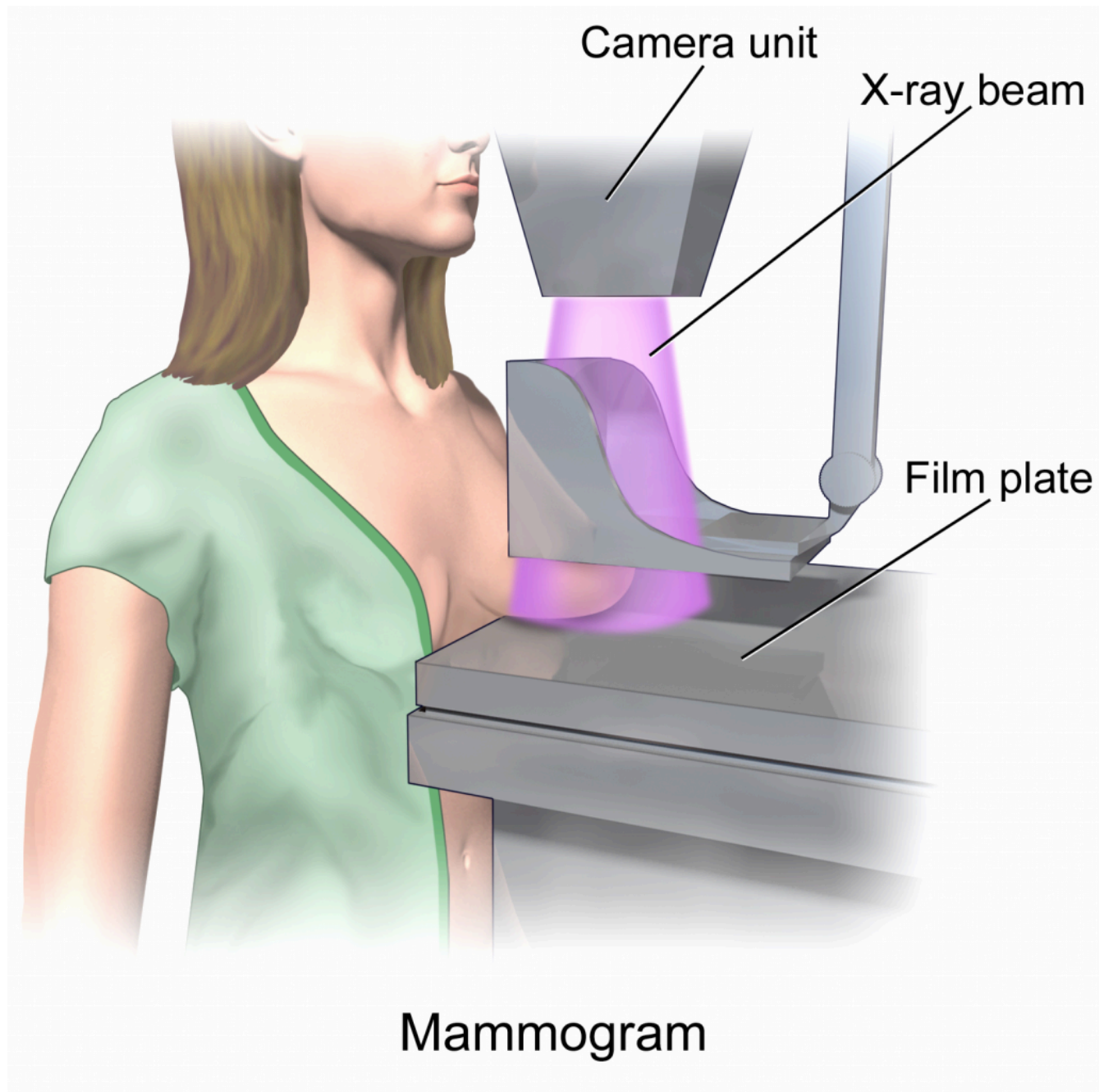


Figure 3.13A – CC Mammography Illustration

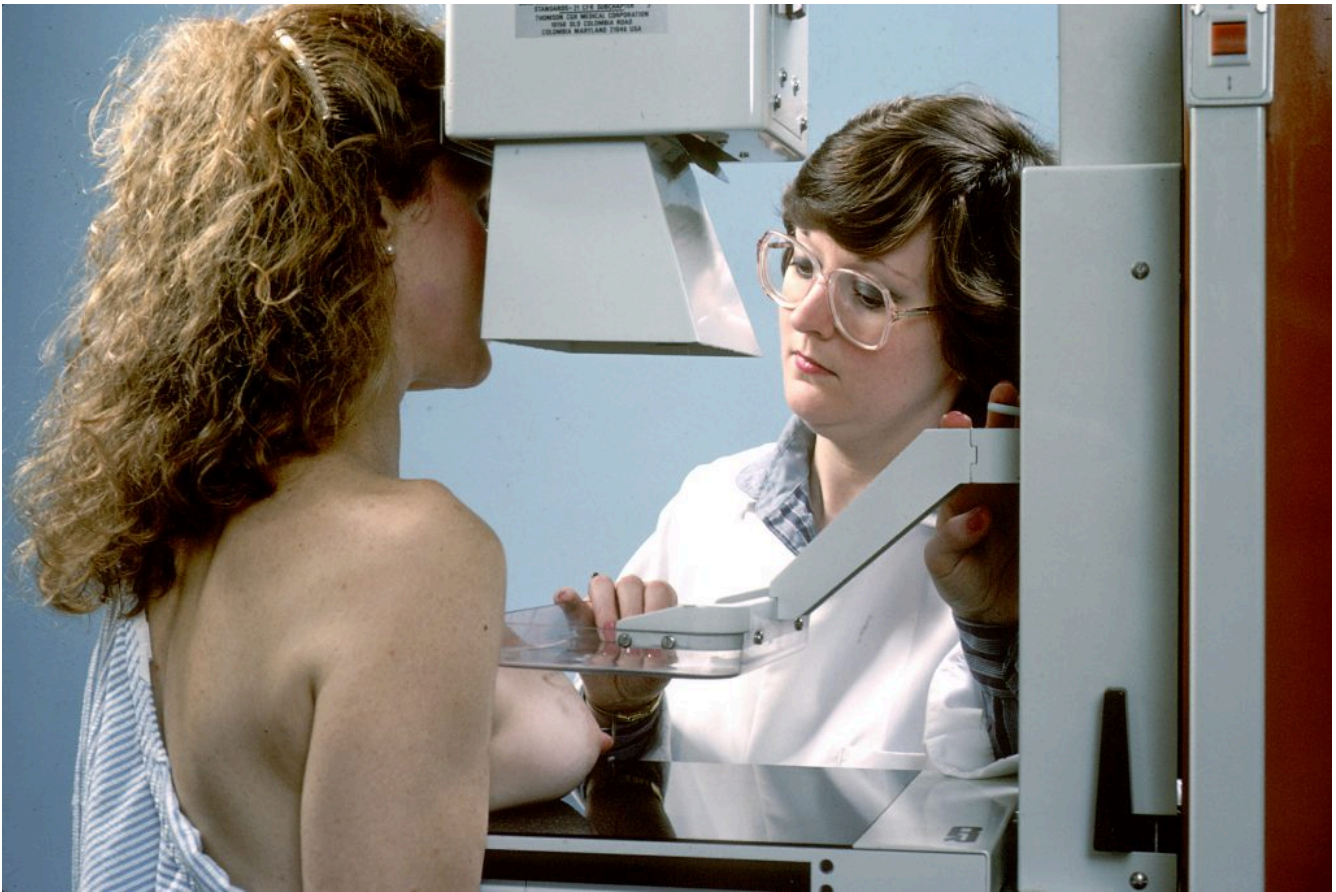

Figure 3.13B – Patient being positioned for a CC Mammogram

In order to minimize x-ray scatter and create a relatively uniform tissue density prior to x-ray exposure of the breast tissue it is standard practice to compress the breast tissue between radiolucent plastic plates. This can be uncomfortable for some patients but it is not dangerous or overly painful. An image of a patient positioned for a cranial-caudal mammographic image is provided (Figure 3.13).

The same general concepts of appearance of different tissues on x-rays applies to mammography, i.e. air is black, fat is lower opacity than mammary glands and connective tissue and calcium is the most opaque element visualized. The detection of small calcifications is a common finding on mammograms depicting breast cancer. The resulting x-rays generated by mammography are seen in Figure 3.14.

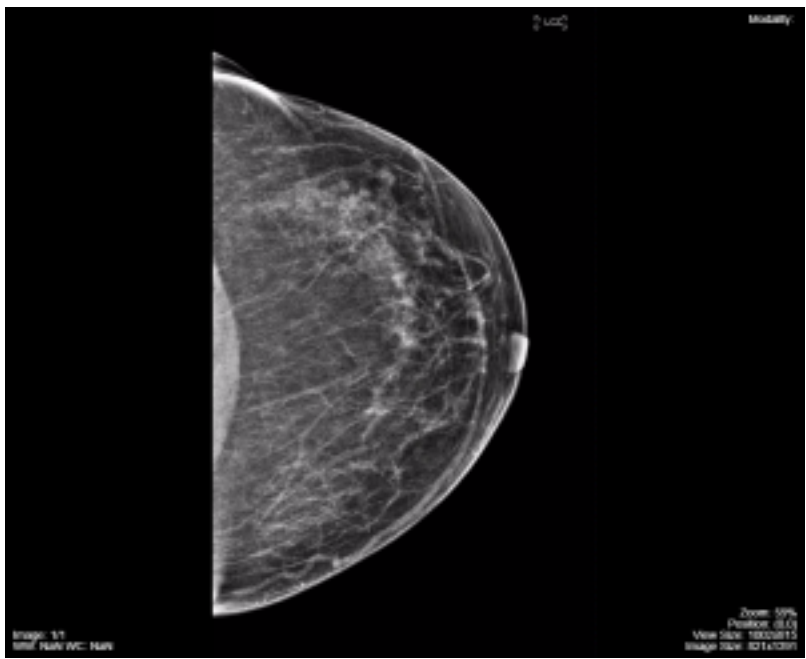


Figure 3.14A Mammography CC image, left side, normal screening mammography image

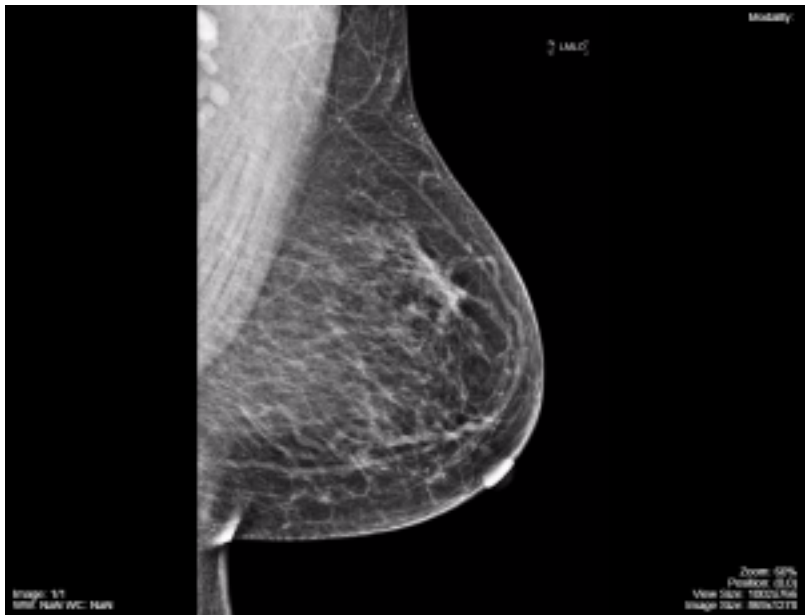


Figure 3.14B Mammography, MLO image, left side, normal screening mammography image

ODIN Link for Normal Mammography images, Figure 3.14: <https://mistr.usask.ca/odin/?caseID=20170410101815189>

These screening images depict normal breast tissue, fat, and connective tissue. The more opaque tissue at the back edge of the images is the pectoralis major muscle. The breast tissue is predominantly fat replaced and there is no evidence of atypical calcifications, a nodule, mass, or architectural distortion. Normal lymph nodes are seen in the axillary area.

Attributions

Fig 3.12 Mammography x-ray Machine by Dr. Brent Burbridge MD, FRCPC, University Medical Imaging Consultants, College of Medicine, University of Saskatchewan is used under a [CC-BY-NC-SA 4.0](#) license

Fig 3.13A Illustration for positioning for a Cranial-Caudal (CC) Mammogram by Bruce Blausen. Used under Creative Commons Attribution CC BY, 3.0, Unported. https://en.wikipedia.org/wiki/Mammography#/media/File:Blausen_0628_Mammogram.png

Fig 3.13B Imaging of a patient being positioned for a CC Mammogram. National Cancer Institute, Bill Branson. This image is in the public domain and can be freely reused. cancergovstaff@mail.nih.gov

Fig 3.14A Mammography CC image, left side, normal screening mammography image by Dr. Brent Burbridge MD, FRCPC, University Medical Imaging Consultants, College of Medicine, University of Saskatchewan is used under a [CC-BY-NC-SA 4.0](#) license. Can be accessed from <https://mistr.usask.ca/odin/?caseID=20170410101815189>

Fig 3.14B Mammography, MLO image, left side, normal screening mammography image by Dr. Brent Burbridge MD, FRCPC, University Medical Imaging Consultants, College of Medicine, University of Saskatchewan is used under a [CC-BY-NC-SA 4.0](#) license. Can be accessed from <https://mistr.usask.ca/odin/?caseID=20170410101815189>

Fluoroscopy

Fluoroscopy utilizes live x-rays to visualize anatomic structures. The live x-ray beam is activated by the radiologist performing the procedure. It is best utilized for examinations that depict active physical properties such as intestinal peristalsis or swallowing. The image quality in fluoroscopy is controlled by multiple x-ray detectors in the table that adjust the x-ray dose based upon the size and thickness of the tissue being imaged. The field of view of the x-ray exposure can also be controlled to minimize unnecessary exposure of other anatomy. The image can also be magnified to enhance detection of abnormalities.

An example of a fluoroscopic examination is the esophogram and upper gastrointestinal series. The patient is asked to swallow barium sulfate and gas-forming granules. The barium can be seen to move with positioning (gravity) and peristalsis as it moves antegrade through the digestive tract while the gas rises to the highest point of the intestinal tract based upon patient positioning. The barium and the gas help to outline the inner lining of the intestine. The live fluoroscopic x-rays visualize the motion of the barium and the gas. It is also possible to capture still images and/or cine mode images that are stored in the Picture Archive and Communication System (PACS).

Cine mode images are still images captured at a rapid rate and can be viewed sequentially, like a video, after being stored in the PACS. Other fluoroscopy aided examinations include arthrography, barium enema, cystourethrogram, sinus tract injections, myelography and hysterosalpingography, to name a few.

The positioning of the patient is dependent on the physical capabilities of the patient and the exam that is to be performed. For example, when carrying out an esophogram, the best positioning would be an upright (standing) patient and an oblique or lateral view of the anatomy to watch the barium proceeding down the esophagus. Additional oblique and lateral views allow one to visualize abnormalities in multiple planes and to determine if any abnormality of the intestinal mucosa is concealed by swallowed barium on one view. If aspiration of ingested fluid or food into the lungs is clinically suspected the lateral projection allows one to determine if fluids are entering the trachea during swallowing.

A Fluoroscopy machine is seen in Figure 3.15.

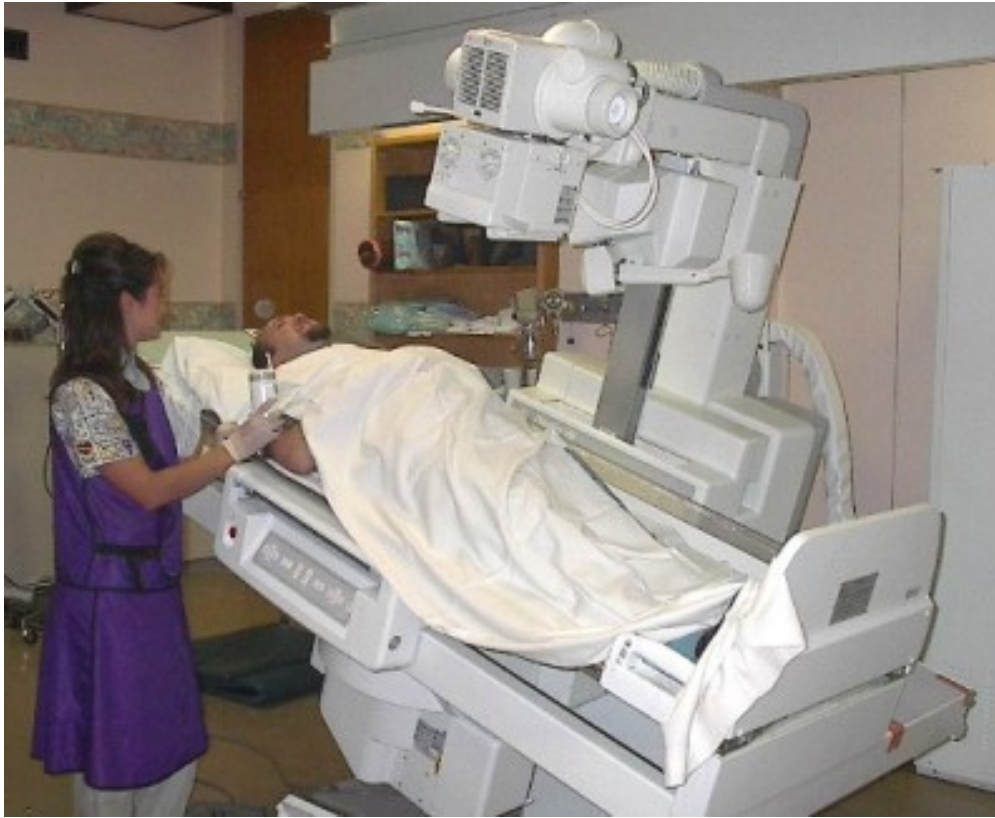

Figure 3.15 A Fluoroscopy Machine

Figure 3.16 depicts still images of a barium enema, performed to assess the colon for possible malignant polyps.

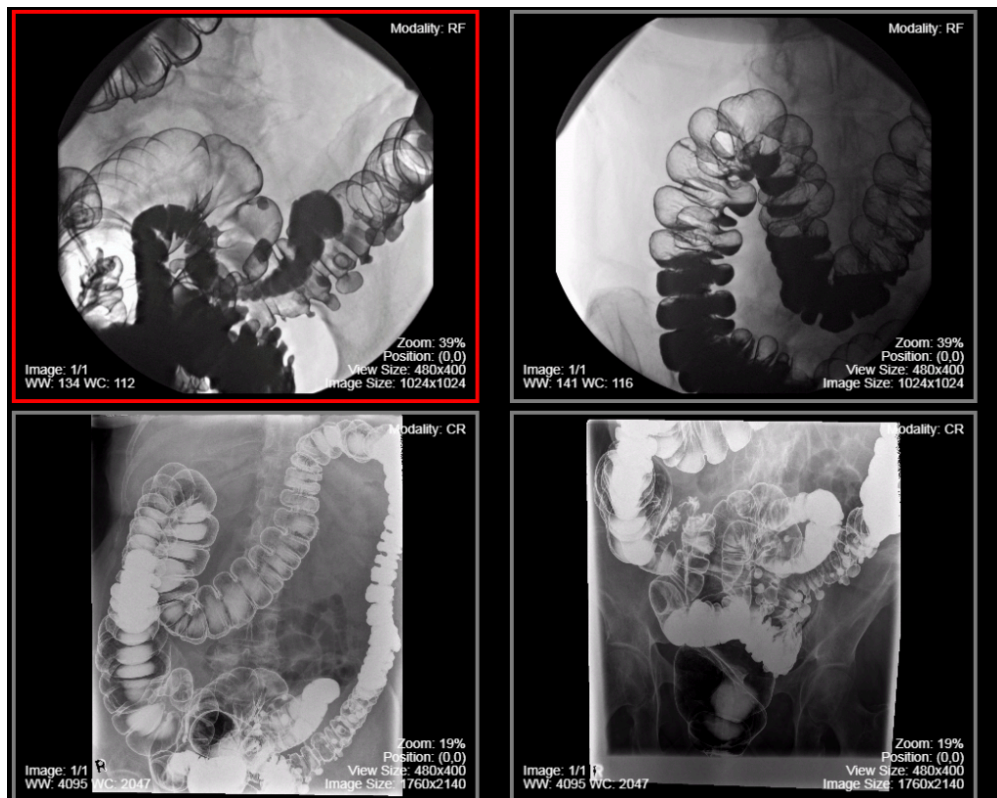


Figure 3.16 Barium Enema images

ODIN Link for Normal Barium Enema images, Figure 3.16: <https://mistr.usask.ca/odin/?caseID=20141112102803610>

The video in Figure 3.17 depicts live fluoroscopy of the upper esophagus for a patient whose images demonstrate aspiration of the barium into the trachea.



A video element has been excluded from this version of the text. You can watch it online here: <https://openpress.usask.ca/undergradimaging/?p=4806>

Figure 3.17 Fluoroscopy of the Pharynx and Upper Esophagus, video. Video clip available at <https://openpress.usask.ca/app/uploads/sites/34/2019/02/3.17-Fluoroscopy-cine-2.mp4>

ODIN Link for Pharynx Fluoroscopy images, Figure 3.17: <https://mistr.usask.ca/odin/?caseID=20160216105351798>

Fluoroscopy images are most often displayed for review inverted in comparison to standard x-ray images. Hence, air is white and metal is black. They can also be displayed as standard x-rays if this is advantageous for interpretation, see the barium enema images. The principles of absorption and transmission of the x-rays is unchanged, but the images are digitally manipulated to be the inverse of x-rays, much like film negatives in photography. The effect of image inversion for Fluoroscopy images is depicted in Figure 3.18.

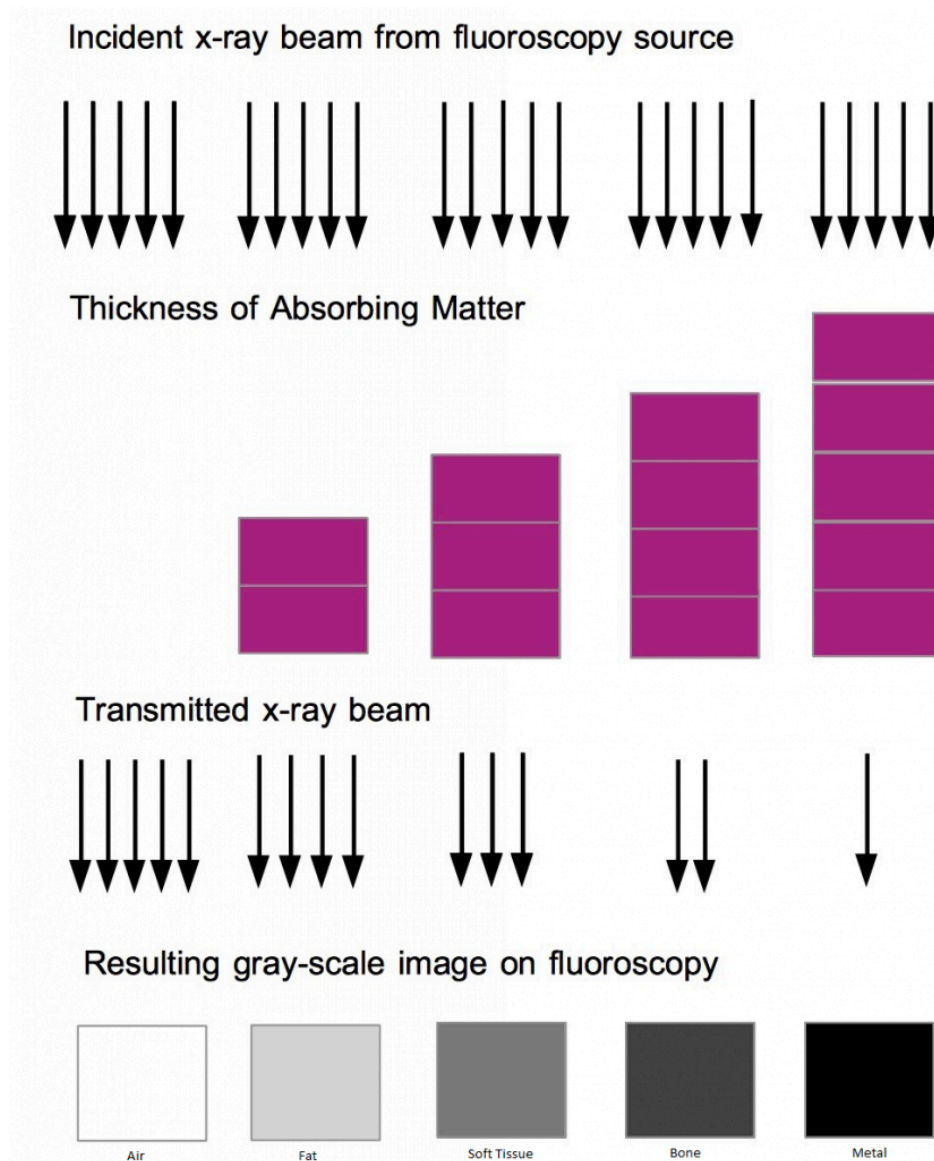


Figure 3.18 Fluoroscopy Images are Inverted in Comparison to x-rays

Fluoroscopy:

- Uses live x-rays
- Images are very often inverted compared to conventional x-ray images
- Often use barium sulfate and gas-forming granules as contrast

Examples of Fluoroscopic procedures includes:

- Esophagram
- Upper Gastrointestinal Series
- Arthrogram

- Barium Enema

Attributions

Fig 3.15 A Fluoroscopy Machine by Dr. Brent Burbridge MD, FRCPC, University Medical Imaging Consultants, College of Medicine, University of Saskatchewan is used under a [CC-BY-NC-SA 4.0](#) license.

Fig 3.16 Barium Enema images by Dr. Brent Burbridge MD, FRCPC, University Medical Imaging Consultants, College of Medicine, University of Saskatchewan is used under a [CC-BY-NC-SA 4.0](#) license.

Fig 3.17 Fluoroscopy of the Pharynx and Upper Esophagus, video by Dr. Brent Burbridge MD, FRCPC, University Medical Imaging Consultants, College of Medicine, University of Saskatchewan is used under a [CC-BY-NC-SA 4.0](#) license. Video can be accessed at <http://openpress.usask.ca/undergradimaging/wp-content/uploads/sites/34/2017/07/Fluoroscopy-cine-2.mp4>. Static images can be accessed at <https://mistr.usask.ca/odin/?caseID=20160216105351798>.

Fig 3.18 Fluoroscopy Images are Inverted in Comparison to x-rays by Dr. Brent Burbridge MD, FRCPC, University Medical Imaging Consultants, College of Medicine, University of Saskatchewan is used under a [CC-BY-NC-SA 4.0](#) license.

Angiography

This modality relies upon x-rays to create images. It is a fluoroscopy unit with advanced features required for vascular and other interventional procedures. For discussion regarding the creation of x-rays used for fluoroscopy, see the X-ray section.

An angiography machine is essentially a fluoroscopy unit that has the added feature of having the x-ray source and detectors mounted on a c-arm apparatus. The c-arm allows for movement of the source and detector around the patient who lies supine on the angiography table. The operator can acquire images in a wide variety of anatomic projections. Therefore, patient movement is not required for this imaging modality. The angiography unit also has advanced software applications that facilitate complex arterial and body interventional procedures beyond the capabilities of a standard fluoroscopy unit. As with fluoroscopy, the images are viewed inverted in comparison to standard radiographs.

The x-ray dose for Angiography is controlled by multiple detectors that adjust the radiation exposure to maximize image quality and minimize x-ray exposure. The machine only emits radiation when the operator uses a foot pedal to activate the x-ray tube. The area imaged can be collimated, or coned, to minimize the area exposed to x-rays. The anatomy can also be magnified to improved diagnostic capacity.

The images acquired are obtained very rapidly in cine mode resulting in a set of stacked images, that when stored and viewed, simulate a video recording. Cine mode allows for the dynamic assessment of moving contrast and movement of catheters and guide wires inside the anatomy of the patient. A standard c-arm angiography unit is depicted in Figure 3.19.

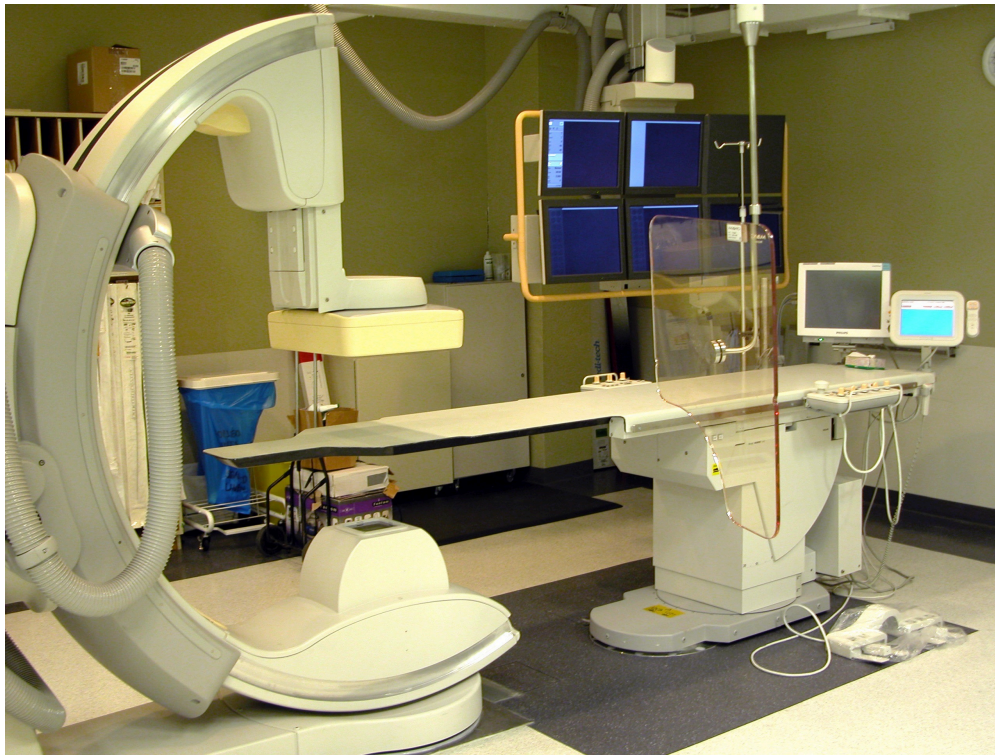

Figure 3.19 Angiography Machine with C-Arm

For angiography, the radio-opaque contrast agent used is injected intra-arterially while x-ray images are acquired. This is an invasive process that requires the injection to be performed via a small intra-arterial catheter that administers the contrast in close proximity to the origin of the arterial structure being investigated, i.e. carotid angiography requires an injection of contrast into the selected carotid artery. The catheter used is usually manipulated into position using fluoroscopy from a remote arterial access site i.e. the common femoral artery, the radial artery, or the brachial artery.

Arterial access relies upon the “Seldinger” technique, using local anesthetic, to insert the intra-arterial catheter used for the procedure. Blood vessels lack internal innervation and therefore, the catheter and guidewire can be manipulated without causing patient pain or discomfort.

This machine can also be used for Interventional Radiology procedures where catheters, guidewires, stents, feeding tubes, etc. are visualized with the c-arm fluoroscopy. Water-soluble contrast agents can also be injected during these procedures to depict the anatomy of structures such as, the bile ducts, intestine, renal collecting system, veins, etc.

Digital Subtraction Angiography

All modern angiography units capture images and present them in subtracted mode. The subtraction process is digital using a computer to superimpose a non-contrast enhanced image onto a set of contrast enhanced cine images, resulting in subtracted images that depict only the anatomic structure filled with contrast since the back-

ground anatomy has been subtracted away by the digital image modification process. A digital, subtracted, carotid angiogram is depicted in Figure 3.20.

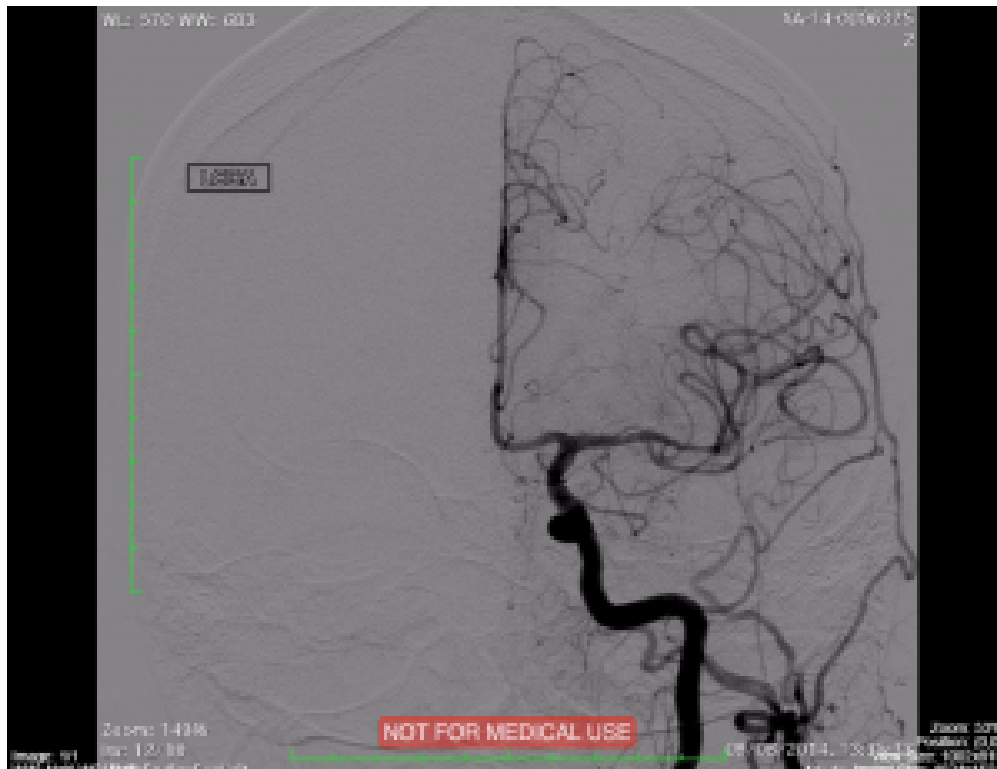

Figure 3.20: Carotid Angiography, Digital Subtraction Angiography

ODIN Link for Carotid Angiography images, Figure 3.20: <https://mistr.usask.ca/odin/?caseID=20160216203559803>

The contrast used for angiography is an iodine based pharmaceutical and is water soluble. During angiography, it is injected into the artery of interest and replaces the blood for a very short period of time. This contrast agent progresses antegrade in the vascular tree related to the direction of blood flow. It quickly clears from the arteries and exits the region via venous drainage. The circulating contrast is predominantly excreted by the kidneys into the urine.

Angiography:

- Uses x-rays
- Is invasive; requires contrast administered intravenously or intra-arterially
- Images are presented inverted in “digital subtraction” mode (DSA)

Attributions

Fig 3.19 Angiography Machine with C-Arm by Dr. Brent Burbridge MD, FRCPC, University Medical Imaging Consultants, College of Medicine, University of Saskatchewan is used under a [CC-BY-NC-SA 4.0](#) license.

Fig 3.20 Carotid Angiography, Digital Subtraction Cerebral Angiography by Dr. Brent Burbridge MD, FRCPC, University Medical Imaging Consultants, College of Medicine, University of Saskatchewan is used under a [CC-BY-NC-SA 4.0](#) license.

Computed Tomography (CT)

CT relies upon x-rays to facilitate image creation. The x-ray tube is situated in a ring assembly that is able to spin around the horizontal table that the patient lies on. The x-ray tube generates x-rays only when programmed and activated by a CT Technologist. The detectors for the x-rays that pass through the patient are located in the ring structure and rotate in unison with the source of the x-rays. The whole assembly that holds the x-ray tube and x-ray detectors is in the large doughnut shaped part of the unit called, the gantry. At the same time that the tube and detectors spin the horizontal table top that the patient lies on moves slowly through the gantry ring. This rotating x-ray source, associated with the rotating detectors, and the horizontally moving table top is called a helical CT scanner. This imaging device is presented in Figure 3.21.

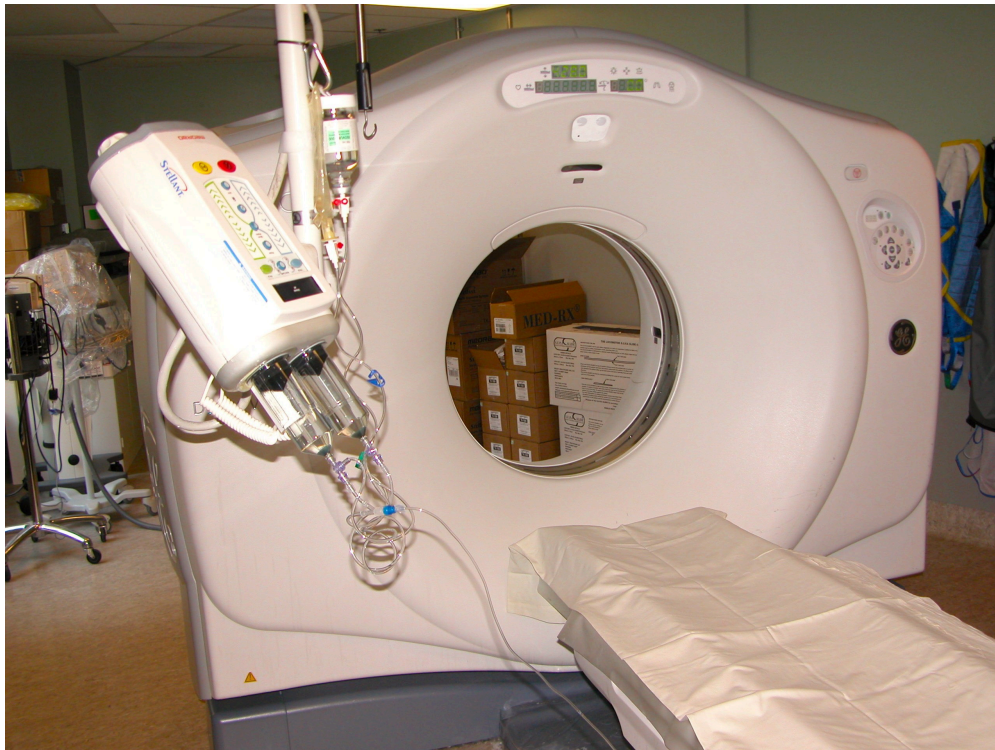

Figure 3.21 Helical CT Scanner

The patient does not need to be moved, or re-positioned, to obtain CT images in different anatomic planes. The patient lies on the CT table in anatomic position and remains in that position throughout the study. The stan-

Standard orientation of image acquisition for CT is in the axial plane, hence the old name for this machine of CAT (computed axial tomography) scanner. Often the axial images obtained during the initial x-ray exposure will be digitally reformatted into other anatomic planes i.e. sagittal and coronal. These reformatted images are the result of a computer algorithm reformatting the original digital image data and, as such, these supplemental anatomic planes of imaging do not require additional x-ray exposure.

The CT gantry can be tipped cranially and caudally to deviate from the axial plane by 30 degrees in either direction and this can be used to correct for patient anatomic variability to maintain the axial plane, if necessary. It also allows for unique imaging along an angled plane that can be used when requested by the referring physician or the radiologist. A widely used example of imaging in an angled plane is found for CT Head examinations. It is not conventional to acquire these images in the axial plane but to image the brain on the canthomeatal (lateral orbit canthus to the aural meatus) line and therefore, the CT gantry must be tilted to ensure that all CT Head images are acquired in this plane. Originally, this plane was chosen as it maximizes information about the intra-cranial contents while minimizing the exposure of the orbits (lens) to radiation. The orbito-meatal line has become the internationally recognized plane for acquiring CT head images. This line is depicted in Figure 3.22.

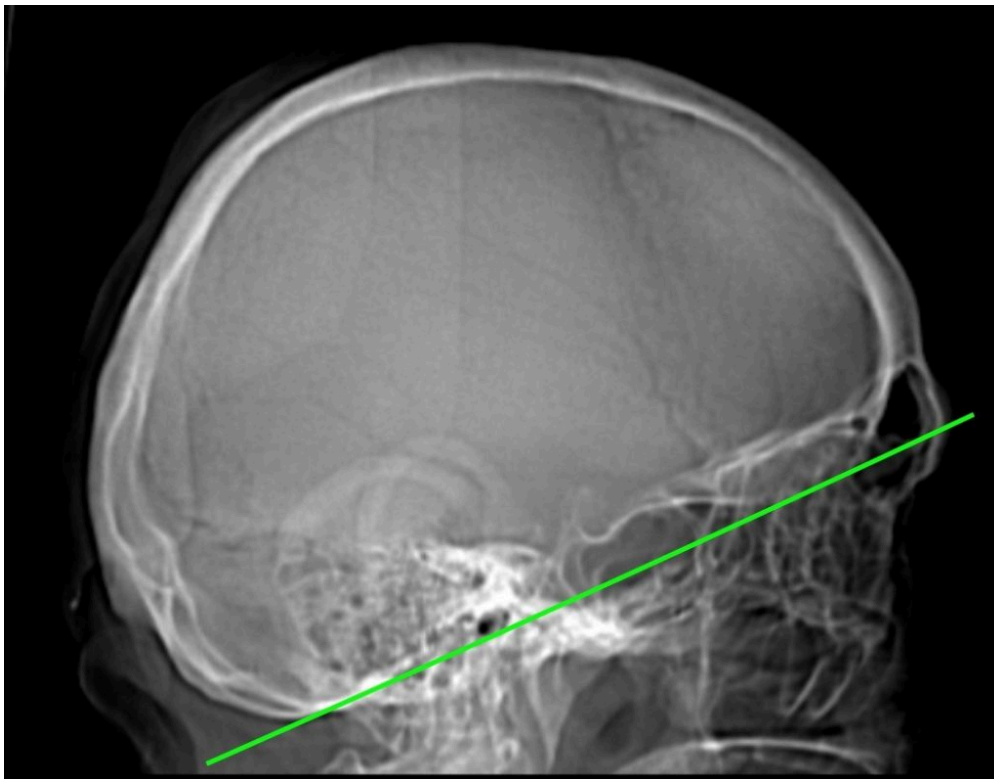


Figure 3.22 The plane of imaging related to the cantho-meatal line

The physics of CT image creation are complex and require complex computer processing to create images that are visible for clinical use. As the x-ray tube and the x-ray detectors revolve around the patient thousands of mathematical calculations are performed to determine how much of the incident x-ray beam was absorbed by a volume of tissue. This volume of tissue is called a voxel. The calculated absorption of the x-rays by a voxel is converted into a pixel density that is displayed on a gray scale from -1,000 (air) to +1,000 (metal). This scale is called the **Hounsfield unit (HU) scale** after one of the principle inventors of CT, Sir Godfrey Hounsfield. The calculated

density of this voxel is then allocated to a pixel on a grid of the 512 x 512 pixels that forms each individual CT image.

Therefore, if the volume of tissue contained air, or gas, the pixel density allocated would be close to -1,000 HU, while if the volume of tissue analyzed contained metal (bullet fragment, etc.) the pixel would be assigned a density close to the +1,000 HU. The assignment of pixel density to voxels spans the entire possible range of pixels from -1,000 – +1,000 HU, resulting in 2,000 shades of grey. An image with the HU measurements of specific anatomic regions is provided in Figure 3.23.

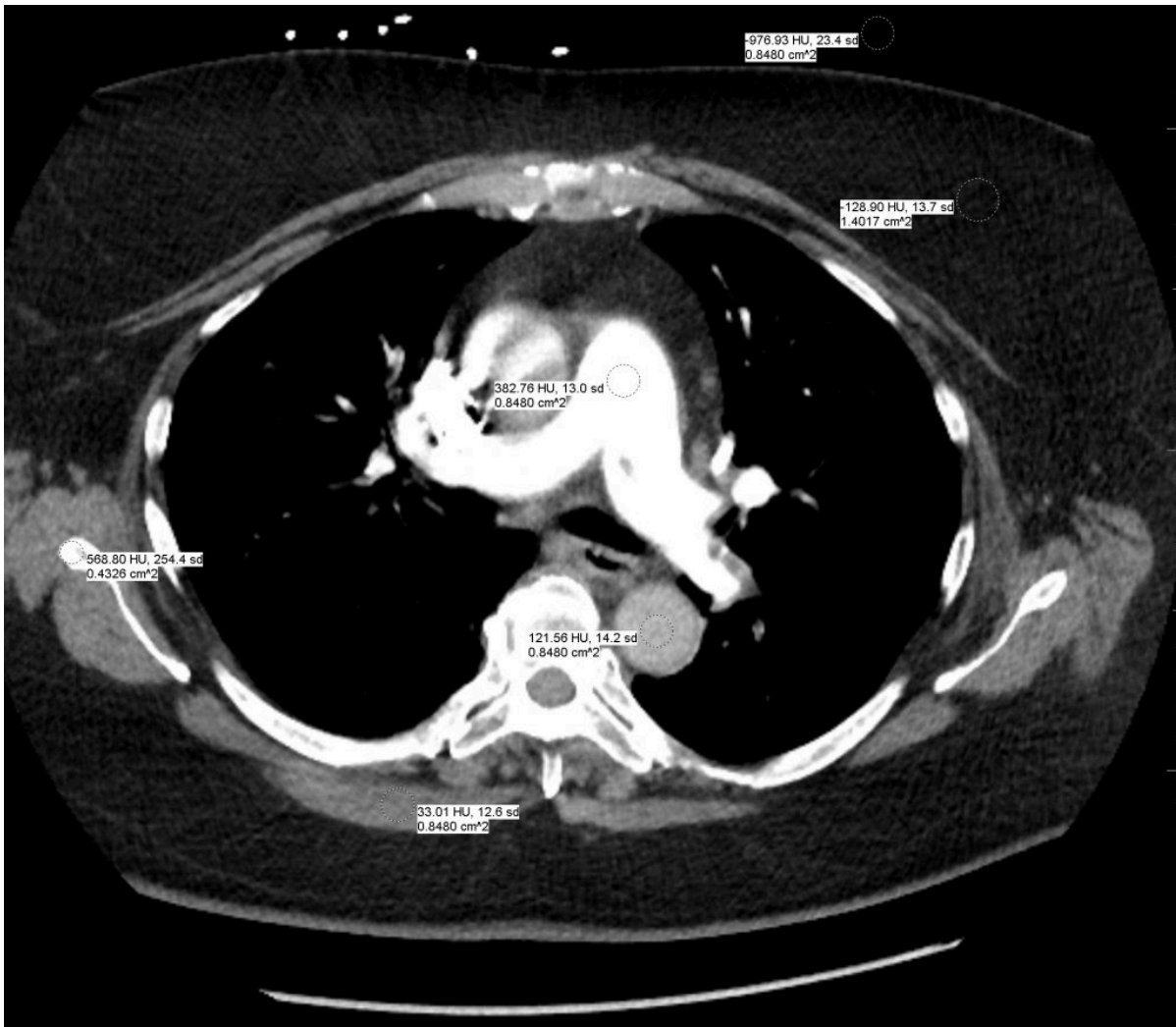


Figure 3.23 Images of CT with HU measurements

CT density: a region on a CT image is described as being more, or less, dense than another region. The liver is more dense than the renal cortex. This variation in pixel density can be quantified by measuring all the pixels in a region and creating an average pixel density i.e. region of interest of an area of liver can be measured, with a standard deviation, 50 HU +/- 5 HU, etc. The HU density of some common structures is provided in Table 3.2.

- 1000	Air
- 600	Lung
- 120 to - 90	Fat
0	Water
- 5 to 15	Bile
10 to 15	CSF
20 to 40	Soft Tissue
20 to 30	White Matter
37 to 45	Grey Matter
40	Old Blood
80 to 100	Acute Blood
700	Medullary Bone
800	Cortical Bone
1000	Metal

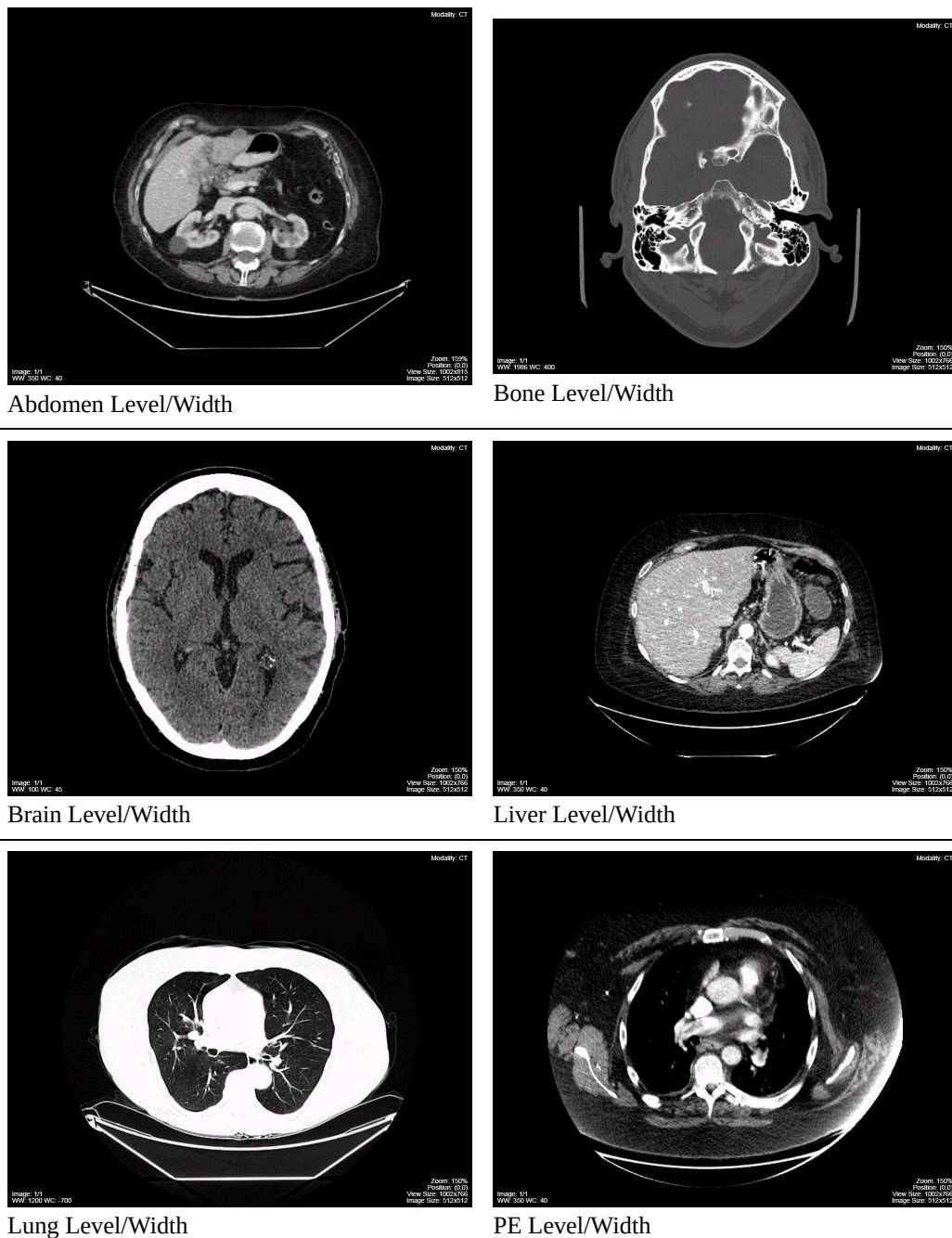
Table 3.2 HU Scale

The viewer of the CT can decide how to adjust the level and window of the displayed CT images to accentuate tissues of a defined pixel density. The level and window are at the discretion of the viewing radiologist and can be set to their preferences. There are a variety of established level and window settings, i.e. abdomen, bone, brain, etc. These help to provide some level of uniformity for comparison of multiple CT examinations. Level and window setting for six common tissues are as follows:

Anatomy	Level	Window
Abdomen	40	400
Bone	300	2000
Brain	35	80
Liver	50	200
Lung	-700	1500
PE	50	351

Table 3.3 Six common tissue levels and windows

CT images demonstrating the appearance of these six different level and window settings are provided in Figure 3.24.



Abdomen Level/Width

Bone Level/Width

Brain Level/Width

Liver Level/Width

Lung Level/Width

PE Level/Width

Figure 3.24 CT images with different level and window settings

ODIN Link for Figure 3.24: <https://mistr.usask.ca/odin/?caseID=20170706145901557>

Level and **Window** are unique physical properties of CT images that allow the user to adjust the centre and the width of the gray scale that is portrayed on the images. This is an adjustment that is applied to the raw CT data and does not require repeated patient imaging to obtain the different levels and windows. The level is the centre of the gray scale, set to the HU of the tissue of most interest i.e. the centre (level) of the gray scale for brain window is 35 HU. The window is the width of the gray scale that surrounds the level setting, thus defining the range of

HU for white and black seen on the image. For the brain images the width of the HU scale is 80 HU. An illustration depicting this for brain and bone level and window setting are provided in Figure 3.25.

Brain




Figure 3.25A Brain Level and Window

Bone



Figure 3.25B Bone Level and Window

Once the window range is set, any structures with a pixel density greater than the defined window will appear white and everything with a pixel density less than the defined window will appear black. The ability to adjust the range of greys that are displayed on the image, makes it possible for the interpreter to analyze and compare structures of interest. It is important to remember that when viewing images on a particular level and window setting the anatomy of structures that fall outside the gray scale you are viewing will not be optimally analyzed. This is particularly evident when you assess the difference in appearance of the head images provided demonstrating the brain and the bone level and window settings. Brain tissue is well visualized on the brain level and window while there is no useful information about the bone of the skull and vice versa when the bone level and window is viewed, see Figure 3.26.

Brain

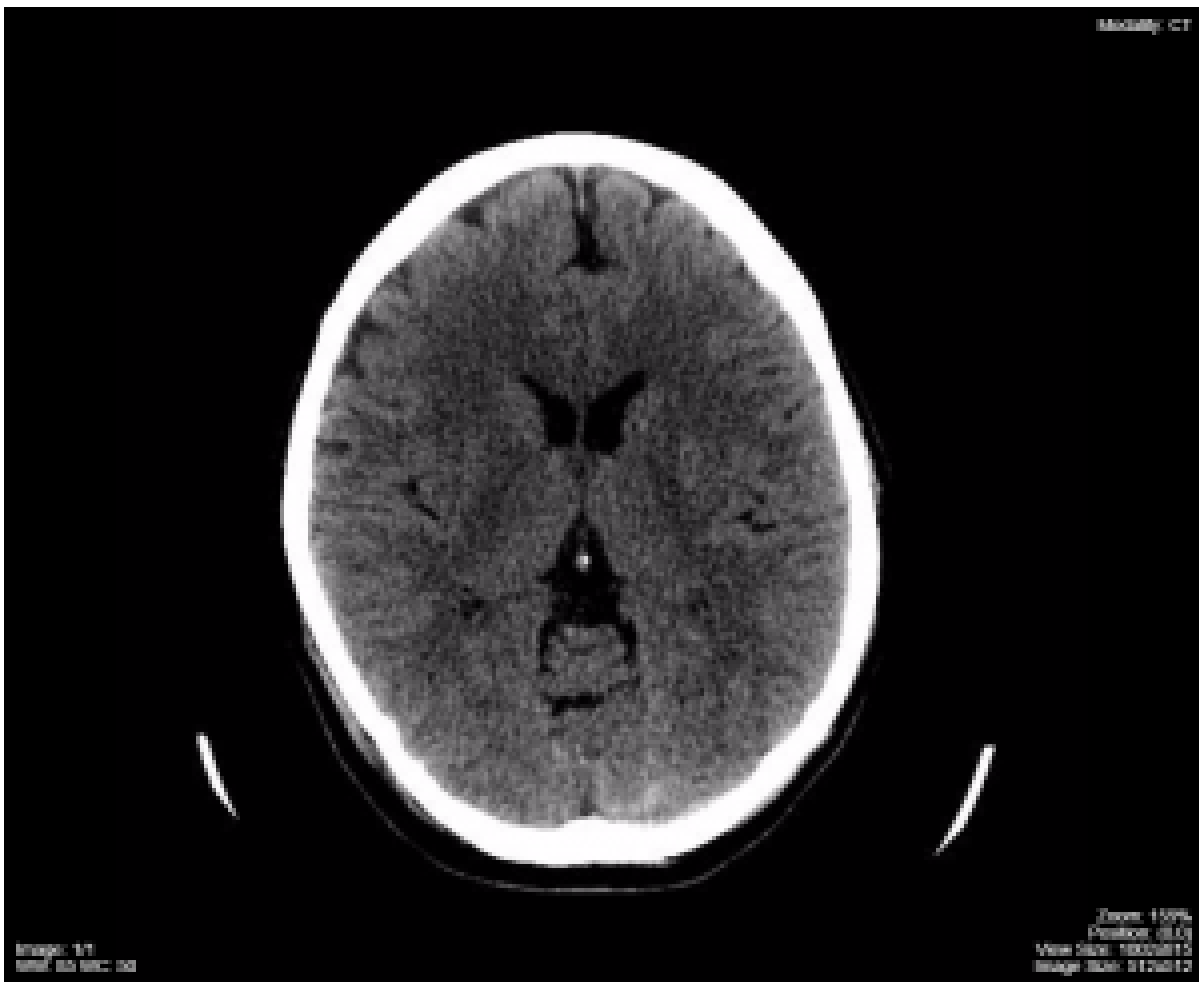

Figure 3.26A Head CT visible on brain level and window. Bone not well seen.

Bone

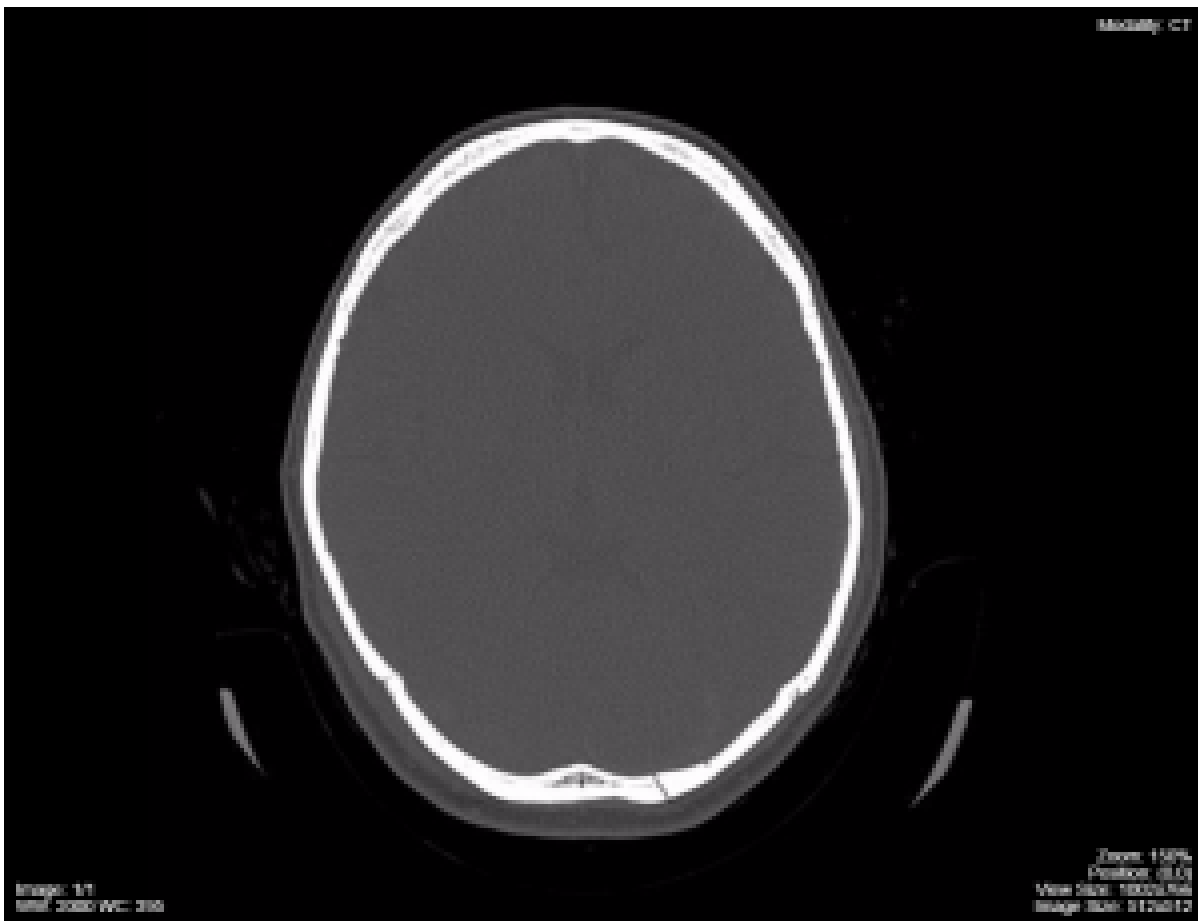


Figure 3.26B Head CT on bone level and window. Brain not well seen.

ODIN Link for Figure 3.26: <https://mistr.usask.ca/odin/?caseID=20170714073330478>

It is important to realize the effect of level and window and review the image data set provided to you at all the appropriate level and window settings. For example, in the thorax one should view the images on lung, mediastinal, and bone level and window settings to perform a full assessment of the patient's anatomy.

The standard viewing format for the CT image display is to look at the images like a loaf of sliced bread with the observer standing at the foot end of the table while the patient is in anatomic position. Therefore, the patient's right sided anatomy is on the left side when looking at the display monitor. The image is marked with a R (right), L (*left*), A (anterior), and P (posterior) indicators to orient the viewer. See Figure 3.27.

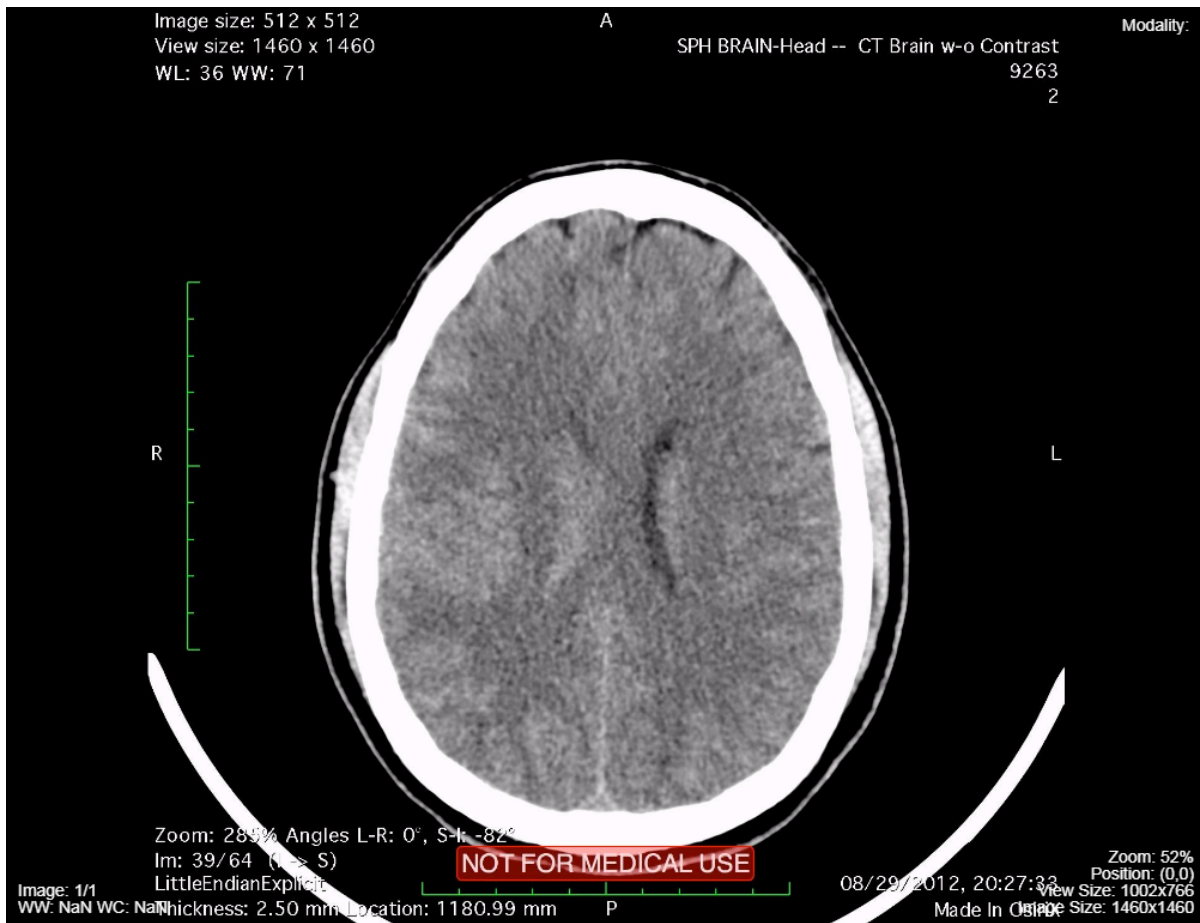


Figure 3.27 Standard viewing orientation for an axial CT image

ODIN link for Figure 3.27: <https://mistr.usask.ca/odin/?caseID=20160216160816162>

CT imaging administers a high radiation exposure to the patient compared to other imaging modalities. The best way to limit patient radiation exposure is to not image excessive anatomy i.e. plan the CT scan to image as little anatomy as possible. Newer CT scanners have the ability to adjust the x-ray dose administered based upon the changes in volume and thickness of the patient anatomy. Also, newer scanners can use software algorithms to reformat images obtained with very low dose radiation and achieve diagnostic quality.

There are two major technical features of the CT data set that helps to minimize overall patient radiation exposure:

a) The images are obtained as such thin slices, so closely aligned to each other, that the digital data can be reformatted with software in the coronal and sagittal planes with resulting very high image quality. Therefore, the patient only requires one dose of radiation to achieve visualization of their anatomy in the axial, coronal, and sagittal planes, this minimizing overall radiation exposure. (See Figure 3.28)

Axial

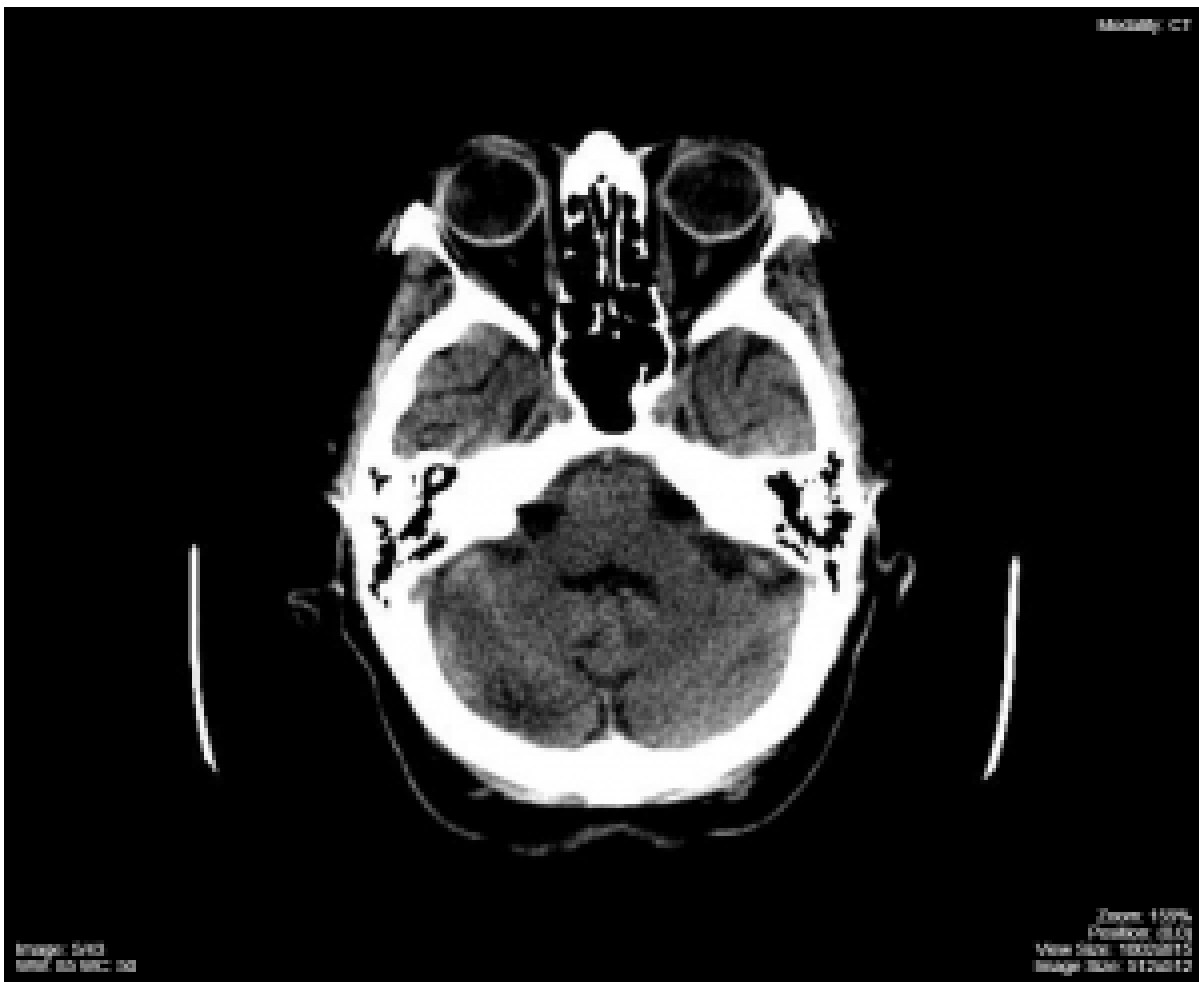

Figure 3.28A CT image displayed in axial orientation

Sagittal

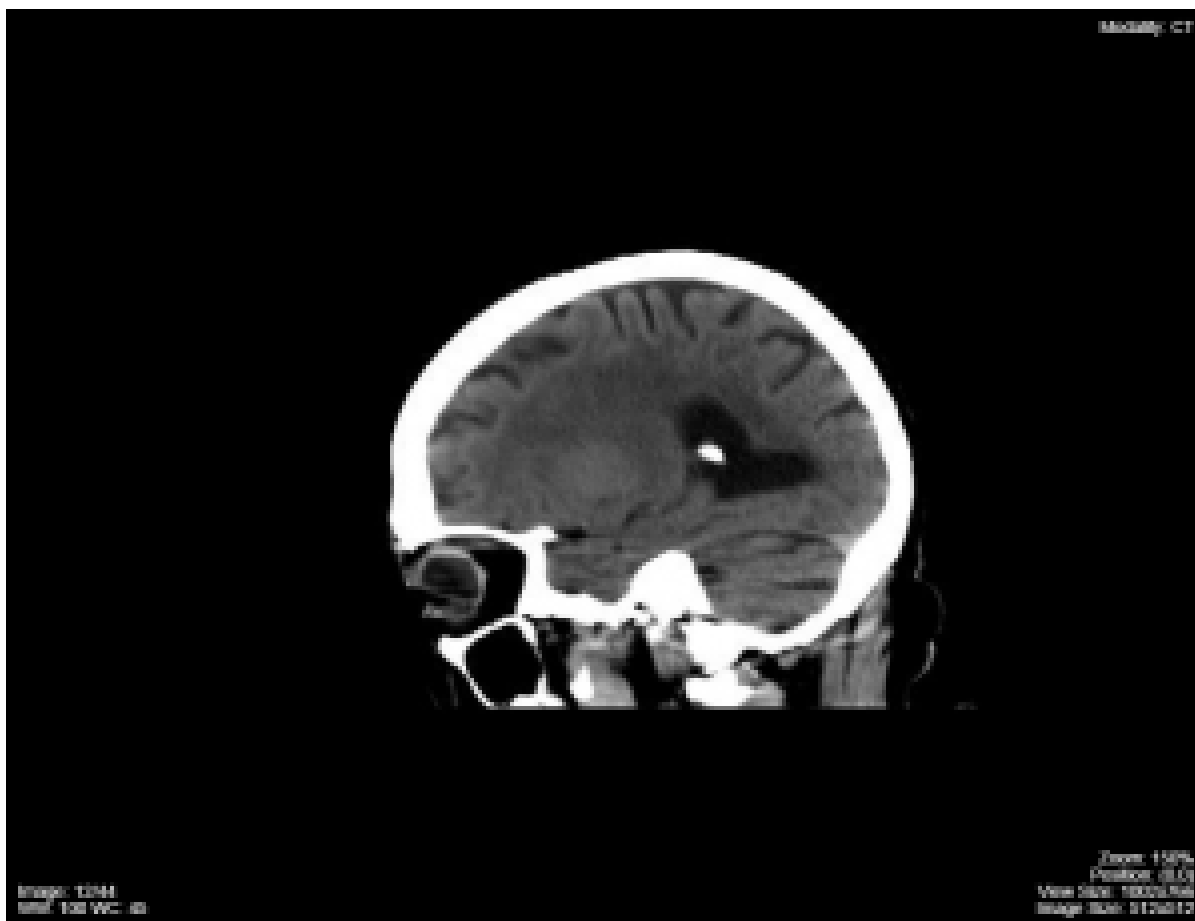

Figure 3.28B CT image displayed in sagittal orientation

Coronal

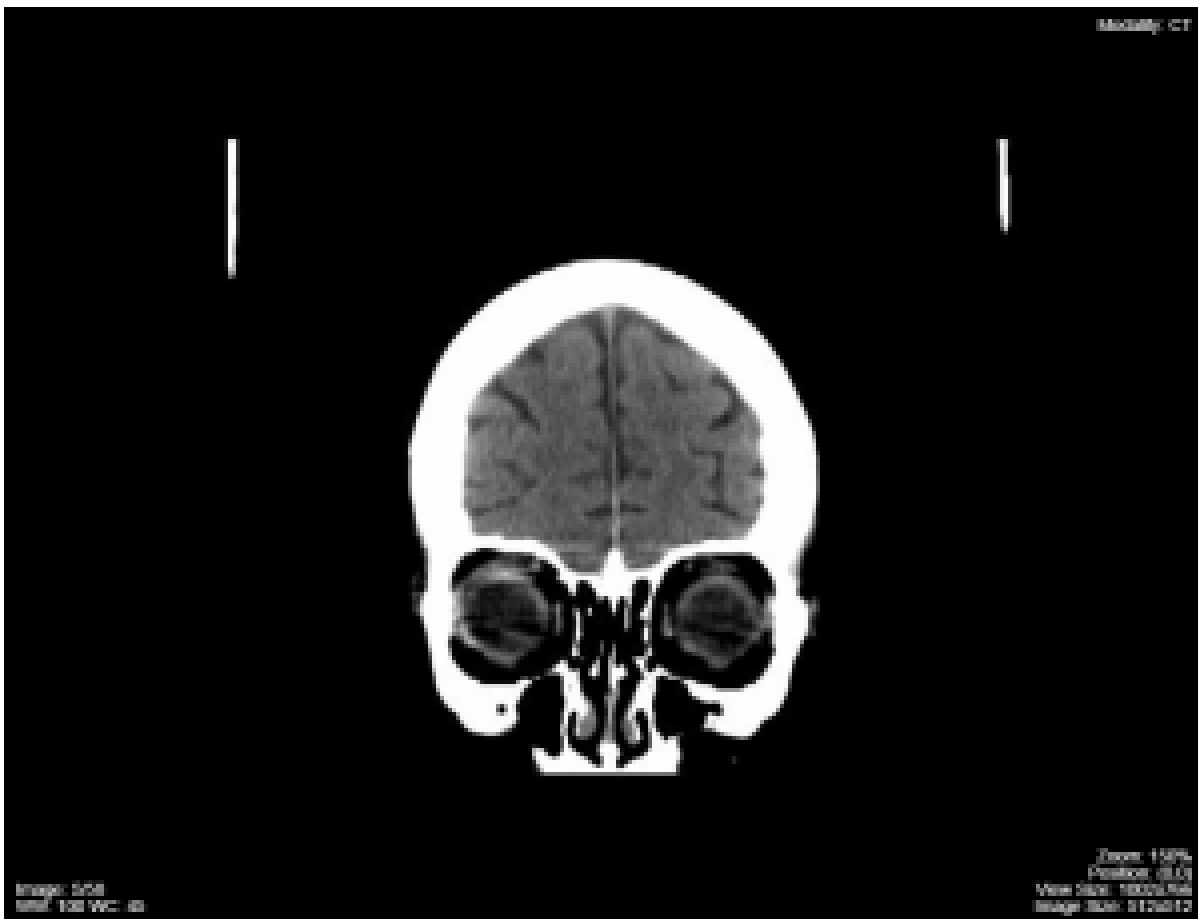


Figure 3.28C CT image displayed in coronal orientation

ODIN Link for Figures 3.28A – C: <https://mistr.usask.ca/odin/?caseID=20160216170931060>

b) The level/window settings can be adjusted for each individual image, regardless of the displayed plane of imaging, to best demonstrate a wide variety of anatomy, i.e. bone, lung, abdomen, mediastinum, etc. This again provides maximum utility of the images acquired from a single radiation dose. (See figure 3.29)

Lung

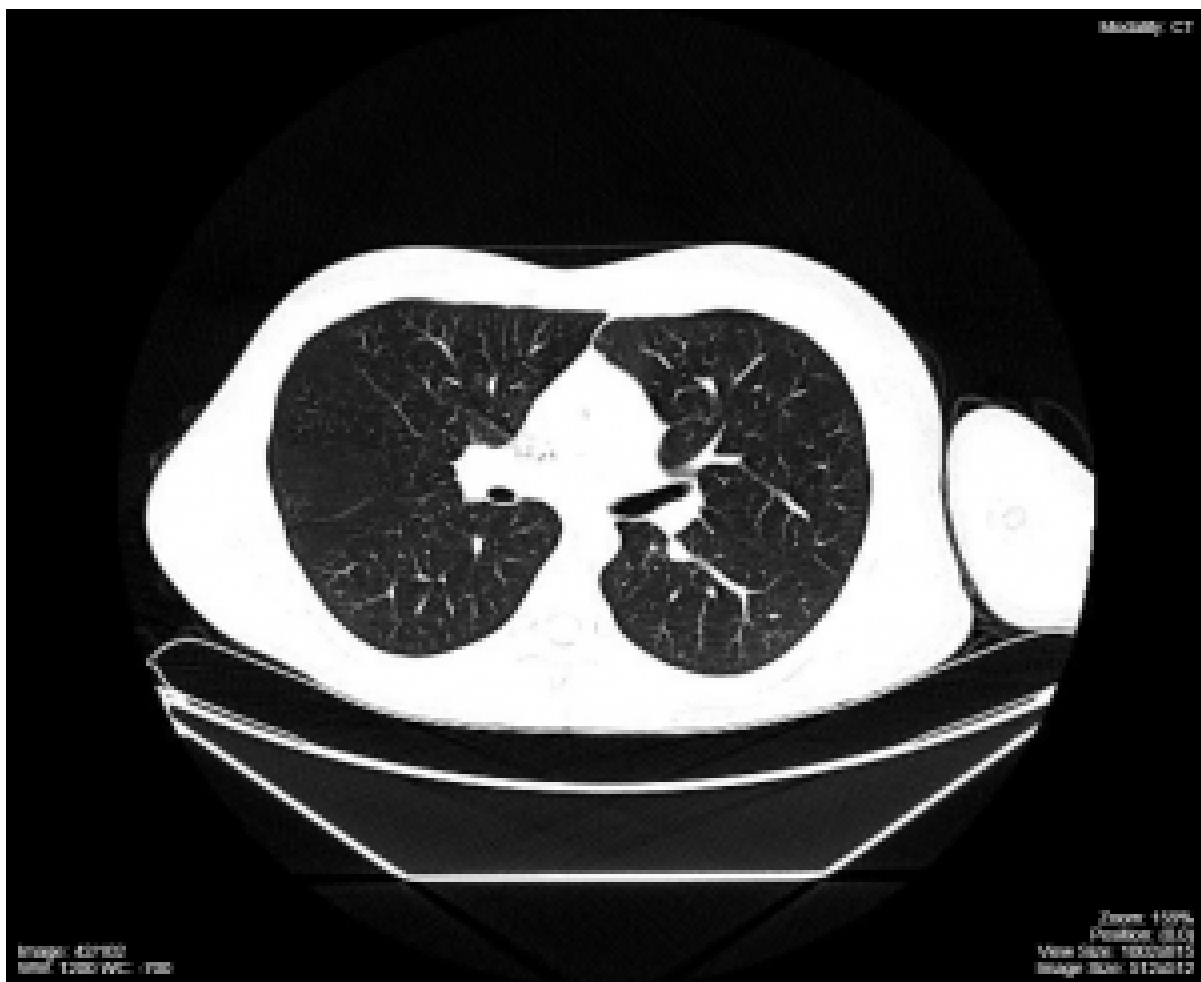

Figure 3.29A CT of the chest on lung level/window

Mediastinum

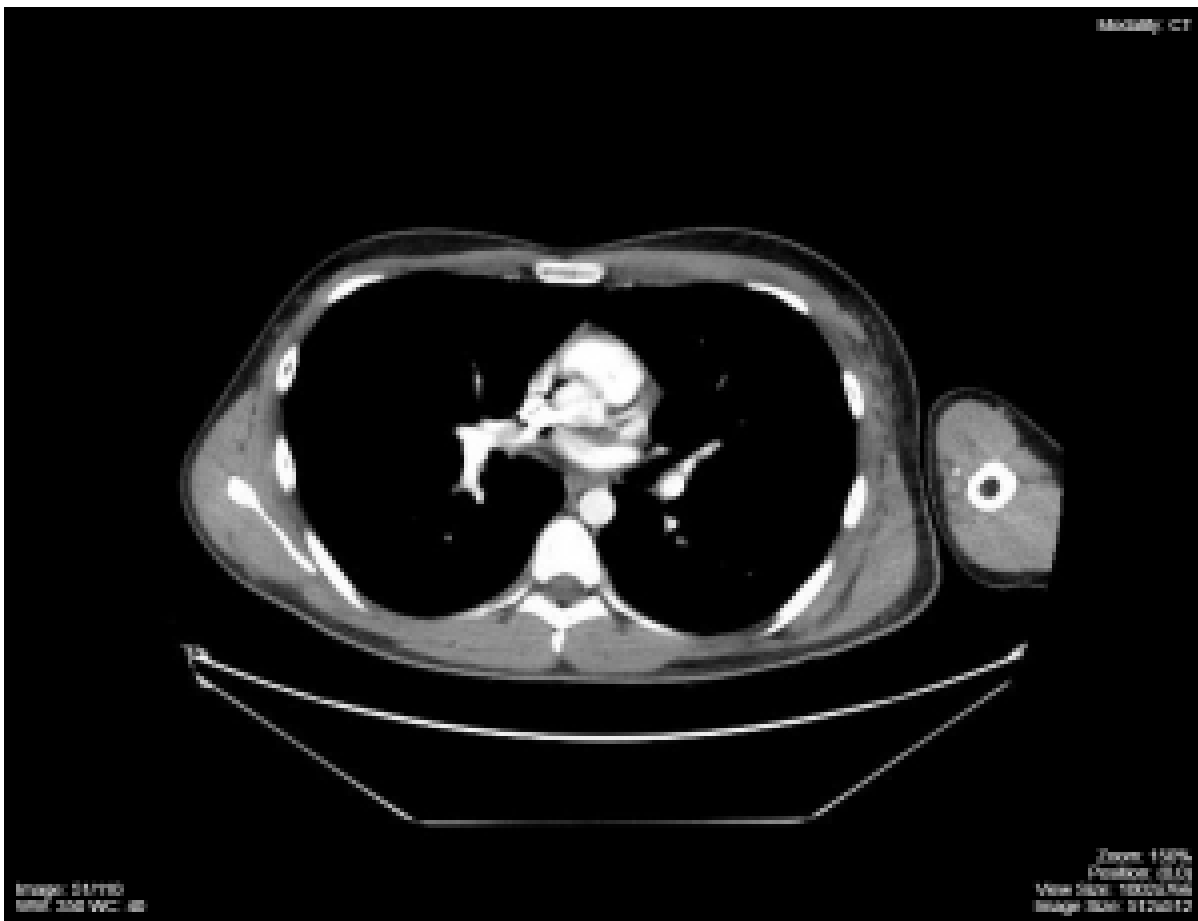

Figure 3.29B CT of the chest on mediastinal level/window

ODIN Link for Figures 3.29A and B: <https://mistr.usask.ca/odin/?caseID=20160216171203513>

Computed Tomographic Angiography

CT has also become highly adapted to imaging arterial and venous anatomy and in some instances has replaced catheter based angiography as the gold standard examination, e.g. pulmonary angiography has been supplanted by CT PE (pulmonary embolism) studies. This is due to the ability of the newer, multi-detector, helical, CT scanners to rapidly cover a large area of patient anatomy due to the size of the detectors. Hence, contrast enhanced CT images can be obtained during a narrow window of time when a particular vascular structure is maximally enhanced with intravenous contrast agent. The image acquisition can be timed to maximally enhance arteries or veins. *Figure 3.30* demonstrates optimal timing of the CT images for enhancement of the pulmonary arteries.

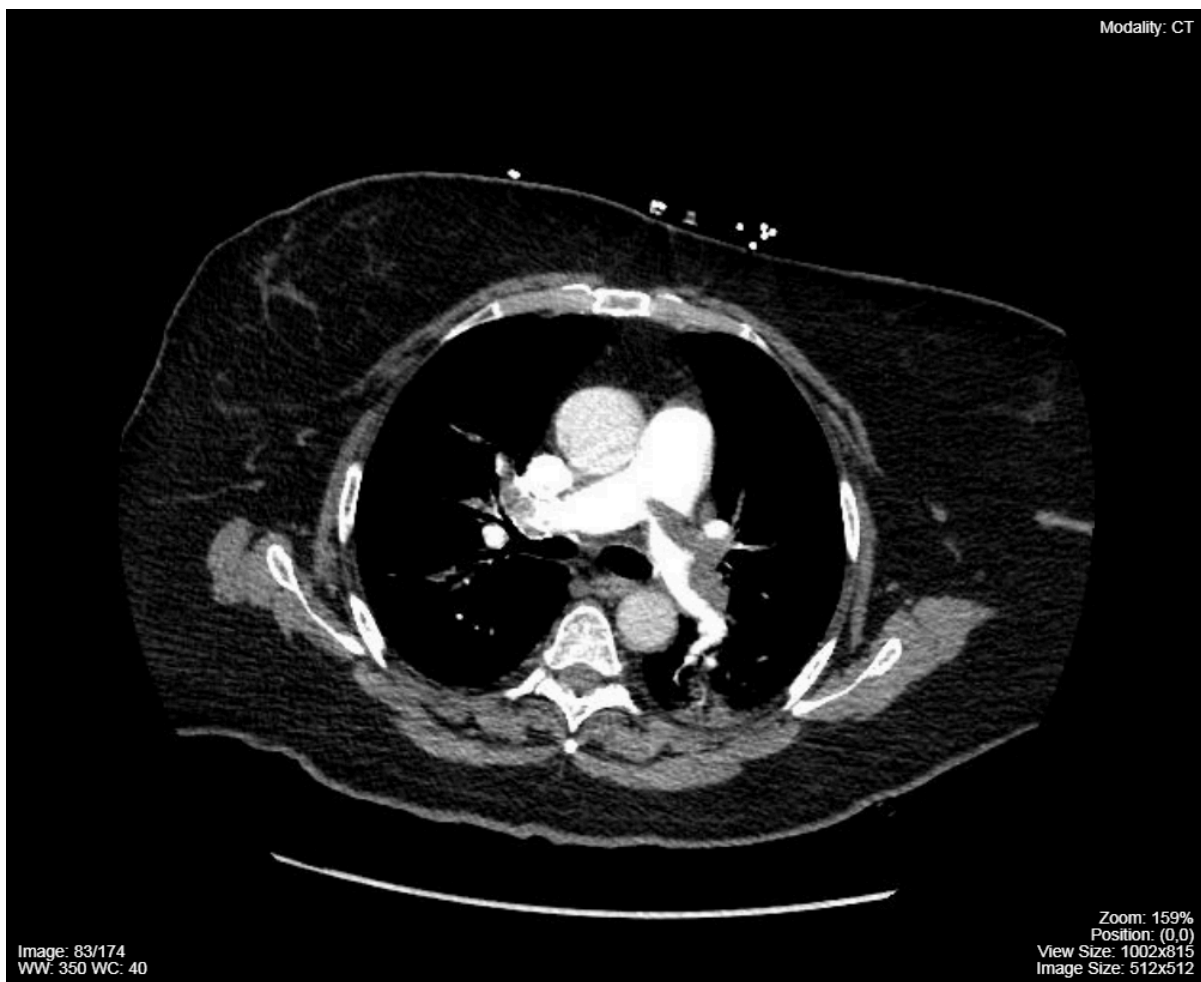

Figure 3.30 CT PE image maximizing the injected contrast in the pulmonary arteries

ODIN Link for CT PE, Figure 3.30: <https://mistr.usask.ca/odin/?caseID=20160216182645272>

Computed Tomography:

- Takes images in an axial format, and re-formats them into sagittal and coronal images
- Uses the Hounsfield Unit scale (HU) to assign densities to tissues
- Hounsfield Units range from -1000 (*air*) to +1000 (*metal*) with 0 assigned to water

Image Appearance:

- 6 standard level/window settings for assessing various structures, however any user specified level/window setting can be used
- Abdomen, Bone, Brain, Liver, Lungs, Pulmonary Embolism (PE)
- Level refers to the Hounsfield Unit the image is centered on
- Window refers to the range of Hounsfield Units displayed on either side of the Level

- When viewing CT images, the patient's right is on the left side of the display monitor

Radiation Exposure:

- Reduced by setting the CT x-ray dose to as low as feasible to minimize the total radiation exposure
- The CT Technologist can minimize the total volume of tissue irradiated by setting the margins of the imaged anatomy to as small a region as feasible
- One set of images can be reformatted in different anatomic planes and adjusted (level/window) to optimally view the anatomy without additional x-ray exposure

Computed Tomography Angiography (CTA):

- Useful for the assessment arterial imaging such as, the pulmonary arteries for Pulmonary Embolism (PE), intra-cranial arteries for aneurysms, and cervical arteries for narrowing, occlusion, or dissection, etc.
- Uses contrast that is injected into the venous system

Attributions

Fig 3.21 Helical CT Scanner by Dr. Brent Burbridge MD, FRCPC, University Medical Imaging Consultants, College of Medicine, University of Saskatchewan is used under a [CC-BY-NC-SA 4.0](#) license.

Fig 3.22 The plane of imaging related to the cantho-meatal line by Dr. Brent Burbridge MD, FRCPC, University Medical Imaging Consultants, College of Medicine, University of Saskatchewan is used under a [CC-BY-NC-SA 4.0](#) license.

Fig 3.23 Images of CT with HU measurements by Dr. Brent Burbridge MD, FRCPC, University Medical Imaging Consultants, College of Medicine, University of Saskatchewan is used under a [CC-BY-NC-SA 4.0](#) license.

Fig 3.24 CT Images with different level and window settings by Dr. Brent Burbridge MD, FRCPC, University Medical Imaging Consultants, College of Medicine, University of Saskatchewan is used under a [CC-BY-NC-SA 4.0](#) license.

Fig 3.25A Brain Level and Window by Dr. Brent Burbridge MD, FRCPC, University Medical Imaging Consultants, College of Medicine, University of Saskatchewan is used under a [CC-BY-NC-SA 4.0](#) license.

Fig 3.25B Bone Level and Window by Dr. Brent Burbridge MD, FRCPC, University Medical Imaging Consultants, College of Medicine, University of Saskatchewan is used under a [CC-BY-NC-SA 4.0](#) license.

Fig 3.26A Head CT visible on brain level and window. Bone not well seen by Dr. Brent Burbridge MD, FRCPC,

University Medical Imaging Consultants, College of Medicine, University of Saskatchewan is used under a [CC-BY-NC-SA 4.0](#) license.

Fig 3.26B Head CT on bone level and window. Brain not well seen by Dr. Brent Burbridge MD, FRCPC, University Medical Imaging Consultants, College of Medicine, University of Saskatchewan is used under a [CC-BY-NC-SA 4.0](#) license.

Fig 3.27 Standard viewing orientation for an axial CT image by Dr. Brent Burbridge MD, FRCPC, University Medical Imaging Consultants, College of Medicine, University of Saskatchewan is used under a [CC-BY-NC-SA 4.0](#) license.

Fig 3.28A CT image displayed in axial orientation from one radiation exposure event by Dr. Brent Burbridge MD, FRCPC, University Medical Imaging Consultants, College of Medicine, University of Saskatchewan is used under a [CC-BY-NC-SA 4.0](#) license.

Fig 3.28B CT image displayed in sagittal orientation from one radiation exposure event by Dr. Brent Burbridge MD, FRCPC, University Medical Imaging Consultants, College of Medicine, University of Saskatchewan is used under a [CC-BY-NC-SA 4.0](#) license.

Fig 3.28C CT image displayed in coronal orientation from one radiation exposure event by Dr. Brent Burbridge MD, FRCPC, University Medical Imaging Consultants, College of Medicine, University of Saskatchewan is used under a [CC-BY-NC-SA 4.0](#) license.

Fig 3.29A CT of the chest on lung level/window by Dr. Brent Burbridge MD, FRCPC, University Medical Imaging Consultants, College of Medicine, University of Saskatchewan is used under a [CC-BY-NC-SA 4.0](#) license.

Fig 3.29B CT of the chest on mediastinal level/window by Dr. Brent Burbridge MD, FRCPC, University Medical Imaging Consultants, College of Medicine, University of Saskatchewan is used under a [CC-BY-NC-SA 4.0](#) license.

Fig 3.30 CT PE image maximizing the injected contrast in the pulmonary arteries by Dr. Brent Burbridge MD, FRCPC, University Medical Imaging Consultants, College of Medicine, University of Saskatchewan is used under a [CC-BY-NC-SA 4.0](#) license.

Ultrasound (US)

This modality relies upon high frequency, inaudible, sound arising from a piezoelectric crystal, in a hand-held transducer, for the creation of images. Hence the nomenclature of “ultrasound”. The ultrasound transducer emits sound roughly 5% of the time and then listens for the returning echoes 95% of the time. Ultrasound transmission is facilitated by acoustic gel that is applied to the probe and to the patient’s skin to minimize the air-gap.

The returning sound is altered in wavelength and intensity and arrives back to the probe after being reflected from tissues of different depths beneath the skin. Based upon the absorptive or reflective properties of the anatomy being assessed, the ultrasound machine assigns a pixel brightness to that particular tissue. A complex, computer driven, algorithm determines the characteristics of the returning echoes and displays the sound on a gray scale. No echoes returning to the transducer is represented as black, while areas that return a larger proportion of the sound to the transducer are white. The image displayed on the ultrasound machine monitor is a real-time, constantly refreshing, image that actively displays the changing location of the ultrasound probe. Images stored for future review in PACS are screen captures from the real-time imaging feed and are stored to preserve images that become part of the patients’ medical record. These images are called B-mode. (Figure 3.31)

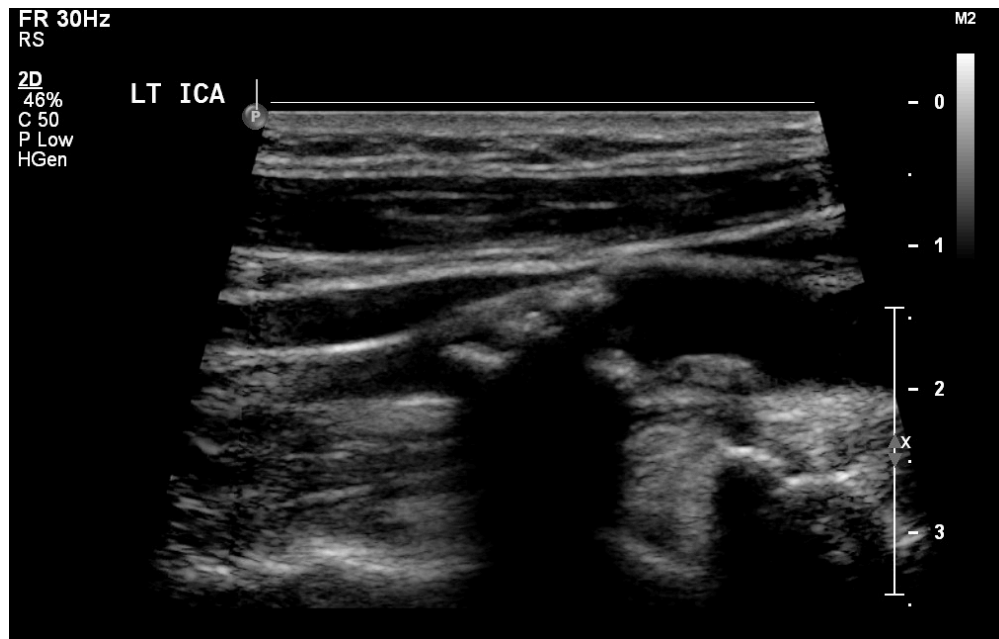


Figure 3.31 B-Mode Ultrasound of the Carotid bulb with atherosclerotic plaque

ODIN Link for Carotid Ultrasound image, Figure3.31: <https://mistr.usask.ca/odin/?caseID=20170717232359948>

The patient lies in anatomic position for the most part but may be asked to roll to different positions to determine if entities such as calculi or fluid move with change in patient position. Ultrasound is the most difficult modality to understand from an anatomic standpoint as ultrasound images are not acquired with a standardized position of the ultrasound transducer in reference to anatomic position, or in reference to the patient's anatomy. Also, as the patient moves during the ultrasound examination this introduces further variability in the appearance of the acquired images that is not a factor for other imaging modalities. Figure 3.32A depicts standard fixed location ultrasound machine, while Figure 3.32B demonstrates a smaller, mobile unit.

Static Ultrasound Machine

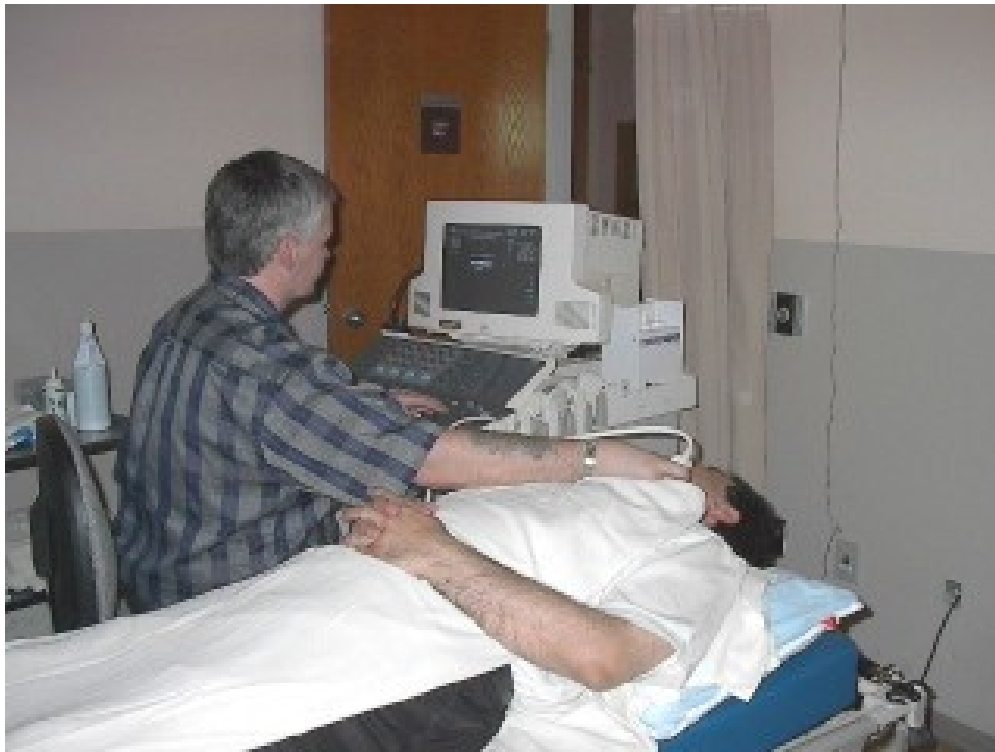

Figure 3.32A Ultrasound Machine

Mobile Ultrasound

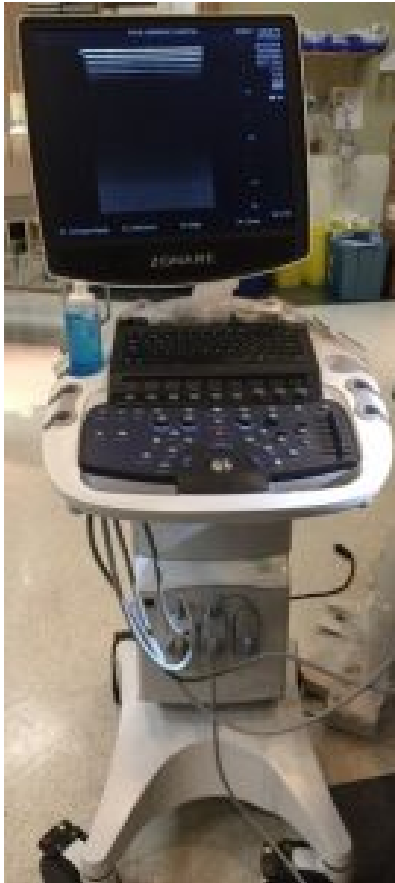

Figure 3.32B Mobile Ultrasound Machine

Ultrasound images are described in terms of their relative echogenicity. Water is the least complex structure seen on ultrasound and it returns very few echoes back to the transducer, therefore, it has very low echogenicity (anechoic) and is seen as a black structure on the image. An example, of a low echogenicity anatomic structure is a renal cyst or bile in the gallbladder. More complex anatomy results in more sound being echoed back to the ultrasound transducer for conversion to image pixels and is described as being echogenic (brighter) on ultrasound. The liver is an echogenic anatomic structure and is usually more echogenic than the renal cortex. See Figure 3.33.

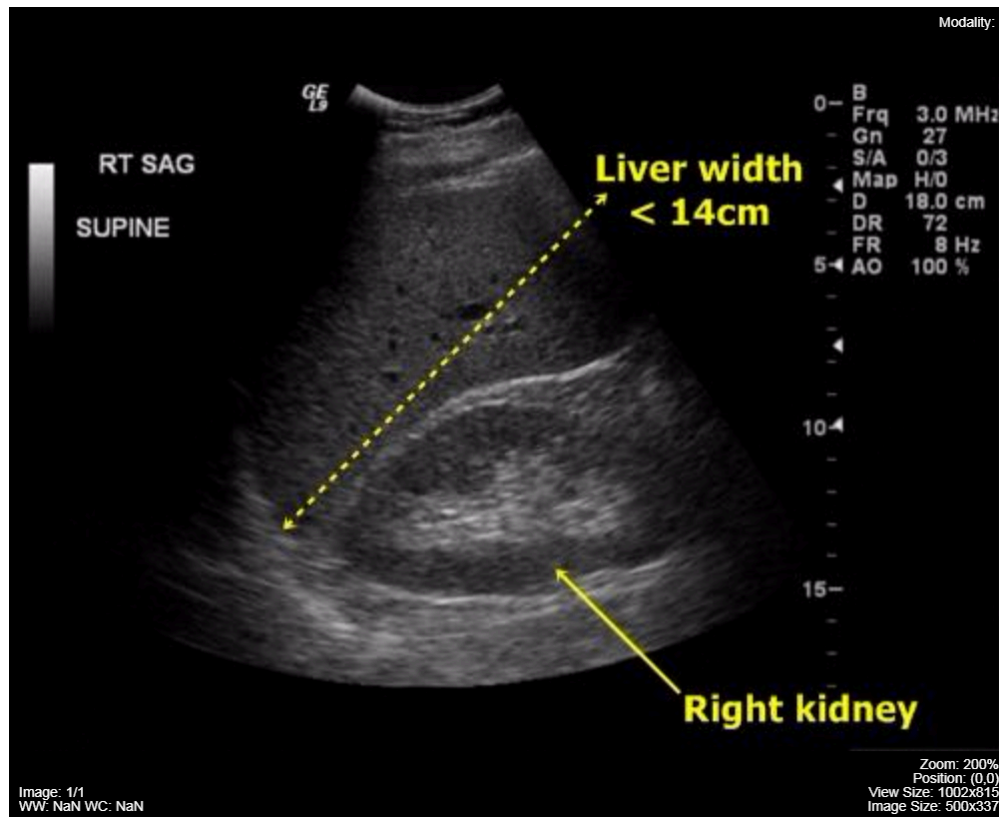


Figure 3.33 Ultrasound image of the normal liver and kidney. The echogenicity of the liver is greater than the echogenicity of the adjacent renal cortex

ODIN Link for Normal Liver image, Figure 3.33: <https://mistr.usask.ca/odin/?caseID=20170714161249997>

Note the much lower echogenicity of the normal gallbladder contents in Figure 3.34:

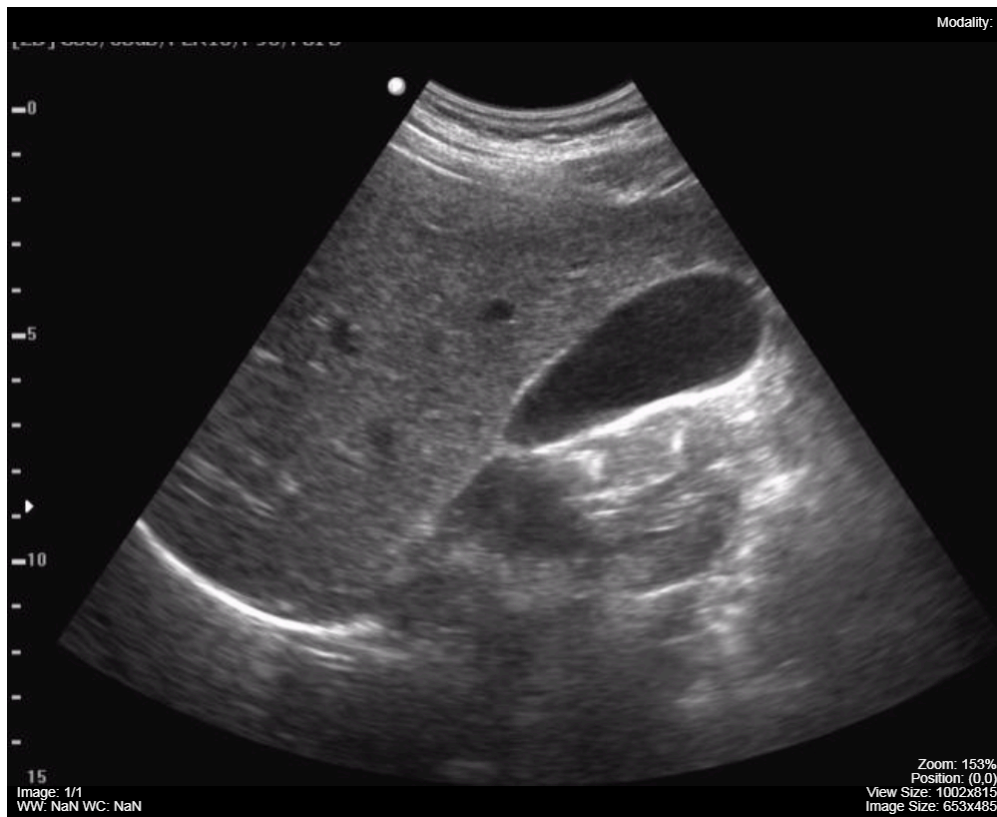


Figure 3.34 Gallbladder

ODIN Link for Gallbladder image, Figure 3.34: <https://mistr.usask.ca/odin/?caseID=20170714161445517>

The echogenicity of an organ can change dependent upon the infiltration of tissues with lipid. Hepatosteatorosis (fatty liver) is an abnormal increase in lipid within the hepatocytes of the liver. It is often associated with an enlarged liver. Figure 3.35 demonstrates an image of a normal liver and then an enlarged liver (20.9 cm cranial-caudal, normal < 15 cm) with a very increased liver echogenicity and absorption of the ultrasound beam leading to loss of anatomic detail in the deep liver.

Normal

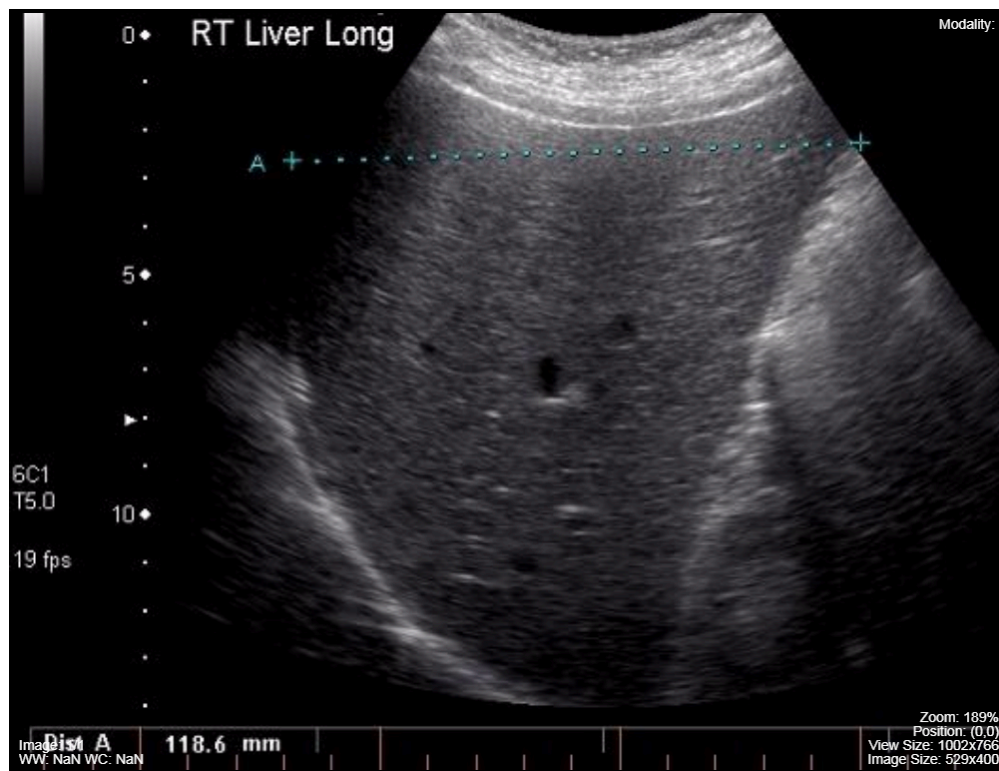


Figure 3.35A Normal Liver Ultrasound

Hepatomegaly and Hepatosteatosi

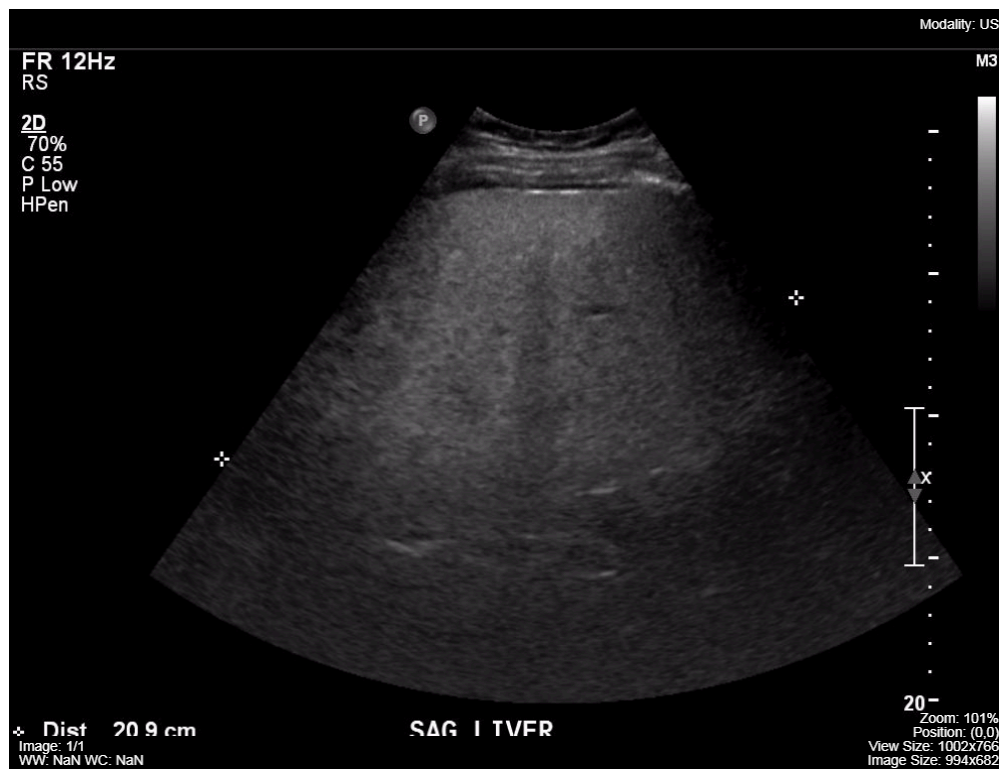


Figure 3.35B Hepatomegaly and hepatic steatosis on Ultrasound

ODIN Link for Figures 3.35A and B: <https://mistr.usask.ca/odin/?caseID=20170714161553485>

Ultrasound:

- Anatomy appears black when sound waves are not reflected back to the ultrasound transducer
- Anatomy appears white when sound waves are reflected back to the ultrasound transducer
- Anatomy is described by its relative echogenicity i.e. liver is more echogenic than normal bile and the renal cortex is less echogenic than liver parenchyma

Terminology

Echoic: Sound is reflected back from the tissue to be measured by the ultrasound machine.

Anechoic: Sound is not reflected back to the ultrasound probe from this tissue.

Hypoechoic: The sound reflected back to the ultrasound probe is decreased in comparison to some other tissue in the anatomy being assessed i.e. the bile in the gallbladder is hypoechoic in comparison to the liver.

Hyperechoic: The sound reflected back is increased in comparison to some other tissue in the anatomy being assessed i.e. the liver is hyperechoic compared to the bile in the gallbladder.

Doppler Ultrasound

Ultrasound can analyze flowing fluids and determine if there is a frequency shift over the length of a structure using the Doppler principle of the changing frequency of sound waves as they travel over a distance (like the ambulance siren as it approaches and recedes from the detector, the ear). Static B-mode images associated with Doppler assessment is called *Duplex Doppler*. Colour can be applied to the imaging to represent the direction of blood flow in relation to the ultrasound probe. By convention blood flowing toward the transducer is an orange-red colour and flow away from the transducer is a blue color. (Figures 3.36) Colour Doppler images are often displayed with a spectral pattern of flowing blood on the same image, representing changes in blood velocity with systole and diastole. (Figures 3.37)

Colour Doppler

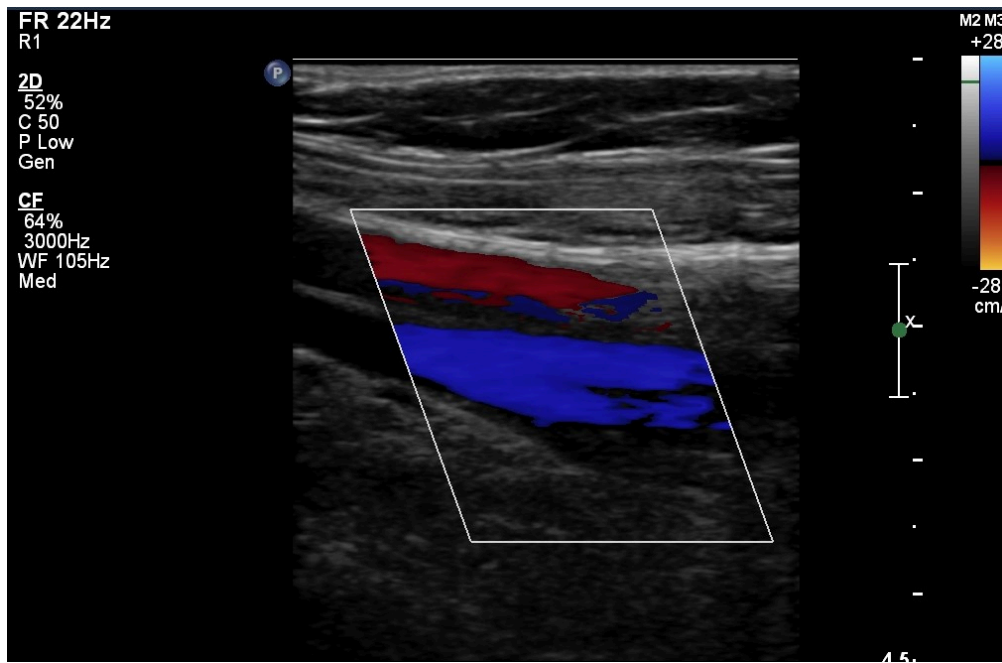


Figure 3.36 Colour Doppler, of the neck

Colour and Spectral Doppler

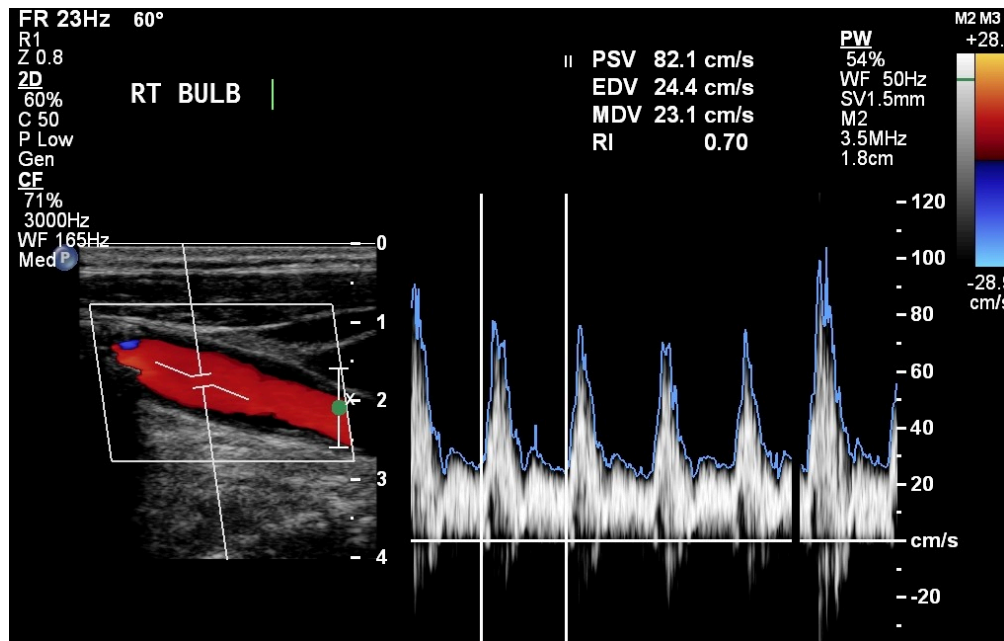


Figure 3.37 Colour Doppler of the neck with Spectral Display

While assessing the vessels with Doppler the ultrasound system also displays an absolute measurement of the velocity of the moving fluid measured in cm/second. Velocities in narrowed tubular structures (blood vessels) are predictably increased based upon the Poiseuille's law. The most common clinical applications of these physical phenomena are the detection of carotid artery stenosis in the region of the carotid bulb and for the detection of venous thrombosis.

Poiseuille's Law is: $Q = \frac{\pi Pr^4}{8nL}$

Q	Flow Rate	r	Radius
Π	Constant (Phi)	n	Viscosity of the fluid
P	Pressure	L	Length of the tubular structure

Figure 3.38 demonstrates a carotid Doppler ultrasound with abnormally high velocities associated with an internal carotid artery stenosis.

Internal Carotid

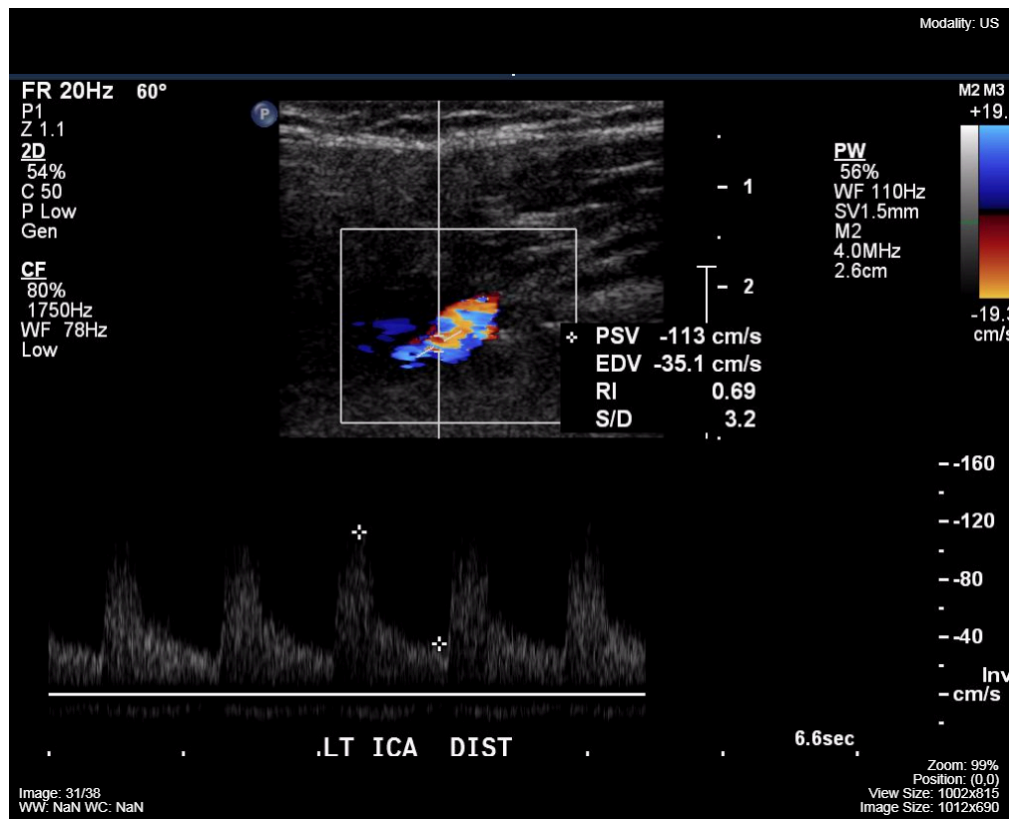


Figure 3.38A Carotid Doppler Ultrasound

Carotid Bulb

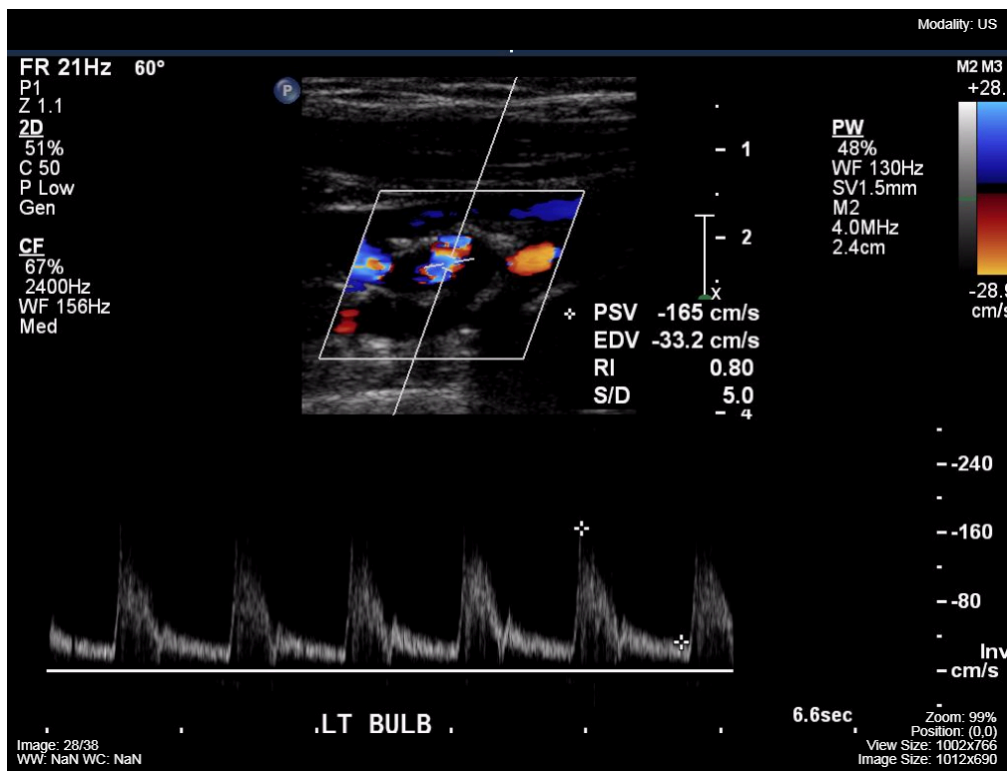


Figure 3.38B Carotid Doppler Ultrasound

Vertebral

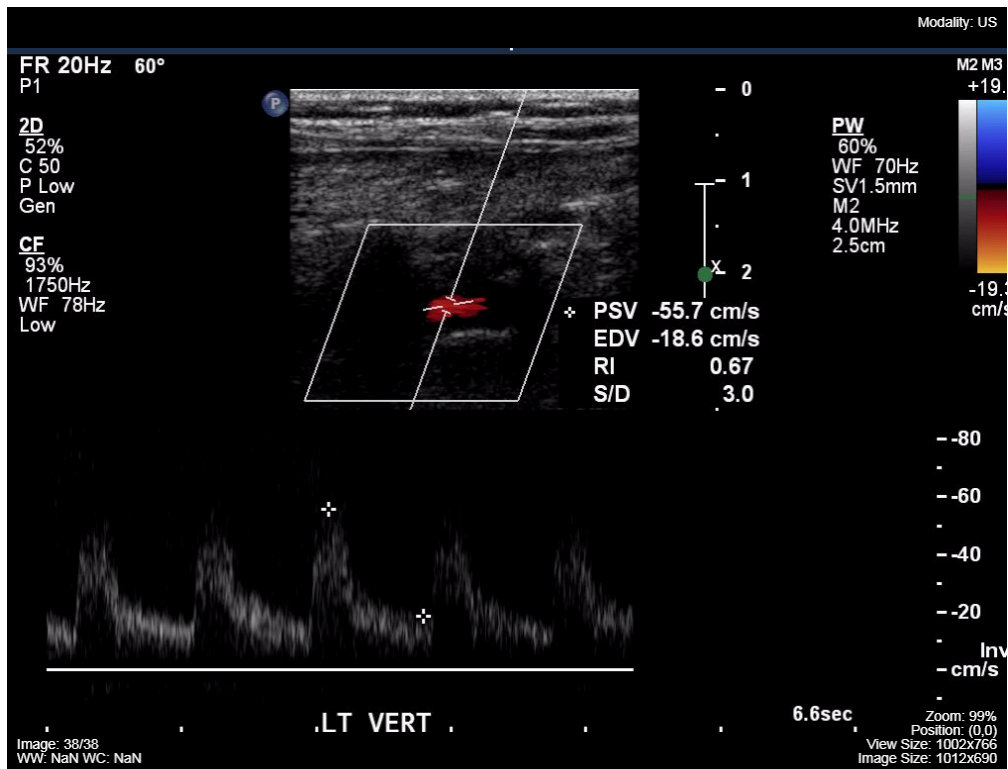


Figure 3.38C Carotid Doppler Ultrasound

ODIN Link for Figures 3.38A – C: <https://mistr.usask.ca/odin/?caseID=20160219111444458>

Doppler Ultrasound:

- Blue on Doppler = fluid moving away from probe
- Red on Doppler = fluid moving towards the probe

Blue Away, Red Towards – BART

Ultrasound Probes

Different anatomic structures can be better visualized if the ultrasound transducer is designed to fit the anatomy of the area i.e. convex (curved) transducers are optimal for abdominal and obstetric imaging, linear probes are best adapted to vascular and small superficial structures (thyroid), while the prostate gland is best visualized with a long, wand-shaped ultrasound transducer that can reach the gland via the rectum (endo-cavitary probe). This same physical configuration of the ultrasound probe can be used for intra-vaginal image acquisition for the assessment of female pelvic anatomy (uterus, endometrium, and ovaries). *Figure 3.39* contains three common probes, a linear 20 MHz, a curved array 4 MHz and a larger curved array 6 MHz.



Figure 3.39 Linear probe and two curved array probes

A feature of ultrasound probes that effects image quality is the correlation of the frequency of sound emitted with

the depth of tissue interrogated. Higher frequency probes have a limited depth of field but provide better image resolution of the near field anatomy. Lower frequency probes are best for deep tissue imaging. Hence, a thyroid ultrasound may be performed with a 20 MHz probe while deep abdomen ultrasound probes are in the 4 – 5 MHz range. Maximal tissue depth for the low frequency probes is approximately 20 cm and these probes do not provide imaging details of the subcutaneous tissues.

The depth of the tissue being imaged from the skin surface limits the ability of ultrasound to view patient anatomy i.e. it would be very unusual to be able to see all of the structures of the abdomen from front to back due to the depth limitation of ultrasound of approximately 15 – 20 cm. Two physical entities that negatively impact ultrasound image quality are the presence of gas in the area (lung, intestinal gas) and bone.

Ultrasound Probes:

- Higher frequency better image resolutions of near field
- Higher frequency has limited depth
- Lower frequency better deep tissue imaging

Ultrasound Image Quality

- **Depth of tissue:** deeper depth associated with declining image quality
- **Presence of Gas:** more gas associated with poorer quality
- **Bone:** high scattering, causes a shadow on imaging

Attributions

Fig 3.31 B-Mode Ultrasound of the Carotid bulb with atherosclerotic plaque by Dr. Brent Burbridge MD, FRCPC, University Medical Imaging Consultants, College of Medicine, University of Saskatchewan is used under a [CC-BY-NC-SA 4.0](#) license.

Fig 3.32A Ultrasound Machine by Dr. Brent Burbridge MD, FRCPC, University Medical Imaging Consultants, College of Medicine, University of Saskatchewan is used under a [CC-BY-NC-SA 4.0](#) license.

Fig 3.32B Mobile Ultrasound Machine by Dr. Brent Burbridge MD, FRCPC, University Medical Imaging Consultants, College of Medicine, University of Saskatchewan is used under a [CC-BY-NC-SA 4.0](#) license.

Fig 3.33 Ultrasound image of the normal liver and kidney. The echogenicity of the liver is greater than the echogenicity of the adjacent renal cortex by Dr. Brent Burbridge MD, FRCPC, University Medical Imaging Consultants, College of Medicine, University of Saskatchewan is used under a [CC-BY-NC-SA 4.0](#) license.

Fig 3.34 Gallbladder by Dr. Brent Burbridge MD, FRCPC, University Medical Imaging Consultants, College of Medicine, University of Saskatchewan is used under a [CC-BY-NC-SA 4.0](#) license.

Fig 3.35A Normal Liver Ultrasound by Dr. Brent Burbridge MD, FRCPC, University Medical Imaging Consultants, College of Medicine, University of Saskatchewan is used under a [CC-BY-NC-SA 4.0](#) license.

Fig 3.35B Hepatomegaly and hepatic steatosis on Ultrasound by Dr. Brent Burbridge MD, FRCPC, University Medical Imaging Consultants, College of Medicine, University of Saskatchewan is used under a [CC-BY-NC-SA 4.0](#) license.

Fig 3.36 Colour Doppler, of the neck by Dr. Brent Burbridge MD, FRCPC, University Medical Imaging Consultants, College of Medicine, University of Saskatchewan is used under a [CC-BY-NC-SA 4.0](#) license.

Fig 3.37 Colour Doppler of the neck with Spectral Display by Dr. Brent Burbridge MD, FRCPC, University Medical Imaging Consultants, College of Medicine, University of Saskatchewan is used under a [CC-BY-NC-SA 4.0](#) license.

Fig 3.38A Internal Carotid Doppler Ultrasound Dr. Brent Burbridge MD, FRCPC, University Medical Imaging Consultants, College of Medicine, University of Saskatchewan is used under a [CC-BY-NC-SA 4.0](#) license.

Fig 3.38B Carotid Bulb Doppler Ultrasound by Dr. Brent Burbridge MD, FRCPC, University Medical Imaging Consultants, College of Medicine, University of Saskatchewan is used under a [CC-BY-NC-SA 4.0](#) license.

Fig 3.38C Vertebral Doppler Ultrasound by Dr. Brent Burbridge MD, FRCPC, University Medical Imaging Consultants, College of Medicine, University of Saskatchewan is used under a [CC-BY-NC-SA 4.0](#) license.

Fig 3.39 Linear probe and two curved array probes by Dr. Brent Burbridge MD, FRCPC, University Medical Imaging Consultants, College of Medicine, University of Saskatchewan is used under a [CC-BY-NC-SA 4.0](#) license.

Magnetic Resonance Imaging (MRI)

Magnetic resonance images (MRI) are created by utilizing a high strength magnetic field and radio waves. All of the protons in the body are aligned in the cranial/caudal axis by the magnetic field of the MR. When a radio wave is broadcast into the body this perturbs the protons. When the radio wave ceases the protons snap back to align with the magnetic field. The protons liberate energy when they snap back into alignment with the magnetic field. This liberated energy is detected by sensor coils surrounding specific regions of the patient's anatomy i.e. knee coils, head coils, etc. Through a process of complex, computer based, mathematical calculations the emitted energy is converted into pixels for digital image creation, display, and review. An MR machine is seen in *Figure 3.40*.

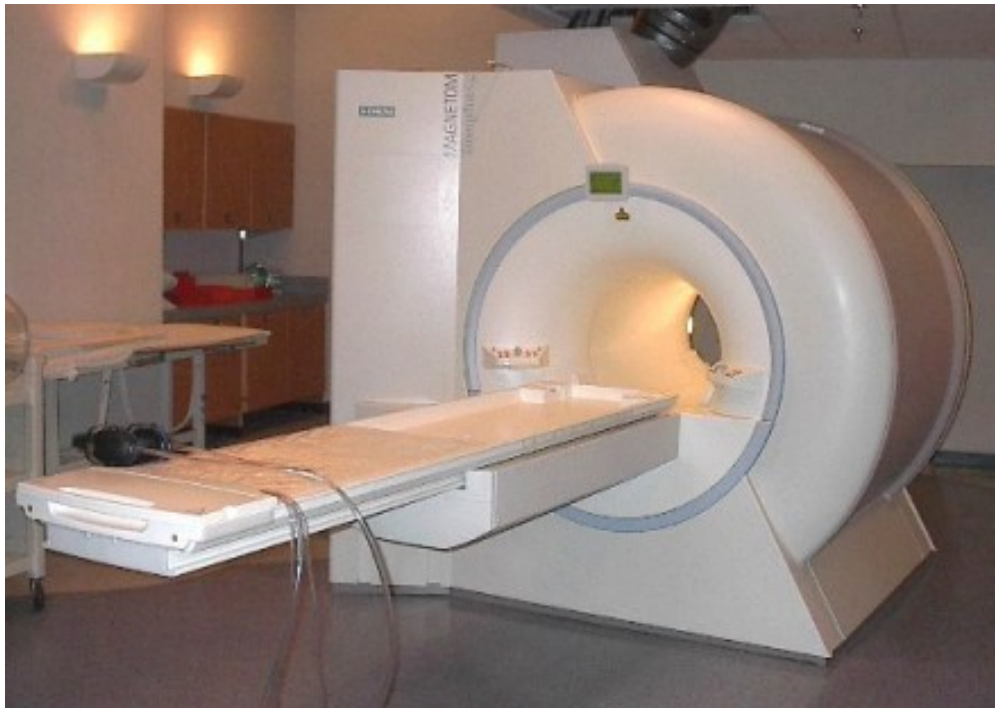


Figure 3.40 Magnetic Resonance Imaging Machine

Image Appearance

The appearance of different tissue on MR images is described as displaying *greater, or lesser, signal in compar-*

ison the other anatomy in the region. The signal in question is the energy that the perturbed protons liberated when they fall back into alignment with the magnetic field. The signal intensity of the tissue in question changes based upon the image acquisition parameters set by the MR Technologist, under the direction of a supervising Radiologist. The parameters set result in the acquisition of a set of images called an MR imaging sequence. On one sequence cerebrospinal fluid will appear as black pixels (T1 sequence) while on another sequence it is white pixels (T2 sequence). This difference in tissue appearance can be exploited to determine if pathology is present.

MR Image Appearance:

- T1 Sequence – Cerebrospinal fluid appear as black
- T2 Sequence – Cerebrospinal fluid appears as white

Image Acquisition

Magnetic Resonance Imaging (MRI or MR), has the physical appearance of a Computed Tomography machine, i.e. it has a long tube with a tabletop that transports the patient into the centre of the tube for imaging. Patients lie on their back (supine) in the MR machine just like CT. The patient does not need to move or be re-positioned in the scanner to improve, or alter, the appearance of the patient's anatomy. The patient does need to be prone for breast imaging, but that is the only examination that requires altered patient positioning.

The body region of interest for MR is surrounded by a coil that creates the radio waves and captures the radio waves used to create the images. There are different coils for different anatomic regions i.e. knee, head, breast, etc.

There are MR machines that do not have a tube or bore configuration called open magnets. They are designed to image children, obese patients and claustrophobic patients. These units are less frequently deployed in clinical practice.

MRI can acquire images in any plane of anatomic orientation, but these must be acquired as separate imaging sequences with unique technical parameters set for each sequence. Therefore, the more MR sequences planned, the longer the examination will take. This is unlike CT where the creation of images in alternative anatomic planes is performed by software manipulation of the pixels after image acquisition.

Safety

MRI is for the most part a very safe imaging modality. Some examinations may require intravenous contrast agents (Gadolinium based) and patients with known hyper-sensitivity to these agents should not have MR with contrast. Gadolinium based contrast agents may also cause renal injury in some patients who have predisposing

poor renal function. One should consult with the imaging centre prior to booking a patient with diminished renal function for a contrast enhanced MR.

This imaging modality utilizes very high strength magnetic field to generate images. There are potential hazards related to missile type incidents where ferromagnetic objects are rapidly drawn into the MR magnet. In addition, implanted objects in patients such as cochlear implants, pacemakers and leads, aneurysm clips, and other medical devices may interact with the magnetic field. Patients require rigorous screening by the referring medical team and by the MR team to prevent serious adverse events related to magnetic field related injuries.

Contraindications to MRI:

- Known hyper-sensitivity to Gadolinium based agents
- Renal insufficiency
- Claustrophobia
- Implanted metallic medical device (*cochlear implants, pacemakers and leads, aneurysm clips*)

MRI depicts exquisite anatomic detail and provides the best depiction of anatomy of any of the imaging modalities. As with CT, the appearance of MR images can be modified by the addition of contrast agents.

MRI can also be used to visualize blood moving in vessels and it can also acquire images that analyze the molecular composition of tissue i.e. MR spectroscopy. There are also some MR imaging sequences that can detect differential metabolic activity in tissue and this can be applied to brain activity assessment i.e. functional MR (fMRI).

Hence, MRI has become one of the most important and versatile imaging tools in the Medical Imaging Department. It is particularly valuable for Neurologic and Musculoskeletal imaging. (Figures 3.41, 3.42)

T1 Axial MRI

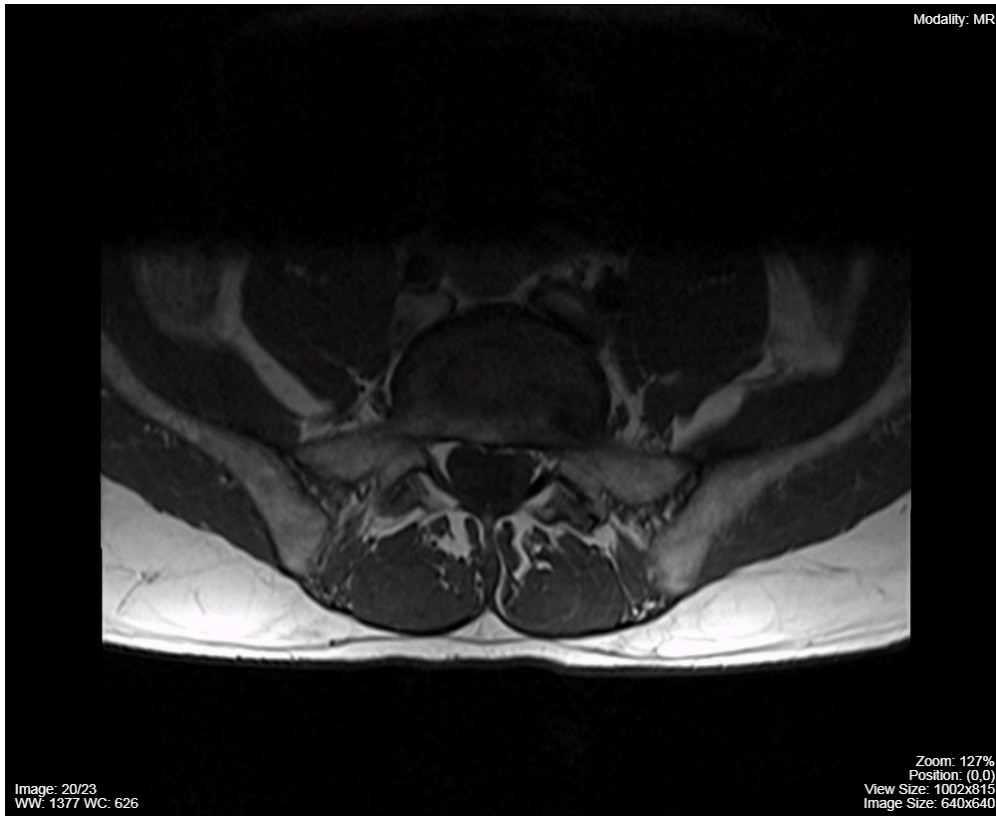


Figure 3.41A Lumbar Spine MRI T1 Sequence – Dark Cerebrospinal Fluid, Axial Plane

T1 Sagittal MRI

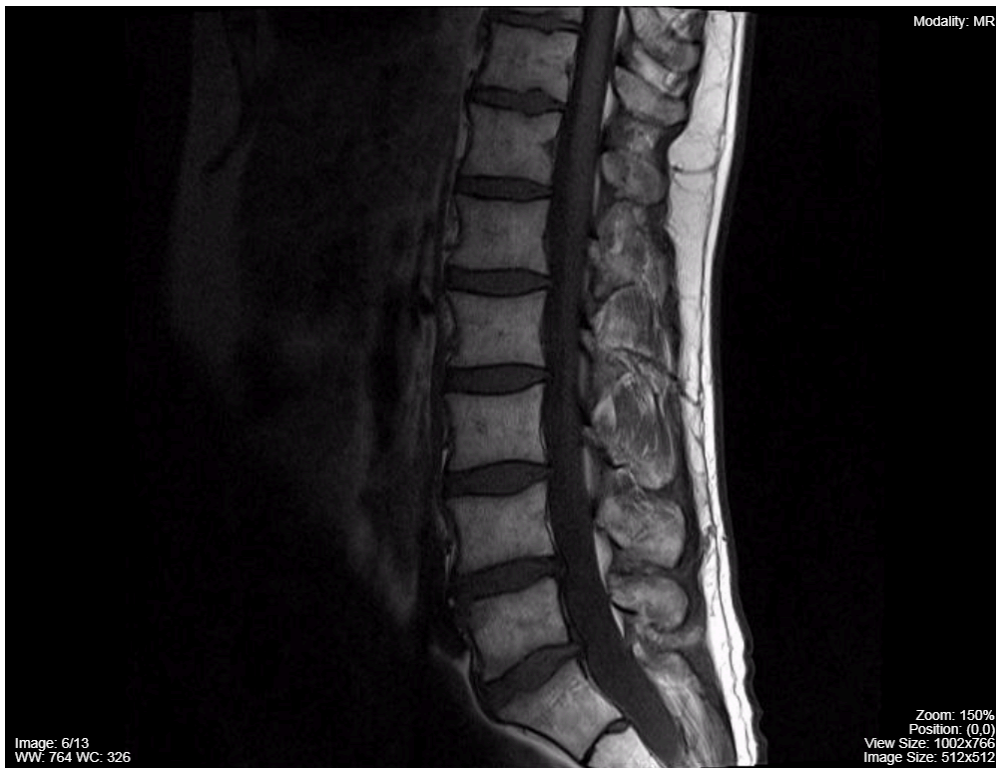

Figure 3.41B Lumbar Spine MRI T1 Sequence – Dark Cerebrospinal Fluid, Sagittal Plane

ODIN Link for Figures 3.41A and B: <https://mistr.usask.ca/odin/?caseID=20150311160705967>

T2 Axial MRI

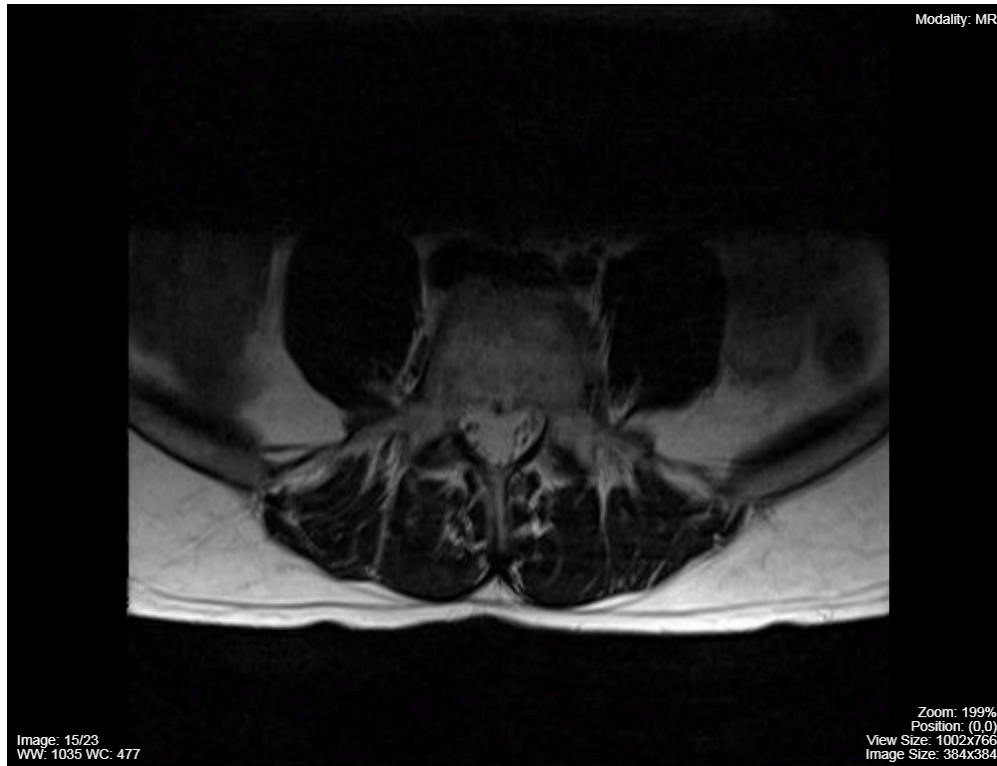

Figure 3.42A Lumbar Spine MRI T2 Sequence – White (bright) Cerebrospinal Fluid, Axial Plane

T2 Sagittal MRI

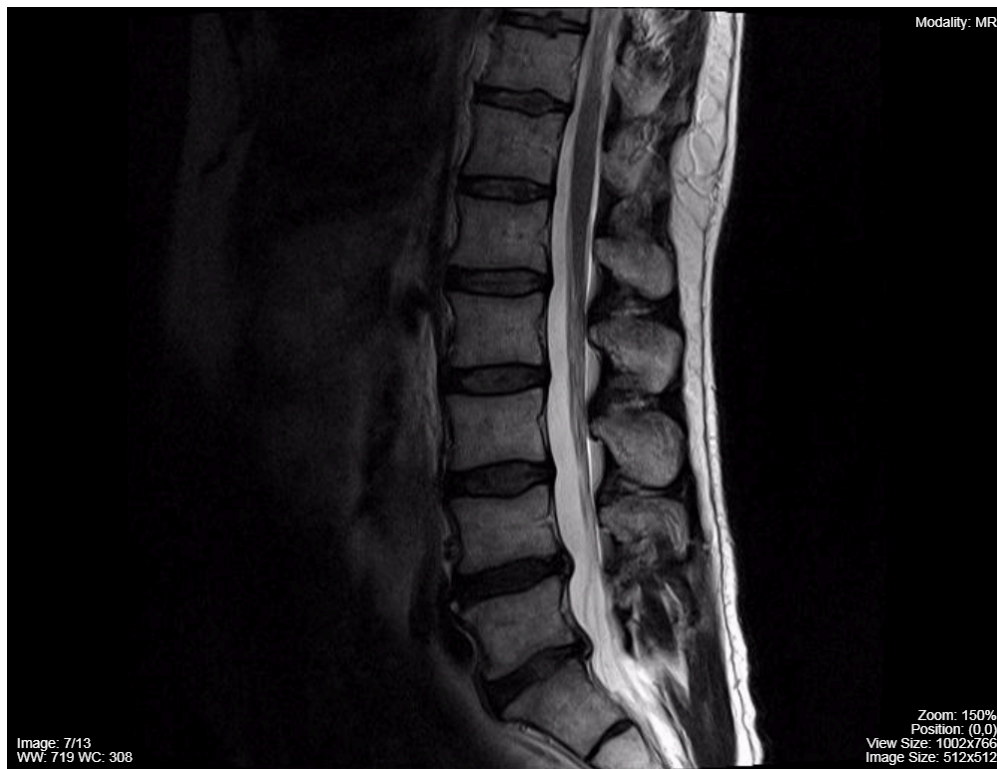

Figure 3.42B Lumbar Spine MRI T2 Sequence – White (bright) Cerebrospinal Fluid, Sagittal Plane

ODIN Link for Figures 3.42A and B: <https://mistr.usask.ca/odin/?caseID=20150311160933373>

Attributions

Fig 3.40 Magnetic Resonance Imaging Machine by Dr. Brent Burbridge MD, FRCPC, University Medical Imaging Consultants, College of Medicine, University of Saskatchewan is used under a [CC-BY-NC-SA 4.0](https://creativecommons.org/licenses/by-nc-sa/4.0/) license.

Fig 3.41A Lumbar Spine MRI T1 Sequence – Dark Cerebrospinal Fluid, Axial Plane by Dr. Brent Burbridge MD, FRCPC, University Medical Imaging Consultants, College of Medicine, University of Saskatchewan is used under a [CC-BY-NC-SA 4.0](https://creativecommons.org/licenses/by-nc-sa/4.0/) license.

Fig 3.41B Lumbar Spine MRI T1 Sequence – Dark Cerebrospinal Fluid, Sagittal Plane by Dr. Brent Burbridge MD, FRCPC, University Medical Imaging Consultants, College of Medicine, University of Saskatchewan is used under a [CC-BY-NC-SA 4.0](https://creativecommons.org/licenses/by-nc-sa/4.0/) license.

Fig 3.42A Lumbar Spine MRI T2 Sequence – White (bright) Cerebrospinal Fluid, Axial Plane by Dr. Brent Burbridge MD, FRCPC, University Medical Imaging Consultants, College of Medicine, University of Saskatchewan is used under a [CC-BY-NC-SA 4.0](https://creativecommons.org/licenses/by-nc-sa/4.0/) license.

Fig 3.42B Lumbar Spine MRI T2 Sequence – White (bright) Cerebrospinal Fluid, Sagittal Plane by Dr. Brent Bur-

bridge MD, FRCPC, University Medical Imaging Consultants, College of Medicine, University of Saskatchewan is used under a [CC-BY-NC-SA 4.0](#) license.

Nuclear Medicine

The patient becomes the source of the radiation required to produce nuclear medicine images after being injected with a radioactive pharmaceutical agent. The pharmacologic agent, bound to the radioactive substance, will concentrate in different organs and tissues based upon the physiology and pharmaco-distribution of the compound administered. The radiation dose administered to the patient is adjusted for the size and weight of the patient. Dosing must be precise to avoid inadvertent radiation poisoning. The pharmaceutical agents used to bind and deliver the radioactive isotope must be sterile and quality control must ensure the molecular structure of the drug is stable and effective.

For example, the radioactive substance for a bone scan, Technetium 99m (^{99m}Tc), is chemically bound to a pharmacologic agent, diphosphonate, and this is injected intravenously. Technetium is a β -emitter and this radioactivity is emitted as the radionuclide decays. The detector system registers the emitted photons and transforms the energy emitted into pixels on an image display. Therefore, a nuclear medicine bone scan depicts radioactivity arising from bone as the pharmacologic agent, diphosphonate, physiologically interacts with living bone. Similarly, a renal Nuclear Medicine scan depicts the kidneys, ureters and bladder as the pharmacologic agent is preferentially metabolized and concentrated in these tissues.

Figure 3.43 depicts a Nuclear Medicine machine. After the patient is injected with the radioactive pharmaceutical they lie on the table in a supine position while the machine detects the emitted radiation.

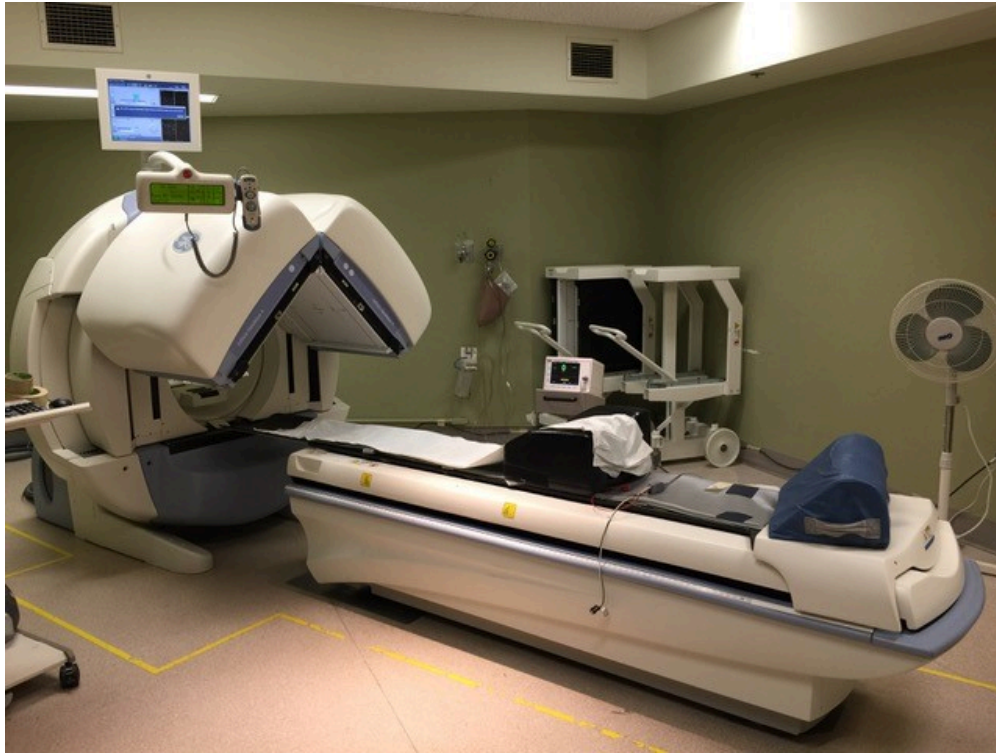

Figure 3.43 Nuclear Medicine Scanner

An example of a normal bone scan for a pediatric patient is provided in *Figure 3.44A*, while the normal bone scan for an adult is in *Figure 3.44B*.

Pediatric Bone Scan

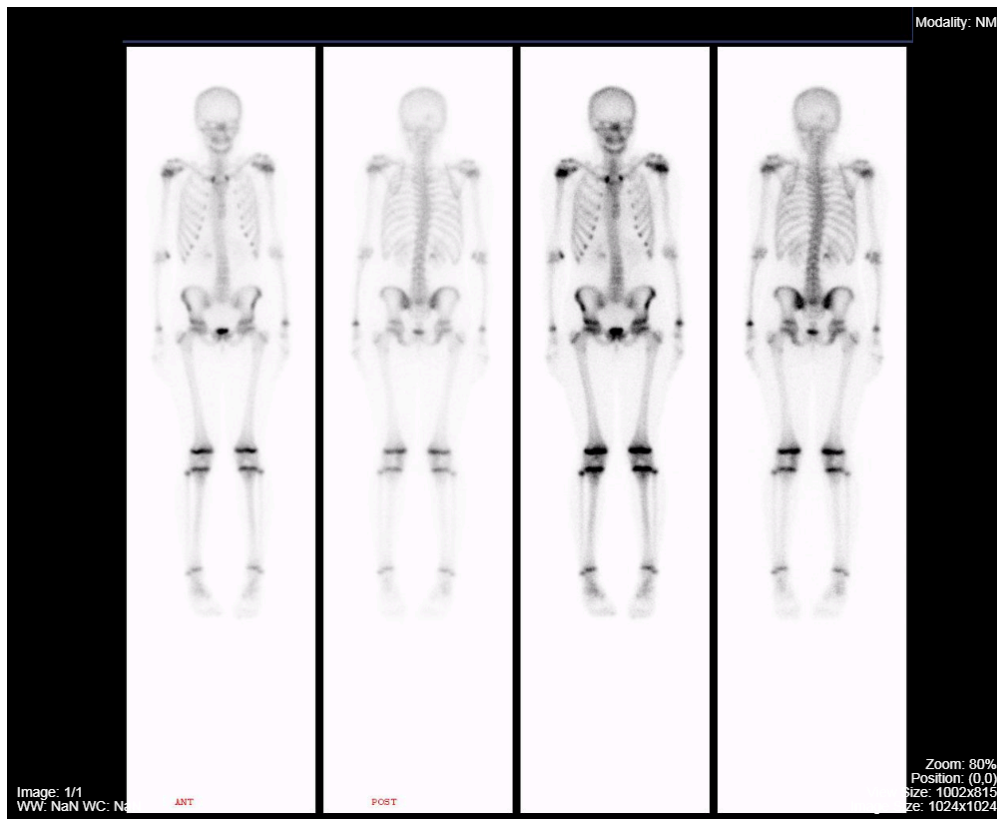


Figure 3.44A Normal, Pediatric, Nuclear Medicine Bone Scan

ODIN Linkd for Figure 3.44A: <https://mistr.usask.ca/odin/?caseID=20150311160158082>

Normal Adult Bone Scan

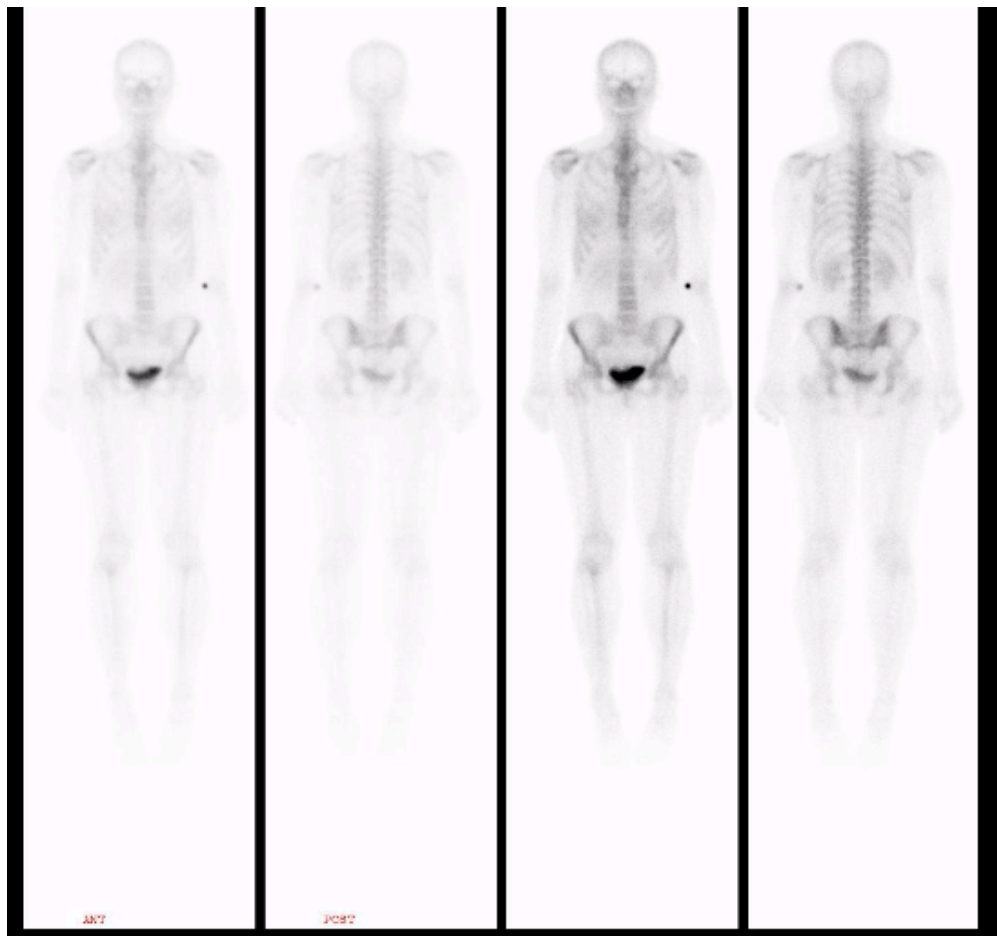


Figure 3.44B Normal, Adult, Nuclear Medicine Bone Scan

ODIN Link for Figure 3.44B: <https://mistr.usask.ca/odin/?caseID=20170731231621906>

The images above depict a normal pediatric bone scan. Areas of active bone growth i.e. epiphyseal growth plates, demonstrate more radioactivity as the pharmacologic substrate bound to the radioactive Technetium concentrates in areas of heightened bone metabolic activity. This is in contrast to *Figure 3.44B*, where the adult does not have the same areas of uptake of the Technetium-diphosphonate.

Due to the physics of the detection of emitted photons, the images acquired are low in anatomic detail (spatial resolution), but provide information about the physiology of the tissue being imaged related to the quantitative uptake of the radioactivity into the target tissues. Therefore, regions of the patient's anatomy that harbor a larger concentration of the injected radioactive substance emit the largest amount of detectable radiation. The areas emitting radiation are displayed in black on static, standard, nuclear medicine images. More detected radiation results in a blacker region of the resulting image. For the pediatric bone scan displayed previously one can appreciate that the growth centres of the child's bones are more metabolically active and are blacker on the bone scan.

Nuclear Medicine:

- Uses an internal source of radiation (e.g. Technetium 99m)
- Low spatial resolution
- Provides information about the physiology of the tissue being assessed

PET/CT

Positron Emission Tomography – Computed Tomography (PET-CT) is a fused imaging technology that detects positron emission from the radioactive source (Fluorine) and creates images for display. There is a CT scanner built into the same apparatus that houses the positron detector and the two examinations can be acquired with the patient remaining in the same anatomic position. The patient lies supine on the table while the table-top moves into the scanner housing. Since the CT and the PET scan are obtained simultaneously it is subsequently possible to overlay (fuse) one image set on the other to correlate the activity level of positron emission with the anatomy seen on the CT. *Figure 3.45* illustrates the appearance of a PET/CT scanner.

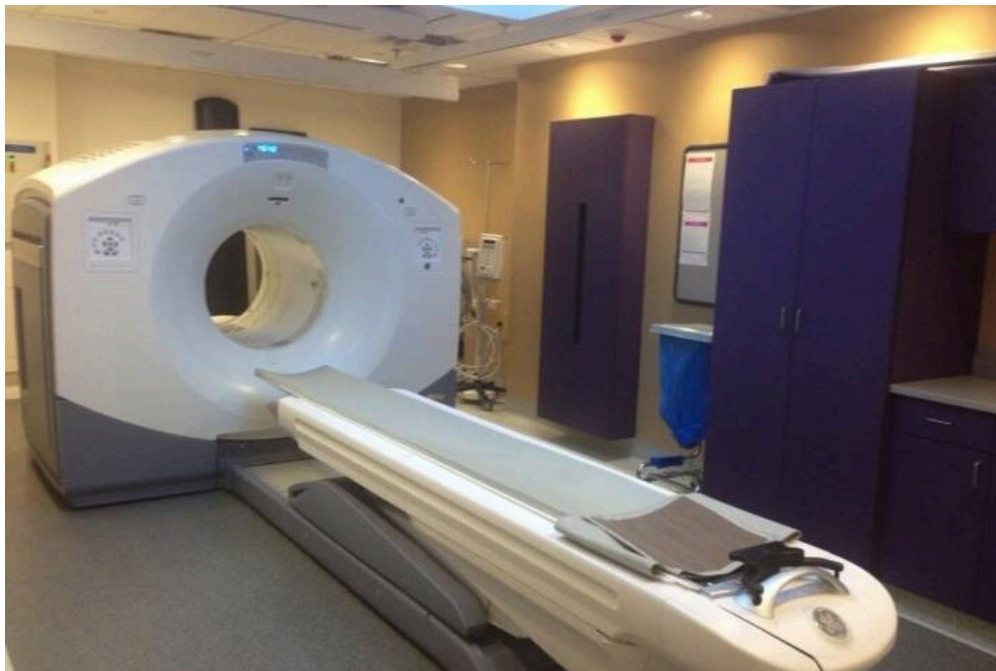

Figure 3.45 PET/CT Scanner

PET-CT has emerged as a very important imaging tool for the detection of metabolically active tissue. The most common radioactive substance used for PET-CT is fluorine bound to glucose. Elevated tissue metabolic activity for glucose will result in more of the radioactive fluorine concentrating in those tissues. Malignancies and infections metabolize glucose at an accelerated rate and can be imaged with PET even when the CT scan, taken for correlation, is normal.

The regions of the fused PET/CT axial scans that have the most metabolic activity are registered as a bright red/orange colour while those areas with little metabolic activity are black. A PET/CT axial scan for a patient with widespread lymphoma and is provided for review in *Figure 3.46A*.

A PET whole body image is displayed in *Figure 3.46B*. The regions of greater metabolic activity results in a blacker pixels for the PET portion of the scan.

Fused PET/CT

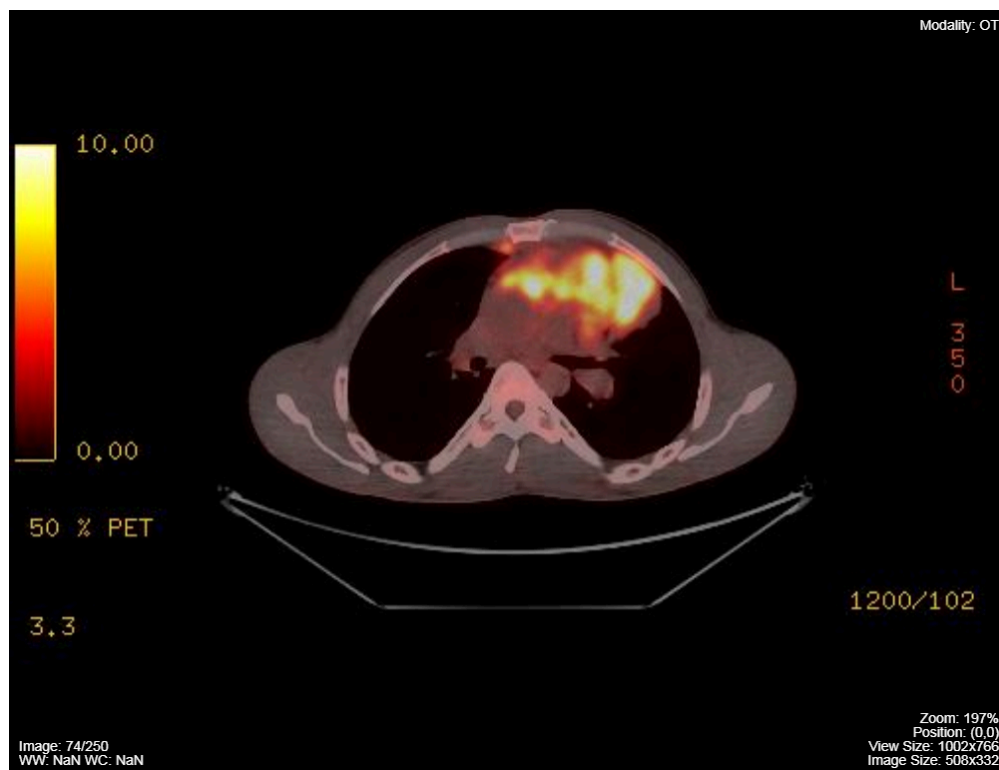


Figure 3.46A PET/CT – Fused image, PET image superimposed on the of the axial chest CT for a patient with lymphoma

Whole Body PET Image

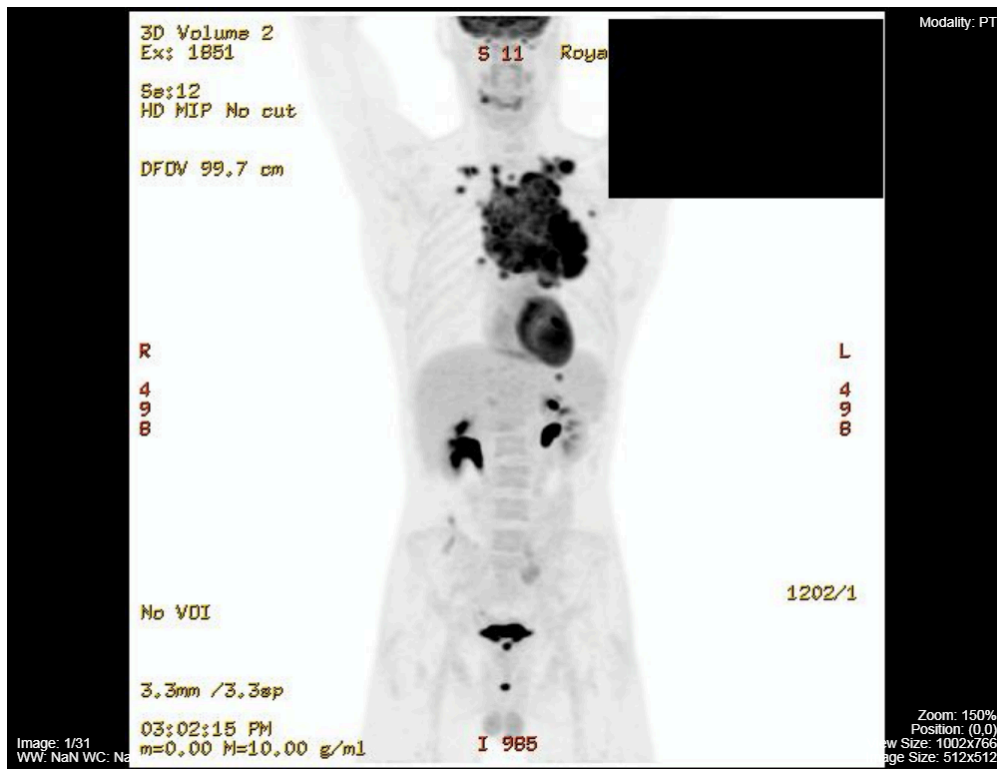


Figure 3.46B PET, whole body image, for a patient with lymphoma

ODIN Link for Figures 3.46A and B: <https://mistr.usask.ca/odin/?caseID=20160130102832209>

Attributions

Fig 3.43 Nuclear Medicine Scanner by Dr. Brent Burbridge MD, FRCPC, University Medical Imaging Consultants, College of Medicine, University of Saskatchewan is used under a [CC-BY-NC-SA 4.0](#) license.

Fig 3.44A Normal, Pediatric Nuclear Medicine Bone Scan by Dr. Brent Burbridge MD, FRCPC, University Medical Imaging Consultants, College of Medicine, University of Saskatchewan is used under a [CC-BY-NC-SA 4.0](#) license.

Fig 3.44B Normal, Adult Nuclear Medicine Bone Scan by Dr. Brent Burbridge MD, FRCPC, University Medical Imaging Consultants, College of Medicine, University of Saskatchewan is used under a [CC-BY-NC-SA 4.0](#) license.

Fig 3.45 PET/CT Scanner by Dr. Brent Burbridge MD, FRCPC, University Medical Imaging Consultants, College of Medicine, University of Saskatchewan is used under a [CC-BY-NC-SA 4.0](#) license.

Fig 3.46A PET/CT image of the chest for a patient with lymphoma by Dr. Brent Burbridge MD, FRCPC, University Medical Imaging Consultants, College of Medicine, University of Saskatchewan is used under a [CC-BY-NC-SA 4.0](#) license.

Fig 3.46B PET image of the whole body for a patient with lymphoma by Dr. Brent Burbridge MD, FRCPC, University Medical Imaging Consultants, College of Medicine, University of Saskatchewan is used under a [CC-BY-NC-SA 4.0](#) license.

Principles of Imaging Techniques – References

- 1) Amis, Jr. SE, Butler PF, Applegate KE, Birnbaum, SE. American College of Radiology White Paper on Radiation Dose in Medicine. J Am Coll Radiol 2007;4:272-284.
- 2) Image Wisely. <http://www.imagewisely.org/> Last accessed, Aug. 22, 2017.
- 3) Image Gently. <http://www.imagegently.org/> Last accessed Aug 22, 2017.
- 4) Novelline, R. A., & Squire, L. F. (2004), sixth edition. Squire's fundamentals of radiology. Cambridge, Mass: Harvard University Press.
- 5) CAR Referral Guidelines: [CAR Website](#) Last accessed July 2017.
- 6) ACR Appropriateness Criteria: [Chapter in this book](#) – [ACR Website](#) Last accessed July 2017.
- 7) Choosing Wisely – Canada: [Chapter in this book](#) – [CWC Website](#) Last accessed July 2017.
- 8) Seldinger, I. Catheter Replacement of the Needle in Percutaneous Arteriography: A new technique. Acta Radiologica 1953, 39:5,368 — 376.

Chapter 4 – Contrast Media in Radiology

Contrast Media in Radiology

Learning Objectives

Knowledge

- Recognize the indications for the use of contrast media in the study of various organs/organ systems using fluoroscopy, CT, DSA, and MRI
- Know the risks and side effects of commonly used contrast media.
- Determine the use of the various timing phases of contrast media application and their respective values according to the clinical problem.
- Define nephrogenic systemic fibrosis (NSF), related to MRI contrast, and the measures that can be taken to minimize this risk

Competancies

- Recognize if a CT is contrast-enhanced, or not
- Recognize various types of contrast-enhanced fluoroscopic examinations
- Communicate the risks and benefits of contrast media application for various common radiological examinations (including radiography, fluoroscopy, DSA, CT, and MRI) to patients and their families

A fundamental factor that results in diagnostic images being clinically useful is the concept that different anatomic tissues have differential appearances on imaging, whether it be density, intensity, or echogenicity. For example, the density of the liver on Computed Tomography (CT) does not match that of the gallbladder, and therefore, these structures can be differentiated on CT images.

When tissues are very similar in appearance to the structures around them, e.g. arteries vs. veins in the hilum of the lung, it is sometimes necessary to utilize a contrast agent to help differentiate one structure from another. The administered contrast alters the way that x-rays pass through the patient to reach the image detector or alter the response of tissues to ultrasound or to magnetic fields, and hence effect the appearance of the resulting images making it different from an image without contrast agent administered. Malignant tissues often display differential contrast enhancement than normal tissue making them more visible on imaging. Often, it is important to time

image acquisition based upon the length of time from contrast injection to capturing the image to accentuate the visibility of arteries, veins, and organs, optimizing the detection of abnormalities.

There are a number of different forms of imaging contrast (*gas, liquid, suspension*) allowing for delivery by *mouth, per rectum, intraluminal, or intravenous/intraarterial routes*. Each different delivery mode has unique applications, for example, a suspension of particulate barium sulfate is a type of oral contrast used for fluoroscopy (esophagrams, upper gastrointestinal series, and small bowel follow-throughs). Particulate suspensions of barium can only be administered into the intestinal tract. Administration, or leakage, of barium outside the intestinal tract may have severe, adverse outcomes for the patient.

The majority of contrast used in x-ray based imaging is water soluble. This is a pharmacologic agent bound to molecules of iodine and it is administered intravenously, intracavitary, or intraarterially. The presence of the iodine prevents the x-rays from penetrating the contrast enhanced tissue, resulting in these structures appearing denser (more opaque) on imaging. For example, dense contrast in veins or arteries can be almost as dense as bone on CT imaging. Knowledge of the physiology of blood-flow and the anatomic distribution of arteries and veins is important in the interpretation of contrast enhanced images.

Because Magnetic Resonance Imaging (MR) imaging does not use x-rays, contrast enhancement for MR is a paramagnetic, *gadolinium based, contrast agent (GBCA)* that can be injected intravenously or intra-articularly. The use of paramagnetic contrast agents for MR functions to alter the signal from the tissues in which it concentrates, which is accomplished by altering the response of water molecules in the tissues to the magnetic field and radio waves that are used in MRI.

Ultrasonography with contrast is performed infrequently. Ultrasound contrast is a liquid suspension containing micro-bubbles, or microspheres, for injection. The gas encapsulated within the shell of the microsphere results in increased echogenicity of the tissues that harbour the contrast agent. When injected into the blood stream, ultrasonographers can visualize the echogenic bubbles or spheres.

Contrast Agents in Imaging:

- Many forms of contrast (gas, liquid, suspension) with many forms of delivery (by mouth, per rectum, intraluminal, intravenous, and intra-arterial)
- CT most often uses water-soluble contrast; iodine bound to a pharmacologic agent
- MR uses gadolinium based contrast agents (GBCA)
- Ultrasound can use gas containing micro-bubbles or micro-spheres as a contrast agent

Modality Specific Contrast Utilization

Fluoroscopy

Fluoroscopy is an x-ray based modality used for a wide variety of imaging procedures. Examples of some of the procedures include, barium swallows, barium enemas, interventional procedures (catheter insertion, angioplasty, and angiography), myelography, upper gastrointestinal series, and small bowel follow-through and arthrography. For double contrast barium enemas both gas and barium are introduced into the colon to acquire optimal images of the mucosa of the bowel. Therefore, fluoroscopy can potentially employ all three forms of imaging contrast (water soluble, suspension, and gas) for a wide variety of procedures.

Figure 4.1 demonstrates a shoulder arthrogram where water soluble contrast has been injected into the joint space of the shoulder as part of a diagnostic or therapeutic procedure. The needle was maneuvered into the joint space using fluoroscopy and the dispersal of the injected contrast is monitored with fluoroscopy and/or sequential images.

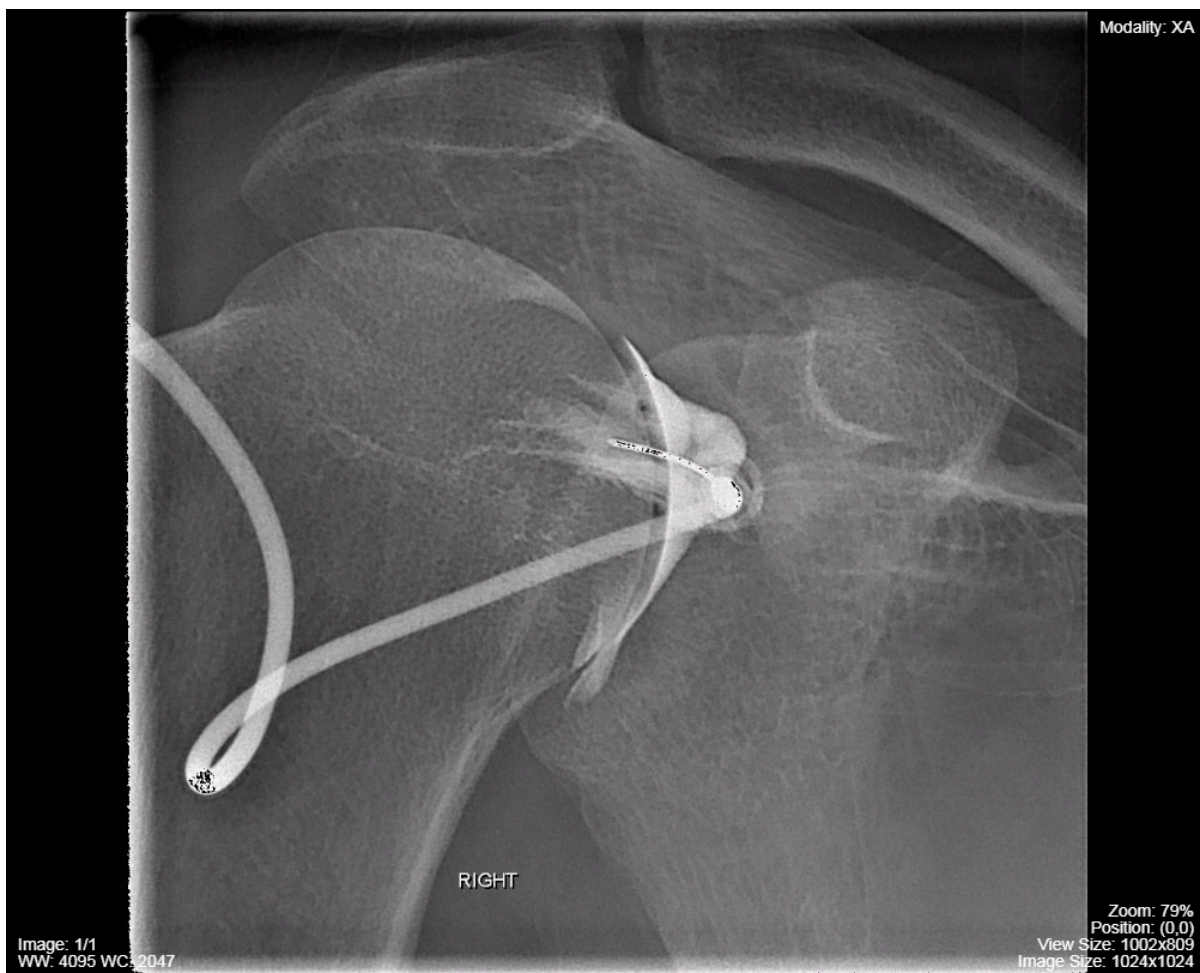


Figure 4.1A – Fluoroscopy, Shoulder Arthrogram Early Phase of Injection

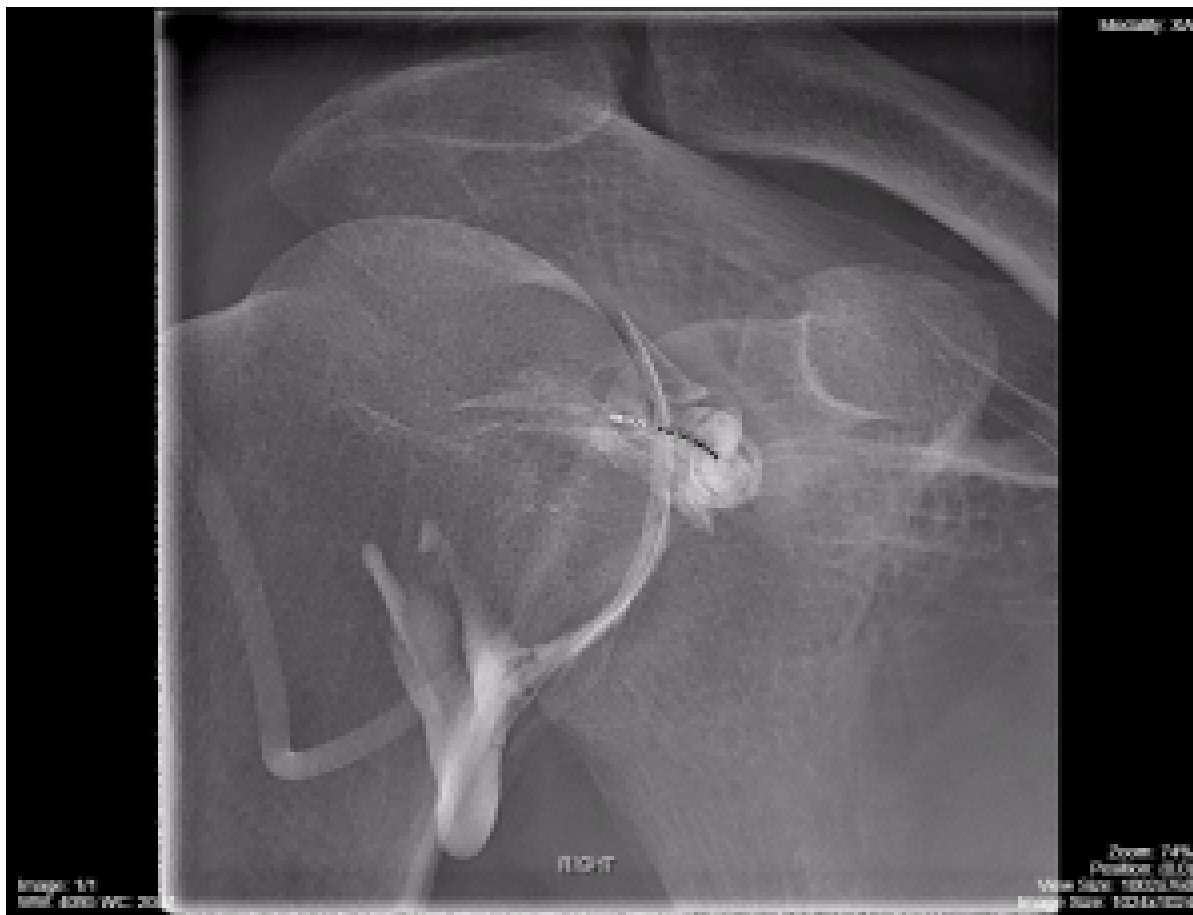

Figure 4.1B – Fluoroscopy, Shoulder Arthrogram Mid-phase of Contrast Injection

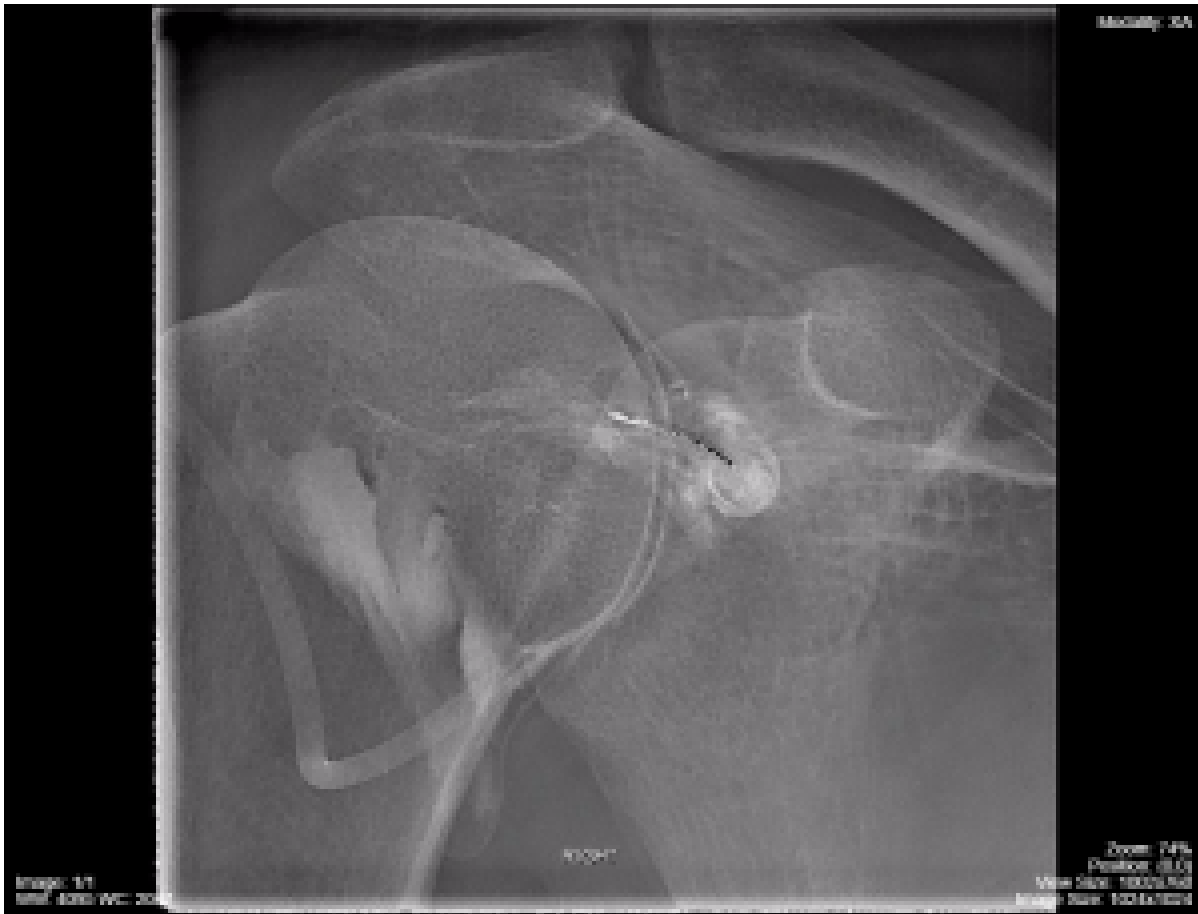

Figure 4.1C – Fluoroscopy, Shoulder Arthrogram Late-phase of Contrast Injection

Computed Tomography

There are a wide variety of indications for contrast in CT. CT has excellent contrast resolution and this feature can be used to detect subtle differences in tissue enhancement and help to detect liver metastases, central tumor necrosis, and other pathologies that rely upon the differential concentration of injected contrast agent. On a daily basis CT uses the largest volume of water soluble contrast agent in the entire Diagnostic Radiology department. Examples of the use of contrast for CT imaging include, arterial phase imaging, CT Angiography (CTA) such as pulmonary arterial imaging for a Pulmonary Embolus (PE) study, and lung cancer staging to differentiate between lymph nodes, veins, and arteries in the pulmonary hilum. Oral, water soluble, contrast can also be used in the intestinal tract to facilitate visualizing the stomach, small bowel, or large bowel. For CT, bowel contrast must be water soluble as barium creates very prominent artifacts due to the atomic number of barium absorbing a large amount of the administered x-rays. Gas, in the form of injected carbon dioxide, is used for the performance of CT Colonography.

Figure 4.2 depicts two sets of CT scans, one set is without contrast (denoted as No C), and one set is with intravenous contrast (denoted as C+). The images are scans of the abdomen, with arrows pointed to the abdominal aorta and the common iliac arteries. The study with contrast in the arteries makes it easier to differentiate the arteries from the surrounding tissues, especially downstream of the aortic bifurcation. The images were acquired

quite early after the intravenous injection of the contrast agent in the arterial phase of enhancement, contrast in the superior mesenteric artery, the renal arteries, and the kidneys is also noted.

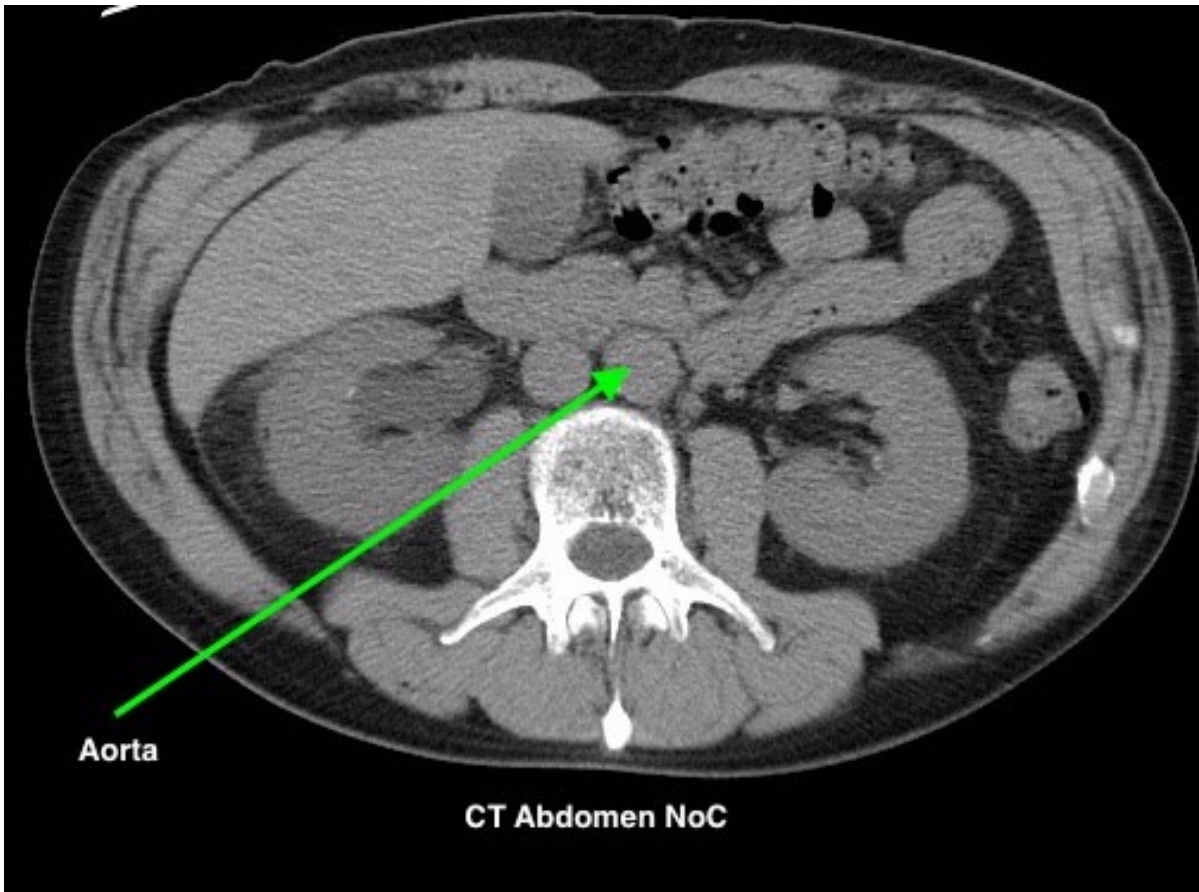


Figure 4.2A CT Aorta, C-

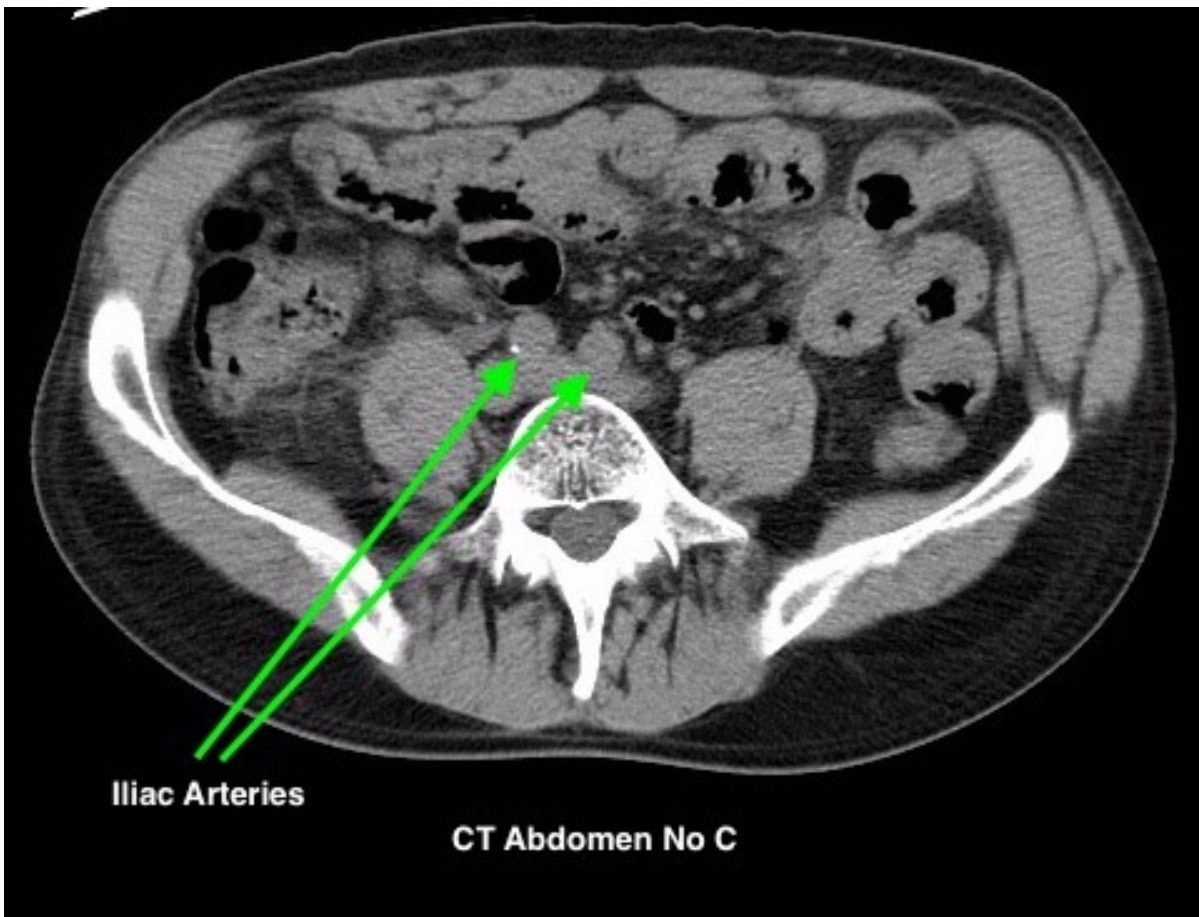


Figure 4.2B CT Iliac Arteries, C-

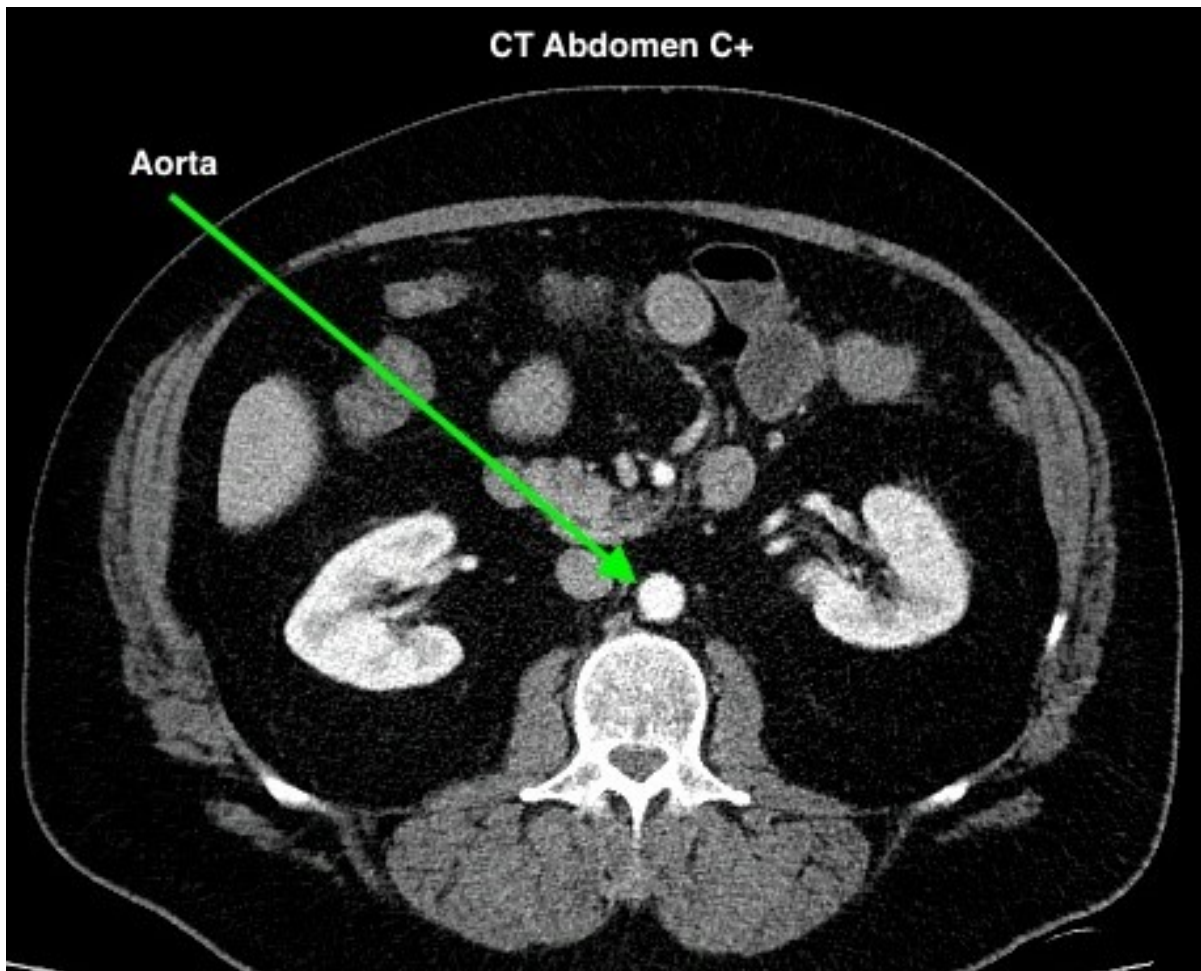


Figure 4.2C CT Aorta, C+

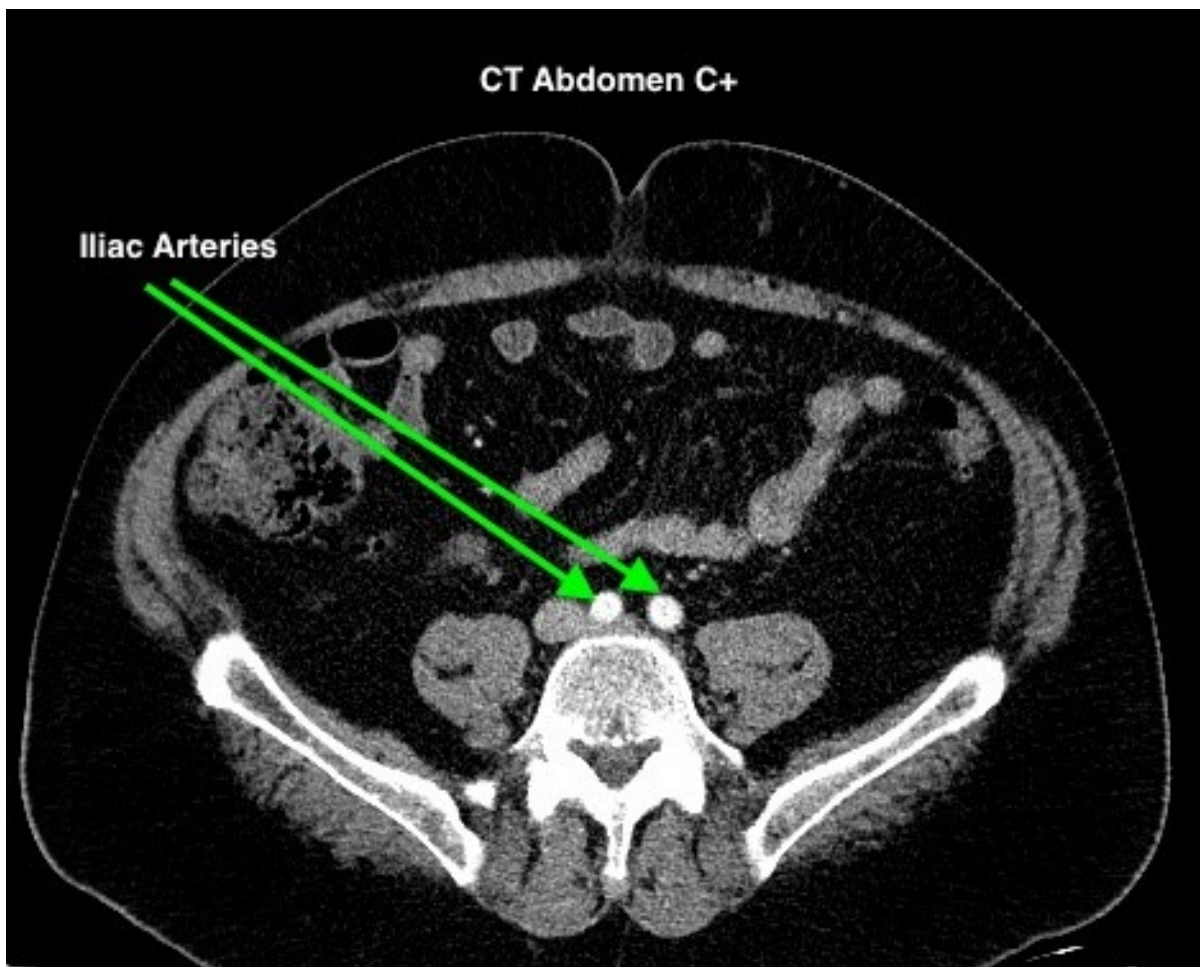


Figure 4.2D CT Iliac Arteries, C+

Timing the Phase of Contrast Media for CT

The timing of image acquisition, relative to the time of injection of the contrast agent, can impact which anatomic structures harbour the greatest concentration of the administered contrast. This phenomenon is most important for CT. Five phases of contrast enhancement for CT imaging are discussed below.

The non-enhanced phase (no injected contrast) allows for a determination of the baseline status of the patient's anatomy. Additionally, any structures that are calcified will be readily discernible, e.g. calculi, vascular calcifications, and dystrophic calcification in some tumours. These abnormalities will appear different from the surrounding tissues because of the calcium present in them. Administering contrast may obscure these calcified structures, especially urinary collecting system calculi, making detection difficult.

An early arterial phase, seconds after contrast administration, involves imaging very quickly after a bolus of intravenous contrast is administered, and can be useful for detecting certain abnormalities, specifically related to the arterial abnormalities (e.g. – arterial dissections).

The late arterial phase, requires images to be acquired 15 – 20 seconds after the early arterial phase has passed,

and is ideal for imaging anatomic structures that are highly vascularized, such as the liver, spleen, and kidneys. These are especially useful for the identification of masses in these organs.

The portal venous phase, is a later phase image acquisition that takes advantage of the fact the contrast has cleared the arterial tree and is maximally concentrated in the mesenteric venous structures, the splenic vein, and the portal vein. This is often an important phase for assessing liver perfusion and cirrhotic patients for portal hypertension.

A delayed phase, also known as the ‘wash out phase’ or the ‘equilibrium phase’, occurs significantly later after contrast administration. This has also been called the total body opacification phase of contrast enhancement. The acquisition of serial images of an adrenal gland mass is an example of the use of ‘wash out’ imaging as benign lesions will demonstrate a different pattern of contrast ‘wash out’ than malignant tumours.

Timing of Contrast Media for CT:

- Non-Enhanced Phase – baseline status of patient’s anatomy, calculi, calcification
- Early Arterial Phase – for certain arterial abnormalities (e.g. arterial dissection)
- Late Arterial Phase – for highly vascularized structures (e.g. liver, spleen, kidney)
- Portal Venous Phase – concentrated in mesenteric and portal venous structures
- Delayed Phase – wash out phase / equilibrium phase. To visualize lesions that retain contrast (e.g. tumors)

Digital Subtraction Angiography

Digital Subtraction Angiography (DSA) has a wide variety of indications, including, active GI bleeding, arterial stenosis for intervention, intervention for aneurysms, and arteriovenous malformation (AVM) diagnosis and treatment. Water soluble contrast agent for DSA is directly injected into the arterial lumen via a catheter that has been inserted by an Interventional radiologist. The images acquired for DSA are digitally subtracted using a computer to superimpose a non-enhanced image over the contrast enhanced images resulting in subtracted images that depict only the arteries as the background anatomy has been subtracted away.

Magnetic Resonance Imaging (MRI) Contrast

Contrast enhanced MR imaging is useful for a wide variety of applications, most notably to assess neurological malignancies. Other uses include characterizing lesions that have atypical appearances throughout the body, including neurologic abnormalities such as demyelination. It is also beneficial for assessing types of liver tumors and different types of arteriovenous malformations.

Risk Factors Associated with Contrast Agents

Any drug has risk associated with it, as do contrast agents used in medical imaging. A potential acute situation related to water soluble contrast is the risk of an ‘allergic-like’ reaction (anaphylactoid). This reaction is anaphylactoid as it does not meet the defined criteria for a true allergic reaction (i.e. symptom free exposure to the antigen, development of an immune system mediated response to the antigen, anaphylactic reaction to the next exposure to the antigen). Anaphylactoid reactions to water soluble contrast agents can occur with the first exposure to contrast, skip contrast exposures, and can be highly unpredictable ranging from mild physical responses to cardiovascular collapse and death. Although severe anaphylactoid responses to water soluble contrast are very uncommon, a number of risk factors exist that increase a patient’s risk of developing an allergic-like reaction. The most significant risk factor for an anaphylactoid reaction, or any other type of reaction to water soluble contrast agent, is to have had a previous reaction to contrast. Furthermore, having a known allergy to anything else also increases a patient’s risk, but not nearly to the same extent as reacting to previous contrast. Therefore, contrast can likely still be administered if the patient reports an unrelated allergic.

For patients that are considered high-risk for an ‘allergic type’ adverse reaction to contrast, one may consider the use of pre-medication to lessen the chance of an adverse effect. The most common pre-medications used are oral corticosteroid supplemented with an oral, non-selective antihistamine. It is still possible that a patient can have an allergic-like or non-allergic type reaction, regardless of whether they have been administered pre-medication, and this is known as a “breakthrough reaction”. For more specific guidance about when to use pre-medication and for the recommended drug prophylactic regimen, please see the [ACR Manual on Contrast Media](#).

There are other relative **contraindications** to contrast agents that should be taken into consideration including: Severe anxiety disorders; Patients on Beta-Blockers; Sickle-Cell Trait or Disease; and Hyperthyroidism (when using an iodinated contrast medium).

There are non-allergic adverse events that may effect the urinary system including, Contrast-Induced Nephrotoxicity (CIN), as well as Nephrogenic Systemic Fibrosis (NSF).

Contrast-Induced Nephrotoxicity is a direct result of the adverse effect that contrast agent have on glomerular filtration. There is often a transient reduction in renal function for any patient receiving iodinated, water soluble, contrast agents. This becomes more of an issue if the patient’s renal function is impaired prior to contrast injection. Often, it requires a clinical decision to proceed with contrast even when renal function is poor due to the importance of the imaging examination requested for patient management. The patient’s renal function can be protected slightly by aggressively hydrating the patient prior to contrast injection.

Nephrogenic Systemic Fibrosis (NSF) is related to the use of gadolinium based contrast agents for MRI and primarily involves the skin and the subcutaneous tissues, but can also affect organs (lungs, heart, skeletal muscles). The presentation initially involves skin thickening, and/or may involve pruritus. Note that NSF does not present acutely, and can take days-to-months to develop, and more rarely, years. The most significant risk factors for developing NSF include using GBCA in the setting of chronic/end-staged kidney disease. Other risk factors for NSF are patients that have experienced acute kidney injury (AKI), or have been exposed to high-doses of and/or had multiple exposures to GBCA.

There are newer, Group II, GCBA's that do not increase the risk for NSF, however, Group I agents do increase risk and patients receiving group I agents should be screened because of the limited scientific research into the risks. Therefore, one way to mitigate the risks of NSF for a patient with end-stage renal disease that require a contrast-enhanced MR investigation, it may be preferable to use an iodinated contrast media for a CT, or a type II GBCA instead.

Ultrasound Contrast Agents have the potential to cause direct toxic or allergic-like complications, however, this is a very infrequent risk. There may be an increased risk of cardiopulmonary reaction if the patient has a prior cardiopulmonary condition, however, these reactions are very rare.

Pregnancy and Breast Feeding

Caution needs to be taken when imaging women who are pregnant, or potentially pregnant, because of the potential risks associated with exposure of the fetus to ionizing radiation. If imaging is required despite concerns for radiation one must realize that water-soluble, iodinated, contrast agents and gadolinium contrast agents can cross the placenta, as well as, be excreted into breast milk. The effects of these drugs on the fetus, or infant, are not well understood.

While iodinated contrast agents administered intravenously are excreted into the breast milk, less than 1% of the administered dose will be excreted via this pathway, and subsequently less than 1% of the dose that the baby receives will be absorbed by the infant's gastrointestinal tract. For Gadolinium contrast agents, less than 0.04% of the administered dose is excreted into the milk, and less than 1% of the ingested contrast is absorbed by the infant's gastrointestinal tract. Therefore, the relative exposure of the infant to either of these contrast agents via breast milk is minimal after a maternal administration. For more information on this topic refer to the [ACR Manual on Contrast Media](#).

Risks of Contrast Agents:

- Potential for allergic-like reactions
- Higher risk with previous allergic-like reaction or unknown-type reaction to contrast agents
- Patients at high risk can take pre-medications to decrease their risk (corticosteroids, non-selective antihistamine)
- Consideration against using contrast agents: Severe anxiety; Patients on Beta-Blockers, Those with Sickle-Cell (trait or disease), and Hyperthyroidism
- Potential for Contrast-Induced Nephrotoxicity (CIN) or Nephrogenic Systemic Fibrosis (NSF)

Pregnancy and Breast Feeding

- Caution needs to be taken when imaging women who are pregnant or potentially pregnant
- Water-Soluble, iodinated, contrast agents and Gadolinium agents can cross placenta barriers

and are excreted in breast milk

For More Information:

ACR Manual on Contrast – Website – <https://www.acr.org/Quality-Safety/Resources/Contrast-Manual>

Attributions

Fig 4.1A Fluoroscopy – Shoulder Arthrogram Early Phase of Injection by Dr. Brent Burbridge MD, FRCPC, University Medical Imaging Consultants, College of Medicine, University of Saskatchewan is used under a [CC-BY-NC-SA 4.0](#) license.

Fig 4.1B Shoulder Arthrogram Fluoroscopy Mid-Phase of Injection by Dr. Brent Burbridge MD, FRCPC, University Medical Imaging Consultants, College of Medicine, University of Saskatchewan is used under a [CC-BY-NC-SA 4.0](#) license.

Fig 4.1C Shoulder Arthrogram Late Phase of Injection by Dr. Brent Burbridge MD, FRCPC, University Medical Imaging Consultants, College of Medicine, University of Saskatchewan is used under a [CC-BY-NC-SA 4.0](#) license.

Fig 4.2A CT Aorta, C- by Dr. Brent Burbridge MD, FRCPC, University Medical Imaging Consultants, College of Medicine, University of Saskatchewan is used under a [CC-BY-NC-SA 4.0](#) license.

Fig 4.2B CT Iliac Arteries, C- by Dr. Brent Burbridge MD, FRCPC, University Medical Imaging Consultants, College of Medicine, University of Saskatchewan is used under a [CC-BY-NC-SA 4.0](#) license.

Fig 4.2C CT Aorta, C+ by Dr. Brent Burbridge MD, FRCPC, University Medical Imaging Consultants, College of Medicine, University of Saskatchewan is used under a [CC-BY-NC-SA 4.0](#) license.

Fig 4.2D CT Iliac Arteries, C+ by Dr. Brent Burbridge MD, FRCPC, University Medical Imaging Consultants, College of Medicine, University of Saskatchewan is used under a [CC-BY-NC-SA 4.0](#) license.

Chapter 5 – Approach to Reviewing X-ray Imaging

General Approach to Reviewing x-ray Imaging

Have a strategy, stick to it, and look at the images systematically. Use a method that allows you to assess all of the images provided. You should individualize the image review process in order for you to internalize and standardize your approach.

A useful principle to use when interpreting medical images is that of symmetry i.e. most anatomy in the chest is symmetrical from right to left so you can compare and contrast within the image. This does not hold true for the heart, for example, but is useful for bones and the lungs in general. When possible, assess the image from side-to-side to look for symmetry.

Air rises and this can give you a clue as to the position of the patient when the image was taken, i.e. upright, supine, or decubitus. Pathologic collections of gas/air also rise based upon patient position, e.g. a pneumothorax is best seen in the apex of the hemithorax on an upright chest x-ray.

Images may be modified by the addition of positive contrast (barium, water soluble iodine, etc.) or negative contrast (air, carbon dioxide, etc.) to facilitate the detection of abnormality.

Look for these technical features when reviewing x-rays

1. Name, Age, Gender, Date of image acquisition, and Laterality.

Patient (name/ identification number(s)/ date of birth, gender).

Date and time the image was taken.

Ensure laterality is correct i.e. the Right or Left marker should correspond to proper anatomic orientation.

Determine if previous imaging is available for comparison.

These elements are pivotal in matching the image with the particular clinical situation. Reviewing the most recent imaging is paramount. Comparison of the most recent imaging to previous imaging will allow for the detection of changes related to pathology or treatment.

2. Is the image too dark or too light?

If the x-ray is too light (white) this is related to insufficient x-rays reaching the detector. This could be due to the x-ray technologist not programming the x-ray machine to deliver an adequate dose of x-rays or it may be due to a large patient absorbing an excessive amount of the incident x-ray beam. If too much radiation has been administered for the image acquisition, the resulting image will be too dark (black). Both errors diminish the diagnostic utility of the x-ray.

3. Is the x-ray rotated in relation to anatomic position?

Images should be acquired in anatomic position when possible. The process of the standardization of patient positioning for x-rays results in a predictable appearance of the images and will assist the image interpreter in developing an concept of what normal images look like.

This subsequently facilitates the detection of abnormalities in anatomy as the interpreter has a strong foundation in what normal images look like. Non-anatomic positioning can alter the appearance of an x-ray and one must learn the effects of this sub-optimal positioning on the utility of the final image(s) and not be misled into suggesting that the images are abnormal.

Rotated, Tilted, Poor Inspiration

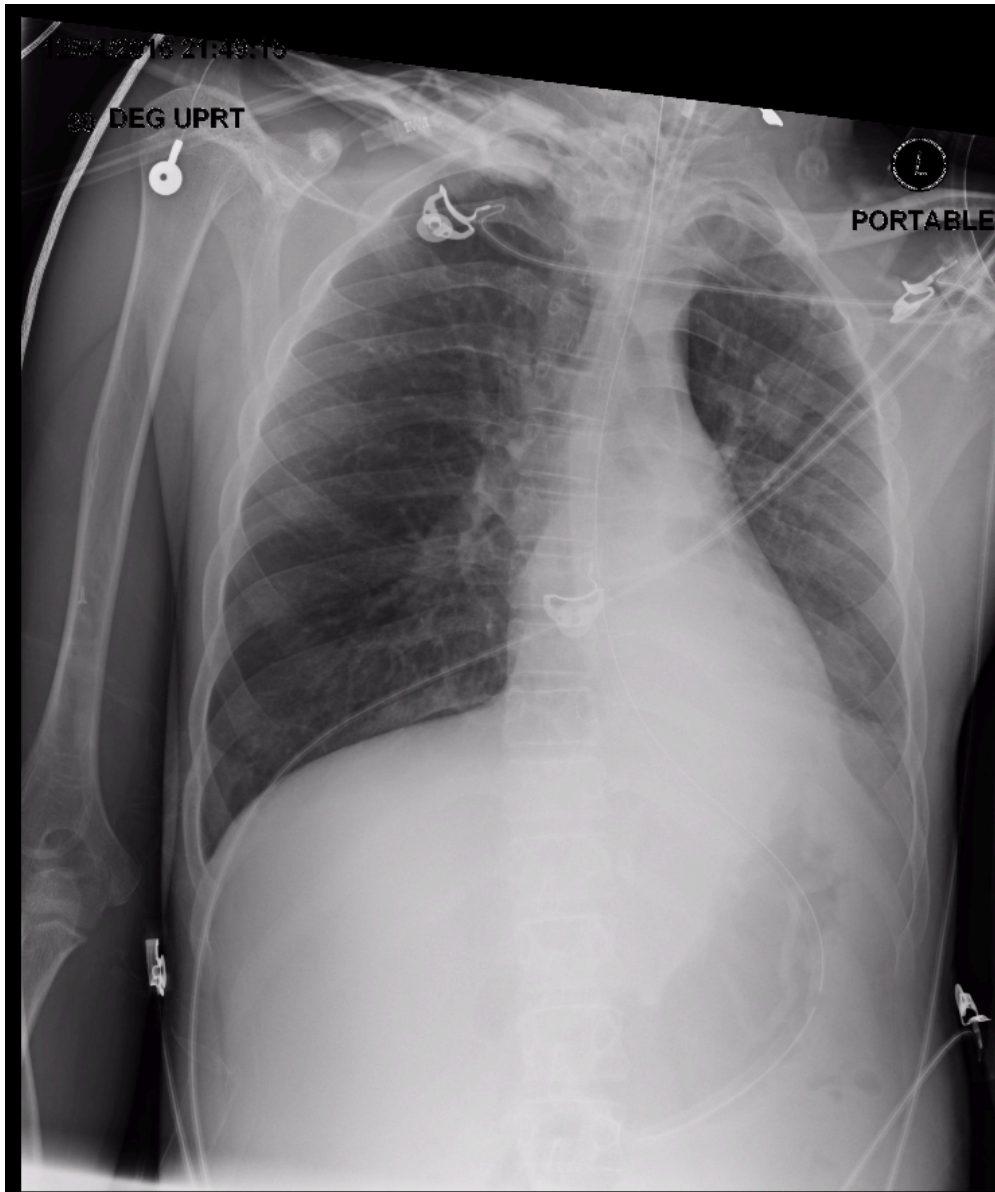


Figure 5.1 A portable, upright, chest x-ray with the patient tipped to the left and rotated to the left.

Better Positioning

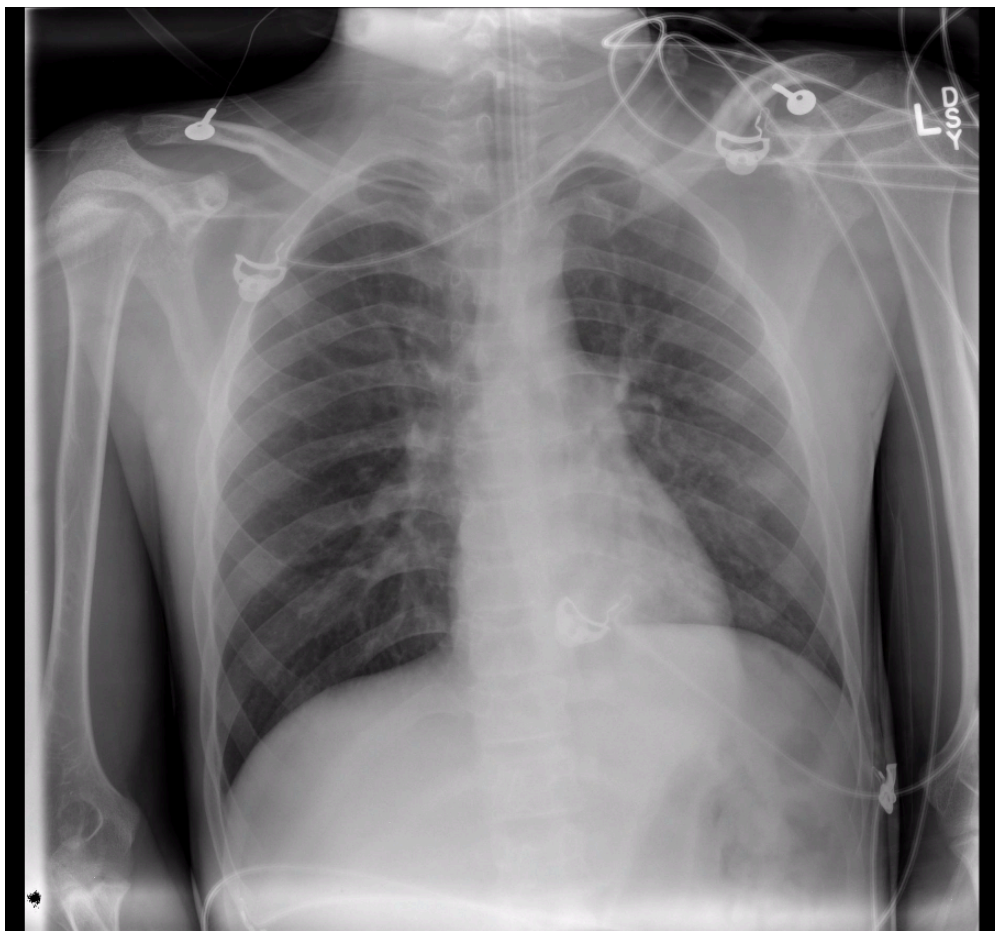

Figure 5.2 A portable, upright, chest x-ray taken with patient in standardized, anatomic position

4. Has important anatomy been missed on the available image?

Infrequently, the images provided do not include important pertinent anatomy e.g. the chest x-ray image does not include one of the hemidiaphragms. This can result in an error. If the excluded anatomy is clinically important, repeat radiographs will be warranted.

Reviewing X-ray Imaging:

- Name, Age, Gender, Date of Image Acquisition
- Is the x-ray too dark or too light?
- Is the x-ray rotated in relation to anatomic position?
- Has important anatomy been missing on the available image?

Attributions

Fig 5.1 A portable upright x-ray where the image is not taken with proper body alignment, the patient is rotated and tilted by Dr. Brent Burbridge MD, FRCPC, University Medical Imaging Consultants, College of Medicine, University of Saskatchewan is used under a [CC-BY-NC-SA 4.0](#) license.

Fig 5.2 A portable upright x-ray taken with patient in proper alignment by Dr. Brent Burbridge MD, FRCPC, University Medical Imaging Consultants, College of Medicine, University of Saskatchewan is used under a [CC-BY-NC-SA 4.0](#) license.

Approach to the Chest x-ray (CXR)

An approach to reviewing a chest x-ray (CXR) will create a foundation that will facilitate the detection of abnormalities. You should create your own strategy. There is no correct way to analyze chest x-ray images. Consistency and thoroughness are good general strategies. With time, and repetition, the process will become subconscious. Repetitive viewing of images will help establish a baseline of normality and normal variation that will represent an internal yard stick for the detection of variation from normal. Remember, abnormalities on imaging are simply aberrations of normal anatomy. Detection of an abnormality, or abnormalities, will allow facilitate the diagnosis of clinical conditions that may require medical attention.

The standard upright views of the chest are made when a patient is typically placed between an x-ray source and an x-ray detector. When the x-rays penetrate the tissues of the patient, they stimulate an x-ray detector that alters the energy of the x-ray beam into a digital pixel grid. The radiograph produced is referred to as a roentgenogram and named after Wilhelm Konrad Roentgen who received the first Nobel Prize for Physics in 1901 for his work in defining the major properties of x-rays and the conditions necessary for their production. It was Roentgen who coined the term “x-ray”.

Terminology Pertinent to the Chest x-ray:

Term	Definition
Lucency	Darker area on the image due to the transmission of relatively more of the administered x-rays that subsequently interact with the x-ray detector
Opacity	Whiter area on the image due to absorption, or scattering, of the incident x-rays prior to them reaching the x-ray detector
Consolidation	Process by which air in the lungs is replaced by products of disease rendering the lung more solid (opaque)
Nodule	Opacity < 3 cm in diameter
Mass	Opacity > 3 cm in diameter
Line	Linear opacity < 2 mm in thickness
Stripe	Linear opacity 2 – 5 cm in thickness
Hilum	Singular
Hila	Plural
Hilar	Adjective

Table 5.1 Terminology pertinent to chest x-ray

Chest x-ray Image Acquisition, Patient Positioning:

The standard chest x-ray is routinely taken in two views at near total lung capacity:

1. A posteroanterior (PA) view (Figure 5.3A) with the patient in the standing position opposing the front of their chest against the film cassette or image detector housing, and
2. A lateral view (Figure 5.3B). The lateral view is helpful in localizing the position of an abnormality from ventral to dorsal and also because on the PA view the lower lungs are obscured by the hemidiaphragms.

Posteroanterior (PA):

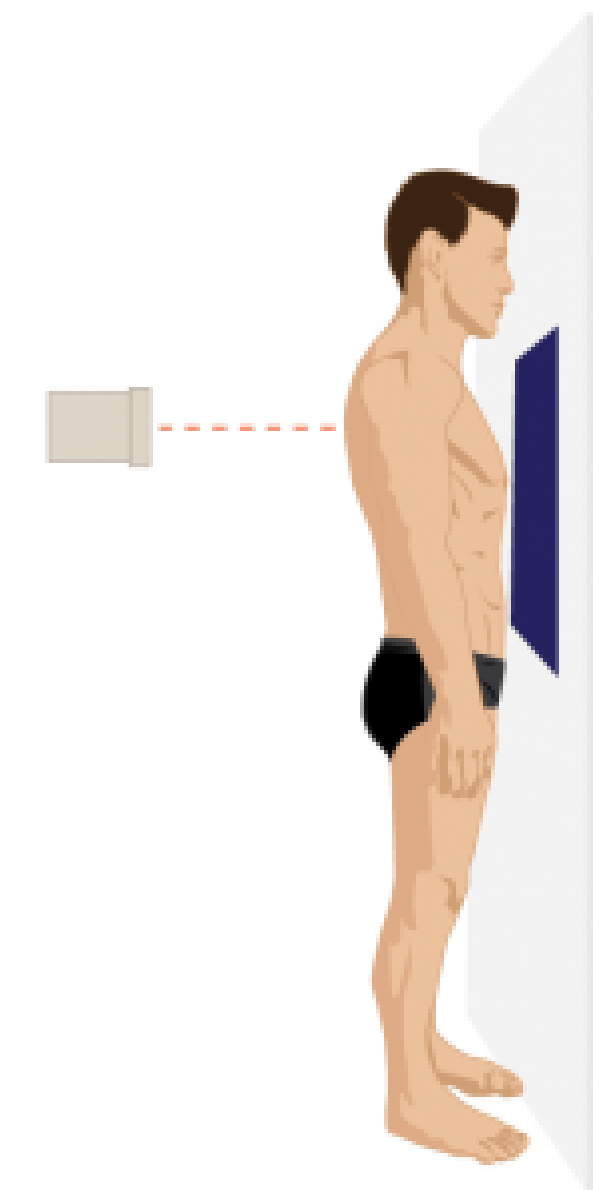


Figure 5.3A Positioning for a Posterior-Anterior Chest x-ray

Lateral:

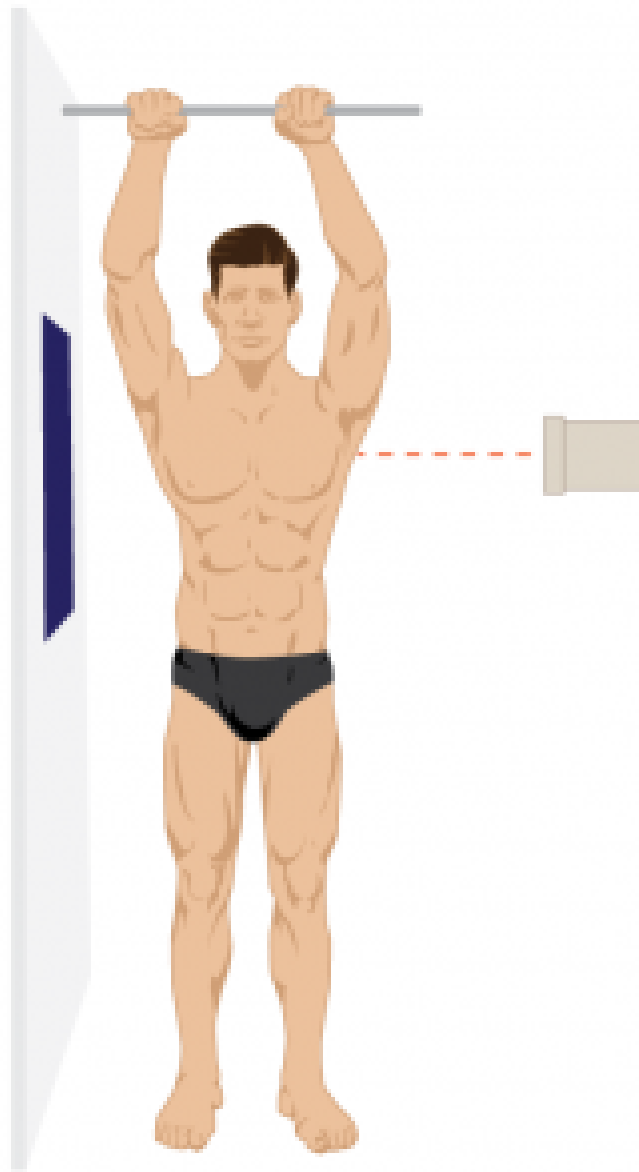


Figure 5.3B Positioning for a Lateral Chest x-ray

Normal PA and Lateral Chest x-rays

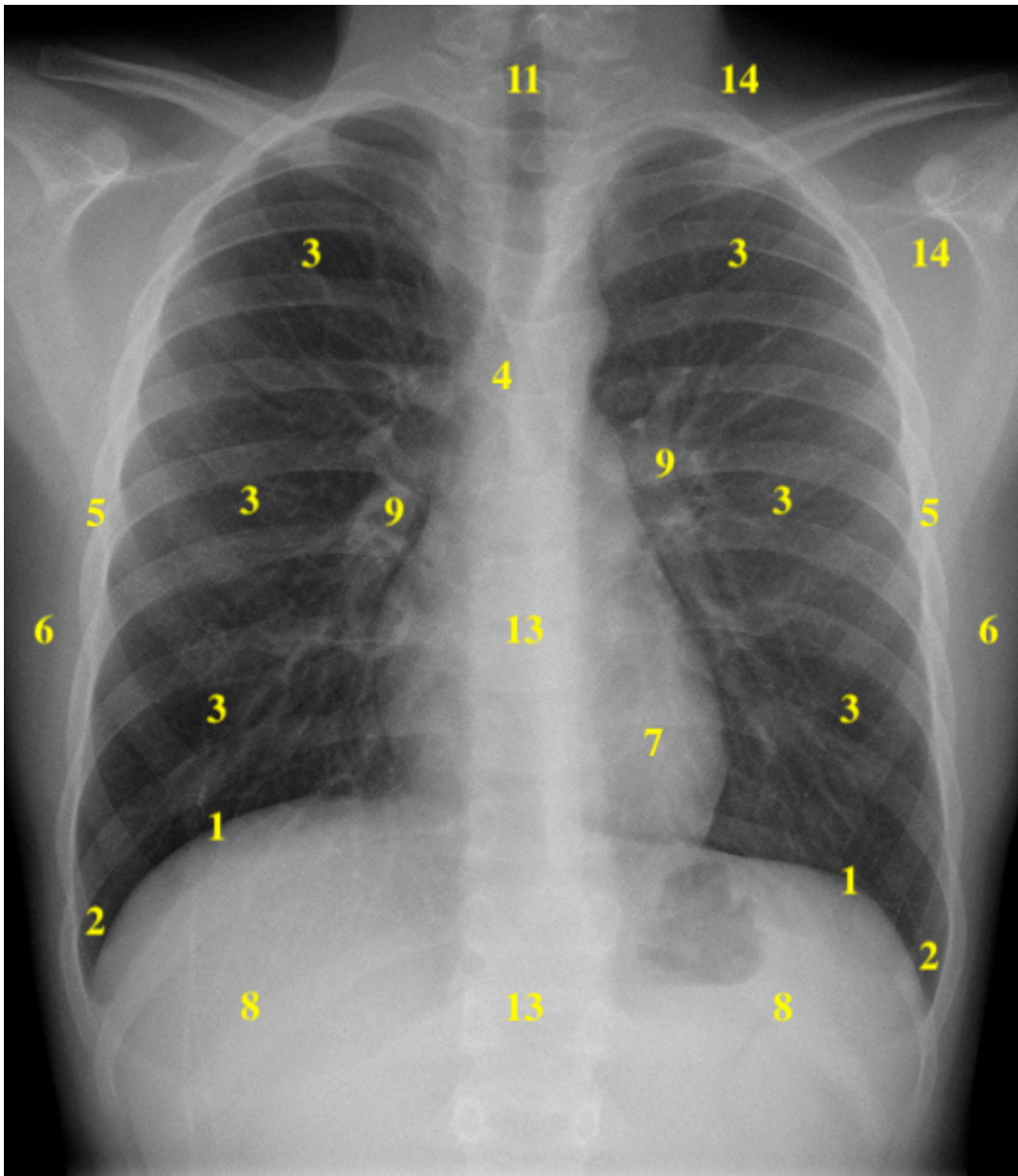


Figure 5.4A PA Chest x-ray

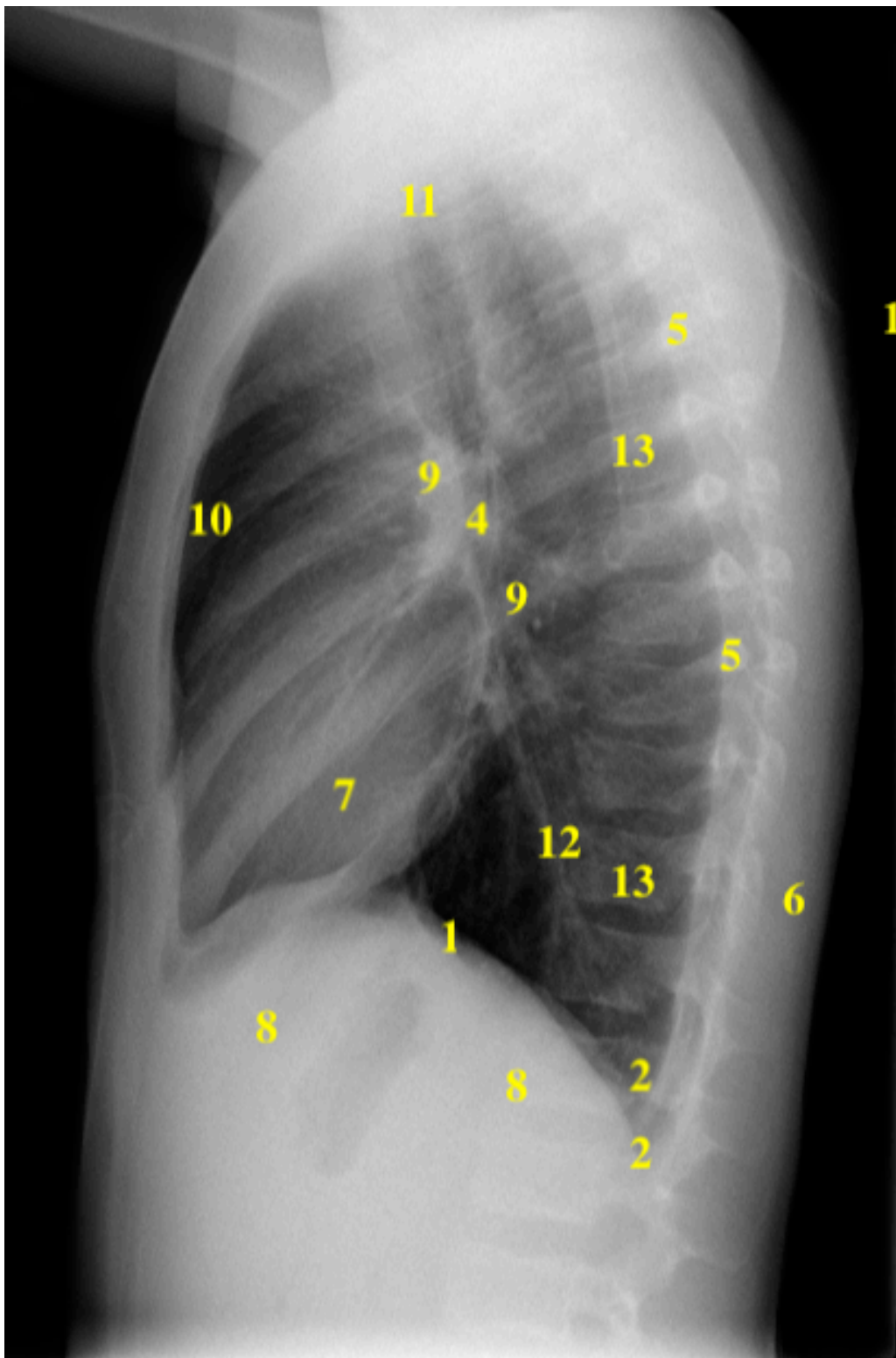


Figure 5.4B Lateral Chest x-ray

One option for performing a systematic analysis of the chest x-ray can be based upon a structured assessment of a numerical list of anatomic elements:

1	Hemidiaphragms	8	Below Hemidiaphragms
2	Costophrenic Angles	9	Hila
3	Zones of the Lungs	10	Anterior Mediastinum and Sternum
4	Carina and Bronchi	11	Trachea
5	Pleura and Ribs	12	Posterior Mediastinum
6	Chest Wall	13	Spine
7	Cardiac Silhouette	14	Soft Tissue of the Axilla and Lower Neck

Table 5.2 – Numerical List of Highlighted Anatomic Structures for Figures 5.4A and 5.4B

Portable Chest x-ray

An alternative imaging acquisition strategy is available for those patients who are unable to attend the Imaging Department and stand or sit upright for the standard images. The portable chest x-ray unit can be deployed to the patient's bedside. The source of the x-rays for portable imaging enters the patient from the anterior anatomy and the x-ray detection plate is posterior to the patient i.e. Anteroposterior (AP) images. A lateral view is not obtained using this image strategy. The portable chest x-ray is a less optimal imaging strategy as there are factors that alter the appearance of the image due to patient positioning and altered magnification of some anatomic structures. Also, the patient is often unwell resulting in inferior anatomic positioning and sub-optimal inspiration. There are often a variety of tubes, catheters, and other artifacts that alter the appearance of the portable chest x-ray.

Figure 5.5 ODIN link for Normal Portable Chest x-ray: <https://mistr.usask.ca/odin/?caseID=20170114100724626>

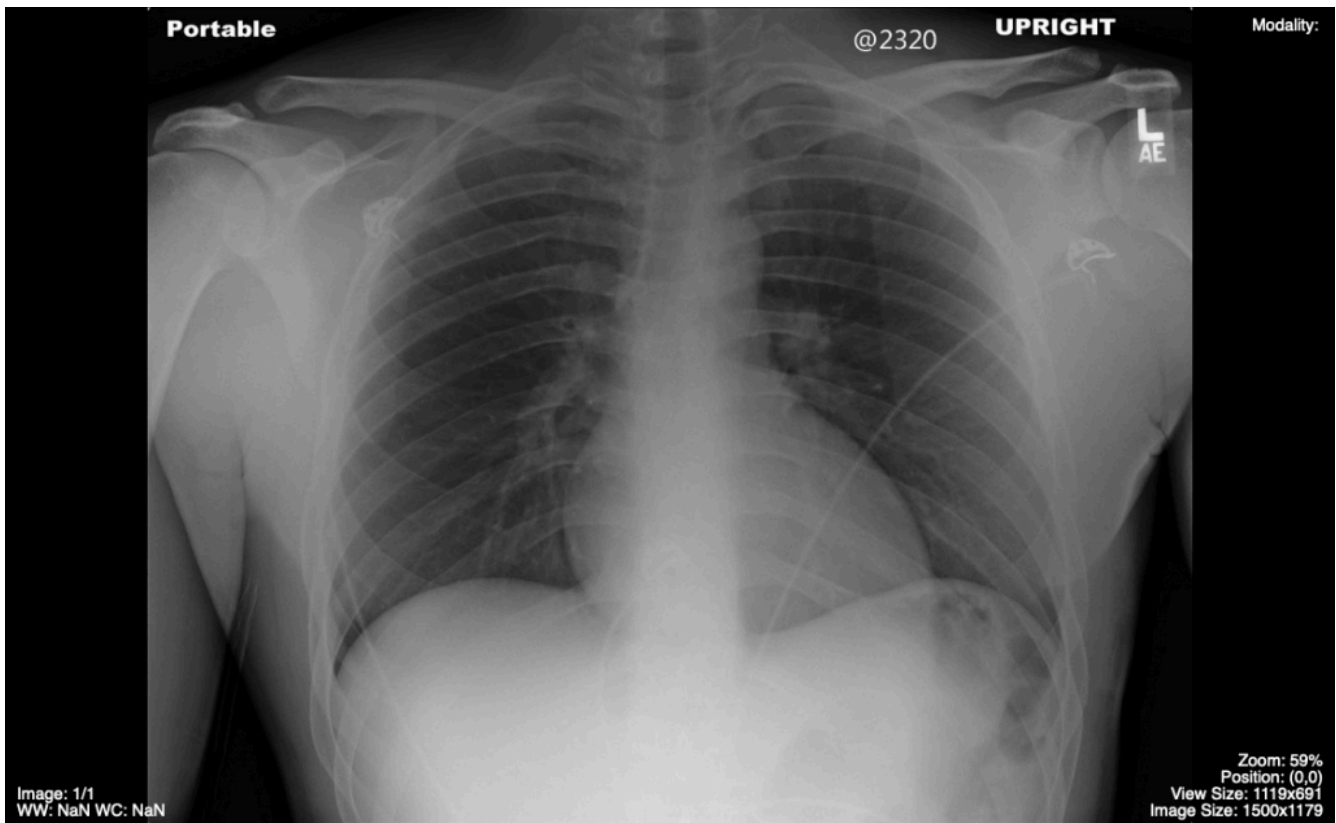


Figure 5.5 Normal Portable Chest x-ray

Additional chest x-ray strategies are also available: a) expiration views (pneumothorax or air-trapping), lordotic views (to assess the apices of the lungs), and the decubitus view (to assess for fluid mobility or air-trapping). These special views are usually goal specific and should be ordered to facilitate the diagnosis of a unique disease process i.e. pneumothorax, a foreign body obstructing an airway, apical lung nodules or masses, and pleural effusion. These pathologies will be discussed in subsequent chapters.

Strategies for Assessing Chest x-ray Images

1) Assess Image Quality:

Acronym: '*RIPE*':

Rotation	The medial aspect of each clavicle should be equidistant from the vertebral spinous processes
----------	---

Inspiration	Adequate inspiration is when: 5 – 6 anterior ribs, 9 – 10 ribs posteriorly in the mid-clavicular line, the lung apices, both costophrenic angles and the lateral rib edges are all visible
-------------	---

Projection	AP vs. PA film
------------	----------------

Exposure	Left hemidiaphragm visible to the spine and vertebrae visible behind the heart
----------	--

Table 5.3 – ‘RIPE’ Acronym

Alterations in standardized positioning, or x-ray exposure, will alter the ‘typical’ appearance of the image and may lead to inaccurate assessment, or misdiagnosis.

Ensure laterality is correct i.e. the Right (R) or Left (L) marker should correspond to proper anatomic orientation, e.g. left ventricular outline in the left hemithorax, etc.

2) ABCDE Approach

A – Airways/Mediastinum:

Airways

The trachea is normally located centrally or just slightly to the right of midline.

If the trachea is deviated, look for anything that could be pushing or pulling the trachea.

Pushing of trachea – e.g. large pleural effusion / tension pneumothorax / mediastinal mass

Pulling of trachea – e.g. lobar collapse, lung fibrosis

Rotation of the patient can give the appearance of a deviated trachea, so as mentioned above, check the clavicles to rule out rotation as the cause.

Carina

The carina is located at the point at which the trachea divides into the left and right main bronchus. On a good quality CXR this division should be visible. This division creates a carinal angle. This bifurcation of the trachea is an important landmark when assessing nasogastric tube placement, as the NG tube should pass distal to the carina in a vertical, midline, orientation.

Bronchi

The right main bronchus is generally wider, shorter, and more vertically oriented than the horizontally oriented,

longer, left main bronchus. As a result, it is more common for inhaled foreign objects to become lodged in the right side bronchial tree as the route is more direct. Depending on the quality of the CXR, you may be able to see the main bronchi branching into further subdivisions of bronchi which supply each of the lungs lobes.

Mediastinum

Paratracheal stripes

Right thicker than left, should have smooth contours. Lobulation of the contour of the paratracheal region suggests mass(es) or lymphadenopathy.

Mediastinal contours

The mediastinum contains the heart, great vessels, lymphoid tissue, major airways, and a number of potential spaces where pathology can occur. The lung – soft tissue boundary of the mediastinum on a CXR is a very important relationship to assess. This lung – soft tissue boundary is caused by the contrast between the predominantly air filled lung against the soft tissue of the mediastinum. This allows one to determine if an abnormally large, or bulging mediastinal contour is present or if an assortment of smaller bulges can be seen related to hilar or mediastinal lymph nodes or enlarged vessels.

If the lung opacity adjacent to the mediastinum is different (pneumonia, atelectasis, interstitial markings) this may partially, or completely, obscure the normally expected distinctive, smooth mediastinal interface, this is called the “Silhouette sign”. Gas in the mediastinum (pneumomediastinum) and gas in the pleural space (pneumothorax) will also alter the appearance of the mediastinal contours as the gas will be lucent. Pleural fluid (effusion) can obscure mediastinal anatomy if it accumulates in the vicinity.

Aortic knob

Left lateral edge of the aorta as it arches back over the left main bronchus.

Loss of definition and/or enlargement of the aortic knob contour is abnormal.

Aorto-pulmonary window

The aorto-pulmonary window is a space located between the arch of the aorta and the left pulmonary artery. This space can become opaque and may have an outward convex margin, as a result of mediastinal lymphadenopathy (e.g. malignancy).

Hilar structures

The hila consist of pulmonary vasculature, lymph nodes, fat, and the major bronchi.

The left pulmonary artery branch is more vertical and is a visible component of the left hilum while the right is more horizontal and not seen.

The left hilum is often positioned slightly higher than the right (97%), it is also more posterior on the lateral view, but there is variability.

The hila are usually roughly the same size, so asymmetry should raise suspicion of pathology.

Hilar enlargement can be caused by a number of different pathologies: bilateral symmetrical enlargement can be seen in sarcoidosis or lymphoma. Unilateral / asymmetrical enlargement may be due to underlying lung malignancy.

B - Breathing:

Lungs

You can divide each lung into 3 zones, each occupying 1/3 of the height of the lung.

Alternatively, one can create 3 imaginary zones radiating from the hilum i.e. inner zone with larger caliber vessels and bronchi, mid-zone with medium sized vessels, and the outer zone with small vessels. These zones do not equate to lung lobes.

Inspect each zone, ensuring that appropriately sized lung markings occupy the zone. Assess for asymmetry. The vessels in the lungs are larger in the lower lobes, normally.

Review the lung apices as there may be hidden pathology obscured by the clavicles and ribs.

Increased opacity in an area of the lung may suggest pathology (e.g. consolidation / nodule / mass). The absence of lung markings within a segment of the lung should raise suspicion of pneumothorax or severe emphysema.

Some pathology can cause symmetrical changes in the lung, making it more difficult to recognize, so it's important to keep this in mind (e.g. pulmonary edema).

Pleura:

The pleura are not normally visible in healthy individuals. The pleural surface should be smooth and parallel the rib cage. Fluid (*hydrothorax*) or blood (*hemothorax*) can also accumulate in the pleural space, causing an area of increased opacity. As fluid tracks up the wall of the chest in the pleural space it creates a meniscus just as water does in a beaker.

C - Cardiac:

Cardiac silhouette size (heart size)

The cardiac silhouette should occupy 50%, or less, of the thoracic width (e.g. a cardiothoracic (CTR) ratio of <0.5).

This rule only applies to PA chest x-rays (AP films exaggerate cardiac silhouette size), so you should not draw any conclusions about heart size from an AP film.

If the heart occupies more than 50% of the thoracic width (on a PA CXR) then this suggests enlargement. Enlargement of the cardiac silhouette can occur in a wide variety of conditions including, heart valvular disease, cardiomyopathy, pulmonary hypertension and pericardial effusion.

Assess heart borders

Inspect the borders of the heart which should be well defined in healthy individuals:

The heart borders may become difficult to distinguish from the lung as a result of various pathological processes (e.g. consolidation) which cause increased opacity of the lung tissue. (The silhouette sign)

The right atrium makes up most of the right heart border. The left ventricle makes up some of the left heart border, with a contribution for the left atrium.

Loss of definition of the right heart border is associated with right middle lobe consolidation

Loss of definition of the left heart border is associated with lingular consolidation

D - Diaphragm:

The right hemidiaphragm is in most cases higher than the left (as a result of the underlying liver). The stomach underlies the left hemidiaphragm and is best identified by the gastric air bubble located within it.

The diaphragm should be indistinguishable from the underlying liver in healthy individuals on an erect CXR, however if free gas is present (often as a result of bowel perforation), air accumulates under the diaphragm causing it to elevate and become visibly separate from the liver.

Costophrenic angles

The costophrenic angles are formed from the dome of each hemidiaphragm and the lateral chest wall.

In a healthy individual the costophrenic angles should be clearly visible on a normal CXR as a well defined acute angle.

Loss of this acute angle (referred to as costophrenic blunting) can suggest the presence of fluid, scarring, or consolidation.

E - Etcetera:

Bones – alignment, fractures, lytic or sclerotic lesions. Follow the ribs bilaterally, view the spine and sternum on the lateral view.

Soft tissues – bulging contours, unusual opacities (mass) or lucencies (mastectomy).

Iatrogenic – tubes, catheters, pacemakers, etc.

Normal Chest x-ray Images for Reference

Anatomic Line Drawing – Normal PA Chest x-ray

ODIN Link for Labelled Chest x-ray image, Figure 5.6A and B: <https://mistr.usask.ca/odin/?caseID=20170103165555291>

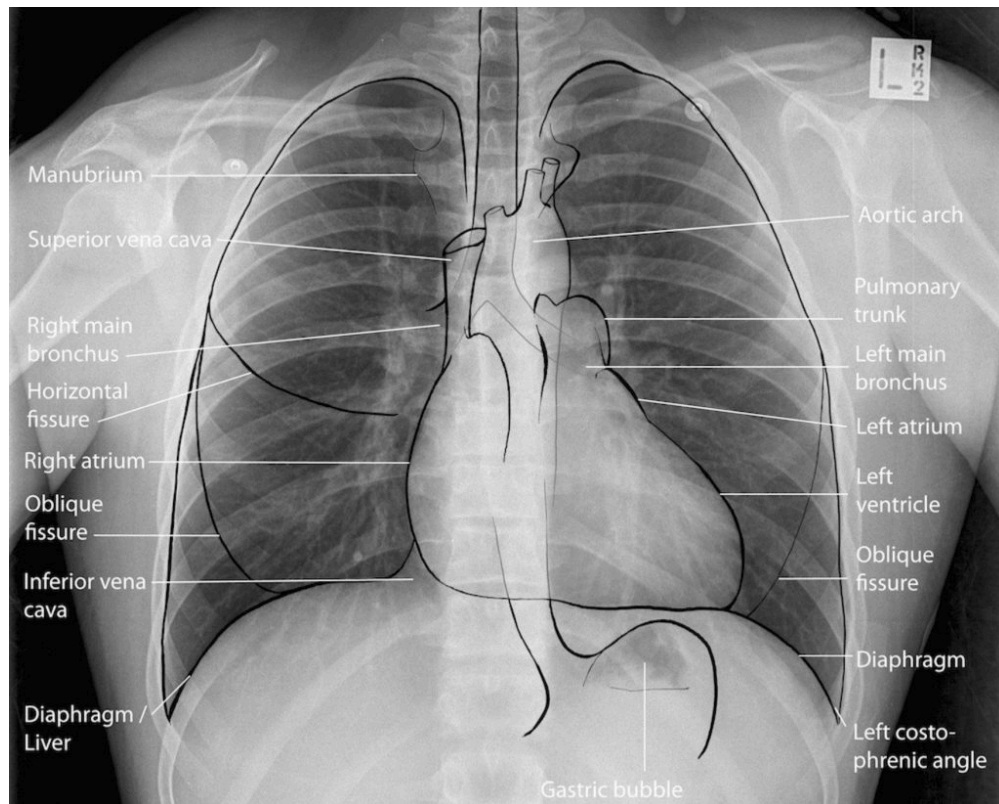


Figure 5.6A Line Drawing of AP Chest x-ray.

Anatomic Line Drawing – Normal Lateral Chest x-ray

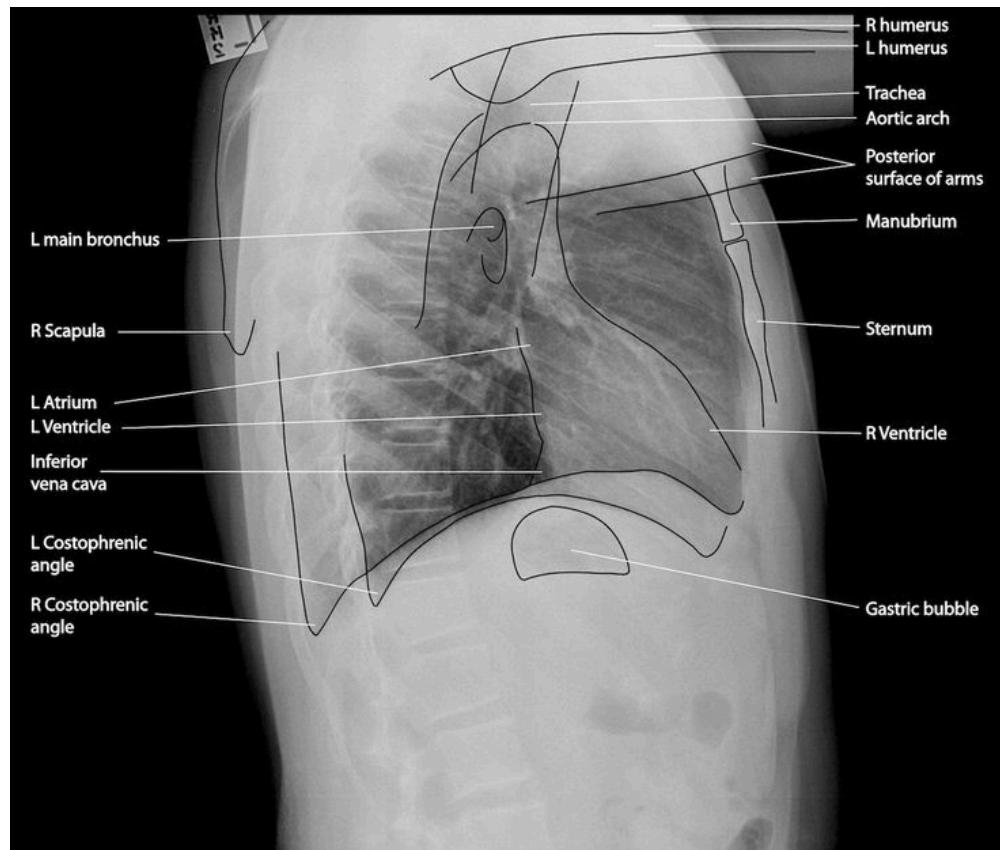


Figure 5.6B Line Drawing of Lateral Chest x-ray.

Attributions

Fig 5.3A Positioning for a PA Chest x-ray, by the Distance Education Unit, University of Saskatchewan, is published using a [CC-BY-NC-SA 4.0 International License](#).

Fig 5.3B Positioning for a Lateral Chest x-ray, by the Distance Education Unit, University of Saskatchewan, is published using a [CC-BY-NC-SA 4.0 International License](#).

Fig 5.4A A Numerical system for the PA Chest x-ray review by Dr. Brent Burbridge MD, FRCPC, University Medical Imaging Consultants, College of Medicine, University of Saskatchewan is used under a [CC-BY-NC-SA 4.0](#) license.

Fig 5.4B A Numerical system for the Lateral Chest x-ray review by Dr. Brent Burbridge MD, FRCPC, University Medical Imaging Consultants, College of Medicine, University of Saskatchewan is used under a [CC-BY-NC-SA 4.0](#) license.

Fig 5.5 Normal Portable Chest x-ray by Dr. Brent Burbridge MD, FRCPC, University Medical Imaging Consultants, College of Medicine, University of Saskatchewan is used under a [CC-BY-NC-SA 4.0 International License](#).

Fig 5.6A [Line Drawing of AP Chest x-ray](#) by Line drawings – #FOAMed Medical Education Resources by LITFL is licensed under a [CC-BY-NC-SA 4.0](#) License.

Fig 5.6B [Line Drawing of Lateral Chest x-ray](#) by Line drawings – #FOAMed Medical Education Resources by LITFL is licensed under a [CC-BY-NC-SA 4.0](#) International License.

Approach to the Abdominal x-ray (AXR)

An approach to reviewing an abdominal x-ray (AXR) will create a foundation that will facilitate the detection of abnormalities. You should create your own strategy. There is no correct way to analyze the images. Consistency and thoroughness are good general strategies. With time, and repetition, the process will become subconscious. Repetitive viewing of images will help establish a baseline of normality and normal variation that will represent an internal yard stick for the detection of variation from normal.

Assess image type and quality

Projection	Supine, Upright, Decubitus, Other
Rotation	The spinous processes of the vertebrae should be equidistant between the pedicles
Exposure	The bones of the spine should be discernible

Anatomic Coverage

Ensure the whole abdomen is visible from the hemidiaphragms to pubic symphysis (may need multiple views to accomplish this). The lateral abdominal walls should be included.

Quadrants or Regions:

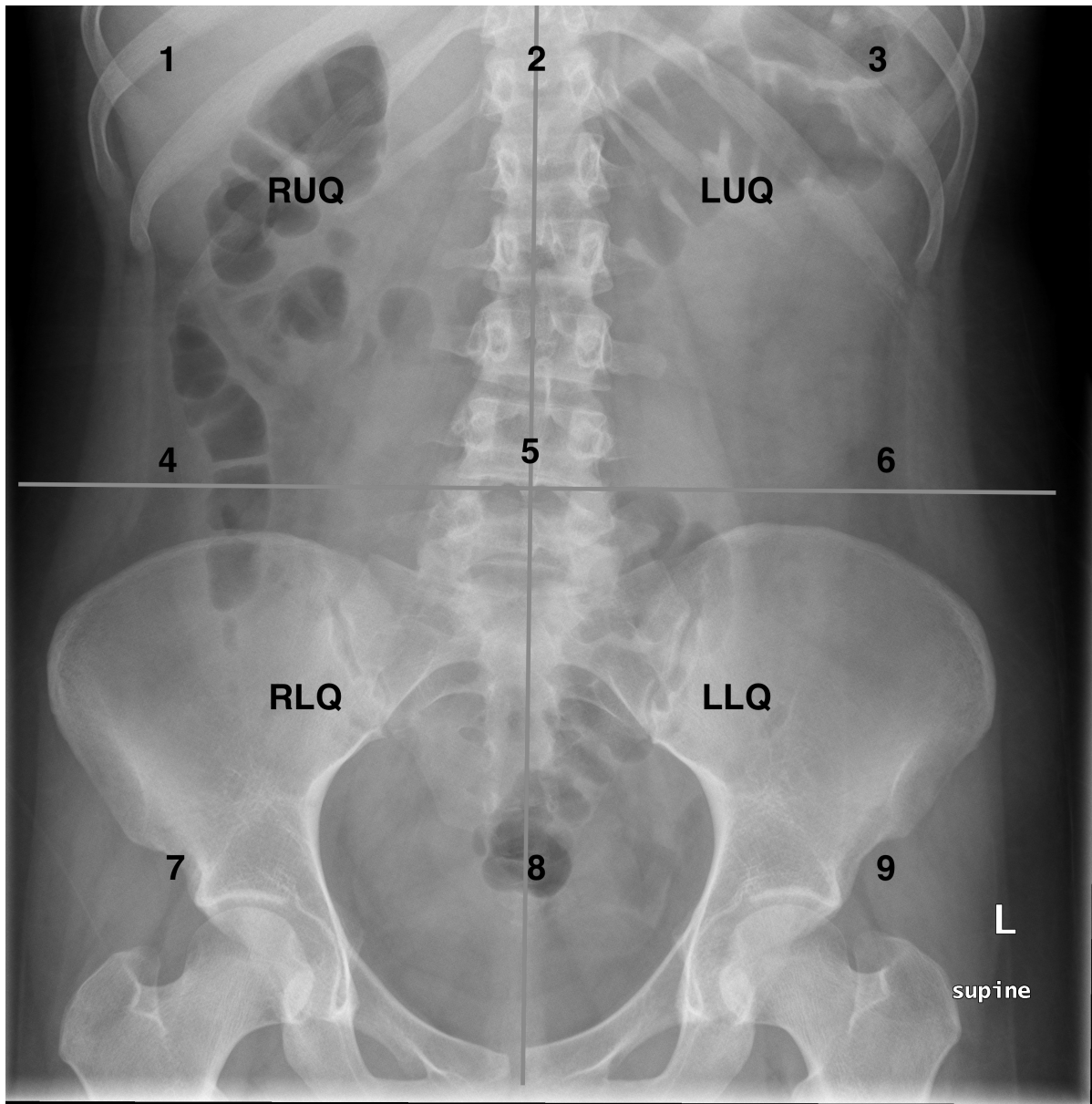


Figure 5.7 Abdomen Quadrants/Regions

The abdomen can be subdivided into four quadrants or nine regions (*see above*).

1	2	3
Right Hypochondrium	Epigastrium	Left Hypochondrium
4	5	6
Right Lumbar	Umbilical	Left Lumbar
7	8	9
Right Iliac	Suprapubic	Left Iliac

It is best to perform a census of at least the four quadrants of the abdomen to assess for abnormalities. If something unusual is detected a description of the abnormality will be more accurate if a description of the zone it occupies is provided.

Abdomen X-ray Image Acquisition Positioning:

Supine:

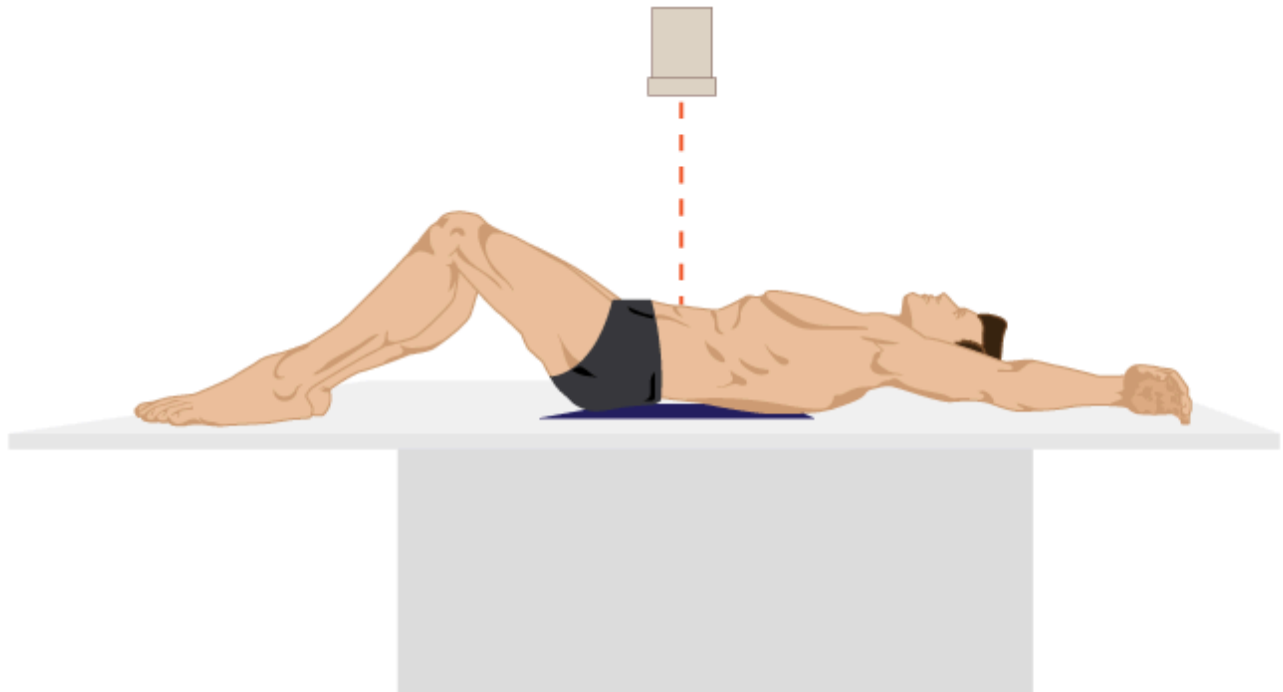


Figure 5.8 Supine Positioning for Abdomen x-ray.

The patient lies on their back and the x-ray beam enters anteriorly. There will be no discernible air-fluid levels in the intestine on this view.

Upright:

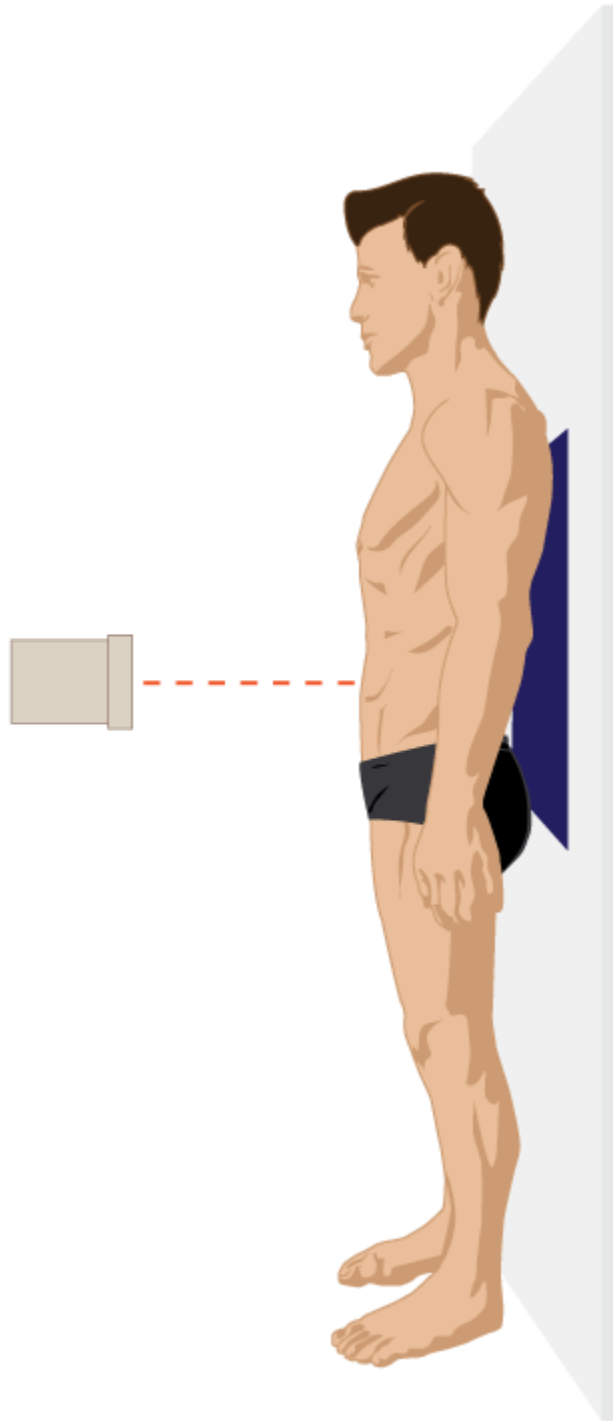


Figure 5.9 Upright Positioning for Abdomen x-ray.

The table is oriented in a vertical orientation and the x-ray beam enters from the anterior abdomen. This image optimally visualizes air-fluid levels and free, intraperitoneal gas.

Decubitus:

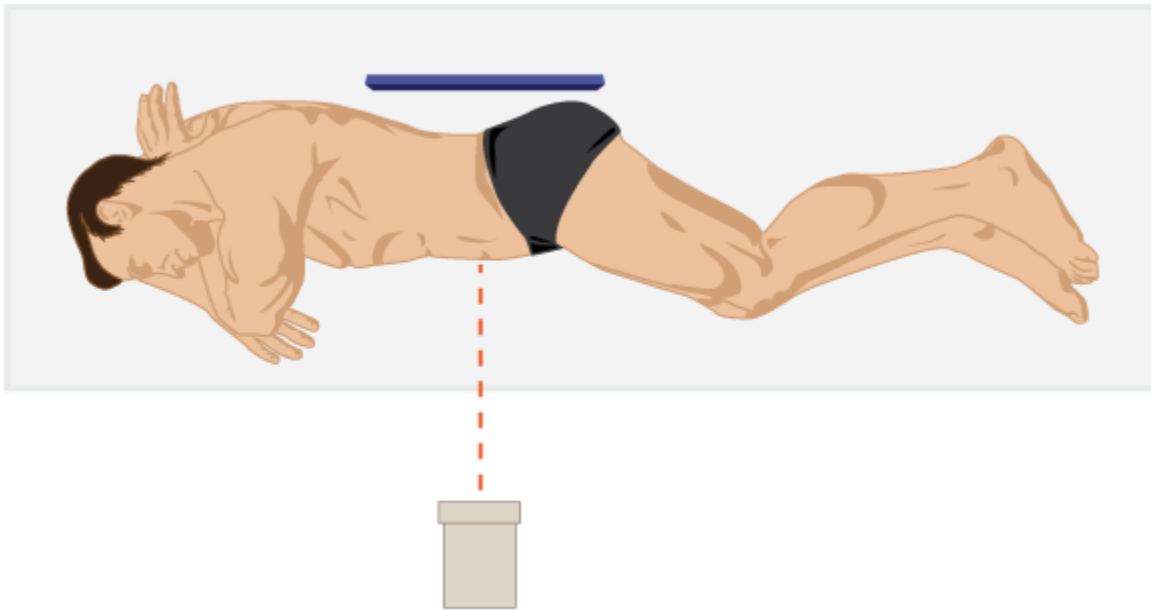


Figure 5.10 Decubitus Positioning for Abdomen x-ray

The patient lies with their side down to the table and the x-ray beam enters anteriorly. Time should be allocated to allow for any gas to rise to the non-dependent region of the abdomen. This is a view commonly used to detect free, intraperitoneal, gas.

Abdominal X-ray Review

The abdominal x-rays variably demonstrate anatomic features i.e. sometimes entities are seen and other times they are not. The conspicuity of an anatomic structure depends upon whether it contains gas or is surrounded by fat. Therefore, intestine not filled with gas that does not have fat at its margins, will not be seen on x-ray.

BBC approach:

- Bowel & other organs
- Bones
- Calcification & artifact

Bowel & other Organs: Stomach, small and large bowel

The stomach is in the left upper quadrant and usually has gas within it. An air-fluid level can be seen in the stomach on the upright and decubitus views.

Differentiating between the small and large bowel on an AXR is not always straightforward but there are a number of clues to help.

The **small bowel** usually lies more centrally, with the large bowel framing it around the periphery. The small bowel's mucosal folds are called valvulae conniventes and are usually seen across the full width of the bowel.

The **large bowel** wall features pouches or sacculations call *haustra (pl)*, *haustrum (sing)*. Between the haustra are bridges of soft tissue that project into the colonic lumen, known as the plicae semilunares coli. The fold pattern created by the plicae are thicker than the valvulae conniventes of the small bowel and usually do not completely traverse the lumen of the colon.

Feces has a mottled appearance and are most often seen in the colon, due to trapped gas within solid feces.

There is considerable normal variation in the distribution of bowel gas and fecal material.

The upper limit of normal diameter of the intestines on an AXR do not usually exceed:

3 cm	Small bowel
6 cm	Colon, except for Cecum
9 cm	Cecum

This is often referred to as the '3/6/9 rule'

Figure 5.11 depicts a normal Abdominal x-ray, the colon and stomach seen well.

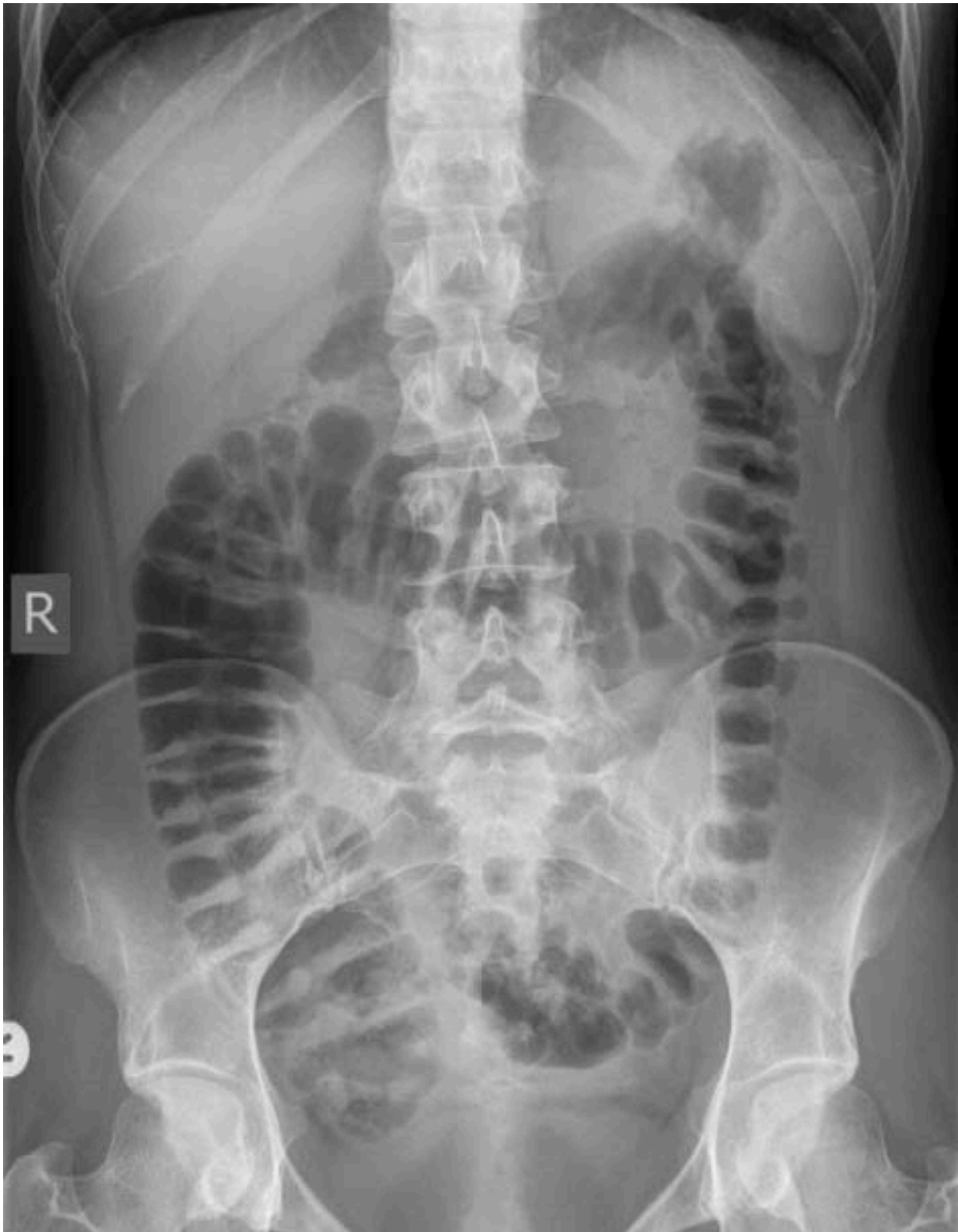

Figure 5.11 Normal Abdominal x-ray.

The colon, with barium and air to highlight the anatomic distribution, of this structure is seen in *Figure 5.12*.

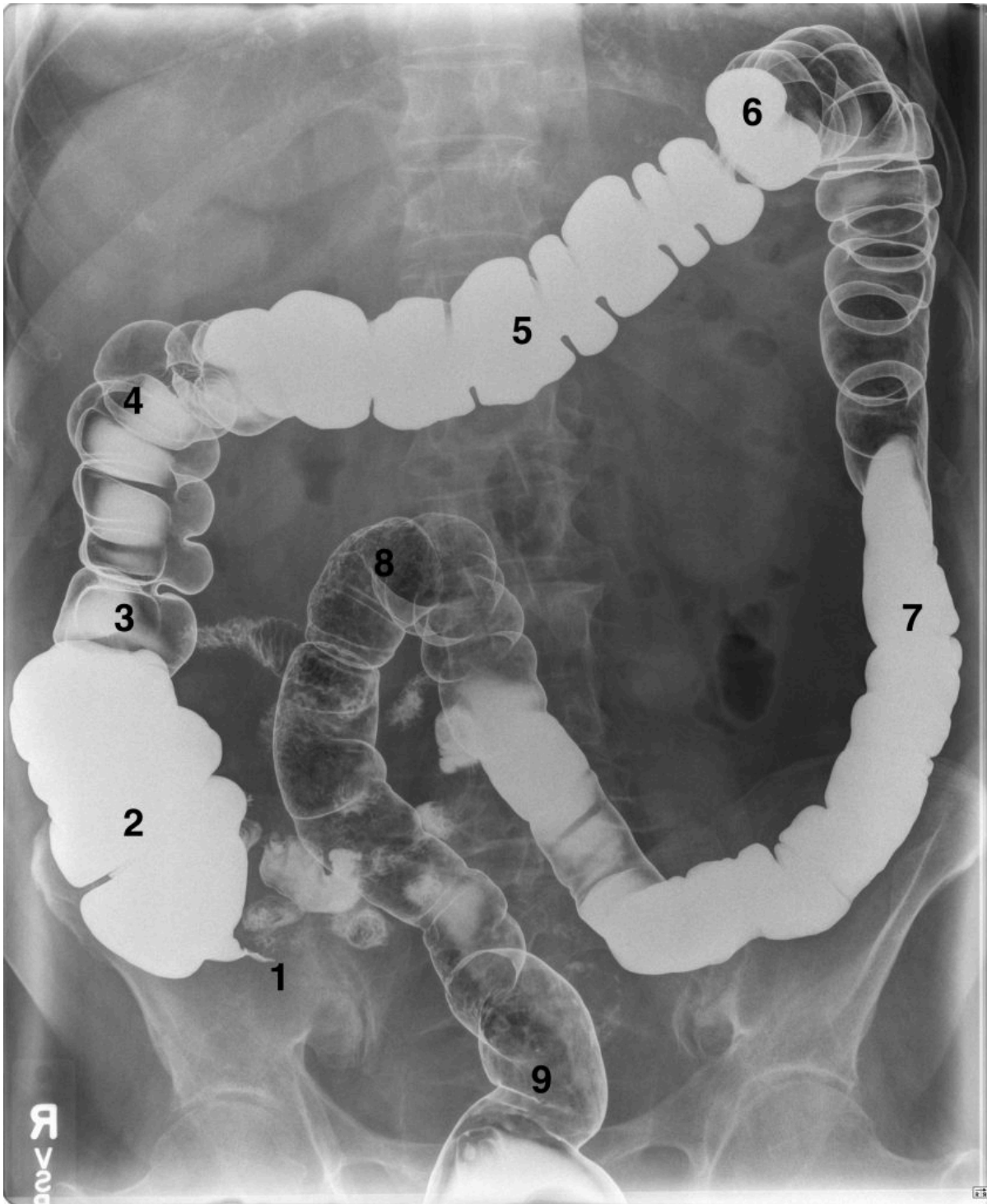


Figure 5.12 Colon anatomy emphasized by the distribution of barium and gas in the colon.

1	Appendix	6	Splenic flexure
2	Cecum	7	Descending colon
3	Ascending colon	8	Sigmoid colon
4	Hepatic flexure	9	Rectum
5	Transverse colon		

Note: Organ margins and psoas shadow details are not visible due the overlapping bowel gas.

Small bowel obstruction

Small bowel obstruction can be visualized on an AXR as dilatation of the small bowel (>3cm).

The valvulae conniventes are much more visible and have what is referred to as a “*coiled spring appearance*”.

The most common cause (75%) of small bowel obstruction is adhesions (related to previous abdominal surgery).

Large bowel obstruction

Large bowel obstruction is most often due to colorectal *carcinoma* and diverticular related *strictures*. Less common causes are hernias or a volvulus.

Other organs and structures

Although AXR isn’t well suited to imaging these structures in their entirety, or consistently on sequential images, they can be variably seen and may offer clues to possible pathology.

Lungs	Check the lung bases, if visible, for abnormalities (e.g. consolidation, pleural fluid), as abdominal pain can sometimes be caused by chest abnormalities (referred pain)
Liver	Large right upper quadrant (RUQ) structure
Gallbladder	Rarely seen. Look for calcified gallstones or cholecystectomy clips
Stomach	Left Upper Quadrant to midline structure. Often contains visible gas. Air-fluid level will change with the projection obtained i.e. not seen on AP, transverse on upright, longitudinal on decubitus.
Psoas muscles	The lateral margin is seen as an oblique, low density, line on either side of the vertebral column.
Kidneys	Often visible, right kidney lower than left
Spleen	Left Upper Quadrant (LUQ), superior to the kidney
Bladder	Variable appearance based upon the degree of fullness. It is outlined by a low density line of fat.

Bones/Musculoskeletal

Many bones are visible on an AXR and it’s important that you can identify each and screen for any pathology (which may be expected or unexpected). In addition, bones on the AXR provide useful landmarks for where you might expect to see a soft tissue structure (e.g. ischial spines are the usual level of the vesico-ureteric junction).

Bones commonly visible on AXR include:

- Ribs
- Thoracic and lumbar vertebrae
- Sacrum/coccyx

- Pelvis
- Proximal femurs

A wide range of bone pathologies can be identified on abdominal x-rays including fractures, osteoarthritis, Paget’s disease and bone metastases.

Image 5.13 demonstrates a variety of bone and musculoskeletal structures, not labelled and labelled:

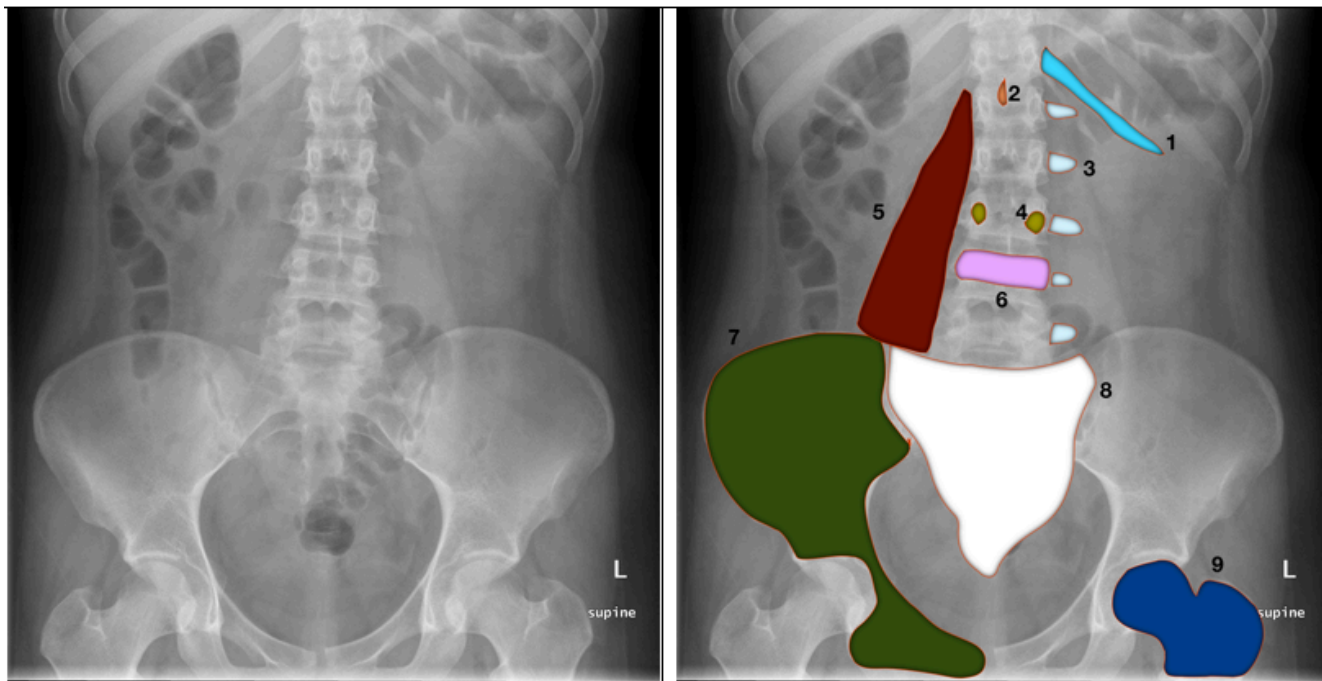


Figure 5.13 Bones and Musculoskeletal Landmarks in the Abdomen.

The margin of the right, lower liver is seen due to fat surrounding the tip of the right lobe. The fat-soft tissue interface also allows us to visualize the psoas muscle margins.

- | | |
|---|--|
| 1 | Left rib |
| 2 | Spinous process |
| 3 | Transverse process of a lumbar vertebrae |
| 4 | Pedicles of L3 vertebra |
| 5 | Right psoas muscle |
| 6 | L4 vertebral body |
| 7 | Right iliac/ischial/pubis bones |
| 8 | Sacrum |
| 9 | Left femoral head |

Calcification and Artifacts

Various high density (white) areas of calcification or artifacts may be seen

Examples include:

- Calcified gallstones in the RUQ
- Renal calculi
- Pancreatic calcification
- Vascular calcification
- Costochondral cartilage calcification
- Contrast (e.g. following barium administration)
- Surgical clips
- Metallic umbilical jewelry, artifact over the approximate location of the umbilicus

Figure 5.14 demonstrates a sample of some possible artifacts seen on abdominal x-rays:

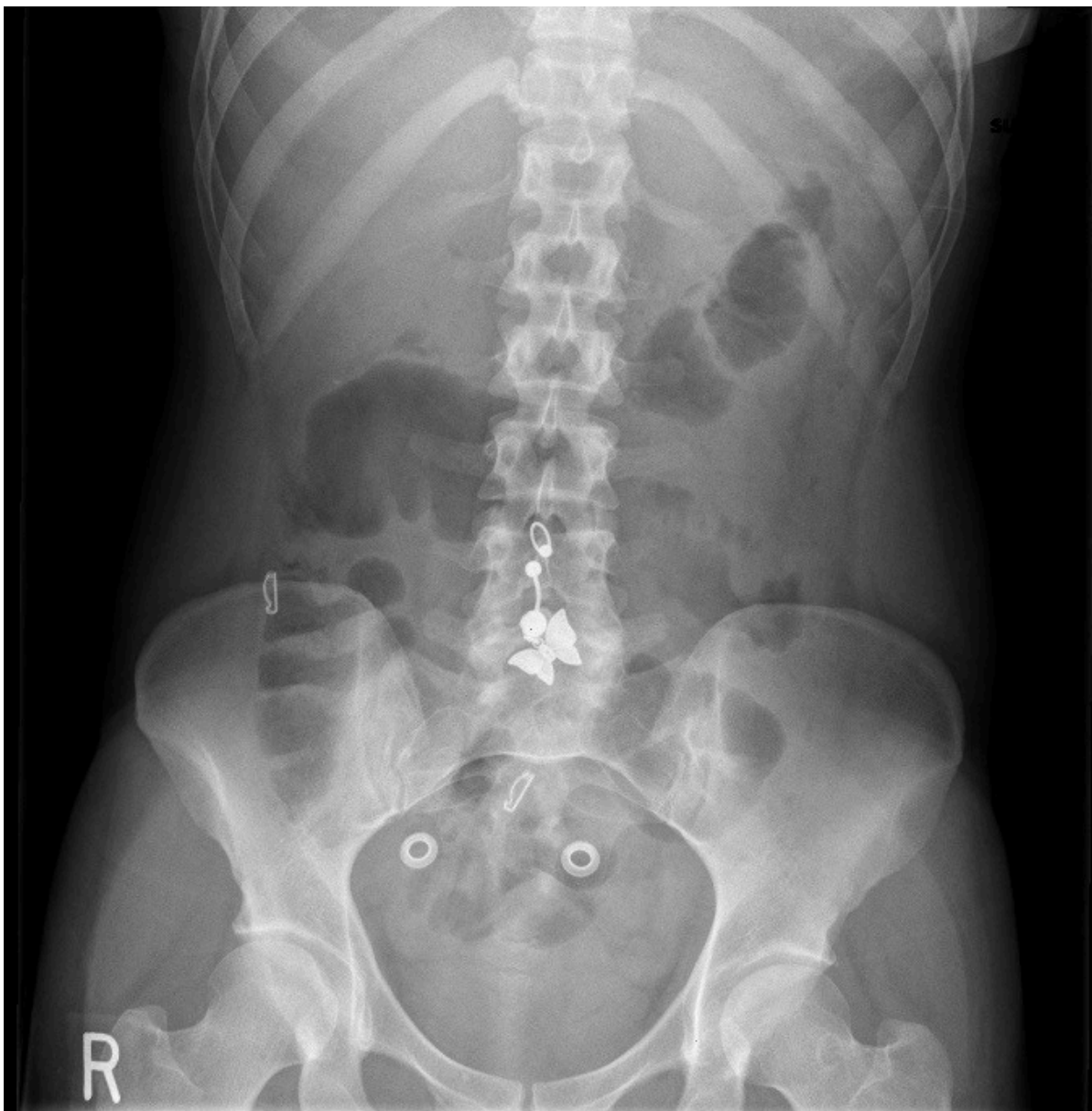


Figure 5.14 Artifacts on Abdomen x-ray. The image demonstrates two umbilical piercings, fallopian tube clips, and the buttons on the patient's pants.

Attributions

Fig 5.7 Abdomen Quadrants/Regions by Dr. Brent Burbridge MD, FRCPC, University Medical Imaging Consultants, College of Medicine, University of Saskatchewan is used under a [CC-BY-NC-SA 4.0](#) license.

Fig 5.8 Supine Positioning for Abdomen x-ray, by the Distance Education Unit, University of Saskatchewan, is published using a [CC-BY-NC-SA 4.0 International License](#).

Fig 5.9 Upright Positioning for Abdomen x-ray, by the Distance Education Unit, University of Saskatchewan, is published using a [CC-BY-NC-SA 4.0 International License](#).

Fig 5.10 Decubitus Positioning for Abdomen x-ray, by the Distance Education Unit, University of Saskatchewan, is published using a [CC-BY-NC-SA 4.0 International License](#).

Fig 5.11 Normal Abdominal x-ray by Dr. Brent Burbridge MD, FRCPC, University Medical Imaging Consultants, College of Medicine, University of Saskatchewan is used under a [CC-BY-NC-SA 4.0](#) license.

Fig 5.12 Colon anatomy emphasized by the presence of barium and air by Dr. Brent Burbridge MD, FRCPC, University Medical Imaging Consultants, College of Medicine, University of Saskatchewan is used under a [CC-BY-NC-SA 4.0](#) license.

Fig 5.13 Bones and Musculoskeletal Landmarks in the Abdomen by Dr. Brent Burbridge MD, FRCPC, University Medical Imaging Consultants, College of Medicine, University of Saskatchewan is used under a [CC-BY-NC-SA 4.0](#) license.

Fig 5.14 Possible Artifacts on Abdomen x-rays. The image demonstrates two umbilical piercings, fallopian tube clips, and the buttons on the patient's pants by Dr. Brent Burbridge MD, FRCPC, University Medical Imaging Consultants, College of Medicine, University of Saskatchewan is used under a [CC-BY-NC-SA 4.0](#) license.

Approach to Bone and Joint x-rays

Image Acquisition:

Optimal image exposure should allow you to see the cortex of the bone distinctly and differentiate between cortex and medulla without difficulty.

The standard views are AP (anterior-posterior) and lateral. These two views are taken at right angles (orthogonal) to each other. If these images are not helpful, ancillary views such as oblique views, or special views such as, an axillary or carpal tunnel view, may be required based upon the clinical scenario.

Stress views i.e. a force is applied to a bone or joint to determine if an injury is present, such as, a subtle avulsion or a suspected tendon or ligament tear causing joint instability. These are acquired as special requests and should be performed in a manner that minimizes patient pain and discomfort.

At least one joint space should be visible in relation to the suspected bone injury. Additional x-ray views and views of another adjacent joint space may be required in some circumstances.

Comparison views to the contralateral, normal bone, or joint, may be required, this is especially true if a subtle growth plate injury is suspected in a child. Comparison views should not be ordered routinely, but should be used if clinically necessary.

It is important to remember that some bone and ligament injuries occur as a common pattern of multiple injuries i.e. the Colle fracture of the distal radius is often associated with an avulsion fracture of the ulnar styloid. Ankle ligament injuries and fractures often occur in a sequence i.e. medial malleolar avulsion fracture (or medial ligament tear), interosseous ligament tear between the tibia and fibula, and a subsequent oblique fracture of the proximal fibula (Maisonneuve fracture complex). Keep this in mind as you encounter various patients and you will develop knowledge and experience of these associated bone and soft tissue injuries.

Fractures usually present as a lucent line on x-rays involving the cortex and medulla of the bone that can be followed from one cortex to the opposite cortex with varying degrees of displacement and malalignment of the involved bone.

There are some fractures that may be associated with bone ischemia and avascular necrosis i.e. capital femoral

fractures and scaphoid fractures. Be aware of this and learn the importance of aggressive and pre-emptive management for these patients.

Anatomic Locations in Bone

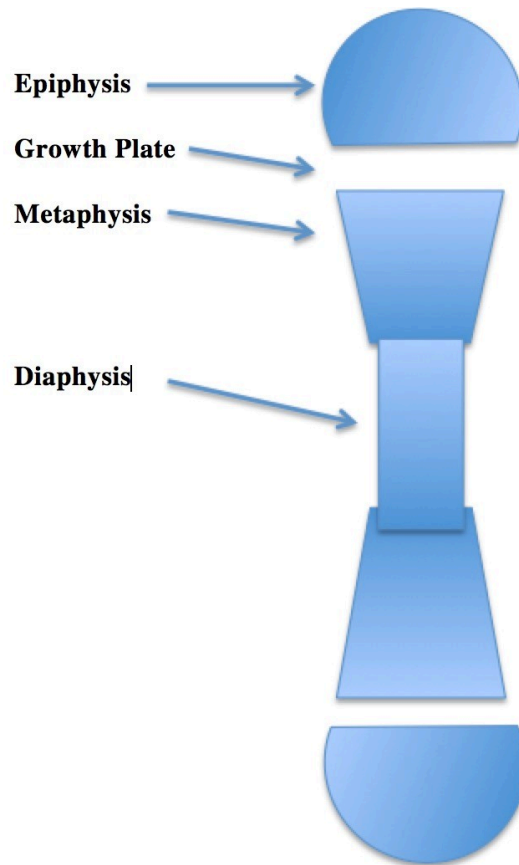


Figure 5.15 Anatomic Locations in Bone.

Diaphysis	Middle of the bone
Metaphysis	Flared region of the bone, between the epiphysis and the diaphysis
Epiphysis	The end of the bone, usually this area is associated with actively growing bone at the epiphyseal plate in children
Intra-articular	The joint space

Complete Fracture:

Fracture line completely traverses the bone effecting the cortex and medulla.

Transverse	Across the long axis of the bone i.e. 90 degrees to the long axis of the bone
Oblique	Passes across the bone with an angle of less than 90 degrees
Spiral	Passes around the bone in a cork screw path
Longitudinal	Fracture is oriented parallel to the long axis of the bone
T-Shaped	There are two fractures, a longitudinal portion and a transverse or oblique portion
Comminuted	More than two bone fragments

Table 5.2 Types of complete bone fractures

Incomplete Fracture:

The fracture does not complete traverse the bone.

Bowing	The bone is bent but not fractured
Buckle	One cortex is bucked outward, the buckle is like a fold The opposite cortex may be fractured or may be intact
Greenstick	One cortex is compressed into denser bone while the contralateral cortex is fractured
Salter-Harris	This classification describes the various epiphyseal and metaphyseal findings to describe the degree of damage to the actively developing growth plate

Table 5.3 Types of Incomplete Bone Fractures

Salter-Harris

Some fractures in children involve the growth plate and the adjacent metaphysis of the bone. These fractures have been categorized using the Salter-Harris classification.

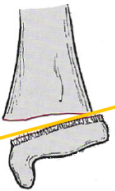
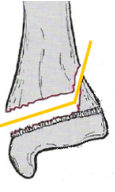
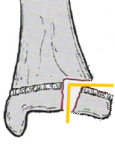
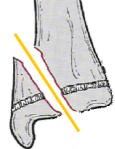
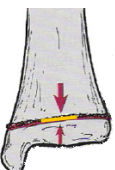
Type	Description	Image
I	<p>The fracture plane extends completely through the growth plate. This type of fracture can be minimally displaced, making detection challenging. Repeated x-rays in 7 days will demonstrate periosteal new bone if a subtle fracture is suspected.</p> <p>5 – 7% frequency.</p> <p>Good prognosis.</p>	
II	<p>The fracture plane leaves a small, triangular or quadrangular portion of the metaphysis in contact with the growth plate. This is the most common type of Salter-Harris injury.</p> <p>75% frequency.</p> <p>Good prognosis.</p>	
III	<p>A quadrangular fragment of the epiphysis is isolated from the adjacent bone.</p> <p>7 – 10% frequency.</p> <p>Poorer prognosis.</p>	
IV	<p>A triangular fragment of epiphysis, growth plate, and metaphysis is separated from the adjacent bone.</p> <p>10% frequency.</p> <p>Poorer prognosis.</p>	
V	<p>This injury is focal and results in delayed abnormal bone growth in a focal region of the bone due crushing type of damage to the growing bone.</p> <p>1% frequency.</p> <p>Worst prognosis</p>	

Table 5.4 Classification of Salter-Harris Fractures

Displacement

Describe based upon the location and orientation of the distal bone fragment.

Distracted	The bone ends are quite displaced away from each other
Impacted	The bone ends are collapsed into each other
Angulated	There is an angle that can be described. The angle can be measured and describe based upon the apex of the angle seen. Some also describe the angle based upon the normal angulation of the bone in the region and whether this has been altered i.e. the bone is varus or valgus in comparison to the normal
Translational	The distal fragment is shifted away from normal
Rotational	The distal fragment is spun out of normal alignment
Pathologic	The bone at the fracture site is abnormal due to infection, congenital bone abnormality, a metabolic bone abnormality, or malignancy. Fractures that are the result of these conditions are pathologic
Avulsion	A small fragment of bone (triangular, quadrangular) is pulled off of the parent bone by a ligament or tendon. The ligament is usually intact as the bone was the greatest point of weakness that gave way
Stress Fractures	Repetitive, low-grade injury to a bone can lead to stress fracture. Frequent sites are the ventral tibial cortex and the metatarsals but they can occur elsewhere. These are most often seen in young active patients who complain of chronic, focal, bone pain

Table 5.5 Types of bone displacements

Descriptors of Displacement
















				
Transverse	Oblique	Spiral	Longitudinal	T-Shaped
				
Comminuted	Bowed	Cortical Buckle	Greenstick	Distracted
				
Impacted	Angulated	Translational	Rotational	Intra-articular

Figure 5.16 Illustrations of Displacement.

Additional Descriptors

Subluxation	Joint alignment is disrupted but the cartilaginous ends of the bones at the joint space are still in contact with each other
Dislocation	The bones have been displaced and the cartilaginous ends of the bones no longer are in proximity to each other
Open Fracture	There is a discontinuity of the skin and underlying soft tissues that allows air to be in contact with the bone and/or the joint space. This type of injury increases the risk for infections such as, septic arthritis and osteomyelitis. There may be an underlying fracture or dislocation, but this is not always the case

Intra-articular, Salter-Harris, and open fractures require enhanced treatment and close clinical follow-up to minimize the possibility of undetected abnormal healing, or infection, that can lead to heightened morbidity or mortality.

Joint, Arthritic Conditions

The two most common arthritic conditions encountered are degenerative (osteoarthritis) and inflammatory (rheumatoid) arthritis. The radiographic appearance of these arthritides will vary based upon severity and distribution. The longer the condition has been present the worse the imaging changes will usually be unless treatment has been instituted. There are a variety of arthritic conditions that can be encountered. Using laboratory assessment, clinical parameters, and imaging features often one can shorten the differential diagnostic possibilities. Osteoarthritis is usually quite distinct from erosive arthritides, i.e. rheumatoid, gout, calcium pyrophosphate, psoriatic, etc. It is beyond the scope of this work to discuss the imaging features of all of the various possible arthritides. The two most common arthritides encountered will be compared using the ABCDS method detailed below.

ABCDS method is one way to approach bone and joint arthritis.

A- Alignment of bones

B- Bones – bone mineralization, new bone formation, erosions, osteophytes, fractures

C- Cartilage – joint space alignment and narrowing, joint calcifications, effusions

D- Distribution of disease – Some distribution of bone involvement is characteristic for certain diseases i.e. hip and knee osteoarthritis, first metatarsal-phalangeal gout, interphalangeal joint rheumatoid arthritis, etc.

S- Soft tissues – swelling and calcifications

Osteoarthritis

Bone alignment is usually normal until the degenerative changes become severe. The bone density is usually within normal limits unless the patient becomes sedentary due to severe joint pain. Erosions of the bone are uncommon in osteoarthritis for the most part, but subchondral cysts can be seen in the joint space. They are not true erosions. The hallmarks of osteoarthritis are joint space narrowing, sub-chondral bone sclerosis, and osteophyte formation. The arthritic changes are asymmetric in the joint and with the contralateral body part. The soft tissues are not usually effected unless the patient develops a joint effusion. Joint crepitations may be felt with range of motion but the joints are not usually red or warm.

Erosive Arthritis (Rheumatoid)

Bone malalignment can be minimal to severe based upon severity of the arthritis. Some deformities of joints i.e. swan neck and hitch hiker thumb deformities are characteristic of rheumatoid arthritis. Often the visible joint deformity is quite noticeable with rheumatoid arthritis as the disease progresses. The bone density is usually diminished with rheumatoid arthritis, this is most noticeable in the peri-articular bone which is preferentially reduced in density. Rheumatoid arthritis is characteristically very symmetrical in distribution. There is joint space

narrowing and peri-articular erosions with the arthritis. Often, the erosions are subtle and small. The hands are often involved early and erosions can be seen in the PIP and MCP joints. Rheumatoid arthritis often effects a wide variety of joints that are not weight bearing and it can involve almost any joint in the body including the acromio-clavicular, gleno-humeral, elbow, and upper cervical spine joints. The soft tissues are often swollen, red, and may feel warm to touch. Effusions may also be palpable.

Attributions

Figure 5.15 Anatomic Locations in Bone by Dr. Brent Burbridge MD, FRCPC, University Medical Imaging Consultants, College of Medicine, University of Saskatchewan is used under a [CC-BY-NC-SA 4.0](#) license.

Figure 5.16 Illustrations of Displacement by Dr. Brent Burbridge MD, FRCPC, University Medical Imaging Consultants, College of Medicine, University of Saskatchewan is used under a [CC-BY-NC-SA 4.0](#) license.

Chapter 6 – Brain and Spine

Intracranial Hemorrhage – Traumatic

ACR – Neurologic – Head Trauma

Case 1

Subdural Hematoma (SDH)

Clinical:

History – This elderly male was more confused than normal and had a more unstable gait since a fall 7 days prior to visiting the ER. The patient was on Plavix related to a previous ischemic stroke.

Symptoms – Confusion and weakness.

Physical – The patient was unaware of his location and the date. He had great difficulty standing without the support of his caregivers. He could not walk.

DDx:

Brain ischemia

Brain tumor

Subdural hematoma

Imaging Recommendation

[ACR – Minor, Acute, Closed, Head Injury, Variant 2.](#)

CT of the Head without IV contrast

ODIN Link for Subdural Hematoma images, Figure 6.1A and B: <https://mistr.usask.ca/>

<odin/?caseID=20150421142940341>

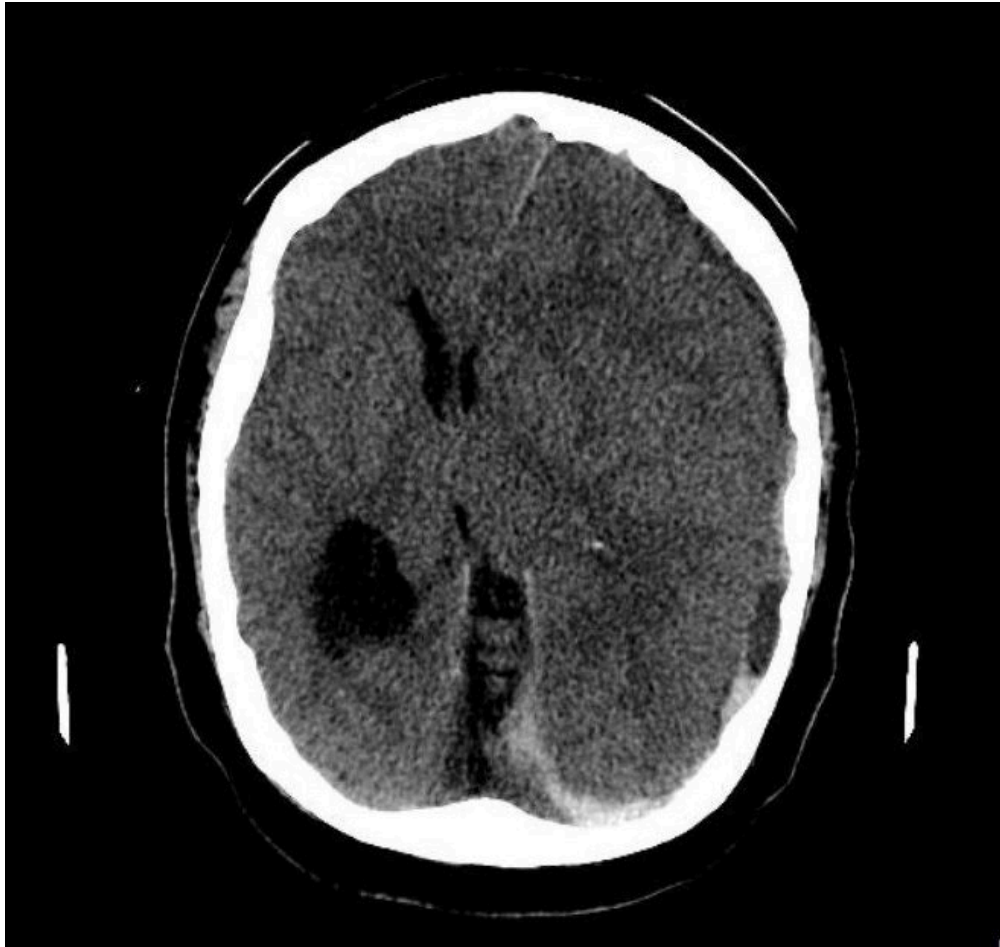

Figure 6.1A Axial CT of Brain at the level of the septum pellucidum.

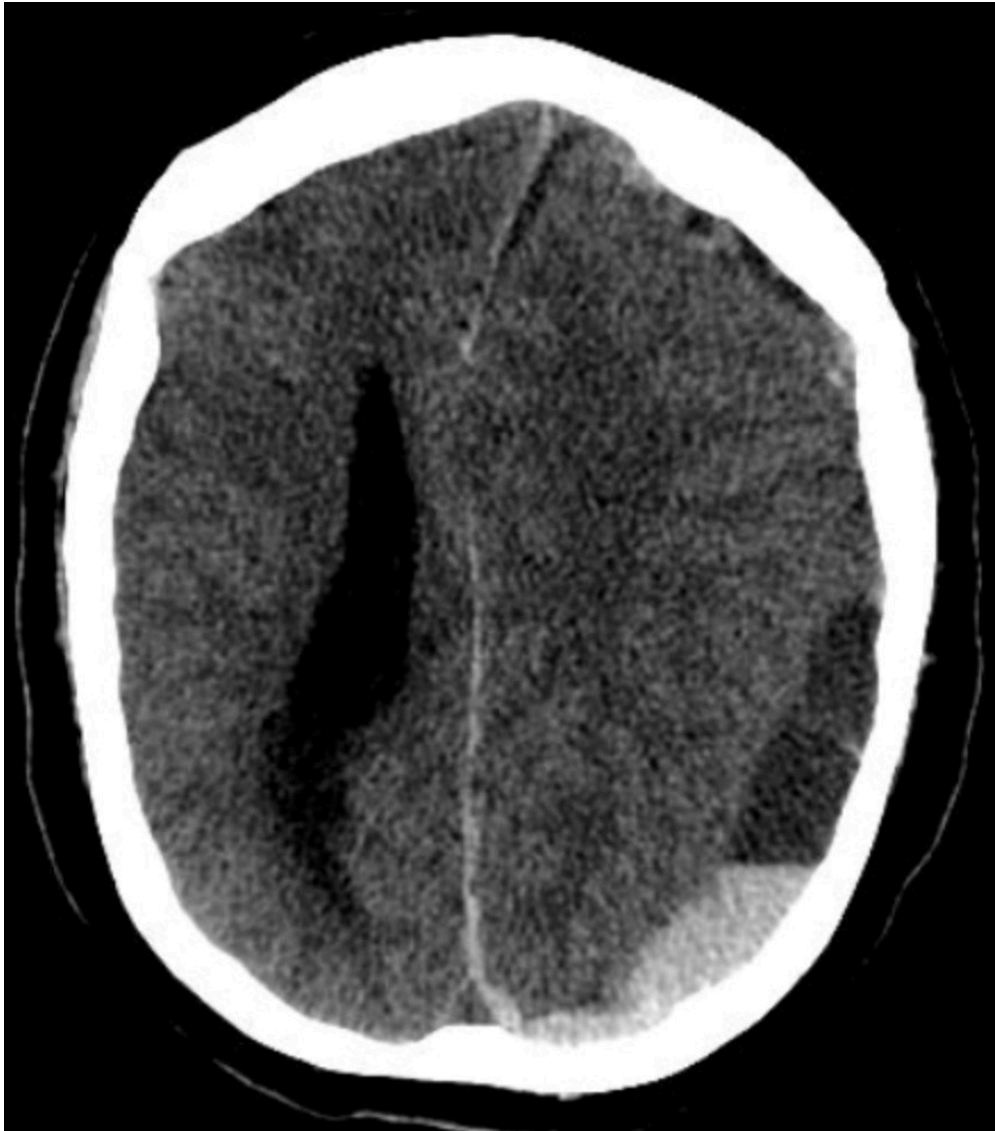

Figure 6.1B Axial CT of Brain more caudally situated compared to Figure 6.1A.

Imaging Assessment

Findings:

There was significant shift of the midline structures to the right. The patient had a mixed density fluid collection in the left subdural space that had regions of water density and regions of higher density within it. There was a layering effect with the brighter fluid posteriorly situated. No large territory infarcts. There was subfalcine herniation of the frontal lobe on the left. No fractures identified.

Interpretation:

Subacute, Subdural Hematoma, Left

Diagnosis:

Subacute, Subdural Hematoma, Left (7 days)

Discussion:

- Subdural hematomas are more common than epidural hematomas and are usually not associated with a skull fracture. They are most commonly a result of deceleration injuries in motor vehicle or motorcycle accidents (younger patients) or secondary to falls (older patients).
- Subdural hematomas are usually produced by damage to the bridging veins that cross from the cerebral cortex to the venous sinuses of the brain. They represent hemorrhage into the potential space between the dura mater and the arachnoid.
- Subdural hematomas usually develop over a longer time period and symptoms and signs may develop slowly.
- An acute subdural hematoma frequently suggests the presence of more severe parenchymal brain injury, with increased intracranial pressure, and the acute subdural may be associated with higher morbidity and mortality.

Imaging findings may include:

- On CT, acute subdural hematomas are crescent-shaped, extra-cerebral bands of high attenuation that may cross suture lines and enter the interhemispheric fissure. They do not cross the midline.
- Typically, a SDH is concave on the inward side towards the brain (epidural hematomas are convex on the inward side).
- As time passes and they become subacute, or if the subdural blood is mixed with lower-attenuating CSF, they may appear isointense (isodense) to the remainder of brain, in which case you should look for compressed or absent sulci or sulci displaced away from the inner table as signs of SDH. For subtle, isodense subdural hematomas, the addition of intravenous contrast for the CT scan may help to enhance the brain gray matter creating a more discernible difference between the gray matter and the non-enhancing subdural hematoma.
- Subdural collections may demonstrate a fluid-fluid level after 1 week, as the cellular matter in the blood settles under the serum.

Case 2

Epidural Hematoma

Clinical:

History – This young male was in a motorcycle accident. He was not wearing a helmet and collided with a parked car at low speed.

Symptoms – He had minor bruising over his right frontal-temporal region. Initially, the patient was able to talk and understood his situation. However, over the next hour he progressed to being obtunded.

Physical – Swelling overlying the right frontal-temporal region. Glasgow coma scale 8. He was non-responsive to verbal commands.

DDx:

Subdural hematoma

Subarachnoid hemorrhage

Brain parenchymal contusion

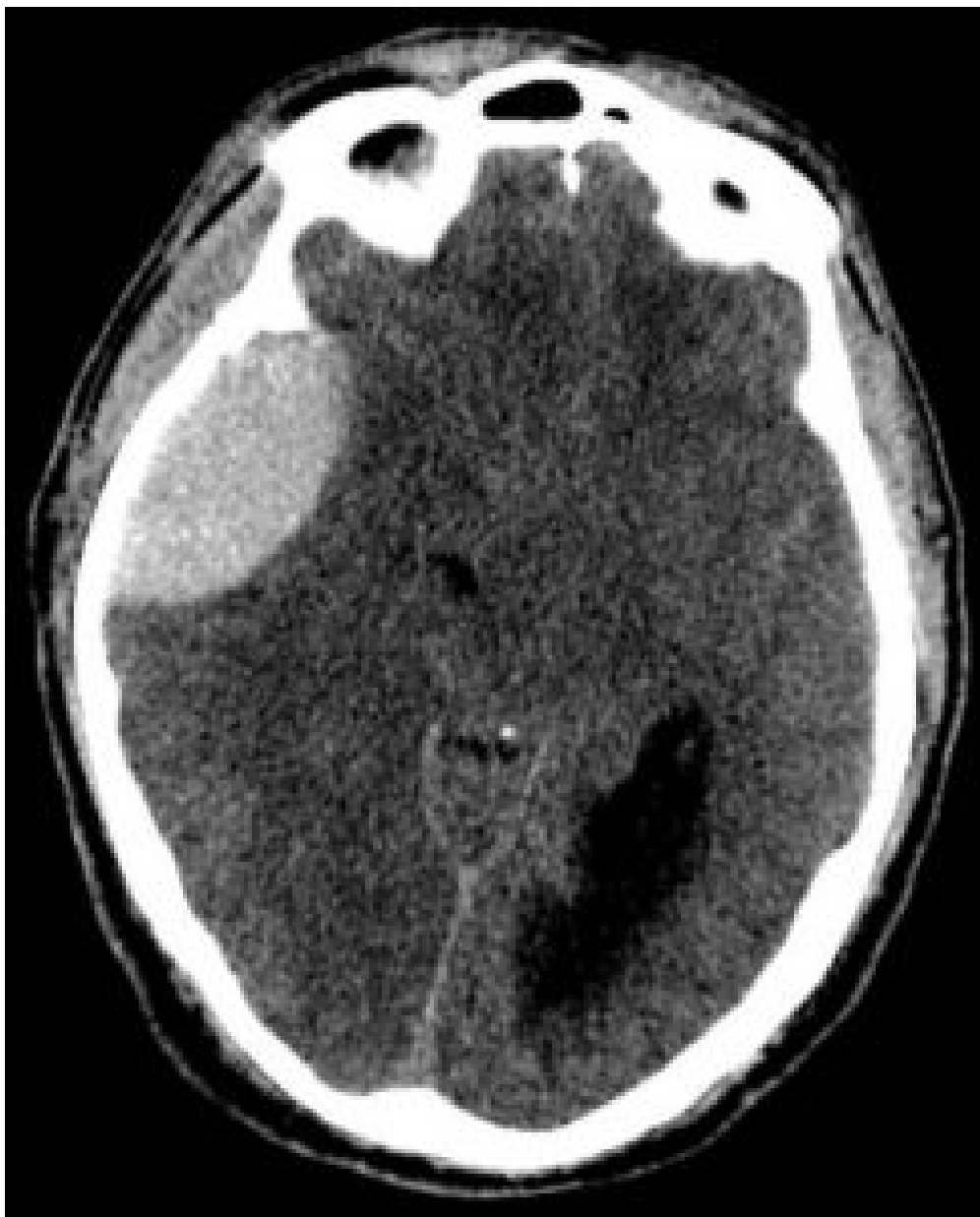Epidural hematoma

Imaging Recommendation

[ACR, Moderate to Severe, Acute, Head Injury, Variant 3](#)

CT Head without IV contrast

ODIN Link for Epidural Hematoma images, Figure 6.2A and B: <https://mistr.usask.ca/odin/?caseID=20170308092218066>



6.2A Axial CT of Head displaying epidural hematoma.

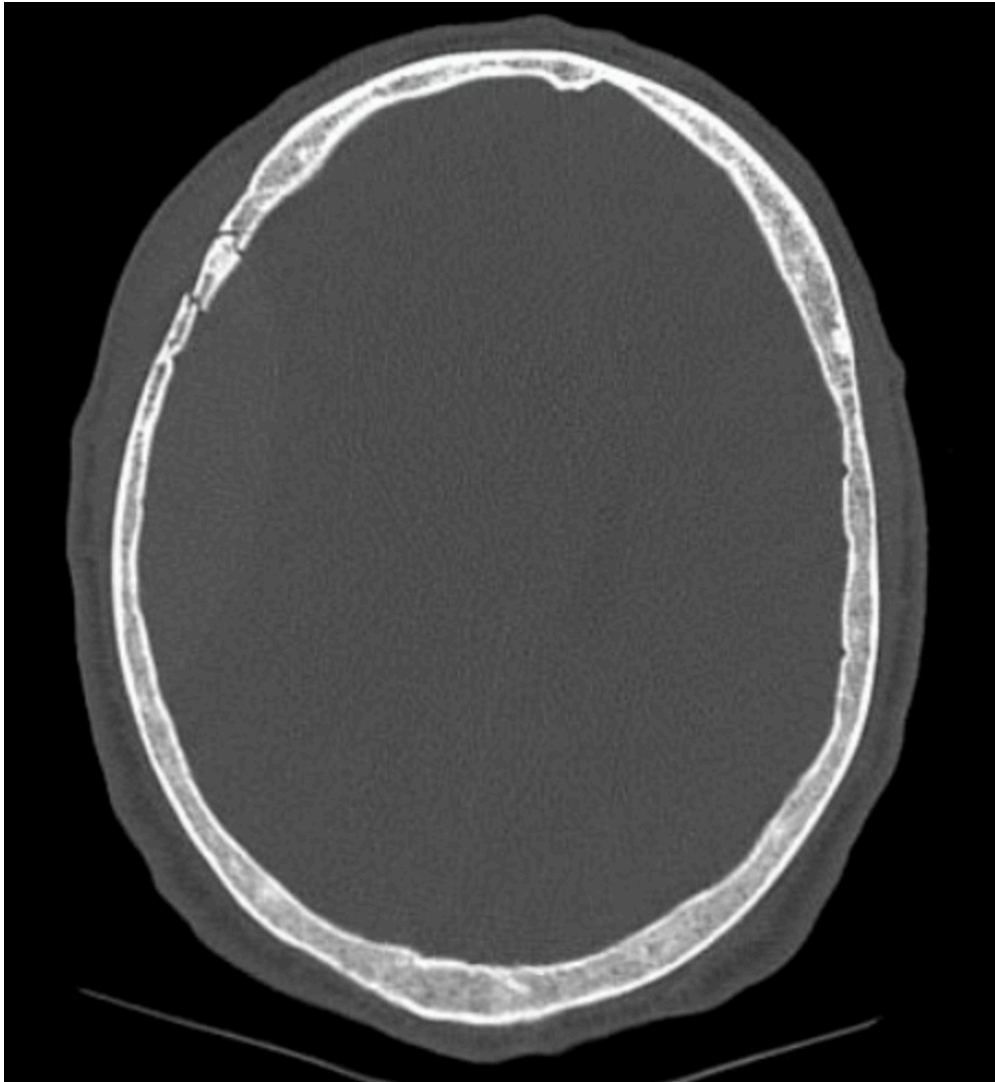


Figure 6.2B Axial CT of Head displaying epidural hematoma

Imaging Assessment

Findings:

There was minor soft tissue swelling overlying the right temporo-parietal region. A temporo-parietal fracture was seen in the right skull. There was a large, lenticular shaped, hyperdense, collection overlying the intracranial right temporal region. There was several areas of hyperdense foci in the deep right brain parenchyma. Severe subfal-cine and moderate transtentorial herniation was seen.

Interpretation:

Epidural hematoma with brain parenchymal contusions.

Diagnosis:

Epidural hematoma with brain parenchymal contusions.

Discussion

- Epidural hematomas represent hemorrhage into the potential space between the dura mater and the inner table of the skull.
- Most cases are caused by injury to the middle meningeal artery or vein from blunt head trauma, typically from a motor vehicle accident.
- Almost all epidural hematomas (95%) have an associated skull fracture, frequently the temporal bone. This fracture injures the middle meningeal artery or vein.
- Epidural hematomas may also be caused by disruption of the dural venous sinuses adjacent to a skull fracture.
- Since the dura is normally fused to the calvarium at the margins of the sutures, it is impossible for an epidural hematoma to cross suture lines (subdural hematomas can cross sutures).
- Epidural hematomas can cross the tentorium (subdural hematomas do not).

Imaging findings may include:

- A high density, extra-axial, biconvex, lens-shaped mass, most often found in the temporo-parietal region.
- There is often an underlying skull fracture, it may traverse the groove in the skull for the middle meningeal artery.

Attributions

Figure 6.1A Axial CT of Brain at the level of the septum pellucidum by Dr. Brent Burbridge MD, FRCPC, University Medical Imaging Consultants, College of Medicine, University of Saskatchewan is used under a [CC-BY-NC-SA 4.0](#) license.

Figure 6.1B Axial CT of Brain more caudal compared to Figure 6.1A by Dr. Brent Burbridge MD, FRCPC, University Medical Imaging Consultants, College of Medicine, University of Saskatchewan is used under a [CC-BY-NC-SA 4.0](#) license.

Figure 6.2A Axial CT of Head displaying epidural hematoma by Dr. Brent Burbridge MD, FRCPC, University Medical Imaging Consultants, College of Medicine, University of Saskatchewan is used under a [CC-BY-NC-SA 4.0](#) license.

Figure 6.2B Axial CT of Head displaying epidural hematoma by Dr. Brent Burbridge MD, FRCPC, University Medical Imaging Consultants, College of Medicine, University of Saskatchewan is used under a [CC-BY-NC-SA 4.0](#) license.

Ischemic Stroke

ACR – Neurologic – Cerebrovascular Disease

Case
Ischemic Stroke

Clinical:

History – This patient had right sided weakness for 5 hours.

Symptoms – Right sided weakness.

Physical – Hemiparesis on the right. Diminished right reflexes.

DDx:

Stroke

Transient Ischemic Attack (TIA)

Imaging Recommendation

[ACR – Cerebrovascular Disease, Variant 3](#)

CT Head without IV contrast

ODIN Link for Ischemic Stroke images, Figure 6.3A and B: <https://mistr.usask.ca/odin/?caseID=20170424151720945>

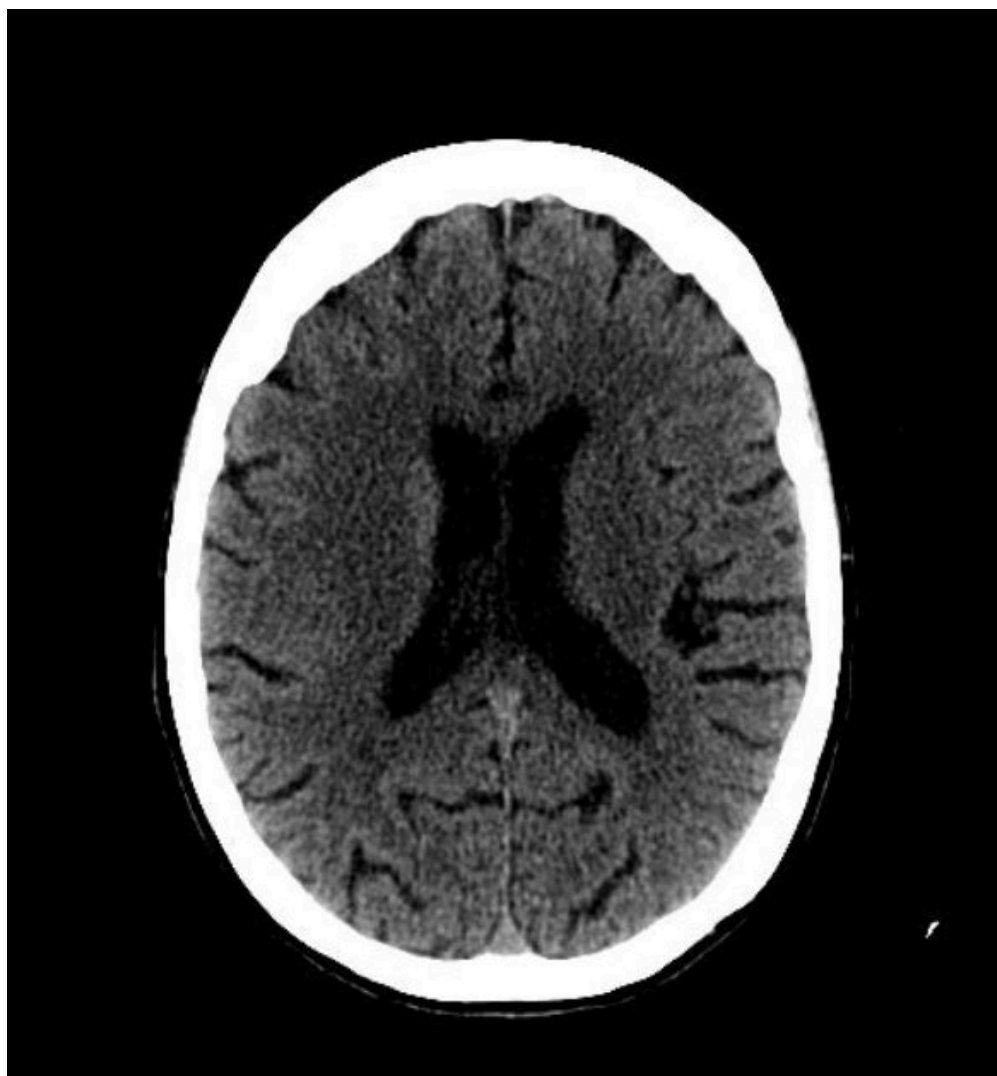

Figure 6.3A Axial CT of Head displaying findings of an ischemic stroke.

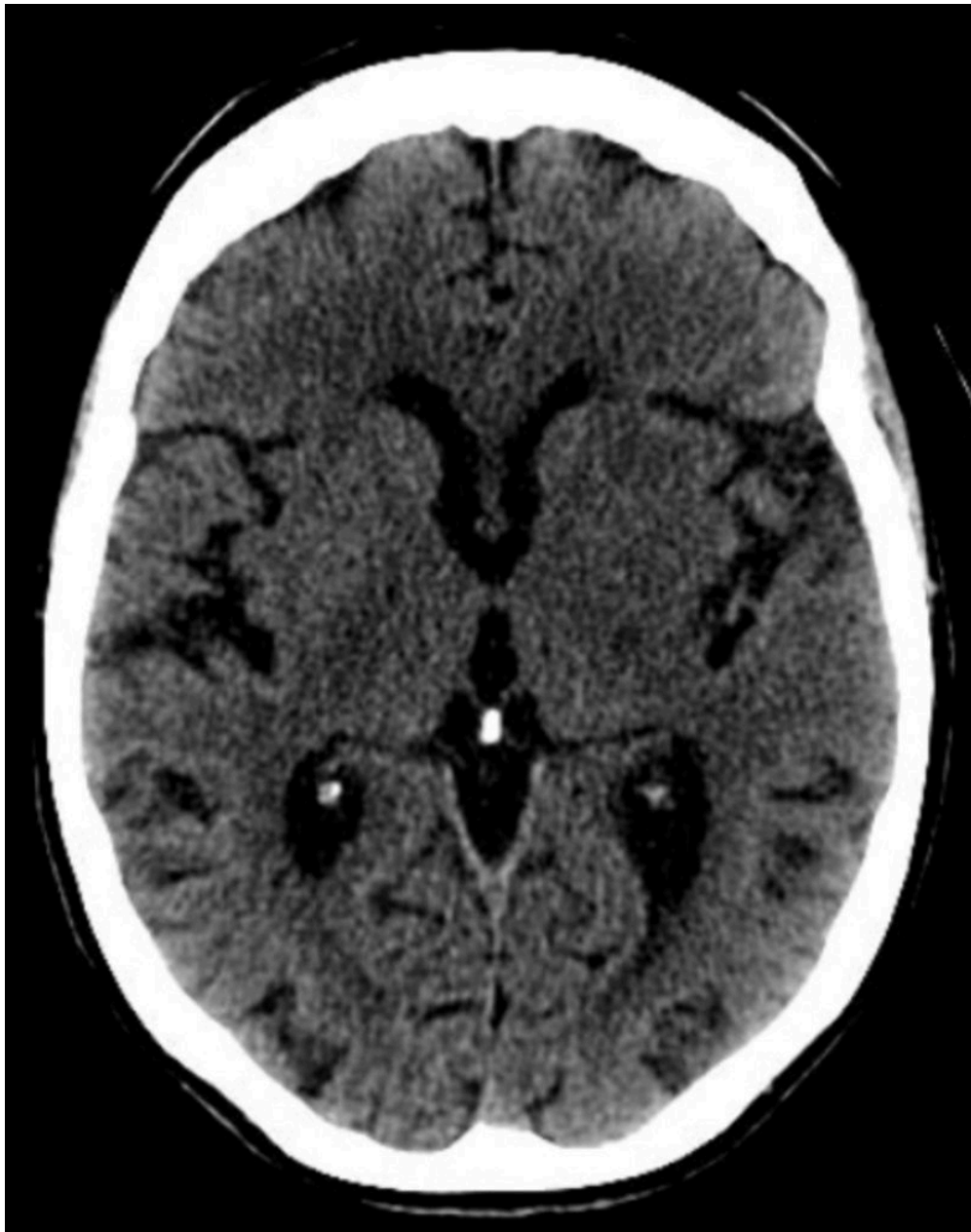

Figure 6.3B Axial CT of Head displaying findings of an ischemic stroke.

Imaging Assessment

Findings:

The left basal ganglial region and the left caudate head were of abnormally low density. There was also loss of the grey matter/white matter differentiation in the left frontal region. The left middle cerebral artery was hyperdense compare to the right suspicious for arterial thrombosis. No intracranial hemorrhage.

Interpretation:

Ischemic stroke in evolution. Possible middle cerebral artery thrombosis.

Diagnosis:

Ischemic stroke.

Discussion

Stroke is a nonspecific term that usually denotes an acute loss of neurologic function. It often occurs when the blood supply to an area of the brain is lost or compromised.

The diagnosis of stroke is usually made clinically. Patients with suspected stroke are imaged to determine if there is another cause for the neurologic impairment besides a stroke (e.g., a brain tumor), to attempt to determine the distribution and severity of the stroke on imaging, and to identify the presence, or absence, of brain parenchymal blood to distinguish ischemic from hemorrhagic stroke. CT can determine whether, or not, hemorrhage is present and may help to determine whether, or not, thrombolytic therapy will be instituted. CT may identify the infarct and characterize it in regards to its vascular distribution.

- Strokes are divided into two large groups: ischemic or hemorrhagic. Ischemic strokes are more common. The classification is important because rapid treatment of ischemic stroke with tissue plasminogen activator (t-PA) or another form of intra-arterial recanalization can improve the prognosis.
- A common cause of ischemic strokes are intra-arterial emboli, the emboli may arise from the heart, the aorta, the common carotid bifurcation or the internal carotid artery bulb.
- The other possible cause of stroke is thrombosis, representing in situ occlusion of the carotid, vertebral, or intracerebral circulation from an atheromatous lesion or large embolus from the central arterial circulation.
- Most acute strokes are initially imaged by obtaining a non-contrast-enhanced CT scan of the brain (within 24 hours of the onset of symptoms), mostly because of its availability.

CT findings of an Ischemic stroke may include:

- The findings depend upon the amount of time that has elapsed since the original ischemic event.
- 0 – 12 hours, imaging may be normal.
- 12 to 24 hours, indistinct area(s) of low attenuation in a vascular distribution.
- > 24 hours, better circumscribed low density lesion(s) with mass effect due to associated edema, that peaks 3 to 5 days after and usually disappears by 2 to 4 weeks.
- > 4 weeks, mass effect disappears. There is now a well-circumscribed, low-attenuation lesion with no contrast enhancement. There may be volume loss in the brain with concomitant prominent CSF spaces in the involved region.

Attributions

Figure 6.3A Axial CT of the Head displaying findings of an ischemic stroke by Dr. Brent Burbridge MD, FRCPC, University Medical Imaging Consultants, College of Medicine, University of Saskatchewan is used under a [CC-BY-NC-SA 4.0](#) license.

Figure 6.3B Axial CT of Head displaying findings of an ischemic stroke by Dr. Brent Burbridge MD, FRCPC, University Medical Imaging Consultants, College of Medicine, University of Saskatchewan is used under a [CC-BY-NC-SA 4.0](#) license.

Tumours of the Brain

Case 1

Meningioma

Clinical:

History – This 90 year old female was being assessed for personality changes and the onset of aggressive behavior over the last year. Her family relayed that this was a slow, progressive change in behavior.

Symptoms – None

Physical – The patient was angry, uncooperative, and combative. No localizing physical findings

Laboratory – Non-contributory

DDx:

Brain Tumor

Meningioma

Silent Infarct

Subdural Hematoma

Imaging Recommendation

CT Head without and with IV contrast

ODIN Link for Meningioma (CT) images, Figure 6.4A and B: <https://mistr.usask.ca/odin/?caseID=20170425233536854>

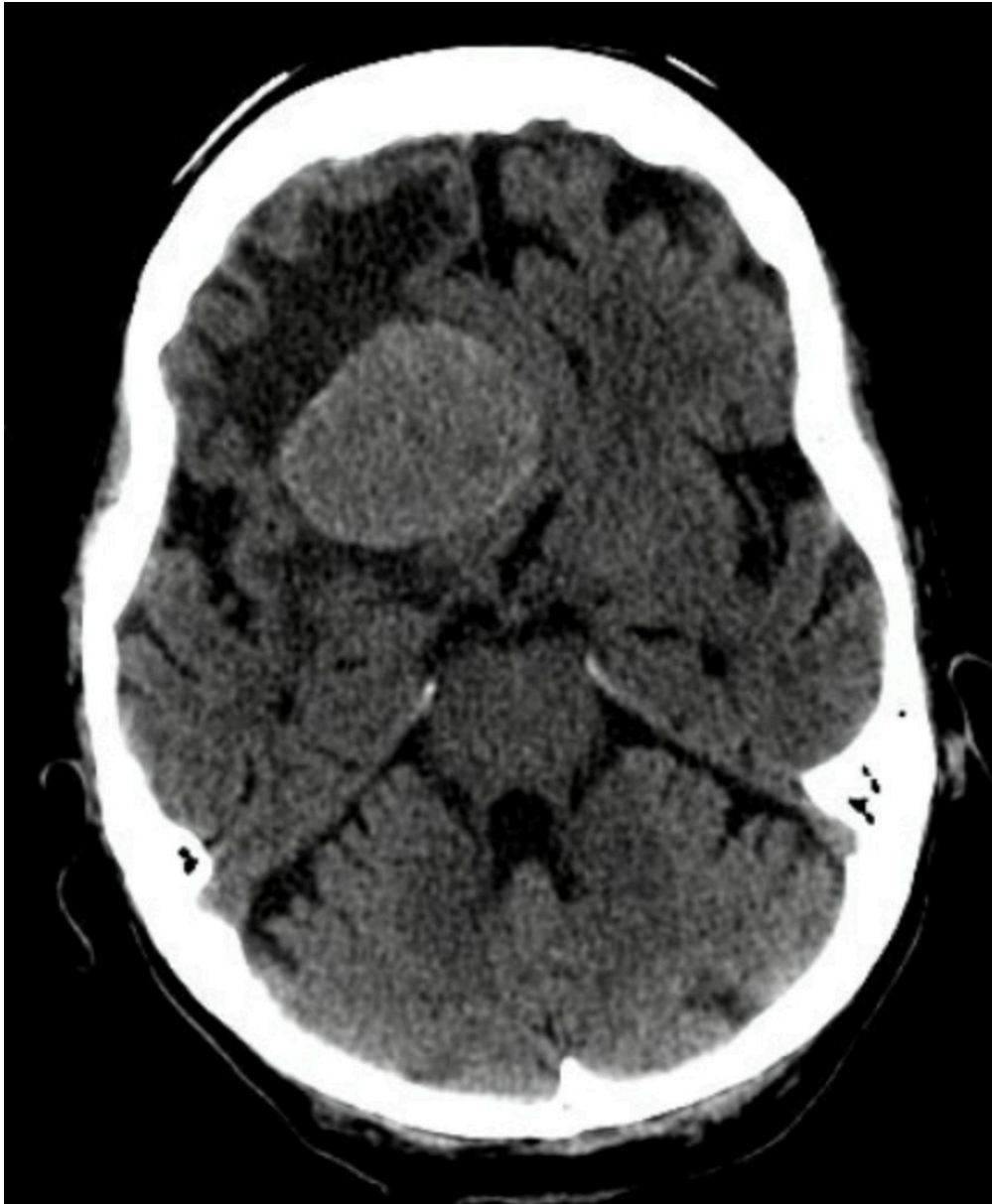

Figure 6.4A Axial CT of Head displaying a Meningioma.

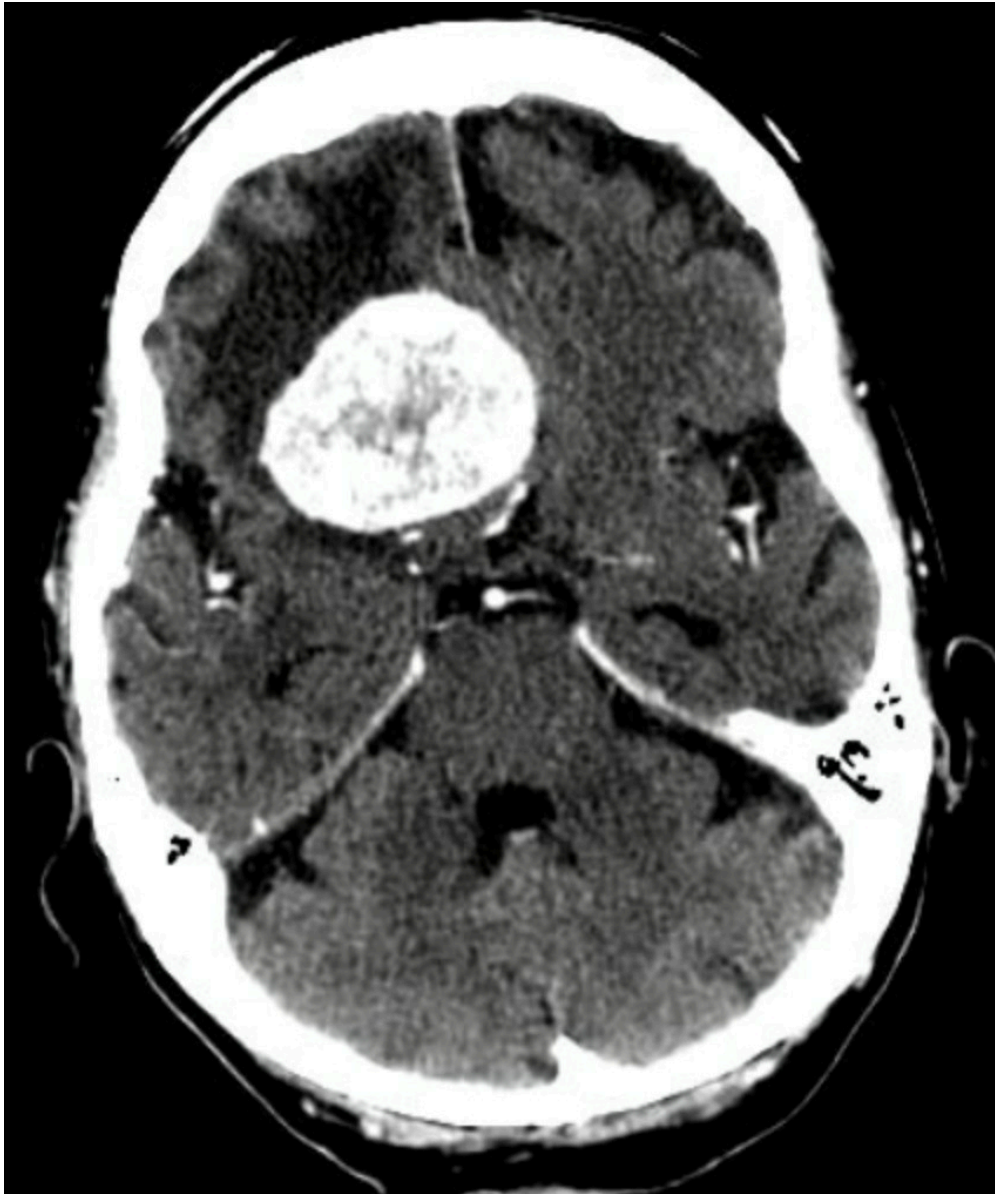

Figure 6.4B Axial CT of Head, with contrast, displaying a Meningioma.

Imaging Assessment

Findings:

A large, peripherally calcified, mass was seen in the right frontal region. There was moderate to severe vasogenic, parenchymal, edema associated with the mass. Moderate mass effect was seen with subfalcine herniation present. The base of the skull was mildly hyperostotic adjacent to the tumour.

Interpretation:

There was a large frontal mass, highly suggestive of a meningioma.

Diagnosis:

Meningioma

Discussion:

Meningiomas are the most common extra-axial mass, usually occurring in middle-aged patients, women > men. Meningiomas are non-glial, intracranial tumours that arise from the meninges. Their most common locations are parasagittal, over the convexities, the sphenoid wing, and the cerebellopontine angle, in decreasing frequency. They tend to be slow-growing with an excellent prognosis if surgically resected, but they may also rarely have more aggressive histology. When multiple, they may have an association with Neurofibromatosis type 2.

CT findings of Meningioma may include:

- On unenhanced CT, over half are hyperdense to normal brain and about 20% contain calcification.
- On contrast-enhanced studies, meningiomas enhance markedly.
- The tumors usually form an obtuse angle with the skull and may have a dural tail of tumour.
- The underlying bone may become dense and hypertrophied.
- If supplied by the middle meningeal artery, there may be enlargement of this artery and its groove in the skull.
- They may induce vasogenic edema in the adjacent brain parenchyma.

Case 2

Glioblastoma

Clinical:

History – This elderly lady was in a Nursing Home.

Symptoms – Obtunded, worsening confusion.

Physical – Semi-conscious. Disoriented. Left arm and leg weakness.

DDx:

Brain infarction

Subdural hematoma

Brain tumor

Imaging Recommendation

[ACR – Cerebrovascular Disease, Suspected Intracranial Hemorrhage, Variant 12](#)

CT Head without and with IV contrast

ODIN Link for Glioblastoma images (CT and MRI), Figure 6.5A and B: <https://mistr.usask.ca/odin/?caseID=20170308094826974>

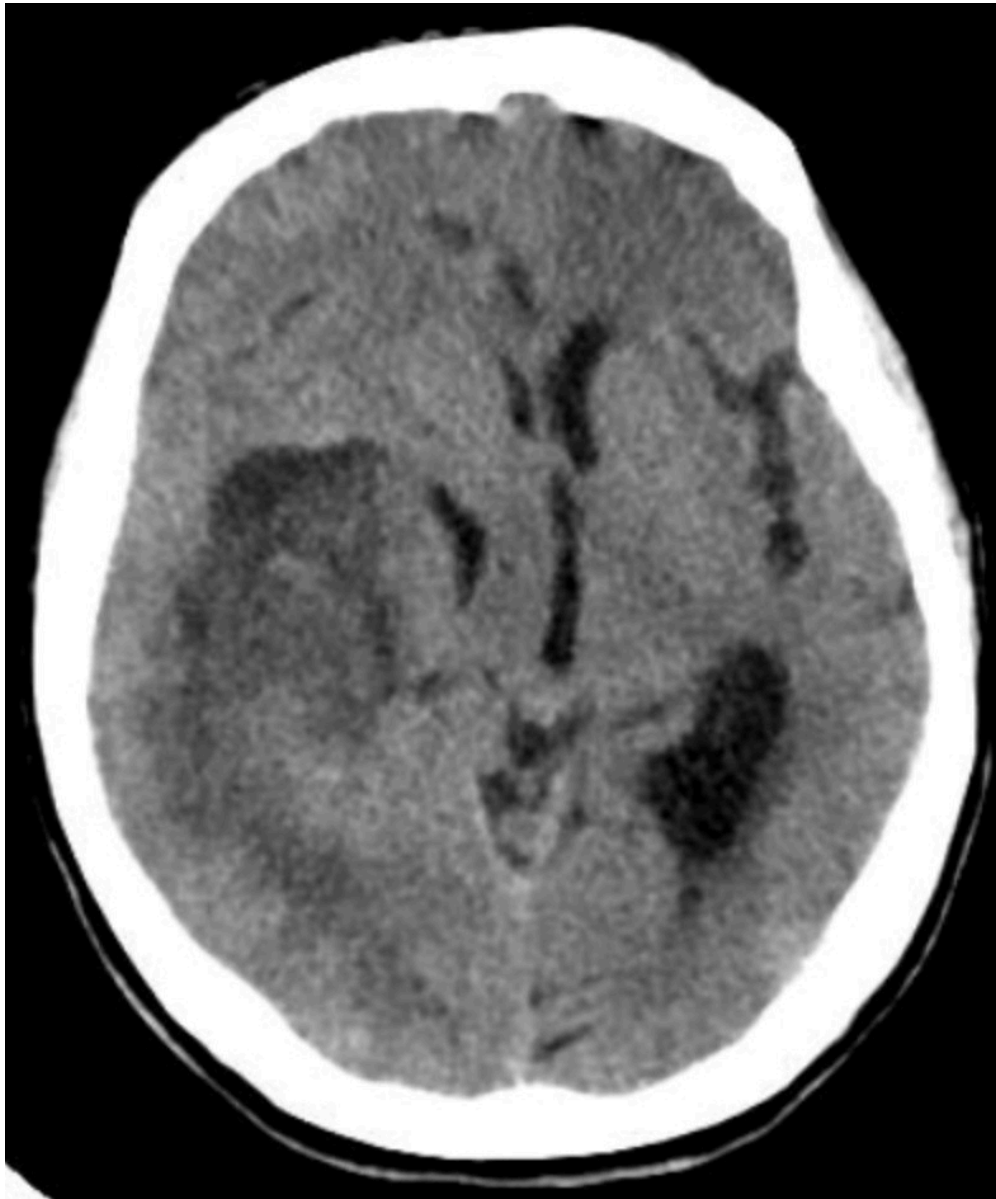

Figure 6.5A Axial CT of Head, without contrast, displaying a mixed density mass.

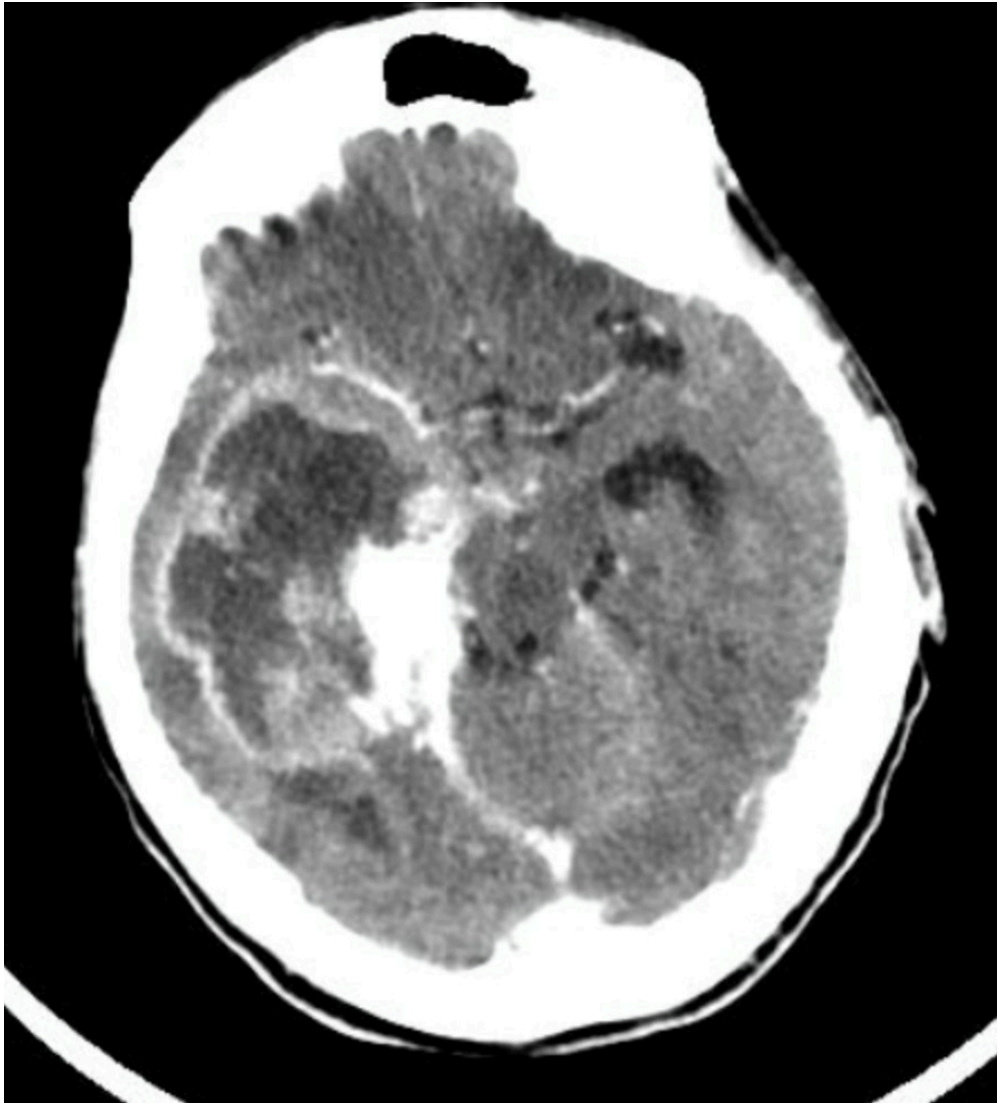


Figure 6.5B Axial CT of Head, with contrast, displaying contrast enhancement suspicious for a Glioblastoma.

Imaging Assessment

Findings:

There was a large complex mass in the right parietal-occipital region with central low density. There was mild vasogenic edema of the adjacent brain. Subfalcine herniation was noted. There was effacement of the ipsilateral, lateral ventricle and dilation of the contralateral, lateral ventricle. There was a very inhomogeneous pattern of contrast enhancement with prominent rim or ring enhancement seen surrounding the margin of the mass. This was a solitary lesion.

Interpretation:

Brain Tumor with edema and central necrosis.

Diagnosis:

Glioblastoma Multiforme, Biopsy Proven

Discussion:

Gliomas are the most common primary, supratentorial, intra-axial mass in an adult. They account for 30% of brain tumors of all types and 80% of all primary malignant brain tumors.

Glioblastoma multiforme accounts for more than half of all gliomas, astrocytomas about 20%, with the remainder split among ependymoma, oligodendroglioma, and mixed glioma (e.g., oligoastrocytoma).

Glioblastoma multiforme occurs more commonly in males between 65 to 75 years of age, especially in the frontal and temporal lobes.

It has the worst prognosis of all gliomas. It infiltrates adjacent areas of the brain along white matter tracts, making it difficult to resect, but like most brain tumors, it does not produce extra-cerebral metastases.

Imaging findings of a Glioblastoma Multiforme may include:

- As the most aggressive of tumours, glioblastoma multiforme frequently demonstrates necrosis within the tumor.
- The tumour infiltrates the surrounding brain tissue, frequently crossing the white matter tracts of the corpus callosum to the opposite cerebral hemisphere, producing a pattern called a butterfly glioma.
- The tumour is often associated with considerable vasogenic edema, mass effect, and enhances with contrast, at least in part.

Attributions

Figure 6.4A Axial CT of Head, without contrast, displaying a Meningioma by Dr. Brent Burbridge MD, FRCPC, University Medical Imaging Consultants, College of Medicine, University of Saskatchewan is used under a [CC-BY-NC-SA 4.0](#) license.

Figure 6.4B Axial CT of Head, with contrast, displaying a Meningioma by Dr. Brent Burbridge MD, FRCPC, University Medical Imaging Consultants, College of Medicine, University of Saskatchewan is used under a [CC-BY-NC-SA 4.0](#) license.

Figure 6.5A Axial CT of Head, without contrast, displaying a mass suspicious for malignancy by Dr. Brent Burbridge MD, FRCPC, University Medical Imaging Consultants, College of Medicine, University of Saskatchewan is used under a [CC-BY-NC-SA 4.0](#) license.

Figure 6.5B Axial CT of Head, with contrast, displaying contrast enhancement suspicious for a Glioblastoma by

Dr. Brent Burbridge MD, FRCPC, University Medical Imaging Consultants, College of Medicine, University of Saskatchewan is used under a [CC-BY-NC-SA 4.0](https://creativecommons.org/licenses/by-nc-sa/4.0/) license.

Hydrocephalus

ACR – Neurologic – Headache

Case

Aqueductal Stenosis, Obstructive Hydrocephalus

Clinical:

History – Nausea, vomiting, headache.

Symptoms – Headache.

Physical – The patient had possible papilledema. No focal neurologic abnormalities.

DDx:

Brain Tumor

Hydrocephalus

Meningitis

Imaging Recommendation

[ACR – Neurologic – Headache – Focal Neurologic Deficit or Papilledema, Variant 13](#)

MR of the Head without IV contrast – if not available, or contraindicated, CT is the next best examination

CT of the Head without IV contrast

ODIN Link for Hydrocephalus images, Figure 6.6A and B: <https://mistr.usask.ca/>

<odin/?caseID=20170426091006728>

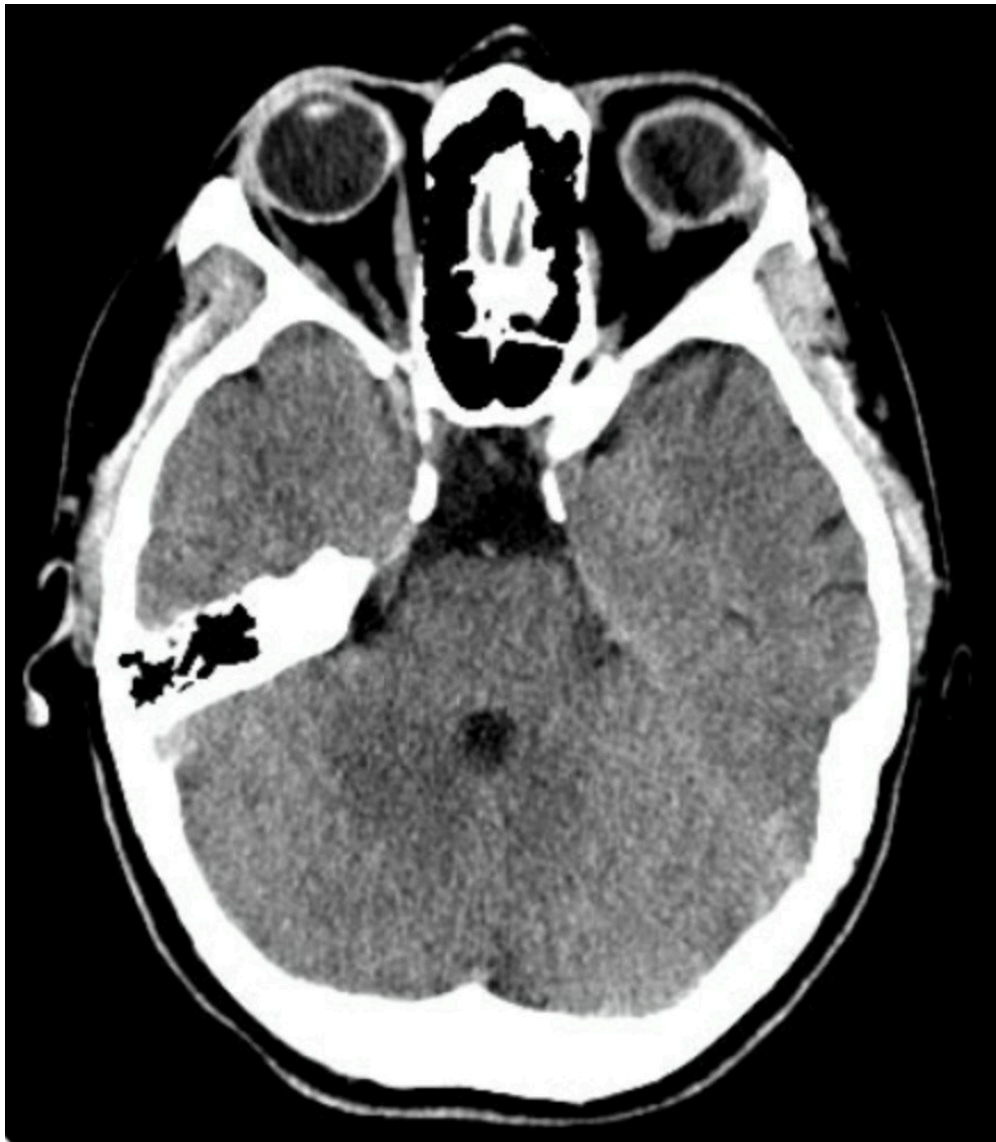


Figure 6.6A Axial CT of Head displaying a dilated Cerebral Aqueduct

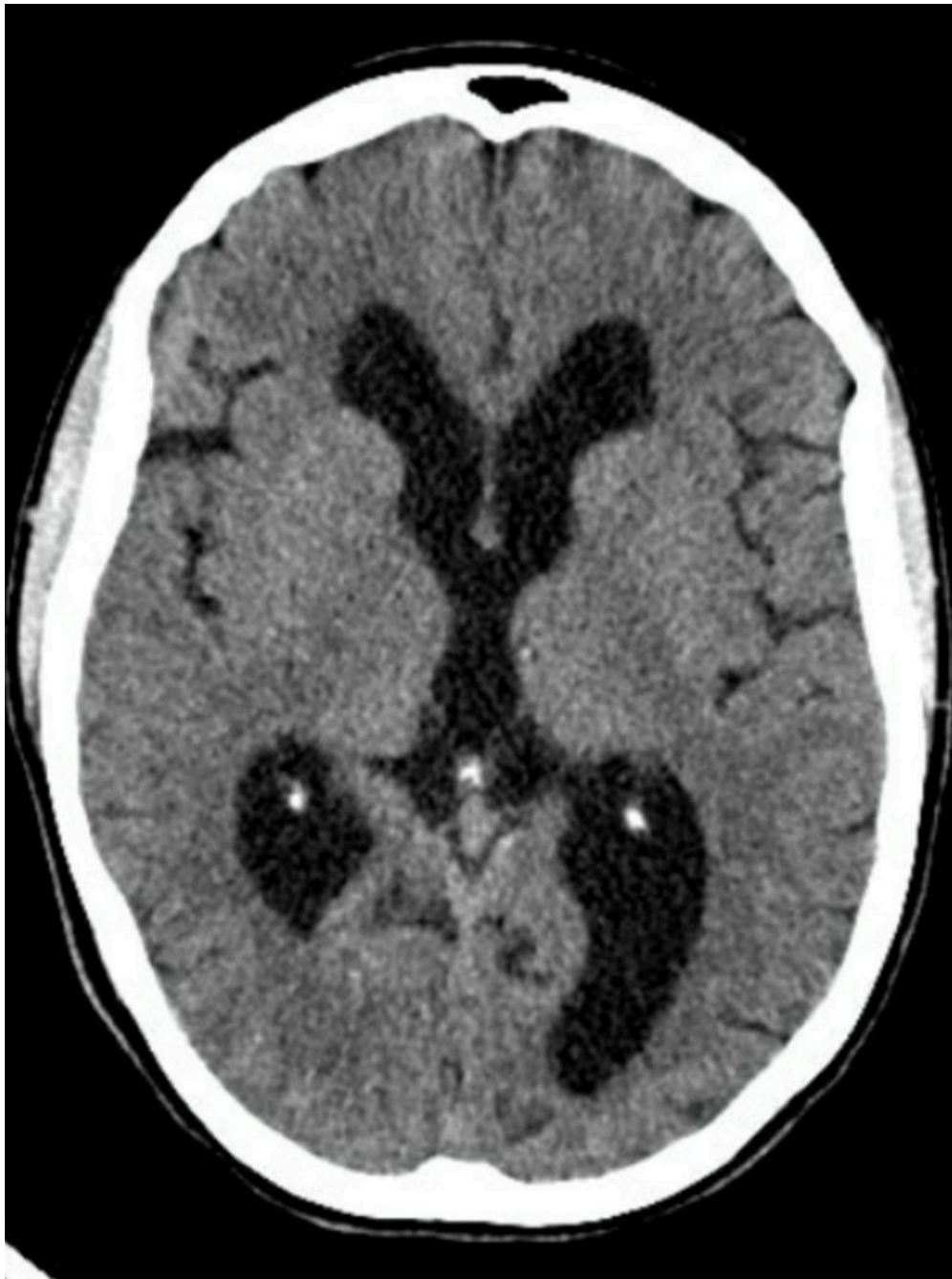

Figure 6.6B Axial CT of Head displaying dilated ventricles consistent with Hydrocephalus

Imaging Assessment

Findings:

The ventricles cranial to the cerebral aqueduct were dilated. The aqueduct became non-visible downstream in the brainstem. The fourth ventricle was not enlarged. No evidence of a mass or extrinsic lesion.

Interpretation:

Probable aqueductal stenosis. MR of the brain was recommended to assess for subtle intra or extra-ventricular causes for aqueductal stenosis.

Diagnosis:

Aqueductal Stenosis, Hydrocephalus

Discussion:

Headache is a cardinal symptom of increased intracranial pressure and is frequently accompanied by nausea and vomiting, which is usually worst in the mornings. In the setting of headache, the presence of bilateral papilledema indicates increased intracranial pressure that is transmitted to the optic nerve sheath. As such, the differential diagnosis for headache in the setting of papilledema is quite broad. It includes any mass such as, abscess, primary or metastatic tumors, hematoma, cerebral edema, communicating or obstructive hydrocephalus, idiopathic intracranial hypertension (IIH), dural venous sinus thrombosis, and entities that result in increased cerebrospinal fluid (CSF) production. MRI of the head with and without contrast is the imaging study of choice. CT of the head with contrast may be appropriate if MRI is contraindicated or not available.

The cause, or type of, the patient's headache should be evaluated by procuring a careful history and performing a physical examination while focusing on detecting any warning signals that would prompt further diagnostic testing. In the absence of worrisome features in the history or examination, the task is then to diagnose the primary headache syndrome based on the clinical features.

If atypical clinical features are present, or the patient does not respond to conventional therapy, the possibility of a secondary headache disorder should be investigated.

When considering such a common disorder as headache, indications for imaging use become relevant. This is particularly true in the face of emerging and rapidly evolving technologies in use today. Performing low-yield studies is likely to result in false-positive results, with the consequent risk of additional and unnecessary procedures. Additionally, the cost to the healthcare system must be considered related to imaging. The yield of positive studies in patients referred with isolated, non-traumatic headache is approximately 0.4%. Assuming the cost of a CT scan is \$400, and a magnetic resonance imaging (MRI) scan is \$900, the cost to detect a lesion is \$100,000 with CT and \$225,000 with MRI.

One should not assume, however, that there is no social benefit in negative imaging studies in the setting of headache. Indeed, headache symptoms can be quite ominous and onerous, and there can be tremendous costs with respect to loss of productivity and quality-of-life.

Imaging findings of Hydrocephalus:

- Hydrocephalus is defined as an expansion of the ventricular system on the basis of an increase in the volume of cerebrospinal fluid contained within it.
- In hydrocephalus the ventricles are usually disproportionately dilated when compared with the sulci, whereas both the ventricles and sulci are proportionately enlarged in cerebral atrophy.

- The temporal horns are particularly sensitive to increases in CSF pressure. In the absence of hydrocephalus, the temporal horns are barely visible. With hydrocephalus the temporal horns may be greater than 2 mm in size.
- Acute hydrocephalus may result in peri-ventricular edema in the white matter.
- Two major subtypes: Communicating and Non-communicating hydrocephalus.
- Intra-ventricular blood and subarachnoid blood can lead to communicating hydrocephalus.
- Classically, the 4th ventricle is dilated in communicating hydrocephalus and normal in size in non-communicating hydrocephalus.

Canadian CT Head Rules (CCHR)

Guidance for Requesting a CT Head Examination

There are several clinical guidelines that discuss when it is appropriate to order a CT Head for patients with minor trauma. These Canadian guidelines are: The Canadian CT Head Rules (CCHR), established and validated in Ottawa, Canada, the NEXUS, and the NOC, as well. It is important to know the guidelines that are being applied in your jurisdiction and use these for CT Head requests.

The Canadian CT Head Rules (CCHR) for Minor Head Injury Patients, include the following:

Minor Head Injury is:

- Minimal head injury (no loss of consciousness, amnesia, or disorientation)

The Rules are not applicable to the following:

- Age <16 years
- No clear history of trauma as the primary event
- Has a bleeding disorder or is anticoagulated
- Obvious penetrating skull injury or depressed skull fracture
- Glasgow coma scale < 13

Medium Risk of Brain Injury

- Amnesia for events before injury > or = 30 minutes
- Dangerous mechanism of injury^{##}

Higher Risk of Brain Injury

- Glasgow Coma Scale < 15 at 2 hours after injury
- Suspected open or depressed skull fracture

- An sign of a basal skull fracture^{*}
- Vomiting > or + = episodes
- Age > 65 years

– Dangerous Mechanism

- Pedestrian struck by vehicle
- Occupant ejected from motor vehicle
- Fall from an elevation of > or = 3 feet or 5 stairs

* – Basal skull fracture

- Hemotympanum
 - “Raccoon” eyes
 - Cerebrospinal fluid rhinorrhea or otorrhea
 - Battle’s sign
-

Attributions

Figure 6.6A Axial CT of Head displaying a dilated Cerebral Aqueduct by Dr. Brent Burbridge MD, FRCPC, University Medical Imaging Consultants, College of Medicine, University of Saskatchewan is used under a [CC-BY-NC-SA 4.0](#) license.

Figure 6.6B Axial CT of Head displaying a dilated ventricles consistent with Hydrocephalus by Dr. Brent Burbridge MD, FRCPC, University Medical Imaging Consultants, College of Medicine, University of Saskatchewan is used under a [CC-BY-NC-SA 4.0](#) license.

Low Back Pain

ACR – Neurologic – Low Back Pain

Case

Low back pain. No red flags

Clinical:

History – This 49 year old male had a 4 week history of low back pain.

Symptoms – Low back pain, limited range of motion, muscle spasm.

Physical – No neurological symptoms or signs. No red flags.

DDx:

Back spasms

Intervertebral disc herniation

Fibromyalgia

Muscle injury

Imaging Recommendation

[ACR – Neurologic – Low Back Pain, Acute, Subacute, or Chronic, Variant 1](#)

No Imaging Recommended

Lumbar spine x-rays were ordered, regardless.

ODIN Link for Lumbar Spine x-ray images, Figure 6.7A and B: <https://mistr.usask.ca/odin/?caseID=20150311180052507>

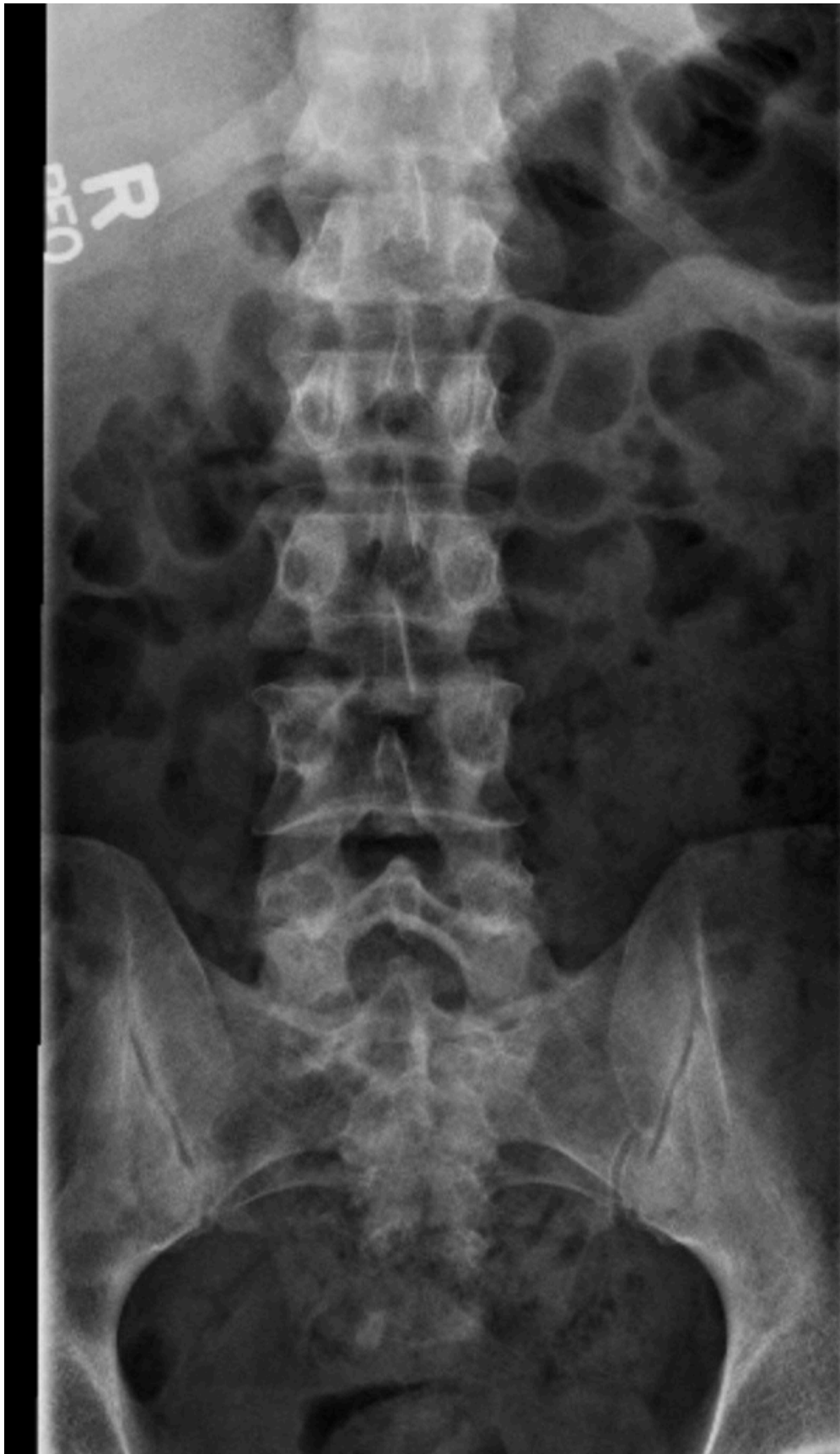

Figure 6.7A AP x-ray of lower spine.

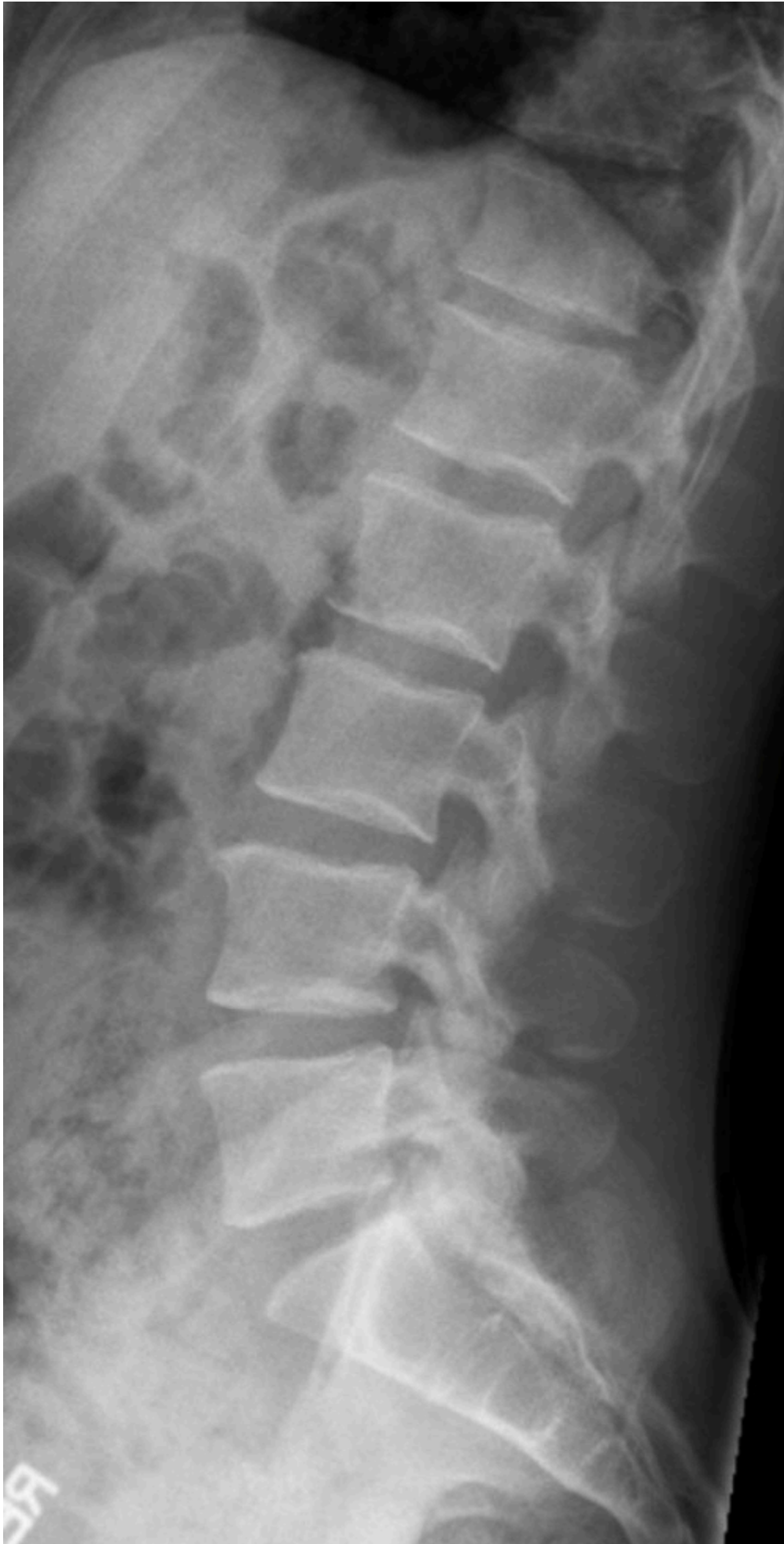

Figure 6.7B Lateral x-ray of lower spine.

Imaging Assessment

Findings:

A minor lumbar scoliosis, convex to the right, was seen. Minor facet degenerative changes were present. Nil else.

Interpretation:

No significant abnormalities, age appropriate degenerative changes

Diagnosis:

Low back pain, no red flags

Discussion:

Low back pain (LBP), with or without radiculopathy, is one of the leading causes of years lived with disability and the third ranking cause of disability-adjusted life years. It is the second most common reason for a physician visit and affects 80% – 85% of people over their lifetime.

The American College of Physicians and the American Pain Society classify LBP into the following broad categories: nonspecific LBP, back pain potentially associated with radiculopathy or spinal stenosis, and back pain potentially associated with another specific spinal cause.

Additionally, guidelines from the American College of Physicians and the American Pain Society emphasize a focused history and physical examination, reassurance, initial pain management medications if necessary, and consideration of physical therapies without routine imaging in patients with nonspecific LBP. Duration of symptoms also helps guide treatment algorithms in patients with acute, subacute, or chronic LBP.

Additionally, assessment of psychosocial risk factors when obtaining patient history is a strong predictor of patients who are predisposed to developing chronic disabling LBP problems.

Although there is great variability in the definition of acute and subacute LBP, for the purposes of this discussion, we will use the Institute for Clinical Systems Improvement definitions of 0–6 weeks to definite acute LBP, 6–12 weeks for subacute LBP, and >12 weeks to define chronic LBP.

Uncomplicated acute LBP and/or radiculopathy is a benign, self-limited, condition that does not warrant any imaging studies. Imaging is considered in those patients who have had up to 6 weeks of medical management and physical therapy that resulted in little or no improvement in their back pain. It is also considered for those patients presenting with red flags raising suspicion for a serious underlying condition, such as cauda equina syndrome (CES), malignancy, fracture, or infection.

Red Flags:

Possible Underlying Condition	Red Flag
Malignancy or Infection	Known, previous malignancy
	Unexplained weight loss
	Intravenous drug use
	Chemotherapy
	Prolonged corticosteroid use
Fracture	Fall or lifting in an elderly patient
	History of significant trauma
	Prolong corticosteroid use
Major Neurologic Compromise (Cauda equina, paralysis,)	Loss of anal sphincter tone
	Fecal or urinary incontinence
	Urinary retention
	Saddle anesthesia
	Progressive weakness in the lower limbs

Attributions

Figure 6.7A AP x-ray of lower spine. by Dr. Brent Burbridge MD, FRCPC, University Medical Imaging Consultants, College of Medicine, University of Saskatchewan is used under a [CC-BY-NC-SA 4.0](https://creativecommons.org/licenses/by-nc-sa/4.0/) license.

Figure 6.7B Lateral x-ray of lower spine. by Dr. Brent Burbridge MD, FRCPC, University Medical Imaging Consultants, College of Medicine, University of Saskatchewan is used under a [CC-BY-NC-SA 4.0](https://creativecommons.org/licenses/by-nc-sa/4.0/) license.

Spine Fracture

ACR – Neurologic – Low Back Pain, Variant 2

Case

T12, ventral, vertebral, compression fracture

Clinical:

History – This 65 year old female experienced severe low back pain after jumping down from the back of a pick-up truck.

Symptoms – Upper, low back pain.

Physical – Bent forward due to back pain. Pain ranked as severe, 7 – 8/10. Range of motion of the spine was very diminished. No neurological symptoms or red flags.

DDx:

Disc herniation

Muscle spasms

Vertebral compression fracture

Imaging Recommendation

[ACR – Neurologic – Low Back Pain, Variant 9](#)

Advanced imaging with CT or MR of the spine, neurologic symptoms favour obtaining MR

X-rays are useful for screening and localization

ODIN Link for Spine Trauma images (x-ray and CT), Figures 6.8A and B: <https://mistr.usask.ca/odin/?caseID=20150311230928657>

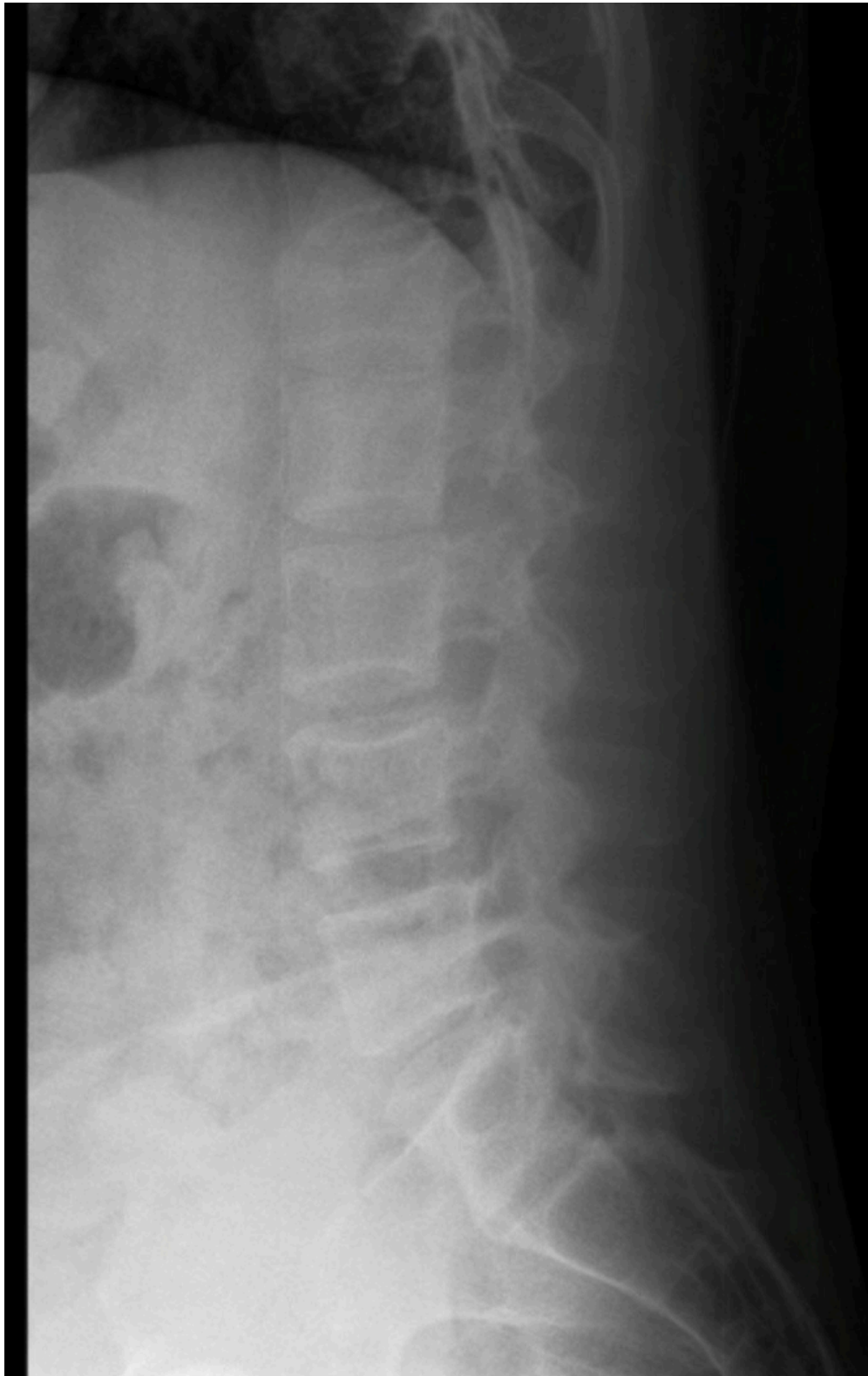

Figure 6.8A Lateral x-ray of the lower spine, T12 fracture.

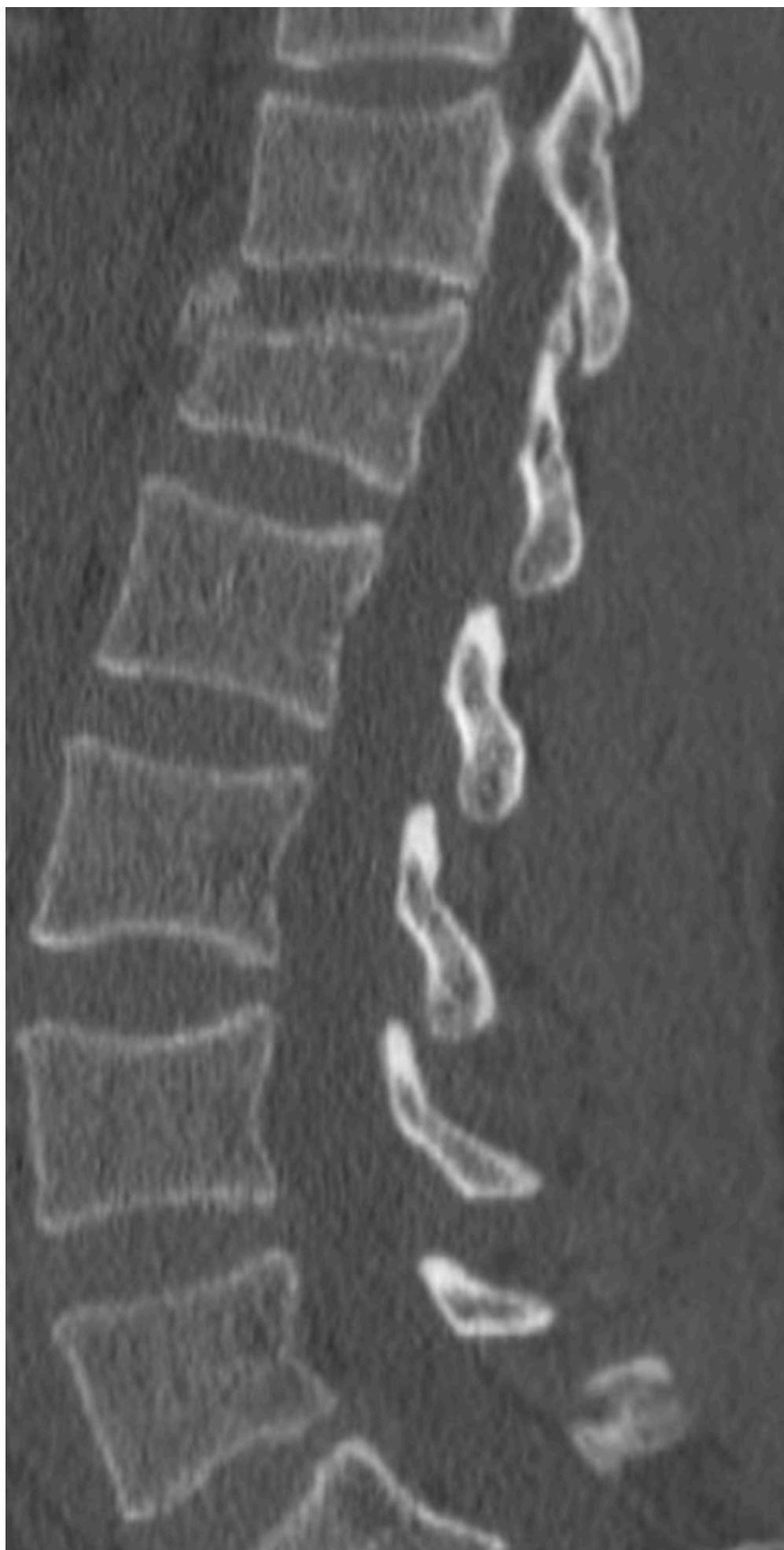

Figure 6.8B Sagittal Reformat of a CT Scan of the lower spine, T12 fracture.

Imaging Assessment**Findings:**

There was a ventral, cranial, end plate, fracture of the T12 vertebral body. This was a mild compression fracture. There was minimal osteopenia of the bones. Nil else.

CT imaging did not reveal any suspicious skeletal lesions.

Interpretation:

Minor compression fracture. Probably osteoporotic.

Advanced spine imaging (CT or MR) can help to rule out malignancy, or infection, if there is clinical concern.

Diagnosis:

T12, ventral, vertebral compression fracture

Discussion:

Vertebral compression fractures can be caused by osteoporosis, direct acute trauma in an otherwise healthy vertebra, and neoplasms. Neoplasms causing vertebral compression fractures include: 1) primary bone neoplasms (hemangiomas, giant cell tumors), 2) infiltrative neoplasms (multiple myeloma, lymphoma), and 3) metastatic neoplasms. Osteoporotic vertebral compression fractures are the most commonly encountered fractures that require surgical and medical treatment and are the focus of this narrative.

Postmenopausal women represent the majority of patients at risk for developing osteoporotic fractures of any type, and vertebral compression fractures represent 25% of osteoporotic fractures. Painful vertebral compression fractures may cause a marked decline in physical activity and quality of life, leading to general physical de-conditioning. This, in turn, may prompt further complications related to poor inspiratory effort (atelectasis and pneumonia) and venous stasis (deep venous thrombosis and pulmonary embolism).

Successful management of painful vertebral compression fractures has the potential for improving quality of life, increasing the expectancy of an independent and/or productive life, and preventing superimposed medical complications. Some have suggested that management of painful vertebral compression fractures may also have a cost benefit for society as a whole; however, assessment of any potential societal benefits is difficult due to the inexactness of methods for quantifying pain-related disability.

Management Overview

The traditional first-line treatment of painful vertebral compression fractures is conservative management, which includes medical management with or without methods of immobility. Most pain-related symptoms from vertebral

compression fractures are resolved with this management. Successful medical management also involves appropriate screening for osteoporosis and appropriate follow-up treatment.

Attributions

Figure 6.8A Lateral x-ray of the lower spine, T12 fracture by Dr. Brent Burbridge MD, FRCPC, University Medical Imaging Consultants, College of Medicine, University of Saskatchewan is used under a [CC-BY-NC-SA 4.0](https://creativecommons.org/licenses/by-nc-sa/4.0/) license.

Figure 6.8B Sagittal CT, reformat, of the lower spine, T12 fracture by Dr. Brent Burbridge MD, FRCPC, University Medical Imaging Consultants, College of Medicine, University of Saskatchewan is used under a [CC-BY-NC-SA 4.0](https://creativecommons.org/licenses/by-nc-sa/4.0/) license.

Brain and Spine – References

- 1) Stiell IG, Wells GA, Vandemheen K, et al. The Canadian CT Head Rule for patients with minor head injury. *Lancet*. 2001;357(9266):1391-1396.
- 2) Vilaas S. Shetty, MD; Martin N. Reis, MD; Joseph M. Aulino, MD, et al. ACR Appropriateness Criteria[®] Head Trauma. Available at <https://acsearch.acr.org/docs/69481/Narrative/> American College of Radiology. Accessed, June 30, 2017.
- 3) Michael B. Salmela, MD; Shabnam Mortazavi, MD; Bharathi D. Jagadeesan, MD, ACR, et al. Appropriateness Criteria[®] Cerebrovascular Disease. <https://acsearch.acr.org/docs/69478/Narrative/> American College of Radiology. Accessed, June 30, 2017.
- 4) Annette C. Douglas, MD; Franz J. Wippold II, MD; Daniel F. Broderick, MD, et al. Appropriateness Criteria[®] Headache. <https://acsearch.acr.org/docs/69482/Narrative/> American College of Radiology. Accessed, June 30, 2017.
- 5) Nandini D. Patel, MD; Daniel F. Broderick, MD; Judah Burns, MD, et al. Appropriateness Criteria[®] Low Back Pain. <https://acsearch.acr.org/docs/69483/Narrative/> American College of Radiology. Accessed, June 30, 2017.
- 6) Richard H. Daffner, MD; Barbara N. Weissman, MD; Franz J. Wippold II, MD, et al. Appropriateness Criteria[®] Suspected Spine Trauma. <https://acsearch.acr.org/docs/69359/Narrative/> American College of Radiology. Accessed, June 30, 2017.

Chapter 7 – Breast

Introduction to Breast Imaging

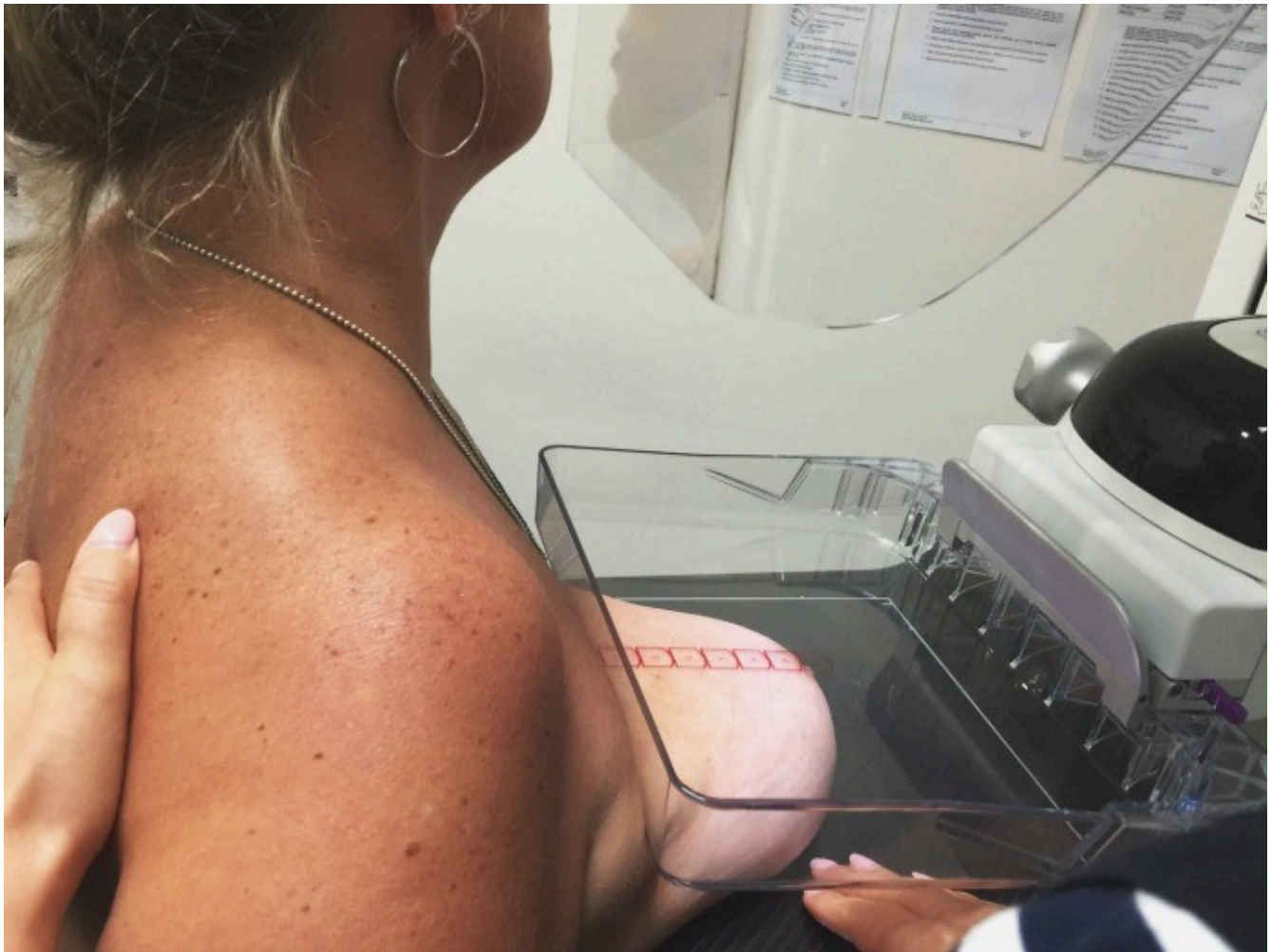Communicate the basic technical aspects of mammography, and breast ultrasound

Mammograms are x-ray images of the breast tissue obtained in a standardized manner following a routine, reproducible, breast positioning strategy and a stringent quality assurance program. The mammography machine acquires images while the breast tissue is being firmly compressed by plastic paddles. The compression spreads the breast tissue evenly and minimizes the thickness of the tissue to be imaged. Spreading and thinning the breast tissue results in the acquisition of images using less radiation as there is less tissue thickness for the x-rays to pass through. The x-rays generated by the machine are based upon a molybdenum, rather than a tungsten, x-ray tube anode which optimizes the x-ray beam for imaging soft tissues (fat, connective and mammary tissue).

Ultrasound uses traditional probes with higher frequency to better image the breast tissue that is in close proximity to the overlying skin.

Mammography/Breast Imaging Centres in Canada are accredited and audited for quality by the Canada Association of Radiologists.

Mammography Image Acquisition



Acquisition of a Cranial-Caudal Mammogram of the Right Breast

ODIN Link for Mammography image, Figure 7.1: <https://mistr.usask.ca/odin/?caseID=20170406103150705>

For More Information:

Canadian Association of Radiologists – Mammography Accreditation – <http://www.car.ca/en/accreditation/map.aspx>

Breast Cancer Screening

Screening imaging for the detection of breast cancer was established in an attempt to image tumours prior to their development into clinically detectable abnormalities.

Imaging:

There are a variety of available guidelines that facilitate the development of a physician-patient strategy for

screening for breast malignancy. These strategies may include clinical, laboratory, and imaging parameters. These guidelines have been refined to address unique patient sub-groups i.e. low risk, average risk, intermediate risk, and high risk of developing breast cancer, There are a variety of Guidelines for Breast Screening.

Canadian Association of Radiology (CAR) Practice Guidelines

- Asymptomatic women 40 – 49 years should undergo screening mammography every year
- Asymptomatic women aged 50 – 75 should undergo screening mammography every one to two years
- Women over the age of 74 should have screening mammography at one to two-year intervals if they are in good general health

Normal Mammogram Cranial-Caudal (CC) Projection

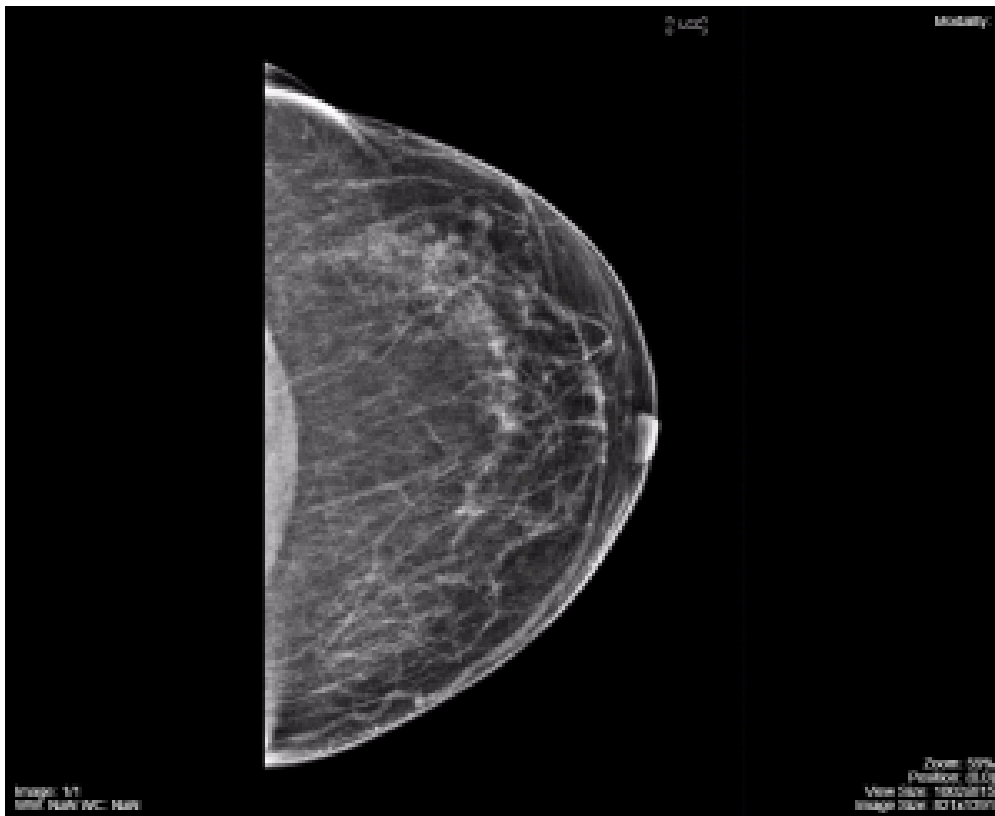

Figure 7.2A Normal Mammography Image, CC Projection

Normal Mammogram Medio-Lateral Oblique (MLO) Projection

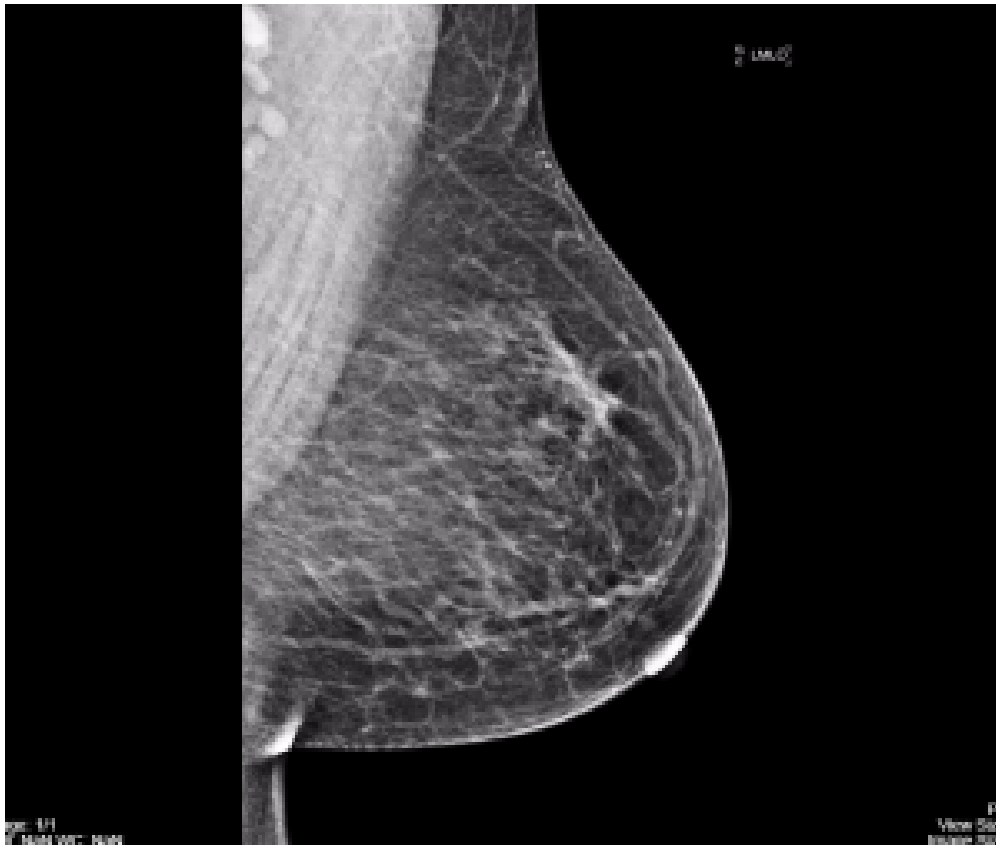

Figure 7.2B Normal Mammography Image, MLO projection.

ODIN Link for Normal Mammograms, Figure 7.2A and B: <https://mistr.usask.ca/odin/?caseID=20170410101815189>

As discussed earlier, it is also possible to use ultrasound to image the breast. *Figure 7.3* is an example of a normal breast ultrasound scan.

Normal Breast Ultrasound

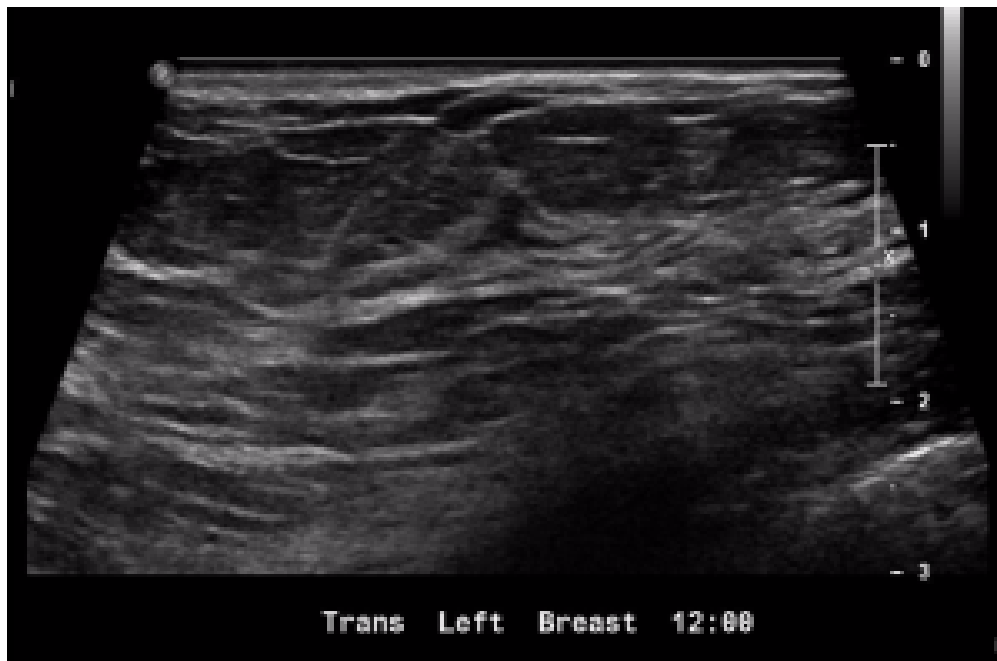

Figure 7.3 Normal Breast Ultrasound

ODIN Link for Normal Breast Ultrasound, Figure 7.3: <https://mistr.usask.ca/odin/?caseID=20170731231436765>

Note how the above figures (*Figure 7.2 and Figure 7.3*) contrast from the following figure (*Figure 7.4*) which shows a breast mass that can be visualized both on mammography and ultrasound.

Breast Mass Mammography

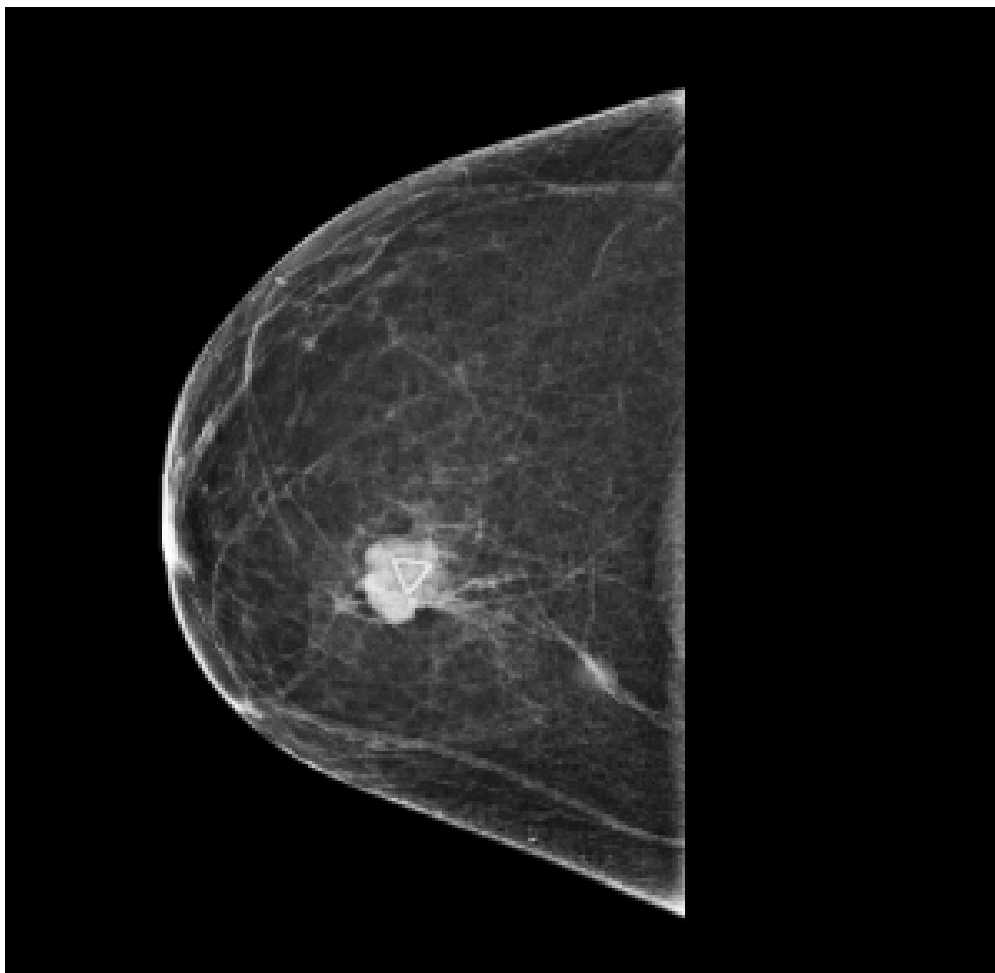


Figure 7.4A Mammography of a breast mass.

Breast Mass Ultrasound

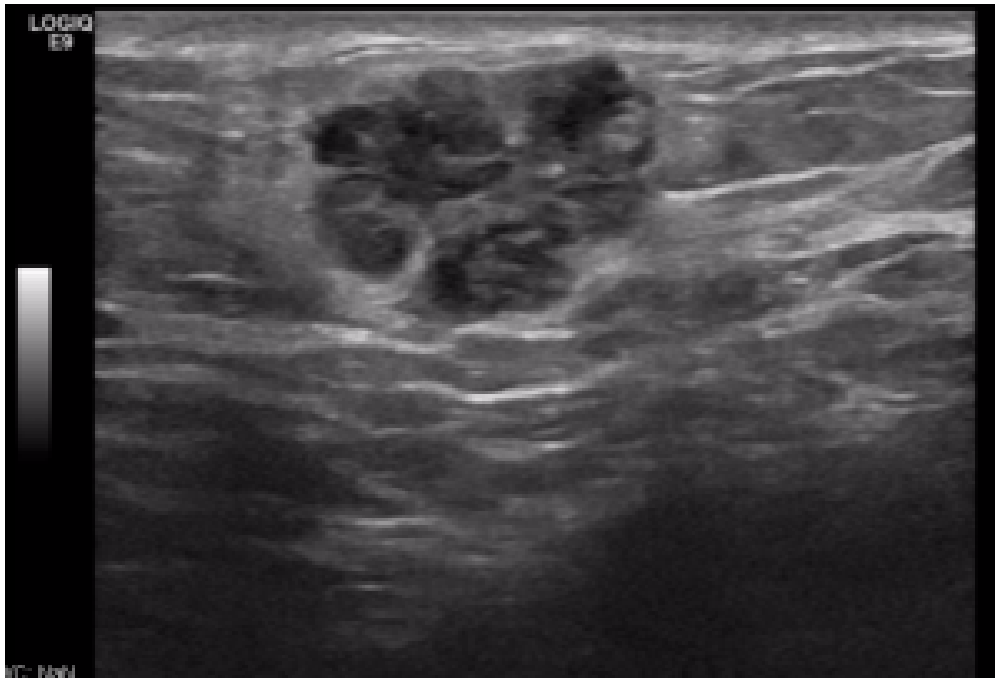


Figure 7.4B Ultrasound of a breast mass.

ODIN Link for Breast mass, Figure 7.4A and B: <https://mistr.usask.ca/odin/?caseID=20160127111954560>

For More Information:

CAR: Practice Guidelines and Technical Standards for Breast Imaging and Intervention

http://www.car.ca/uploads/standards%20guidelines/car_breastimagingguidelines_2016_en.pdf

ACR: Appropriateness Criteria – Breast Imaging – <https://acsearch.acr.org/docs/70910/Narrative/>

Attributions

Figure 7.1 Acquisition of a mammogram in the cranial-caudal projection. Image courtesy of, <http://lifeloveandhiccups.blogspot.ca/search?q=mammogram>. Used with permission.

Figure 7.2A Normal Mammography Image, CC Projection by Dr. Brent Burbridge MD, FRCPC, University Medical Imaging Consultants, College of Medicine, University of Saskatchewan is used under a [CC-BY-NC-SA 4.0](https://creativecommons.org/licenses/by-nc-sa/4.0/) license.

Figure 7.2B Normal Mammography Image, MLO projection by Dr. Brent Burbridge MD, FRCPC, University Medical Imaging Consultants, College of Medicine, University of Saskatchewan is used under a [CC-BY-NC-SA 4.0](https://creativecommons.org/licenses/by-nc-sa/4.0/) license.

Figure 7.3 Normal Breast Ultrasound by Dr. Brent Burbridge MD, FRCPC, University Medical Imaging Consultants, College of Medicine, University of Saskatchewan is used under a [CC-BY-NC-SA 4.0](#) license.

Figure 7.4A Mammography of a breast mass by Dr. Brent Burbridge MD, FRCPC, University Medical Imaging Consultants, College of Medicine, University of Saskatchewan is used under a [CC-BY-NC-SA 4.0](#) license.

Figure 7.4B Ultrasound of a breast mass by Dr. Brent Burbridge MD, FRCPC, University Medical Imaging Consultants, College of Medicine, University of Saskatchewan is used under a [CC-BY-NC-SA 4.0](#) license.

Palpable Breast Mass

ACR – Palpable Breast Mass

Case

Palpable Breast Mass

Clinical:

History: This 51 year old, female, patient discovered a left breast lump while in the shower. It was not present on her last physical examination one year ago. She had a family history of breast cancer in her maternal grandmother and her maternal aunt.

Symptoms: She felt a lump in the left breast above the nipple.

Signs: No evidence of skin thickening or nipple retraction. A hard, but slightly mobile, tumor was felt with lobulated margins. No lymph nodes palpable.

DDx:

Variant of anatomy

Benign breast tumor – cyst, fibroadenoma, fibrocystic change, fat necrosis, radial scar, abscess.

Malignant breast tumor

Metastatic disease to the breast

Imaging Recommendation

[Palpable breast mass, Woman 40 year of age, or older, initial evaluation, Variant 1.](#)

Mammography

The evaluation of a palpable abnormality most often begins with mammography and/or breast tomosynthesis. Imaging analysis of the lesion features will lead to a recommendation for further management based upon the ACR, Breast Imaging Reporting and Data System (BI-RADS).

If mammography is suspicious for malignancy the next examination would usually be an ultrasound of the mass and the ipsilateral axilla.

[ACR Recommendation for Palpable breast mass. Woman 40 years of age, or older. Mammography findings suspicious for malignancy. Next examination to perform. Variant 2](#)

Breast/Axillary Ultrasound

ODIN Link for Images 7.5A and B: <https://mistr.usask.ca/odin/?caseID=20150707195257929>

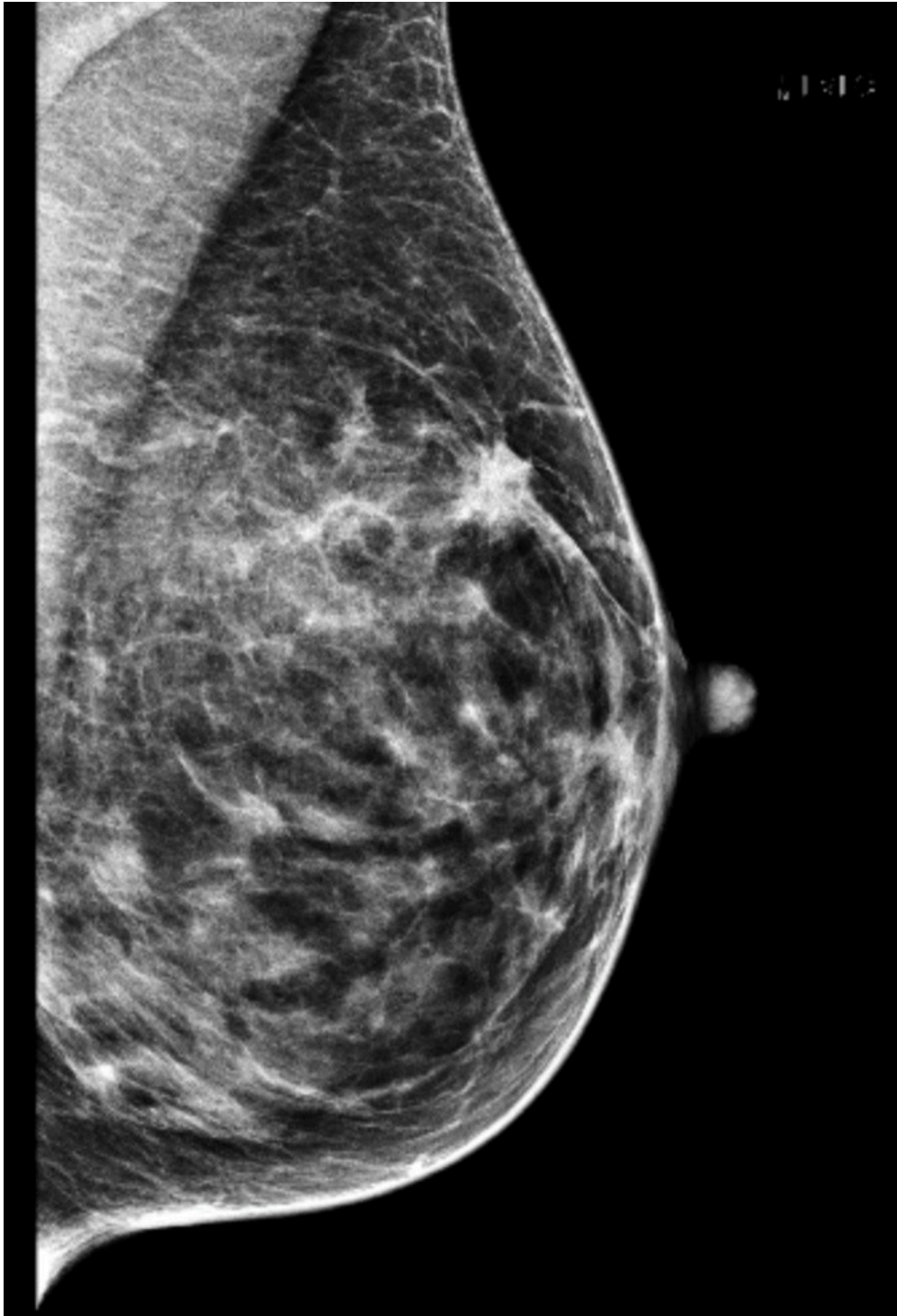


Figure 7.5A Mammography image of a breast mass.

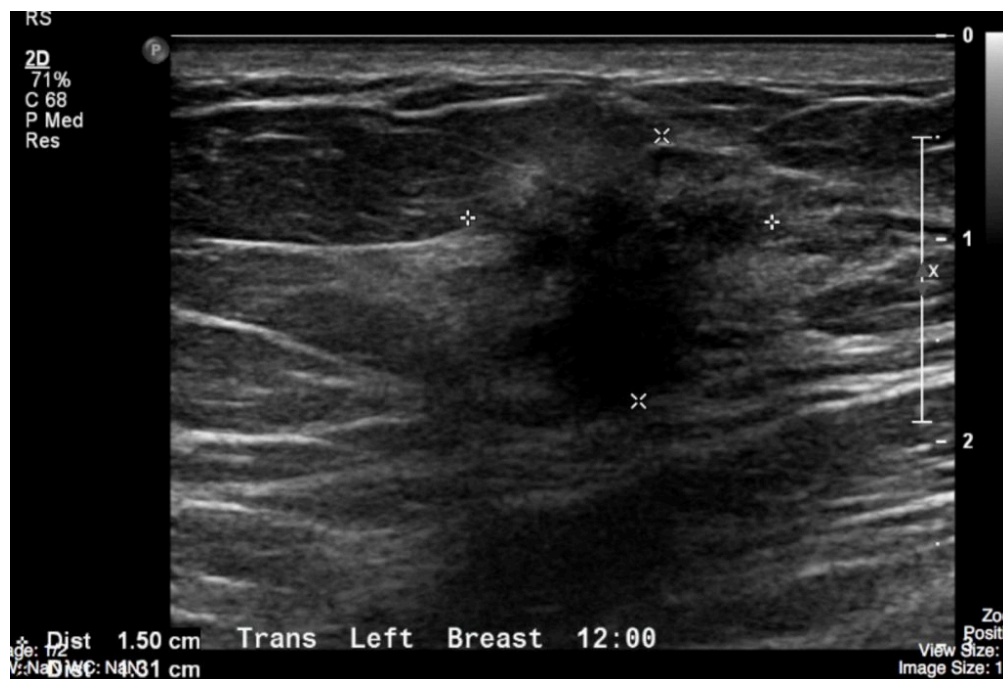

Figure 7.5B Ultrasound image of a breast mass.

Imaging Assessment

Findings:

Left Mammography

There was a 1.5 – 2 cm lobulated, spiculated, mass, with minimal architectural distortion, in the left breast at the 2 o'clock location roughly 2.5 – 3 cm cranial to the nipple. The mass does not efface with targeted, focal compression, imaging. Ultrasound of the breast was recommended. No skin abnormalities identified.

Left Breast Ultrasound

A lobulated, spiculated, mass was detected 2 cm from the nipple at the 2 o'clock location. It was taller than wide and demonstrated acoustic shadowing. No satellite lesions seen. The left axillary images were normal.

Interpretation:

The mass in the left breast had malignant features on mammography and breast ultrasound.

BI-RADS 5, high suspicion for malignancy, tissue diagnosis was recommended.

Diagnosis:

Breast mass with malignant features

Pathology:

Ultrasound Guided Core Biopsy of the mass was performed.

Invasive Ductal Carcinoma was diagnosed on microscopic assessment.

Discussion:

Breast cancer is the most common female malignancy and the second leading cause of female cancer death. Between 20,000 – 25,000 new cases of breast cancer will be diagnosed in Canada a year. Most palpable breast lumps are benign, but a new palpable breast mass is a common presenting sign of breast cancer. These masses may be detected by patient self-examination or during a physical examination carried out by a health professional.

Mammographic findings may include:

- Atypical breast calcification(s)
- Visible soft tissue mass(es)
- Tissue architectural distortion
- Skin thickening
- Skin retraction
- Nipple retraction
- Asymmetry in breast size

Attributions

Figure 7.5A Mammography image of a breast mass by Dr. Brent Burbridge MD, FRCPC, University Medical Imaging Consultants, College of Medicine, University of Saskatchewan is used under a [CC-BY-NC-SA 4.0](#) license.

Figure 7.5B Ultrasound image of a breast mass by Dr. Brent Burbridge MD, FRCPC, University Medical Imaging Consultants, College of Medicine, University of Saskatchewan is used under a [CC-BY-NC-SA 4.0](#) license.

BI-RADS

The Breast Imaging – Reporting and Data System

This ACR established schema is in its fifth edition. It has been established and deployed in an attempt to standardize the information included in a breast imaging report and to provide a methodology for reviewing outcomes based upon standardized descriptors of imaging findings and standardized management strategies. The data from this schema can be used to evaluate positive and negative biopsy results and improve the quality of patient care.

After detecting and describing the abnormal findings present on the imaging examination the final breast imaging report (mammography, ultrasound, magnetic resonance imaging) will include an assessment that reflects the findings of the examination, provides a management recommendation, and is associated with an estimate of the potential risk of malignancy.

Table 1: BiRads Classification with Suggested Management and Likelihood of Breast Cancer (adapted)

Category	Management	Likelihood of Cancer
0 – Incomplete Imaging Assessment	Recall or arrange to complete the imaging assessment	Unknown
1 – Negative	Continue Screening	No > General population
2 – Benign Findings	Continue Screening	No > General population
3 – Probably Benign Findings	Short-term imaging follow-up (6 months)	< 2% Likelihood
		> 2% – 95% Likelihood
4 – Suspicious	Tissue diagnosis	Subtypes 4A, 4B, 4C with progressively greater likelihoods of malignancy
5 – Malignancy Very Likely	Tissue diagnosis	> 95% Likelihood
6 – Known, biopsy proven, malignancy	Treatment of Malignancy	100%

Breast – References

- 1) Moy L, Heller S, Baiely L, et al. ACR Appropriateness Criteria® Breast Cancer Screening. Available at <https://acsearch.acr.org/docs/69495/Narrative/> American College of Radiology. Accessed June 30, 2017.
- 2) CAR – Practice Guidelines and Technical Standards for Breast Imaging and Intervention. Available at: http://www.car.ca/uploads/standards%20guidelines/car_breastimagingguidelines_2016_en.pdf Canadian Association of Radiology. Accessed June 30, 2017.
- 3) Mainiero M, Bailey L, D’Orsi C, et al. ACR Appropriateness Criteria® Palpable Breast Abnormality. Available at: <https://acsearch.acr.org/docs/69495/Narrative/> American College of Radiology. Accessed June 30, 2017.
- 4) CAR Diagnostic and Problem Solving Evaluation. Available at: http://www.car.ca/uploads/standards%20guidelines/car_breastimagingguidelines_2016_en.pdf Accessed June 30, 2017.
- 5) Canadian Association of Radiologists Imaging Referral Guidelines. Available at: <http://www.car.ca/en/standards-guidelines/guidelines.aspx> Accessed June 30, 2017.
- 6) D’Orsi DJ, Sickles EA, Mendelson EB, et al. ACR BI-RADS® Atlas, Breast Imaging Reporting and Data System. Reston, VA. American College of Radiology, 2013.

Chapter 8 – Cardiovascular

Normal, Labelled, Chest x-ray, with Cardiovascular Structures

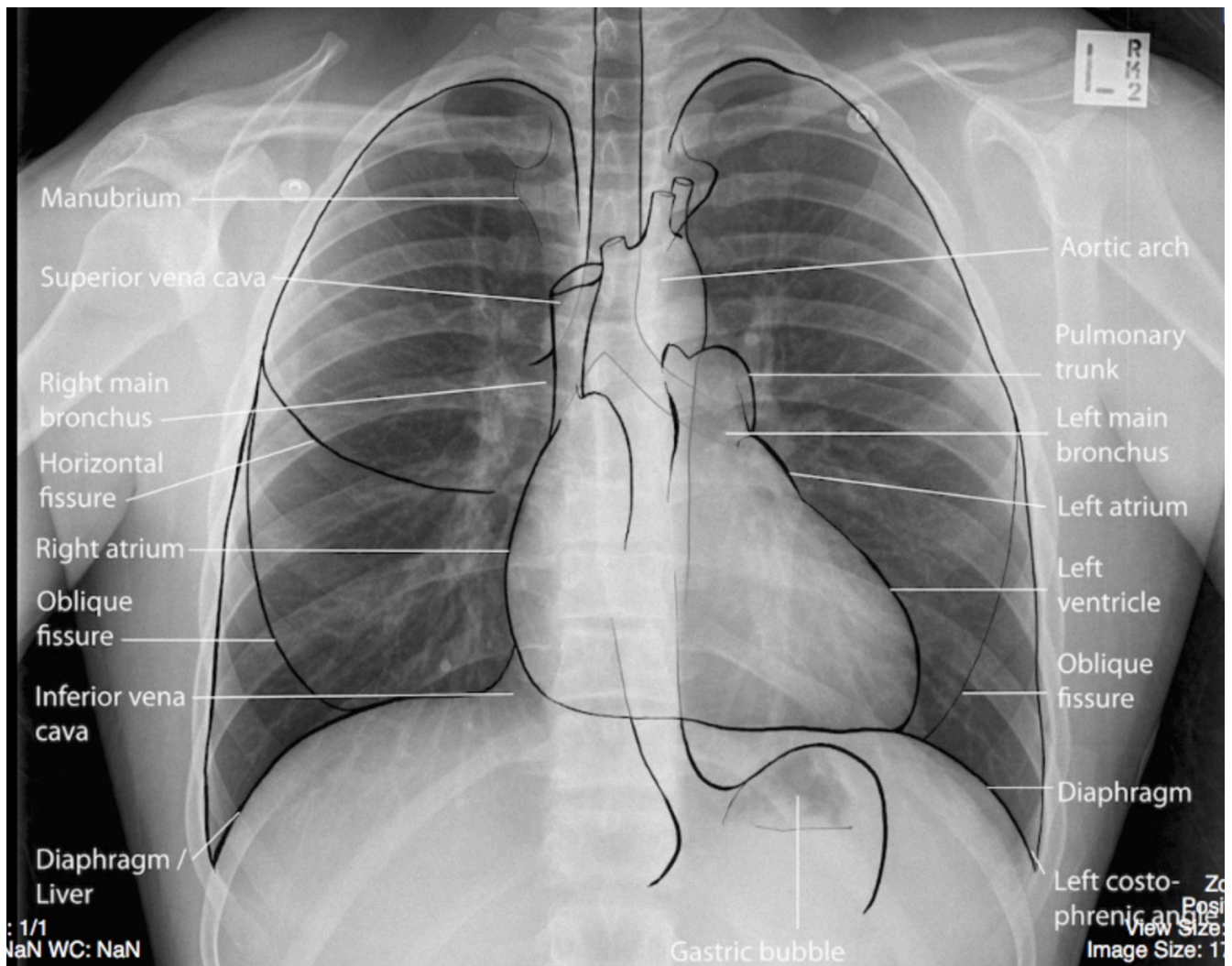


Figure 8.1 Normal PA Chest x-ray, Labelled

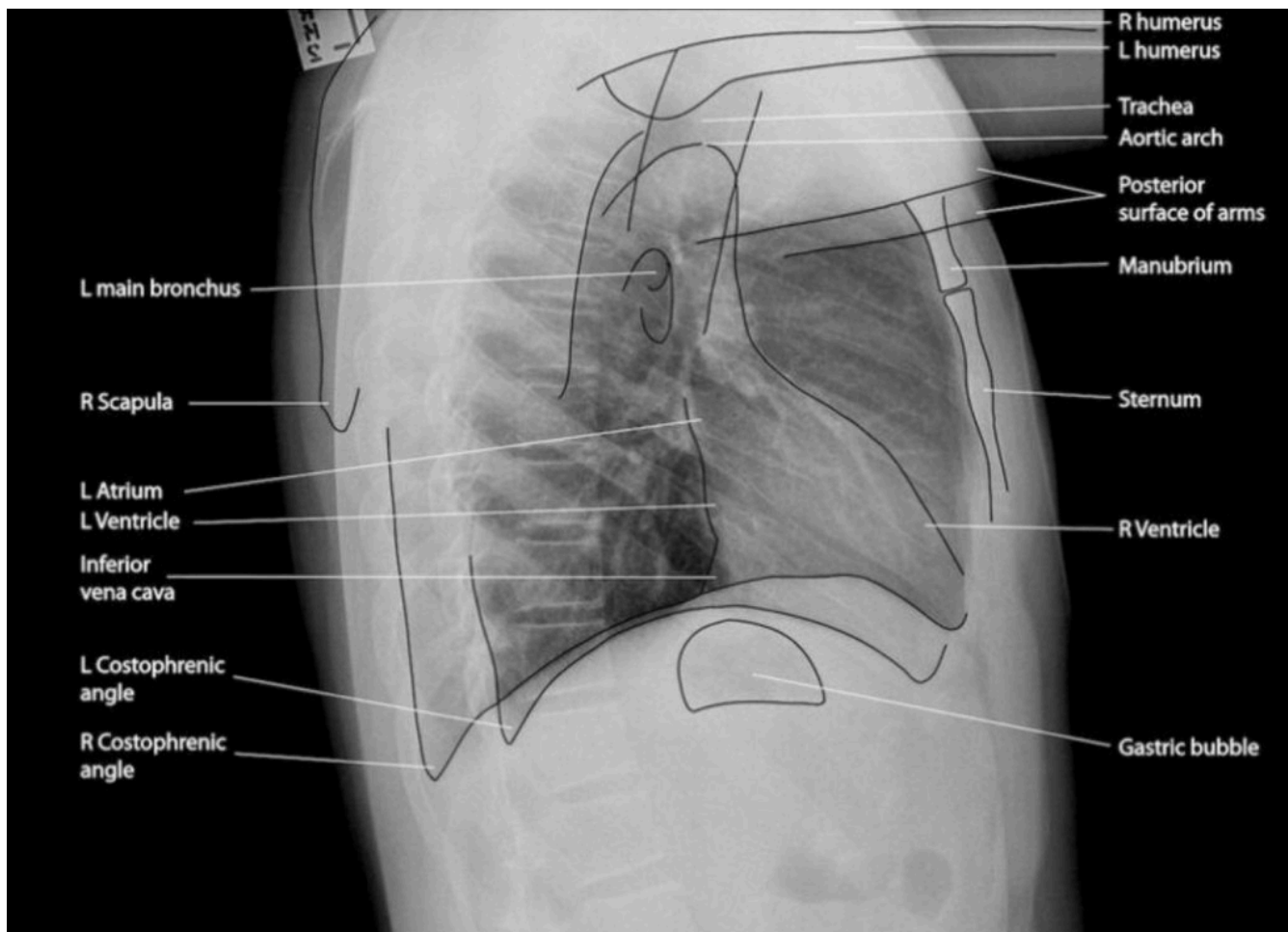


Figure 8.2 Normal Lateral Chest x-ray, Labelled

ODIN Link for Normal Chest x-ray images, Figures 8.1 and 8.2: <https://mistr.usask.ca/odin/?caseID=20170103165555291>

Attributions

Figure 8.1 [Normal PA Chest x-ray](#), Labelled. Line drawing – #FOAMed Medical Education Resources by LITFL is licensed under a [CC-BY-NC-SA 4.0](#) License.

Figure 8.2 [Normal Lateral Chest x-ray](#), Labelled. Line drawing – #FOAMed Medical Education Resources by LITFL is licensed under a [CC-BY-NC-SA 4.0](#) International License.

Enlarged Cardiac Silhouette

Case

Enlargement of the Cardiac Silhouette, Cause Not Yet Diagnosed

Clinical:

History: This patient presented for an Annual Physical Examination. Mild hypertension for 5 years, medicated.

Symptoms: None

Signs: Chest palpation suggested cardiac enlargement. A quiet diastolic murmur was heard.

DDx:

Cardiac – valvular, ischemic, cardiomyopathy

Epicardial – effusion

Extracardiac – fat, mass, fluid, pectus excavatum

Poor Inspiration

Portable imaging technique

Imaging Recommendation

Chest x-ray

ODIN Link for Enlarged Cardiac Silhouette images: <https://mistr.usask.ca/odin/?caseID=20160107114411264>

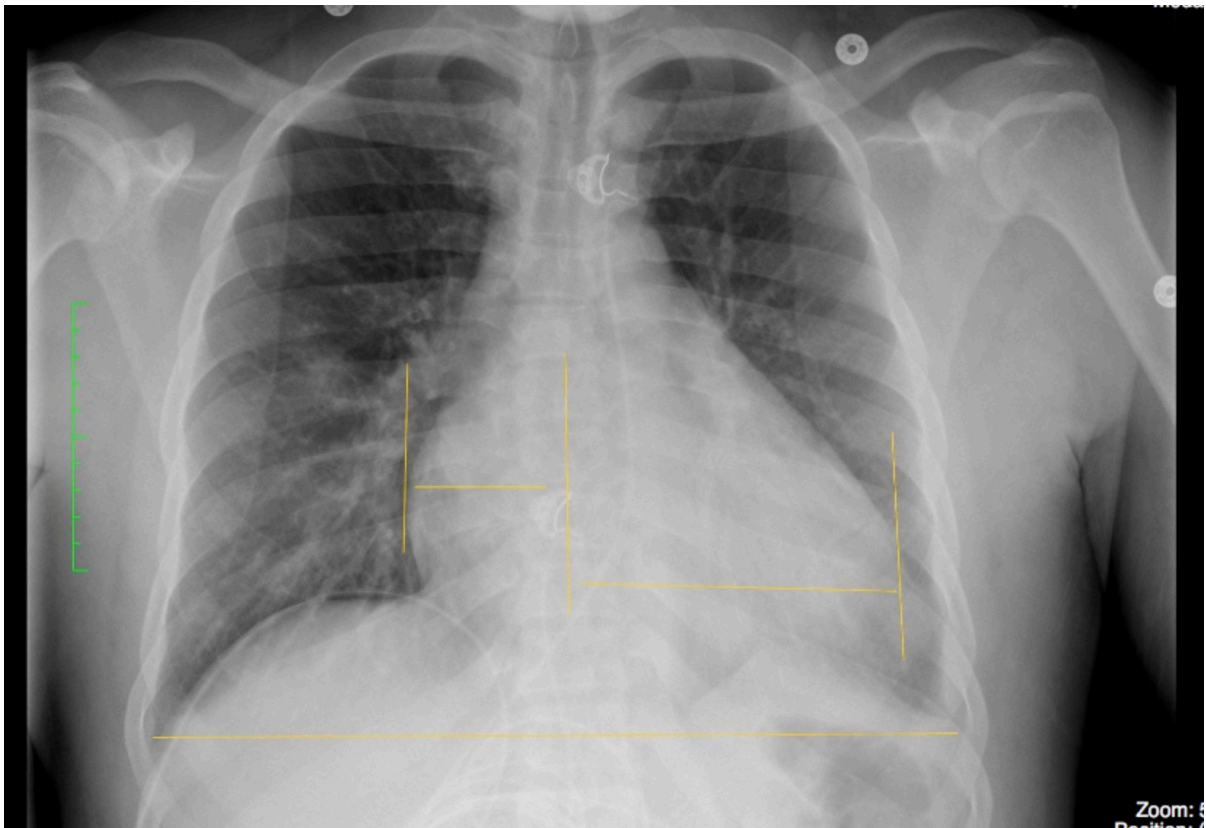


Figure 8.3A Chest x-ray with an enlarged heart shadow, method 1.

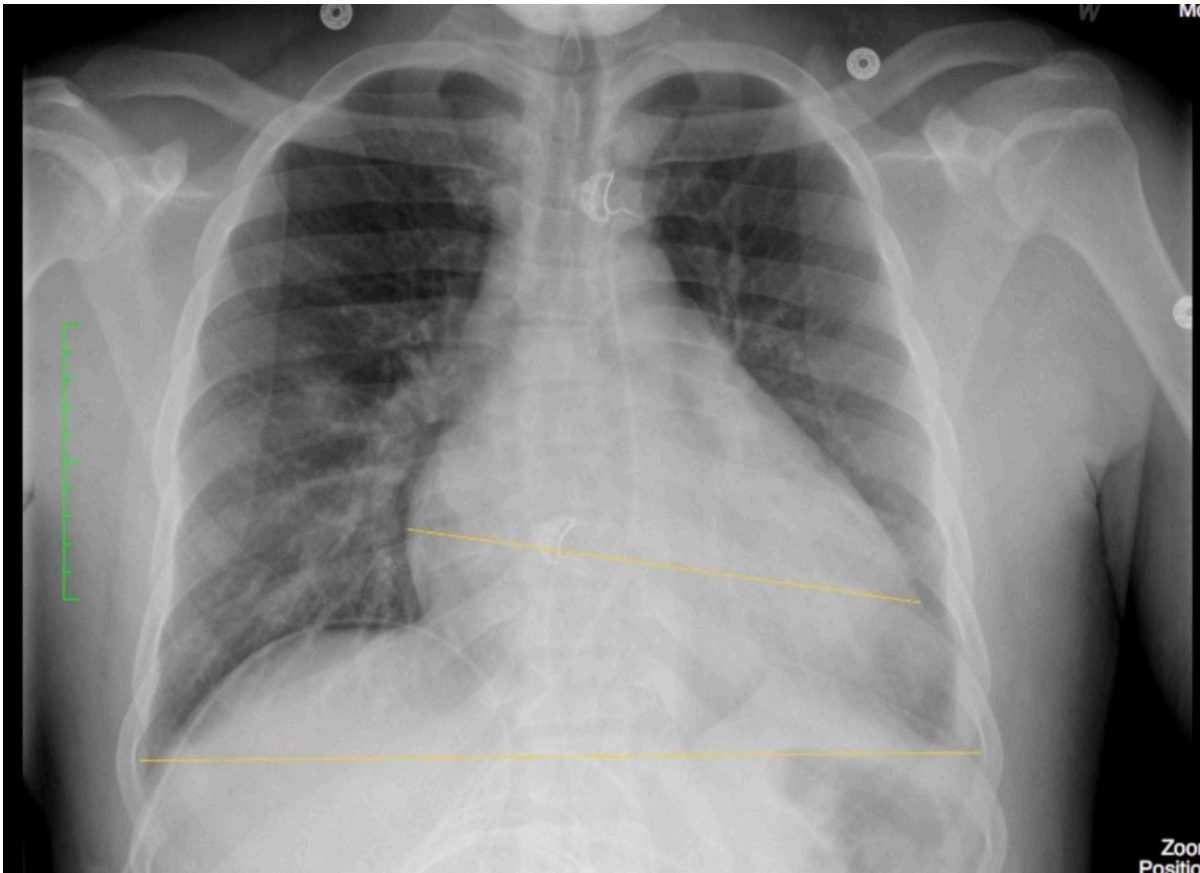


Figure 8.3B Chest x-ray with an enlarged heart shadow, method 2.

Image Assessment

Findings:

The cardiac silhouette was enlarged. The Cardio-Thoracic Ratio (CTR) measured 31/50 cm – 62%. A normal ratio should be less than 50%.

The lungs and pleural spaces were clear. No evidence of alveolar or interstitial edema. No evidence of aortic or coronary artery calcification.

Interpretation:

Enlargement of the cardiac silhouette requiring further investigation. Further investigation with ECG, and Echocardiography, were pending.

Diagnosis:

Enlargement of the Cardiac Silhouette, Cause Not Yet Diagnosed

Discussion:

Potential causes of Enlargement of the Cardiac Silhouette include:

- a) Cardiac chamber(s) (atria, ventricles) – related to valvular disease or cardiomyopathy (ischemic, dilated), congenital heart anomalies, other
- b) Pericardium – pericardial effusion, pericardial tumor
- c) Epicardial – fat, tumor
- d) Anterior Mediastinal mass
- e) Expiratory phase x-ray
- f) PA – Portable x-ray technique

Hence, further history, acquisition of old imaging and subsequent further testing, including imaging, will be required.

Attributions

Figure 8.3A Chest x-ray with an enlarged heart shadow by Dr. Brent Burbridge MD, FRCPC, University Medical Imaging Consultants, College of Medicine, University of Saskatchewan is used under a [CC-BY-NC-SA 4.0](#) license.

Figure 8.3B Chest x-ray with an enlarged heart shadow by Dr. Brent Burbridge MD, FRCPC, University Medical Imaging Consultants, College of Medicine, University of Saskatchewan is used under a [CC-BY-NC-SA 4.0](#) license.

Aortic Dissection and Aneurysm

ACR – Acute Chest Pain – Suspected Aortic Dissection

Case

Type B Aortic Dissection and Aneurysm

Clinical:

History – The patient reported the sudden onset of a “tearing” pain in his chest that began about one hour ago. It was still present and he rated the pain as 7/10 in severity.

Symptoms: “Tearing” chest pain. Persistent, radiating between his shoulder blades.

Signs: Tachycardia. No murmur detected. No blood pressure disparity detected.

DDx:

Aortic Dissection

Aortic Aneurysm

Myocardial Infarction

Pulmonary Embolism

Imaging Recommendation

[ACR Recommendations for Acute Chest Pain – Suspected Aortic Dissection](#)

Chest X-ray

Followed by Contrast Enhanced CT of the Chest, Abdomen and Pelvis, if warranted

ODIN Link for Enlarged Aorta, Chest x-ray, Figure 8.4A and B: <https://mistr.usask.ca/odin/?caseID=20170414181501895>

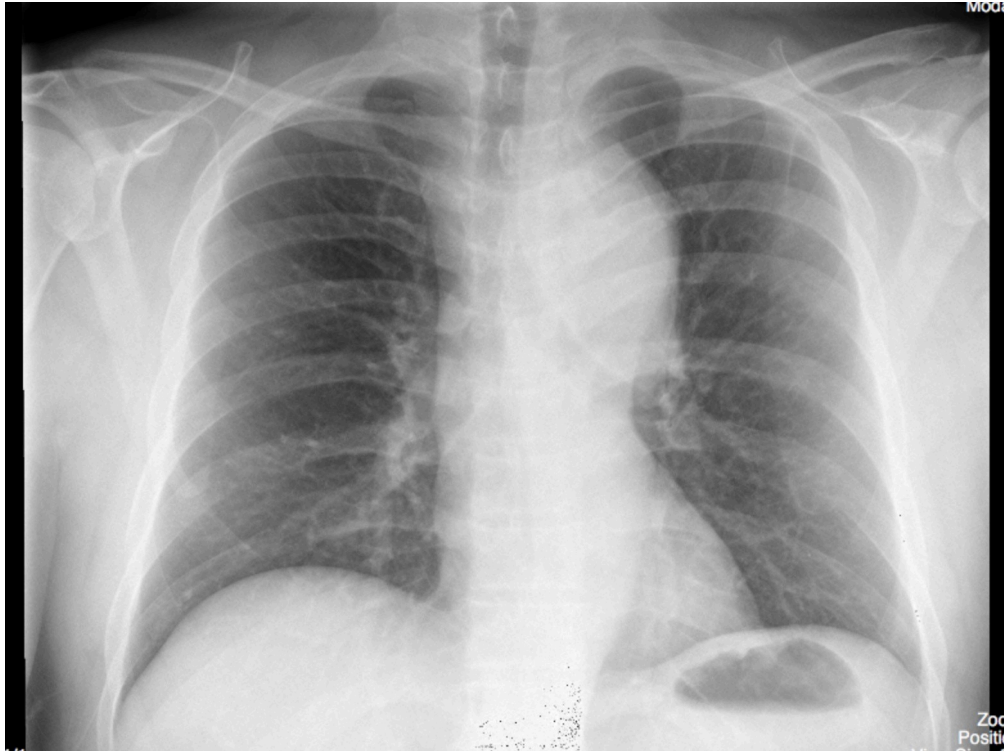


Figure 8.4A Chest x-ray: AP, enlarged aortic knob.

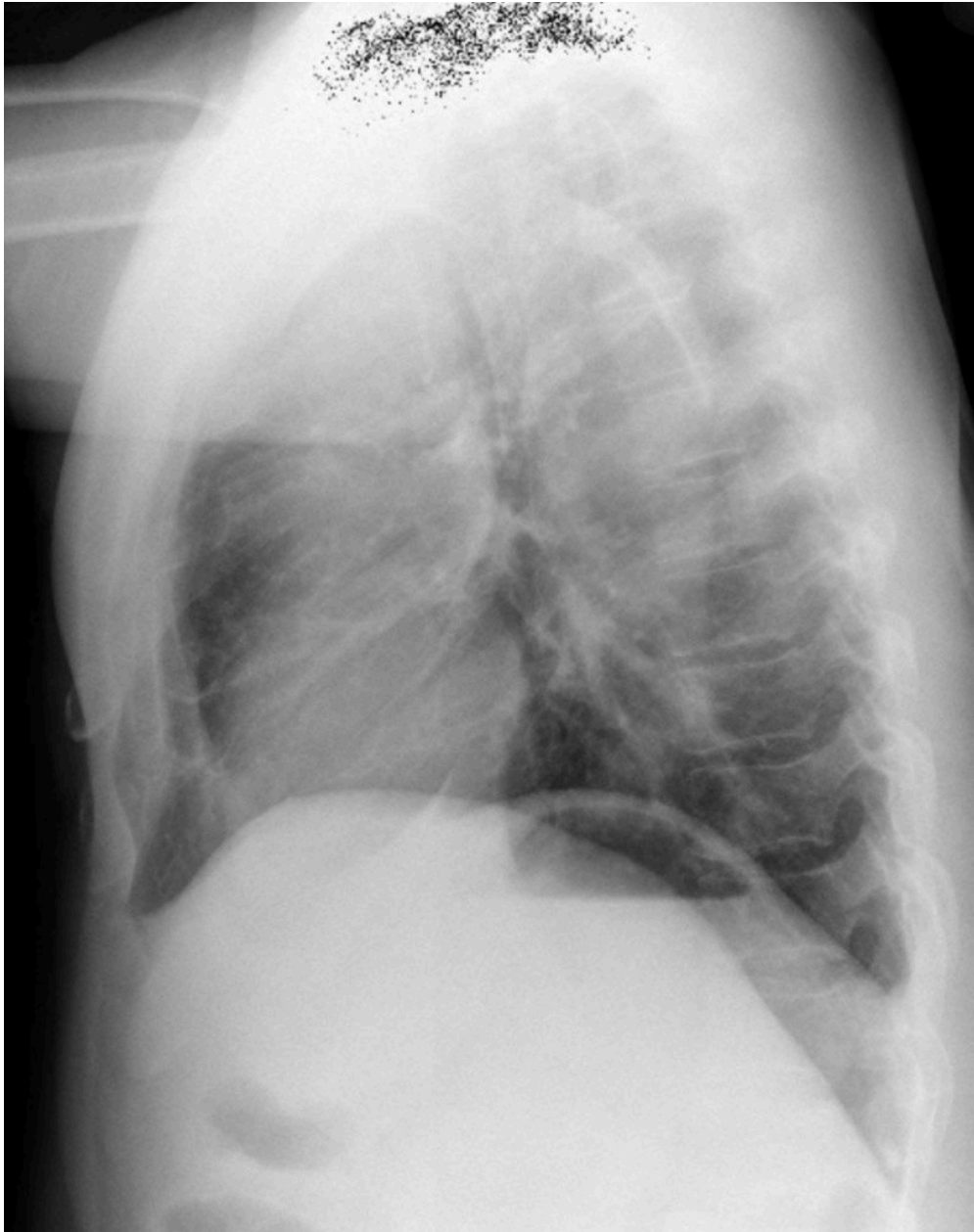


Figure 8.4B Chest x-ray: Lateral, enlarged ascending and arch aorta.

ODIN Link for Aortic CTA, Figure 8.5: <https://mistr.usask.ca/odin/?caseID=20170414181619401>

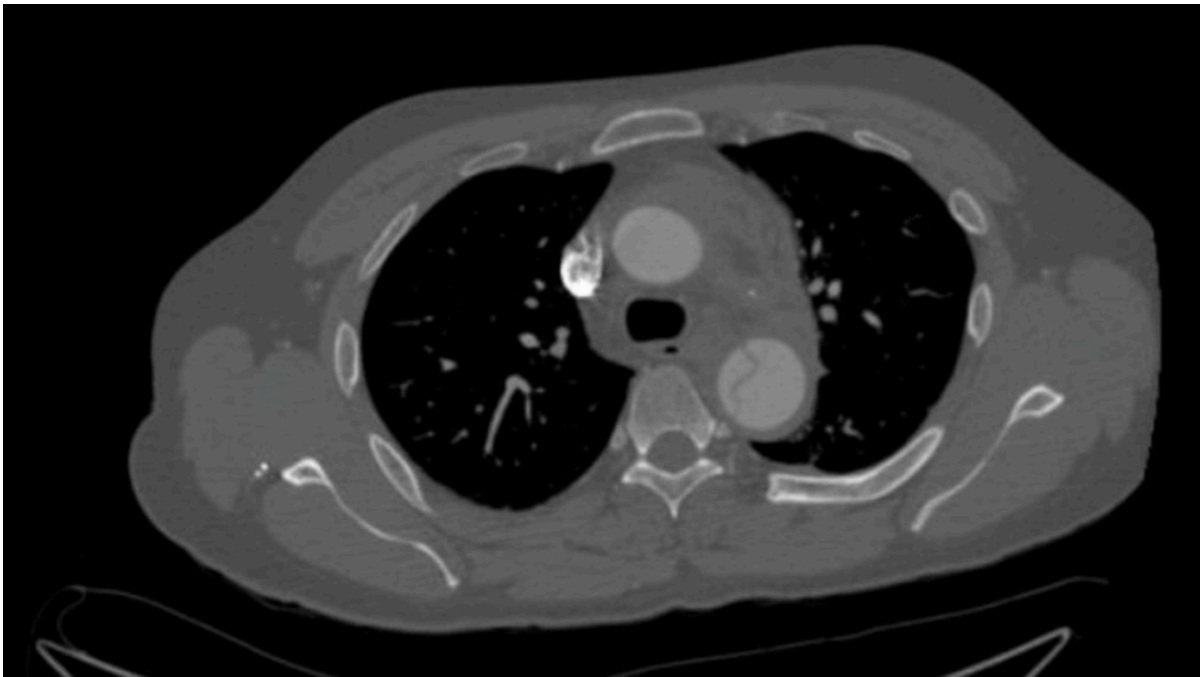


Figure 8.5 Contrast enhanced Computed Tomography of the Chest, Abdomen and Pelvis, intimal flap seen associated with aortic dissection.

Imaging Assessment

Chest x-ray

Findings:

There was a left, apical, pleural cap. The upper mediastinum was widened. The aortic knob was very enlarged and had displaced the trachea to the right. The cardiac silhouette was not enlarged. The lungs were clear.

Interpretation:

The findings suggest aortic enlargement with the apical pleural cap due to secondary mediastinal hematoma. Given the history, the possibility of an aortic dissection, causing the aortic enlargement, must also be considered.

CT

Findings:

Contrast enhancement was visualized in the arterial phase. There was a thin, linear, filling defect in the aorta that originates just distal to the subclavian artery. This linear defect was present to just cranial of the celiac axis and then became non-visible. There was a false lumen in the medial aorta related to the linear filling defect. The findings were consistent with an aortic wall intimal flap and associated dissection that originates just distal to the subclavian artery.

Additionally, there was a small protuberance of the aorta on the lateral aortic knob which was associated with

mediastinal hematoma. This may well represent a pseudoaneurysm related to the dissection. No other significant findings.

Interpretation:

Type B aortic dissection with a secondary aneurysm and pseudoaneurysm with mediastinal hematoma.

Diagnosis:

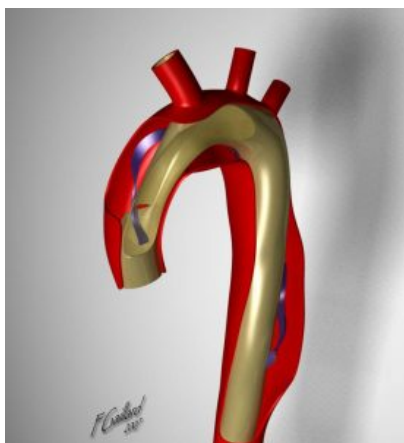
Type B Aortic Dissection

Discussion:

A tear in the aorta between the intima and the media allows blood to dissect the wall for varying lengths of the aorta, usually between the intima and media at the site of the tear but the pulsatile blood then usually dissects into the media at the junction of the inner 1/3 and the middle 1/3. The dissection may rarely perforate the media and enter in to the adventitia, possibly resulting in pseudoaneurysm formation. In general, patients with aortic dissection most commonly are hypertensive, but they may have an underlying condition that can predispose to dissection, i.e.:

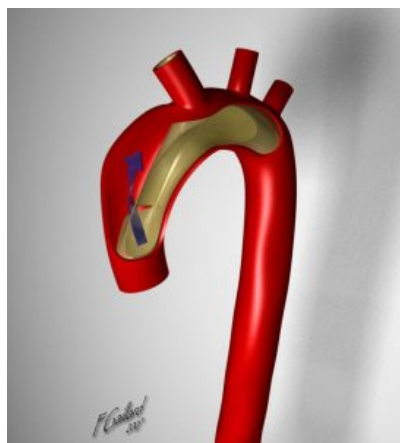
- Cystic medial degeneration
- Atherosclerosis
- Marfan syndrome
- Ehlers-Danlos syndrome
- Trauma
- Syphilis

Aortic dissection most often originates in the ascending aorta (*Stanford type A*)(*DeBakey II*), extending into the descending aorta (*Stanford A*)(*DeBakey I*), or they may only involve the descending aorta (*Stanford type B*)(*DeBakey III*).



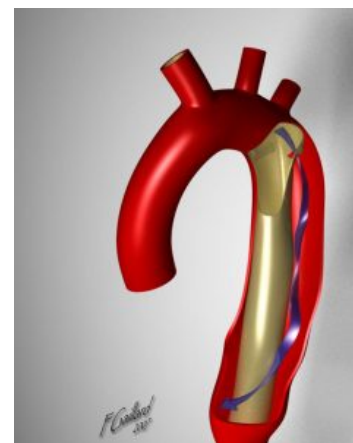
DeBakey I

Stanford A



DeBakey II

Stanford A



DeBakey III

Stanford B

Table 8.1 Classification of Aortic Dissection

Conventional radiographs are not diagnostically reliable, but they may point to the diagnosis when several imaging findings occur together, especially in the proper clinical setting.

Aortic Aneurysm

An aneurysm represents a region of the aorta that is larger than normal size by more than 1.5x. If the aneurysm has all three layers of the arterial wall it is a true aneurysm. It may be concentric (fusiform) or eccentric (saccular) in shape. The aneurysm may be partially calcified and may contain thrombus in some cases. If the aneurysm lacks all three layers of the aorta it is a false or pseudo-aneurysm. Pseudo-aneurysms for the most part represent a tear of the aortic wall with the resulting hematoma contained by the adjacent soft tissues.

The most common cause of aneurysms are atherosclerosis and hypertension. Some are associated with syndromes and other conditions such as Marfan syndrome or syphilis. Dissections of the aorta may also present with imaging findings of aneurysm.

When aneurysms reach a certain diameter they are more prone to rupture. For example, an abdominal aortic aneurysm larger than 5 cm in diameter has an annual risk of rupture of roughly 10%. This increases to an annual risk of 25% for abdominal aortic aneurysms larger than 6 cm in diameter. Imaging plays a major role in the detection, characterization, and follow-up of aortic aneurysms.

X-ray findings of Dissection may include:

- “Widening of the mediastinum” – this has low sensitivity as it is often difficult to diagnose on portable, supine radiographs and it is present in only 20 – 25% of those with dissection.
- Double aortic knob

- Irregular aortic knob
- Left pleural effusion due to a hemothorax.
- Displacement of intimal calcification (1cm or >) is possible. Comparison to previous x-rays may help to determine if this sign is present.

Dissection Classification

Dissection in Ascending Aorta Only; known as:

- Stanford Type A
- DeBakey II

Dissection in Ascending and Descending Aorta; known as:

- Stanford Type A
- DeBakey I

Dissection in Descending Aorta Only; known as:

- Stanford Type B
- DeBakey III

Attributions

Figure 8.4A Chest x-ray: AP, enlarged aortic knob by Dr. Brent Burbridge MD, FRCPC, University Medical Imaging Consultants, College of Medicine, University of Saskatchewan is used under a [CC-BY-NC-SA 4.0](#) license.

Figure 8.4B Chest x-ray: Lateral, enlarged ascending and arch aorta by Dr. Brent Burbridge MD, FRCPC, University Medical Imaging Consultants, College of Medicine, University of Saskatchewan is used under a [CC-BY-NC-SA 4.0](#) license.

Figure 8.5 Contrast enhanced Computed Tomography of the Chest, Abdomen and Pelvis, intimal flap seen associated with aortic dissection by Dr. Brent Burbridge MD, FRCPC, University Medical Imaging Consultants, College of Medicine, University of Saskatchewan is used under a [CC-BY-NC-SA 4.0](#) license.

Figures in Table 8.1: DeBakey I, DeBakey II, and DeBakey III, courtesy of Dr Yuranga Weerakkody and A.Prof Frank Gaillard, Radiopaedia <https://radiopaedia.org/articles/aortic-dissection> and were originally published under a [CC-BY-NC-SA 3.0](#) license.

Congestive Heart Failure

ACR – Dyspnea – Suspected Cardiac Origin

Case

Congestive Heart Failure

Clinical:

History: This 69 year old female patient was receiving medication for hypertension. No other medications. No previous problems with shortness of breath.

Symptoms: The patient reported progressively worsening exercise intolerance that usually ends with shortness of breath. Walking a block makes her very short of breath. No chest pain reported. The patient sleeps with two pillows as she finds that she wakes up short of breath otherwise. She has mild, ankle, pitting edema.

Signs: The patient had good color and was not cyanotic. The jugular veins in her neck were prominent when lying flat. Auscultation revealed mild rhonchi. She had pitting edema from the feet to the knees, bilaterally. No other findings.

Laboratory:

The hemoglobin was minimally decreased and there was evidence of microcytic anemia. Nil else.

DDx:

Dyspnea of possible cardiac origin.

Imaging Recommendation

[ACR – Dyspnea – Suspected Cardiac Origin](#)

Chest X-ray

ODIN Link Congestive Heart Failure images, Figure 8.7A and B: <https://mistr.usask.ca/odin/?caseID=20160318160706756>

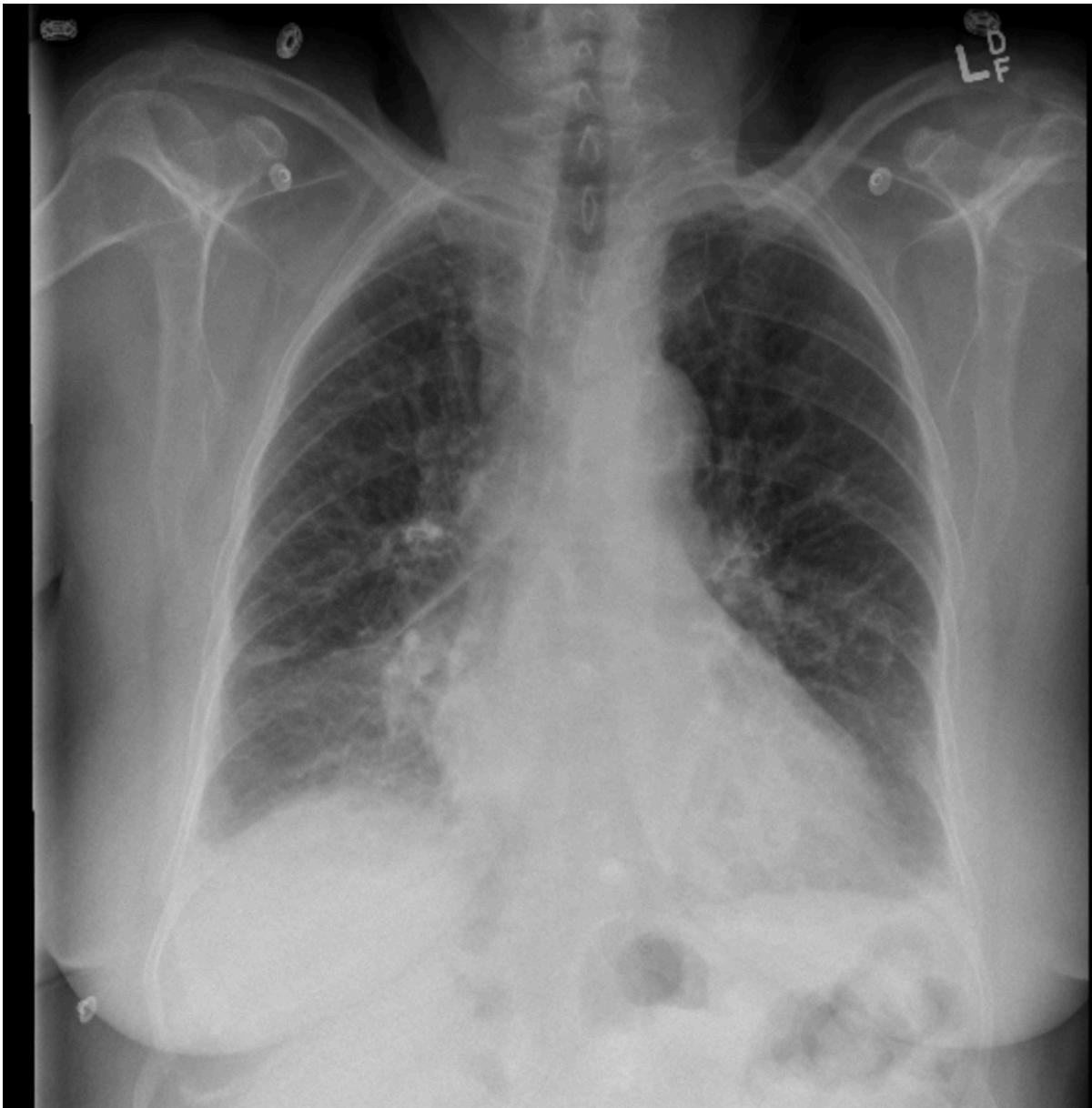


Figure 8.7A PA Chest x-ray displaying CHF.

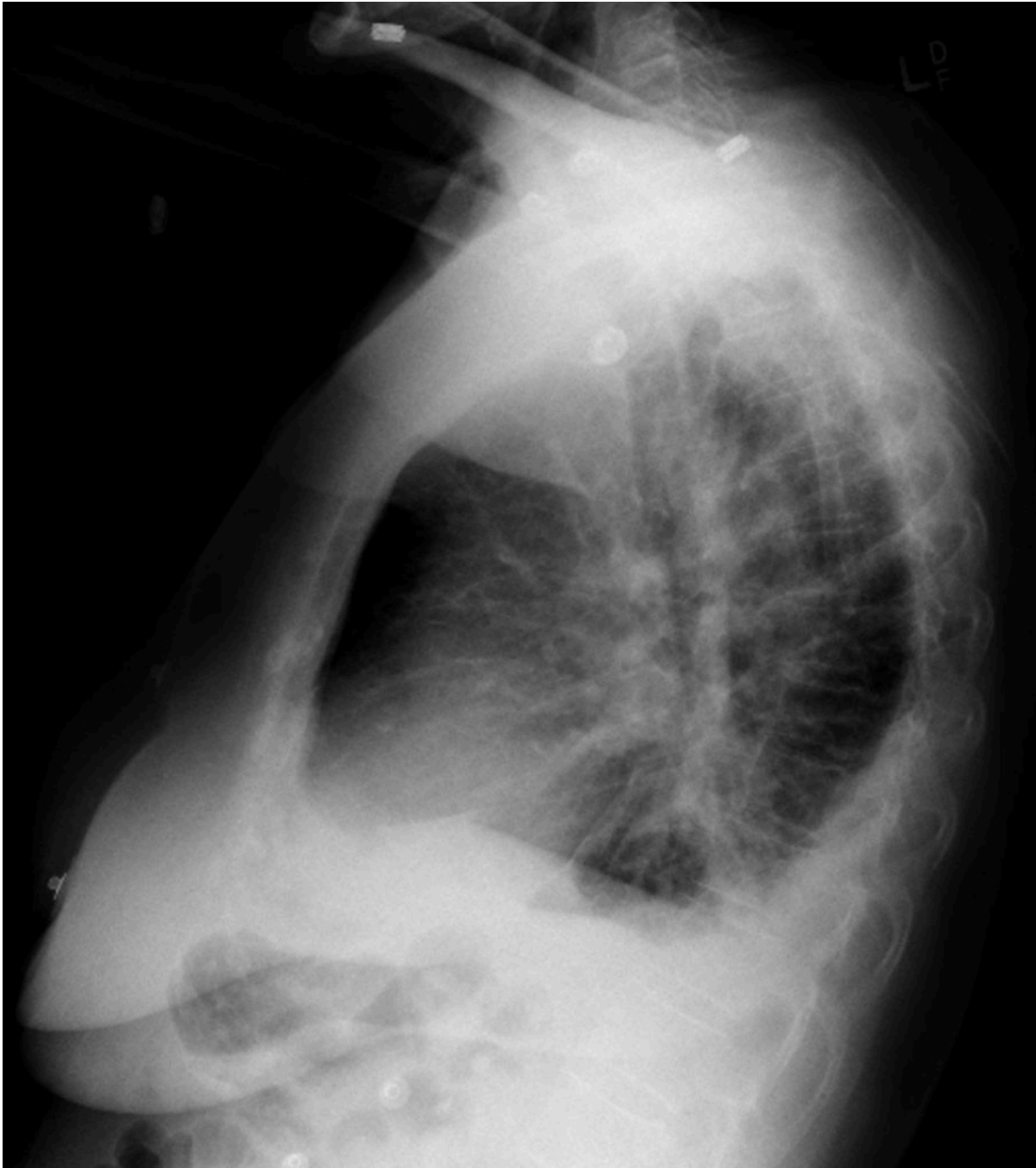

Figure 8.7B Lateral Chest x-ray displaying CHF.

Imaging Assessment

Chest x-ray:

Findings:

The cardiac silhouette was enlarged. There was bronchial wall cuffing and prominence of the upper lobe vessels consistent with vascular redistribution and interstitial edema. The lower lobe vessels were also partially obscured

due to the interstitial edema and possibly mild alveolar edema. Subpleural edema resulted in prominence of the lung fissures. Small-moderate, bilateral, pleural effusions were seen.

Interpretation:

Cardiac silhouette enlargement with secondary findings of Congestive Heart Failure.

Diagnosis:

Congestive Heart Failure

Discussion:

Causes:

- Ischemic heart disease
- Hypertension
- Cardiomyopathy
- Cardiac valvular lesions, such as aortic stenosis and mitral stenosis
- Arrhythmia
- Thyrotoxicosis
- Severe anemia
- Left-to-right shunt

The changes of congestive heart failure are progressive when myocardial functionality is impaired. The early changes occur in the interstitial tissues but spread to the alveolar space and the pleural space.

Pathophysiology:

The myocardium is incapable of ejecting sufficient blood to keep up with the demands of the body for oxygenated blood. Starling's equation becomes altered and there is often a pressure imbalance that results, creating back pressure into the pulmonary circulation. This may be due to hypertension and increased afterload or myocardial damage from ischemia, or cardiomyopathy.

X-ray findings may include:

- Thickened interlobular lung septa (Kerley lines)
- Pulmonary vascular re-distribution (upper lobe vessel enlargement)
- Peri-hilar haziness

- Bronchial wall cuffing (thickening)
- Subfissural edema
- Pleural effusions
- Alveolar edema

Attributions

Figure 8.7A PA Chest x-ray displaying CHF by Dr. Brent Burbridge MD, FRCPC, University Medical Imaging Consultants, College of Medicine, University of Saskatchewan is used under a [CC-BY-NC-SA 4.0](#) license.

Figure 8.7B Lateral Chest x-ray displaying CHF by Dr. Brent Burbridge MD, FRCPC, University Medical Imaging Consultants, College of Medicine, University of Saskatchewan is used under a [CC-BY-NC-SA 4.0](#) license.

Cardiovascular – References

- 1) Line drawings – #FOAMed Medical Education Resources by Life in the Fast Lane (LITFL) is licensed under a Creative Commons Attribution-Non-Commercial-ShareAlike 4.0 International License. Available at <https://lifeinthefastlane.com/investigations/cxr-normal/> Accessed, June 30, 2017.
- 2) Jill E. Jacobs, MD; Larry A. Latson Jr., MS, MD; Suhny Abbara, MD, et al. ACR Appropriateness Criteria® Acute Chest Pain – Suspected Aortic Dissection. American College of Radiology. Available at <https://acsearch.acr.org/docs/69402/Narrative/> Accessed, June 30, 2017.
- 3) [Learning radiology : recognizing the basics](#). William Herring author. Elsevier 2016 *Online access USask Library*. http://usl-primo.hosted.exlibrisgroup.com/primo_library/libweb/action/search.do?vid=USASK Accessed, June 30, 2017.
- 4) Jens Vogel-Claussen, MD; Amany S. M. Elshafee, BCh, MB; Jacobo Kirsch, MD, et al. ACR Appropriateness Criteria® Dyspnea – Suspected Cardiac Origin. Available at <https://acsearch.acr.org/docs/69407/Narrative/> Accessed June 30, 2017.
- 5) [Grainger and Allison's diagnostic radiology : a textbook of medical imaging](#). Andy Adam editor.; Adrian K. Dixon editor.; Jonathan H. Gillard 1964- editor.; Cornelia Schaefer-Prokop editor.; David J Allison; Elsevier (Firm) 2015, *Online access USask Library*. http://usl-primo.hosted.exlibrisgroup.com/primo_library/libweb/action/search.do?vid=USASK Accessed June 30, 2017.

Chapter 9 – Chest

Normal, Labelled, Chest x-ray

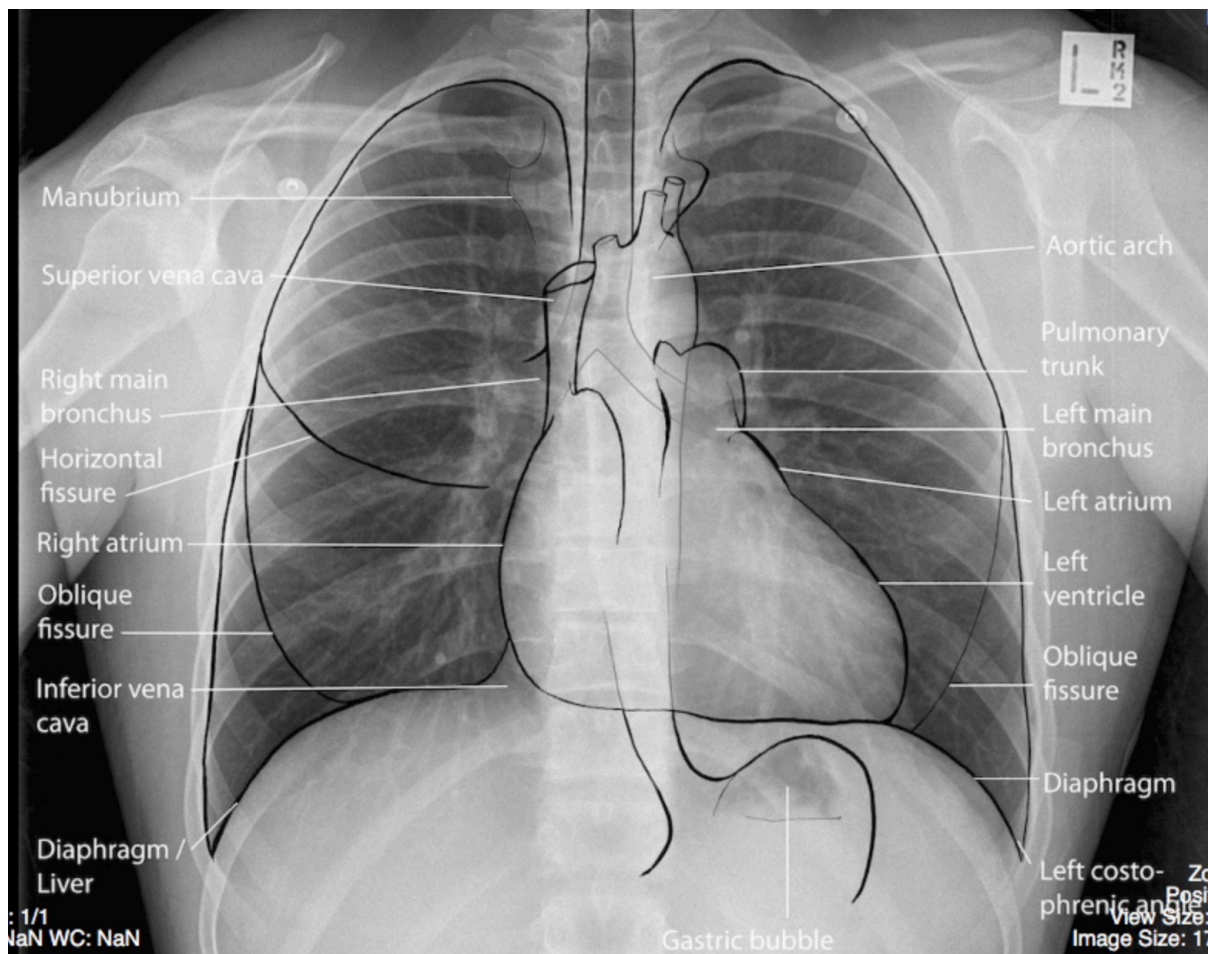


Figure 9.1 Normal PA Chest x-ray, Labelled

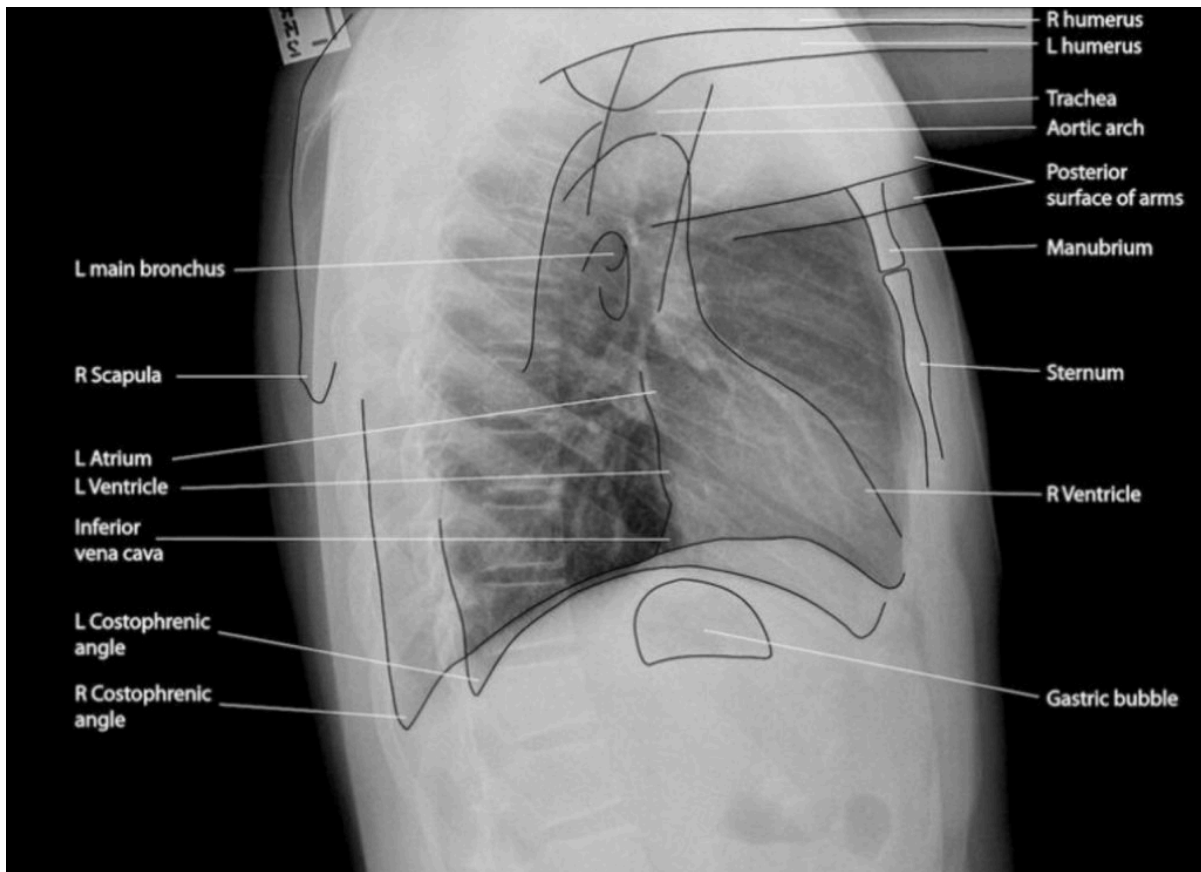


Figure 9.2 Normal Lateral Chest x-ray, Labelled

ODIN Link for Normal Chest x-ray images, Figure 9.1 and 9.2: <https://mistr.usask.ca/odin/?caseID=2017010316555291>

Attributions

Figures 9.1 [Chest x-ray, PA, Line drawing](#) – #FOAMed Medical Education Resources by LITFL is licensed under a [CC-BY-NC-SA 4.0](#) License.

Figure 9.2 [Chest x-ray, Lateral, Line drawing](#) – #FOAMed Medical Education Resources by LITFL is licensed under a [CC-BY-NC-SA 4.0](#) License.

Tubes and Catheters

All inserted or implanted medical devices have some form of identifiable markings embedded in them that allows for localization of the device on radiographs. X-ray imaging is the best modality for localization and identification of these types of medical devices.

Tubes and Catheters

Endotracheal Tube

An endotracheal tube (ET) helps to provide gases to the lungs in a controlled manner. It can also be used to suction secretions from the airways.

The tube should be in the upper trachea, roughly 3 cm from the carina, and not enter the right or left main stem bronchus. There is a small amount of mobility of the tube noted if the neck is flexed or extended. The endotracheal tube must be closely monitored and daily radiographs are recommended.

ODIN Link for Endotracheal tube, Figure 9.3: <https://mistr.usask.ca/odin/?caseID=20150915221432751>

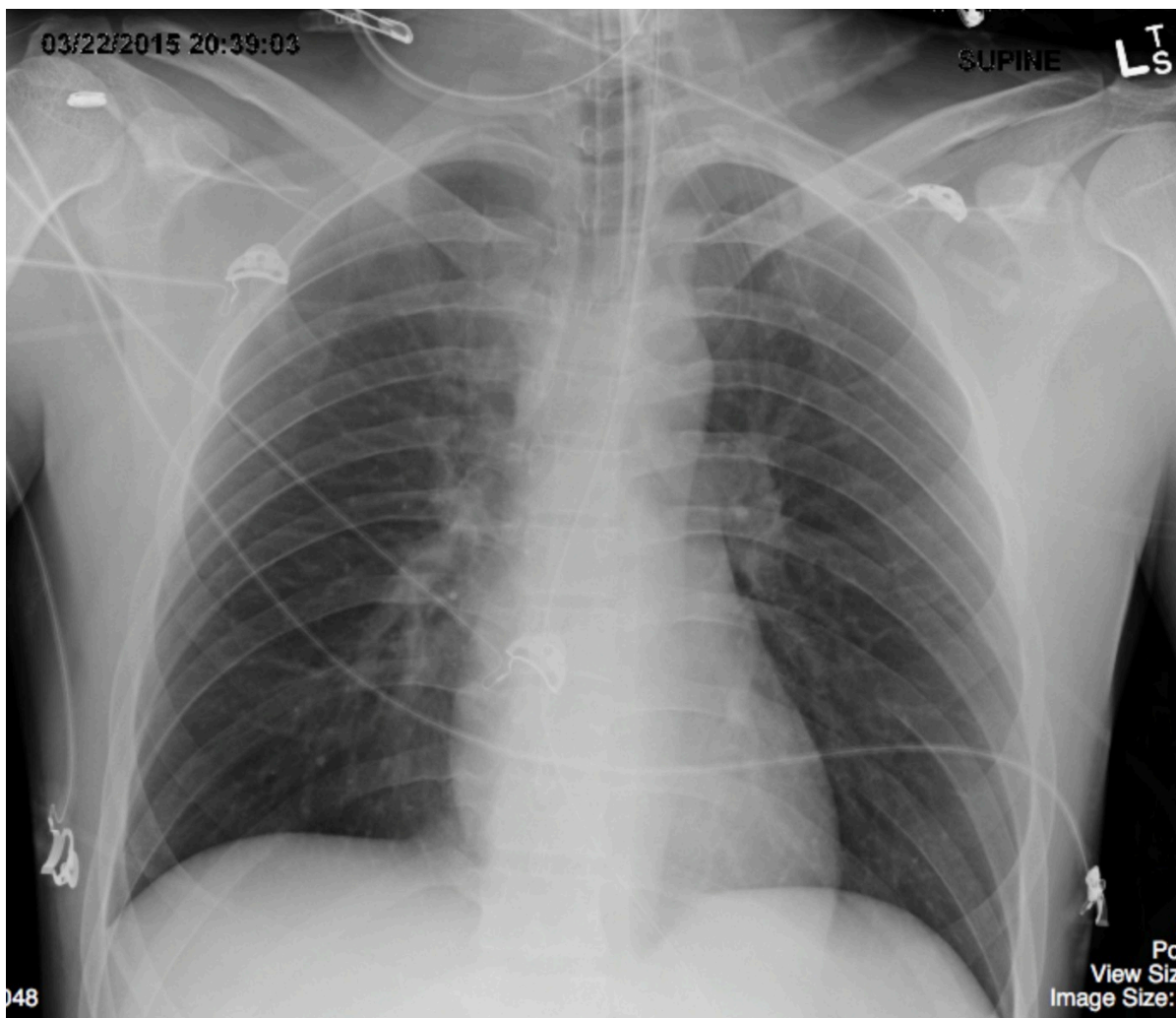


Figure 9.3 X-ray of Endotracheal Tube.

The endotracheal tube is in excellent position, distal to the upper trachea and within 3 cm of the carina. The tube is well centered in the trachea.

Tubes and Catheters

Central Venous Catheters

Any venous catheter placement that results in the tip of the catheter being positioned in the superior or inferior vena cava can be considered to be a central venous catheter.

There are a variety of routes that one can employ to allow the catheter tip to be centrally positioned. The venous access site may be limited due to the type and size of the device i.e. large caliber dialysis type catheters cannot be implanted in the basilic vein.

Best practices dictate that access to the venous system for central vein catheterization should be guided by ultra-

sound, if possible. Use of this technology helps to diminish the risk of inadvertent arterial injury and other adverse events related to inappropriate insertion needle trajectory.

For catheters implanted in the superior vena cava (SVC), the optimal landing point for the catheter tip is considered to be in the SVC just cranial to the right atrium.

ODIN Link for Internal Jugular, Figure 9.4A: <https://mistr.usask.ca/odin/?caseID=20170407155334051>

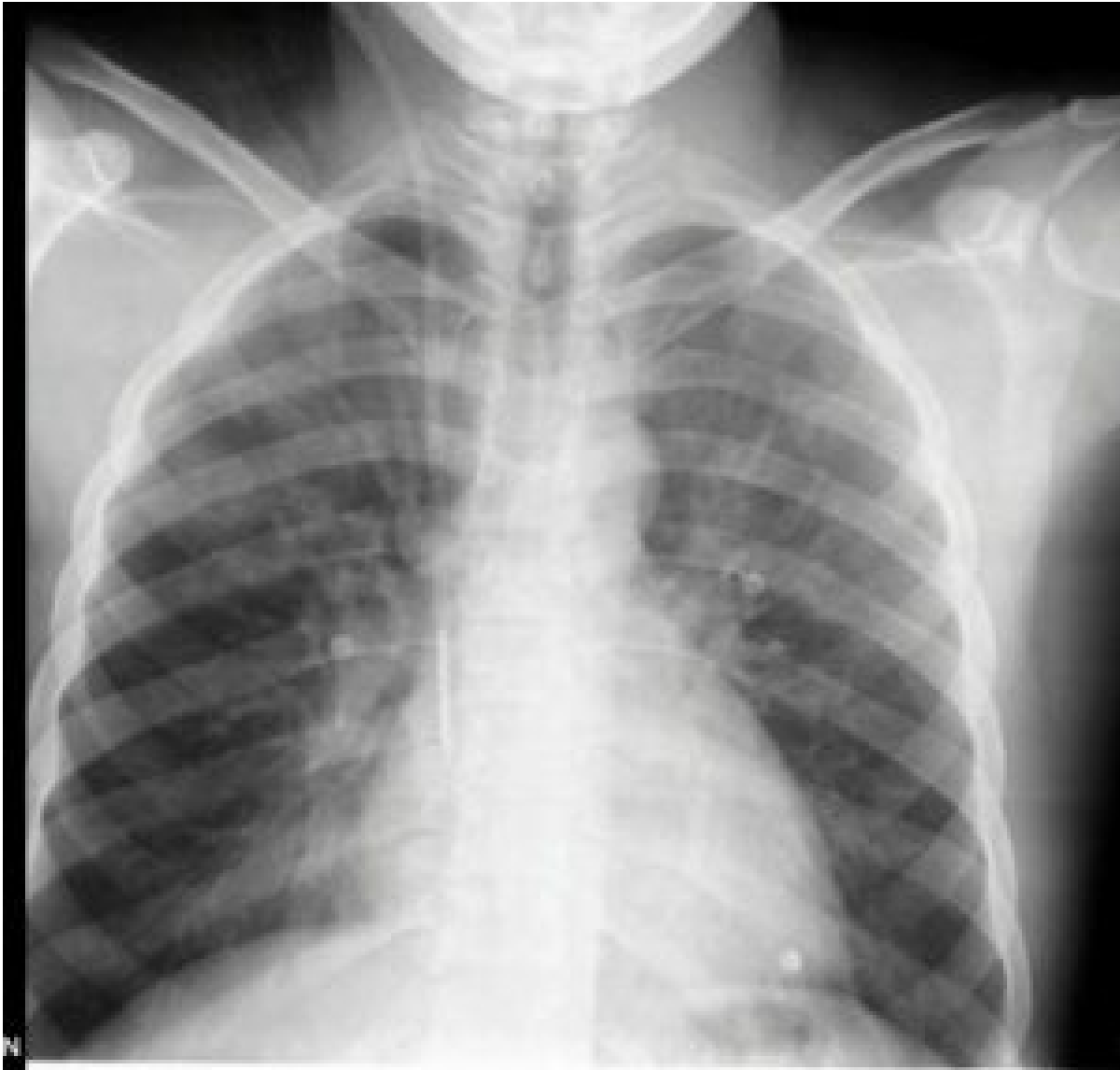

Figure 9.4A Internal Jugular Line.

Internal Jugular Line – The image demonstrated a large caliber catheter the enters into the right neck and terminates with the tip overlying the SVC-Right atrial junction.

ODIN Link for Subclavian Line, Figure 9.4B: <https://mistr.usask.ca/odin/?caseID=20170407155825956>

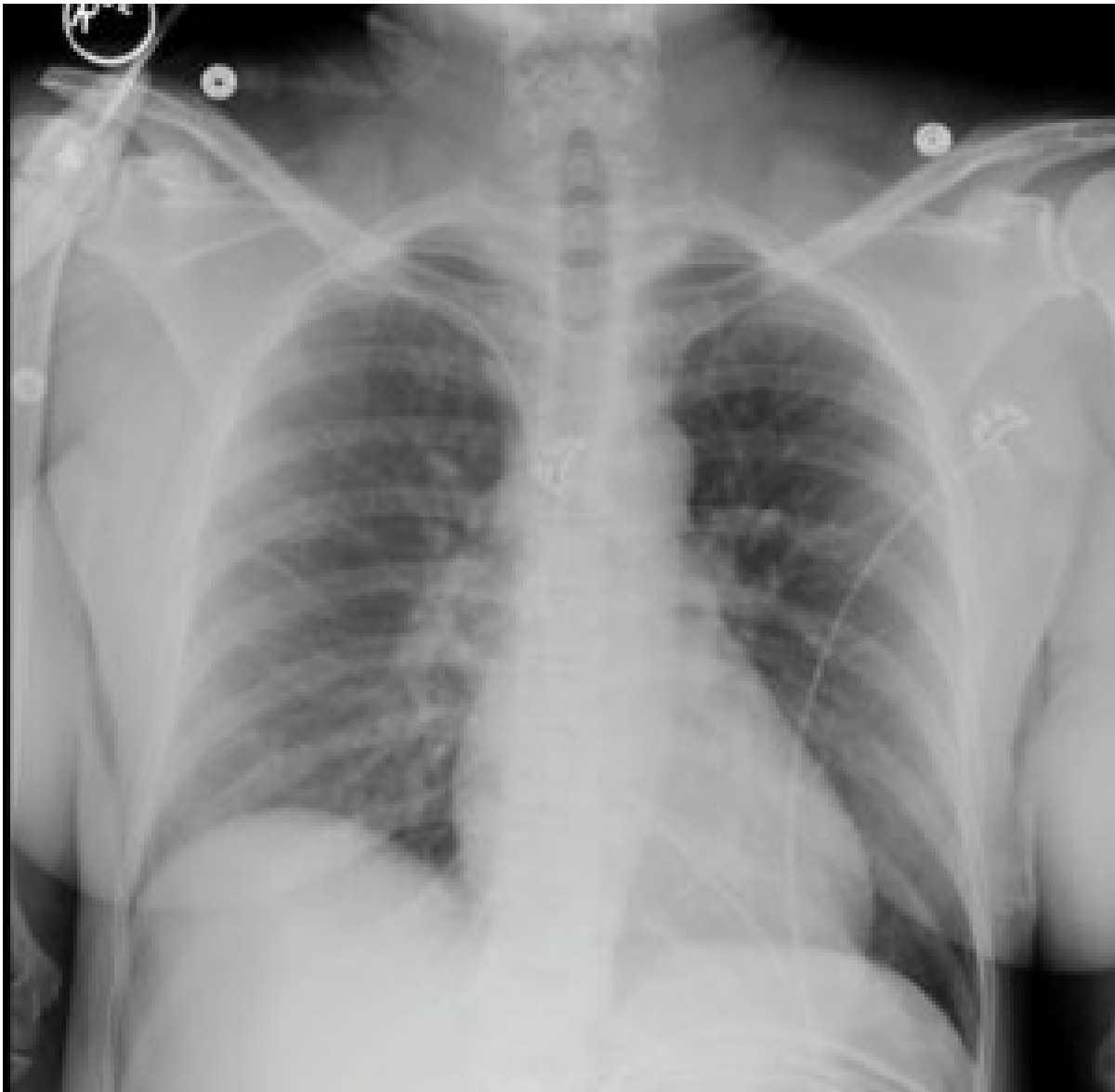

Figure 9.4B Subclavian Line.

Subclavian Line – There was a medium size catheter seen paralleling the under surface of the right clavicle and terminating with the tip overlying the lower mediastinum.

ODIN Link for PICC, Figure 9.4C: <https://mistr.usask.ca/odin/?caseID=20150605095210559>

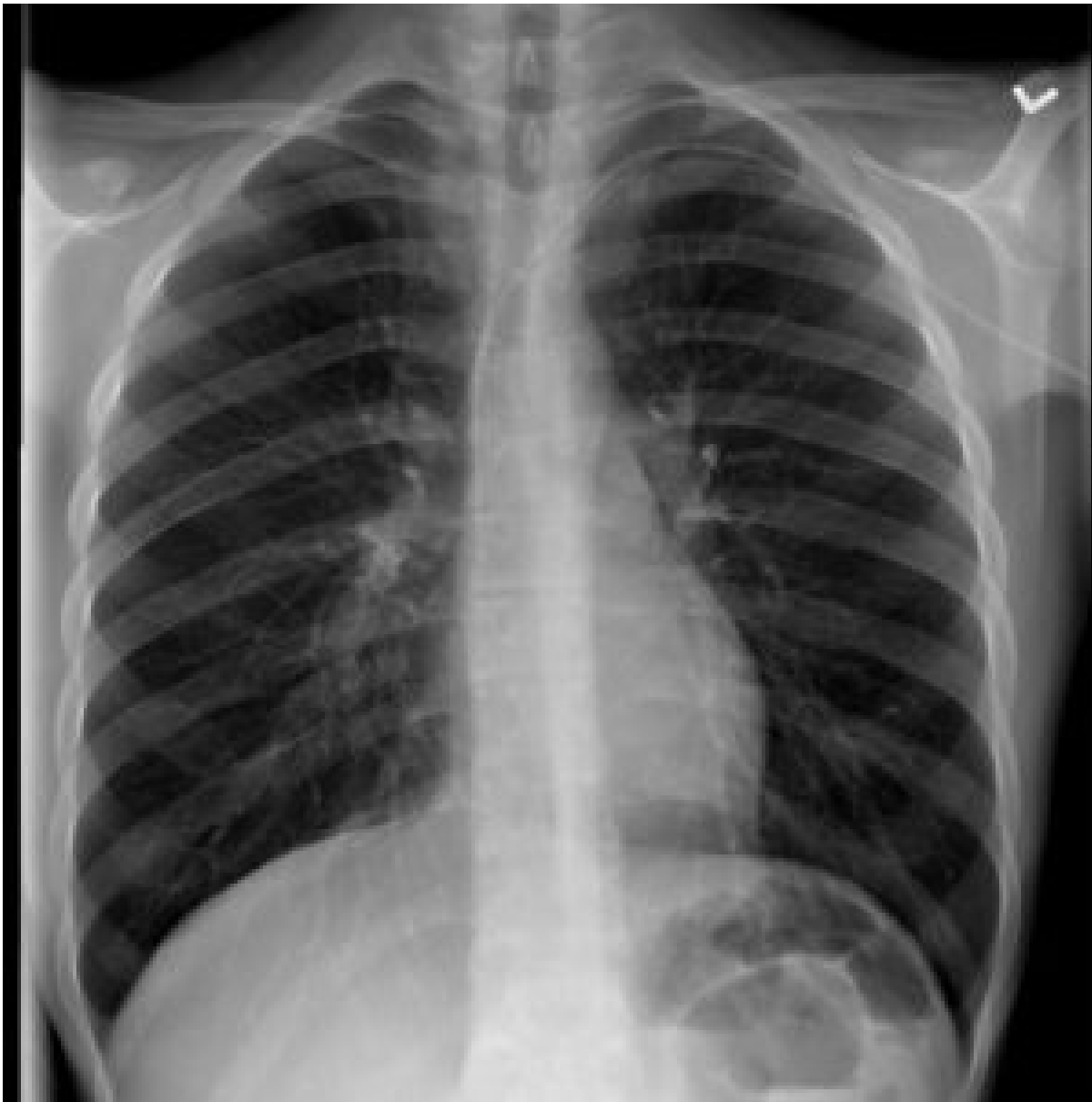

Figure 9.4C PICC – Peripherally Inserted Central Vein Catheter.

PICC – There was a small caliber catheter that entered from the left arm and terminated with the tip superimposed on the SVC-Right atrial junction.

Tubes and Catheters

Nasogastric – Orogastric Tubes

Naso-Orogastric tubes are inserted to allow for the suctioning of the stomach or for the administration of medications and feeding solutions.

Optimally, they should be positioned 8 – 10 cm beyond the gastro-esophageal junction, in the stomach, without any kinks.

These tubes come in different sizes and lengths. They are radio-opaque to make them visible on radiographs. Local policies and procedures for placement and verification of tube placement should be consulted.

ODIN Link for Nasogastric Tube, Figure 9.5: <https://mistr.usask.ca/odin/?caseID=20170116144501259>

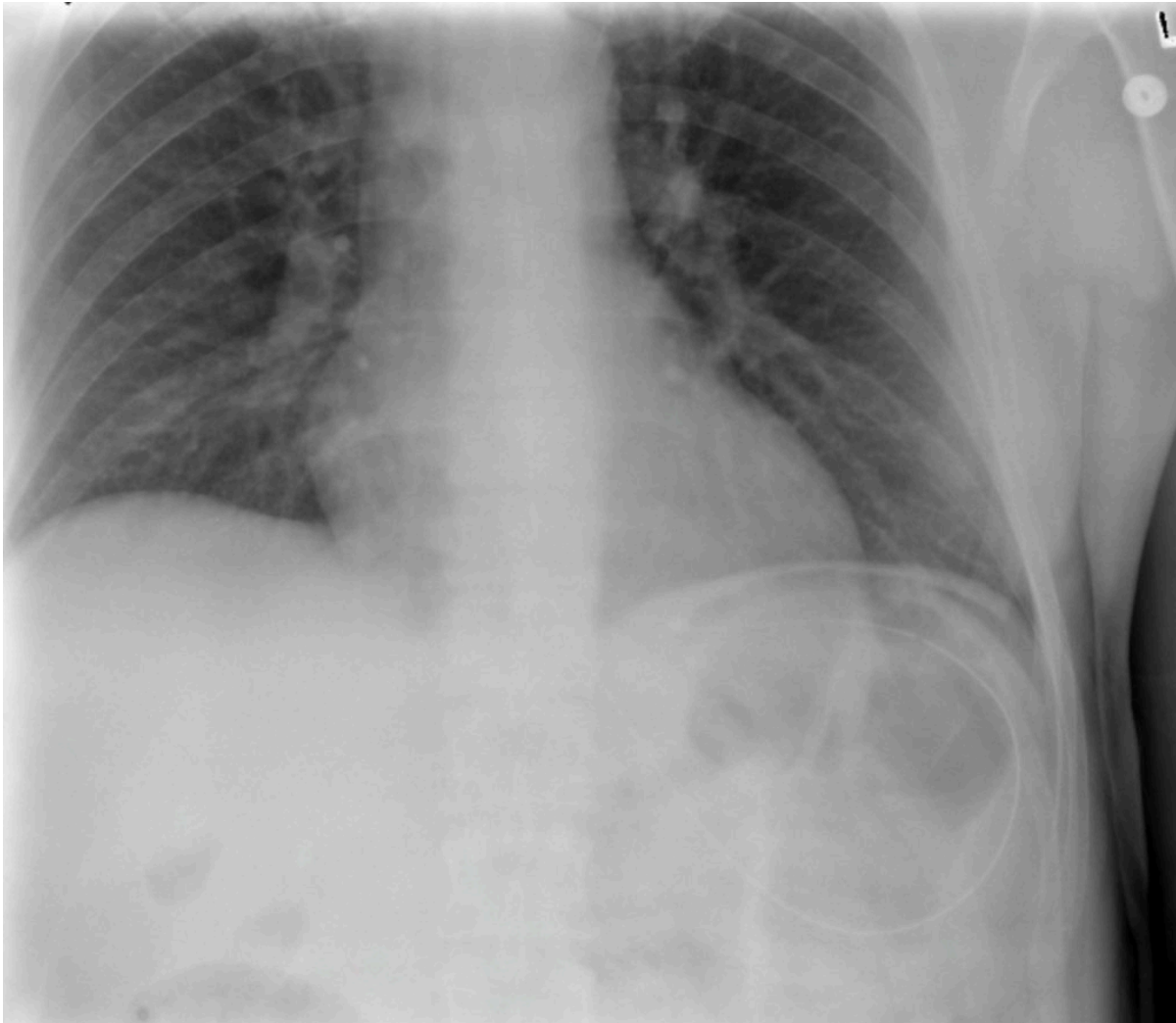


Figure 9.5 Nasogastric Tube – Salem Sump – for Stomach Suction.

This radiograph excluded the anatomy of the upper hemithoraces. There was an NG tube seen that coils in the left upper quadrant of the abdomen. The NG tube was satisfactory in appearance.

ODIN Link for Feeding Tube, Figure 9.6: <https://mistr.usask.ca/odin/?caseID=20151023225106034>

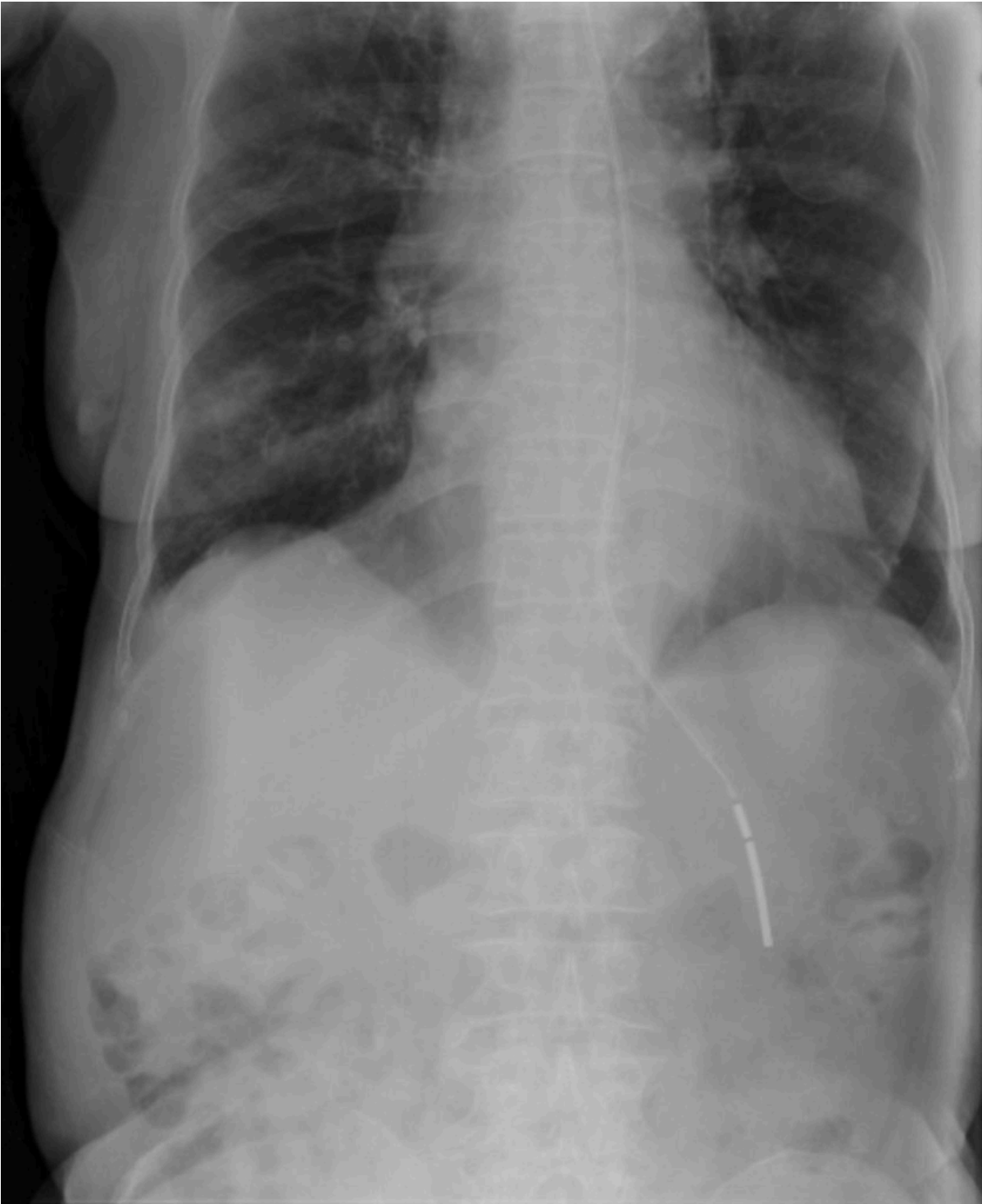

Figure 9.6 Nasogastric Feeding Tube.

This radiograph excludes the anatomy of the upper hemithoraces. There was a weighted feeding tube seen in the left upper quadrant. The tube was beyond the GE junction.

Tubes and Catheters

Chest Drains

Chest drains are most often placed in the pleural space to drain air or fluid (blood, chyle, pus, transudate).

The tube must have sufficient caliber to handle the substance to be drained i.e. larger tubes for thick, viscous fluid. Tubes should be monitored with sequential radiographs to ensure stable position and adequate function. If the drainage tube has side holes, these must be inside the pleural boundary or the pleural contents will leak into the chest wall (subcutaneous emphysema, chest wall fluid).

ODIN Link for Pleural Drains, Figure 9.7: <https://mistr.usask.ca/odin/?caseID=20170117225944372>

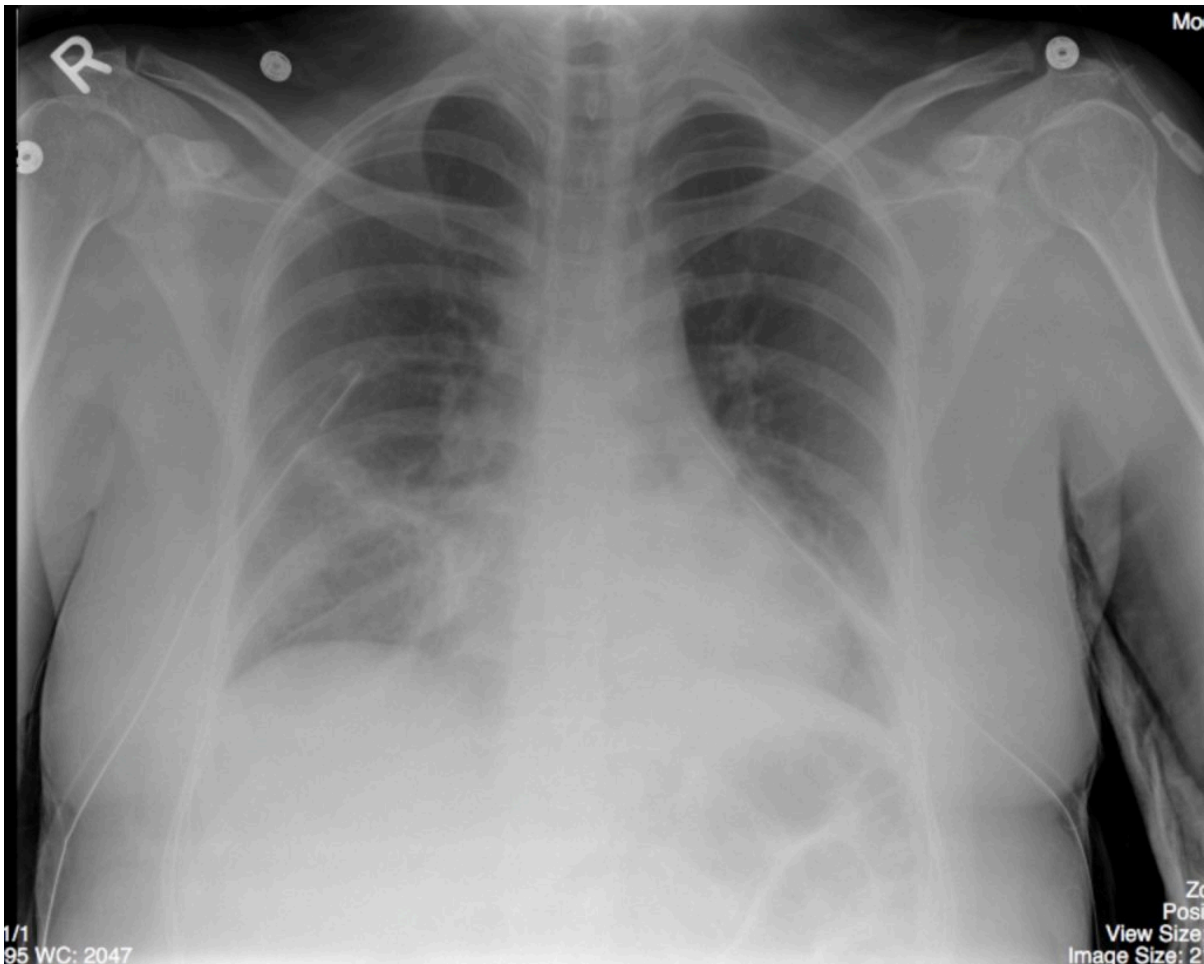


Figure 9.7 Large Caliber Pleural Drains (bilateral).

There were solitary, large caliber pleural drainage catheters in each hemithorax. The discontinuity in the white

marker strip on the tube reveals that the side hole for each drain was well within the margin of the rib cage. The tubes were not kinked. Minimal, residual, pleural fluid was present bilaterally.

ODIN Link for Pleural Pigtails (Pre and Post-Insertion with Ultrasound), Figure 9.8:
<https://mistr.usask.ca/odin/?caseID=20170226235030319>

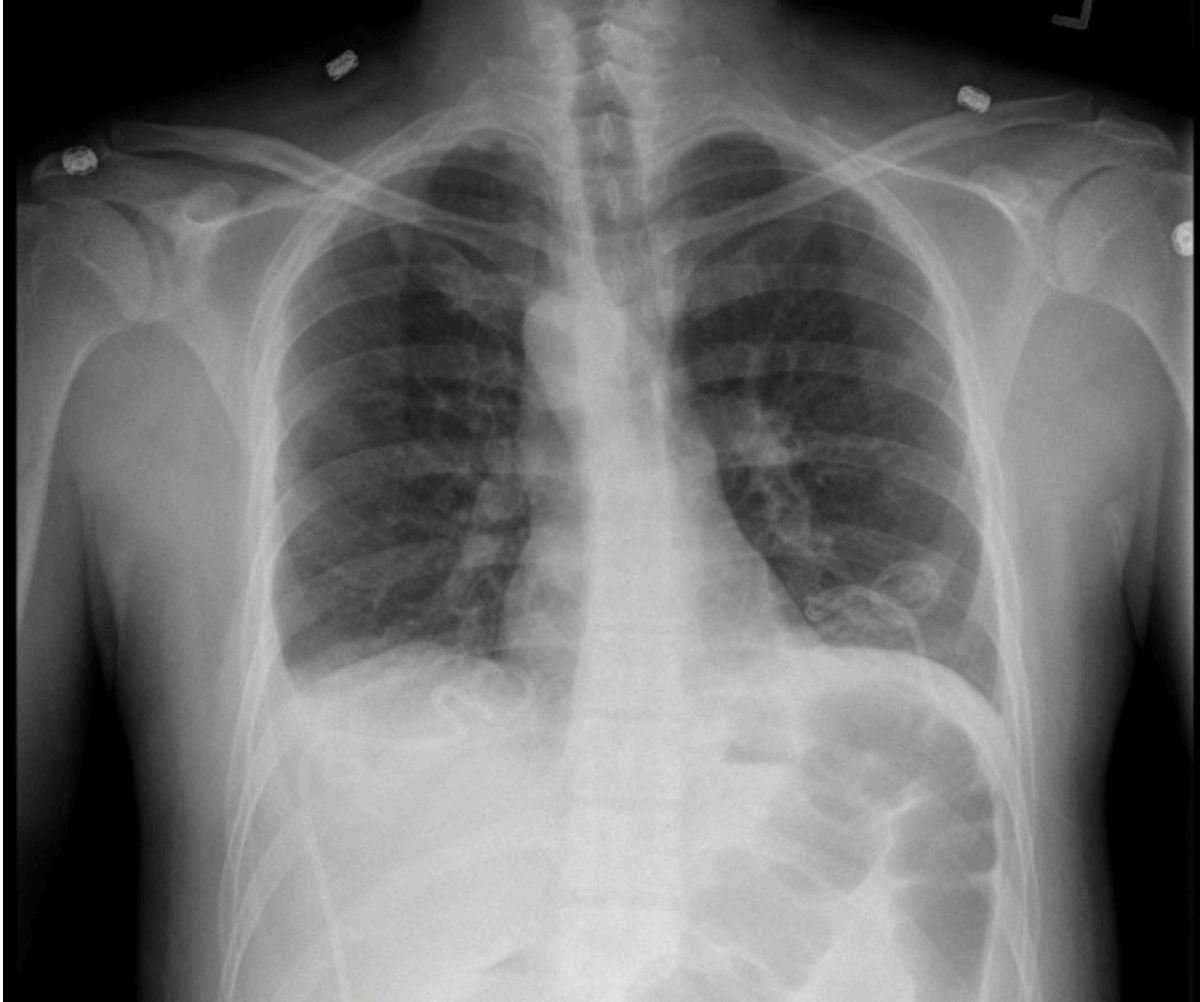

Figure 9.8 Pigtail Pleural Drains (bilateral).

There were solitary, bilateral, small caliber, pigtail type, pleural drains present. The patient made a poor inspiration for the radiograph. Minimal pleural fluid was seen. The patient had a known right aortic arch. The pleural effusions and basilar atelectasis have improved from previous images.

Attributions

Figure 9.3 X-ray of Endotracheal Tube by Dr. Brent Burbridge MD, FRCPC, University Medical Imaging Consultants, College of Medicine, University of Saskatchewan is used under a [CC-BY-NC-SA 4.0](https://creativecommons.org/licenses/by-nc-sa/4.0/) license.

Figure 9.4A Internal Jugular Line by Dr. Brent Burbridge MD, FRCPC, University Medical Imaging Consultants, College of Medicine, University of Saskatchewan is used under a [CC-BY-NC-SA 4.0](#) license.

Figure 9.4B Subclavian Line by Dr. Brent Burbridge MD, FRCPC, University Medical Imaging Consultants, College of Medicine, University of Saskatchewan is used under a [CC-BY-NC-SA 4.0](#) license.

Figure 9.4C PICC – Peripherally Inserted Central Vein Catheter by Dr. Brent Burbridge MD, FRCPC, University Medical Imaging Consultants, College of Medicine, University of Saskatchewan is used under a [CC-BY-NC-SA 4.0](#) license.

Figure 9.5 Nasogastric Tube – Salem Sump – for Stomach Suction by Dr. Brent Burbridge MD, FRCPC, University Medical Imaging Consultants, College of Medicine, University of Saskatchewan is used under a [CC-BY-NC-SA 4.0](#) license.

Figure 9.6 Nasogastric Feeding Tube by Dr. Brent Burbridge MD, FRCPC, University Medical Imaging Consultants, College of Medicine, University of Saskatchewan is used under a [CC-BY-NC-SA 4.0](#) license.

Figure 9.7 Large Caliber Pleural Drains (bilateral) by Dr. Brent Burbridge MD, FRCPC, University Medical Imaging Consultants, College of Medicine, University of Saskatchewan is used under a [CC-BY-NC-SA 4.0](#) license.

Figure 9.8 Pigtail Pleural Drains (bilateral) by Dr. Brent Burbridge MD, FRCPC, University Medical Imaging Consultants, College of Medicine, University of Saskatchewan is used under a [CC-BY-NC-SA 4.0](#) license.

Atelectasis

Case 1

Post-operative Atelectasis

Clinical:

History – This 50 year old female was two days post-operative from a colostomy. She presented with a fever, cough, and fatigue.

Symptoms – Mild cough.

Physical – The lungs were clear on auscultation. Poor inspiration was noted due to abdominal discomfort.

Laboratory – Her white blood cell count was mildly elevated.

DDx:

Atelectasis

Pneumonia

Imaging Recommendation

Chest X-ray

ODIN Link Linear Atelectasis, Figure 9.9: https://mistr.usask.ca/odin/?c_seID=20160412203825261

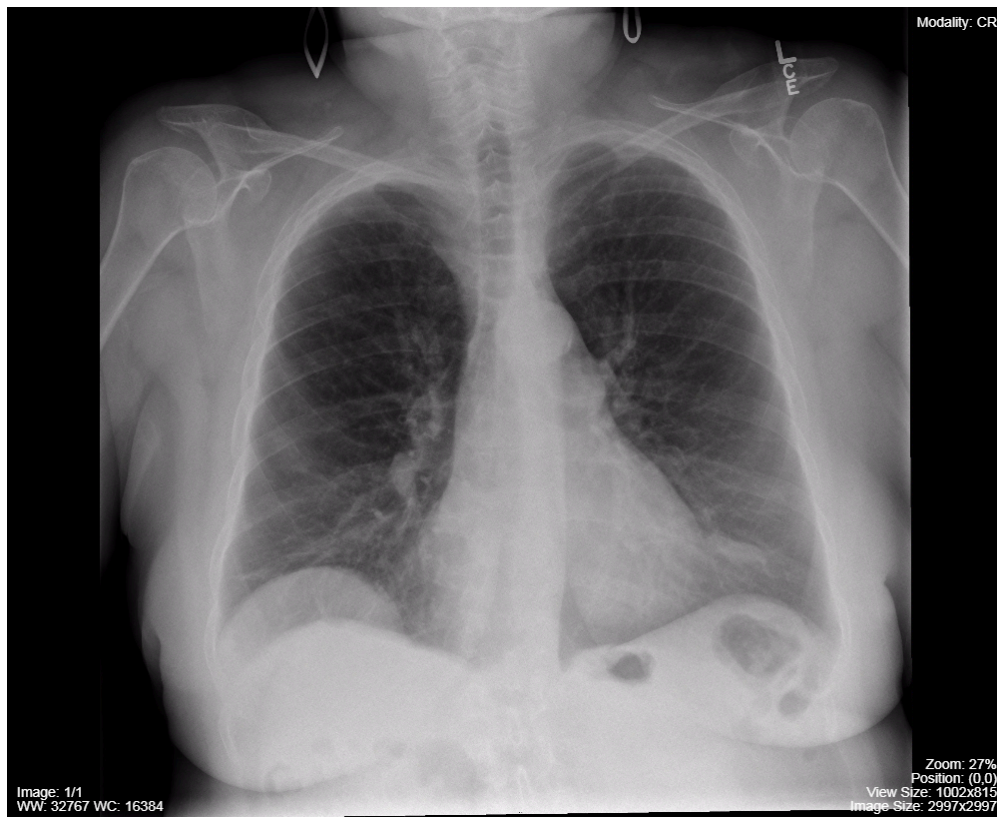


Figure 9.9 Post-Operative Atelectasis: Linear or Plate Like Atelectasis; Left Lower Lobe

Imaging Assessment

Findings:

There were bands of linear opacity in both lower lungs. No evidence of any air bronchograms. Mild eventration of the right diaphragm was seen. No masses or adenopathy.

Interpretation:

Bilateral lung, linear atelectasis.

Diagnosis:

Plate or band-like atelectasis.

Discussion:

Definition of Atelectasis:

Atelectasis is diminished inflation of all, or part of, the lung. The synonym “collapse” is often used interchangeably with atelectasis, particularly when it is severe or accompanied by an obvious increase in lung opacity.

On x-rays and CT scans, reduced volume is seen, accompanied by increased opacity (chest radiograph) or atten-

uation (CT scan) in the affected part of the lung. Atelectasis is often associated with abnormal displacement of fissures, bronchi, vessels, diaphragm, heart, or mediastinum. The distribution can be subsegmental, segmental, or lobar. Subsegmental atelectasis is often qualified by descriptors such as linear, discoid, or platelike.

The different types of atelectasis are:

Passive – Another entity occupies the space usually occupied by lung, most often pleural fluid, but masses i.e. lung, or pleural, can enlarge and cause compression of the adjacent lung. Pneumothorax can also lead to passive atelectasis as the air in the pleural space causes the underlying lung to partially collapse.

Resorptive – An obstruction (intraluminal or extraluminal) prevents the normal ingress and egress of air. The gas in the aerated lung (bronchi, respiratory bronchioles, alveoli) downstream of the obstruction is resorbed/absorbed. This can be seen with endobronchial malignancies, mucous plugs in the bronchi, or extrinsic masses compressing airways leading to bronchial obstruction.

Also, inability to fully inflate the lungs i.e. splinting of the chest due to pain, and prolonged bed rest. may lead to linear bands of resorptive atelectasis.

Cicatrizing (*/ˈsɪkəˌtrɪz/*) – Abnormal lung elasticity prevents the lung from expanding completely. This is often encountered after radiation therapy to the lung or as the result of a fibrosing infection such as tuberculosis.

X-ray findings may include:

- Atelectasis is often opaque lung associated with the diminished volume of air containing lung.
- Atelectasis can occur in a subsegmental (linear), segmental, or lobar distribution.
- The appearance of the diminished lung volume depends upon the type of atelectasis.

Case 2

Post Intubation Atelectasis

Clinical:

History – This 3 year old male presented with severe asthma and required endotracheal intubation.

Symptoms – None – intubated, sedated, and paralyzed.

Physical – No breath sounds in the left hemi-thorax or upper right lung.

Laboratory – Non-contributory.

DDx:

Atelectasis

Collapse

Pneumonia

Imaging Recommendation

Chest X-ray

ODIN Link Misplaced Endotracheal Tube and Atelectasis, Figure 9.10: <https://mistr.usask.ca/odin/?caseID=20170114165716169>

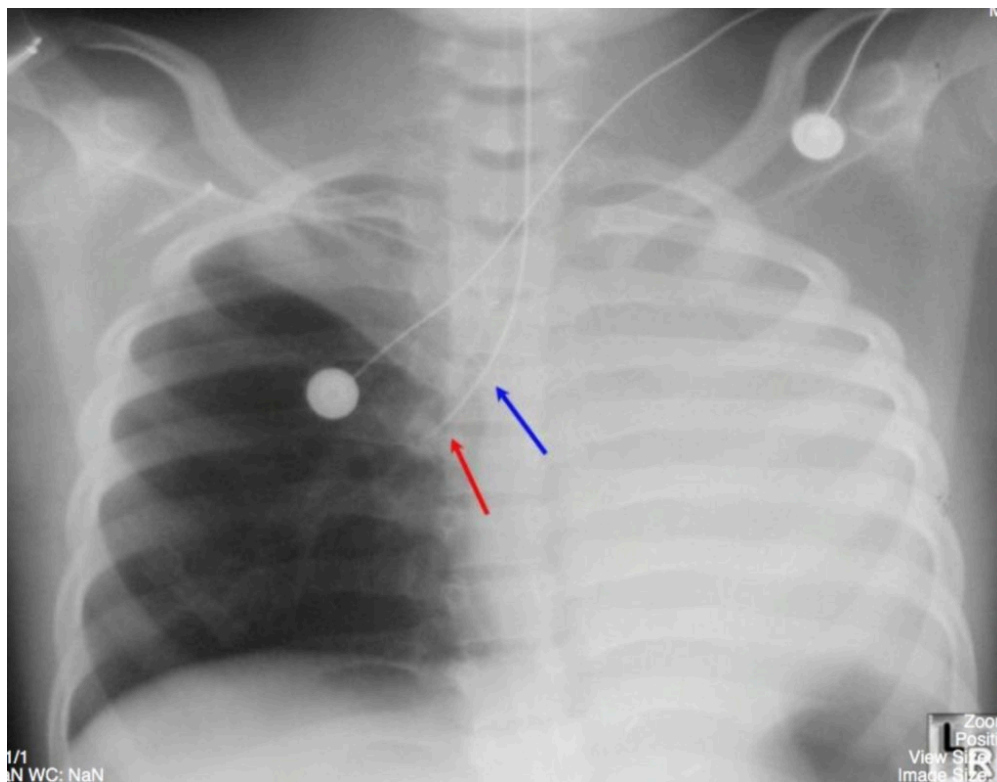


Figure 9.10 Resorptive Atelectasis. Endotracheal tube in right main bronchus. Totally atelectatic left lung and atelectasis of right upper lobe

Imaging Assessment

Findings:

The left lung is totally opacified as is the right upper lobe. The endotracheal tube is in the right main bronchus quite distal in location. Note how the cardiac shadow was not seen in the right hemithorax as the central mediastinal structures have all shifted to the left due to the total atelectasis of the left lung.

Interpretation:

Total, resorptive, atelectasis with obstruction of the bronchi supplying both lobes of the left lung and the right upper lobe by the endotracheal tube.

Diagnosis:

Misplaced endotracheal tube leading to resorptive (obstructive) atelectasis.

Case 3**Pleural effusions, Passive atelectasis****Clinical:**

History – This 42 year old male had severe gallstone pancreatitis. He presented with severe shortness of breath and abdominal pain.

Symptoms – Severe shortness of breath with increased work of breathing and anxiety due to breathlessness.

Physical – Diminished breath sounds in both hemi-thoraces. Decreased volume in both lungs.

Laboratory – Non-contributory.

DDx:

Atelectasis

Collapse

Pneumonia

Pleural effusions

Imaging Recommendation

Chest X-ray

ODIN Link for Massive Pleural Effusions and Atelectasis (Chest x-ray and Ultrasound), Figure 9.11A and B: <https://mistr.usask.ca/odin/?caseID=20170407235902470>

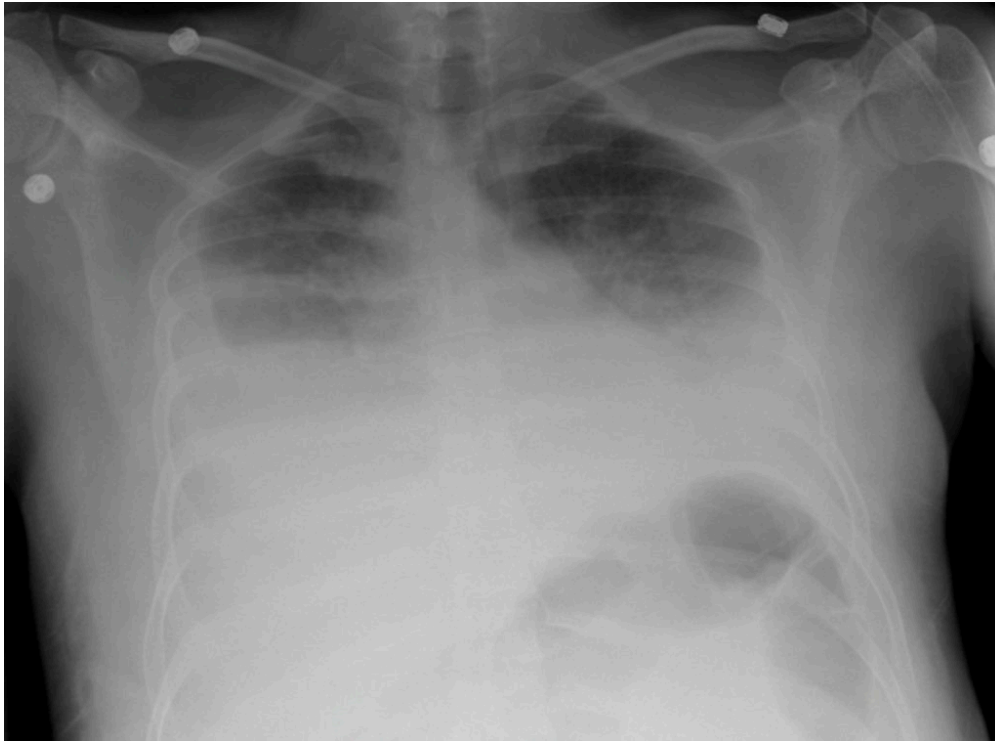


Figure 9.11A Passive Atelectasis. Large Pleural Effusions

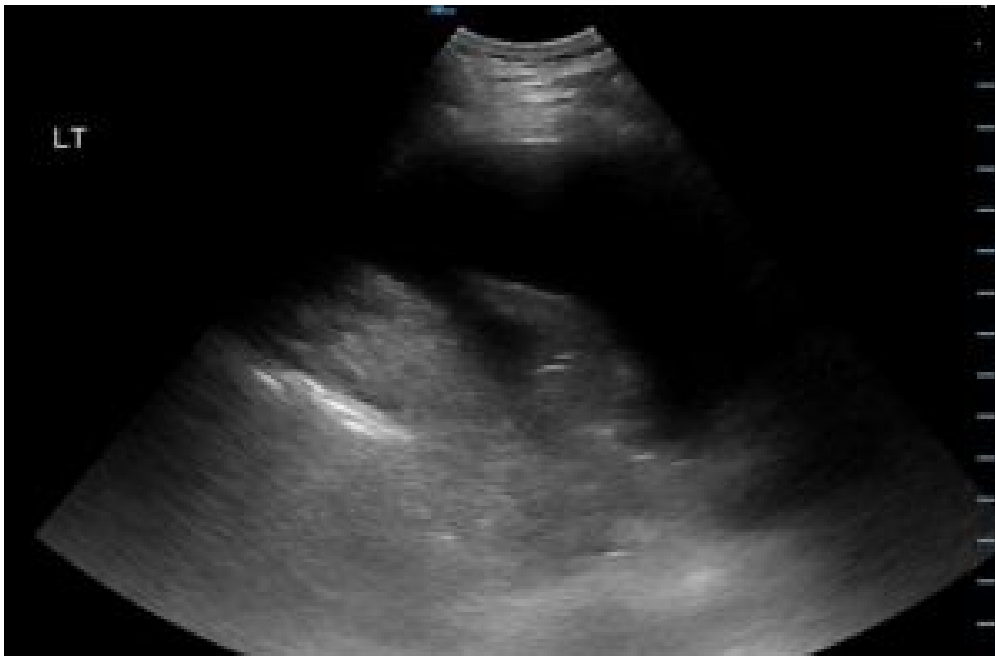


Figure 9.11B Passive Atelectasis – Ultrasound, large pleural effusion with atelectasis

Imaging

Findings CXR:

The volume of the aerated lungs is very diminished. There were large, bilateral pleural effusions.

Interpretation:

Basilar atelectasis due to large bilateral pleural effusions.

Findings US:

The basilar lung is an echogenic collapsed, triangular structure. The collapsed lung is basically suspended in the pleural fluid. There is a large, anechoic region surrounding the collapsed lung.

Diagnosis:

Passive atelectasis due to large, bilateral, pleural effusions.

Attributions

Figure 9.9 Post-Operative Atelectasis: Linear or Plate Like Atelectasis; Left Lower Lobe by Dr. Brent Burbridge MD, FRCPC, University Medical Imaging Consultants, College of Medicine, University of Saskatchewan is used under a [CC-BY-NC-SA 4.0](#) license.

Figure 9.10 Resorptive Atelectasis. Endotracheal tube in right main bronchus. Totally atelectatic left lung and atelectasis of right upper lobe by Dr. Brent Burbridge MD, FRCPC, University Medical Imaging Consultants, College of Medicine, University of Saskatchewan is used under a [CC-BY-NC-SA 4.0](#) license.

Figure 9.11A Passive Atelectasis. Massive Pleural Effusions by Dr. Brent Burbridge MD, FRCPC, University Medical Imaging Consultants, College of Medicine, University of Saskatchewan is used under a [CC-BY-NC-SA 4.0](#) license.

Figure 9.11B Passive Atelectasis – Ultrasound, large pleural with atelectasis by Dr. Brent Burbridge MD, FRCPC, University Medical Imaging Consultants, College of Medicine, University of Saskatchewan is used under a [CC-BY-NC-SA 4.0](#) license.

Lobar and Lung Collapse – Suspected Lung Malignancy

ACR – Chest – Acute Respiratory Illness in Immunocompetent Patient

Case

Left Upper Lobe Collapse, Central LUL Lung Mass

Clinical:

History – This 58 year old female had a 30 pack/year cigarette smoking history. She had been previously diagnosed with mild emphysema and chronic bronchitis.

Symptoms – She complained of a worsening cough with blood tinged sputum. She also had mild, dull, left chest pain that was persistent. The shortness of breath associated with her emphysema seemed to be slightly worse.

Physical – The trachea was deviated to the left. There were transmitted breath sounds in the left upper chest. There were coarse rales and rhonchi in the left chest. Percussion reveals that the left hemidiaphragm was elevated in comparison to the left. No palpable masses or lymph nodes.

DDx:

Emphysema/Chronic Bronchitis exacerbation

Lobar Collapse due to mucous plugging

Lung Malignancy

Imaging Recommendation

[ACR – Chest – Acute Respiratory Illness in Immunocompetent Patient – Variant 9](#)

Chest X-ray

ODIN Link for Left Upper Lobe partial Collapse Chest x-ray, Figure 9.12A and B: <https://mistr.usask.ca/odin/?caseID=20170415101643471>

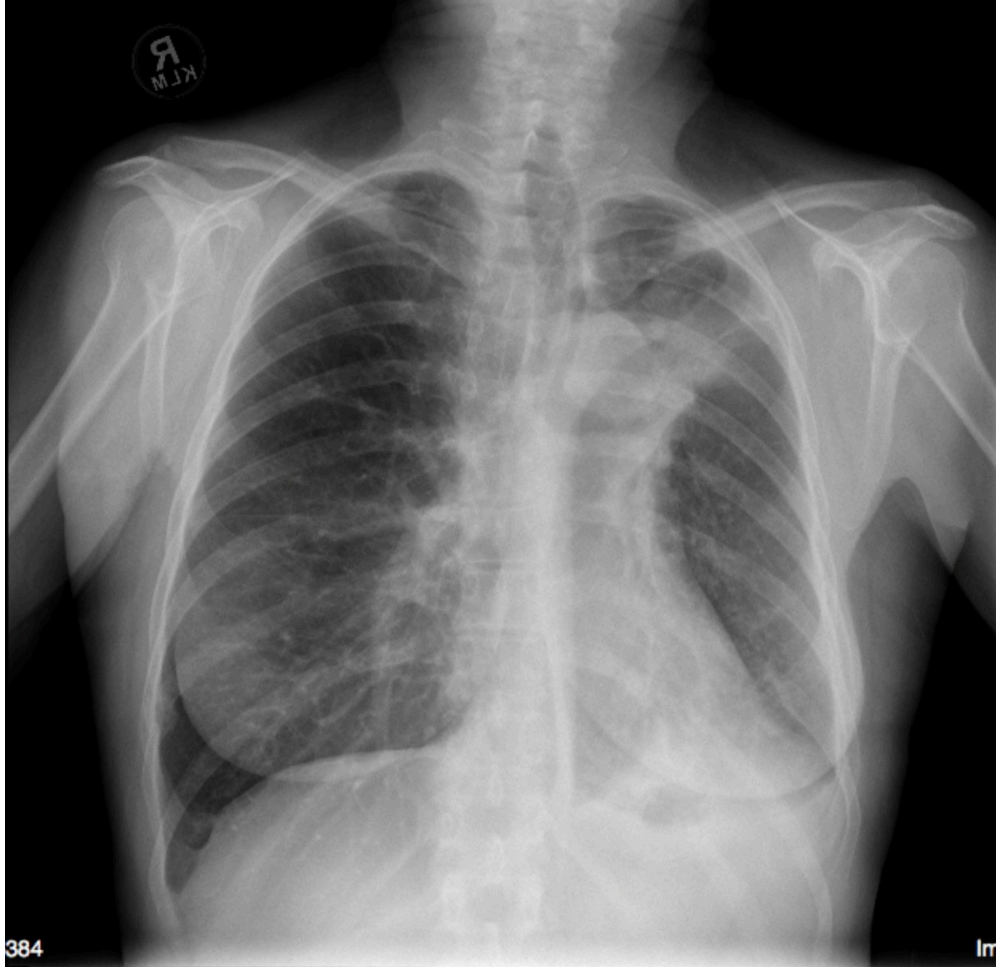


Figure 9.12A PA Chest x-ray of Left Upper Lobe Collapse

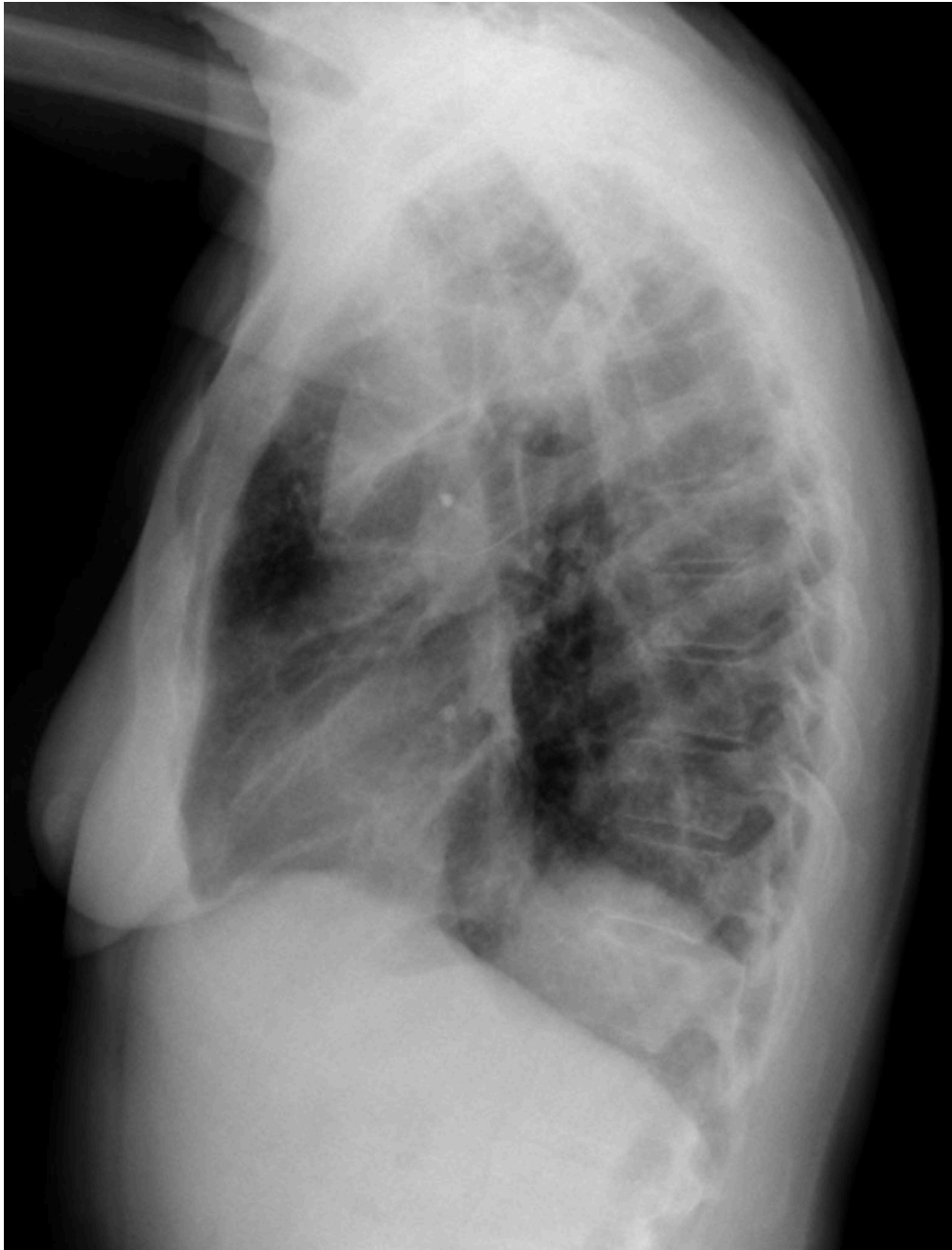


Figure 9.12B Lateral Chest x-ray of Left Upper Lobe Collapse

Imaging Assessment

Findings:

There was overall diminished volume in the left hemithorax (hemidiaphragm was elevated, the mediastinum was shifted to the left, there was vague haziness in left lung, and the trachea was deviated to the left). The left upper lobe was opaque and partially collapsed and there was a rounded margin of the hilar and left upper lung opacity suggesting an underlying tumor. The left upper lobe bronchus was surrounded by opacity and was irregular and constricted. The aortic shadow was obscured by the adjacent opaque lung. No obvious lymphadenopathy.

Interpretation:

Partial left upper lobe collapse with high suspicion for an associated left upper lobe lung mass. CT of the chest was recommended.

Diagnosis:

Left Upper Lobe Collapse

Pathology:

Adenocarcinoma of the Lung

Limited CT (No contrast) for Core Needle Biopsy LUL Mass (Biopsy = Adenocarcinoma)

ODIN Link to CT Core Needle Biopsy LUL Mass, Figure 9.13: <https://mistr.usask.ca/odin/?caseID=20170118173043442>

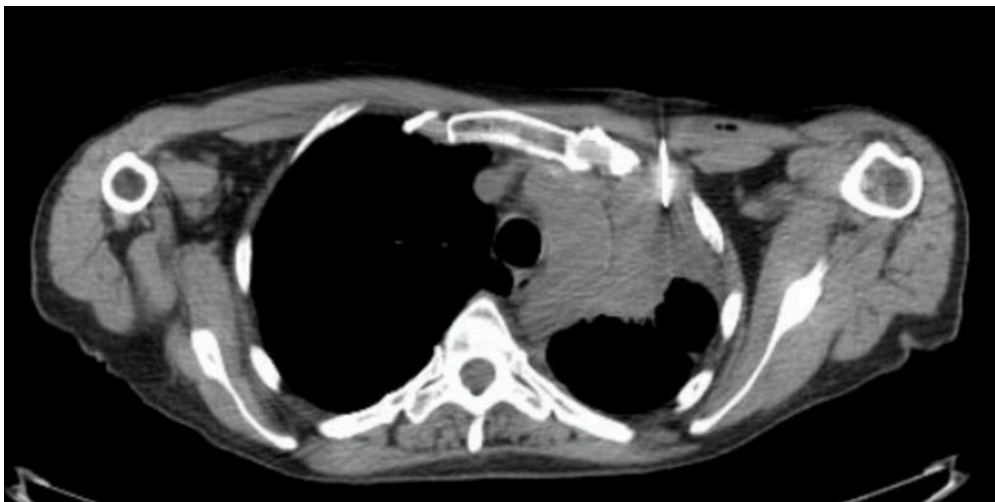


Figure 9.13 CT Core Needle Biopsy of Left Upper Lobe Mass

Discussion:

New and unexpected lobe or lung collapse is a very ominous finding in a patient over the age of fifty, especially if they have a history of cigarette smoking. If there are any imaging signs that suggest a mass lesion this requires immediate further investigation.

If the lung opacity is suspected to be related to community acquired pneumonia, with minimal imaging signs to suggest volume loss, the imaging abnormalities should initially be managed medically. If the radiographs do not improve with medical management i.e. complete resolution, the patient requires further investigation to determine if there is an underlying cause for the lung opacity .

Lung Malignancy

- Lung cancer is the most common fatal malignancy in men.
- Lung cancer is the second most common malignancy in women (next to breast cancer).
- The major sub-types of lung cancer are Adenocarcinoma, Squamous Cell Carcinoma, Small Cell Carcinoma and Large Cell.
- Primary lung cancer usually presents as a solitary nodule or mass. Adenocarcinoma often presents as a peripheral lung nodule or mass.
- More centrally situated lung malignancies may cause lobar or lung opacification with, or without, volume loss. A central, or hilar, location for lung malignancy is common with Small Cell Carcinoma.

X-ray findings may include:

- The collapsed lobe will be more opaque on imaging.
- Normally, fissures can be seen on x-rays when the fissure is in the same plane as the x-ray beam. It is seen as a thin white line composed of the visceral and parietal pleura of opposing lobes. The fissure abutting the collapsed lobe will migrate to a new location following the collapsed lobe.
- Often the fissure of the lung acts as a barrier to the spread of the lung opacity and there will be a sharp demarcation between the collapsed lung and the normal adjacent lung. The fissure will no longer be identifiable as a unique structure as it is no longer surrounded by aerated lung.
- The global volume of the hemithorax with the collapsed lobe will be diminished.
- This global volume loss may result in shifting of the mediastinum towards the collapsed lung.
- There may be an ipsilateral mass or hilar adenopathy visible.
- The bronchus supplying the collapsed lobe may not be visible.

Attributions

Figure 9.12A PA Chest x-ray of Left Upper Lobe Collapse by Dr. Brent Burbridge MD, FRCPC, University Medical Imaging Consultants, College of Medicine, University of Saskatchewan is used under a [CC-BY-NC-SA 4.0](#) license.

Figure 9.12B Lateral Chest x-ray of Left Upper Lobe Collapse by Dr. Brent Burbridge MD, FRCPC, University Medical Imaging Consultants, College of Medicine, University of Saskatchewan is used under a [CC-BY-NC-SA 4.0](#) license.

Figure 9.13 CT Core Needle Biopsy of Left Upper Lobe Mass by Dr. Brent Burbridge MD, FRCPC, University Medical Imaging Consultants, College of Medicine, University of Saskatchewan is used under a [CC-BY-NC-SA 4.0](#) license.

Pleural Effusion

ACR – Chest – Acute Respiratory Illness in Immunocompetent Patient

Case 1

Large Bilateral Pleural Effusion

Clinical:

History: This 38 year old male was diagnosed with gallstone pancreatitis. He had severe pancreatitis. He was admitted for medical management.

Symptoms: Shortness of breath, slowly worsening over 24-48 hours. No chest pain.

Signs: Increased respiratory rate, increased work of breathing, anxious, muffled breath sounds bilaterally, percussion revealed very diminished aerated lung bilaterally.

DDx:

Bilateral Pleural effusions

Pulmonary Embolism

Pneumonia

Atelectasis

Imaging Recommendation

[ACR – Chest – Acute Respiratory Illness in Immunocompetent Patient, Variant 4](#)

Chest X-ray

ODIN Link for Large Pleural Effusions (Chest x-ray and Ultrasound), Figure 9.14: <https://mistr.usask.ca/odin/?caseID=20170407235902470>

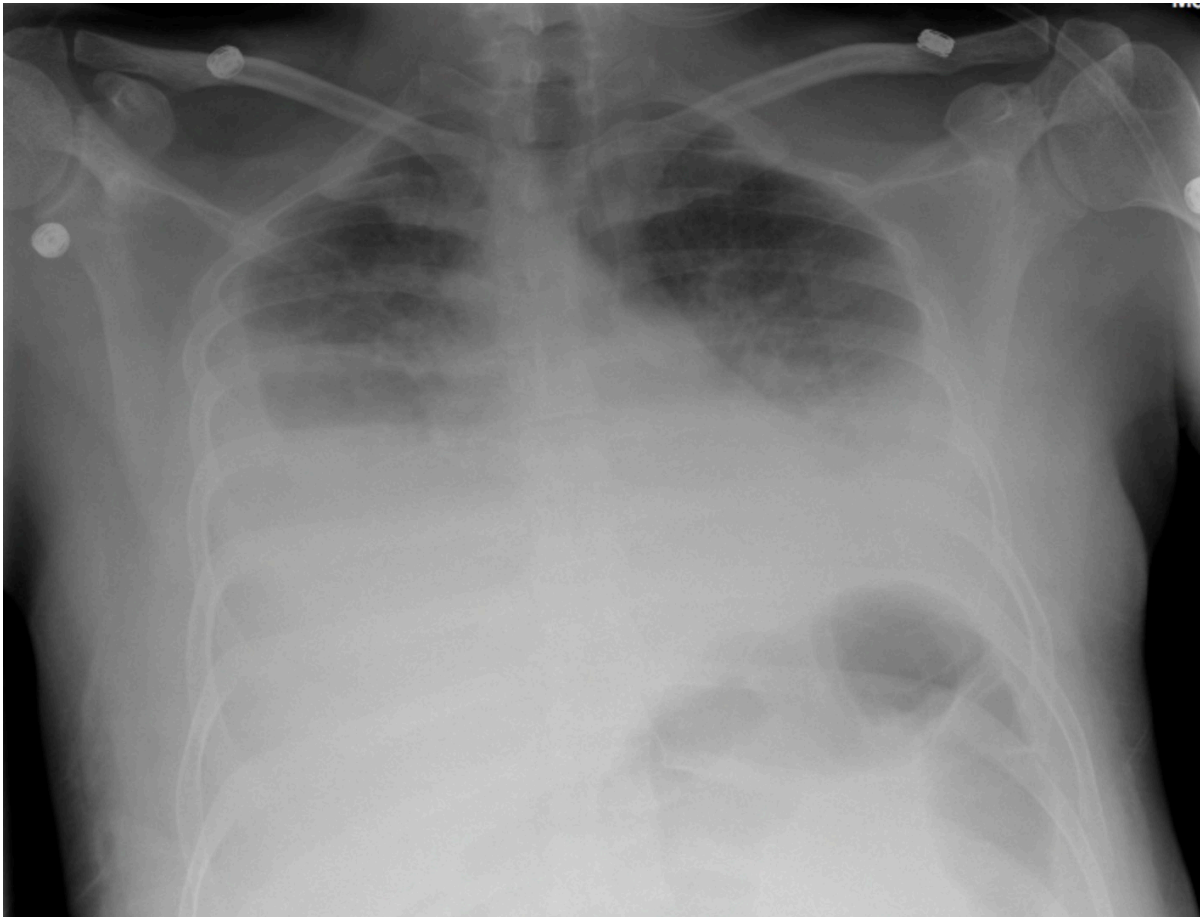


Figure 9.14 Chest X-ray displaying large bilateral pleural effusions.

Imaging Assessment

Findings:

The lungs were poorly aerated. There were large pleural effusions present. The size of the cardiac silhouette could not be determined due to the pleural fluid. No evidence of pneumothorax.

Interpretation:

Large, bilateral pleural effusions.

Diagnosis:

Large Bilateral Pleural Effusions – X-ray and Ultrasound

Pathology:

Pleural Transudate

Discussion:

Pleural fluid may be transudate, exudate, blood, chyle, or infusate. Pleural fluid occupies space and causes the underlying lung to collapse as there is limited space in the hemithorax.

The margins of the fluid will create a meniscus with the pleura that is not seen with isolated lung consolidation.

Normally, several hundred milliliters of pleural fluid are produced and reabsorbed each day. Fluid is produced at the parietal pleura from a capillary bed and is resorbed both at the visceral pleura and by lymphatic drainage throughout the parietal pleura.

Etiology of Pleural Effusion

Fluid accumulates in the pleural space when there is an imbalance in fluid production or resorption.

Increased rate of fluid production:

- Increasing hydrostatic pressure, as in left heart failure.
- Decreasing colloid osmotic pressure, as in hypoproteinemia.
- Increasing capillary permeability, as can occur in toxic disruption of the capillary membrane in pneumonia or hypersensitivity reactions.

Decreased rate of absorption:

- Lymphangitic blockade by tumor or increased venous pressure that decreases the rate of fluid transport via the thoracic duct.
- Decreased pressure in the pleural space, as in atelectasis of the lung due to bronchial obstruction.
- Pleural effusions can also form when there is transport of peritoneal fluid from the abdominal cavity through the diaphragm or via lymphatics from a subdiaphragmatic process.

X-ray findings may include:

- Conventional radiography is usually the first step in the detection of a pleural effusion.
- The pleural fluid is opaque.
- Pleural fluid should fall with gravity and be in the most dependent part of the hemithorax, based upon patient positioning for the x-ray i.e. upright, supine, decubitus, etc. If you are suspicious of an effusion and want to see if the pleural fluid will move, it is best to do an ipsilateral side down x-ray of the chest (decubitus view).
- The fluid creates a concave meniscus in the pleural space, seen at the margins of the fluid col-

lection.

- Fluid should be mobile and the detection of small pleural effusions can be facilitated by acquiring a same side down decubitus chest x-ray to see if the fluid moves with gravity.

Other Imaging Modalities that can Detect Pleural Effusion

- These include, Computed tomography (CT) and ultrasonography (US). CT and US are both sensitive for the detection of small amounts of pleural fluid.
- CT is the best modality for evaluating if there is an underlying abnormality causing the effusion or when the patient has complete opacification of a hemithorax that requires further assessment.
- US is especially helpful for guiding an interventional procedure to remove the pleural fluid (thoracentesis).

Case 2

Small Bilateral Pleural Effusions – Malignant

Clinical:

History: This 60 year old female was diagnosed with breast cancer 1 year prior to these x-rays. She was being followed by a Medical Oncologist. Chest x-rays were requested on the day of her clinic visit.

Symptoms: Fatigue, mild, aching, right chest pain.

Signs: Previous left mastectomy. Nil else.

ODIN Link for Small Pleural Effusions (Chest x-ray and Ultrasound), Figure 9.15A and B: <https://mistr.usask.ca/odin/?caseID=20151203165605789>

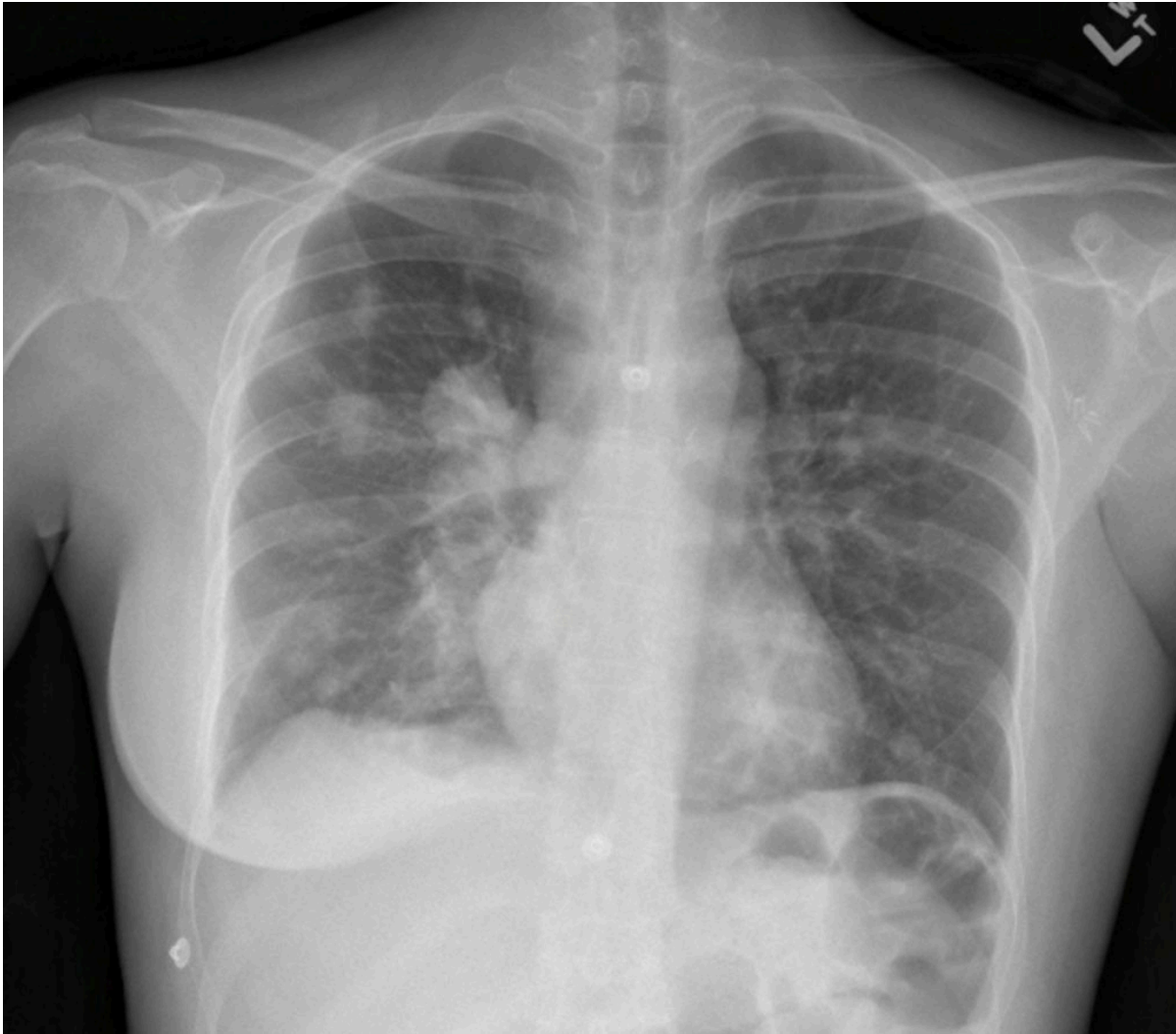


Figure 9.15A Chest x-ray displaying metastatic lung disease.

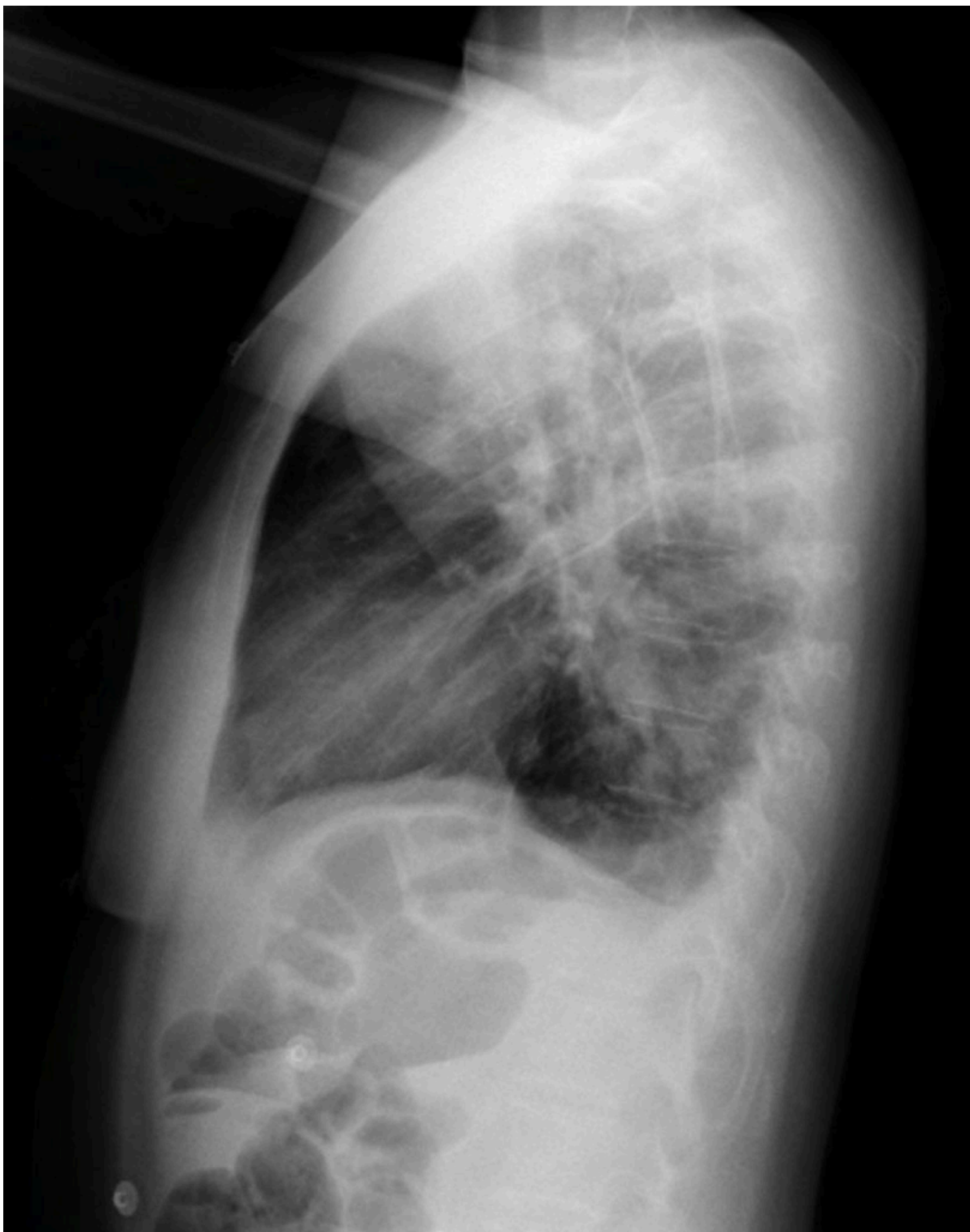

Figure 9.15B Chest x-ray displaying metastatic lung disease.

Imaging Assessment

Findings:

The patient has had a previous left mastectomy. There were nodular lesions in both lungs. The right costophrenic

angle was suspected to be blunted on the frontal x-ray. There was definitely blunting of the posterior costophrenic sulci bilaterally on the lateral x-ray.

Interpretation:

Metastatic lung nodules. Small right pleural effusion.

Diagnosis:

Metastatic disease lung and pleural.

Pathology:

Malignant pleural effusion, breast cancer metastatic disease.

Case 3**Moderate Right Pleural Effusion****Clinical:**

History: This 40 year old male complained of fever, cough, and right chest pain. He was admitted for medical management.

Symptoms: Shortness of breath, slowly worsening over 24-48 hours. Right chest pain, worse with deep breathing.

Signs: Increased respiratory rate, increased work of breathing, anxious, transmitted breath sounds on the right, percussion revealed very diminished aerated lung on the right. He had a fever of 40 degrees Celsius.

ODIN Link for Large Pleural Effusion, Figure 9.16A and B: <https://mistr.usask.ca/odin/?caseID=20170407235605957>

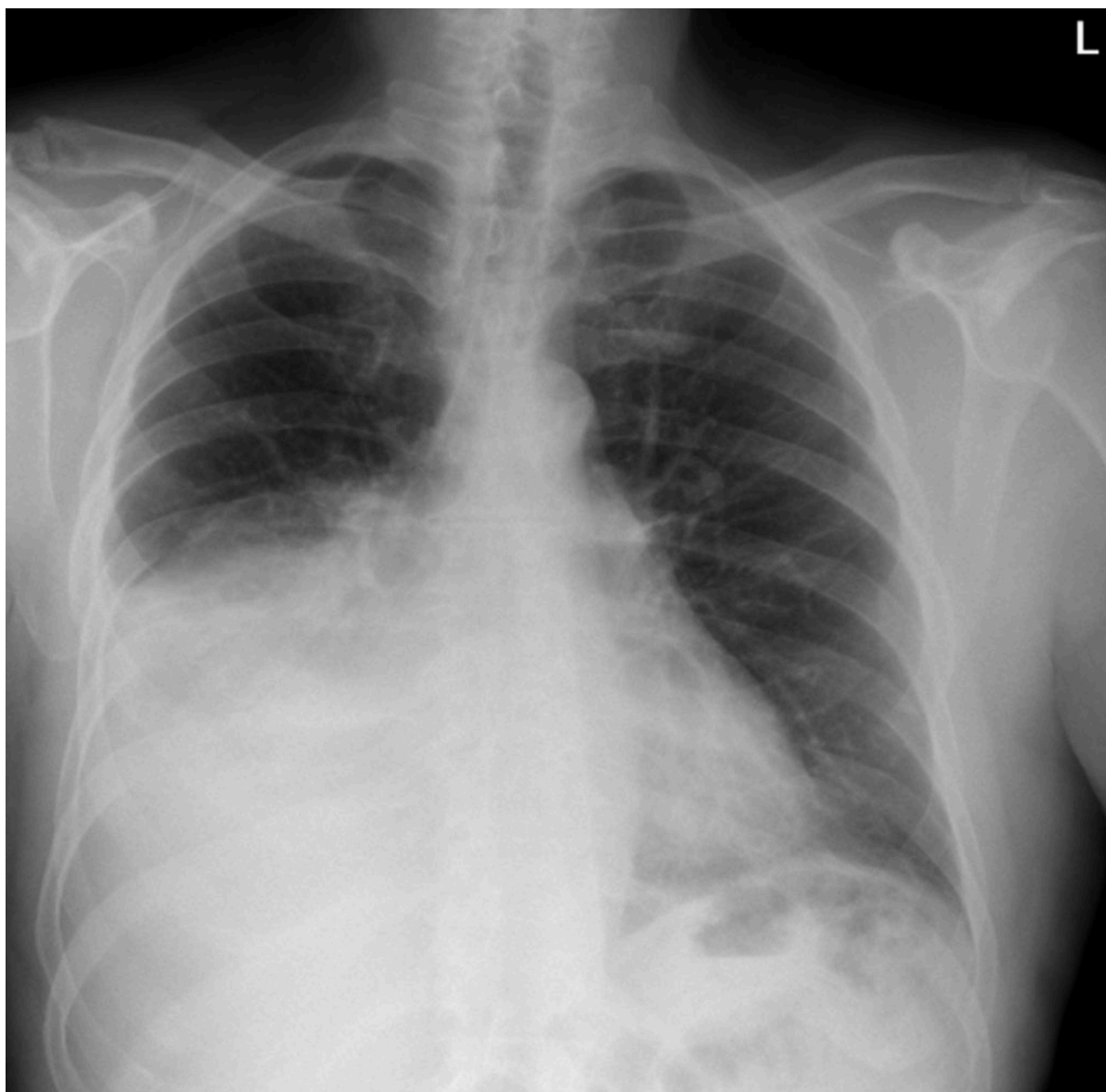


Figure 9.16A Chest x-ray displaying Lobar Consolidation/Collapse.

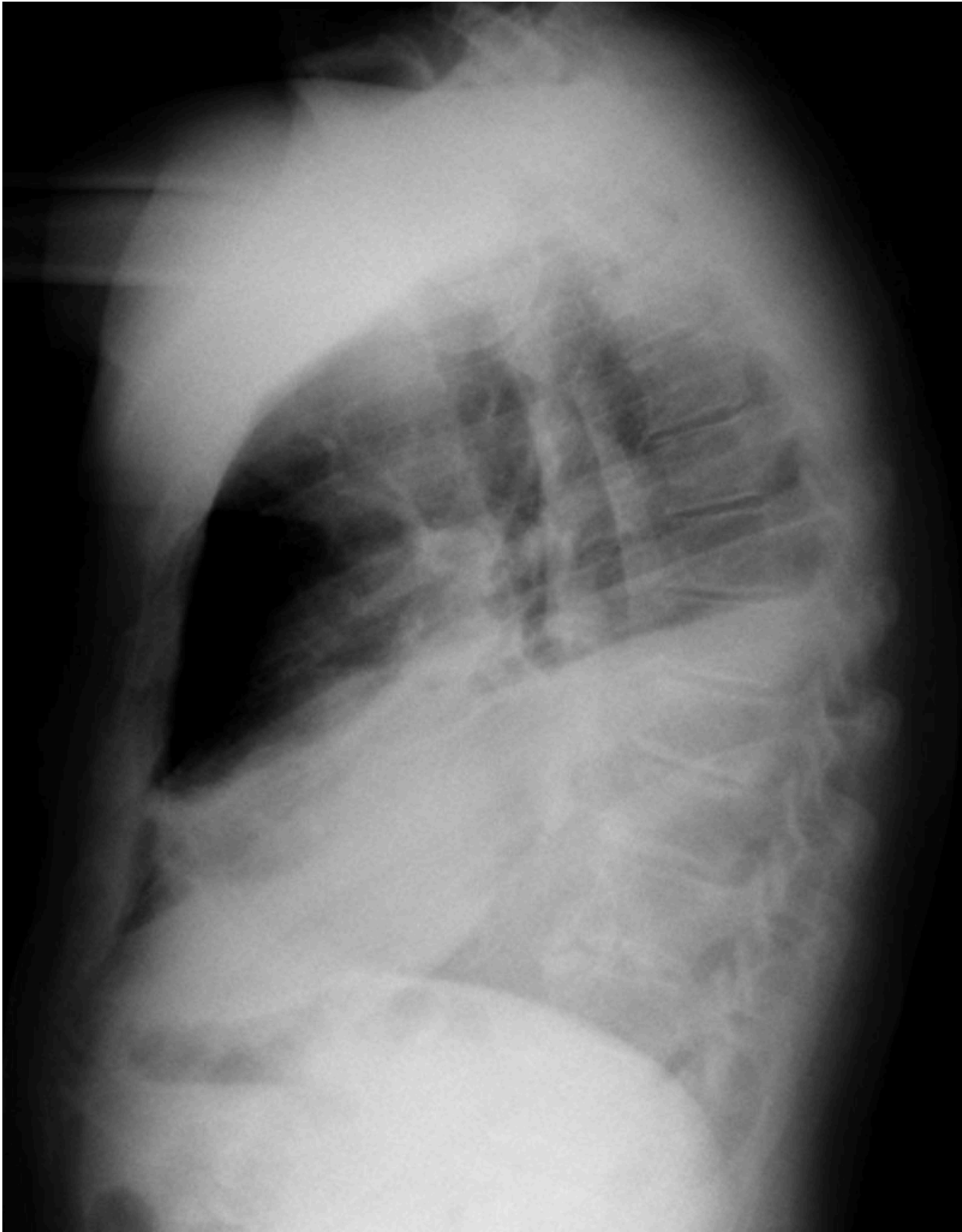


Figure 9.16B Lateral Chest x-ray displaying Lobar Consolidation/Collapse.

Imaging Assessment

Findings:

The right lower lobe was opaque. There were right lower lobe air bronchogram. A right pleural effusion was present.

Interpretation:

Right lower lobe consolidation with reactive right pleural effusion.

Diagnosis:

Community acquired pneumonia.

Pathology:

Pneumonia with reactive pleural effusion.

Attributions

Figure 9.14 AP Chest x-ray displaying large bilateral pleural effusions by Dr. Brent Burbridge MD, FRCPC, University Medical Imaging Consultants, College of Medicine, University of Saskatchewan is used under a [CC-NC-SA](#) license.

Figure 9.15A PA Chest x-ray displaying metastatic lung disease by Dr. Brent Burbridge MD, FRCPC, University Medical Imaging Consultants, College of Medicine, University of Saskatchewan is used under a [CC-NC-SA](#) license.

Figure 9.15B Lateral Chest x-ray displaying metastatic lung disease by Dr. Brent Burbridge MD, FRCPC, University Medical Imaging Consultants, College of Medicine, University of Saskatchewan is used under a [CC-NC-SA](#) license.

Figure 9.16A PA Chest x-ray displaying Lobar Consolidation/Collapse by Dr. Brent Burbridge MD, FRCPC, University Medical Imaging Consultants, College of Medicine, University of Saskatchewan is used under a [CC-NC-SA](#) license.

Figure 9.16B Lateral Chest x-ray displaying Lobar Consolidation/Collapse by Dr. Brent Burbridge MD, FRCPC, University Medical Imaging Consultants, College of Medicine, University of Saskatchewan is used under a [CC-NC-SA](#) license.

Pneumonia

ACR – Chest – Acute Respiratory Illness in Immunocompetent Patient

Case 1

Right Upper Lobe and Left Lower Lobe Consolidation with Air Bronchograms

Clinical:

History – This 50 year old male had just returned from a trip to Cuba. He presented with a fever, fatigue, and a cough productive of green sputum.

Symptoms – Progressively worsening cough associated with a fever of 39C. He was producing green sputum. He also complained of a mildly sore throat.

Physical – Coarse rales were heard in the right upper chest and the left lower chest. Transmitted breath sounds were also heard in these regions. His tonsils and pharynx were reddened with white exudate seen on the tonsillar fossae.

Laboratory – His white blood cell count was elevated.

DDx:

Pharyngitis

Pneumonia

Bronchitis

Imaging Recommendation

[ACR – Chest – Acute Respiratory Illness in Immunocompetent Patient, Variant 4](#)

Chest X-ray

ODIN Link for Pneumonia images, Figure 9.17A and B: <https://mistr.usask.ca/odin/?caseID=20170221151826268>

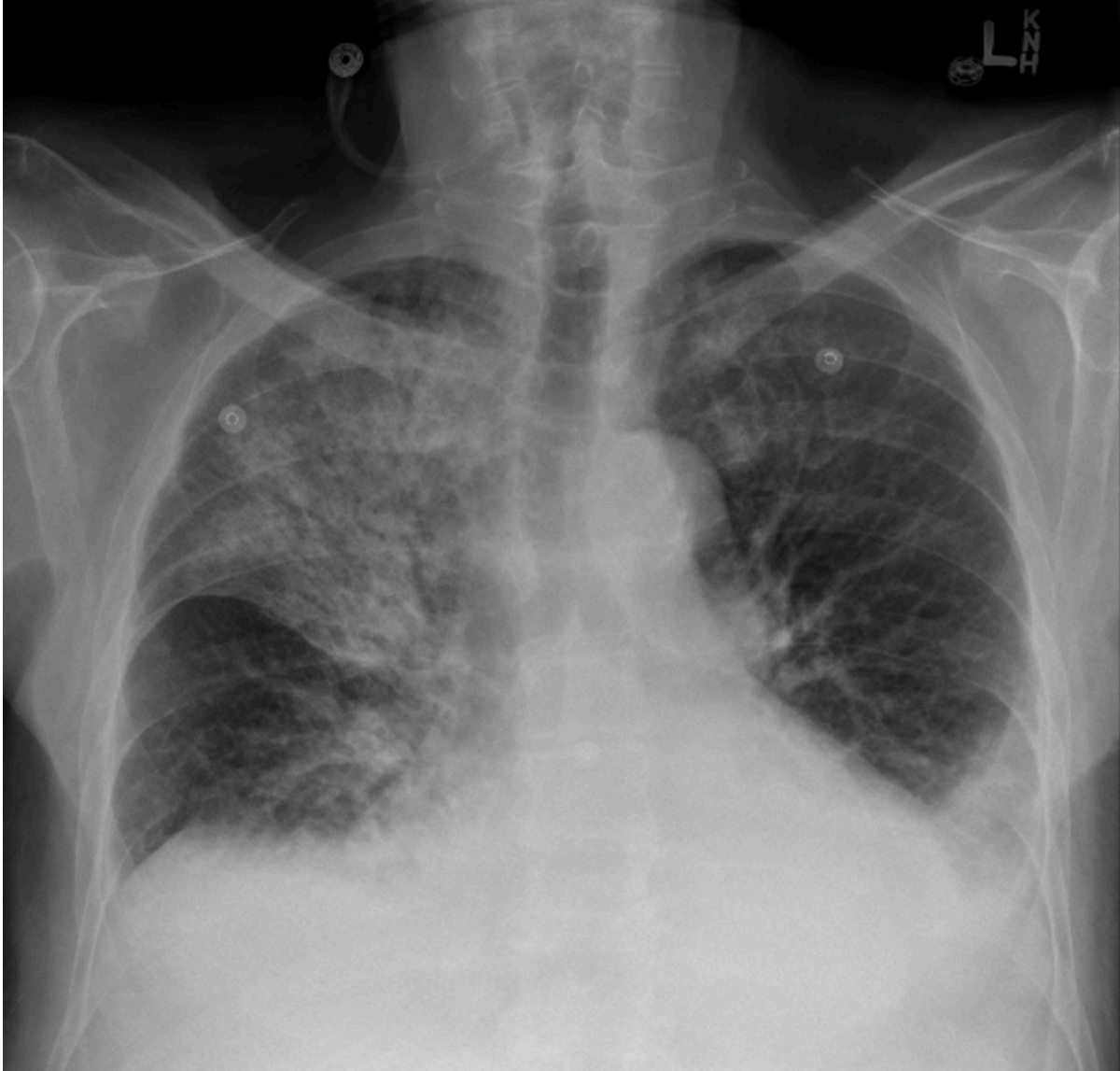


Figure 9.17A AP Chest x-ray, Pneumonia.

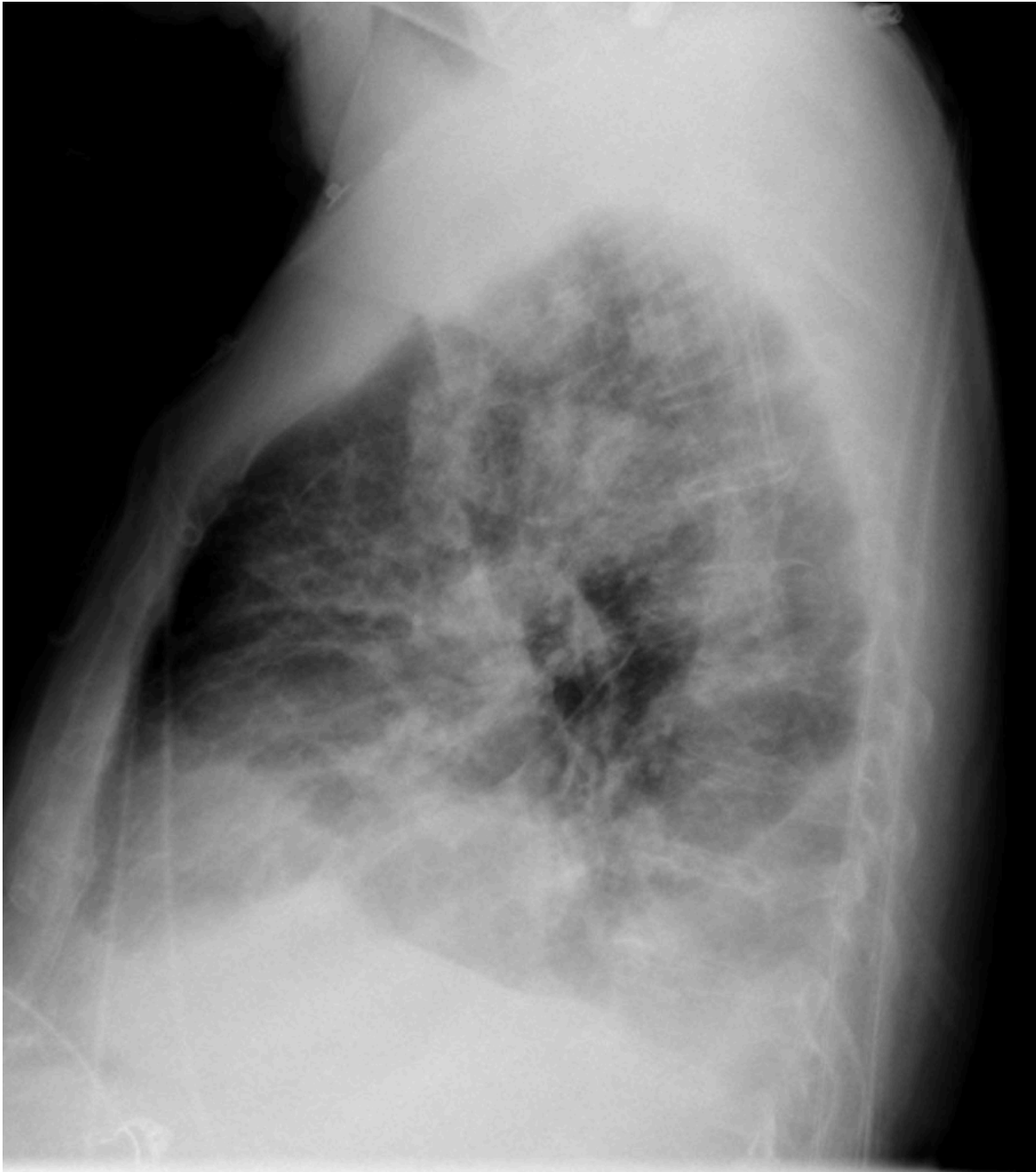

Figure 9.17B Lateral Chest x-ray, Pneumonia.

Imaging Assessment

Findings:

There were small, bilateral pleural effusions. The right upper lobe and the left lower lobe were densely consolidated with air bronchograms seen in these regions. There was patchy airspace consolidation throughout the lungs. No masses or adenopathy.

Interpretation:

Bilateral lung consolidation associated with small bilateral effusions. If the clinical presentation includes fever, this is most likely pneumonia.

Diagnosis:

Right Upper Lobe and Left Lower Lobe Consolidation with Air Bronchograms – Community Acquired Pneumonia

Discussion:

Generalized opacity of the lung, with preserved volume of the lung, is called *consolidation*. Consolidation can be caused by fluid (transudate, exudate), blood, protein, and cells. In the clinical setting of associated fever and abnormalities of the white blood cell count, the pattern would fit best with infective consolidation (pneumonia, exudate).

Pneumonia can be defined as *consolidation of the lung produced by inflammatory exudate*, usually as a result of an infectious agent. Most pneumonias produce airspace disease, either lobar or segmental. Other pneumonias demonstrate interstitial disease and others produce findings in both the airspaces and the interstitium. Most microorganisms that produce pneumonia are spread to the lungs via the tracheobronchial tree, either through inhalation or aspiration of the organisms.

An air-bronchogram is the presence of a tubular, air filled, bronchus that does not contain exudate. The margins of the consolidated lung are irregular as alveoli are recruited by passage of exudate from one to the other via the pores of Kohn, resulting in an ill defined edge to the consolidation. Fissures block the spread of consolidation and there is a straight edge demarcating consolidation abutting a fissure.

X-ray findings may include:

- Opaque segment or lobe (consolidation).
- The margins of the opacity may have a fluffy boundary due to spread through the alveolar sacs via the pores of Kohn.
- The consolidation does not cross any fissures.
- The volume of the opaque lung is preserved.
- Air bronchograms may be present.

Case 2**Pediatric Right Upper Lobe Consolidation
Abuts Major Fissure**

Clinical:

History – This 5 year old male was lethargic and looked unwell. He presented with a fever, cough productive of green sputum, and fatigue.

Symptoms – Progressively worsening cough associated with a fever of 39C. He was producing green sputum. He also complained of a mildly sore throat.

Physical – Coarse rales were heard in the right upper chest and the left lower chest. Transmitted breath sounds were also heard in these regions. His tonsils and pharynx were reddened with white exudate seen on the tonsillar fossae. His tympanic membranes were normal.

Laboratory – His white blood cell count was elevated.

Imaging Recommendation

[ACR – Chest – Acute Respiratory Illness in Immunocompetent Patient, Variant 4](#)

Chest X-ray

ODIN Link Rounded Pneumonia images, Figure 9.18A and B: <https://mistr.usask.ca/odin/?caseID=20150702231205343>

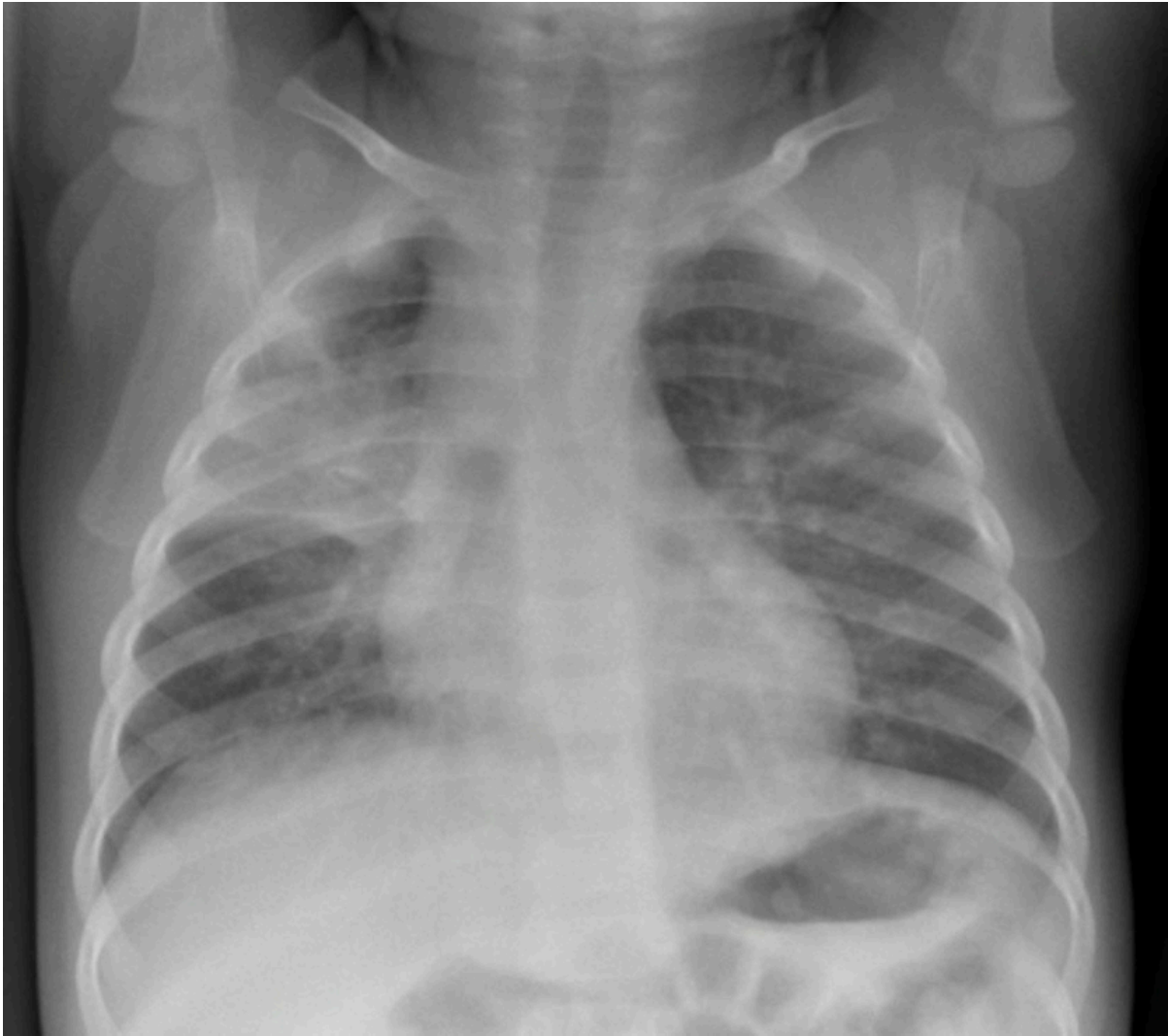


Figure 9.18A Pediatric Chest x-ray. Rounded Pneumonia

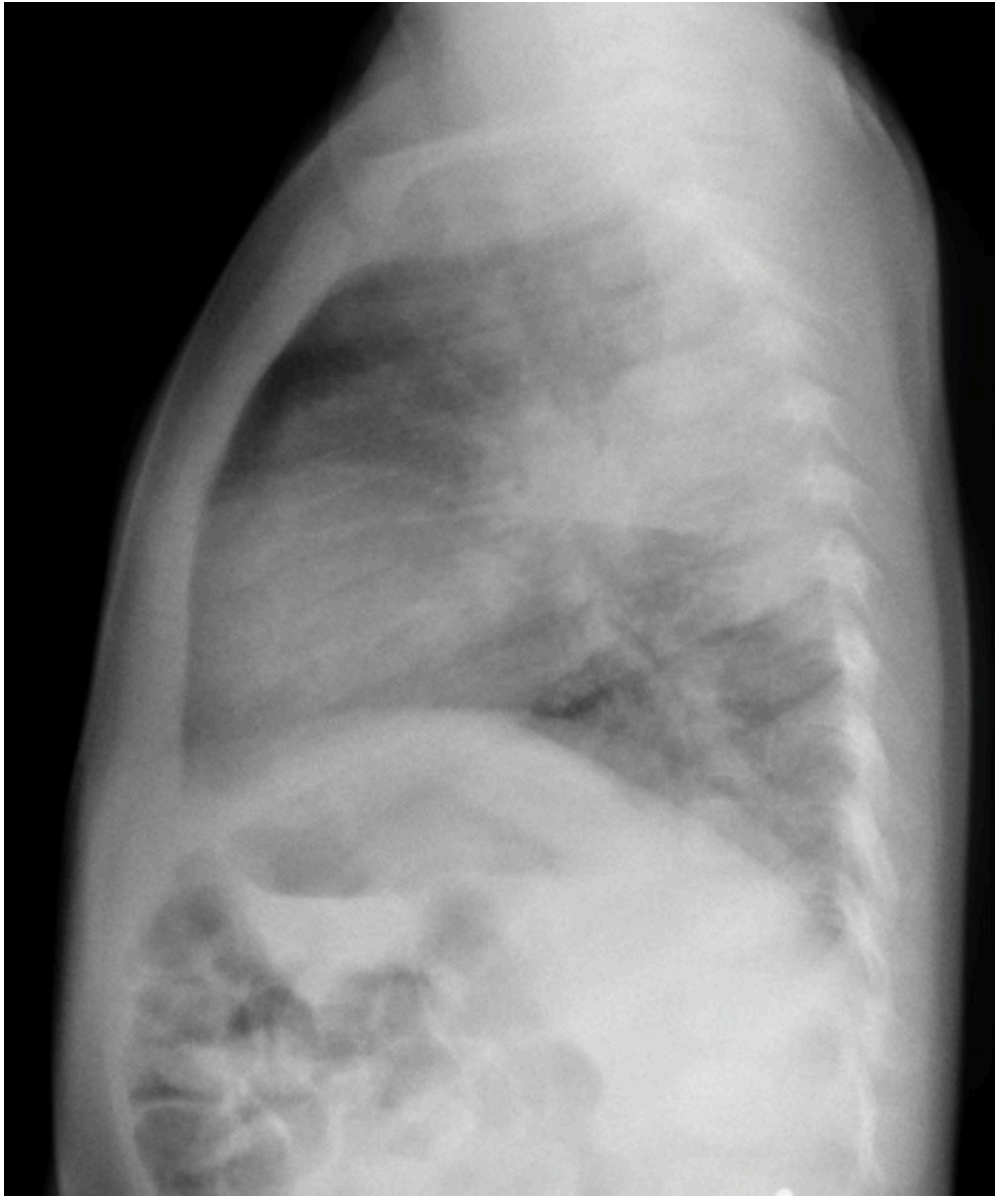


Figure 9.18B Lateral Pediatric Chest x-ray. Rounded Pneumonia.

Imaging Assessment

Findings:

There was no evidence of pleural effusion. The right upper lobe was consolidated with air bronchograms seen in this region. The edges of the lung opacity do have rounded contours at several locations. There was patchy airspace consolidation throughout the lungs. No masses or adenopathy.

Interpretation:

Right lung consolidation. If the clinical presentation includes fever, this is most likely pneumonia. The smooth contour of area of consolidation is typical for 'rounded pneumonia' most often seen in children.

Diagnosis:

Right Upper Lobe Consolidation, Rounded Pneumonia, with Air Bronchograms – Community Acquired Pneumonia

Rounded Pneumonia

This is a subtype of pneumonia that occurs in children between 2 and 10 years of age. The pores of Kohn and the communications between bronchioles are less mature in children and this prevents the spread of exudate via these pathways. Hence, the margins of the pneumonia in this subtype are smoother and more distinct resulting in a rounded edge contour of the consolidation.

Attributions

Figure 9.17A AP Chest x-ray, Pneumonia by Dr. Brent Burbridge MD, FRCPC, University Medical Imaging Consultants, College of Medicine, University of Saskatchewan is used under a [CC-BY-NC-SA 4.0](#) license.

Figure 9.17B Lateral Chest x-ray, Pneumonia by Dr. Brent Burbridge MD, FRCPC, University Medical Imaging Consultants, College of Medicine, University of Saskatchewan is used under a [CC-BY-NC-SA 4.0](#) license.

Figure 9.18A Pediatric Chest x-ray. Rounded Pneumonia by Dr. Brent Burbridge MD, FRCPC, University Medical Imaging Consultants, College of Medicine, University of Saskatchewan is used under a [CC-BY-NC-SA 4.0](#) license.

Figure 9.18B Lateral Pediatric Chest x-ray. Rounded Pneumonia by Dr. Brent Burbridge MD, FRCPC, University Medical Imaging Consultants, College of Medicine, University of Saskatchewan is used under a [CC-BY-NC-SA 4.0](#) license.

Pneumothorax

ACR – Chest – Acute Respiratory Illness in Immunocompetent Patient

Clinical:

History – This 51 year old male had mild shortness of breath after a failed, left, subclavian venous catheter insertion. Ultrasound had not been used for attempted venous access.

Symptoms – Mild shortness of breath.

Physical – He had muffled, to absent, breath sounds on the left.

Diagnosis – Iatrogenic pneumothorax related to a failed venous catheter insertion.

DDx:

Pneumothorax

Atypical Pneumonia

Hemothorax

Imaging Recommendation

[ACR – Chest – Acute Respiratory Illness in Immunocompetent Patient, Variant 4](#)

Chest X-ray

Case 1

Pneumothorax – Small Left

ODIN Link for Small Pneumothorax image. Figure 9.19A and B: <https://mistr.usask.ca/odin/?caseID=20150730223723202>

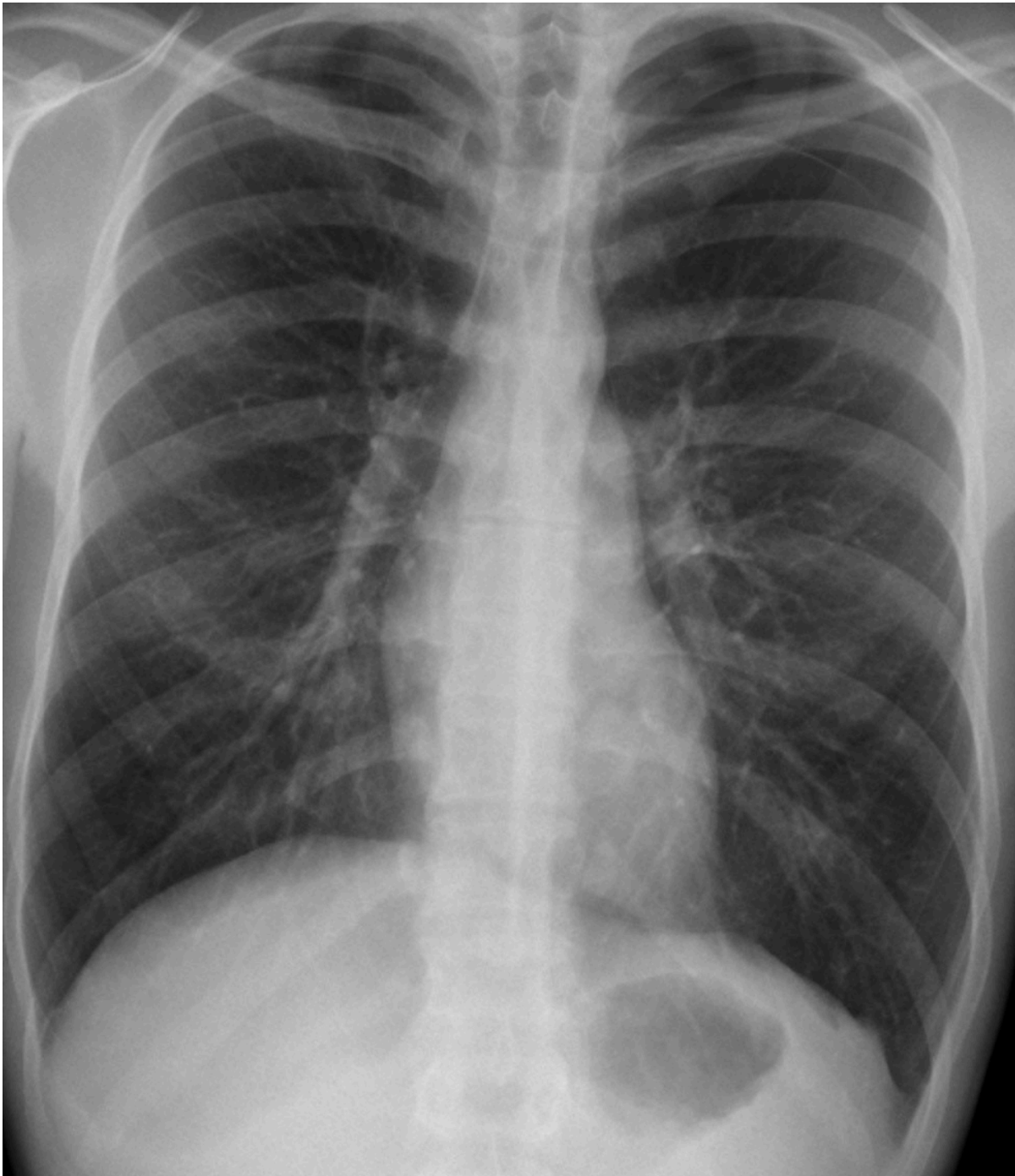


Figure 9.19A AP Chest x-ray, Pneumothorax, Small.

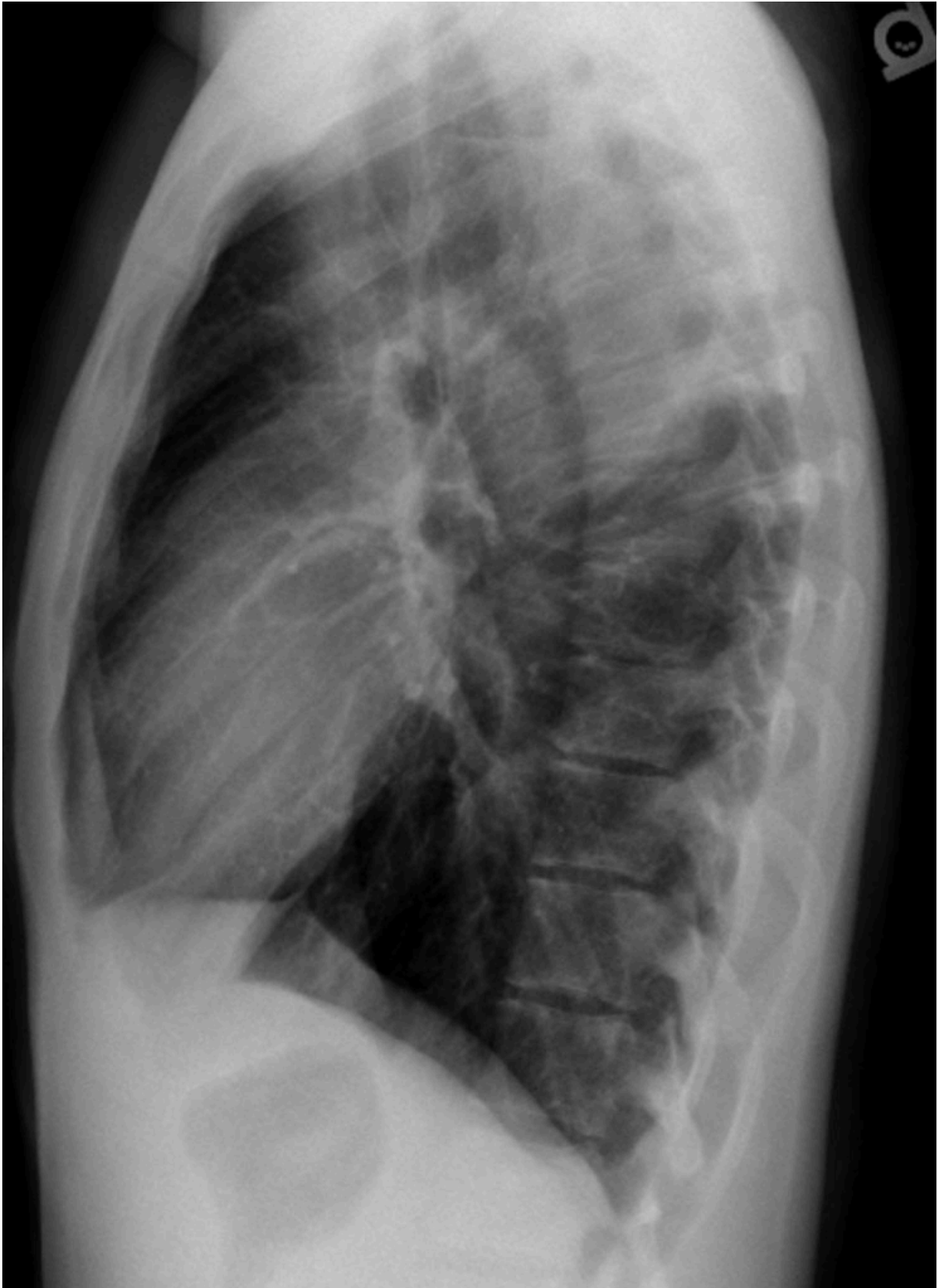


Figure 9.19B Lateral Chest x-ray, Pneumothorax, Small.

Image Assessment

Findings:

The left lung was mildly hyperinflated. There was a visible pleural line in the apex of the left hemithorax. This line was convex outward. There were no visible lung markings beyond this pleural line.

Diagnosis:

Small left pneumothorax

Discussion:

Pneumothorax may be associated with trauma, a recent medical procedure, mechanical lung ventilation, or may occur spontaneously. Typically, air leaks out of the lung due to puncture, tear, or rupture in the visceral pleura. This air accumulates between the two pleural layers. Less commonly, there is an open wound in the chest wall that allows air to enter the pleural space.

Most pneumothoraces are caused by trauma. Lung injury may be caused by a projectile (low velocity – knife or high velocity – bullet). Alternatively, the chest wall is injured causing fractures of ribs that lacerate the pleura. Trauma can also cause a tear of the bronchus or lung leading to a pneumothorax.

Small pneumothoraces are often asymptomatic, but as they enlarge the patient may become short of breath and develop pleural pain. There may be distant breath sounds and less often an audible pleural rub.

X-ray findings may include:

- Ipsilateral hemithorax may be more lucent.
- The visceral pleura may be seen as a visible white line with lucency beyond this.
- This pleural line is convex outward.
- There are no visible lung markings beyond the pleural line.
- The ipsilateral lung may demonstrate atelectasis as the lung collapses.
- If an air/fluid level is seen in the pleural space due to bleeding, infection, chyle, or transudate this is a clue to the presence of pneumothorax as air rises to create the air/fluid level.
- If the pneumothorax becomes larger it may push the mediastinum into the contralateral hemithorax (tension pneumothorax).
- On a supine radiograph the costophrenic angle may become deeper and be more prominent. Also, the cardiac margin may become more distinct as air rises up ventrally.

Case 2

Pneumothorax – Moderate (right)**Clinical:**

History – This 6 month old patient had been resuscitated for an acute respiratory arrest on the ward. He had been ventilated by a face mask and CPR had been performed. A chest x-ray was requested after resuscitation.

Symptoms – Shortness of breath.

Physical – He had muffled, to absent, breath sounds on the right.

Diagnosis – Pneumothorax, post-resuscitation.

Imaging Recommendation

[ACR – Chest – Acute Respiratory Illness in Immunocompetent Patient, Variant 4](#)

Chest X-ray

ODIN Link for Moderate Pneumothroax, Figure 9.20: <https://mistr.usask.ca/odin/?caseID=20110802141052824>

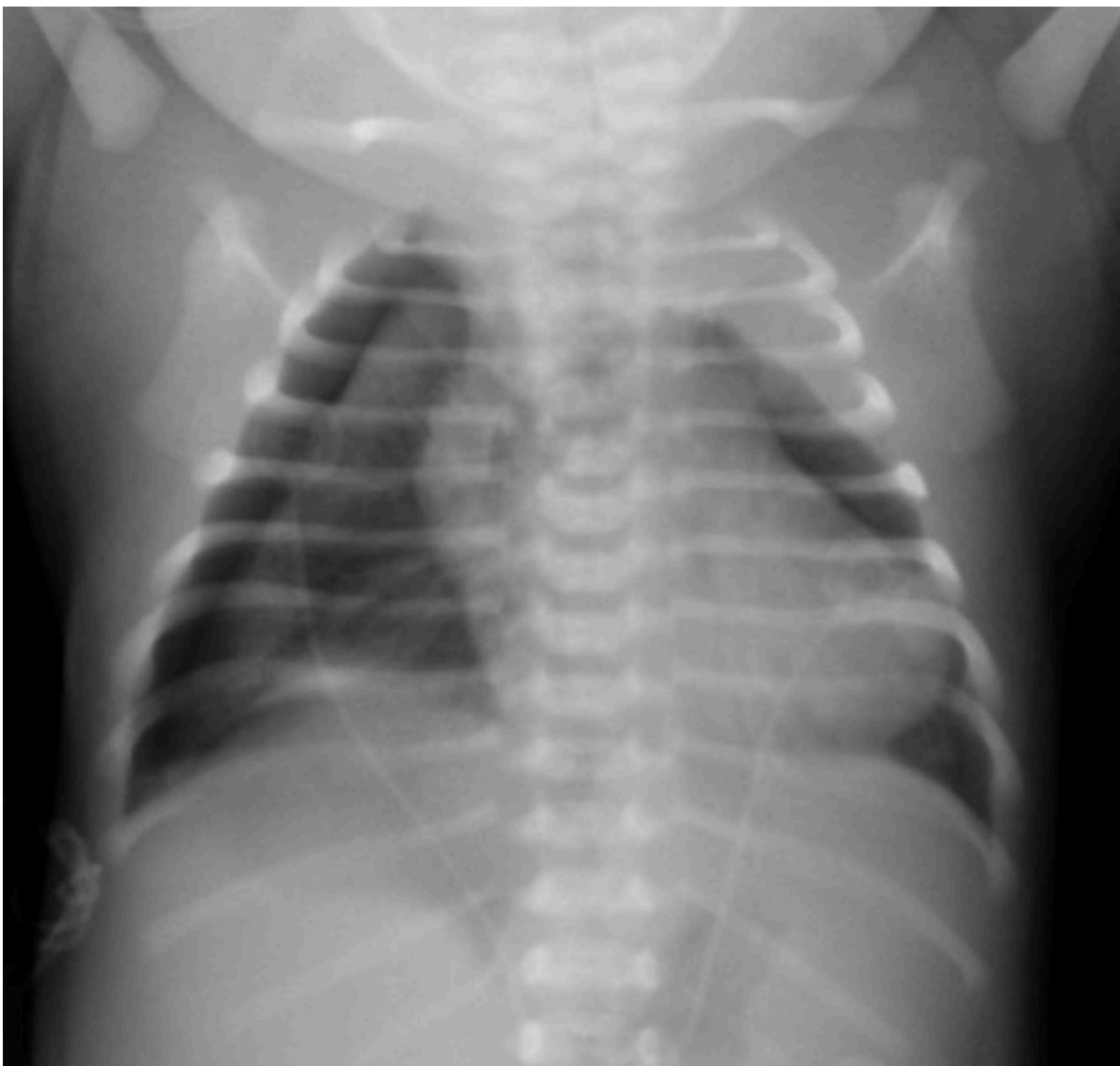

Figure 9.20 PA Chest x-ray, Pneumothorax, Moderate.

Image Assessment

Findings:

There was a visible pleural line in the right hemithorax. This line is convex outward. There was a small pleural effusion on the left seen in the apex of the chest due to the supine position.

Diagnosis:

Moderate right pneumothorax. Probably related to baro-trauma during resuscitation.

Case 3

Pneumothorax – Tracheal Deviation – Tension (*left*)**Clinical:**

History – This 36 year old female had left chest pain and shortness of breath after a piercing (body adornment) was inserted into the left anterior chest wall.

Symptoms – Shortness of breath. Left chest pain. Anxiety.

Physical – She had muffled, to absent, breath sounds on the left. The trachea was markedly deviated to the right. The patient was in distress.

Diagnosis – Tension pneumothorax, caused by a piercing traversing the parietal and visceral pleural, lacerating the underlying lung.

Imaging Recommendation

[ACR – Chest – Acute Respiratory Illness in Immunocompetent Patient, Variant 4](#)

Chest X-ray

ODIN Link for Tension Pneumothorax images, Figure 9.21A and B: <https://mistr.usask.ca/odin/?caseID=20151218105631900>

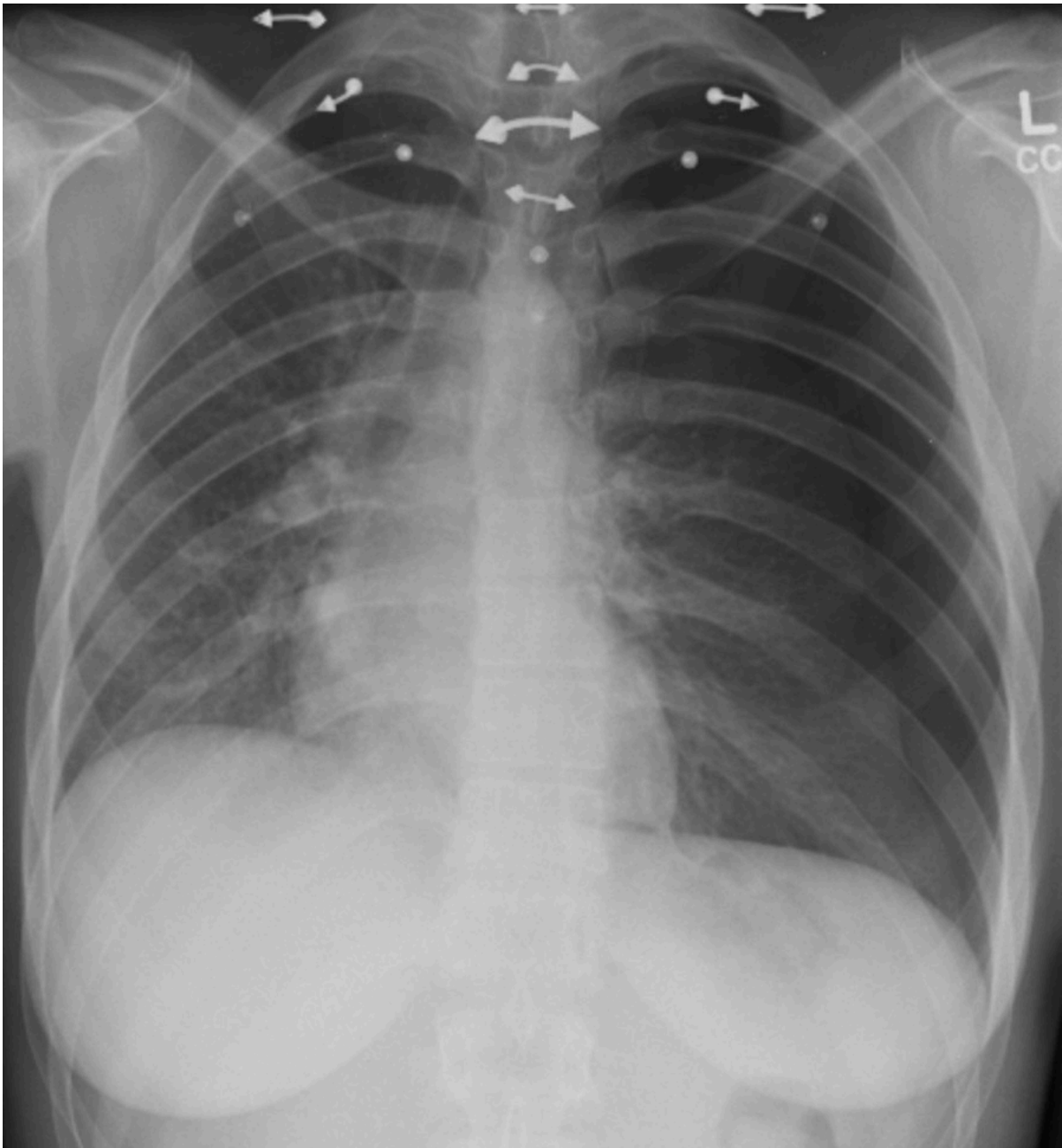


Figure 9.21A AP Chest x-ray, Pneumothorax, Tension

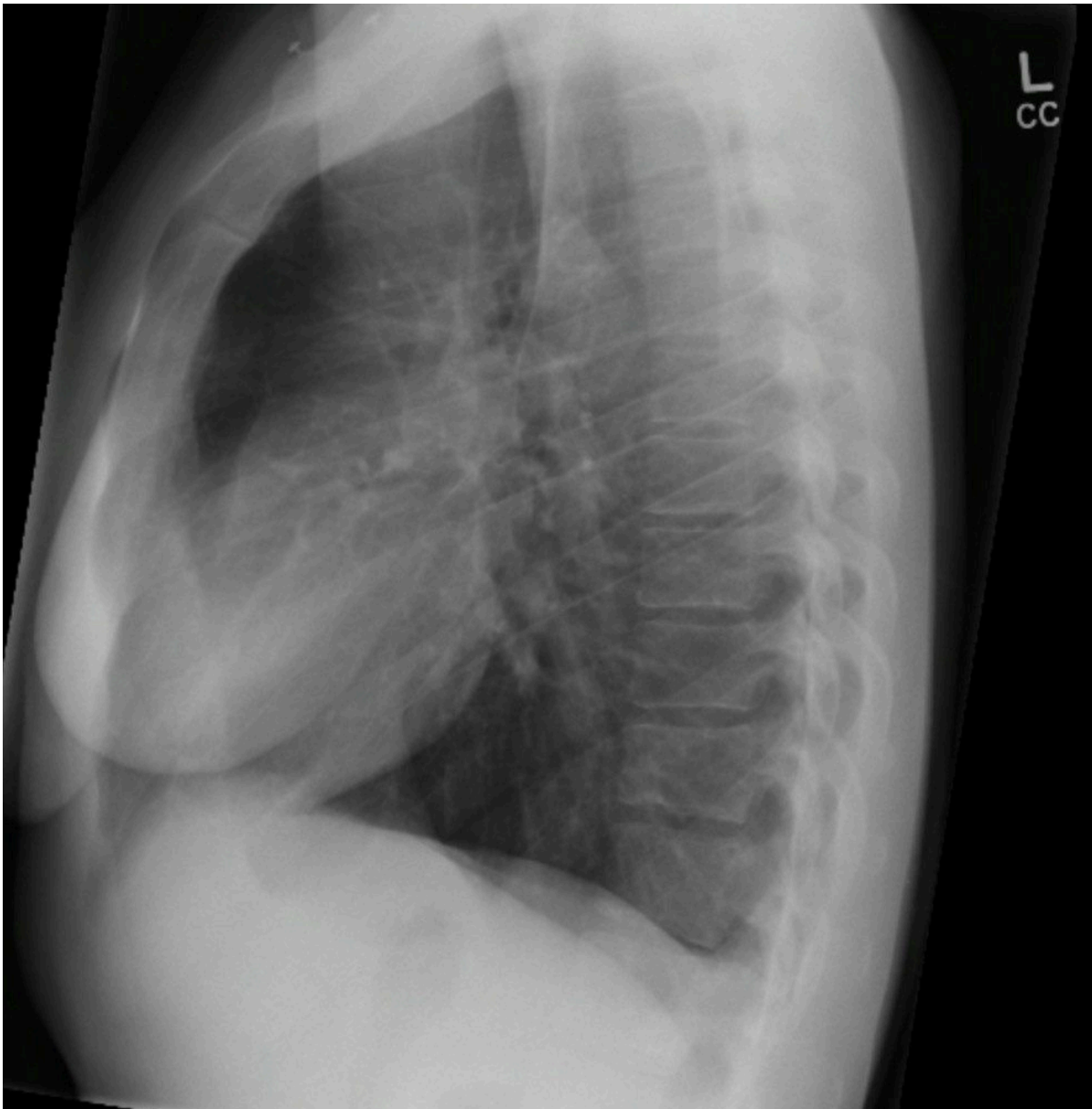


Figure 9.21B Lateral Chest x-ray, Pneumothorax, Tension

Attributions

Figure 9.19A AP Chest x-ray, Pneumothorax, Small by Dr. Brent Burbridge MD, FRCPC, University Medical Imaging Consultants, College of Medicine, University of Saskatchewan is used under a [CC-BY-NC-SA 4.0](https://creativecommons.org/licenses/by-nc-sa/4.0/) license.

Figure 9.19B Lateral Chest x-ray, Pneumothorax, Small by Dr. Brent Burbridge MD, FRCPC, University Medical Imaging Consultants, College of Medicine, University of Saskatchewan is used under a [CC-BY-NC-SA 4.0](https://creativecommons.org/licenses/by-nc-sa/4.0/) license.

Figure 9.20 PA Chest x-ray, Pneumothorax, Moderate by Dr. Brent Burbridge MD, FRCPC, University Medical

Imaging Consultants, College of Medicine, University of Saskatchewan is used under a [CC-BY-NC-SA 4.0](#) license.

Figure 9.21A AP Chest x-ray, Pneumothorax, Tension by Dr. Brent Burbridge MD, FRCPC, University Medical Imaging Consultants, College of Medicine, University of Saskatchewan is used under a [CC-BY-NC-SA 4.0](#) license.

Figure 9.21B Lateral Chest x-ray, Pneumothorax, Tension by Dr. Brent Burbridge MD, FRCPC, University Medical Imaging Consultants, College of Medicine, University of Saskatchewan is used under a [CC-BY-NC-SA 4.0](#) license.

Emphysema

ACR – Chest – Chronic Dyspnea – Suspected Pulmonary Origin

Clinical:

History – Known history of chronic lung disease. The patient was a 50 pack/year cigarette smoker.

Symptoms – Cough – dry, shortness of breath, and wheezing.

Physical – Increased AP diameter, indrawing on inspiration, pursed lip breathing, distant breath sounds, hyperresonant chest percussion.

DDx:

Emphysema – Chronic Obstructive Pulmonary Disease (COPD)

Asthma

Imaging Recommendation

[ACR – Chest – Chronic Dyspnea – Suspected Pulmonary Origin, Variant 1](#)

Chest X-ray

Case 1

Moderate

ODIN Link for Moderate Emphysema images, Figure 9.22A and B: <https://mistr.usask.ca/odin/?caseID=20150210214936966>

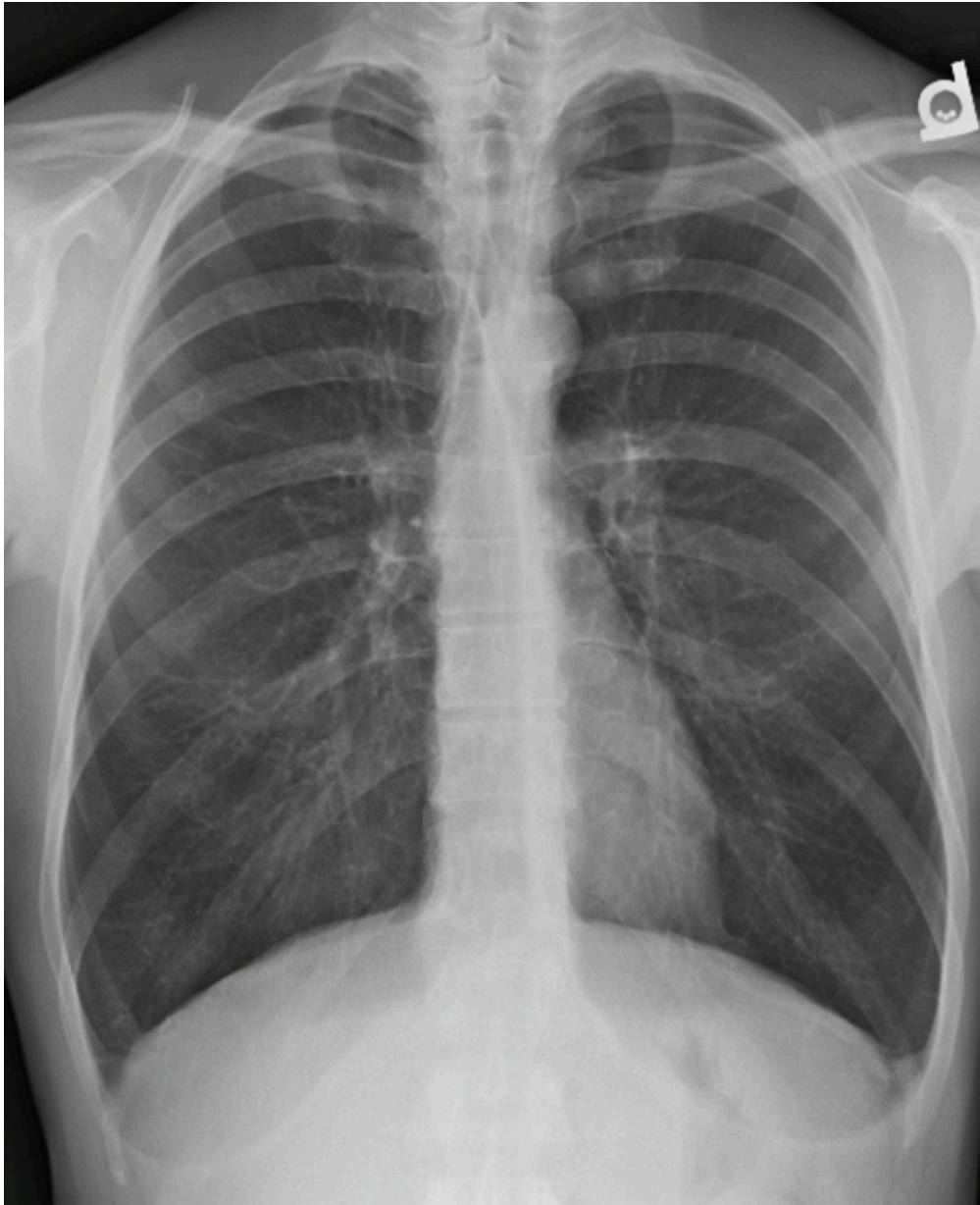


Figure 9.22A PA Chest x-ray displaying moderate COPD

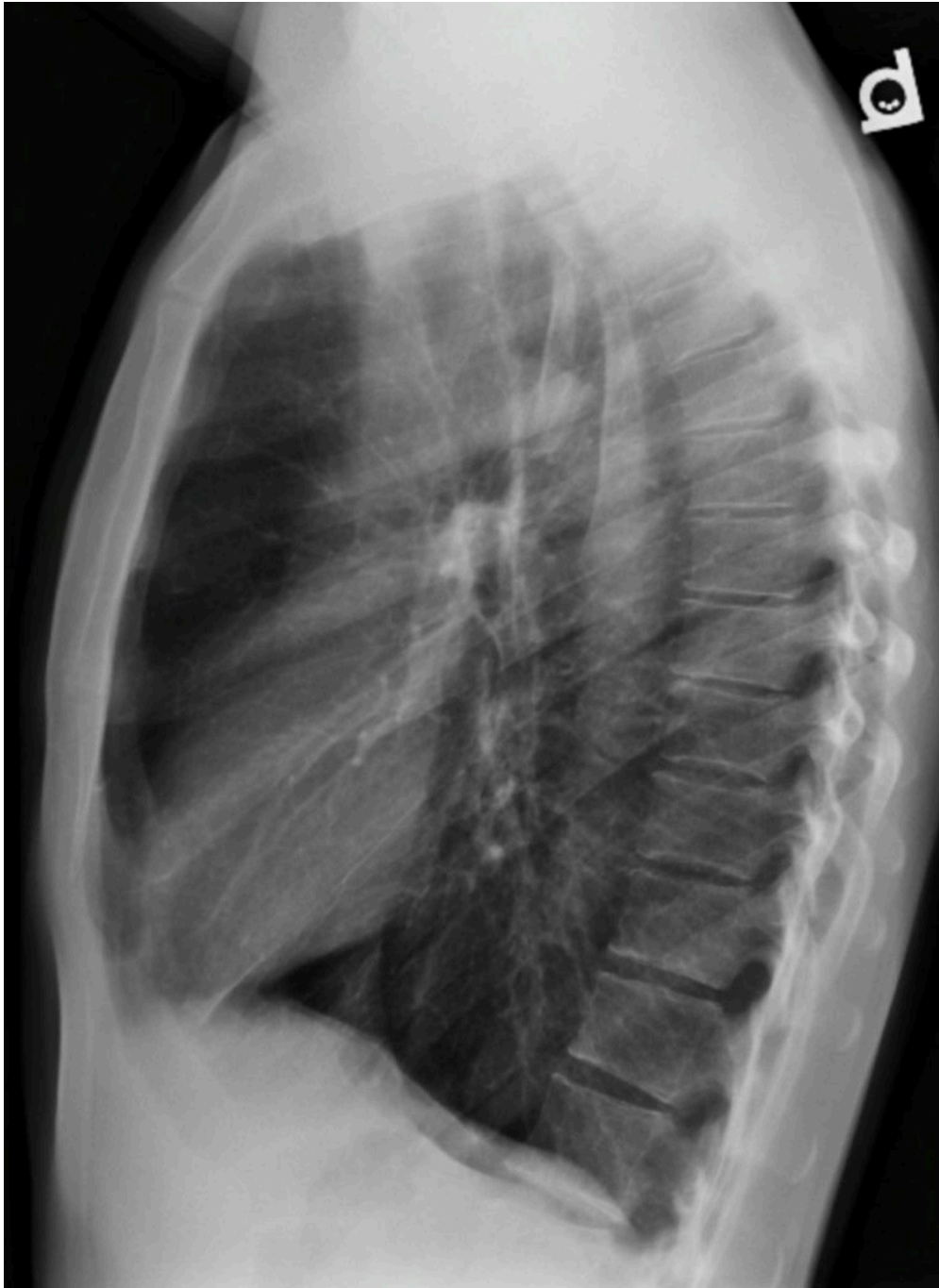

Figure 9.22B Lateral Chest x-ray displaying moderate COPD

Imaging Assessment

Findings:

There was evidence of hyperinflation, including flattening of the diaphragm, especially on the lateral x-ray. The retrosternal clear space was widened and the AP diameter of the chest was increased. The lungs were hyperlucent with minimal deficiency of peripheral vascular markings. No evidence of pre-capillary hypertension.

Interpretation:

The abnormalities are in keeping with COPD.

Diagnosis:

COPD

Pathology:

Chronic Obstructive Pulmonary Disease

Discussion:

(COPD) is a long-term response to inhaled irritants or chemicals (tobacco smoke). This exposure leads to a cascade of inflammation, infection, and prostease enzyme imbalance that leads to the destruction of the connective tissues of the bronchi and acini of the lungs. The lungs become simplified into larger air containing spaces with damaged alveoli and bronchi.

The diagnosis of COPD is not made with chest radiographs but with clinical assessment and pulmonary ventilation testing to detect altered air flow related to expiratory obstruction during the breathing cycle. Radiographic findings may be very subtle to non-existent in the early stages of COPD.

- Chronic obstructive lung disease (COPD) is defined as a disease of airflow obstruction due to chronic bronchitis or emphysema.
- Chronic bronchitis is defined clinically by productive cough, whereas emphysema is defined pathologically by the presence of permanent and abnormal enlargement and destruction of the air spaces distal to the terminal bronchioles.
- Emphysema has three pathologic patterns
- Centriacinar (centrilobular) emphysema features focal destruction limited to the respiratory bronchioles and the central portions of the acinus. It is associated with cigarette smoking and is most severe in the upper lobes.
- Panacinar emphysema involves the entire alveolus distal to the terminal bronchiole. It is most severe in the lower lung zones and generally develops in patients with homozygous alpha 1 -antitrypsin deficiency.
- Paraseptal emphysema is the least common form. It involves distal airway structures, alveolar ducts, and sacs. Localized to fibrous septa or to the pleura, it can lead to formation of bullae, which may cause pneumothorax. It is not associated with airflow obstruction.

X-ray findings may include:

- Flattened hemidiaphragms due to overinflation of the lungs

- Increased AP diameter of the chest
- The retrosternal air space may become enlarged.
- The lungs become more lucent as the air spaces coalesce into larger simplified air containing regions.
- The vessels in the peripheral lung become cut-off and tapered.
- There may be large, air-containing, cystic spaces in the lungs (bullae)

Case 2

Severe

Clinical:

History – Known history of chronic lung disease. The 75 year old patient was a 60 pack/year cigarette smoker.

Symptoms – Cough – dry, shortness of breath, and wheezing. Unable to walk more than 50 steps due to severe shortness of breath.

Physical – Increased AP diameter, in drawing on inspiration, pursed lip breathing, distant breath sounds, hyper-sonant chest percussion.

Imaging Recommendation

[ACR – Chest – Chronic Dyspnea – Suspected Pulmonary Origin, Variant 1](#)

Chest X-ray

ODIN Link for Severe Emphysema images, Figure 9.23A and B: <https://mistr.usask.ca/odin/?caseID=20150428195929268>

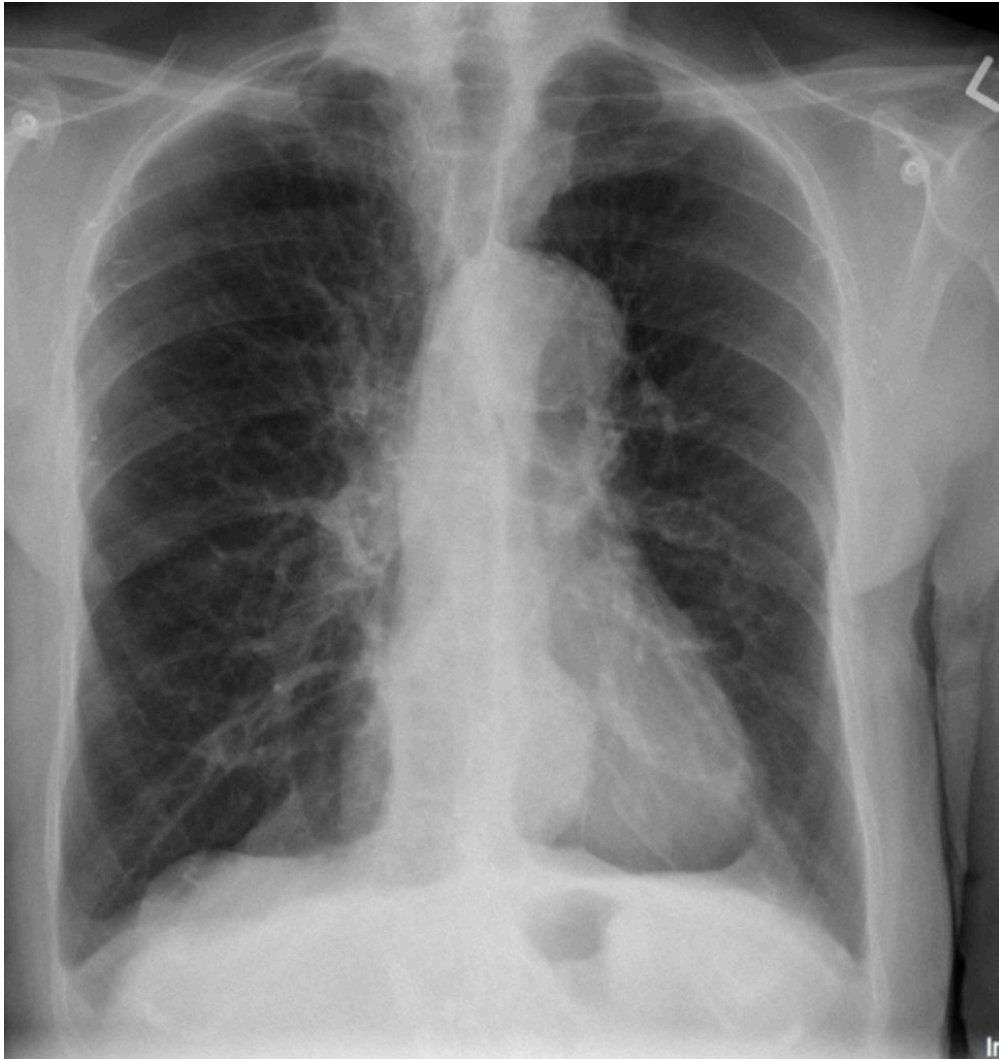


Figure 9.23A PA Chest x-ray displaying severe COPD.

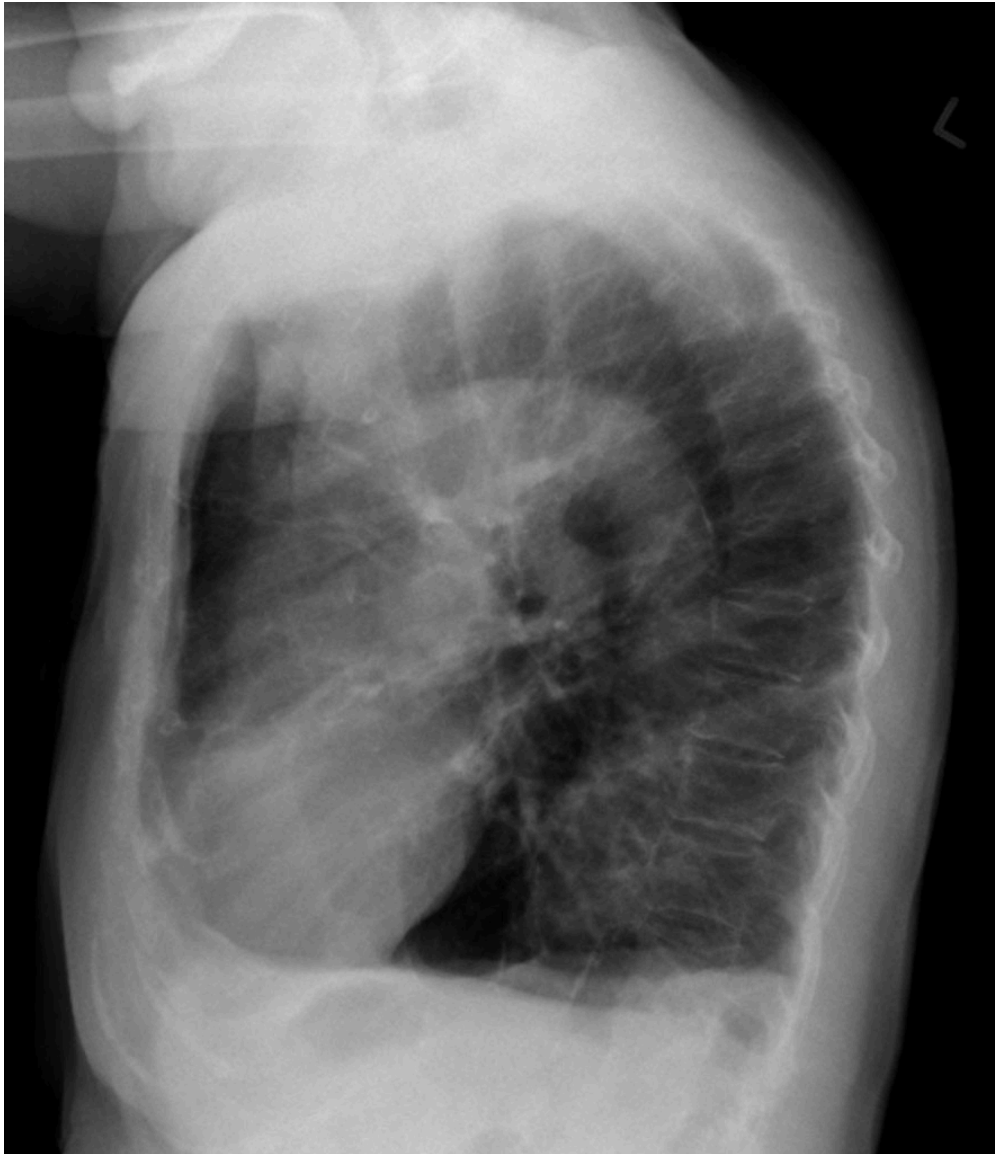

Figure 9.23B Lateral Chest x-ray displaying severe COPD.

Imaging Assessment

Findings:

There was evidence of hyperinflation, including severe flattening of the diaphragm, especially on the lateral x-ray they were inverted. The retrosternal clear space was widened and the AP diameter of the chest was increased. The lungs were hyperlucent with a deficiency of peripheral vascular markings. There was enlargement of the central pulmonary arteries consistent with pre-capillary hypertension.

Interpretation:

The abnormalities are in keeping with COPD.

Diagnosis:

COPD – Severe, with pulmonary artery hypertension

Pathology:

Chronic Obstructive Pulmonary Disease

Attributions

Figure 9.22A PA Chest x-ray displaying moderate COPD by Dr. Brent Burbridge MD, FRCPC, University Medical Imaging Consultants, College of Medicine, University of Saskatchewan is used under a [CC-BY-NC-SA 4.0](#) license.

Figure 9.22B Lateral Chest x-ray displaying moderate COPD by Dr. Brent Burbridge MD, FRCPC, University Medical Imaging Consultants, College of Medicine, University of Saskatchewan is used under a [CC-BY-NC-SA 4.0](#) license.

Figure 9.23A PA Chest x-ray displaying severe COPD by Dr. Brent Burbridge MD, FRCPC, University Medical Imaging Consultants, College of Medicine, University of Saskatchewan is used under a [CC-BY-NC-SA 4.0](#) license.

Figure 9.23B Lateral Chest x-ray displaying severe COPD by Dr. Brent Burbridge MD, FRCPC, University Medical Imaging Consultants, College of Medicine, University of Saskatchewan is used under a [CC-BY-NC-SA 4.0](#) license.

Solitary Lung Nodule

ACR – Chest – Radiographically Detected Solitary Pulmonary Nodule

Case

Incidental, Solitary Pulmonary Nodule

Clinical:

History – As part of a General Physical Exam, a routine chest x-ray was ordered on this 53 year old male. His last physical examination was 3 years ago. Chronic smoker. Mild COPD. Insulin dependent diabetic.

Symptoms – Dry cough, mild chronic dyspnea. Nil acute.

Physical – Non-contributory.

DDx:

Routine screening, smoker.

Solitary pulmonary nodule detected.

Imaging Recommendation

[ACR – Chest – Radiographically Detected Solitary Pulmonary Nodule, Variant 1](#)

Chest X-ray

CT Chest without and with IV contrast

ODIN Link for Chest x-ray images, Figure 9.24A and B: <https://mistr.usask.ca/odin/?caseID=20170202123906863>

ODIN Link for Chest CT images, 9.24: <https://mistr.usask.ca/odin/?caseID=20170202131226013>

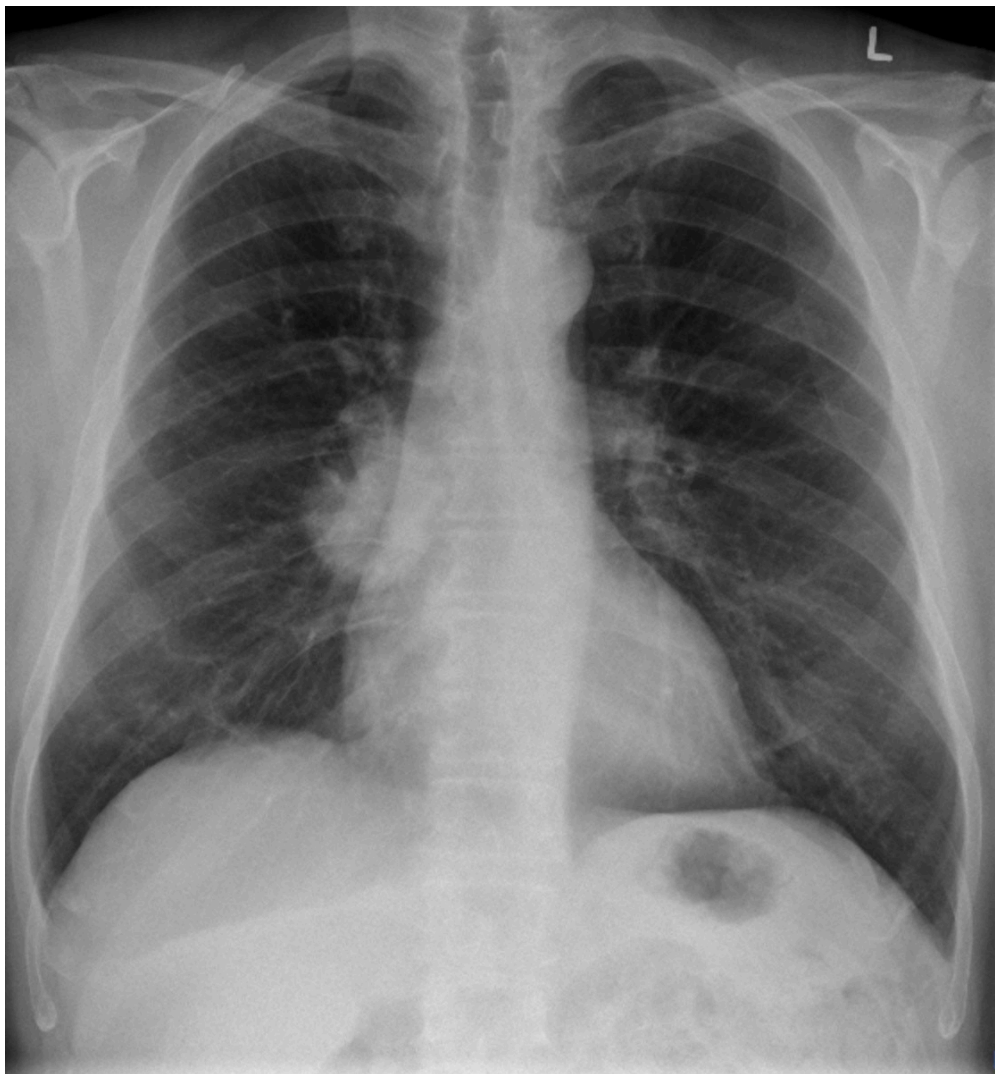


Figure 9.24A PA Chest x-ray displaying a solitary lung nodule

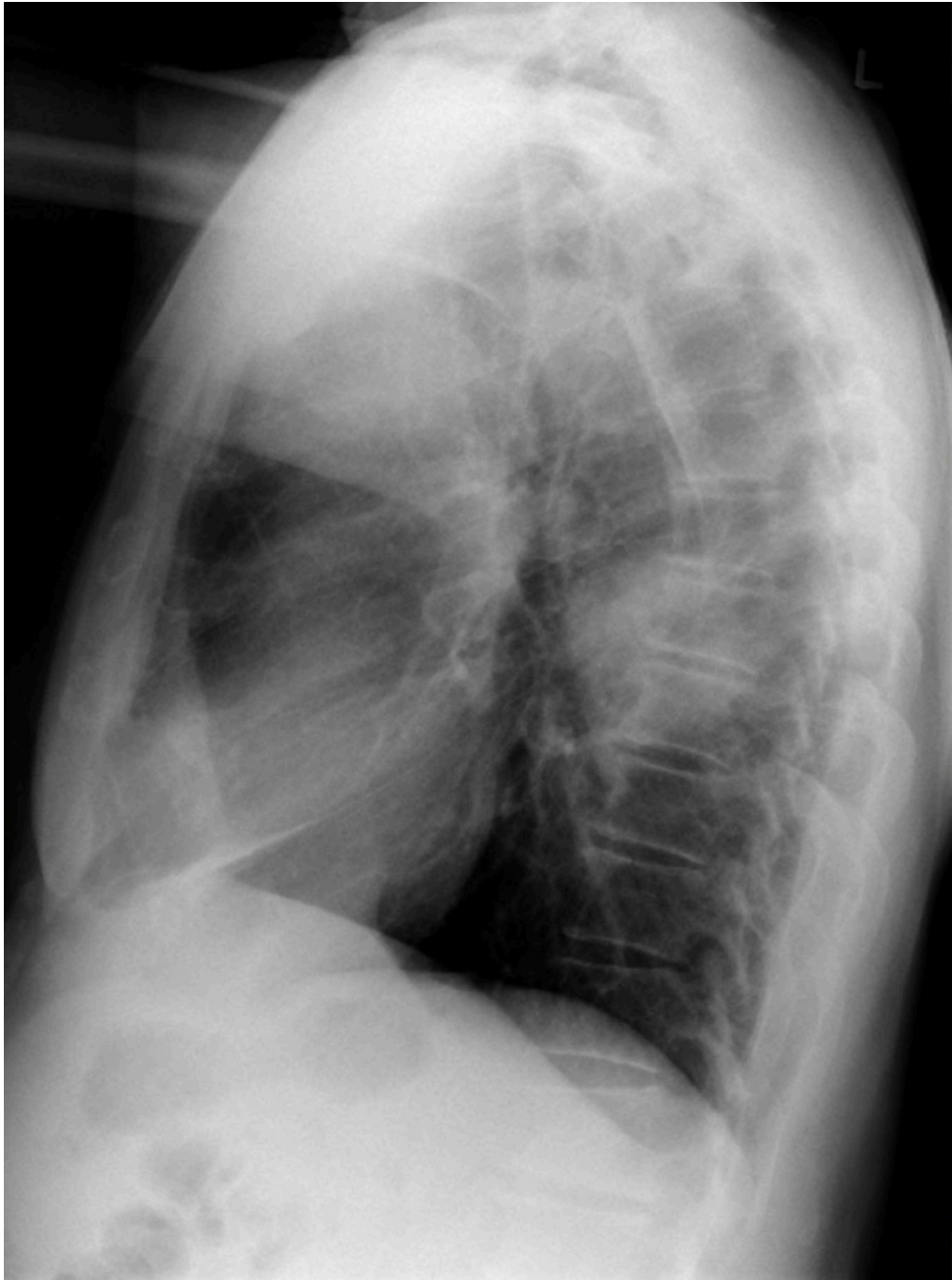


Figure 9.24B Lateral Chest x-ray demonstrating a solitary pulmonary nodule

Imaging Assessment

Findings:

There were changes of mild COPD. A 2.5 – 3 cm diameter, circumscribed, opacity was seen in the right lower lobe. The opacity overlapped the right hilum and the thoracic spine. No other findings.

Interpretation:

Solitary pulmonary nodule. This abnormality was suspicious for a malignancy. CT of the chest was recom-

mended for further assessment. If concern persists for malignancy after this examination an imaging guided needle biopsy of the lung nodule should be considered.

Diagnosis:

Solitary Pulmonary Nodule – Suspicious for Malignancy

Discussion:

A **nodule** is defined as a **circumscribed opacity < 3 cm in diameter**. The differential is broad. There are imaging features that suggest benignity, while for others there are imaging features that require imaging follow-up or biopsy.

The Fleischner Society has established nodule follow-up guidelines:

<https://fleischnersociety.org>

X-ray findings may include:

- A nodule or mass is an opacity with smooth or lobulated margins.
- The margins of the nodule or mass may be smooth, lobulated, or spiculated.
- There may be calcification in the nodule or mass.
- Masses may grow to invade the pleura, chest wall, hilum, mediastinum, and may cross fissures.
- The mass may have adenopathy or pleural effusion associated with it.

Attributions

Figure 9.24A PA Chest x-ray displaying a solitary lung nodule by Dr. Brent Burbridge MD, FRCPC, University Medical Imaging Consultants, College of Medicine, University of Saskatchewan is used under a [CC-BY-NC-SA 4.0](https://creativecommons.org/licenses/by-nc-sa/4.0/) license.

Figure 9.24B Lateral Chest x-ray displaying a solitary lung nodule by Dr. Brent Burbridge MD, FRCPC, University Medical Imaging Consultants, College of Medicine, University of Saskatchewan is used under a [CC-BY-NC-SA 4.0](https://creativecommons.org/licenses/by-nc-sa/4.0/) license.

Multiple Lung Nodules

Case

Multiple Pulmonary Nodules

Clinical:

History – This 64 year old female had a nephrectomy for renal cell carcinoma 1 year ago. She was lost to follow-up. She was seeing her primary physician for mild chest pain, shortness of breath, and fatigue.

Symptoms – Mild, dull, chest pain. Weight loss (7 kg in 3 months). Fatigue.

Physical – Nephrectomy scar was seen. Nil else.

DDx:

Infection, Pneumonia

Malignancy

Imaging Recommendation

Chest X-ray

ODIN Link for Multiple Pulmonary Nodules images, Figure 9.25: <https://mistr.usask.ca/odin/?caseID=20170119104540694>

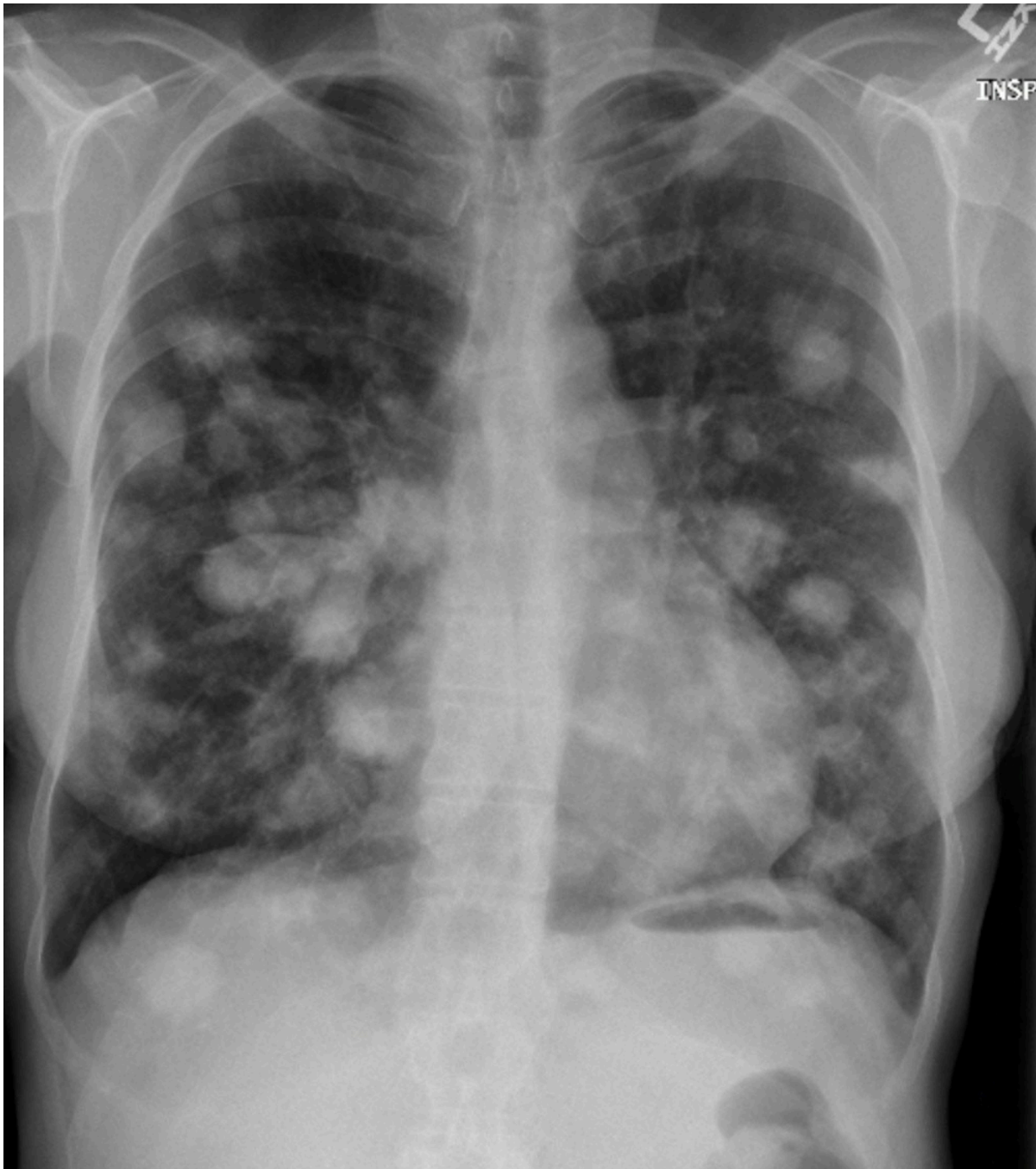


Figure 9.25 Chest x-ray displaying multiple lung nodules

Imaging Assessment

Findings:

There were multiple nodules in both lungs of varying sizes. They were round and well marginated. No evidence of central necrosis. No evidence of lymphadenopathy. No other findings.

Interpretation:

Embolic infection

Embolic malignancy

Diagnosis:

Metastatic Disease – Renal Cell Carcinoma

Discussion:

Multiple nodules in the lung are most often metastatic lesions that have traveled through the bloodstream from a distant primary (hematogenous spread). Hematogenous spread of infection may also be possible. Multiple metastatic nodules are usually of differing sizes, varying from micronodular to “cannonball” masses, indicating tumour embolization that occurred at different times. They are frequently sharply marginated.

Possible Tumours of Origin:	
Males	Females
<i>Colorectal carcinoma</i>	Breast cancer
Renal cell carcinoma	Colorectal carcinoma
Head and neck tumors	Renal cell carcinoma
Testicular and bladder carcinoma	Cervical or endometrial carcinoma
Malignant melanoma	Malignant melanoma
Sarcomas	Sarcomas

Possible Primary Tumours that may result in Lung Metastases, by Gender

X-ray findings may include:

- Nodules of similar or varying sizes.
- The patient may be cachectic due to malignancy.
- The nodules may be smooth or lobulated.
- There may be cavitation in some types of nodules or masses.

Attributions

Figure 9.25 Chest x-ray displaying multiple lung nodules by Dr. Brent Burbridge MD, FRCPC, University Medical Imaging Consultants, College of Medicine, University of Saskatchewan is used under a [CC-BY-NC-SA 4.0](https://creativecommons.org/licenses/by-nc-sa/4.0/) license.

Pulmonary Thromboembolism

ACR – Chest – Acute Chest Pain – Suspected Pulmonary Embolism

Case 1

Pulmonary Embolism

Chest X-ray

Clinical:

History – This 40 year old female had returned to Canada from China on a long trans-Pacific flight the day before. She presented to the ER with chest pain and shortness of breath. She was on oral birth control. No other medications.

Symptoms – The patient complained of a moderate, dull, achy, left chest pain and mild shortness of breath. It came on about 2 hours after landing in the airport.

Physical – A pleuritic rub was heard in the left chest. No other abnormalities.

Laboratory – The patient’s pregnancy test was negative. Her D-Dimer was elevated. Nil else.

DDx:

Pulmonary Thromboembolism

Pneumothorax

Pneumonia

Pleurisy

Imaging Recommendation

[ACR – Chest – Acute Chest Pain – Suspected Pulmonary Embolism, Variant 1](#)

Chest X-ray

Chest CT Angiography

ODIN Link for Chest x-ray images, Figure 9.26A and B: <https://mistr.usask.ca/odin/?caseID=20151201112058093>

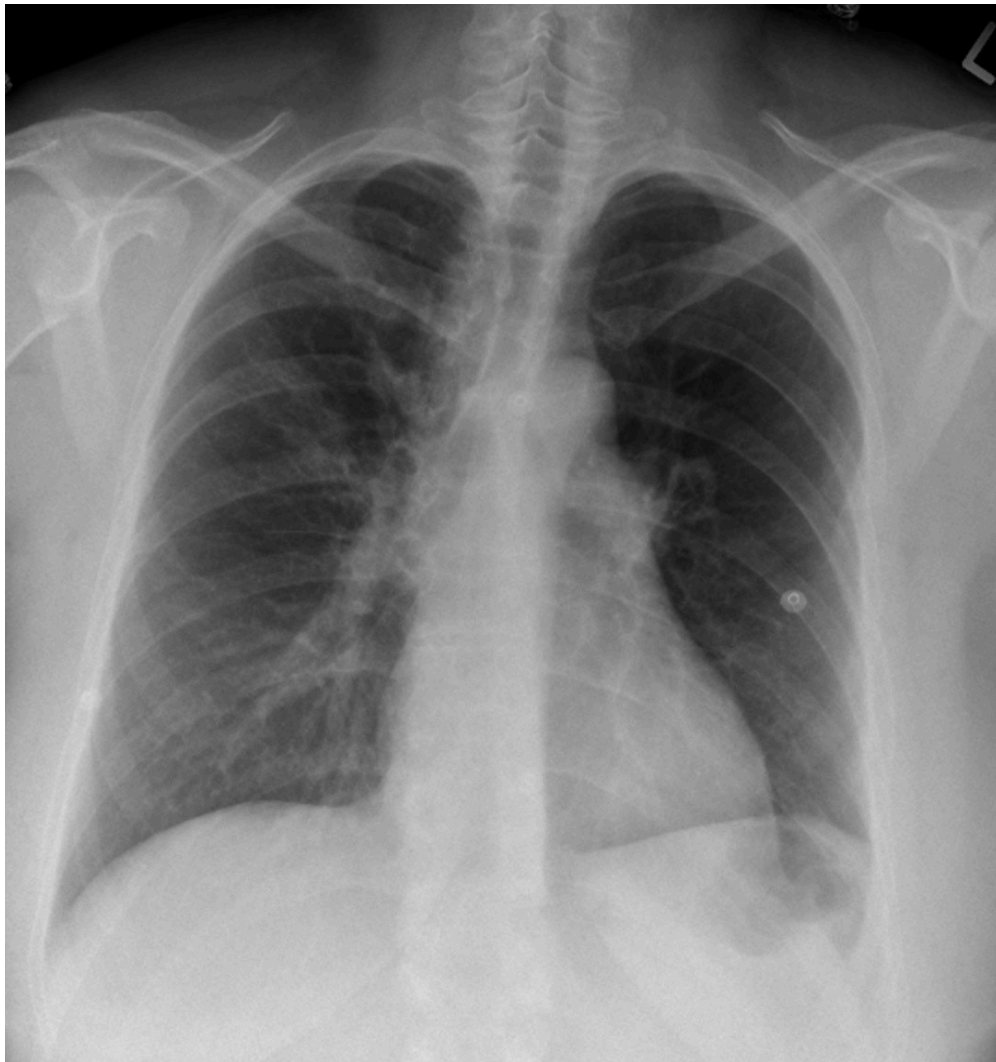


Figure 9.26A PA Chest x-ray, Pulmonary Embolism

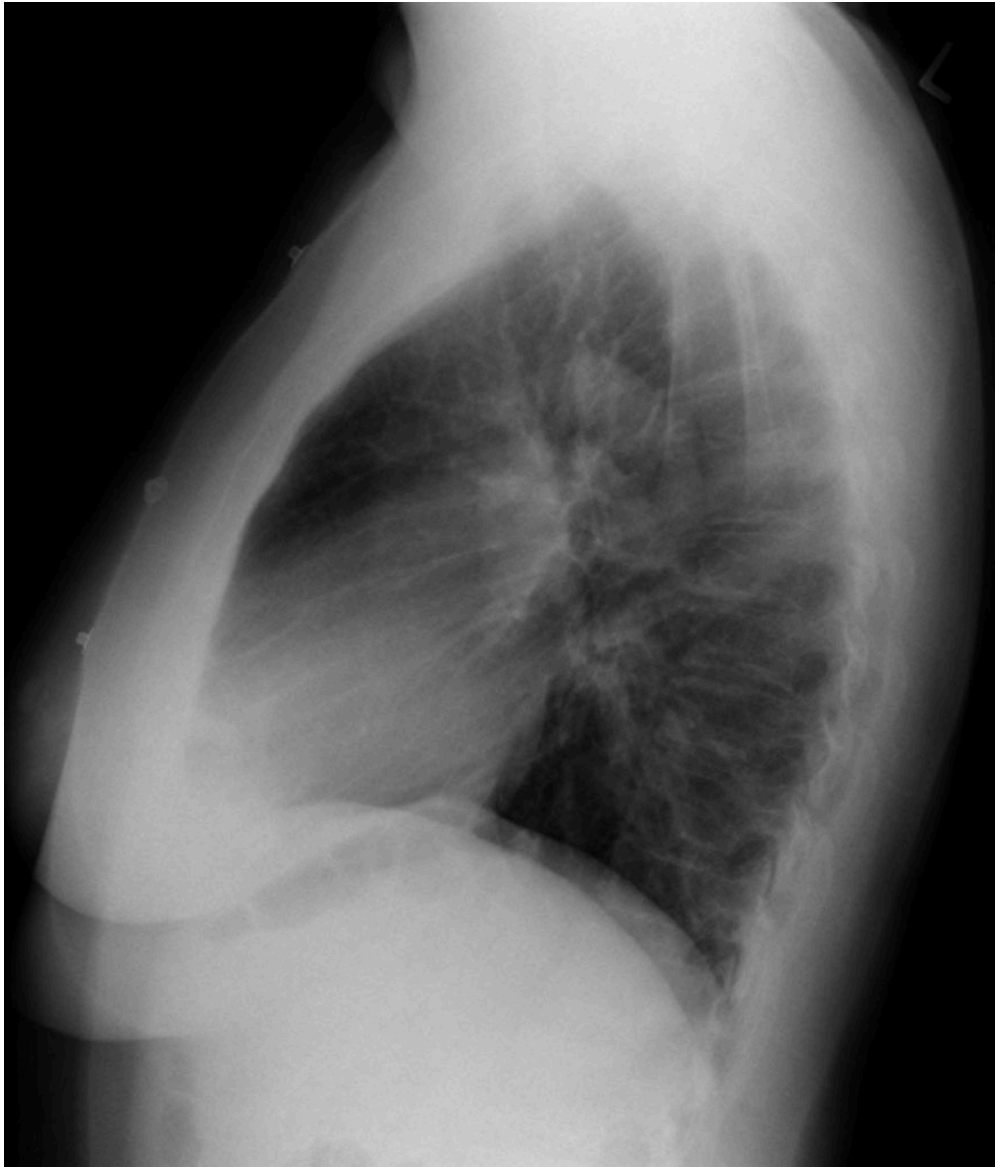


Figure 9.26B Lateral Chest x-ray, Pulmonary Embolism.

Imaging Assessment

Findings:

The cardiac silhouette was not enlarged. The left pulmonary artery was prominent and seemed to end abruptly just downstream of the left hilum. There was a paucity of vessels in the left lung.

Interpretation:

The radiographs demonstrated the, “Westermark sign” and a prominent knuckle of the left pulmonary artery. This suggested an abrupt cut-off of the pulmonary artery secondary to a thromboembolism. CT PE imaging was recommended.

Diagnosis:

High Suspicion for Pulmonary Thromboembolism. CT PE study was recommended.

Pathology:

Venous thrombus, formed in the peripheral venous system, leg, pelvis, arm, embolizes to the pulmonary arterial circulation.

Discussion:

- Over 90% of pulmonary emboli (PE) develop from thrombi in the deep veins of the leg, especially above the level of the popliteal veins. There are often concomitant associations of, recent surgery, prolonged bed rest, cancer, venous foreign body, clotting disorder, and oral contraceptives.
- Although conventional chest radiographs are frequently normal in patients with PE, they can demonstrate nonspecific findings, such as subsegmental atelectasis or small pleural effusions.
- Chest x-ray findings suggestive of PE are **very rare** i.e. Westermark's sign, Hampton's hump, vessel paucity.
- CT pulmonary angiography (CT-PA), the best test for the detection of PE (CT-PE), is made possible by the rapid acquisition of spiral CT images (one breath hold) combined with thin CT slices and rapid bolus injection of intravenous, iodinated, contrast that produces maximal opacification of the pulmonary arteries with little or no motion artifact.
- Another benefit of CT-PE studies is the ability to diagnose other diseases that may simulate PE i.e. aortic dissection, pleural effusion, etc.
- CT-PE has a sensitivity in excess of 90% and has replaced the use of V/Q scans in patients with chronic obstructive pulmonary disease or with an abnormal chest radiograph, in whom, a Nuclear Medicine V/Q scan is known to be less sensitive.
- On CT-PE, acute pulmonary emboli appear as partial or complete filling defects located within the contrast-enhanced lumina of the pulmonary arteries. (See below, Case 2 and 3)

X-ray findings may include:

- May infrequently manifest one of the "classic" findings for pulmonary embolism:
 - Wedge-shaped peripheral air-space disease (Hampton hump)
 - Focal oligemia (Westermark sign).
 - A prominent central pulmonary artery (knuckle sign).
- Pleural effusion.
- No abnormality, the most common finding.

Case 2

Pulmonary Embolism
Chest X-ray and CT

Clinical:

History – This 65 year old male was receiving chemotherapy for colon cancer. He was admitted to the hospital for management of weight loss and swollen legs. He complained of mild shortness of breath.

Symptoms – He had swollen edematous legs.

Physical – No other abnormalities on the chest examination. The legs were swollen with pitting edema.

Laboratory – Hypo-albuminia and mild anemia were noted. His D-Dimer was elevated.

ODIN Link for Pulmonary Embolism (Chest x-ray and CT PE) Images, Figure 9.27A and B:
<https://mistr.usask.ca/odin/?caseID=20170116194753575>

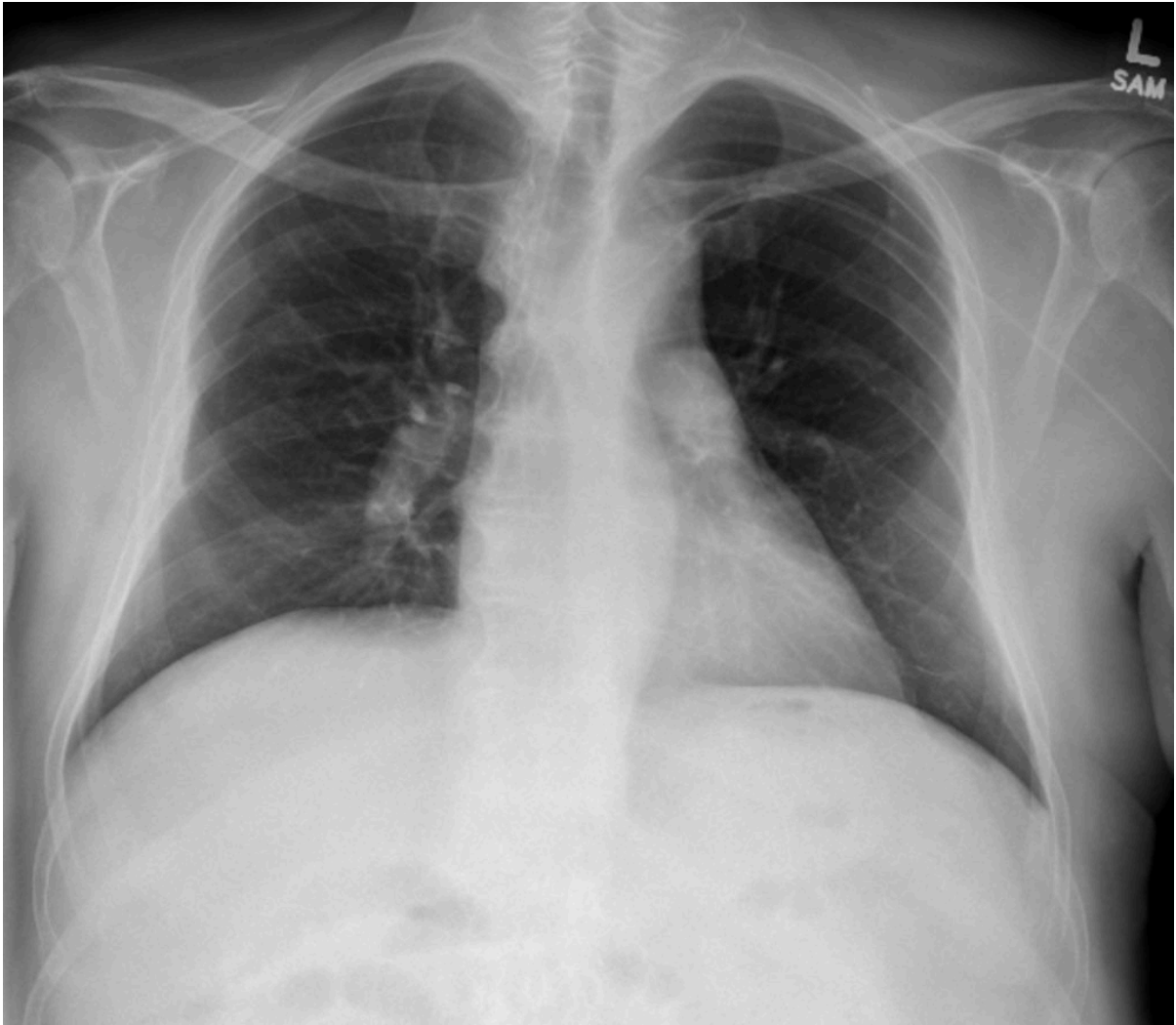


Figure 9.27A PA Chest x-ray, Pulmonary Embolism

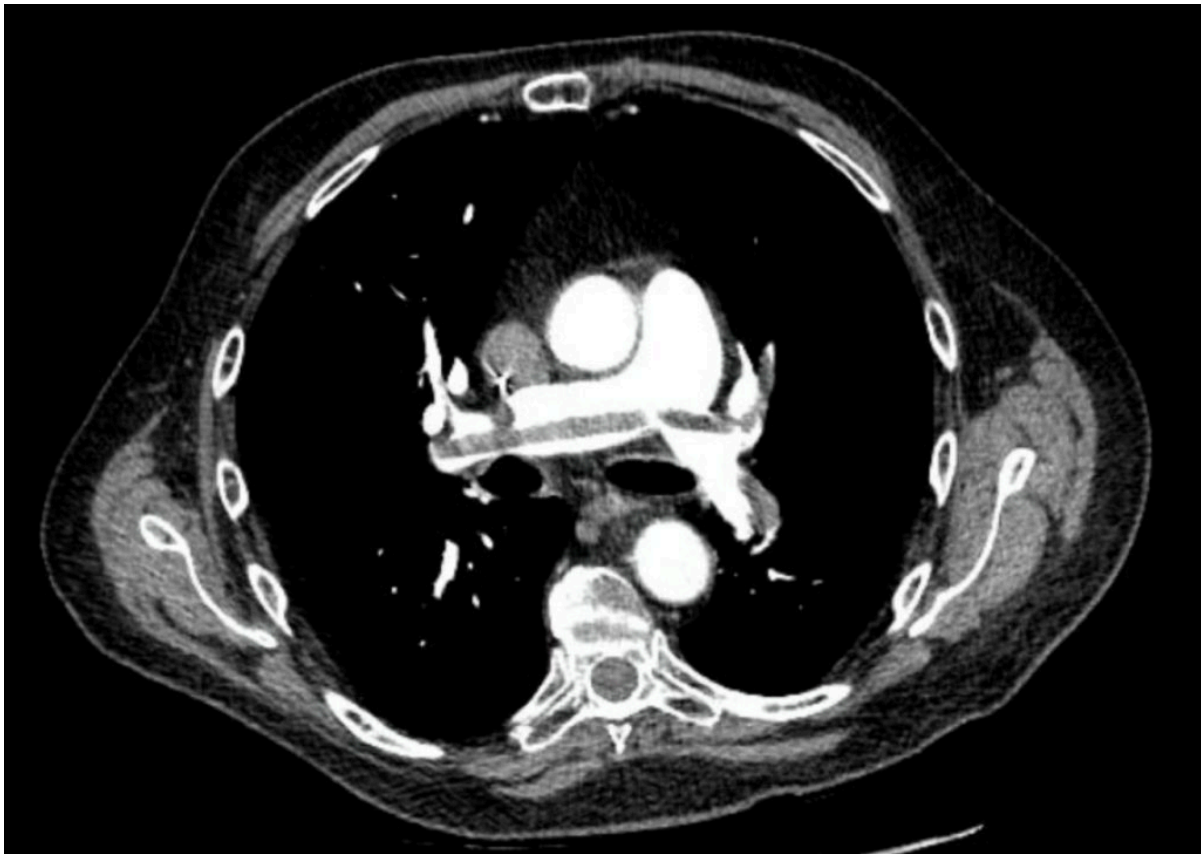


Figure 9.27B CT of the Chest, Pulmonary Embolism

Imaging Assessment

Findings, X-rays:

The cardiac silhouette was not enlarged. The central pulmonary arteries may have been mildly enlarged but this was thought to be due to the result of poor inspiratory effort leading to crowding of hilar anatomy.

Interpretation:

Normal chest x-ray. Due to the patient's signs and symptoms CT-PE imaging was recommended.

Diagnosis:

Clinically, High Suspicion for Pulmonary Thromboembolism.

Findings CT:

There was extensive pulmonary thromboembolism. There was a saddle embolus, with a long segment of thrombus straddling the main pulmonary artery bifurcation. This suggested a large peripheral venous clot burden prior to embolization. Given the patient's leg swelling, consideration should be given to the possibility of extensive leg and pelvic venous thrombosis.

Pathology:

Venous thrombus, formed in the peripheral venous system, leg, pelvis, arm, embolized to the pulmonary arterial circulation.

Case 3**Pulmonary Embolism
Chest X-ray, Nuclear Medicine, and CT****Clinical:**

History – This 25 year old female was pregnant. She was admitted to the hospital after she attended the ER for the management of moderate shortness of breath.

Symptoms – Shortness of breath.

Physical – No other abnormalities on the chest examination. Findings consistent with a 20 week gestation were note. No leg symptoms

Laboratory – Her D-Dimer was elevated.

Diagnosis: – Suspected Pulmonary Thromboembolism.

Imaging Recommendation

[ACR – Chest – Acute Chest Pain – Suspected Pulmonary Embolism, Variant 2](#)

Chest X-ray

Lower Limb Venous Doppler Ultrasound

Perfusion Nuclear Medicine Lung Scan

CT Angiography

Imaging Recommendation: Pulmonary Thromboembolism, Variant 2

ODIN Link for Pulmonary Embolism images (Chest x-ray, CT PE, Nuclear Medicine scan), Figures 9.28
– 9.30: <https://mistr.usask.ca/odin/?caseID=20151201170137752>

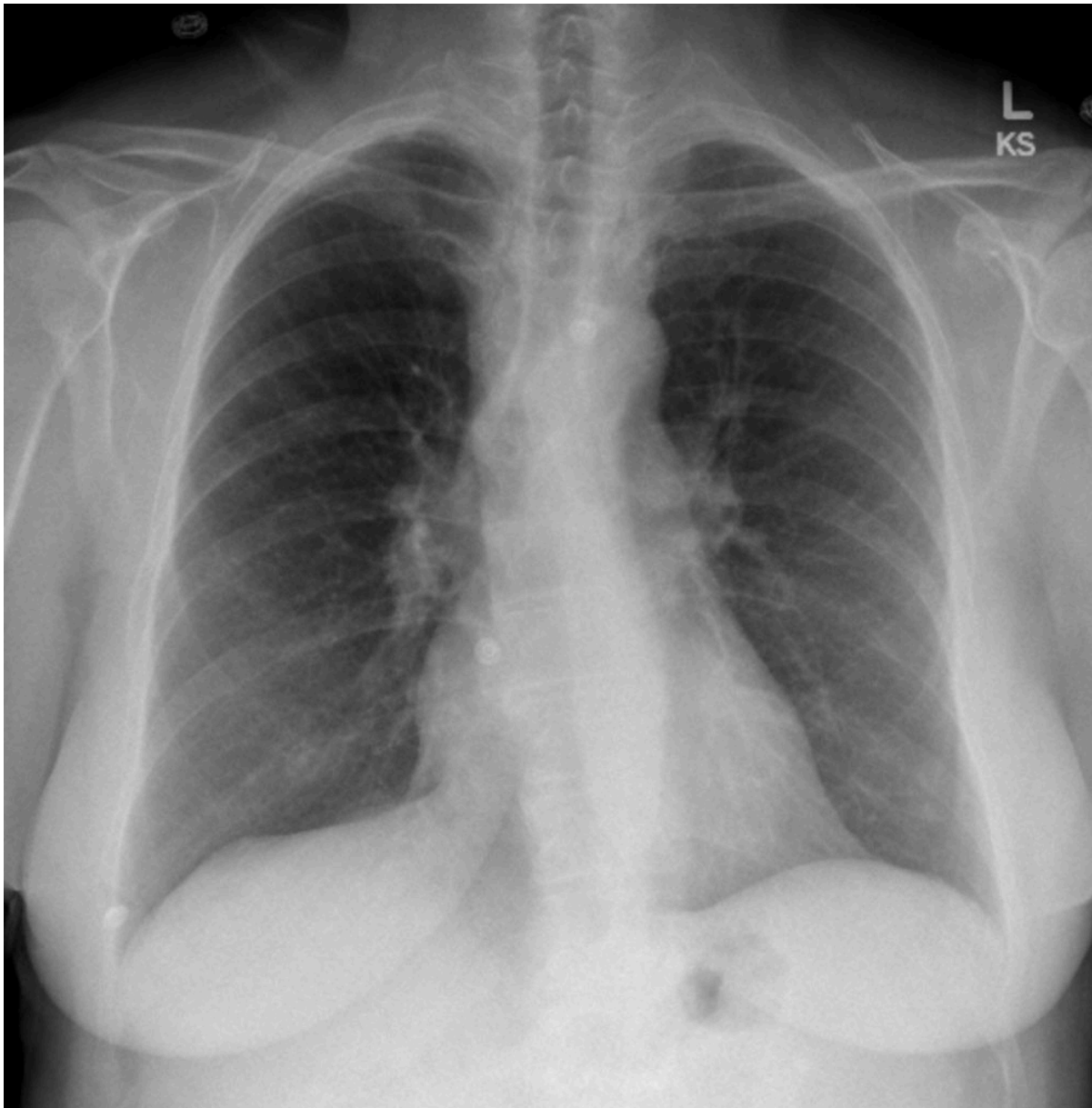


Figure 9.28 PA Chest x-ray, Pulmonary Embolism

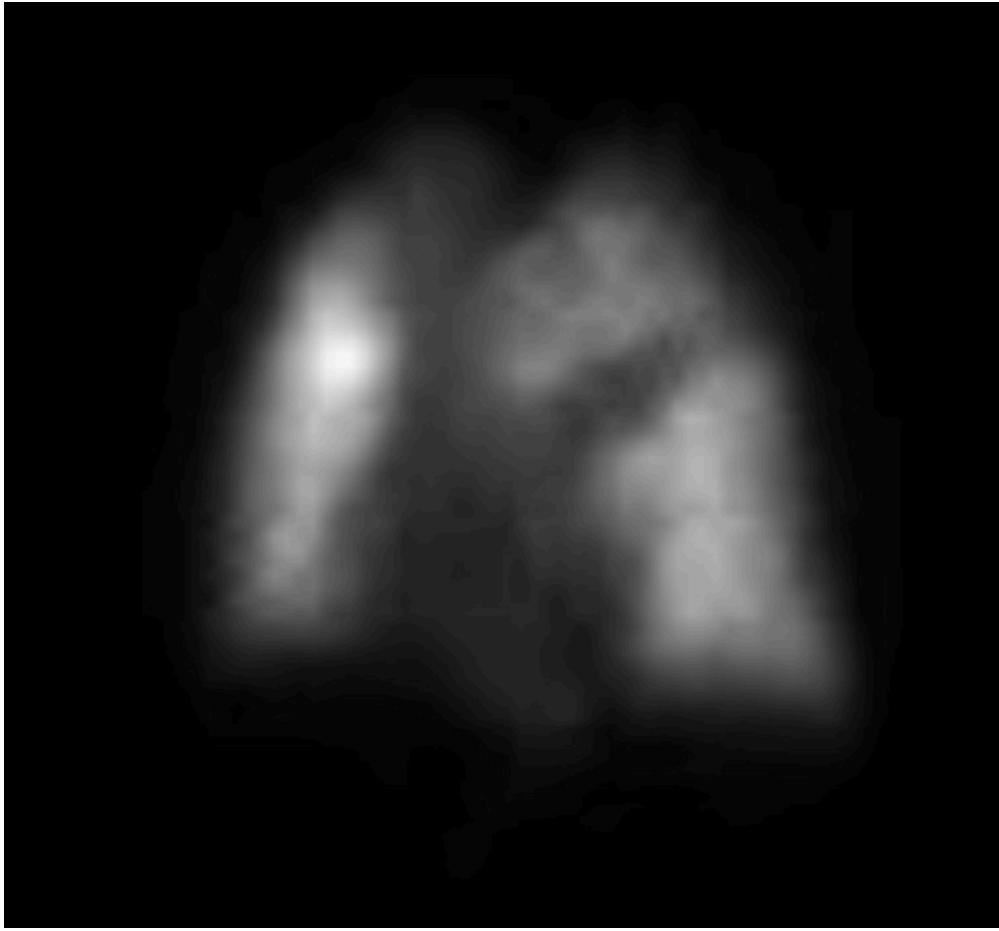


Figure 9.29 Nuclear Medicine Scan of Chest. Pulmonary Embolism

Chest CT, selected image

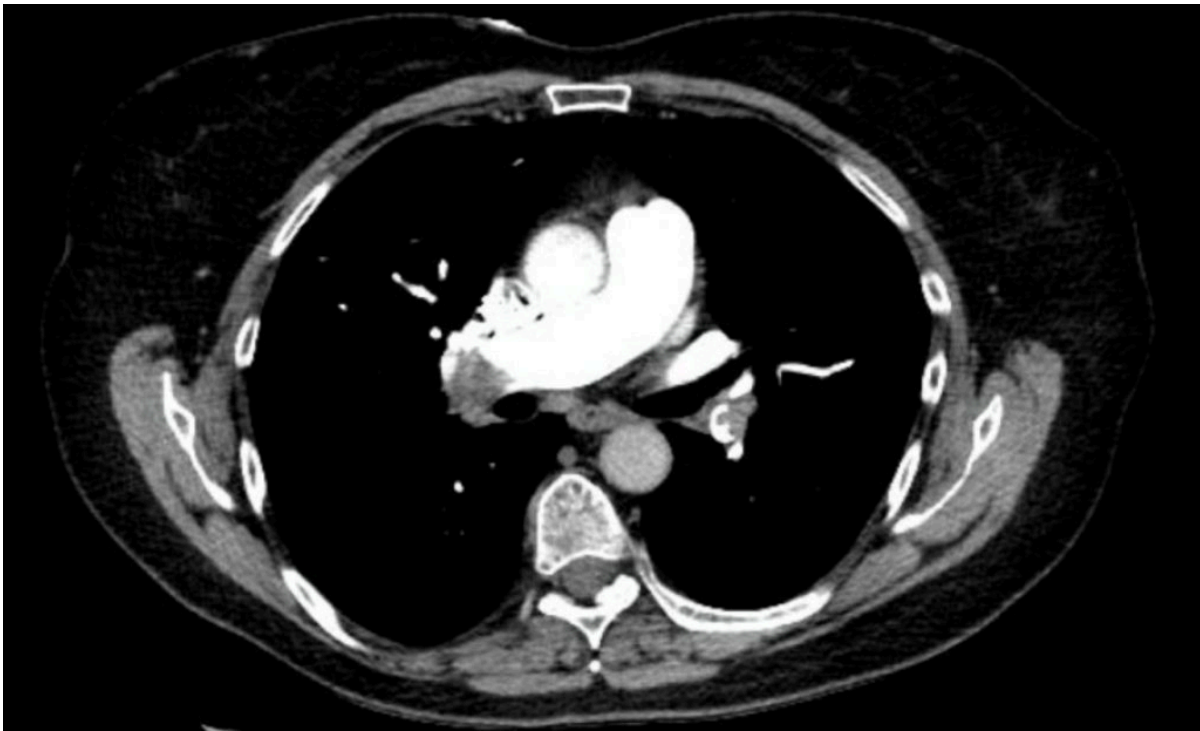


Figure 9.30 CT Scan of the Chest, Pulmonary Embolism

Imaging Assessment

Findings, X-rays:

The cardiac silhouette was not enlarged. There was significant peripheral vascular deficiency in the lungs.

Interpretation:

Due to the patient's signs and symptoms in a pregnant patient perfusion Nuclear Medicine imaging only was recommended.

Diagnosis:

Clinically High Suspicion for Pulmonary Thromboembolism.

Findings Nuclear Medicine:

There were areas of wedge-shaped lack of perfusion on the perfusion Nuclear Medicine scan. High probability of Pulmonary Embolism. Leg Doppler Ultrasound was recommended.

Doppler US Findings:

Negative bilateral leg Doppler Ultrasound. CT PE recommended.

Findings CT:

There was extensive central pulmonary thromboembolism in both lungs.

Pathology:

Venous thrombus, formed in the peripheral venous system, legs or pelvis, embolized to the pulmonary arterial circulation.

Attributions

Figure 9.26A PA Chest x-ray, Pulmonary Embolism by Dr. Brent Burbridge MD, FRCPC, University Medical Imaging Consultants, College of Medicine, University of Saskatchewan is used under a [CC-BY-NC-SA 4.0](#) license.

Figure 9.26B Lateral Chest x-ray, Pulmonary Embolism by Dr. Brent Burbridge MD, FRCPC, University Medical Imaging Consultants, College of Medicine, University of Saskatchewan is used under a [CC-BY-NC-SA 4.0](#) license.

Figure 9.27A PA Chest x-ray, Pulmonary Embolism by Dr. Brent Burbridge MD, FRCPC, University Medical Imaging Consultants, College of Medicine, University of Saskatchewan is used under a [CC-BY-NC-SA 4.0](#) license.

Figure 9.27B CT of the Chest, Pulmonary Embolism by Dr. Brent Burbridge MD, FRCPC, University Medical Imaging Consultants, College of Medicine, University of Saskatchewan is used under a [CC-BY-NC-SA 4.0](#) license.

Figure 9.28 PA Chest x-ray, Pulmonary Embolism by Dr. Brent Burbridge MD, FRCPC, University Medical Imaging Consultants, College of Medicine, University of Saskatchewan is used under a [CC-BY-NC-SA 4.0](#) license.

Figure 9.29 Nuclear Medicine Scan of Chest. Pulmonary Embolism by Dr. Brent Burbridge MD, FRCPC, University Medical Imaging Consultants, College of Medicine, University of Saskatchewan is used under a [CC-BY-NC-SA 4.0](#) license.

Figure 9.30 CT Scan of the Chest, Pulmonary Embolism by Dr. Brent Burbridge MD, FRCPC, University Medical Imaging Consultants, College of Medicine, University of Saskatchewan is used under a [CC-BY-NC-SA 4.0](#) license.

Chest – References

- 1) Line drawings – #FOAMed Medical Education Resources by Life in the Fast Lane (LITFL) is licensed under a Creative Commons Attribution-Non-Commercial-ShareAlike 4.0 International License. Available at <https://lifeinthefastlane.com/investigations/cxr-normal/> Accessed, June 30, 2017.
- 2) Jacobo Kirsch, MD; Tan-Lucien H. Mohammed, MD, et al. ACR Appropriateness Criteria®, Chest – Acute Respiratory Illness in Immunocompetent Patient. Available at <https://acsearch.acr.org/docs/69446/Narrative/> Accessed, June 30, 2017.
- 3) Debra Sue Dyer, MD; Tan-Lucien H. Mohammed, MD; Jacobo Kirsch, MD, et al. ACR Appropriateness Criteria®, Chest – Chronic Dyspnea – Suspected Pulmonary Origin. Available at <https://acsearch.acr.org/docs/69448/Narrative/> Accessed June 30, 2017.
- 4) [Learning radiology : recognizing the basics](#). William Herring author. Elsevier 2016 *Online access USask Library*. http://usl-primo.hosted.exlibrisgroup.com/primo_library/libweb/action/search.do?vid=USASK Accessed, June 30, 2017.
- 5) Jeffrey P. Kanne, MD, Leif E. Jensen, MD, MPH, Tan-Lucien H. Mohammed, MD, et al. ACR Appropriateness Criteria®, Chest – Radiographically Detected Solitary Pulmonary Nodule. Available at <https://acsearch.acr.org/docs/69455/Narrative/> Accessed June 30, 2017.
- 6) Fleischner Society – <https://fleischnersociety.org>
- 7) Michael A. Bettmann, MD, Scott G. Baginski, MD, Richard D. White, MD, et al. ACR Appropriateness Criteria®, Chest – Acute Chest Pain – Suspected Pulmonary Embolism. Available at <https://acsearch.acr.org/docs/69404/Narrative/> Accessed June 30, 2017.

Chapter 10 – Gastrointestinal and Abdominal

Cholecystitis

ACR – Gastrointestinal – Right Upper Quadrant Pain

Case
Cholecystitis

Clinical:

History – This 45 year old female presented to the emergency room with moderate to severe right upper quadrant pain. She had noted vague pain in the right upper quadrant when eating for the last 4 months.

Symptoms – The patient relates that she had moderate, persistent, right upper quadrant pain.

Physical – The liver was difficult to palpate due to the patient’s large size (Body Mass Index – 30). The patient was tender in the right upper quadrant and there was a positive Murphy’s sign. She had a fever of 40C. There was guarding on palpation in the right upper abdomen.

Laboratory – The serum liver enzymes and bilirubin were normal. Her white blood cell count was elevated.

DDx:

Cholecystitis

Choledocholithiasis

Liver abscess

Diverticulitis

Colitis

Imaging Recommendation

[ACR – Gastrointestinal – Right Upper Quadrant Pain – Suspected Cholecystitis, Variant 1](#)

Ultrasound Abdomen

ODIN Link for Gallbladder Ultrasound images, Figure 10.1A and B: <https://mistr.usask.ca/odin/?caseID=20170126223613024>

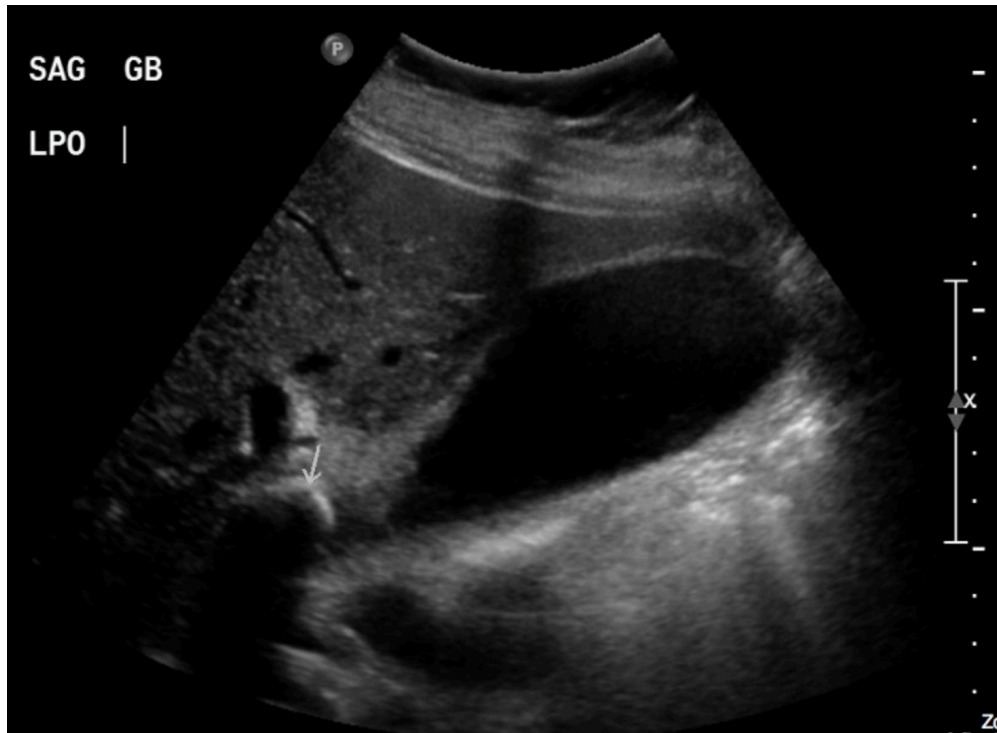

Figure 10.1A Sagittal ultrasound of the Gallbladder

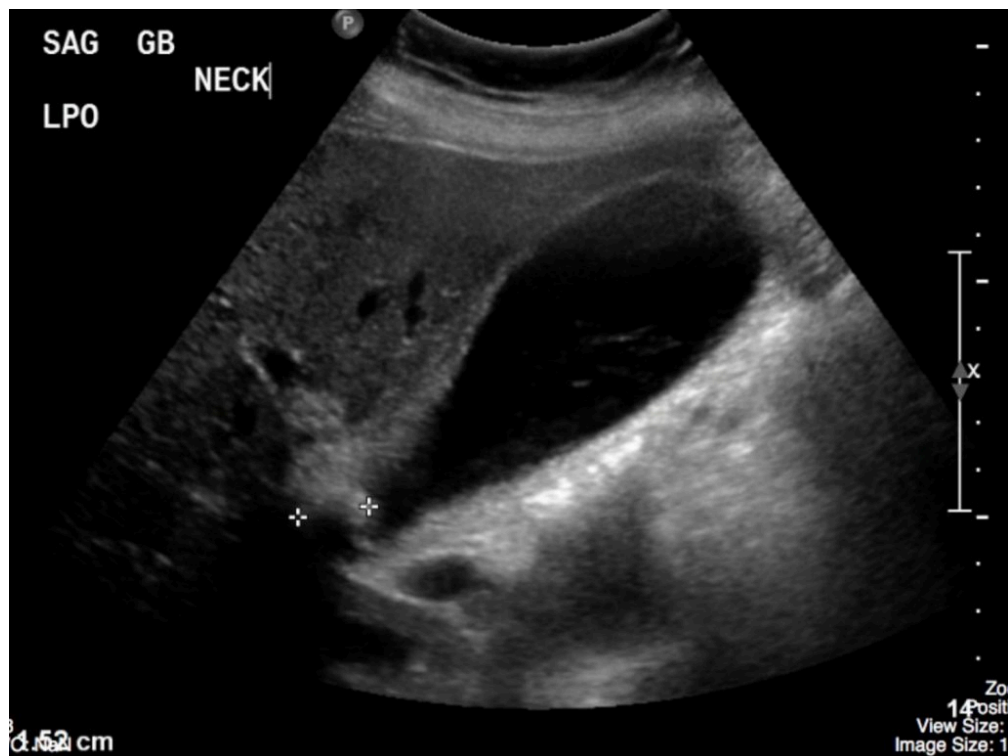


Figure 10.1B Sagittal Ultrasound of the Gallbladder Neck and Calculus

Imaging Assessment

Findings:

The gallbladder was distended. The gallbladder was very tender on ultrasound probe pressure (Sonographic Murphy's Sign). There was a large gallstone seen in the neck of the gallbladder. The gallbladder wall was mildly thickened and there was a small amount of fluid adjacent to the gallbladder.

Interpretation:

The findings were in keeping with Cholelithiasis and Cholecystitis.

Diagnosis:

Cholelithiasis and Cholecystitis

Discussion:

- Cholelithiasis is estimated to affect more than 20 million Americans. This does not lead to cholecystitis in a large number of individuals. In almost all cases, acute cholecystitis starts with a gallstone impacted in the neck of the gallbladder or cystic duct. The presence of gallstones does not, by itself, mean that the patient's pain is emanating from the gallbladder, because asymptomatic gallstones are common. Cholecystitis may occur, less commonly, in the absence of stones (acalculous cholecystitis).

X-ray findings may include:

- No abnormalities
- Visible, calculi, may be multiple and faceted but only 15% of biliary calculi have enough calcium within them to be visible on x-rays.
- Gas may be seen in the biliary tree if there has been recent passage of a bile duct stone.

Ultrasound findings may include:

- Gallstones are characteristically echogenic and produce acoustical shadowing because they reflect most of the signal back to the transducer.
- Acoustic shadowing describes a band of reduced echoes behind an echo-dense object (e.g., a gallstone) that reflects most of the sound waves. This finding can have diagnostic value in identifying a calculus, such as in the gallbladder and kidney.
- Gallstones usually fall to the dependent part of the gallbladder, based upon the patient's position at the time of the scan. Gallbladder calculi will move when the patient is re-positioned. This helps to differentiate gallstones from polyps or tumors.
- Biliary sludge can be found in the lumen of the gallbladder and is an aggregation that may contain cholesterol crystals, bilirubin, and glycoproteins. It is often associated with biliary stasis. Although it may be echogenic, sludge does not produce acoustical shadowing as gallstones do.

Recognizing Acute Cholecystitis on US:

- The presence of gallstones, possibly impacted in the neck of the gallbladder or in the cystic duct.
- Thickening of the gallbladder wall (>3 mm)
- Pericholecystic fluid (fluid around the gallbladder)
- A positive sonographic Murphy sign (Pain that is elicited by compression of the gallbladder with the US probe).
- In the presence of gallstones and gallbladder wall thickening, US has a positive predictive value for acute cholecystitis as high as 94%.

Attributions

Figure 10.1A Sagittal ultrasound of the Gallbladder by Dr. Brent Burbridge MD, FRCPC, University Medical

Imaging Consultants, College of Medicine, University of Saskatchewan is used under a [CC-BY-NC-SA 4.0](#) license.

Figure 10.1B Sagittal Ultrasound of the Gallbladder Neck and Calculus by Dr. Brent Burbridge MD, FRCPC, University Medical Imaging Consultants, College of Medicine, University of Saskatchewan is used under a [CC-BY-NC-SA 4.0](#) license.

Intestinal Perforation- Pneumoperitoneum

Case 1

Pneumoperitoneum

Clinical:

History – This patient was stabbed in the abdomen outside the neighbourhood bar.

Symptoms – Pain associated with a knife wound in the left lower abdomen.

Physical – A single linear, puncture wound was seen in the left lower abdomen. No active bleeding. Hemodynamically stable. No other findings.

DDx:

Abdominal Wall Laceration

Perforated Viscus

Solid Organ Laceration

Imaging Recommendation

Trauma Imaging

Chest x-ray

Abdominal x-ray

ODIN Link for Chest and Supine Abdomen images, Figure 10.2A and B: <https://mistr.usask.ca/odin/?caseID=20170119170923860>

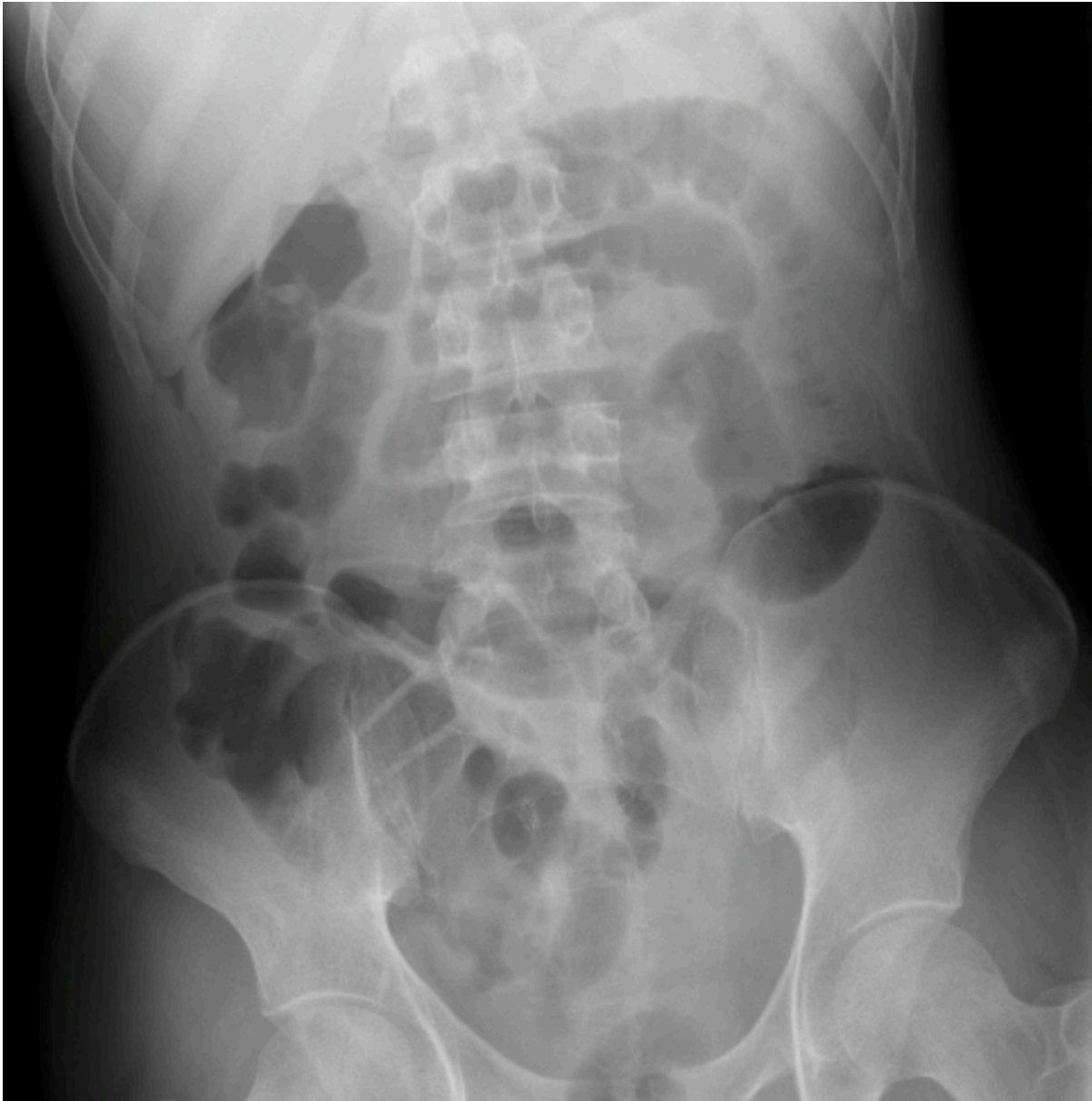

Figure 10.2A Abdominal x-ray displaying possible perforated viscus, Rigler's sign in right upper quadrant.

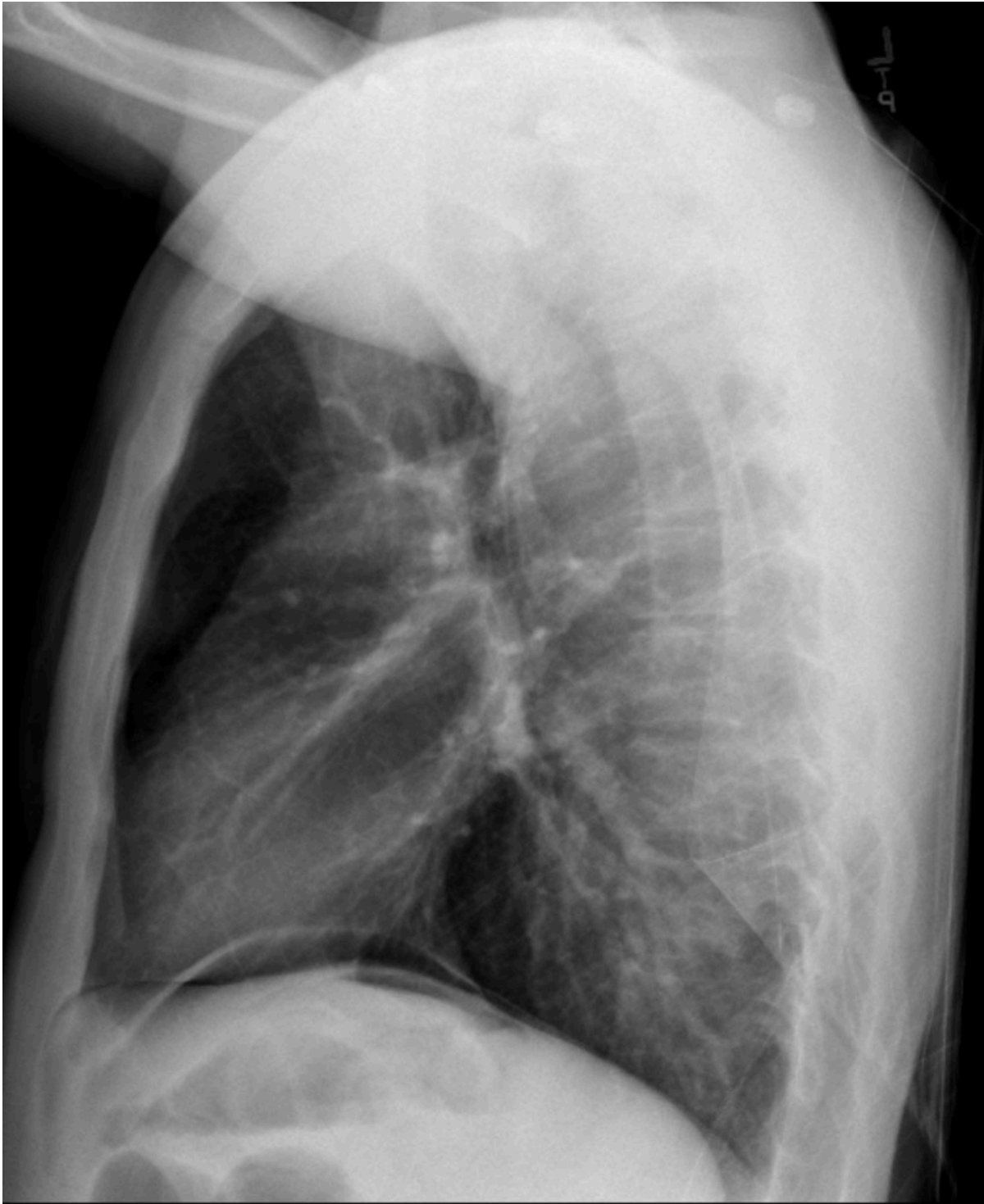


Figure 10.2B Lateral chest x-ray displaying sub-diaphragmatic free gas.

Imaging Assessment

Findings:

Abdominal x-ray – There was a positive Rigler sign in in the right upper quadrant. No other findings.

Chest x-ray – Pneumoperitoneum was seen beneath the hemidiaphragms.

Interpretation:

Probable perforated hollow viscus.

Diagnosis:

Pneumoperitoneum. Perforated hollow viscus.

Discussion:

Causes for pneumoperitoneum:

- Perforated hollow viscus
- Recent surgery
- Recent drainage procedure – needle aspiration or drainage tube insertion
- Gas forming organism in peritoneal fluid
- Vaginal route
- Inflammatory bowel disease
- Pneumothorax
- Mechanical ventilation
- Peritoneal dialysis

X-ray findings may include:

There are three major signs of free intraperitoneal gas, arranged below in the order in which they are most commonly seen:

- Air beneath the diaphragm
- Visualization of both sides of the bowel wall (Rigler Sign)
- Visualization of the falciform ligament

Air Beneath the Diaphragm

- Gas will rise to the highest part of the abdomen.
- In the upright position, free gas will usually reveal itself under the diaphragm as a crescentic lucency that parallels the under surface of the diaphragm.
- The size of the crescent will be roughly proportional to the amount of free gas.

Visualization of both sides of the bowel wall

- On the normal abdominal radiograph, we visualize air only inside the lumen of the bowel, not outside the bowel wall. This is because the bowel wall is soft tissue density and is surrounded by tissue of the same density.
- The introduction of gas into the peritoneal cavity enables us to visualize the wall of the bowel itself since the wall is now surrounded on both inside and outside by gas (Rigler sign).

Visualization of the falciform ligament

- The falciform ligament courses over the free edge of the liver anteriorly. It contains a remnant of the obliterated umbilical artery. It is normally invisible, composed of soft tissue and surrounded by tissue of similar density.
- When free gas is present and the patient is in the supine position, the free gas may rise over the anterior surface of the liver, surround the falciform ligament, and render it visible.

Case 2

Large Pneumoperitoneum**Clinical:**

History – This patient was just discharged two days previously after laparoscopic appendectomy.

Symptoms – Generalized abdominal pain and bloating.

Physical – The patient’s abdomen was distended and tympanitic. He had mild peritoneal irritation. He was hemodynamically stable. He had a mild fever of 38.5C. No other findings.

DDx:

Post-operative adynamic ileus

Perforated Viscus

Dehiscence of the appendectomy stump

Bowel obstruction

Imaging Recommendation

Chest x-ray

Abdominal x-ray

ODIN Link for Massive Pneumoperitoneum images (Chest x-ray and 3 Views of the Abdomen), Figure 10.3A and B: <https://mistr.usask.ca/odin/?caseID=20110921160717536>

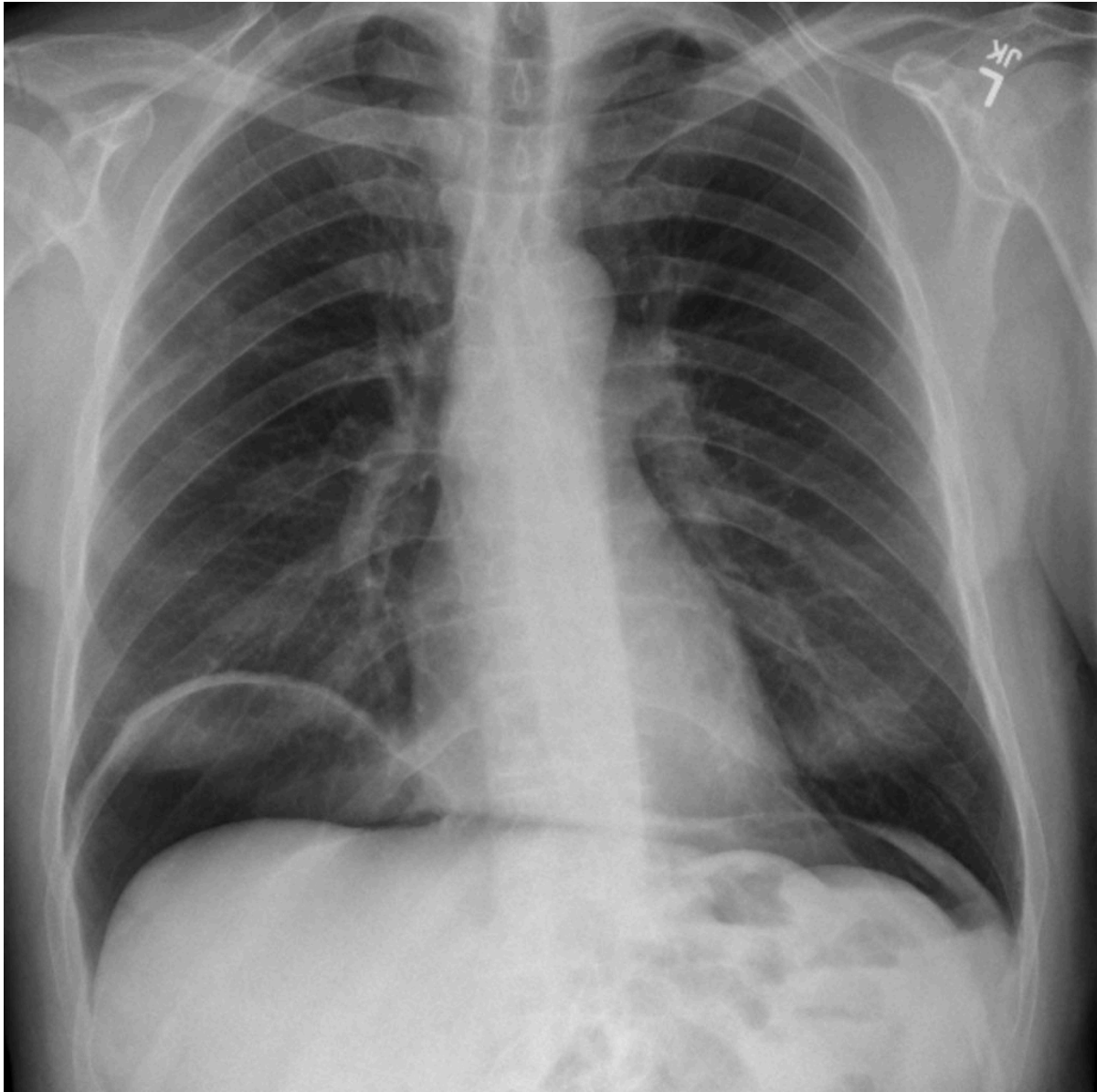


Figure 10.3A Chest x-ray displaying massive pneumoperitoneum

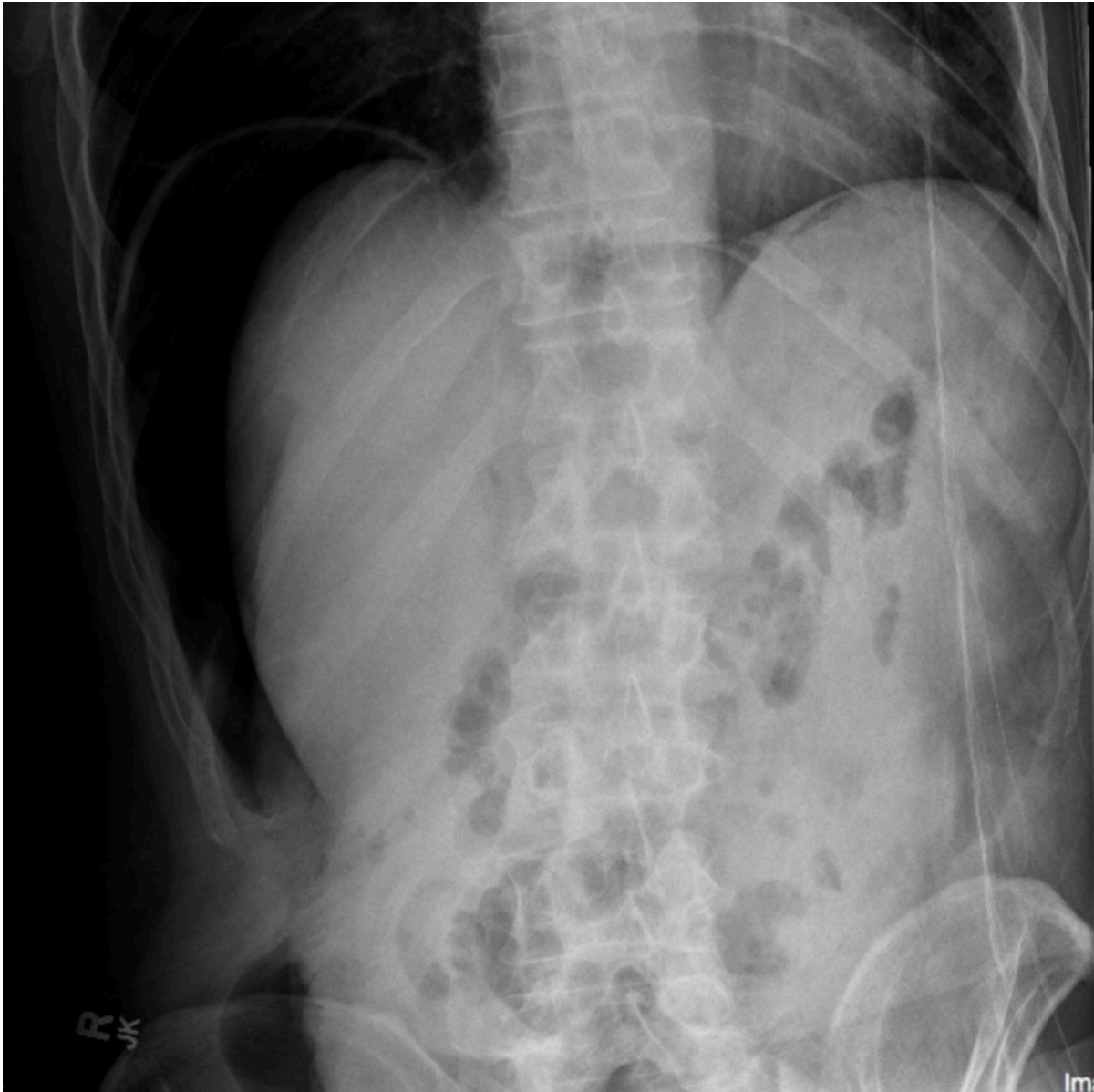

Figure 10.3B Decubitus Abdominal x-ray displaying massive pneumoperitoneum

Imaging Assessment

Findings:

Chest x-ray – Pneumoperitoneum was seen beneath the hemidiaphragms.

Abdominal x-ray – Massived pneumoperitoneum was seen. No evidence of bowel obstruction or ileus. No evidence of post-operative abscess. No other findings.

Interpretation:

Probable dehiscence of the appendectomy stump.

Diagnosis:

Pneumoperitoneum, dehiscence of appendectomy closure.

Attributions

Figure 10.2A Abdominal x-ray displaying possible perforated viscus, Rigler’s sign in right upper quadrant by Dr. Brent Burbridge MD, FRCPC, University Medical Imaging Consultants, College of Medicine, University of Saskatchewan is used under a [CC-BY-NC-SA 4.0](#) license.

Figure 10.2B Lateral chest x-ray displaying possible perforated viscus, sub-diaphragmatic free gas by Dr. Brent Burbridge MD, FRCPC, University Medical Imaging Consultants, College of Medicine, University of Saskatchewan is used under a [CC-BY-NC-SA 4.0](#) license.

Figure 10.3A Chest x-ray displaying massive pneumoperitoneum by Dr. Brent Burbridge MD, FRCPC, University Medical Imaging Consultants, College of Medicine, University of Saskatchewan is used under a [CC-BY-NC-SA 4.0](#) license.

Figure 10.3B Decubitus Abdominal x-ray displaying massive pneumoperitoneum by Dr. Brent Burbridge MD, FRCPC, University Medical Imaging Consultants, College of Medicine, University of Saskatchewan is used under a [CC-BY-NC-SA 4.0](#) license.

Ileus

ACR – Gastrointestinal – Acute (non-localized) Abdominal Pain and Fever

Case 1

Adynamic, Generalized Ileus

Clinical:

History – This patient had surgery 2 days prior to these images for a ruptured appendix.

Symptoms – Vague abdominal pain, low-grade fever (37.9C), Not passing flatus or stool for 2 days.

Physical – The abdomen was mildly distended. The laparoscopic access sites were normal. There was a paucity of bowel gas sounds. No focal tenderness, guarding or rebound.

DDx:

Ileus

Small bowel obstruction

Abscess

Large bowel obstruction

Imaging Recommendation

[ACR – Gastrointestinal – Acute \(non-localized\) Abdominal Pain and Fever, Variant 1](#)

Three views of the abdomen – supine, upright, and right side up decubitus view.

CT Abdomen

ODIN Link for Adynamic Ileus images (3 Views of the Abdomen), Figure 10.4A and B:
<https://mistr.usask.ca/odin/?caseID=20160412201915071>

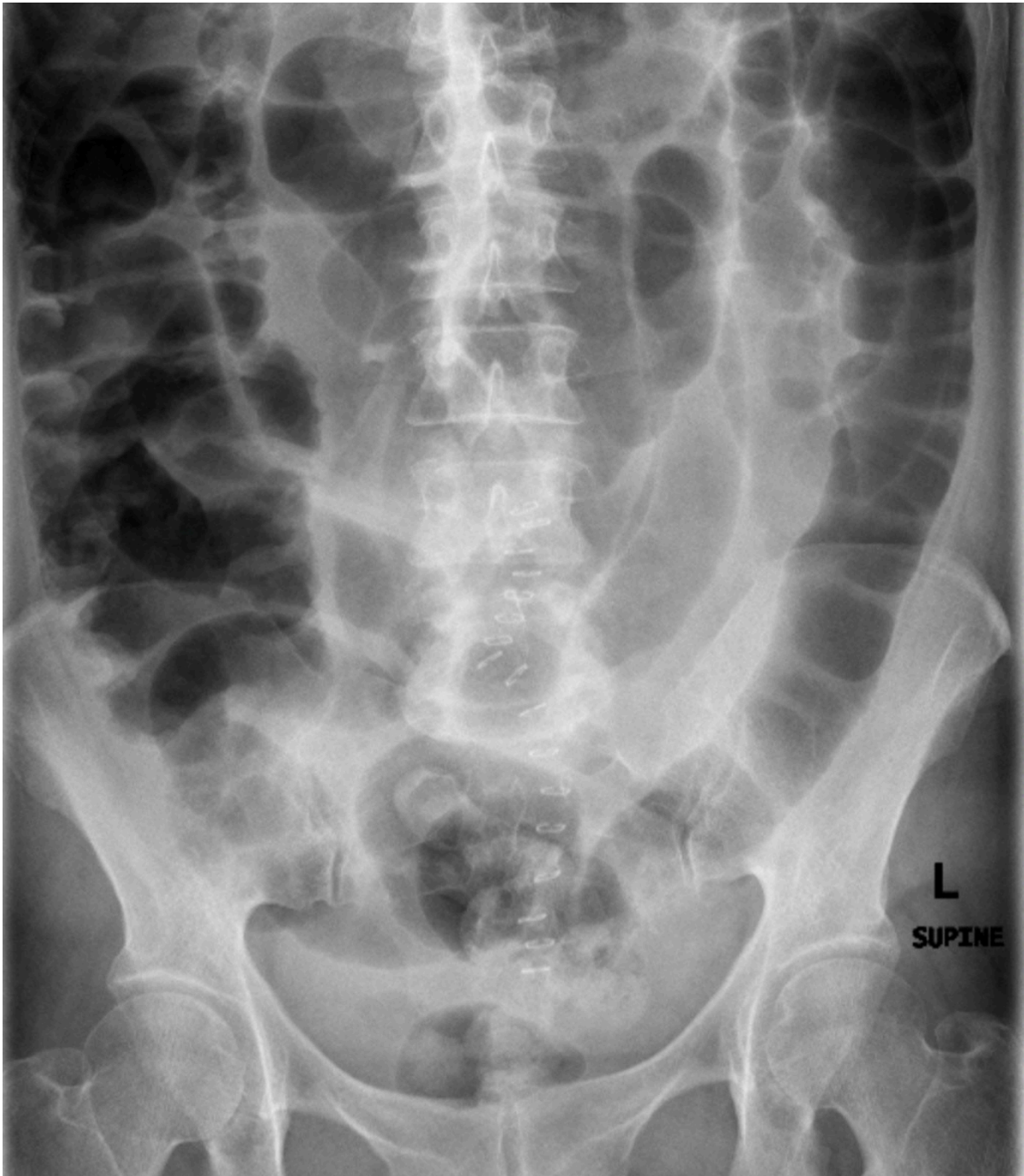

Figure 10.4A Abdominal x-ray, supine, revealing mild, generalized bowel dilation, generalized ileus.

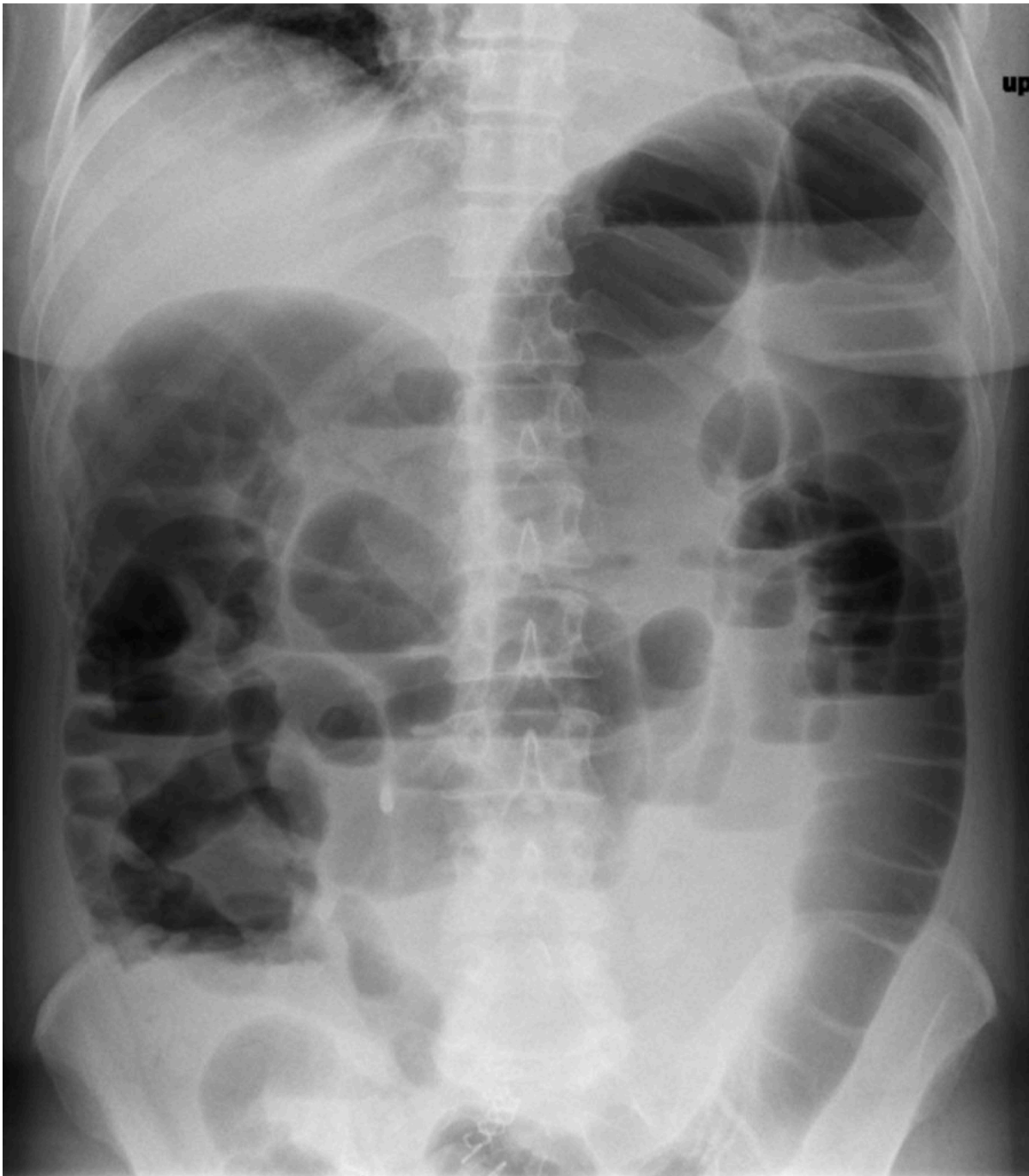


Figure 10.4B Abdominal x-ray, upright, revealing mild, generalized bowel dilation, generalized ileus.

Imaging Assessment

Findings:

No free intraperitoneal gas. No extra-intestinal gas pattern to suggest an abscess. There was atelectasis in the left lower lung. The bowel, small and large, was diffusely, mildly, dilated. There were several small bowel air-fluid levels. No other findings.

Interpretation:

Left lower lobe atelectasis. Adynamic ileus.

Diagnosis:

Adynamic, Generalized Ileus

Discussion:

Ileus can be Generalized or Localized.

Dilated small bowel is wider than 3 cm in diameter. Small bowel dilation related to an ileus usually does not dilate as greatly as that seen in mechanical bowel obstruction.

Generalized – Adynamic Ileus

Seen in the setting of post-operative abdomen/pelvis and Diabetic Ketoacidosis

The entire bowel is aperistaltic or hypoperistaltic. Swallowed air dilates, and fluid fills most loops of both small and large bowel.

A generalized adynamic ileus is almost always the result of abdominal or pelvic surgery, in which the bowel is manipulated during the surgery.

Localized Ileus

Localized relates to something in the abdomen that has the capacity to affect a segment of bowel and result in hypoperistalsis and dilation of a localized region of intestine. This is most often seen associated with an adjacent pathology i.e. pancreatitis, inflammatory bowel disease, contained perforation (abscess), diverticulitis, or appendicitis.

X-ray findings may include:

- One, or two, persistently dilated segments of bowel (usually small bowel). Persistently means that these segments remain dilated on multiple views of the abdomen (supine, prone, upright abdomen) or on serial studies done over the course of time.
- Infrequently, the sentinel segment may be large bowel, rather than small bowel. This can especially occur in the cecum, with diseases such as appendicitis.
- Air–fluid levels may be seen in sentinel segment.
- There may be gas in the rectum or sigmoid colon.

Case 2

Localized Ileus/Sentinel segment**Clinical:**

History – This patient had a history of Crohn’s disease. She was not currently on any medications for this condition. She was experiencing increasing abdominal pain and bloody diarrhea.

Symptoms – Moderate abdominal pain, localized to the right lower quadrant, low-grade fever (37.9C).

Physical – The abdomen was mildly distended. There was a paucity of bowel gas sounds. Focal tenderness was elicited in the right lower quadrant.

DDx:

Ileus

Small bowel obstruction

Abscess

Large bowel obstruction

Imaging Recommendation

[ACR – Gastrointestinal – Acute \(non-localized\) Abdominal Pain and Fever, Variant 1](#)

Three views of the abdomen – supine, upright, and right side up decubitus view.

CT Abdomen

ODIN Link for Localized Ileus images (3 Views of the Abdomen), Figure 10.5A and B:
<https://mistr.usask.ca/odin/?caseID=20170410095031868>

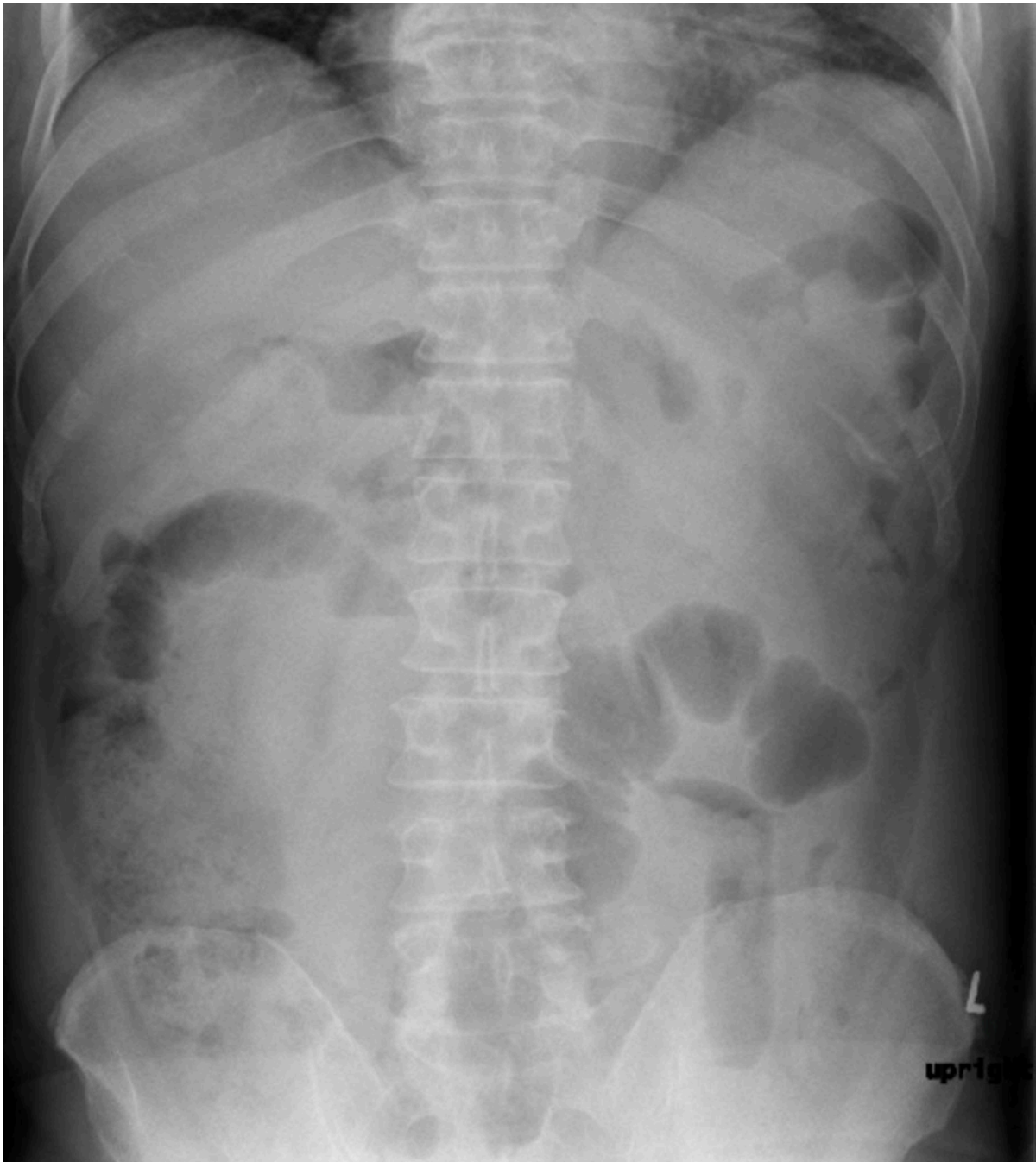


Figure 10.5A Abdominal x-ray, supine, suspicious for localized ileus in right upper quadrant

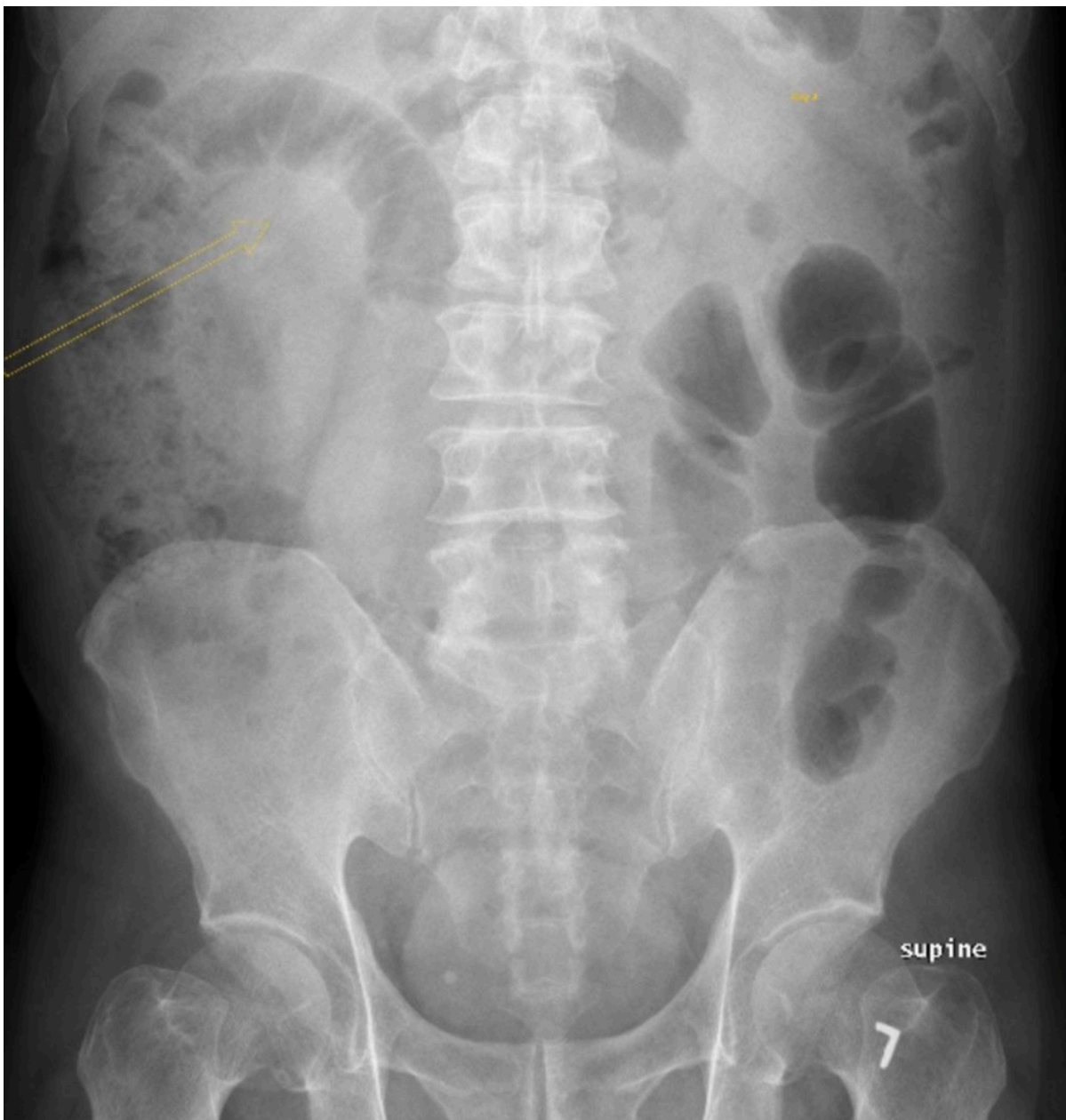


Figure 10.5B Abdominal x-ray, upright, suspicious for localized ileus

Imaging Assessment

Findings:

No free intraperitoneal gas. No extra-intestinal gas pattern to suggest an abscess. There was a localized, persistently dilated, segment of small bowel in the right mid to lower abdomen. This was seen on the supine and upright views, unchanged in the interval between the two images. There was no evidence of air/fluid levels or dilated bowel elsewhere. No other findings.

Interpretation:

Localized, right abdominal, ileus.

Diagnosis:

Localized Ileus. Active Crohn's disease effecting the terminal ileum.

Attributions

Figure 10.4A Abdominal x-ray, supine, revealing mild, generalized bowel dilation, generalized ileus by Dr. Brent Burbridge MD, FRCPC, University Medical Imaging Consultants, College of Medicine, University of Saskatchewan is used under a [CC-BY-NC-SA 4.0](#) license.

Figure 10.4B Abdominal x-ray, upright, revealing mild, generalized bowel dilation, generalized ileus by Dr. Brent Burbridge MD, FRCPC, University Medical Imaging Consultants, College of Medicine, University of Saskatchewan is used under a [CC-BY-NC-SA 4.0](#) license.

Figure 10.5A Abdominal x-ray, supine, suspicious for localized ileus in right upper quadrant by Dr. Brent Burbridge MD, FRCPC, University Medical Imaging Consultants, College of Medicine, University of Saskatchewan is used under a [CC-BY-NC-SA 4.0](#) license.

Figure 10.5B Abdominal x-ray, upright, suspicious for localized ileus by Dr. Brent Burbridge MD, FRCPC, University Medical Imaging Consultants, College of Medicine, University of Saskatchewan is used under a [CC-BY-NC-SA 4.0](#) license.

Intestinal Obstruction

ACR – Gastrointestinal – Suspected Small Bowel Obstruction

Case 1

Adhesions

Clinical:

History – This patient has had numerous ventriculo-peritoneal shunts. He has had many abdominal surgeries for revisions of the shunt tubing. No other significant history.

Symptoms – Abdominal pain and bloating. Diminished appetite. No flatus or bowel movements for 24 hours. Vomiting watery green fluid for 12 hours.

Physical – The abdomen was distended and mildly, diffusely tender. The bowel sounds were infrequent and high-pitched. The abdomen was tympanitic. No rebound or guarding. Scars were seen from his previous surgeries.

DDx:

Suspected Small Bowel Obstruction

Imaging Recommendation

[ACR–Gastrointestinal – Suspected Small Bowel Obstruction, Variant 1](#)

Three views of the Abdomen

CT of the Abdomen

ODIN Link for Small Bowel Obstruction images (3 Views of the Abdomen), Figure 10.6A and B:

<https://mistr.usask.ca/odin/?caseID=20170410113920578>

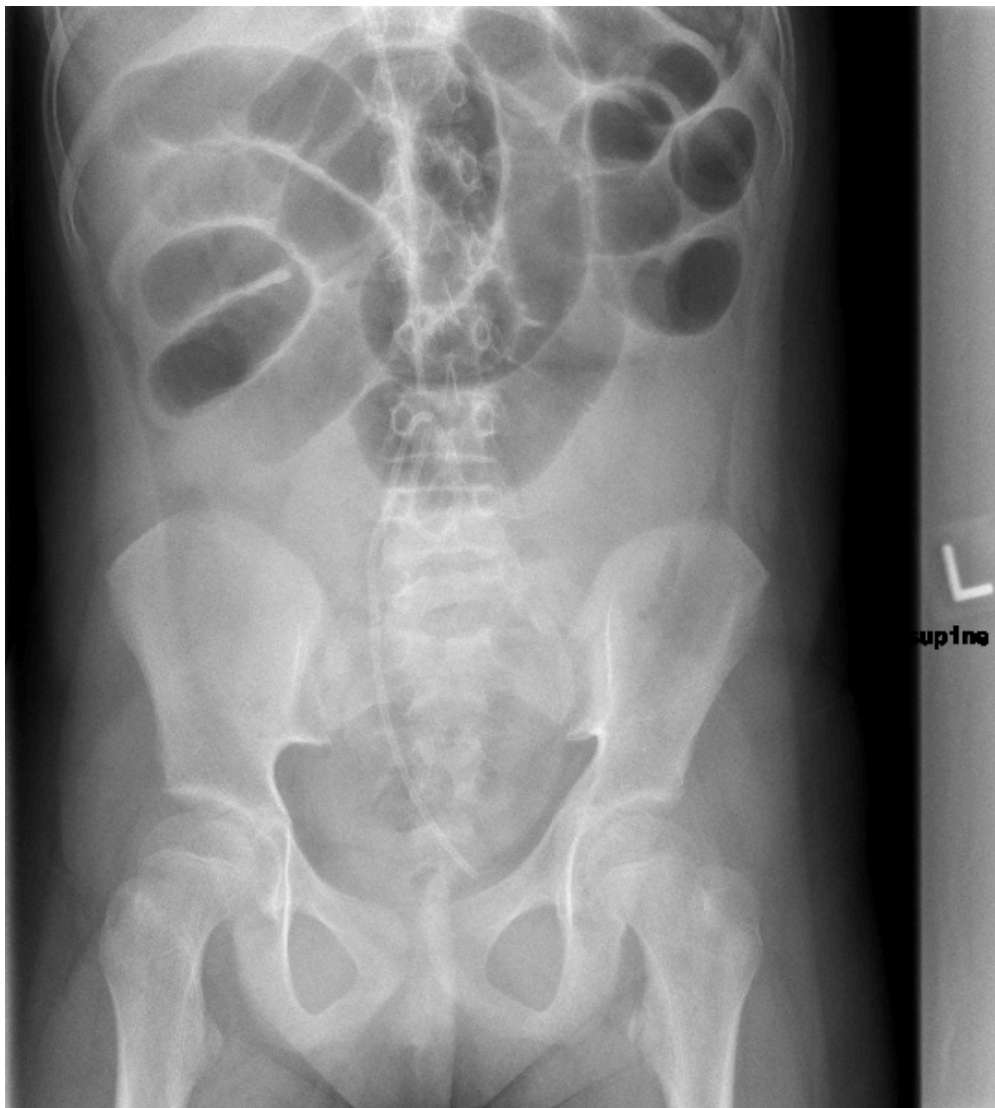

Figure 10.6A Abdominal x-ray, supine, suspicious for SBO

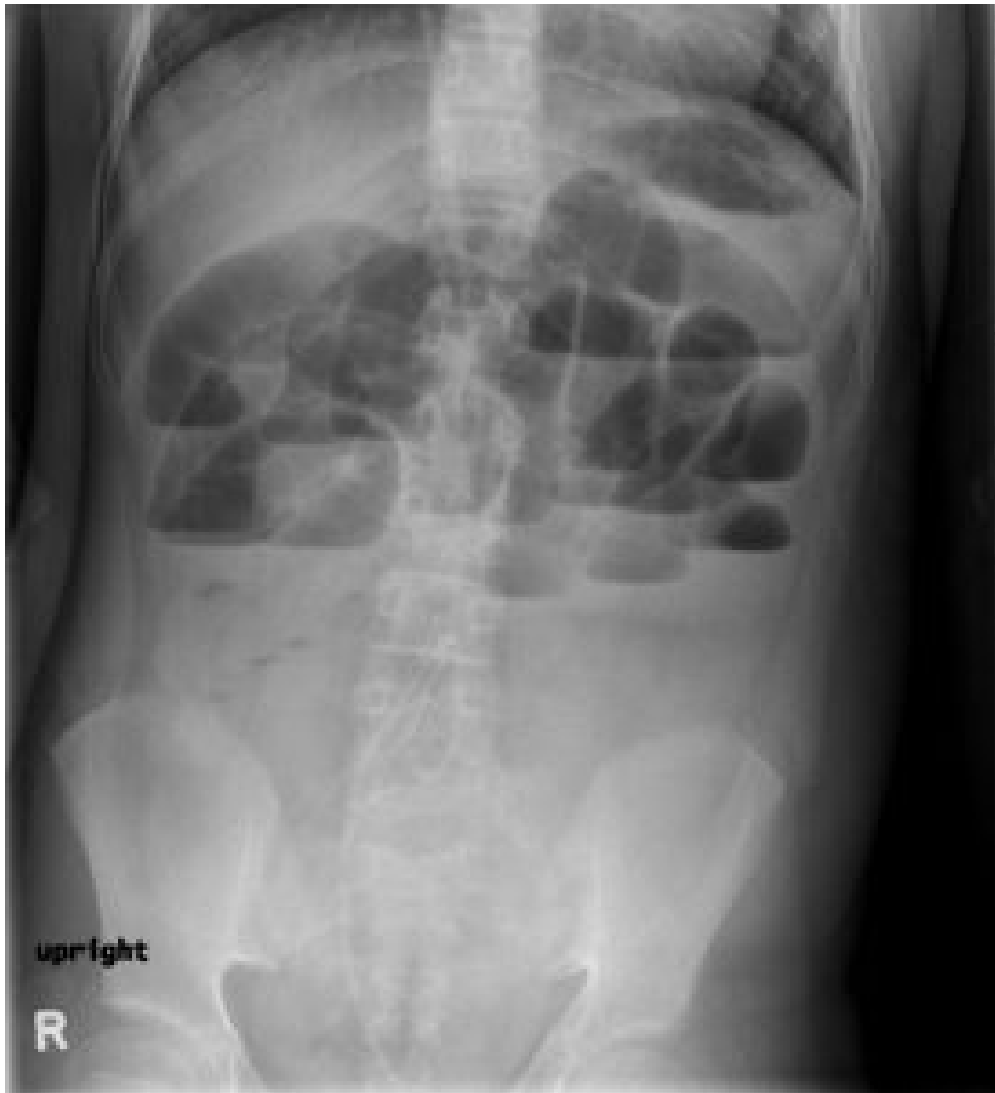

Figure 10.6B Abdominal x-ray, upright, suspicious for SBO

Imaging Assessment

Findings:

There was a paucity of bowel gas in the colon. The small bowel was dilated and there were multiple air-fluid levels (> 3 in number) in the small intestine. No calculi seen. The ventriculo-peritoneal shunt tubing was noted.

Interpretation:

Suspicious for high-grade, or complete, small bowel obstruction.

Diagnosis:

Adhesions, small bowel obstruction from restrictive band.

Discussion:

An abnormality in the small bowel lumen, the small bowel wall, or an abnormality extrinsic to the small bowel can cause a blockage of the lumen. This prevents antegrade passage of gas and fluid. Initially, the small bowel increases peristaltic effort to move the contents forward (hyperperistalsis, high-pitched bowel sounds), then later the peristalsis ceases.

The hyperperistalsis clears the bowel downstream of the obstruction resulting in a relatively clear distal bowel (sigmoid colon, rectum).

Causes of small bowel obstruction include:

- Adhesions after previous abdominal or pelvic surgery
- Inflammatory bowel disease
- Hernias
- Gallstones
- Malignancy
- Ingested foreign body
- Intussusception – more common in children

X-ray findings may include:

- Dilated bowel – small bowel > 2.5 – 3 cm, cecum > 10 cm, transverse colon > 6 cm, sigmoid colon > 4cm
- Gas and fluid in the bowel.
- Air-fluid levels in small bowel > 3 in number
- Less gas and fluid in the bowel downstream of obstruction.

Case 2

Ventral Abdominal Hernia

Clinical:

History – This patient had a previous laparotomy for a perforated diverticulum 10 years ago. A noticeable hernia was present in the ventral abdomen and it was noted to have enlarged over the last two years.

Symptoms – Abdominal pain and bloating. Diminished appetite. No flatus or bowel movements for 48 hours. Vomiting watery green fluid for 24 hours.

Physical – The abdomen was distended and mildly, diffusely tender. The bowel sounds were infrequent and high-pitched. The abdomen was tympanitic. A large, firm, mass was noted in the ventral abdominal wall. It was not particularly tender to palpation. No rebound or guarding.

DDx:

Suspected Small Bowel Obstruction

Ileus

Bowel Perforation

Imaging Recommendation

[ACR–Gastrointestinal – Suspected Small Bowel Obstruction, Variant 1](#)

Three views of the Abdomen

CT of the Abdomen

ODIN Link to Abdominal Wall Mass with Small Bowel Obstruction images (Ultrasound, 2 Views of the Abdomen, and CT), Figure 10.7A and B: <https://mistr.usask.ca/odin/?caseID=20170410112613962>

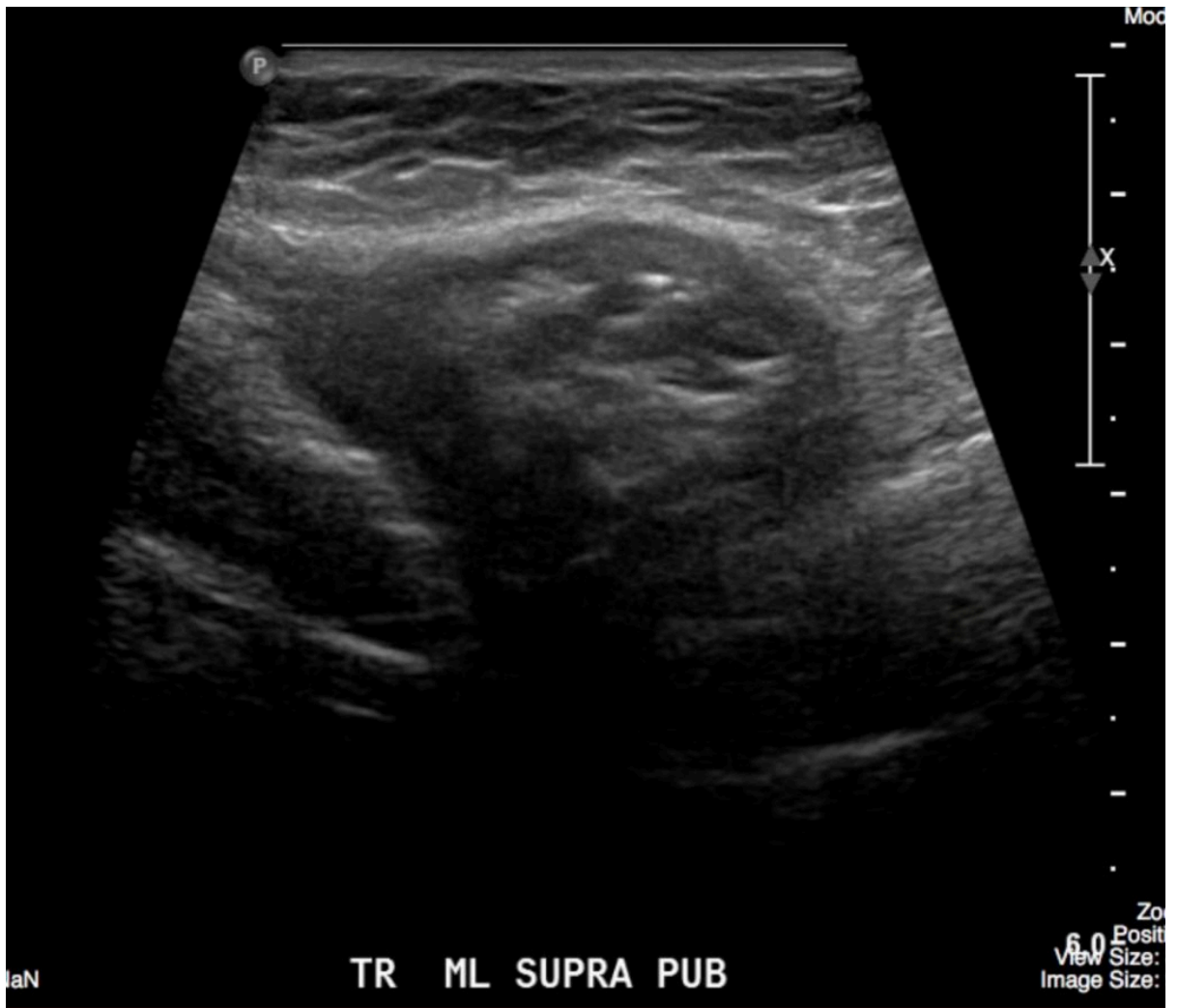

Figure 10.7A Ultrasound of Abdomen displaying a mass in the abdominal wall fat

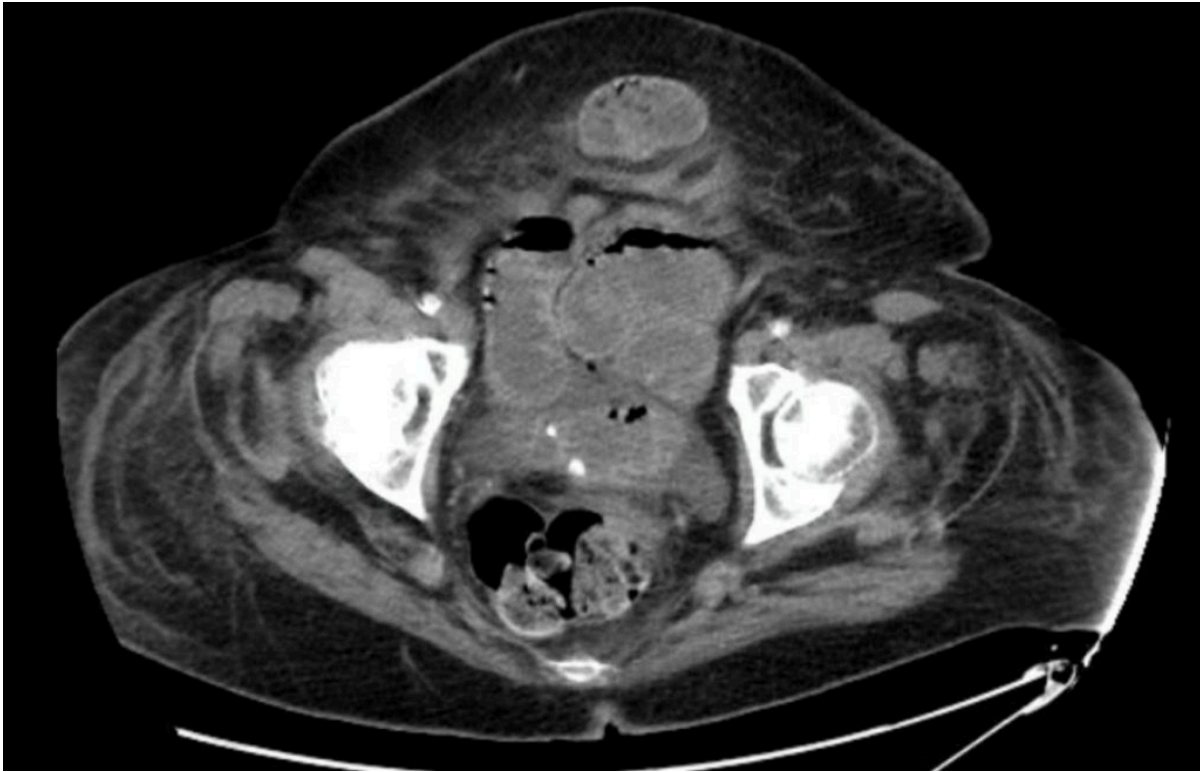

Figure 10.7B CT Scan of the Abdomen displaying a mass in the abdominal wall and very dilated small intestine

Imaging Assessment

Findings:

Ultrasound – A mixed echogenicity mass is seen in the lower mid abdomen. There is suspicion for a fat containing intestine within the hernia sac. No calculi seen.

CT – There was a soft tissue mass in the lower, ventral, abdominal wall, subcutaneous fat. This has the appearance of a hernia. There was intestine in the hernia sac. The visualized small intestine was dilated, consistent with a small bowel obstruction.

Interpretation:

Moderate grade small bowel obstruction.

Diagnosis:

The patient had a ventral, bowel containing hernia, with small bowel obstruction secondary to entrapment of the bowel in the hernia sac (incarceration).

Attributions

Figure 10.6A Abdominal x-ray, supine, suspicious for SBO by Dr. Brent Burbridge MD, FRCPC, University Med-

ical Imaging Consultants, College of Medicine, University of Saskatchewan is used under a [CC-BY-NC-SA 4.0](#) license.

Figure 10.6B Abdominal x-ray, decubitus, suspicious for SBO by Dr. Brent Burbridge MD, FRCPC, University Medical Imaging Consultants, College of Medicine, University of Saskatchewan is used under a [CC-BY-NC-SA 4.0](#) license.

Figure 10.7A Ultrasound of Abdomen displaying a mass in the abdominal wall fat by Dr. Brent Burbridge MD, FRCPC, University Medical Imaging Consultants, College of Medicine, University of Saskatchewan is used under a [CC-BY-NC-SA 4.0](#) license.

Figure 10.7B CT Scan of the Abdomen displaying a mass in the abdominal wall by Dr. Brent Burbridge MD, FRCPC, University Medical Imaging Consultants, College of Medicine, University of Saskatchewan is used under a [CC-BY-NC-SA 4.0](#) license.

Appendicitis

ACR – Right Lower Quadrant Pain

Case
Acute Appendicitis

Clinical:

History – This patient felt unwell and had nausea. She had been unwell for 48 hours.

Symptoms – The patient reported abdominal pain that began in the centre of the abdomen but had migrated to the right lower quadrant. Temperature was 39.5 C.

Physical – The abdominal exam revealed moderated tenderness in the right lower quadrant associated with guarding and rebound tenderness. No discernible mass.

Laboratory – The white blood cell count was elevated.

DDx:

Appendicitis

Abdominal abscess

Ovarian pathology

Imaging Recommendation

These differ for Adults, Children, and Pregnant Women.

[Adults – CT Abdomen and Pelvis, Variant 1](#)

[Children – Ultrasound Abdomen first, CT if inconclusive, Variant 4](#)

Pregnant Women – Abdominal X-ray's are less appropriate

ODIN Link for Appendicitis images (CT Abdomen), Figure 10.8A and B: <https://mistr.usask.ca/odin/?caseID=20160124121451294>

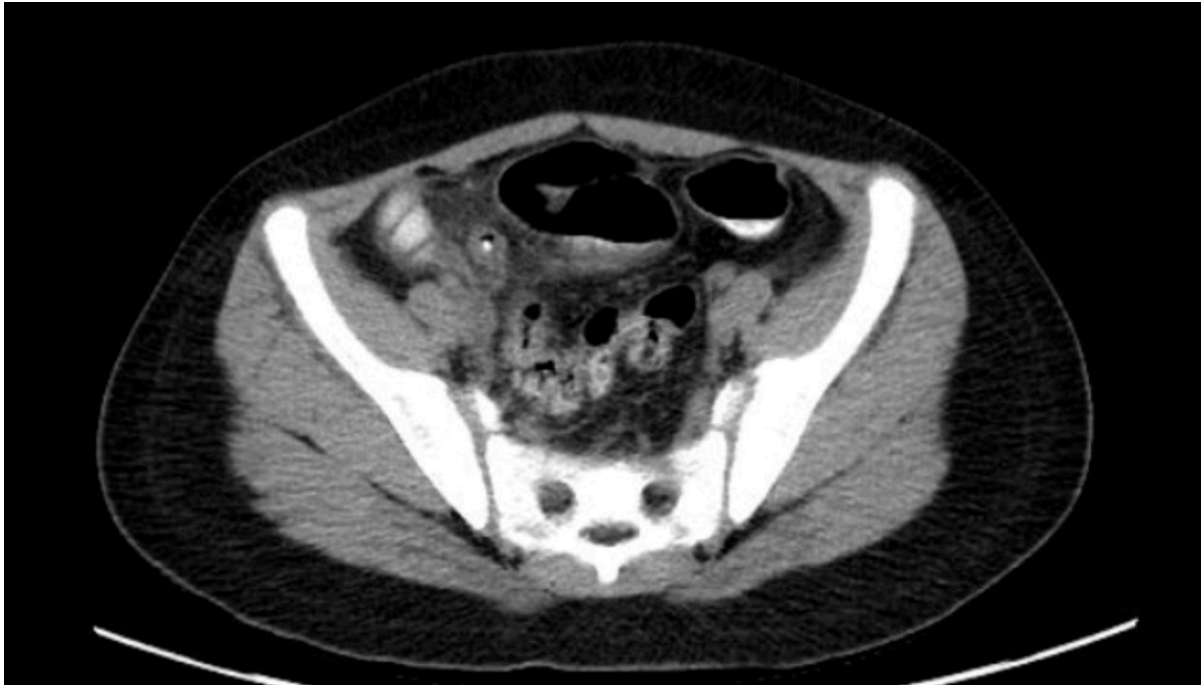

Figure 10.8A Axial CT of an Adult Abdomen demonstrating a thick-walled appendix with a calcified appendicolith

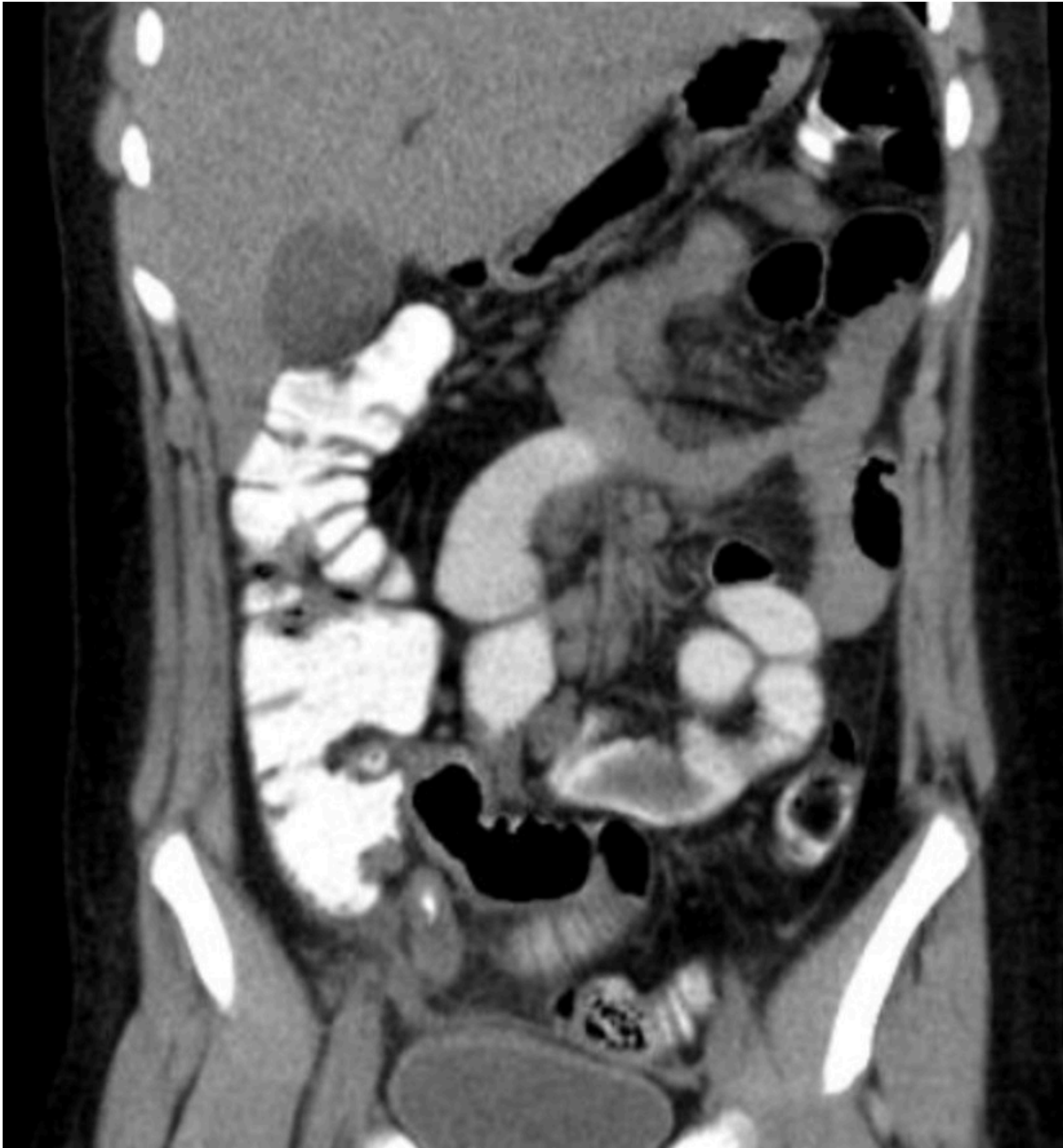

Figure 10.8B Coronal CT of an Adult Abdomen, demonstrating a thick-walled appendix with a calcified appendicolith

ODIN Link for Appendicitis (Child Ultrasound), Figure 10.9A and B: <https://mistr.usask.ca/odin/?caseID=20160124123843254>

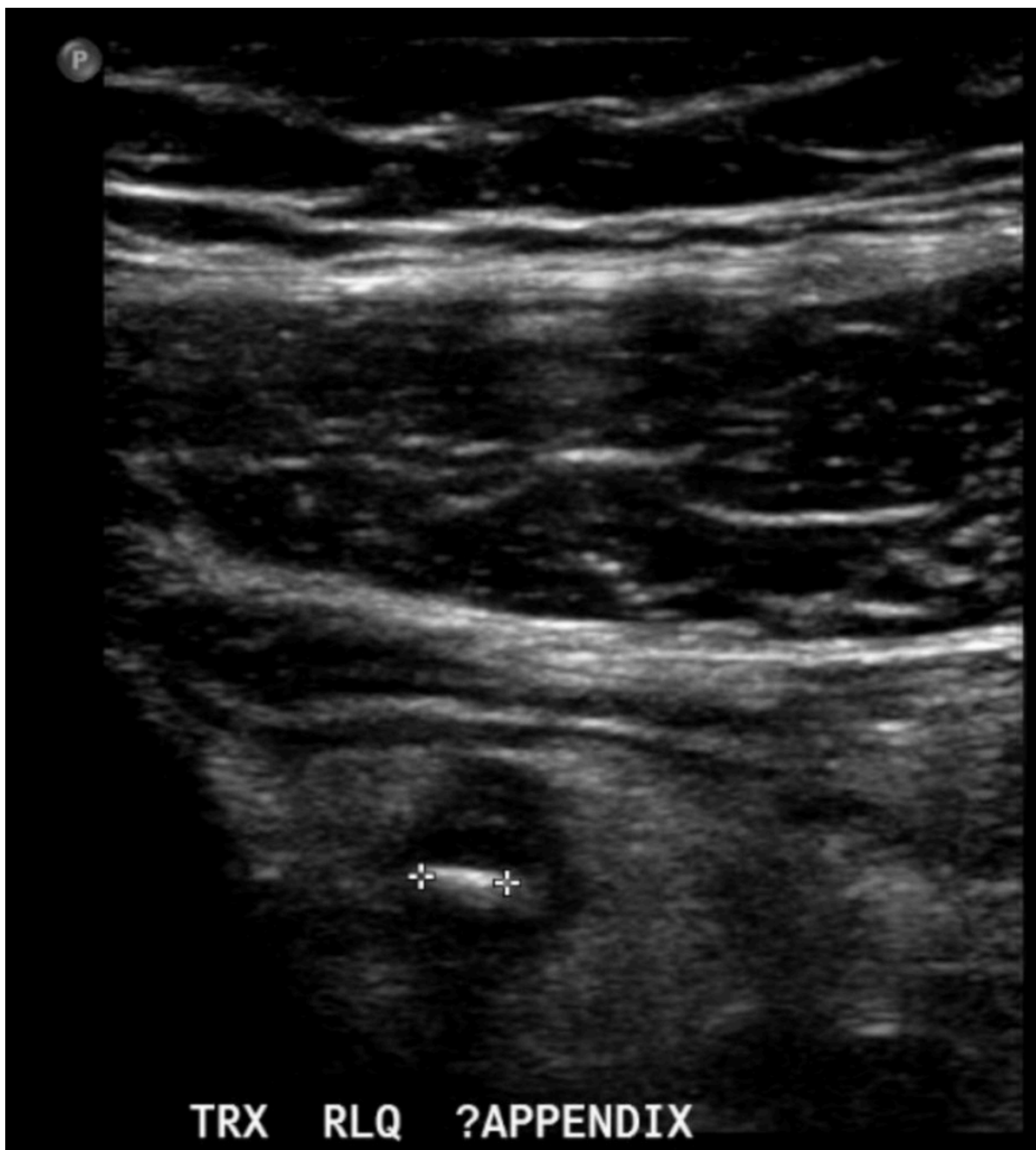

Figure 10.9A Child ultrasound of appendix, short axis, demonstrating a thick-walled appendix with an appendicolith

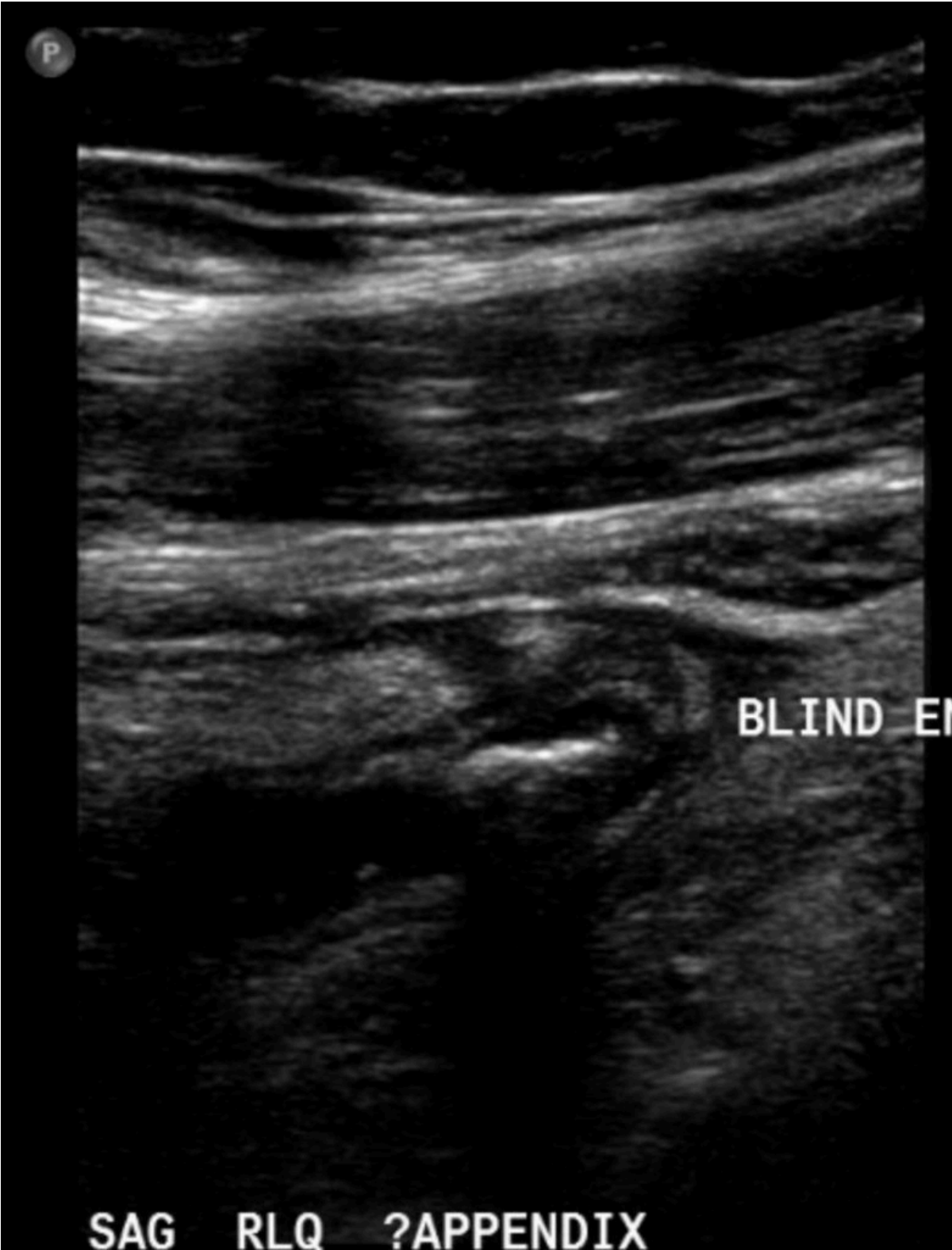

Figure 10.9B Child ultrasound of appendix, long axis, and blind end tubular structure with an appendicolith

Imaging Assessment

Computed Tomography:

Findings:

There was a tubular structure, contiguous with the cecum, in the right lower quadrant with a calcification within it. This was a blind ending structure that was dilated and thick walled distal to the calculus. There was a small bubble of gas within this next to the calculus. No other findings.

Interpretation:

Inflamed appendix with an appendicolith. Consistent with appendicitis.

Ultrasound:

Findings:

A thick walled, blind ending tubular structure was seen in the right lower quadrant. A shadowing calculus was seen in this tubular structure. The tubular structure was very painful with graded compression. No fluid in the vicinity. No adenopathy.

Interpretation:

The findings were in keeping with appendicitis.

Diagnosis:

Appendicitis

Discussion:

Appendicitis is an extremely common cause for a surgical abdomen, i.e. fever, pain, tenderness, rebound tenderness, guarding (suggestive of peritonitis).

The most likely cause for appendicitis is blockage of the appendiceal lumen due to a calculus (appendicolith, 15 – 20%) or due to edema in the wall of the neck preventing the lumen from communicating with the cecum. Trapped intestinal contents in the appendix become static and infected leading to appendicitis.

Clinically, appendicitis often starts as obscure, central, abdominal pain that over time migrates to the right lower quadrant. The maximal site of tenderness in the right lower quadrant is often at McBurney's point (one-third of the distance from the anterior iliac spine to the umbilicus).

The patient may develop guarding and rebound tenderness. If the appendix perforates the patient may develop sepsis related to an abscess or diffuse peritoneal infection.

CT is the imaging modality most useful in adults while US is best for children to avoid radiation exposure in the young.

Imaging findings that suggest appendicitis include:

- Appendicolith
- Blind ending, aperistaltic, tubular structure
- Appendix may be tender with graded compression using the ultrasound probe
- Thick appendix wall, > 6 mm
- Peri-appendiceal increased echogenicity
- Peri-appendiceal fluid

Attributions

Figure 10.8A Axial CT of an Adult Abdomen demonstrating a thick-walled appendix with a calcified appendicolith by Dr. Brent Burbridge MD, FRCPC, University Medical Imaging Consultants, College of Medicine, University of Saskatchewan is used under a [CC-BY-NC-SA 4.0](#) license.

Figure 10.8B Coronal CT of an Adult Abdomen, demonstrating a thick-walled appendix with a calcified appendicolith by Dr. Brent Burbridge MD, FRCPC, University Medical Imaging Consultants, College of Medicine, University of Saskatchewan is used under a [CC-BY-NC-SA 4.0](#) license.

Figure 10.9A Child ultrasound of appendix, short axis, demonstrating a thick-walled appendix with an appendicolith by Dr. Brent Burbridge MD, FRCPC, University Medical Imaging Consultants, College of Medicine, University of Saskatchewan is used under a [CC-BY-NC-SA 4.0](#) license.

Figure 10.9B Child ultrasound of appendix, long axis, and blind end tubular structure with an appendicolith by Dr. Brent Burbridge MD, FRCPC, University Medical Imaging Consultants, College of Medicine, University of Saskatchewan is used under a [CC-BY-NC-SA 4.0](#) license.

Diverticulitis

ACR – Gastrointestinal – Left Lower Quadrant Pain

Case
Diverticulitis

Clinical:

History – 4 days of left lower quadrant pain.

Symptoms – The patient has had persistent, 6/10, pain in the left lower quadrant. Bowel function was normal.

Physical – Fever (40C). There was focal moderate tenderness in the left lower quadrant with deep palpation. Bowel sounds were normal. The rectal examination was normal.

Laboratory – The white blood cell count was elevated.

DDx:

Pelvic/Abdominal Abscess

Diverticulitis

Colitis

Enteritis

Imaging Recommendation

[ACR – Gastrointestinal – Left Lower Quadrant Pain – Suspected Diverticulitis, Variant 1](#)

CT Abdomen and Pelvis

ODIN Link for Diverticulitis images, Figure 10.10A and B: <https://mistr.usask.ca/odin/?caseID=20170416160301674>

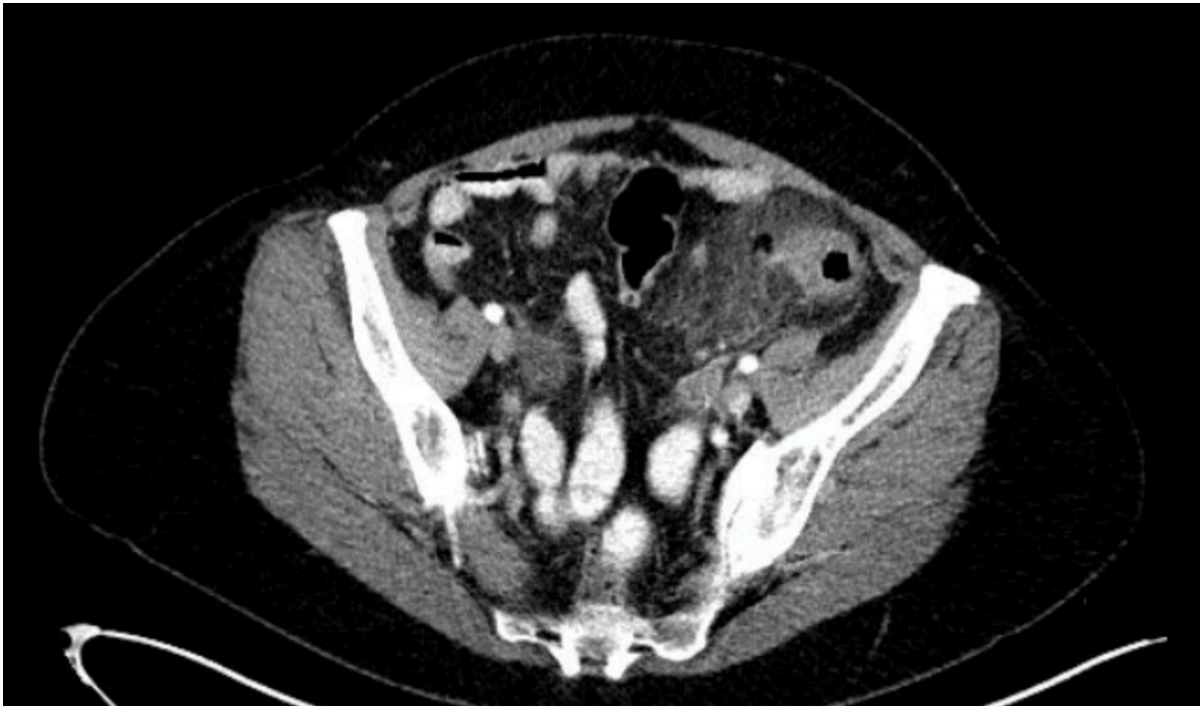

Figure 10.10A Axial CT of Abdomen

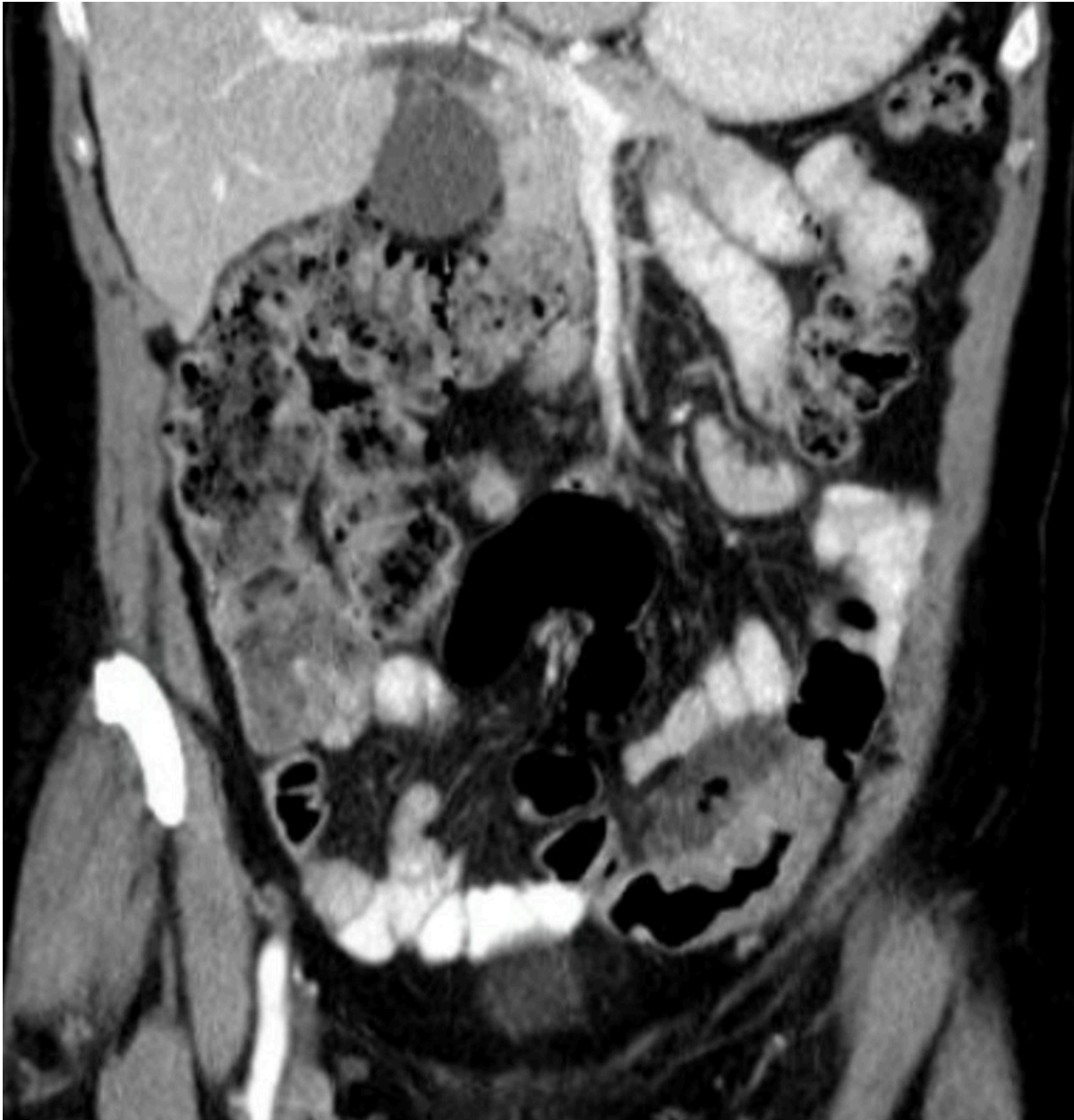

Figure 10.10B Coronal CT of Abdomen

Imaging Assessment

Findings:

There was a very thick-walled segment of the sigmoid colon in the left lower quadrant. There were multiple diverticula in the region. The pericolic fat was indurated. There was a long gas filled diverticulum that may represent a contained perforation of the colon.

Interpretation:

Diverticulitis with a possible contained perforation.

Diagnosis:

Diverticulitis

Colitis

Discussion:

Diverticula of the colon are herniations of mucosa and submucosa through the muscular layer of the colon. They are more common in the distal colon and increase in frequency with age.

At times they can become secondarily infected due to a partially obstructed or obstructed neck of the diverticulum. The diverticula contain fecal contents that can become infected within the closed space. CT is the optimal imaging modality for active diverticulitis.

CT findings of diverticulitis may include:

- Thickened colonic wall > 4 – 5 mm
- Pericolonic haziness due to inflammatory fluid/edema
- Larger fluid collections, abscesses or contained perforations
- Gas bubbles in the wall of the colon, the peri-colonic tissues, or in fluid adjacent to the colon.
- Pneumoperitoneum

The most common cause of left lower quadrant pain in adults is acute sigmoid and/or descending colon diverticulitis. It has been estimated that between 10% and 25% of patients with diverticulosis will ultimately develop diverticulitis

Triage for patients with suspected diverticulitis (i.e., left lower quadrant pain) should address 2 major clinical questions:

- 1) What are the differential diagnostic possibilities in this clinical situation?
- 2) What information is necessary to make a definitive management decision?

Some patients with acute diverticulitis may not require any imaging, notably those with typical symptoms of diverticulitis (e.g., left lower quadrant pain and tenderness) without suspected complications or those with a previous history of diverticulitis who present with clinical symptoms of recurrent disease. In some instances, such patients are treated medically without undergoing radiologic examinations, but diverticulitis can be simulated by other acute abdominal disorders.

Patients with diverticulitis may require surgery or interventional radiology procedures because of associated complications, including abscesses, fistulas, obstruction, or perforation. As a result, there has been a trend toward the

greater use of medical imaging to confirm the diagnosis of diverticulitis, evaluate the extent of the disease, and detect complications before deciding on the most appropriate treatment.

Attributions

Figure 10.10A Axial CT of Abdomen by Dr. Brent Burbridge MD, FRCPC, University Medical Imaging Consultants, College of Medicine, University of Saskatchewan is used under a [CC-BY-NC-SA 4.0](https://creativecommons.org/licenses/by-nc-sa/4.0/) license.

Figure 10.10B Coronal CT of Abdomen by Dr. Brent Burbridge MD, FRCPC, University Medical Imaging Consultants, College of Medicine, University of Saskatchewan is used under a [CC-BY-NC-SA 4.0](https://creativecommons.org/licenses/by-nc-sa/4.0/) license.

Toxic Megacolon

ACR – Gastrointestinal – Acute (non-localized) Abdominal Pain and Fever

Case

Toxic Megacolon

Clinical:

History – This patient had been in the hospital for 5 days after an acute stroke. A urinary tract infection developed secondary to the urinary bladder catheter. The patient was treated with antibiotics and the bladder infection improved.

Transfer to a rehabilitation unit was completed. The patient developed intractable diarrhea and became obtunded, febrile, and seemed very unwell. General surgery was asked to assess the patient.

Symptoms – Poor historian due to stroke and diminished consciousness.

Physical – The abdomen was extremely distended. The patient was in severe pain. Bowel sounds were enhanced. There was guarding but no rebound. Skin turgor was poor suggesting dehydration.

Laboratory – The patient was hypernatremic. The urea and creatinine were elevated. The white cell count was very high. Mild macrocytic anemia was noted.

DDx:

Colitis

Abscess

Enteritis

Perforation

Imaging Recommendation

[ACR – Gastrointestinal – Acute \(non-localized\) Abdominal Pain and Fever, Variant 3](#)

CT Abdomen and Pelvis with Intravenous Contrast

ODIN Link for Toxic Megacolon images (X-rays and CT of the Abdomen), Figure 10.11A and B:
<https://mistr.usask.ca/odin/?caseID=20160330231305076>

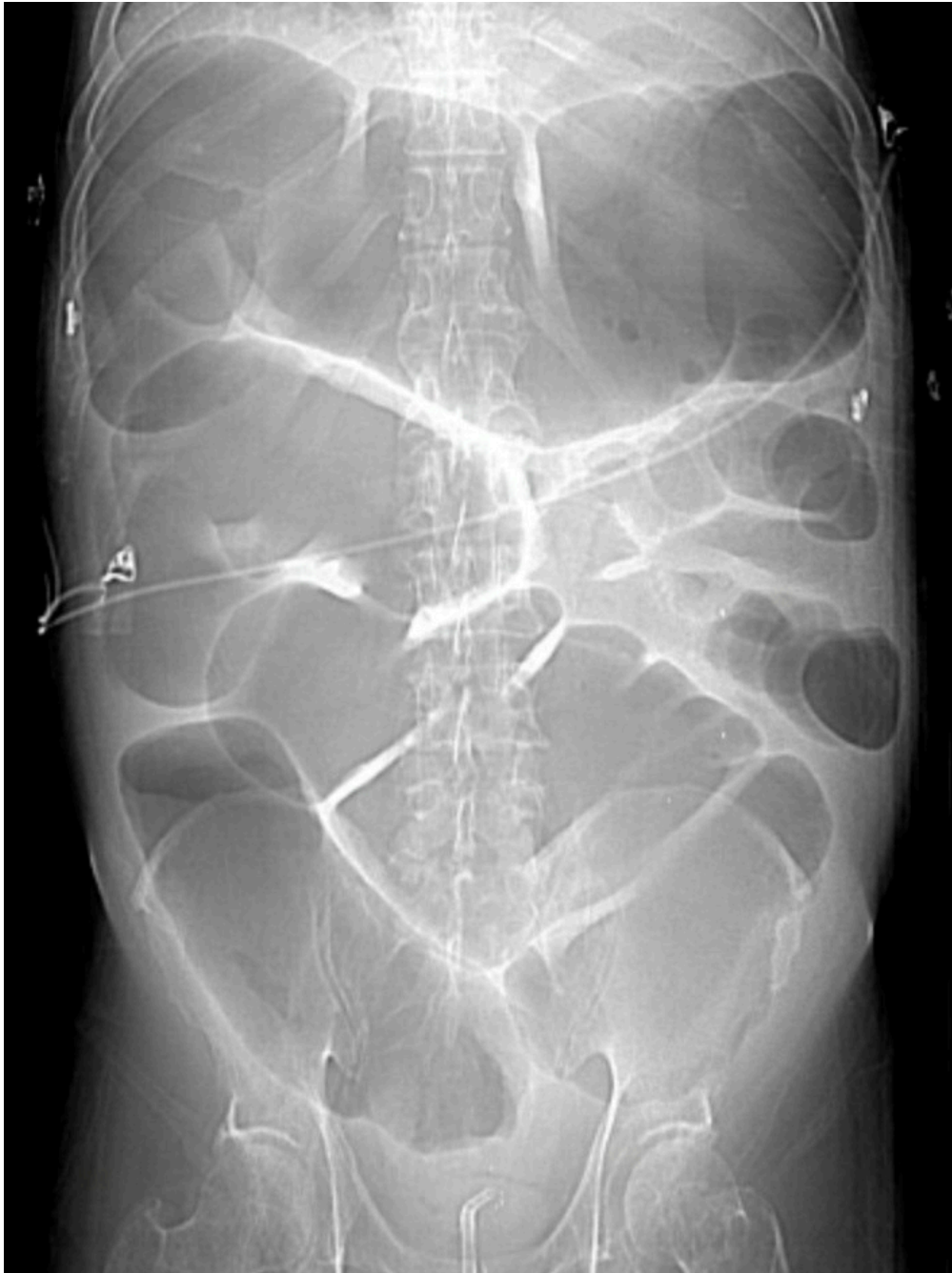

Figure 10.11A Abdominal x-ray of Toxic Megacolon

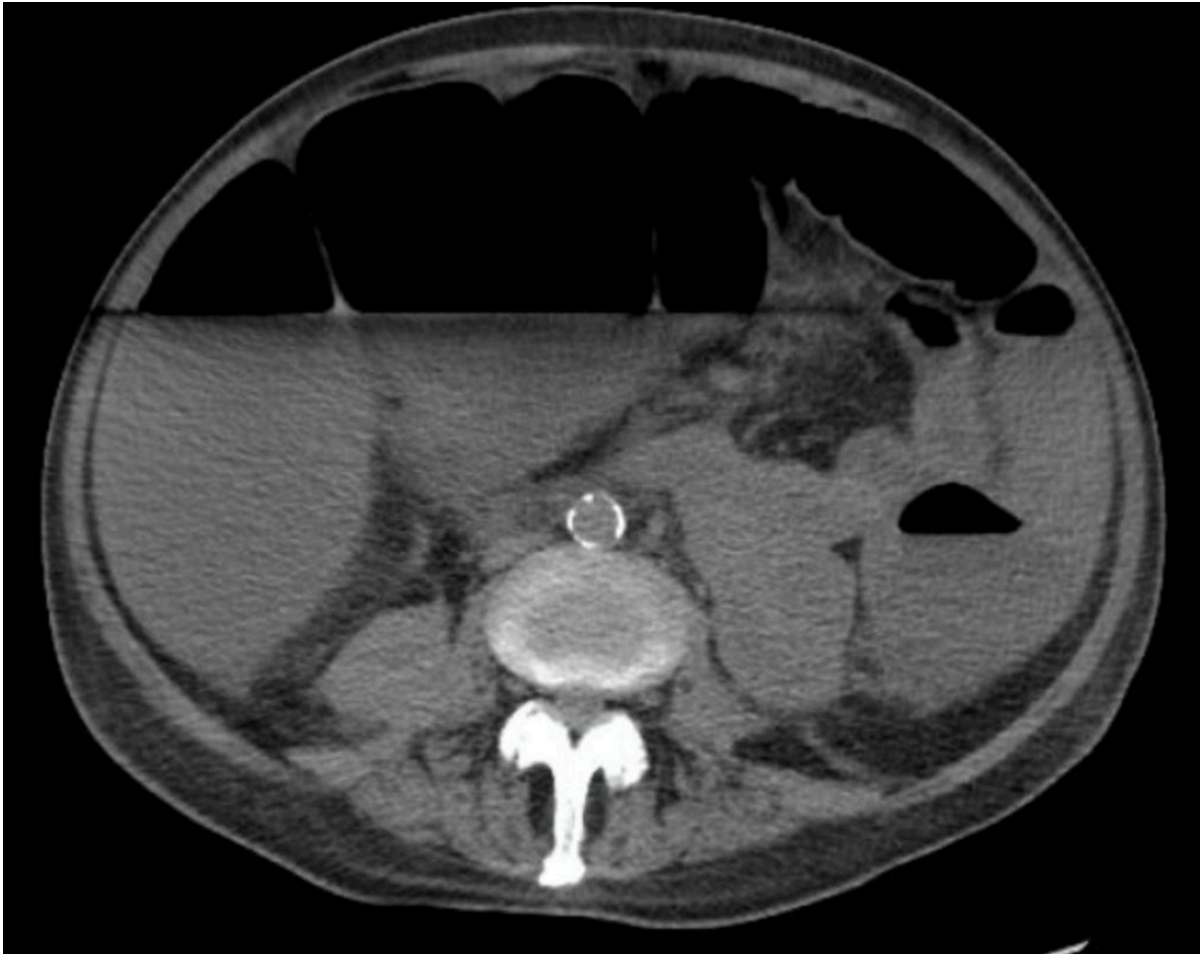

Figure 10.11B Axial CT of Toxic Megacolon

Imaging Assessment

Findings:

Contrast could not be given intravenously due to the poor renal function. There was patchy consolidation in the lung bases and small pleural effusions. The colon was generally, massively, distended. There was marked colonic wall thickening in the pelvis. No evidence of pneumatosis of the bowel or pneumoperitoneum. No evidence of obstruction.

Interpretation:

Toxic Megacolon

Diagnosis:

Clostridium Difficile Colitis

Discussion:

Toxic megacolon is the clinical term for an acute, toxic, colitis, with dilatation of the colon. The dilatation can be

either total or segmental. A more contemporary term for toxic megacolon is simply toxic colitis, because patients may develop toxicity without megacolon.

The hallmarks of toxic megacolon (toxic colitis), a potentially lethal condition, are non-obstructive colonic dilatation and signs of systemic toxicity.

Any of the following may predispose an individual to toxic megacolon – Dehydration, altered mental status, electrolyte abnormality, or hypotension.

TM (TC) was first thought to be a complication only of ulcerative colitis. In fact, TM (TC) may complicate any number of colitides, including inflammatory, ischemic, infectious, radiation, and pseudomembranous. Any three of the following supports the diagnosis of a toxic component – Fever ($>38^{\circ}\text{C}$), tachycardia (>120 beats/min), leukocytosis ($>10.5 \times 10^3/\mu\text{L}$), or anemia.

Imaging findings may include:

- Evidence of colonic dilation – more than 6 cm diameter of the transverse colon, and/or 10 cm diameter of the cecum.
- Thumb printing, thickening of the bowel wall which projects into the lumen (especially the colon)
- Perforation may be focal, contained, or disseminated.
- Pneumatosis intestinalis (gas bubbles in the bowel wall) may be seen
- Gas in the portal venous system is a rare, and very serious, complication.

Attributions

Figure 10.11A Supine Abdominal X-Ray of Toxic Megacolon by Dr. Brent Burbridge MD, FRCPC, University Medical Imaging Consultants, College of Medicine, University of Saskatchewan is used under a [CC-BY-NC-SA 4.0](#) license.

Figure 10.11B Axial CT of Toxic Megacolon by Dr. Brent Burbridge MD, FRCPC, University Medical Imaging Consultants, College of Medicine, University of Saskatchewan is used under a [CC-BY-NC-SA 4.0](#) license.

Liver Tumour

ACR – Gastrointestinal – Liver Lesion – Initial Characterization

Case 1

Hepatocellular Carcinoma

Clinical:

History– This patient was a chronic alcoholic. An ultrasound performed for vague right upper quadrant pain suggested there was a solitary lesion in segment 8 of the liver.

Symptoms – Pain had resolved.

Physical – Non-contributory.

DDx:

Hepatocellular Carcinoma of the Liver (HCC)

Imaging Recommendation

[ACR – Gastrointestinal – Liver Lesion – Initial Characterization, Variant 7](#)

CT Abdomen = MR Abdomen

ODIN Link for Liver Lesion imagins (CT and MRI), Figure 10.12A and B: <https://mistr.usask.ca/odin/?caseID=20170123135553121>

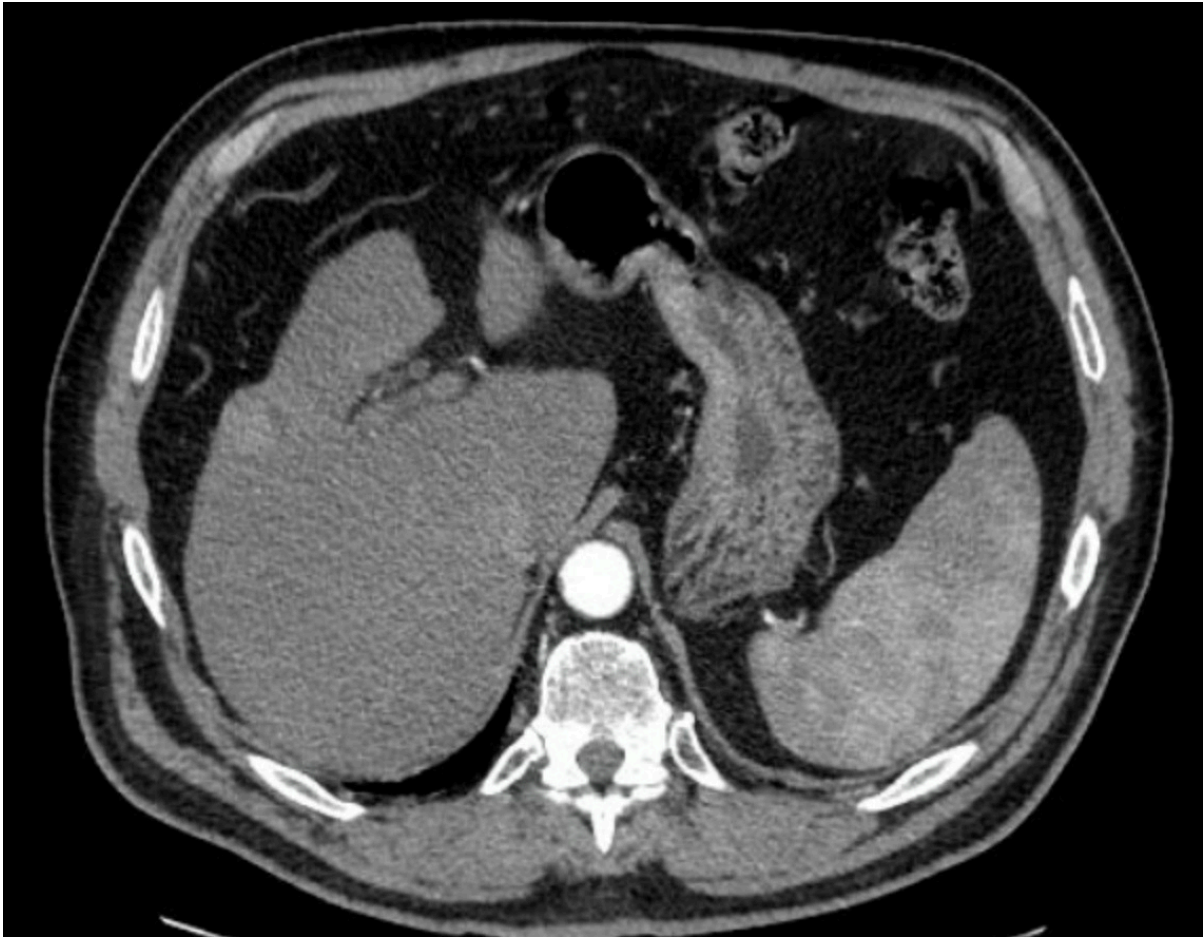

Figure 10.12A Axial CT of Liver

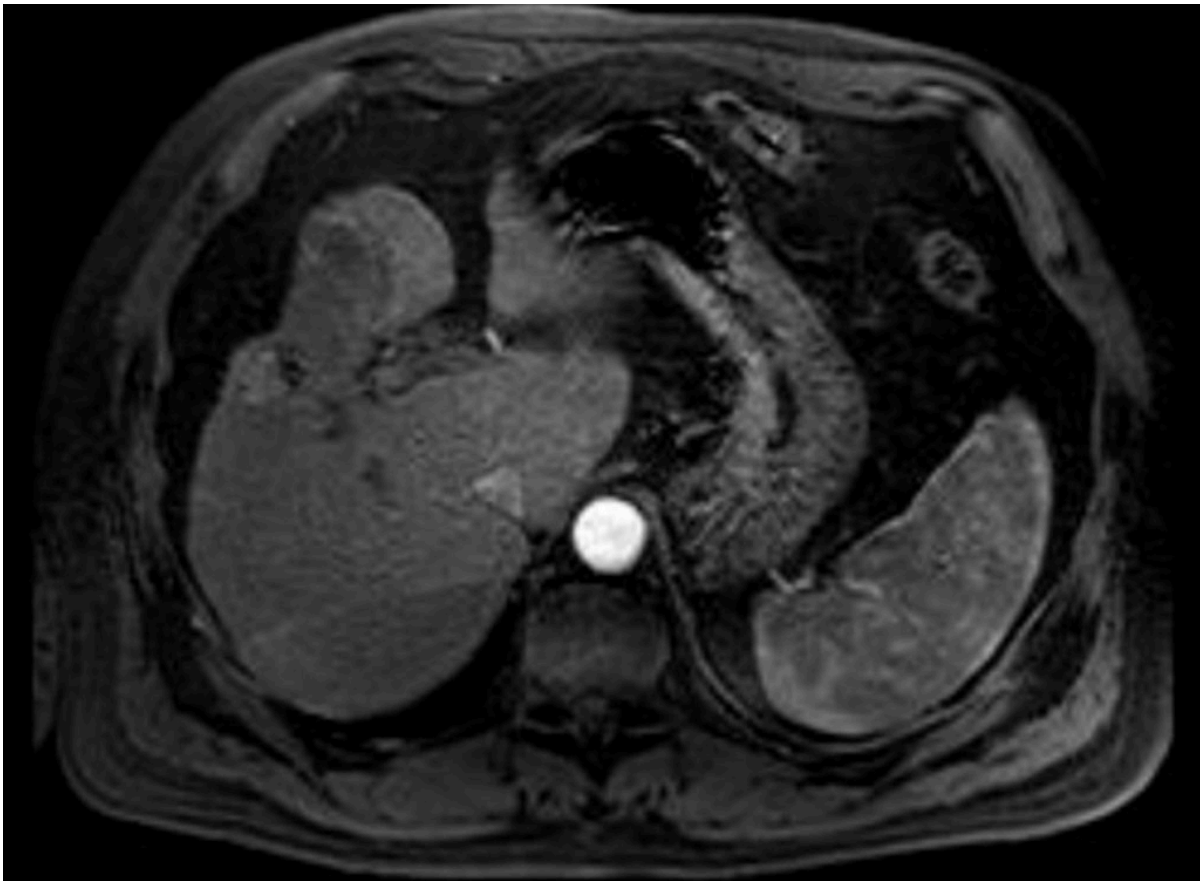


Figure 10.12B Axial MRI of Liver

Image Assessment

Findings:

Both CT and MRI demonstrate a poorly defined, low-grade, contrast enhancing, lesion in segment 8. The liver was small and irregular.

Interpretation:

HCC

Diagnosis:

Hepatocellular Carcinoma – HCC – Biopsy Proven

Discussion:

Due to the high prevalence of benign focal hepatic lesions in adults, liver lesion characterization is an important objective of diagnostic imaging. Incidental liver masses are often discovered in healthy adults during routine imaging procedures, often abdominal ultrasounds performed for other reasons, as well as, during staging of a known malignancy, and they need to be characterized.

Common benign liver masses include cysts, biliary hamartomas, and hemangiomas; common malignant tumors include metastases and hepatocellular carcinomas (HCCs). Less common liver tumors include focal nodular hyperplasia (FNH), hepatocellular adenoma, fibrolamellar HCC, intrahepatic cholangiocarcinoma, biliary cystadenoma and cystadenocarcinoma, lymphoma, stromal tumors, a variety of sarcomas, hemangioendothelioma, and hepatoblastoma, the latter occurring in children.

On occasion, non-tumorous masses may mimic liver tumors. These mimics include focal fat deposition or sparing, abscess, hematoma, vascular shunts such as the ones to treat portal venous-hepatic venous malformations, peliosis hepatitis and transient hepatic attenuation differences on computed tomography (CT), or transient hepatic intensity differences on magnetic resonance imaging (MRI).

Patients with cirrhosis are a special group in whom certain benign (regenerating nodules), premalignant (dysplastic nodules), malignant (HCC), and nontumorous (confluent hepatic fibrosis) masses are more prevalent.

MRI is rapidly becoming the imaging modality of choice for liver lesions characterization after Ultrasound or CT have been completed.

Imaging findings may include:

- Most often normal
- A distended abdomen may be a sign of ascites.

Attributions

Figure 10.12A Axial CT of Liver by Dr. Brent Burbridge MD, FRCPC, University Medical Imaging Consultants, College of Medicine, University of Saskatchewan is used under a [CC-BY-NC-SA 4.0](#) license.

Figure 10.12B Axial MRI of Liver by Dr. Brent Burbridge MD, FRCPC, University Medical Imaging Consultants, College of Medicine, University of Saskatchewan is used under a [CC-BY-NC-SA 4.0](#) license.

Jaundice

ACR – Gastrointestinal – Jaundice

Case

Pancreatic Adenocarcinoma

Clinical:

History – Painless jaundice.

Symptoms – Icteric eyes and skin. Itchy.

Physical – The gallbladder was palpable and non-tender. There was icterus of the sclera and skin. The patient was pale and cachectic.

Laboratory – A pattern of obstructive liver enzymes was noted with elevated direct and indirect bilirubin.

DDx:

Choledocholithiasis

Biliary Tree Malignancy

Pancreatic Malignancy

Metastatic Disease

Imaging Recommendation

[ACR – Gastrointestinal – Jaundice, Variant 2](#)

CT of the Abdomen, with intravenous contrast

Link to ODIN Images, Figure 10.13A and B – <https://mistr.usask.ca/odin/?caseID=20131106091539996>

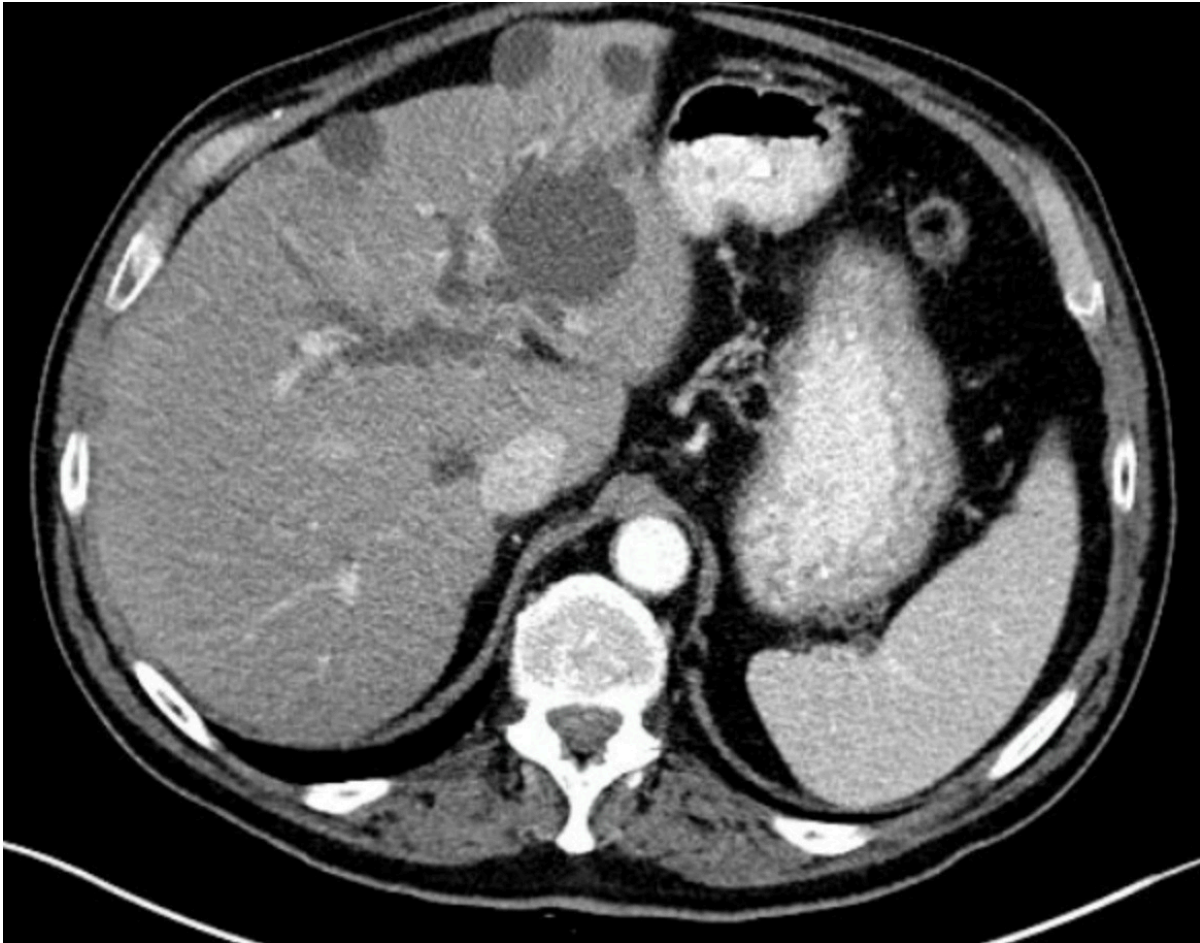


Figure 10.13A Axial CT of the liver demonstrating biliary system dilation

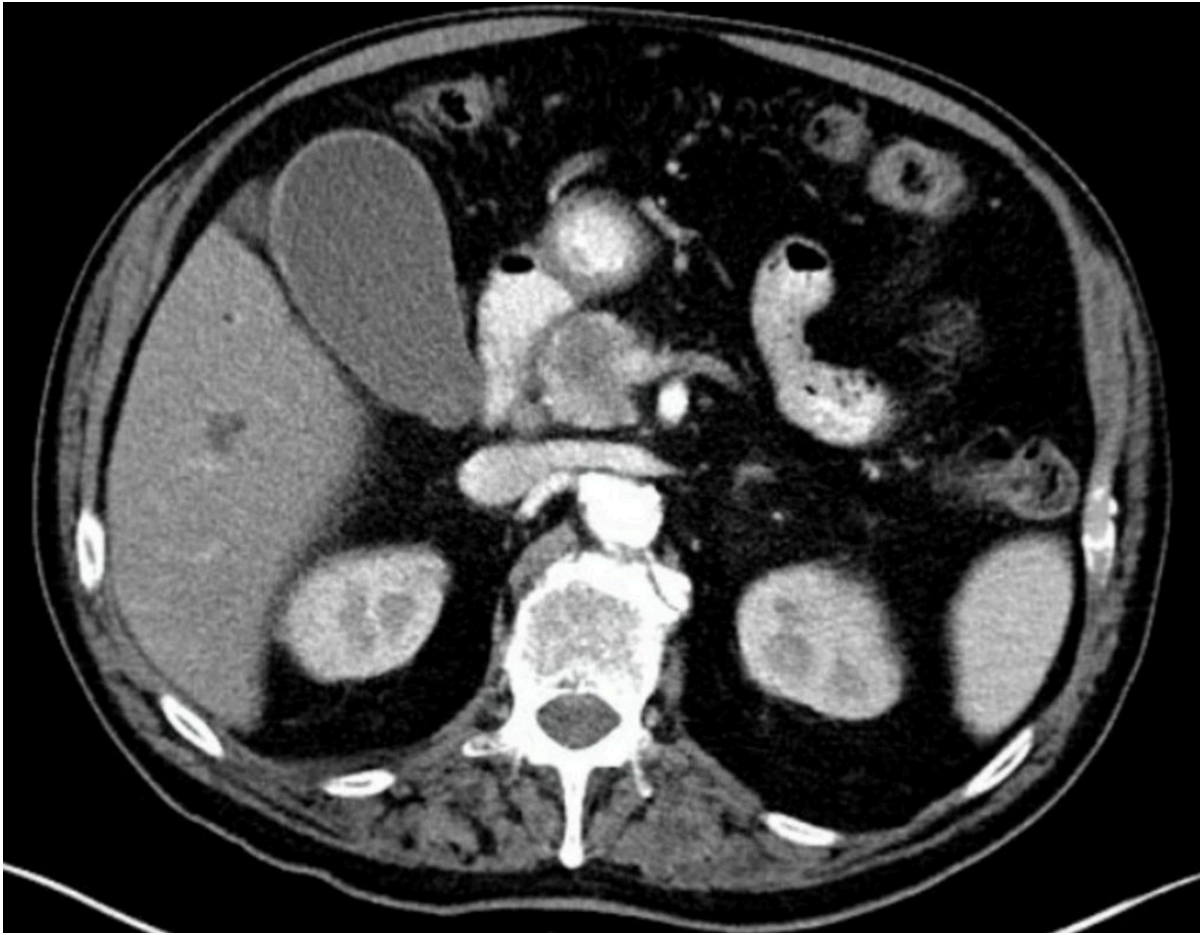


Figure 10.13B Axial CT of the Pancreatic head demonstrating a hypodense mass in the head of the gland

Imaging Assessment

Findings:

The contrast enhanced images demonstrated a non-enhancing mass in the head of the pancreas causing pancreatic duct and extrahepatic bile duct obstruction. There were multiple cysts in the liver. The intrahepatic bile ducts were dilated. No liver masses or nodules.

The pancreatic body and tail were very atrophic. No adenopathy.

Interpretation:

The findings were highly suggestive of a pancreatic malignancy.

Diagnosis:

Pancreatic Adenocarcinoma

Discussion:

One of the difficulties in determining a rational imaging strategy to evaluate jaundiced patients stems from the fact that jaundice is a clinical finding, not a single disease entity. The causes of non-hemolytic jaundice can be divided into two distinct categories: intrahepatic biliary stasis (hepatocellular jaundice) and mechanical biliary obstruction.

Because imaging plays little useful role in the evaluation of intrahepatic biliary stasis, the first task of the clinician caring for the jaundiced patient is to determine if jaundice is caused by bile duct obstruction. Several studies have shown that this distinction can be made in approximately 85% of patients using only clinical findings of age, nutritional status, pain, systemic symptoms, stigmata of liver disease, palpable liver, or gallbladder, and simple biochemical tests.

Patients with a high pretest probability of non-obstructive jaundice usually have either diffuse hepatocellular disease (e.g., cirrhosis, hepatitis), or, more rarely, inability of the liver to handle a bilirubin load (e.g., hemolytic anemia), or a metabolic deficiency (Gilbert's disease). These patients need no imaging; liver biopsy is usually required.

Obstructive jaundice is jaundice resulting from obstruction to the flow of bile from the liver to the duodenum. In adults, extrahepatic (mechanical) obstruction accounts for 40% of patients presenting with jaundice as the primary symptom, and this likelihood increases with advancing age. The most common causes of obstructive jaundice are neoplasms of the pancreas, ampulla of Vater or biliary tract, choledocholithiasis, pancreatitis, and iatrogenic strictures of the biliary tree. Other less common causes include tumors metastatic to the biliary epithelium, sclerosing cholangitis, hepatic tumors adjacent to the liver hilum, perihepatic lymphadenopathy, and other causes of cholangitis.

Attributions

Figure 10.13A Axial CT of the liver demonstrating biliary system dilation by Dr. Brent Burbridge MD, FRCPC, University Medical Imaging Consultants, College of Medicine, University of Saskatchewan is used under a [CC-BY-NC-SA 4.0](#) license.

Figure 10.13B Axial CT of the Pancreatic head demonstrating a hypodense mass in the head of the gland by Dr. Brent Burbridge MD, FRCPC, University Medical Imaging Consultants, College of Medicine, University of Saskatchewan is used under a [CC-BY-NC-SA 4.0](#) license.

Gastrointestinal and Abdominal – References

- 1) Gail M. Yarmish, MD; Martin P. Smith, MD; Max P. Rosen, MD, MPH. ACR Appropriateness Criteria® – Gastrointestinal – Right Upper Quadrant Pain. Available at <https://acsearch.acr.org/docs/69474/Narrative/> American College of Radiology. Accessed June 30, 2017.
- 2) Vahid Yaghmai, MD, MS; Max P. Rosen, MD, MPH; Tasneem Lalani, MD. ACR Appropriateness Criteria® – Gastrointestinal – Acute (non-localized) Abdominal Pain and Fever – Pneumoperitoneum. Available at <https://acsearch.acr.org/docs/69467/Narrative/> American College of Radiology. Accessed June 30, 2017.
- 3) Douglas S. Katz, MD; Mark E. Baker, MD; Max P. Rosen, MD, MPH. ACR Appropriateness Criteria® – Gastrointestinal – Suspected Small Bowel Obstruction. Available at <https://acsearch.acr.org/docs/69476/Narrative/> American College of Radiology. Accessed June 30, 2017.
- 4) Martin P. Smith, MD; Douglas S. Katz, MD; Max P. Rosen, MD, MPH. ACR Appropriateness Criteria® – Gastrointestinal – Right Lower Quadrant Pain – Suspected Appendicitis. Available at <https://acsearch.acr.org/docs/69357/Narrative/> American College of Radiology. Accessed June 30, 2017.
- 5) Michelle M. McNamara, MD; Tasneem Lalani, MD; Marc Anthony Camacho, MD. ACR Appropriateness Criteria® – Gastrointestinal – Left Lower Quadrant Pain – Suspected Diverticulitis. Available at <https://acsearch.acr.org/docs/69356/Narrative/> American College of Radiology. Accessed June 30, 2017.
- 6) Rendon C. Nelson, MD; Ihab R. Kamel, MD, PhD; Mark E. Baker, MD. ACR Appropriateness Criteria® – Gastrointestinal – Liver Lesion – Initial Characterization. Available at <https://acsearch.acr.org/docs/69472/Narrative/> American College of Radiology. Accessed June 30, 2017.
- 7) Tasneem Lalani, MD; Corey A. Couto, MD; Max P. Rosen, MD, MPH. ACR Appropriateness Criteria® – Gastrointestinal – Jaundice. Available at <https://acsearch.acr.org/docs/69497/Narrative/> American College of Radiology. Accessed June 30, 2017.

Chapter 11 – Gynecology and Obstetrics

Benign and Malignant Tumours of the Female Reproductive System

ACR – Women’s Imaging – Clinically Suspected Adnexal/Pelvic Mass/Uterus

Case 1

Uterine Leiomyoma (Fibroid)

Clinical:

History – Annual physical examination.

Symptoms – The patient reported a vague sense of pelvic fullness over the last six months, but no other symptoms.

Physical – The uterus was felt to be globally enlarged and had a discernible, separate, mass in the fundus. Nil else.

DDx:

Uterine Mass

Adnexal Mass

Peritoneal Mass

Imaging Recommendation

[ACR – Women’s Imaging – Clinically Suspected Adnexal/Pelvic Mass/Uterus, Variant 1](#)

Pelvic Ultrasound

ODIN Link for Leiomyoma images (Pelvic Ultrasound), Figure 11.1A and B: <https://mistr.usask.ca/odin/?caseID=20170502170438155>

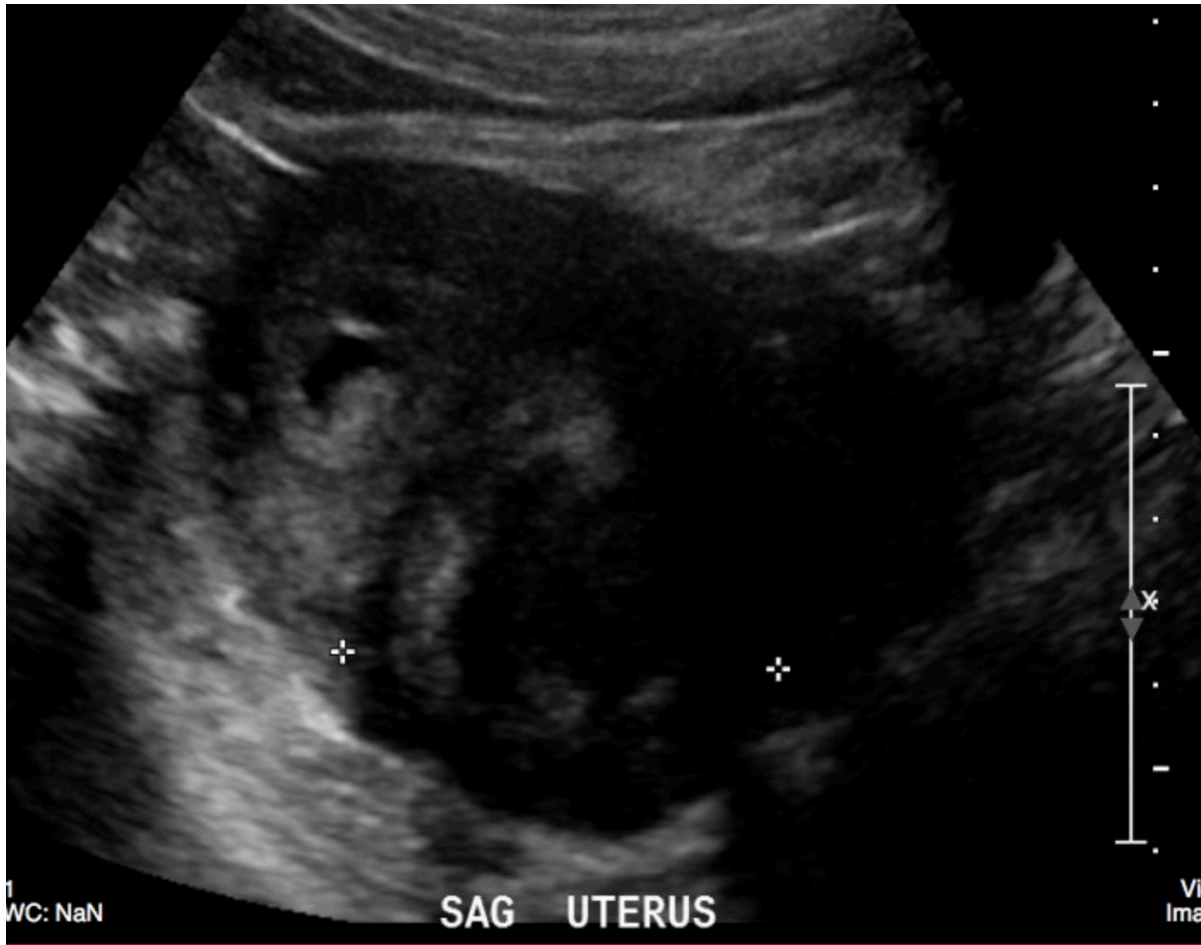

Figure 11.1A Sagittal Ultrasound of the Uterus with a uterine mass.

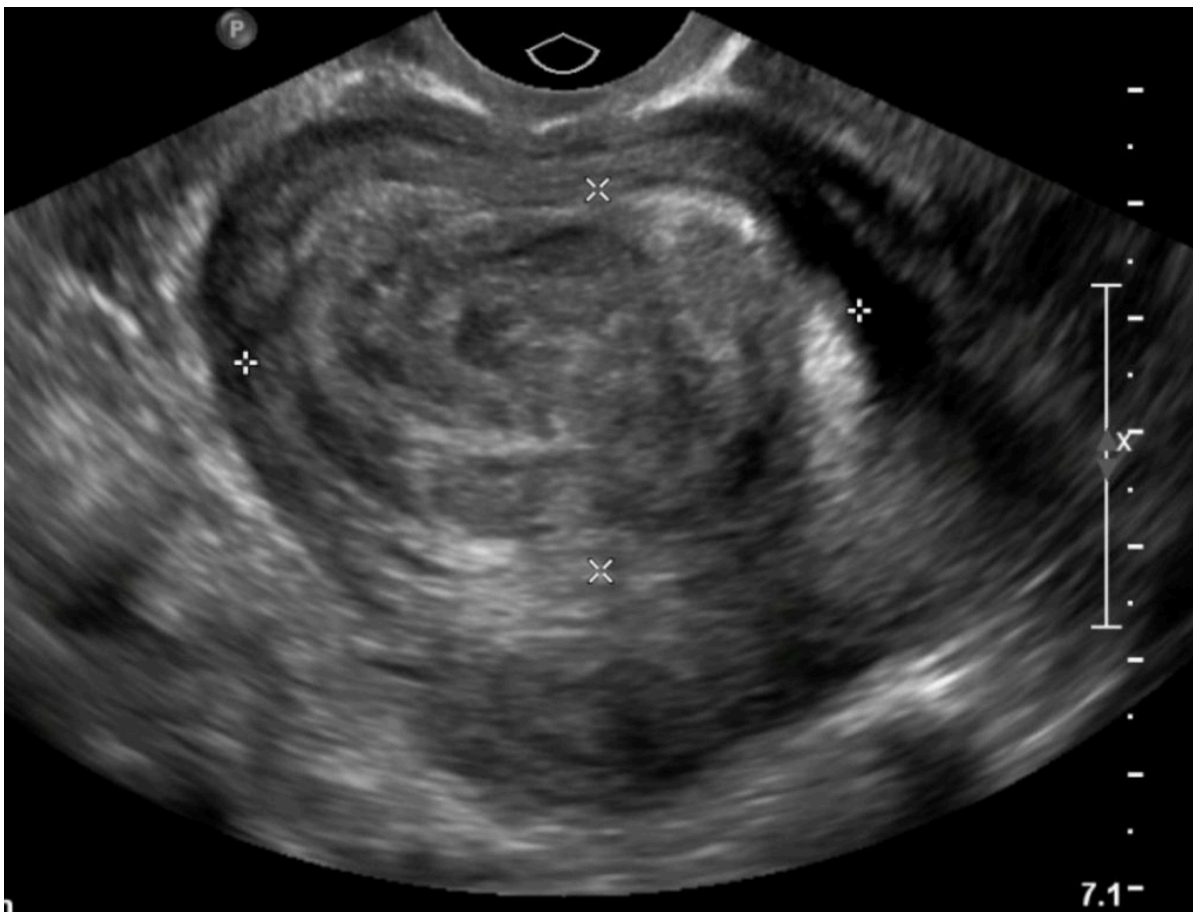

Figure 11.1B Transverse Ultrasound of the Uterus with a mass

Imaging Assessment

Findings:

There was a large, homogeneous mass in the uterus that was of low echogenicity. It caused shadowing of the ultrasound beam. Some fluid was seen in the endometrial cavity. The ovaries were normal.

Interpretation:

Probable Leiomyoma of the Uterus

Diagnosis:

Uterine Leiomyoma (Fibroid)

Discussion:

Suspected uterine and adnexal masses are a common problem clinically, and pelvic ultrasonography (US), specifically endovaginal US, is the first-line imaging modality for assessing them. Its findings, however, should be correlated with the physical examination, history, and laboratory tests. Morphological analysis of adnexal masses with US can help narrow the differential diagnosis.

Recent studies have shown that US (transvaginal plus color Doppler) may discriminate benign from malignant lesions with a sensitivity of 99.1 % and a specificity of 85.9%. However, US is not always reliable for triage of patients to surgery.

Transabdominal sonography (TAS) and transvaginal sonography (TVS) are complementary. In some facilities, patients are scanned by both techniques, but most recent literature regarding adnexal mass US refers to TVS.

- Leiomyomas are benign smooth muscle tumors of the uterus that occur in up to 50% of women over the age of 30.
- Although most women with fibroids are asymptomatic, fibroids can cause pain, infertility, menorrhagia, and urinary or bowel symptoms if they grow large enough.
- US (transabdominal and transvaginal) is the imaging study of choice in evaluating uterine fibroids.
- Magnetic resonance imaging (MRI) is used mainly to evaluate complicated cases or in surgical planning.

Imaging findings may include

- US (transabdominal and transvaginal) is the imaging study of choice in evaluating uterine fibroids.
- Uterine leiomyomas on US are heterogeneously hypoechoic, solid masses, meaning they may display some areas that contain many echoes and others that demonstrate few echoes.
- It is important to characterize the location of fibroids as submucosal (which has implications for bleeding and infertility), myometrial (most common), or serosal (can be pedunculated).

Case 2

Simple Ovarian Cyst

Clinical:

History – Annual physical examination.

Symptoms – No symptoms.

Physical – The right ovary was globally enlarged and had a soft compressible feel on pelvic examination. Nil else.

DDx:

Ovarian Mass

Ovarian Cyst

Pelvic Adenopathy

Imaging Recommendation

[ACR – Women’s Imaging – Clinically Suspected Adnexal/Pelvic Mass/Uterus, Variant 1](#)

Ultrasound

ODIN Link for Ovarian Cyst images (Ultrasound), Figure 11.2A and B – <https://mistr.usask.ca/odin/?caseID=20170123215147808>

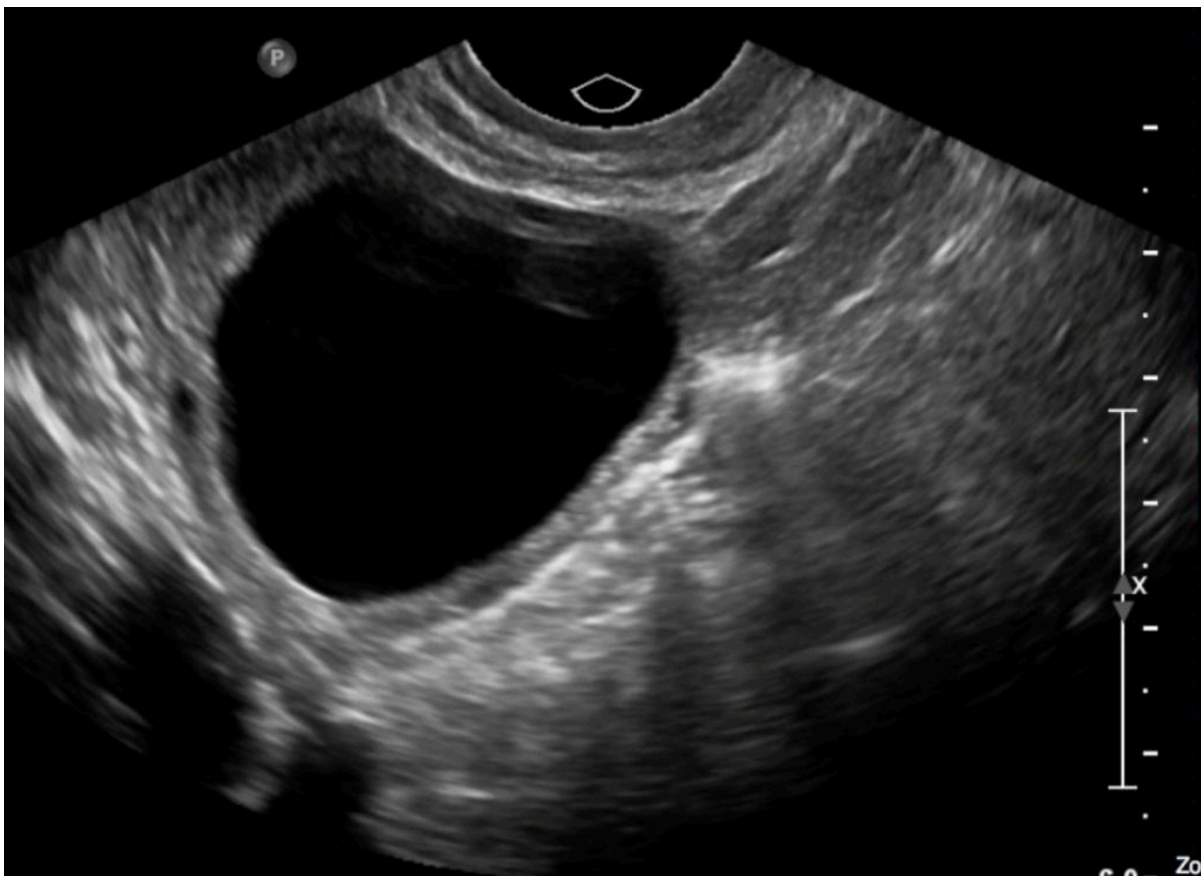

Figure 11.2A Pelvic ultrasound in a female with an ovarian cyst.

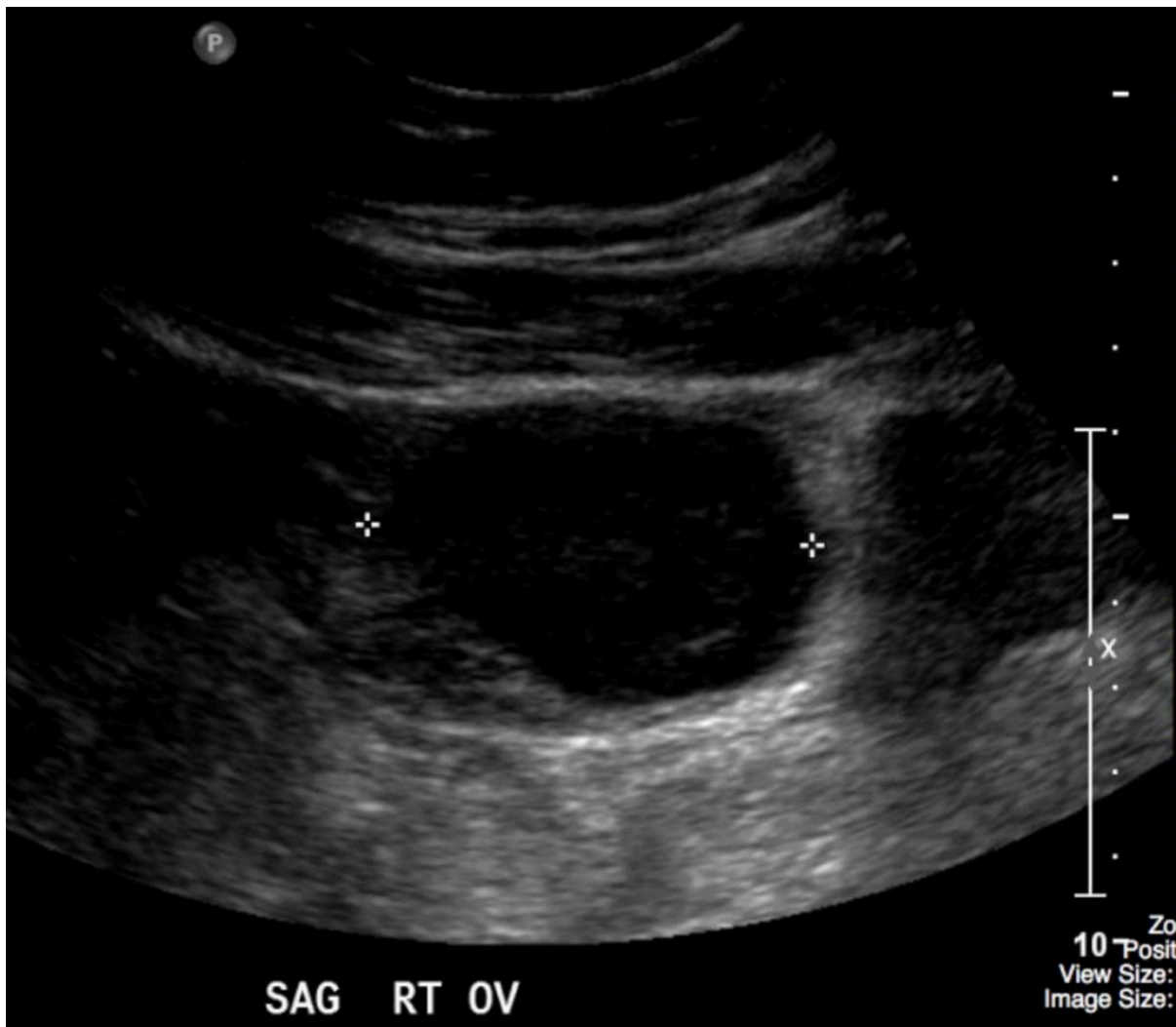


Figure 11.2B Sagittal ultrasound of a right ovarian cyst.

Imaging Assessment

Findings:

The images revealed a simple cyst in the right ovary with no nodules in the cyst wall or abnormal Doppler signal.

Interpretation:

Simple cyst of the right ovary.

Diagnosis:

Simple Ovarian Cyst

Discussion:

Suspected uterine and adnexal masses are a common problem clinically, and pelvic sonography (US), specifically

endovaginal US, is the first-line imaging modality for assessing them. Its findings, however, should be correlated with the history, clinical, and laboratory findings. Morphological analysis of adnexal masses with US can help narrow the differential diagnosis.

Recent studies have shown that US (transvaginal plus color Doppler) may discriminate benign from malignant lesions with a sensitivity of 99.1 % and a specificity of 85.9%. However, US is not always reliable for triaging patients for surgery. Accurate staging is best achieved with MRI.

If one of the non-dominant follicles fills with fluid and does not rupture, a follicular cyst is formed. Follicular cysts are unilateral, usually asymptomatic, and usually involute during the next menstrual cycle or two. Follicular cysts and corpus luteum cysts are called functional cysts of the ovary because they occur as a result of the hormonal stimuli associated with ovulation. Both are characteristically well-defined, thin-walled, anechoic structures with homogeneous internal fluid. They may contain echogenic material if hemorrhage occurs into the “cyst”.

Case 3

Ovarian Dermoid

Clinical:

History: An ultrasound, performed for pelvic pain, incidentally detected an ovarian mass.

Symptoms: None

Physical Examination: Trans-abdominal and bi-manual pelvic examination detected a solid mass in the left adnexa.

DDx:

Ovarian Tumor

Ovarian Cyst

Pelvic Adenopathy

Imaging Recommendation

[ACR – Women’s Imaging – Clinically Suspected Adnexal/Pelvic Mass, Variant 1](#)

Ultrasound

ODIN Link for Ovarian Dermoid images (Ultrasound and CT), Figure 11.3A and B:
<https://mistr.usask.ca/odin/?caseID=20170123215550360>

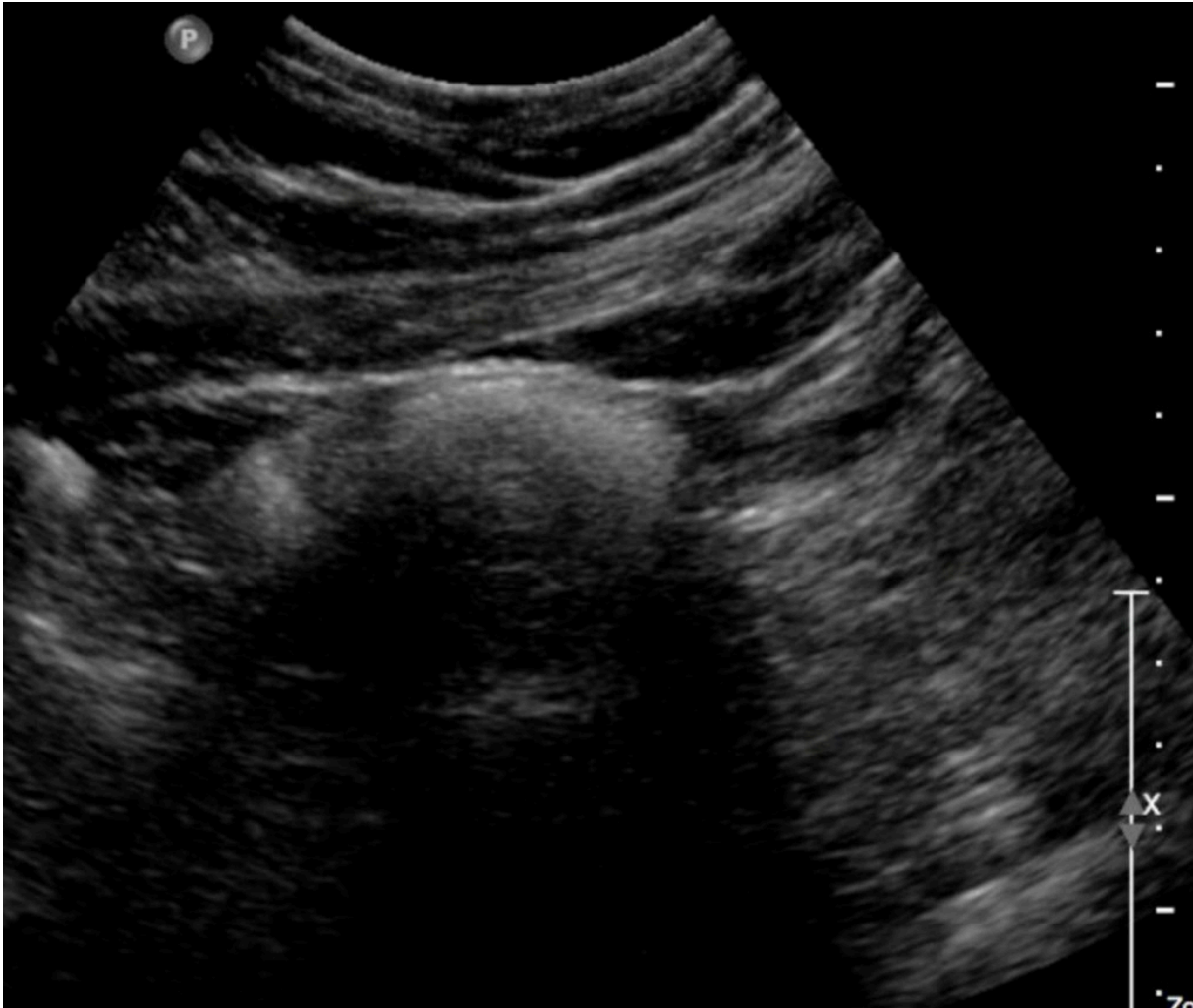

Figure 11.3A Ultrasound of female uterus, echogenic mass with acoustic shadowing.

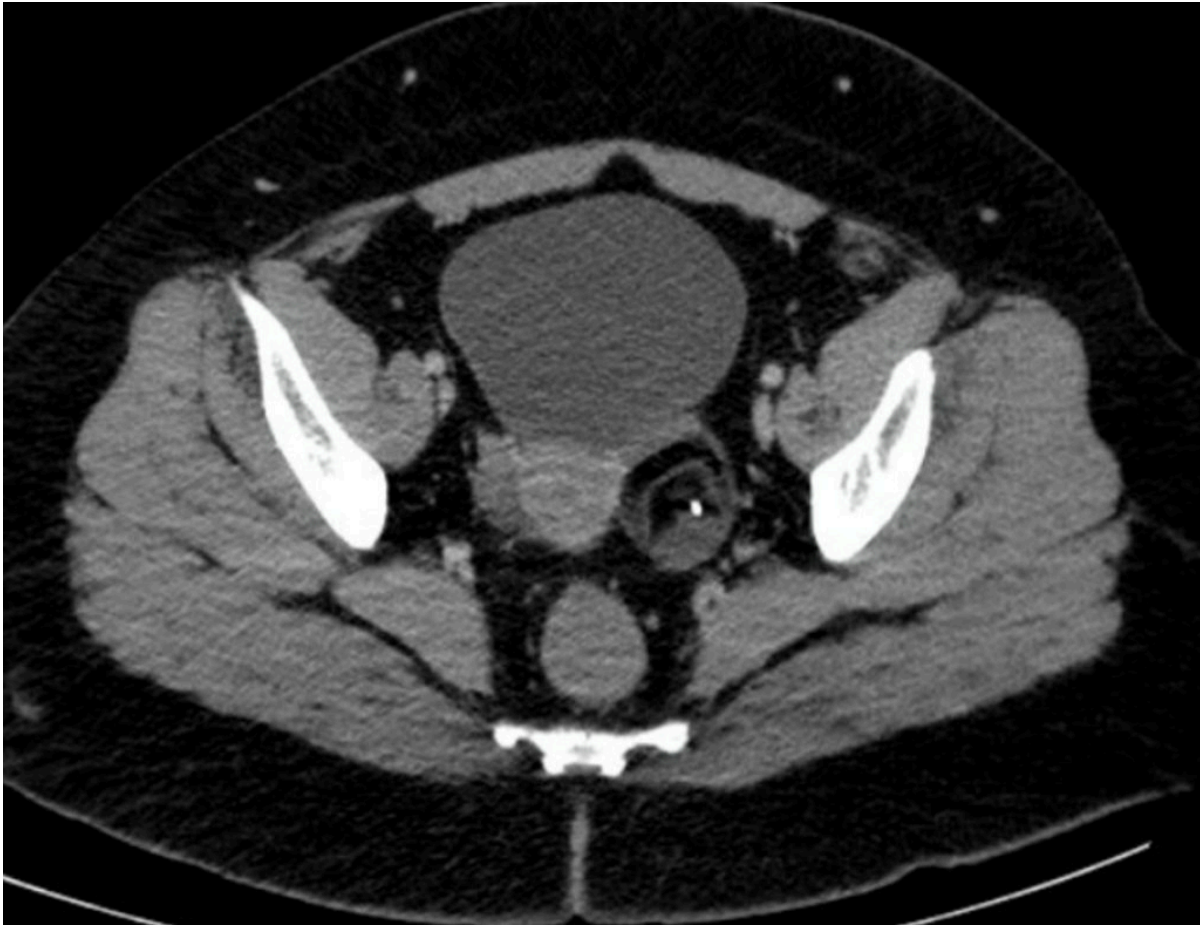


Figure 11.3B CT Scan of female pelvis, left adnexal mass with bone, fat and soft tissue.

Imaging Assessment

Ultrasound

Ultrasound detected a left adnexal mass that demonstrated increased echogenicity and shadowing of the ultrasound beam. No focal calcification detected.

Computed Tomography

CT revealed a mass containing, fat, soft tissue, and calcification in the left adnexa.

Diagnosis: Ovarian Dermoid Tumor

Diagnosis:

Ovarian Dermoid (left)

Discussion:

Dermoid cysts are mature teratomas composed of cells from all three germ layers – ectoderm, mesoderm, and

endoderm – although the ectodermal elements (hair, bone) predominate. They are most commonly found in women of reproductive age, are bilateral in up to 25% of cases, and may serve as a lead point for ovarian torsion.

Imaging findings of a dermoid cyst may include:

- An adnexal mass is present.
- Normal ovarian tissue may be present.
- Dermoid cysts have a variety of echo textures on ultrasound due to the complex tissue present.
- There may be echogenic tissue consistent with fat.
- There may be dense calcifications due to teeth or bone in the mass.
- There may be a complex dot – dash pattern due to layered hair.
- A dermoid plug is a peripheral echogenic nodule – Rokitansky nodule.
- The total size of the mass may not be visible due to shadowing from calcification or fat – the tip of the iceberg sign.
- Fluid – fluid levels may be seen.

Attributions

Figure 11.1A Sagittal Ultrasound of the Uterus with a uterine mass by Dr. Brent Burbridge MD, FRCPC, University Medical Imaging Consultants, College of Medicine, University of Saskatchewan is used under a [CC-BY-NC-SA 4.0](#) license.

Figure 11.1B Transverse Ultrasound of the Uterus with a mass by Dr. Brent Burbridge MD, FRCPC, University Medical Imaging Consultants, College of Medicine, University of Saskatchewan is used under a [CC-BY-NC-SA 4.0](#) license.

Figure 11.2A Pelvic ultrasound in a female with an ovarian cyst by Dr. Brent Burbridge MD, FRCPC, University Medical Imaging Consultants, College of Medicine, University of Saskatchewan is used under a [CC-BY-NC-SA 4.0](#) license.

Figure 11.2B Sagittal ultrasound of a right ovarian cyst by Dr. Brent Burbridge MD, FRCPC, University Medical Imaging Consultants, College of Medicine, University of Saskatchewan is used under a [CC-BY-NC-SA 4.0](#) license.

Figure 11.3A Ultrasound of female uterus, echogenic mass with acoustic shadowing by Dr. Brent Burbridge MD, FRCPC, University Medical Imaging Consultants, College of Medicine, University of Saskatchewan is used under a [CC-BY-NC-SA 4.0](#) license.

Figure 11.3B CT Scan of female pelvis, left adnexal mass with bone, fat and soft tissue by Dr. Brent Burbridge MD, FRCPC, University Medical Imaging Consultants, College of Medicine, University of Saskatchewan is used under a [CC-BY-NC-SA 4.0](https://creativecommons.org/licenses/by-nc-sa/4.0/) license.

Normal Pregnancy

ACR Women's Imaging – Assessment of Fetal Well-Being

Case

Normal Obstetrical Ultrasound – 20 weeks

Clinical:

History – This was a 20 week gestation, routine, obstetrical ultrasound.

Symptoms – Normal pregnancy.

Physical – Active, live fetus, uterine fundus at the level of the umbilicus.

DDx:

Normal Pregnancy

Imaging Recommendation

[ACR Women's Imaging – Assessment of Fetal Well-Being, Variant 1](#)

Ultrasound

ODIN Link for Normal Pregnancy images (Ultrasound), Figure 11.4A and B: <https://mistr.usask.ca/odin/?caseID=20170126222052150>

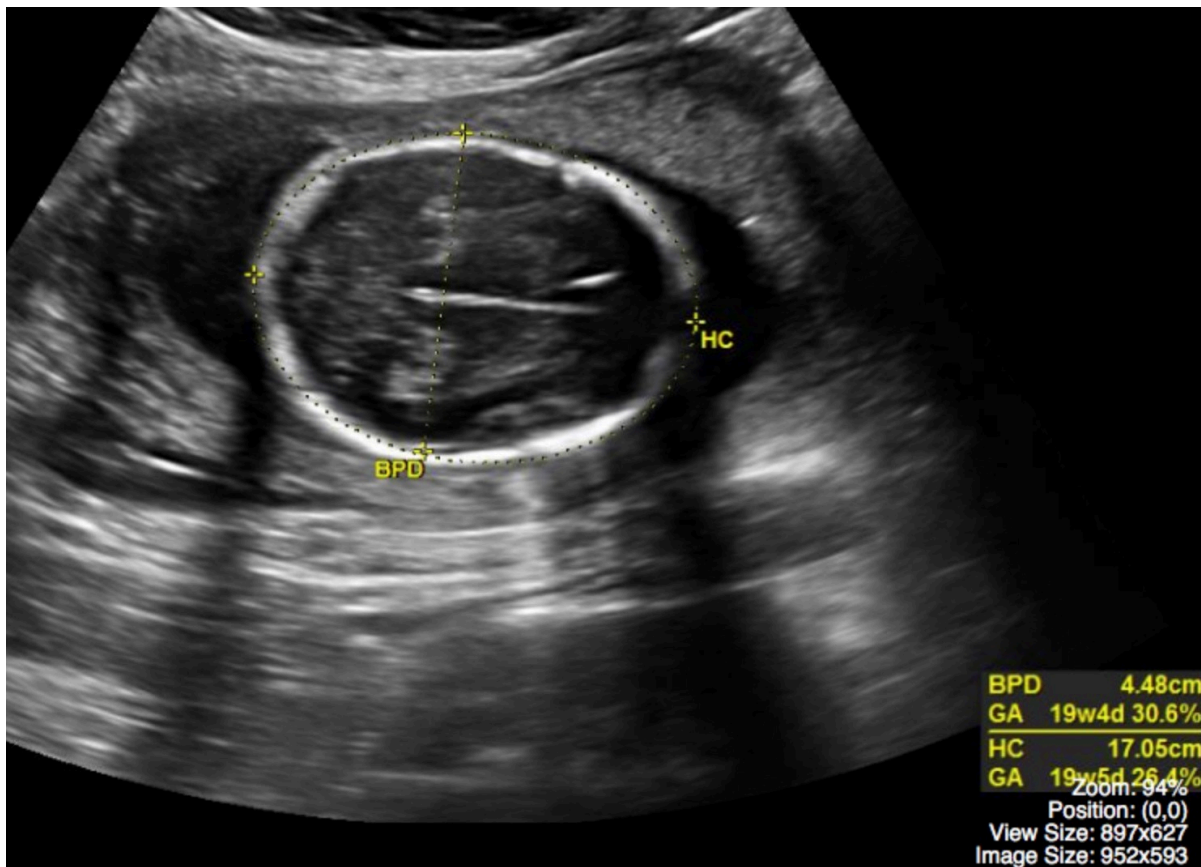


Figure 11.4A Fetal ultrasound demonstrating head circumference measurements

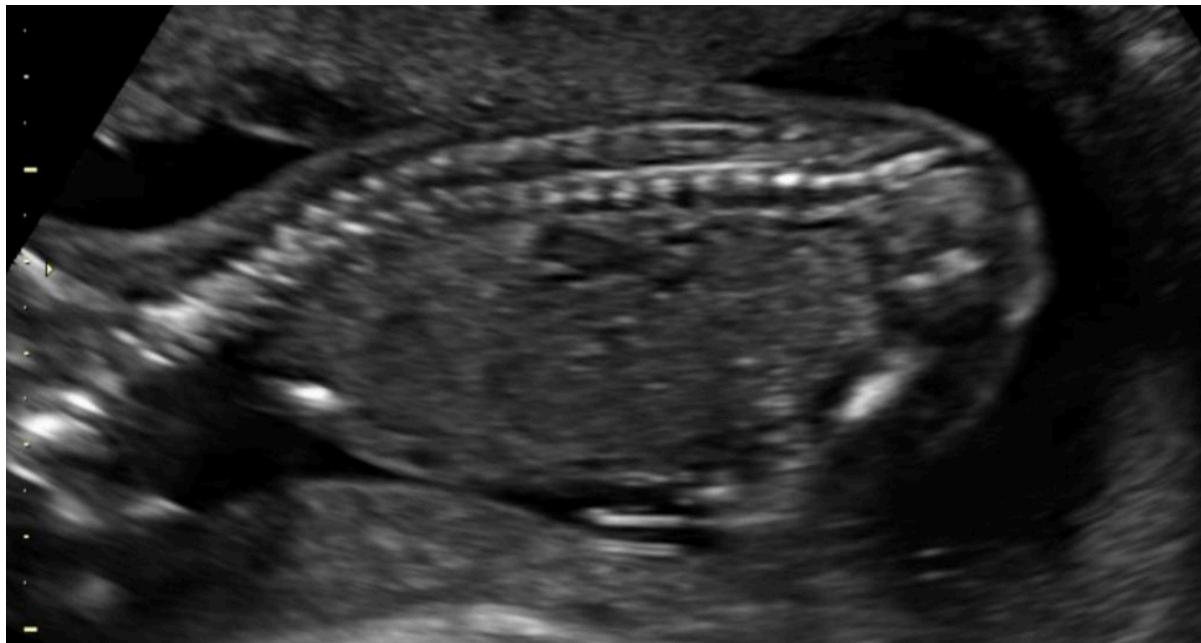


Figure 11.4B Fetal ultrasound demonstrating the spine

Imaging Assessment**Findings:**

Single, live fetus in breech presentation. The placenta was not previa. No fetal abnormalities. The estimated gestational age by ultrasound was 19 weeks, 6 days.

Interpretation:

Normal pregnancy.

Diagnosis:

Normal Obstetrical Ultrasound – 20 weeks

Discussion:

Despite the fact that many fetal deaths occur in women without identifiable risk factors, there is no convincing evidence that routine antenatal testing, in low-risk pregnancies, improves perinatal outcome. This is true for all imaging modalities, including the Biophysical Profile (BPP), Modified Biophysical Profile (mBPP), Doppler assessment of umbilical blood flow, and functional fetal echocardiography. Although there is a paucity of data on the use of the BPP, mBPP, and cardiovascular function testing in low-risk patients, a review of 5 trials involving 14,185 women concluded the use of umbilical artery Doppler US in low-risk or unselected populations had no maternal or perinatal benefits.

Consequently, routine antenatal fetal surveillance by any imaging modality is not recommended in pregnancies at low risk for intrauterine fetal demise.

CAR Imaging Referral Guidelines:

The scan at 18 – 20 weeks is recommended for fetal anatomy. However, screening at this time has not been shown to alter perinatal mortality except where selective termination of pregnancy is applied in the presence of gross fetal abnormality and in cases where fetal therapy or direction of delivery to a high-risk center has proven useful. Ultrasound has a proven value in assessing placenta previa, intrauterine growth restriction, incompetent cervix, and fetal demise at any stage of pregnancy.

For More Information:

CAR – Referral Guidelines: Obstetrics and Gynaecology –

http://www.car.ca/uploads/standards%20guidelines/car-referralguidelines-i-en_20120918.pdf

Attributions

Figure 11.4A Fetal ultrasound demonstrating head circumference measurements by Dr. Brent Burbridge MD, FRCPC, University Medical Imaging Consultants, College of Medicine, University of Saskatchewan is used under a [CC-BY-NC-SA 4.0](#) license.

Figure 11.4B Fetal ultrasound demonstrating the spine by Dr. Brent Burbridge MD, FRCPC, University Medical Imaging Consultants, College of Medicine, University of Saskatchewan is used under a [CC-BY-NC-SA 4.0](#) license.

Ectopic Pregnancy

ACR Women's Imaging – Acute Pelvic Pain in the Reproductive Age Group

Case

Ectopic Pregnancy

Clinical:

History – This 25 year old female presented with moderate to severe pelvic pain in pregnancy. She believed that she was approximately 8 weeks pregnant.

Symptoms – Pelvic pain, no bleeding.

Physical – The left pelvis was exquisitely tender on examination. The patient was pale.

Laboratory – Mild anemia. Serum BHcG – positive.

DDx:

Pelvic Cyst

Ectopic Pregnancy

Pelvic Inflammatory Disease

Imaging Recommendation

[ACR Women's Imaging – Acute Pelvic Pain in the Reproductive Age Group](#)

Pelvic Ultrasound

ODIN Link for Ectopic Pregnancy images (Ultrasound), Figure 11.5A and B): <https://mistr.usask.ca/odin/?caseID=20160729161652687>

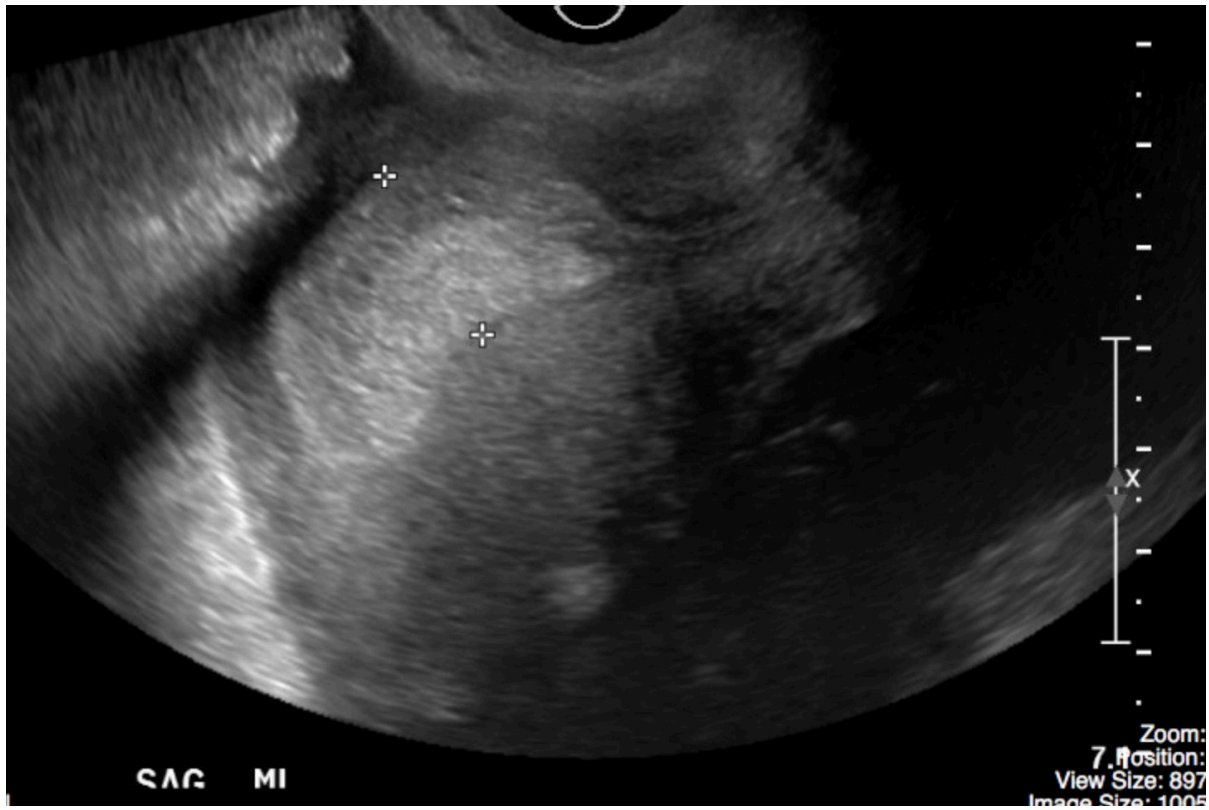


Figure 11.5A Sagittal ultrasound of female pelvis demonstrating thickened, uniformly echogenic, endometrium.

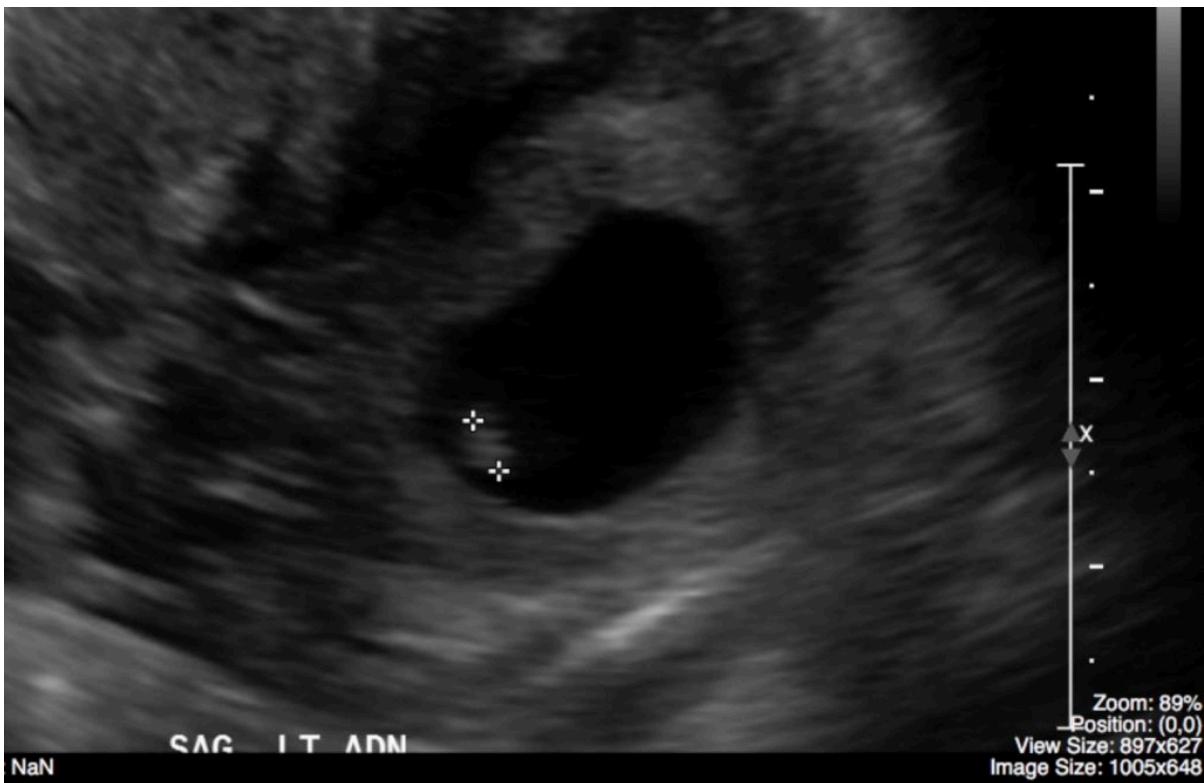

Figure 11.5B Sagittal ultrasound of left adnexal region revealing an extra-uterine gestational sac and fetal pole.

Imaging Assessment

Findings:

There was a small amount of free fluid in the pelvis. A thick endometrium was seen with no evidence of an intrauterine gestational sac.

There was a gestational sac in the region of the left adnexa. It contained a fetal pole and a yolk sac. A fetal heart beat was detected in the fetal pole.

Interpretation:

Left Adnexal Ectopic Pregnancy

Diagnosis:

Ectopic Pregnancy

Discussion:

Most often, an ectopic location is diagnosed by a combination of findings that includes the absence of an identifiable intrauterine pregnancy, often with an extrauterine, extraovarian complex cystic mass, and in which the quantitative serum human chorionic gonadotropin hormone (β -HCG) rises above the discriminatory level, at which

point a normal intrauterine pregnancy should almost always be identified. If those criteria are met, an ectopic pregnancy is presumed present.

The beta (β) subunit of HCG is specific for the hormone produced by placental tissue shortly after the implantation of a fertilized ovum in the uterus. The levels of HCG roughly double every 2 to 3 days in a normal pregnancy. At a β -HCG level more than 3,000 milli-international units per milliliter (mIU/mL), a normal intrauterine pregnancy should be visible with transvaginal US. If not, the current recommendation calls for a repeat β -HCG test and US before undertaking treatment for ectopic pregnancy. Serial β -HCG determinations may help in differentiating an ectopic pregnancy from an early abortion, both of which may display similar sonographic findings. Patients with an early abortion will display falling β -HCG levels on serial serum studies, whereas these levels will rise in ectopic pregnancies, though usually more slowly than in normal intrauterine pregnancies.

An ectopic pregnancy is also presumed present when there are large amounts of free fluid (blood) inside the abdominal cavity. Small amounts of free fluid can develop for other reasons, such as spontaneous abortion, ruptured ovarian cysts, and normal ovulation.

Attributions

Figure 11.5A Sagittal ultrasound of female pelvis demonstrating thickened, uniformly echogenic, endometrium by Dr. Brent Burbridge MD, FRCPC, University Medical Imaging Consultants, College of Medicine, University of Saskatchewan is used under a [CC-BY-NC-SA 4.0](#) license.

Figure 11.5B Sagittal ultrasound of left uterine adnexal region revealing an extra-uterine gestational sac and fetal pole by Dr. Brent Burbridge MD, FRCPC, University Medical Imaging Consultants, College of Medicine, University of Saskatchewan is used under a [CC-BY-NC-SA 4.0](#) license.

Placenta Previa

ACR Women's Imaging – Second and Third Trimester Vaginal Bleeding

Case

Placenta Previa – Posterior

Clinical:

History – This pregnant patient reported sporadic, small amounts of blood per vagina for 2 days.

Symptoms – Nil

Physical – Normal.

DDx:

Incompetent Cervix

Vaginitis

Placenta Previa

Ectopic Pregnancy

Imaging Recommendation

[ACR Women's Imaging – Second and Third Trimester Vaginal Bleeding, Variant 1](#)

Obstetrical Ultrasound

ODIN Link for Placenta Previa images (Ultrasound), Figure 11.6A and B: <https://mistr.usask.ca/>

<odin/?caseID=20170126224802586>

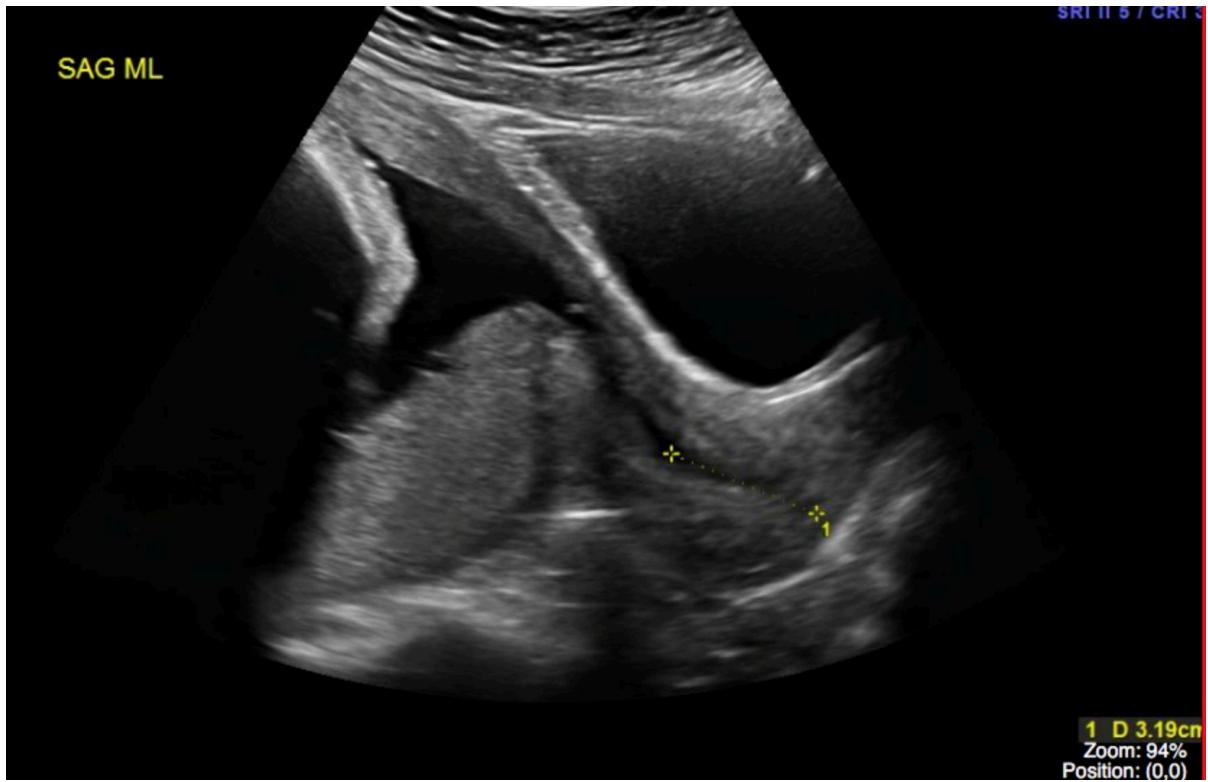


Figure 11.6A Sagittal midline ultrasound of the cervix and placenta.

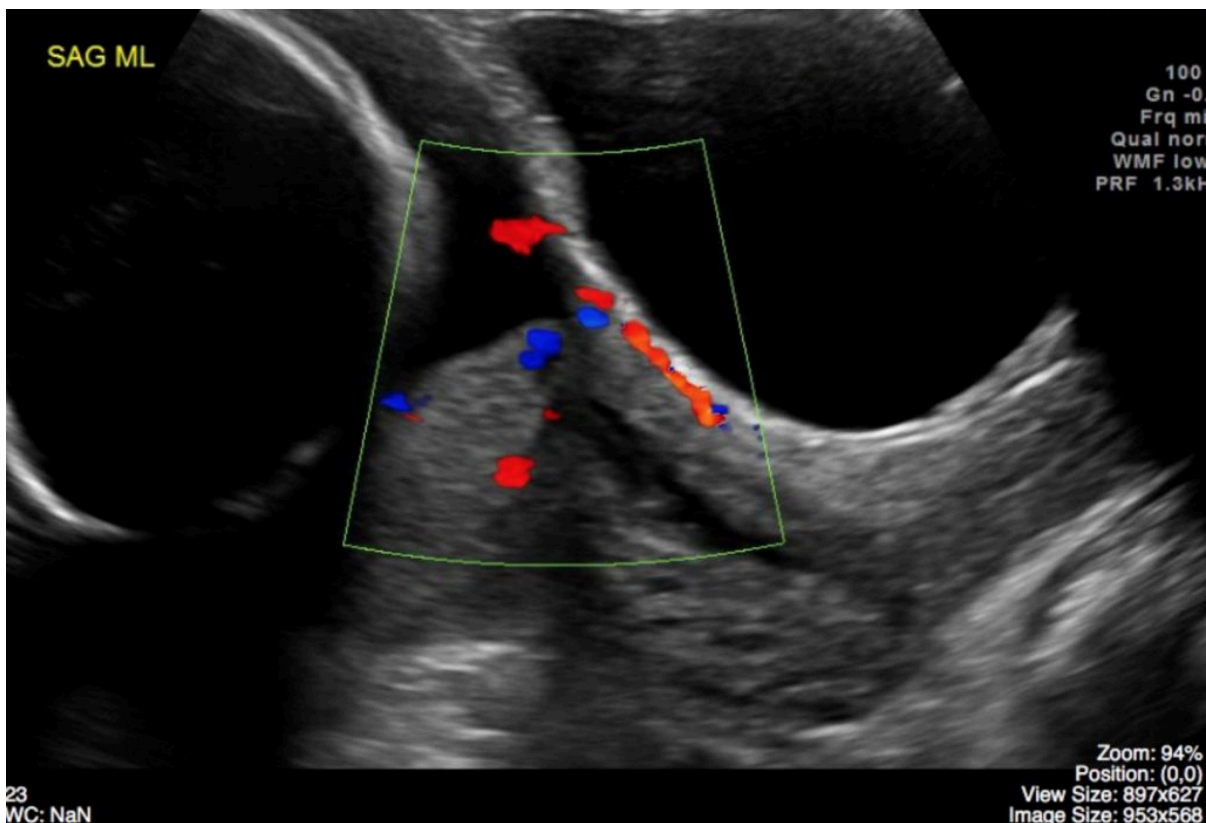


Figure 11.6B Sagittal midline doppler ultrasound of the cervix and placenta in a pregnant patient.

Imaging Assessment

Findings:

A single liver fetus was seen in cephalic presentation. The placenta was posterior and previa. Normal otherwise. The cervix measured 3.2 cm in length. Estimated Gestational Age by US – 30 weeks.

Interpretation:

Posterior Placenta Previa

Diagnosis:

Placenta Previa – Posterior

Discussion:

The underlying cause of placenta previa is unknown. There is a clear association between placental implantation in the lower uterine segment and prior endometrial damage and uterine scarring from curettage, surgery (cesarean delivery), prior placenta previa, or multiple prior pregnancies.

At least 90% of placentas identified as being “low lying” in early pregnancy ultimately resolve by the third trimester. The term “placental migration” is widely used to describe this phenomenon. The placenta clearly does

not move, rather, it is likely that the placenta grows toward the better blood supply at the fundus (a process known as trophotropism), leaving the distal portions of the placenta, closer to the relatively poor blood supply of the lower segment, to regress and atrophy. As the uterus grows and expands to accommodate the developing fetus, there is differential growth of the lower segment, and this may further increase the distance between the lower edge of the placenta and the cervix.

Bleeding from placenta previa may occur before labor as a result of development of the lower uterine segment and effacement of the cervix with advancing gestation. Pre-labor uterine contractions may also produce bleeding, as may intercourse or injudicious vaginal examination. Once labor begins, significant bleeding will occur as the cervix dilates and the placenta is forced to separate from the underlying decidua.

Attributions

Figure 11.6A Sagittal midline ultrasound of the cervix and placenta by Dr. Brent Burbridge MD, FRCPC, University Medical Imaging Consultants, College of Medicine, University of Saskatchewan is used under a [CC-BY-NC-SA 4.0](#) license.

Figure 11.6B Sagittal midline doppler ultrasound of the cervix and placenta in a pregnant patient by Dr. Brent Burbridge MD, FRCPC, University Medical Imaging Consultants, College of Medicine, University of Saskatchewan is used under a [CC-BY-NC-SA 4.0](#) license.

Gynecology and Obstetrics – References

- 1) Robert D. Harris, MD, MPH; Marcia C. Javitt, MD; Phyllis Glanc, MD, et al. ACR Appropriateness Criteria® – Women’s Imaging – Clinically Suspected Adnexal/Pelvic Mass/Uterus. Available at <https://acsearch.acr.org/docs/69466/Narrative/> American College of Radiology. Accessed June 30, 2017.
- 2) Lynn Simpson, MD; Sandeep Prakash Deshmukh, MD; Kika M. Dudiak, MD, et al. ACR Appropriateness Criteria® Women’s Imaging – Assessment of Fetal Well-Being. Available at <https://acsearch.acr.org/docs/3094108/Narrative/> American College of Radiology. Accessed June 30, 2017.
- 3) CAR Guidelines, Obstetrical Imaging. <http://www.car.ca/en/standards-guidelines/guidelines.aspx> Accessed June 30, 2017.
- 4) Ann E. Podrasky, MD; Marcia C. Javitt, MD; Phyllis Glanc, MD, et al. ACR Appropriateness Criteria® Women’s Imaging – Second and Third Trimester Bleeding. Available at <https://acsearch.acr.org/docs/69465/Narrative/> American College of Radiology. Accessed June 30, 2017.

Chapter 12 – Head and Neck

Thyroid – Palpable Nodule

Case

Thyroid, Palpable Nodule, Benign Follicular Nodule

Clinical:

History – This 55 year old female presented for an annual physical.

Symptoms – None.

Physical – Neck examination detected a hard nodule in the right thyroid lobe. The thyroid gland was not enlarged.

DDx:

Thyroid Cyst

Thyroid Nodule

Adenopathy

Parathyroid Nodule

Imaging Recommendation

Palpable Thyroid Nodule

Thyroid Ultrasound

ODIN Link for Thyroid Nodule images (Ultrasound), Figure 12.1A and B: <https://mistr.usask.ca/odin/?caseID=20161101145508526>

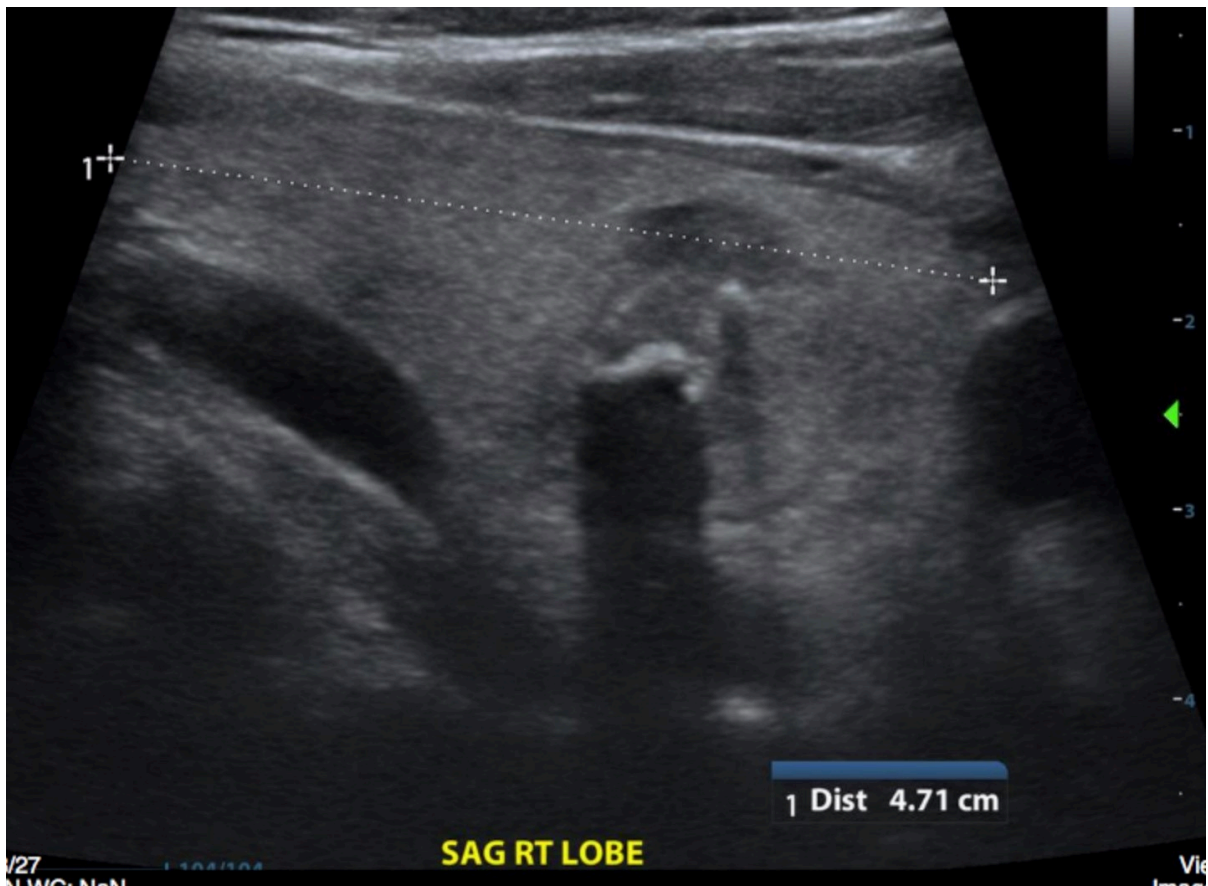

Figure 12.1A Sagittal Right Lobe Ultrasound of Thyroid

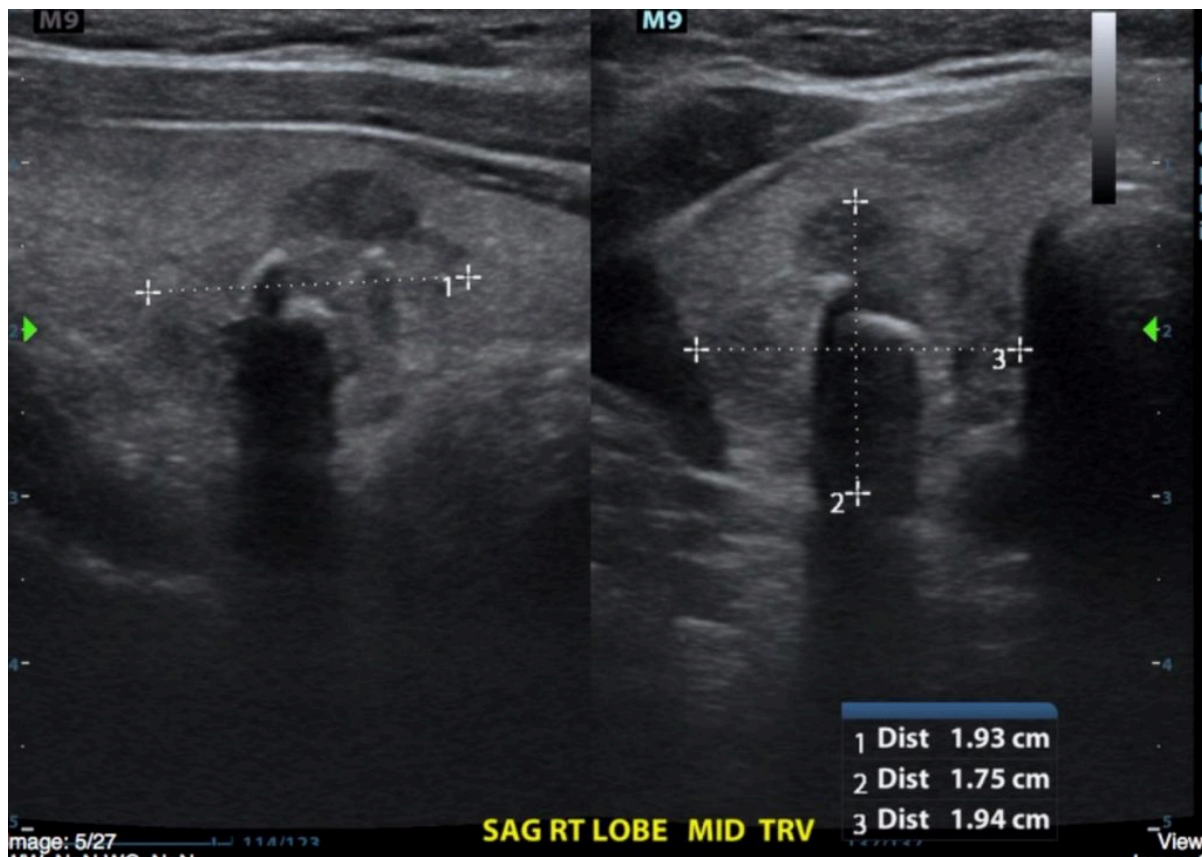


Figure 12.1B Sagittal Right Lobe Ultrasound of Thyroid

Imaging Assessment

Findings:

There was a mixed echogenicity nodule in the right thyroid lobe with at least two foci of very dense calcification. There was minimally increased Doppler signal in this nodule. The nodule measures 1.9 x 1.7 x 1.9 cm. No other obvious nodes or nodules.

Interpretation:

Benign appearing right thyroid nodule.

Diagnosis:

Benign Follicular Nodule

Discussion:

The risk factors associated with an increased likelihood of a malignancy in thyroid nodules include:

- A previous history of irradiation
- A family history of medullary thyroid carcinoma or multiple endocrine neoplasia (MEN) type II,

- Patients younger than 20 years or older than 60 years
- Male patients
- Rapid growth of a nodule
- A nodule with a rim and hard consistency
- An inconspicuous margin of the nodule on palpation
- The presence of enlarged cervical lymph nodes.

Among the modern imaging modalities, high-resolution US is the most sensitive diagnostic modality for the detection of thyroid abnormalities and it is necessary to perform US for the nodules found after palpation. In addition, US can guide FNA for thyroid nodules and it can diagnose lymph node metastasis.

In order to image and describe thyroid abnormalities on ultrasound in a more scientific and logical manner the ACR has established a, “Thyroid Imaging Reporting and Data System – TI-RADS.” One of the important elements of this strategy is to create a lexicon that communicates the relative risk of malignancy for a thyroid nodule based upon objective descriptors and agreed upon ultrasound criteria.

A detailed discussion of the scoring system and nodule risk stratification can be found at the ACR TI-RADS Atlas. This atlas provides detailed examples of nodule imaging features and a methodology for risk of malignancy scoring.

[ACR TI-RADS Atlas](#)

There is no consensus in the literature regarding optimal spacing of follow-up sonograms for nodules that do not meet the criteria for FNA, as growth rates do not reliably distinguish benign from malignant nodules. Scanning intervals of less than 1 year are not warranted, except for proven cancers under active surveillance, that are imaged at the discretion of the referring physician. Follow-up imaging timing should be on the basis of a nodule’s ACR, TI-RADS score.

For More Information:

ACR – Thyroid Imaging Reporting and Data System (TI-RADS) – <https://www.acr.org/Quality-Safety/Resources/TIRADS>

Attributions

Figure 12.1A Sagittal Right Lobe Ultrasound of Thyroid by Dr. Brent Burbridge MD, FRCPC, University Medical Imaging Consultants, College of Medicine, University of Saskatchewan is used under a [CC-BY-NC-SA 4.0](#) license.

Figure 12.1B Transverse Right Lobe Ultrasound of Thyroid by Dr. Brent Burbridge MD, FRCPC, University

Medical Imaging Consultants, College of Medicine, University of Saskatchewan is used under a [CC-BY-NC-SA 4.0](#) license.

Facial Trauma

Case 1

Orbit Fracture

Clinical:

History – This child was struck in the left face by a soccer ball. She had left face pain and swelling.

Symptoms – The left eye was swollen shut.

Physical – No orbital globe injuries. Ocular movements were normal. No visual disturbance. The inferior orbital rim bone was tender.

DDx:

Facial bone fracture

Orbital Blow-out fracture

Maxillary sinus fracture

Imaging Recommendation

X-rays

Followed by CT if abnormal x-rays or abnormal eye muscle function.

ODIN Link for Orbital Tear Drop Fracture images (X-rays and CT), Figure 12.2A and B:
<https://mistr.usask.ca/odin/?caseID=20170404110143590>

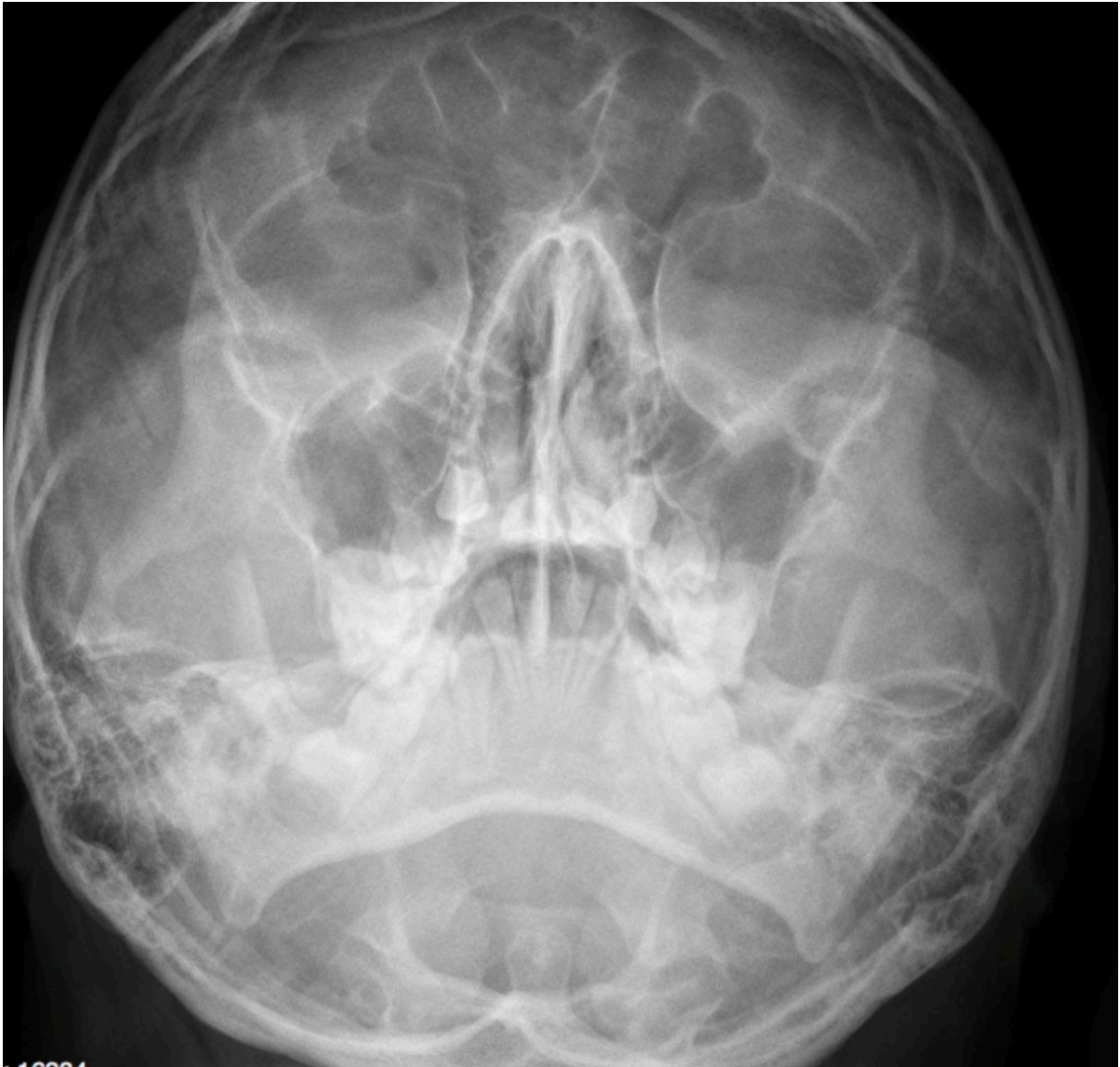


Figure 12.2A Orbital x-ray, Water's view, demonstrating a teardrop opacity in the apex of the left maxillary antrum.

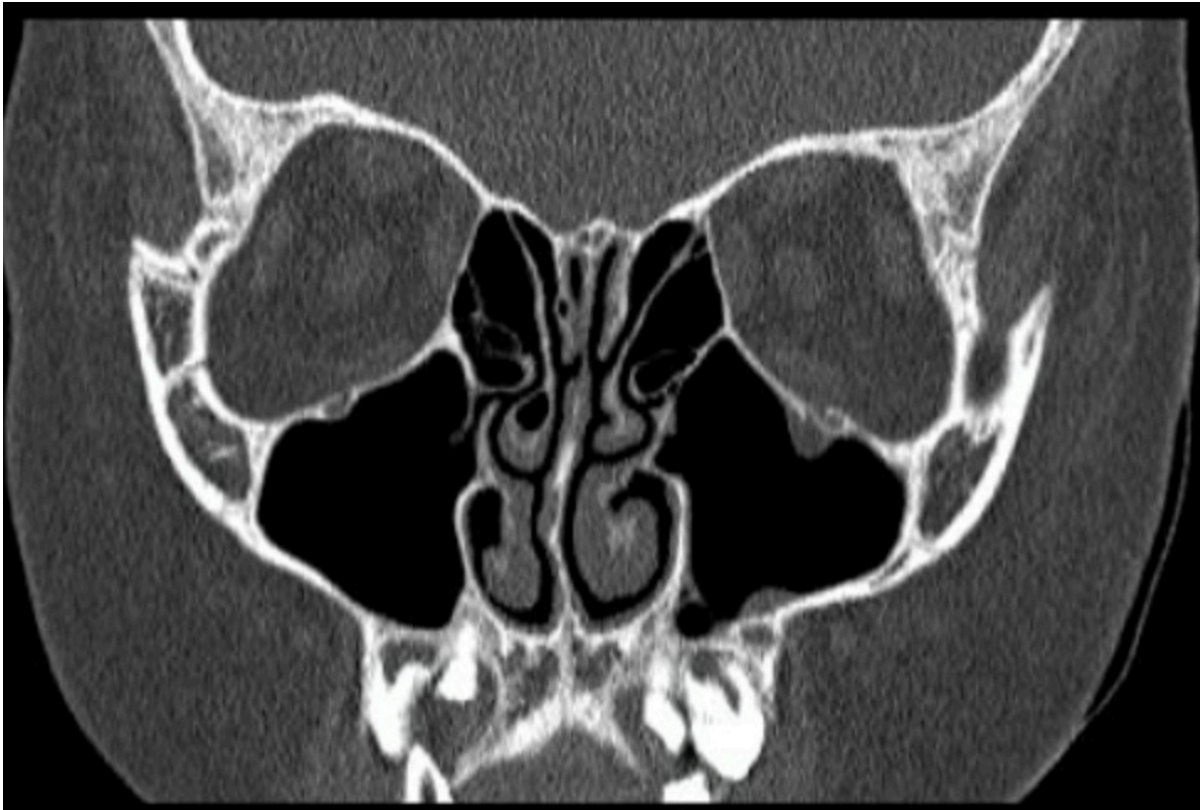


Figure 12.2B CT Scan of the orbits with a teardrop opacity in the apex of the left maxillary antrum.

Imaging Assessment

X-ray Findings:

In the apex of the left maxillary antrum there was a very small, teardrop shaped, soft tissue, opacity. This opacity was only seen on the Water's view. This was suggestive of injury of the apex of the maxillary antrum/floor of orbit. No obvious fractures seen.

Interpretation:

Possible floor of orbit fracture. CT of the orbits was recommended.

CT Findings:

There was a depressed fracture of the floor of the left orbit/apex of the left maxillary sinus. This allowed a small amount of orbital fat to herniate through the bone defect. The ocular muscles were not herniating through the fracture. No hematoma or globe injury.

Diagnosis:

Teardrop Inferior Orbit – Left Floor of orbit fracture.

Discussion:

CT is the imaging study of choice for evaluating facial fractures. Multislice scanners allow for digital reconstruction in the sagittal and coronal planes so that the patient does not have to be repositioned in the scanner.

The most common orbital fracture is the blow-out fracture which is produced by a direct impact on the orbit (e.g., a baseball strikes the eye) and causes a sudden increase in intraorbital pressure leading to a fracture of the inferior orbital floor (into the maxillary sinus) or the medial wall of the orbit (into the ethmoid sinus). Sometimes the inferior rectus muscle can be trapped in the fracture, leading to restriction of upward gaze and diplopia.

Imaging findings of a blow-out fracture of the orbit may include:

- Orbital emphysema. Air in the orbit from communication with one of the adjacent air-containing, ethmoid, or maxillary sinus.
- Fracture through either the medial wall or floor of the orbit.
- Entrapment of fat and/or extraocular muscle, which projects downward as a soft tissue mass into the top of the maxillary sinus.
- Fluid (blood), causing an air – fluid level in the maxillary sinus.

Case 2

Complex Facial Fractures

Clinical:

History – This 25 year old male was kicked in the left face by a horse.

Symptoms – Pain in left face.

Physical – The face was swollen and painful. The mid-face was mobile on physical examination.

DDx:

Severe, Complex, Facial Bone Fractures

Imaging Recommendation

CT of the facial bones

ODIN Link for Complex Facial Fracture images (Drawings and CT), Figure 12.3A and B:

<https://mistr.usask.ca/odin/?caseID=20170307214205636>

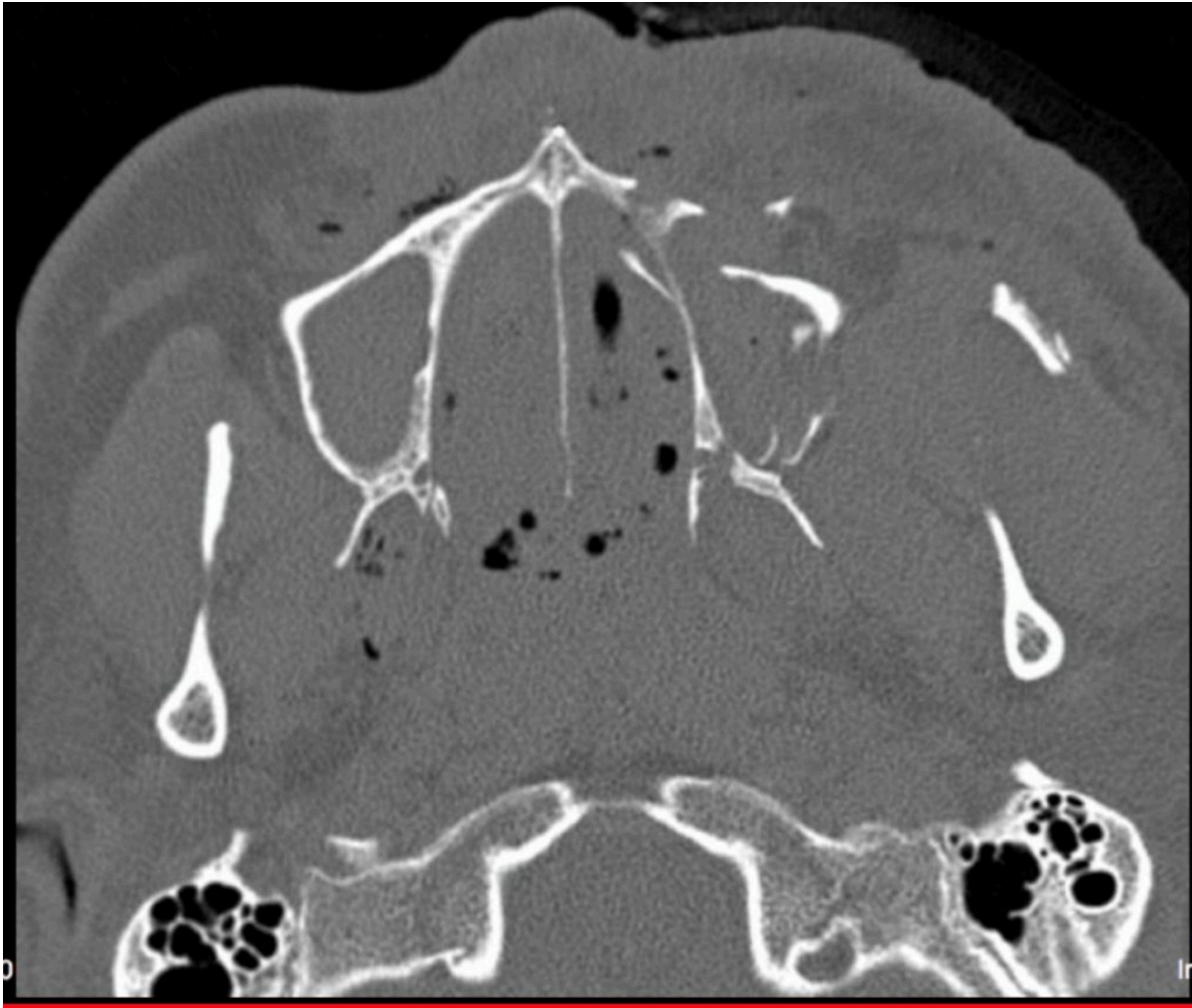

Figure 12.3A CT Scan of the Orbits and Facial region.

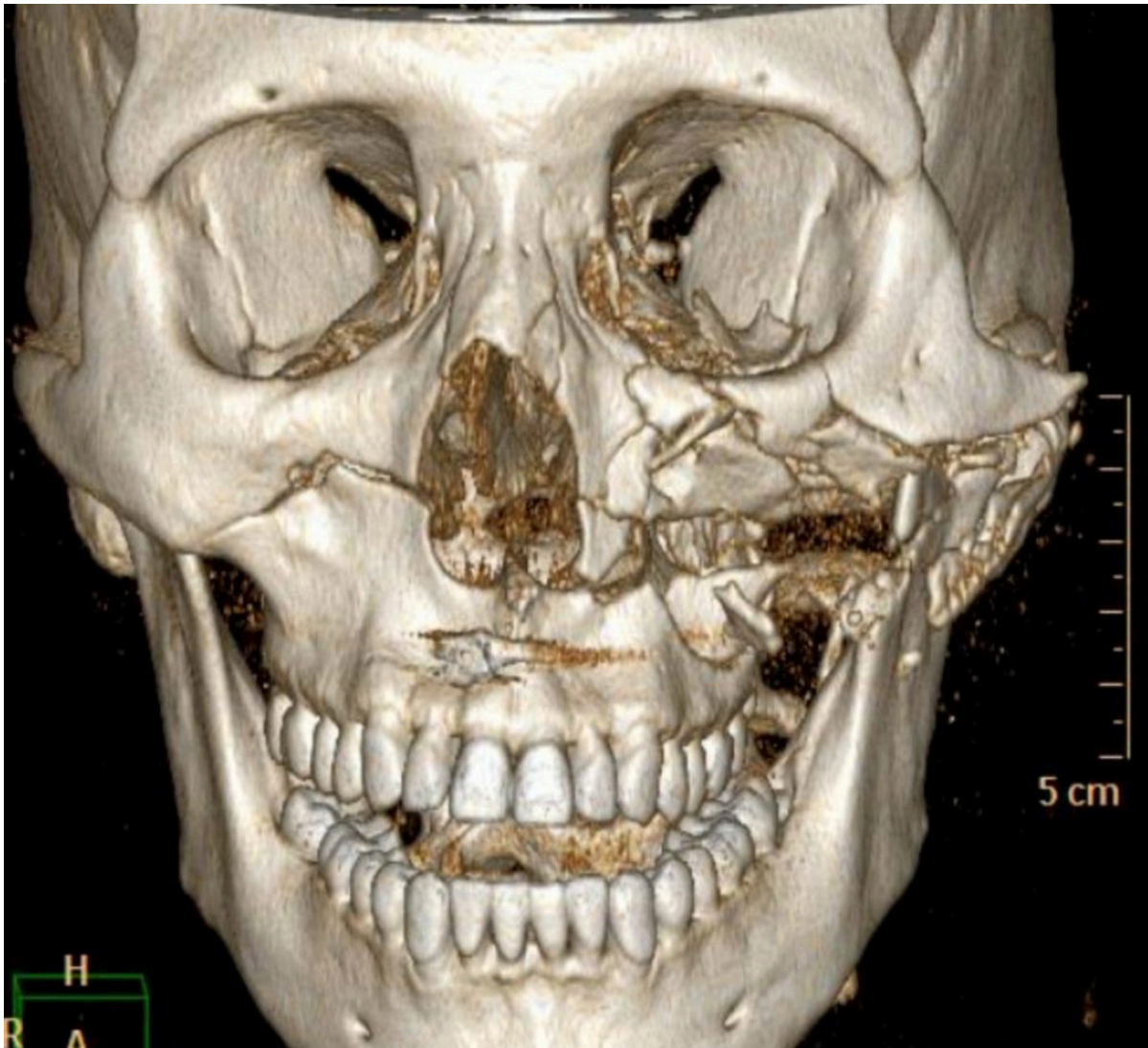


Figure 12.3B CT Scan 3D Rendering of Facial Bones

Imaging Assessment

Findings:

The left facial bones were pulverized including the maxillary bone, the zygoma, and the lateral wall of the orbit. This was a LeFort fracture type 3.

On the right side there is a LeFort fracture, type 2. Orbital contents were not herniating into the maxillary antrum. There was gas in the orbital space bilaterally.

Interpretation:

Complex Facial Bone Fractures.

Diagnosis:

Discussion:

CT is the imaging study of choice for evaluating facial fractures. Multislice scanners allow for digital reconstruction in the sagittal and coronal planes so that the patient does not have to be repositioned in the scanner.

Le Fort Facial Bone Fractures

Le Fort I fracture (horizontal), otherwise known as a floating palate, may result from a force of injury directed low on the maxillary alveolar rim, or upper dental row, in a downward direction. The key component of these fractures, in addition to pterygoid plate involvement, is involvement of the lateral bony margin of the nasal opening. They also involve the medial and lateral buttresses, or walls, of the maxillary sinus, traveling through the face just above the alveolar ridge of the upper dental row. At the midline, the inferior nasal septum is involved.

Le Fort II fracture (pyramidal) may result from a blow to the lower or mid maxilla. The key component of these fractures beyond the pterygoid plate fractures is involvement of inferior orbital rim. When viewed from the front, the fracture is classically shaped like a pyramid. It extends from the nasal bridge at or below the nasofrontal suture through the superior medial wall of the maxilla, inferolaterally through the lacrimal bones which contain the tear ducts, and inferior orbital floor through or near the infraorbital foramen.

Le Fort III fracture (transverse), otherwise known as craniofacial dissociation, may follow impact to the nasal bridge or upper maxilla. The salient feature of these fractures, beyond pterygoid plate involvement, is that they invariably involve the zygomatic arch, or cheek bone. These fractures begin at the nasofrontal and frontomaxillary sutures and extend posteriorly along the medial wall of the orbit, through the nasolacrimal groove and ethmoid air cells. The sphenoid is thickened posteriorly, limiting fracture extension into the optic canal. Instead, the fracture continues along the orbital floor and infraorbital fissure, continuing through the lateral orbital wall to the zygomaticofrontal junction and zygomatic arch. Within the nose, the fracture extends through the base of the perpendicular plate of the ethmoid air cells, the vomer, which are both part of the nasal septum. As with the other fractures, it also involves the junction of the pterygoids with the maxillary sinuses. CSF rhinorrhea, or leakage of the nutrient laden fluid that bathes the brain, is more commonly seen with these injuries due to ethmoid air cell disruption, as the air cells are located immediately beneath the skull base.

Attributions

Figure 12.2A Orbital x-ray demonstrating a teardrop opacity in the apex of the left maxillary antrum by Dr. Brent Burbridge MD, FRCPC, University Medical Imaging Consultants, College of Medicine, University of Saskatchewan is used under a [CC-BY-NC-SA 4.0](#) license.

Figure 12.2B CT Scan of the Orbits with a teardrop opacity in the apex of the left maxillary antrum by Dr. Brent Burbridge MD, FRCPC, University Medical Imaging Consultants, College of Medicine, University of Saskatchewan is used under a [CC-BY-NC-SA 4.0](#) license.

Figure 12.3A CT Scan of the Orbits and Facial region by Dr. Brent Burbridge MD, FRCPC, University Medical Imaging Consultants, College of Medicine, University of Saskatchewan is used under a [CC-BY-NC-SA 4.0](#) license.

Figure 12.3B CT Scan 3D Rendering of Facial Bones by Dr. Brent Burbridge MD, FRCPC, University Medical Imaging Consultants, College of Medicine, University of Saskatchewan is used under a [CC-BY-NC-SA 4.0](#) license.

Sinusitis/Mastoiditis

Case 1

Sinusitis

Clinical:

History – Long-term congested sinuses and sinus pain.

Symptoms – The patient complained of bilateral maxillary sinus fullness for 8 weeks despite a course of antibiotics. She had thick, green mucus from her nose.

Physical – The maxillary antra were tender bilaterally.

DDx:

Allergic Sinusitis

Infectious Sinusitis

Nasal Polyps

Imaging Recommendation

X-rays of the Paranasal Sinuses are not usually required unless symptoms persist for longer than 4 weeks while on treatment.

CT scanning is best utilized for chronic sinusitis to rule out anatomic deformity of the sinus drainage pathways.

ODIN Link for Sinusitis images (X-rays), Figure 12.4A and B: <https://mistr.usask.ca/odin/?caseID=20170420230238974>

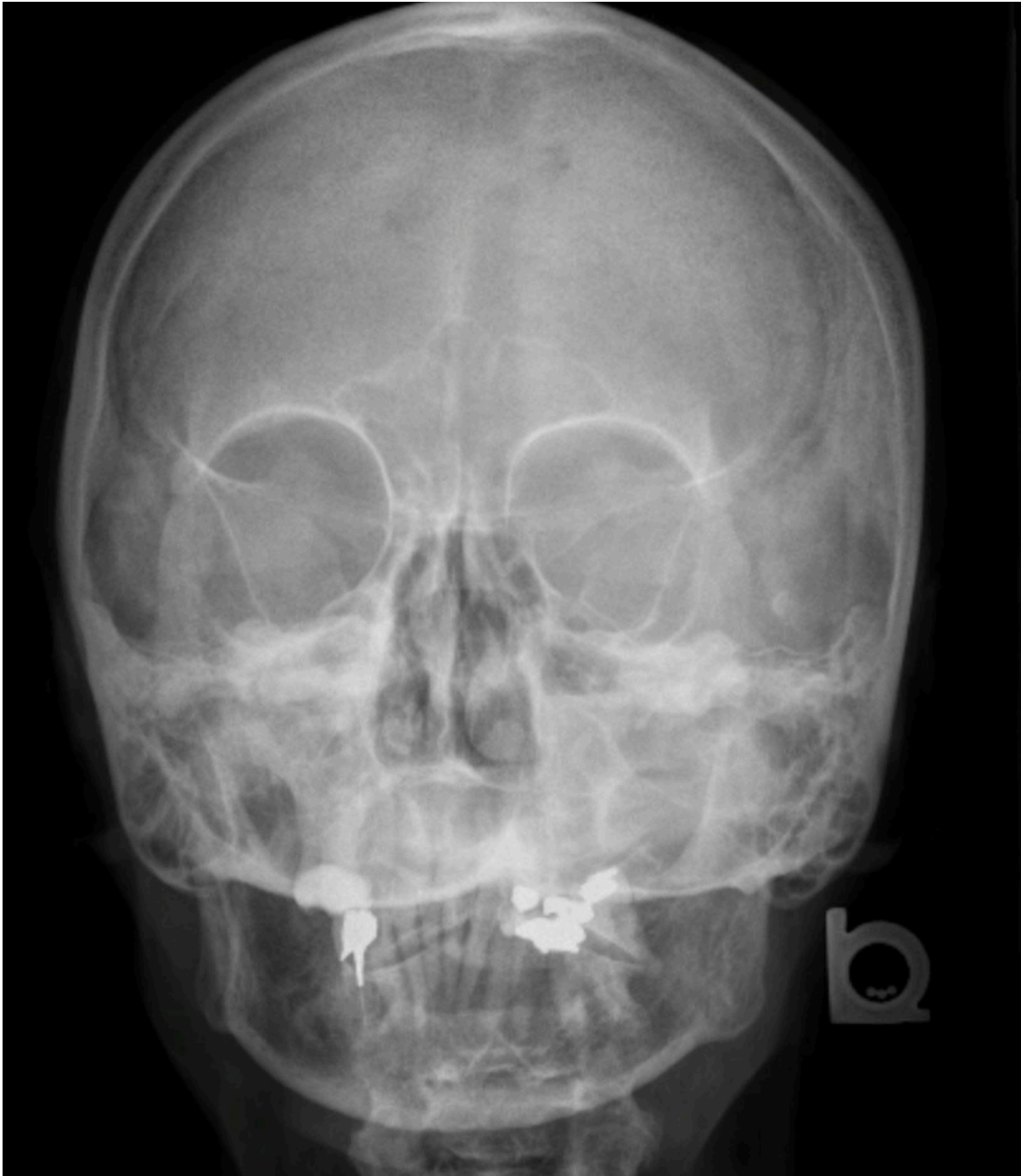

Figure 12.4A X-ray of the facial sinuses, Ap view, demonstrating opacity of the maxillary sinuses.

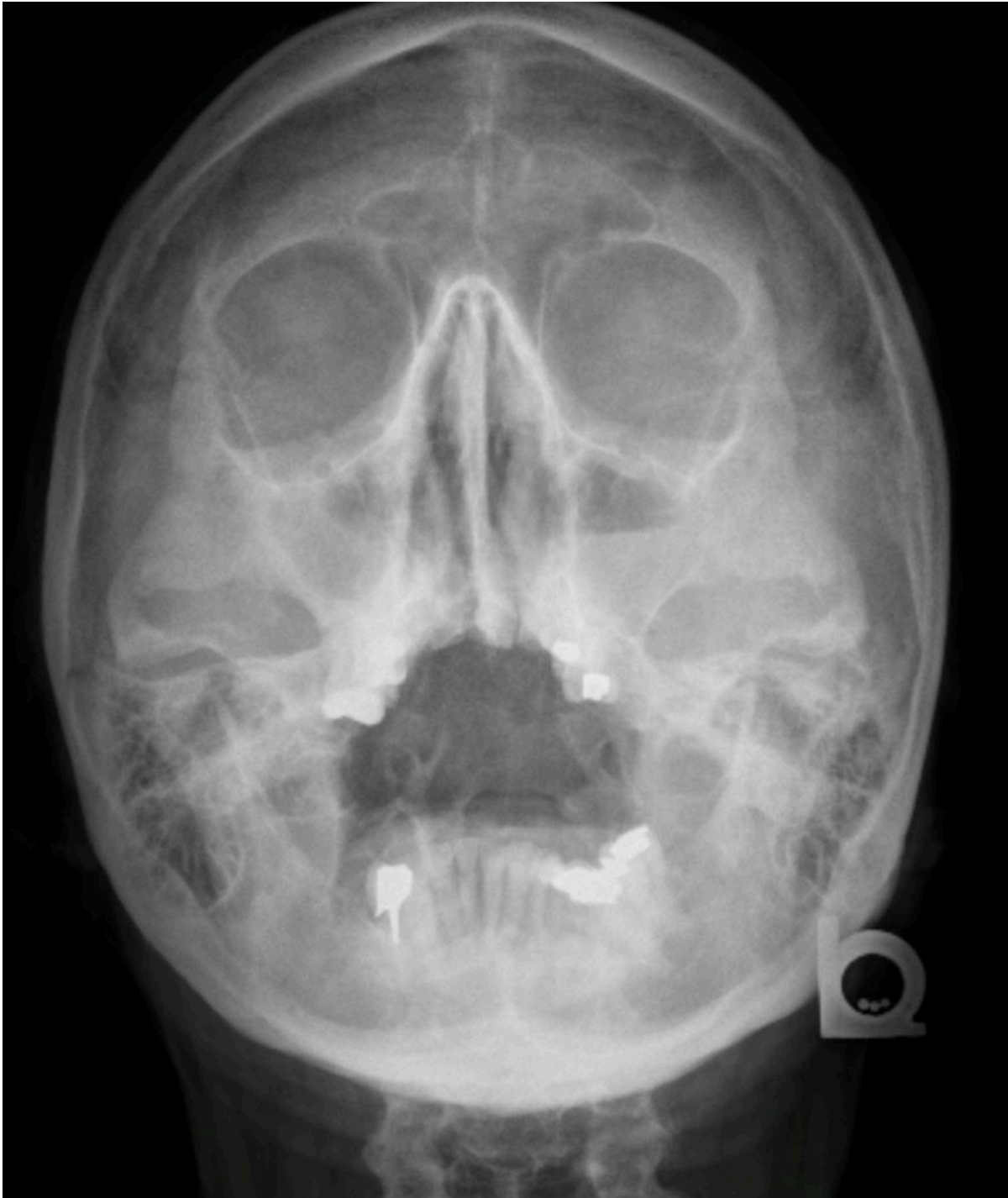

Figure 12.4B X-ray of the facial sinuses, Water's view, with maxillary opacity and a left air-fluid level.

Imaging Assessment

Findings:

The maxillary antra were opacified bilaterally. There was an air-fluid level in the left maxillary antrum. The other sinuses were clear.

Interpretation:

Allergic or infectious sinusitis.

Diagnosis:

Sinusitis

Discussion:

Each of the four paranasal sinuses is connected to the nasal cavity by narrow tubes (ostia), 1 to 3 mm in diameter; these drain directly into the nose through the turbinates. The sinuses are lined with a ciliated mucous membrane (mucoperiosteum).

Pathophysiology:

1. Acute viral infection: Infection with the common cold or influenza
2. Mucosal edema and sinus inflammation
3. Decreased drainage of thick secretions/obstruction of the sinus ostia
4. Subsequent entrapment of bacteria
5. Multiplication of bacteria
6. Secondary bacterial infection

Imaging findings may include:

- Overall, standard radiographs are of limited use in diagnosis, although negative films are strong evidence against the diagnosis.
- CT scans:
 - Much more sensitive than plain radiographs in detecting acute changes and disease in the sinuses.
 - Recommended for patients requiring surgical intervention, including sinus aspiration; it is a useful adjunct to guide therapy.

Case 2**Mastoiditis**

Clinical:

History – Recurrent otitis media, right.

Symptoms – The soft tissues behind the right ear were very painful.

Physical – The soft tissues behind the right ear were red and swollen, there was also a sense of boggy in the tissues. This area was very tender.

DDx:

Mastoiditis

Malignancy of the Mastoid region.

Cellulitis

Imaging Recommendation

CT Scan of the Skull Base and Mastoid Region

ODIN Link for Mastoiditis images, (CT), Figure 12.5A and B: <https://mistr.usask.ca/odin/?caseID=20170317225619481>

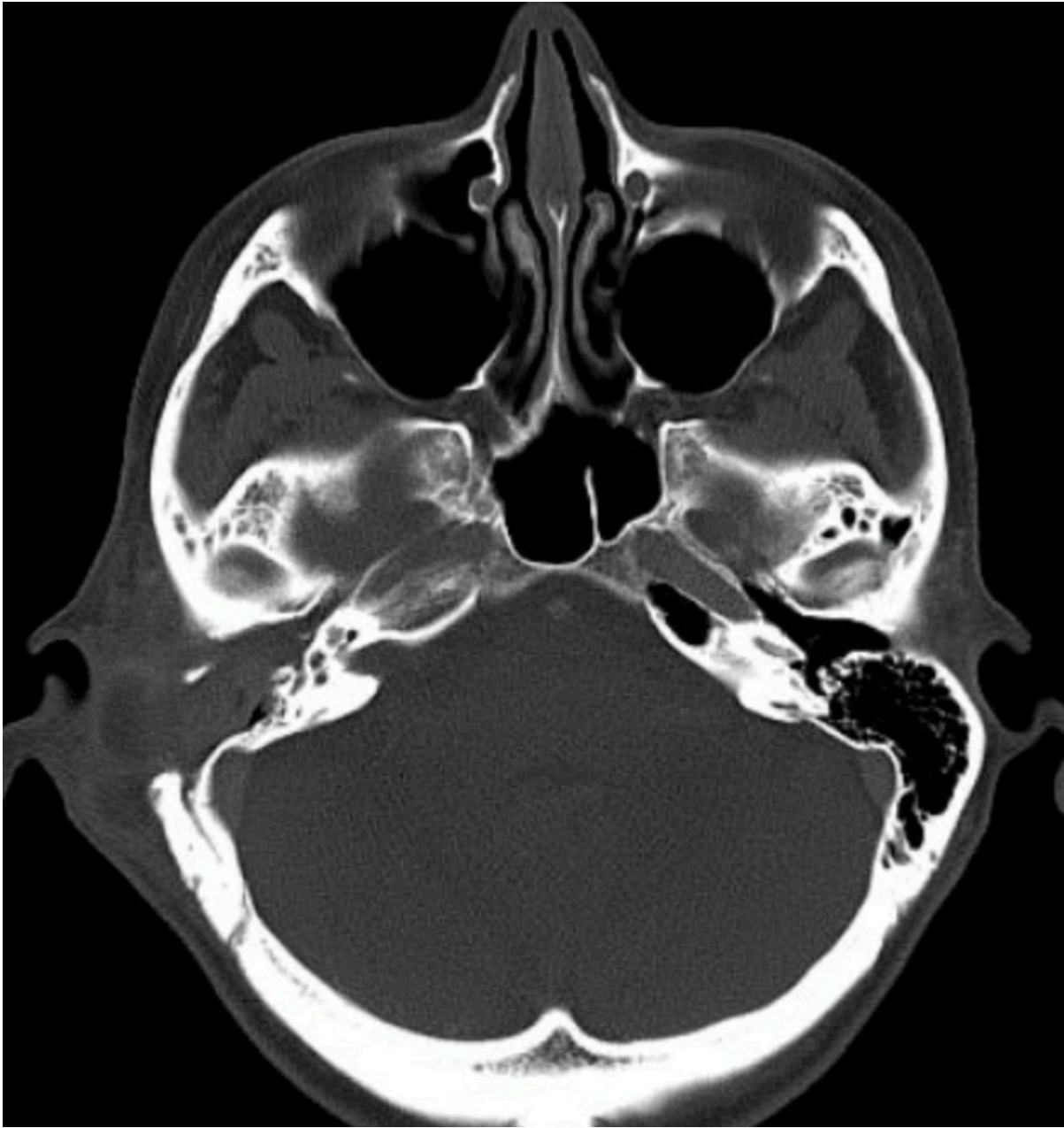

Figure 12.5A CT Scan of the head revealing mastoid air-cell opacity and skull erosion.

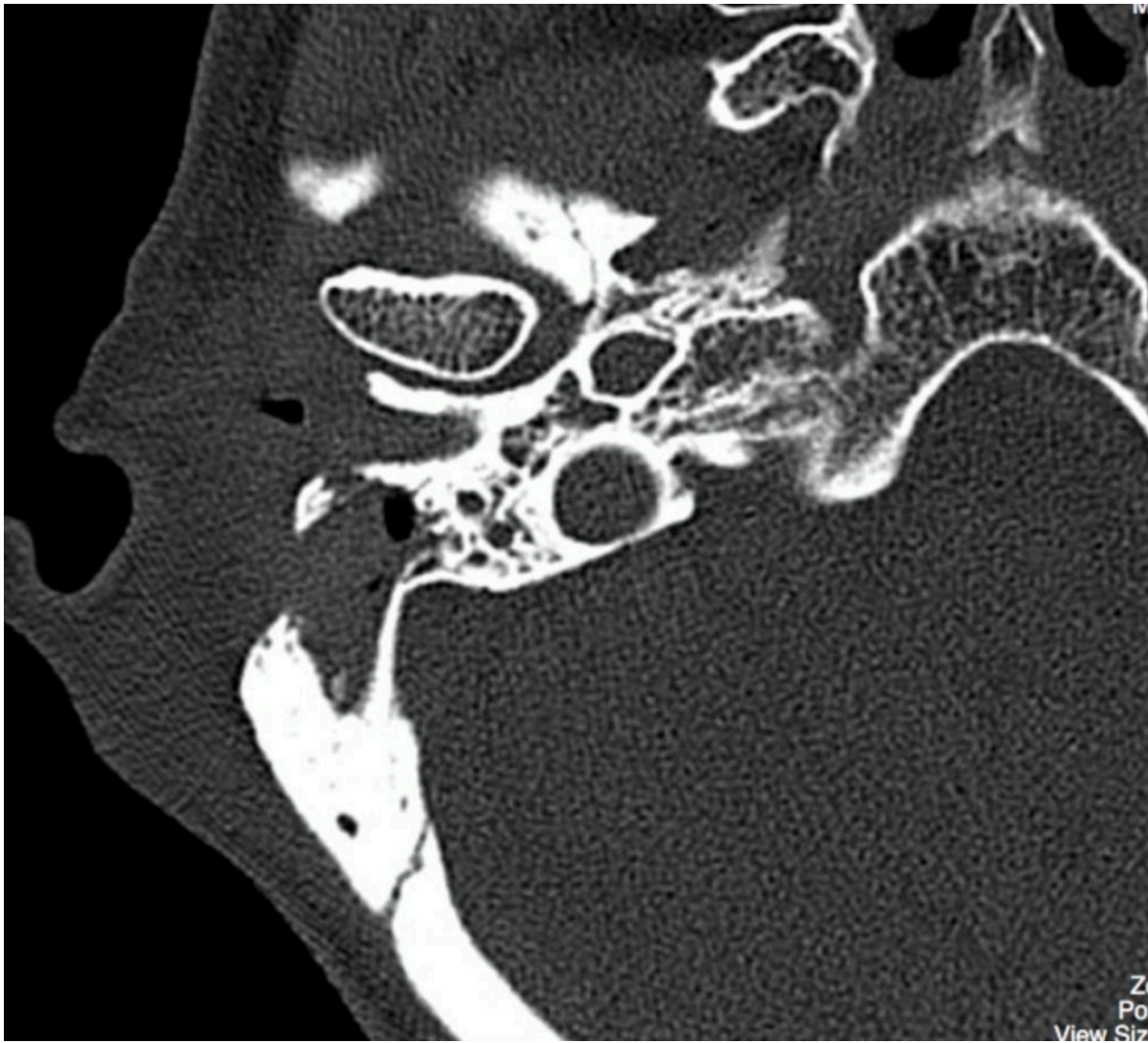

Figure 12.5B CT Scan of the Mastoid with air-cell opacity and skull erosion.

Imaging Assessment

Findings:

The aeration of the right mastoid air cells was diminished. There was destruction of the bone of the lateral aspect of the right mastoid. There was a soft tissue and fluid containing mass behind the right pinna. No intracranial or middle ear abnormalities.

Interpretation:

Mastoiditis/Abscess

Diagnosis:

Mastoiditis/Abscess

Discussion:

Mastoiditis is inflammation of the mastoid process and air cells, a complication of otitis media.

Initial hyperemia and edema of the mucosal lining of the air cells result in accumulation of purulent exudate.

Dissolution of calcium from the bone of the septa of the air cells and osteoclastic activity in the inflamed periosteum lead to bone necrosis and coalescence of air cells.

Most common bacterial isolates are:

1. Streptococcus pneumoniae
2. Streptococcus pyogenes
3. Haemophilus influenzae
4. Moraxella catarrhalis
5. Staphylococcus aureus

Imaging findings may include:

- Plain x-rays of the mastoid region may demonstrate clouding or opacification in areas of pneumatization.
- CT scan can demonstrate early involvement of bone (mastoiditis with bone destruction).
- MRI is more sensitive than CT scan in evaluating soft-tissue involvement and is useful in conjunction with CT scan to investigate other complications of mastoiditis.

Attributions

Figure 12.4A X-ray of the facial sinuses demonstrating opacity of the maxillary sinuses by Dr. Brent Burbridge MD, FRCPC, University Medical Imaging Consultants, College of Medicine, University of Saskatchewan is used under a [CC-BY-NC-SA 4.0](#) license.

Figure 12.4B X-ray of the facial sinuses with maxillary opacity and a left air-fluid level by Dr. Brent Burbridge MD, FRCPC, University Medical Imaging Consultants, College of Medicine, University of Saskatchewan is used under a [CC-BY-NC-SA 4.0](#) license.

Figure 12.5A CT Scan of the head revealing mastoid air-cell opacity and skull erosion by Dr. Brent Burbridge MD, FRCPC, University Medical Imaging Consultants, College of Medicine, University of Saskatchewan is used under a [CC-BY-NC-SA 4.0](#) license.

Figure 12.5B CT Scan of the Mastoid with air-cell opacity and skull erosion by Dr. Brent Burbridge MD, FRCPC,

University Medical Imaging Consultants, College of Medicine, University of Saskatchewan is used under a [CC-BY-NC-SA 4.0](#) license.

Retropharyngeal Abscess – Child

Case

Retropharyngeal Abscess

Clinical:

History – Acute malaise, fever, and lethargy.

Symptoms – Trouble swallowing.

Physical – Fever. The neck was tender to palpation. No masses palpable. The tonsillar fossae were reddened with no purulent exudate present. The neck was stiff and neck range of motion was painful.

Laboratory – WBC is elevated.

DDx:

Tonsillitis

Pharyngitis

Epiglottitis

Foreign Body Ingestion

Retropharyngeal abscess

Imaging Recommendation

Soft tissue x-rays of the neck

ODIN Link for Retropharyngeal Abscess images (X-ray and CT), Figure 12.6A and B:
<https://mistr.usask.ca/odin/?caseID=20161224124222245>

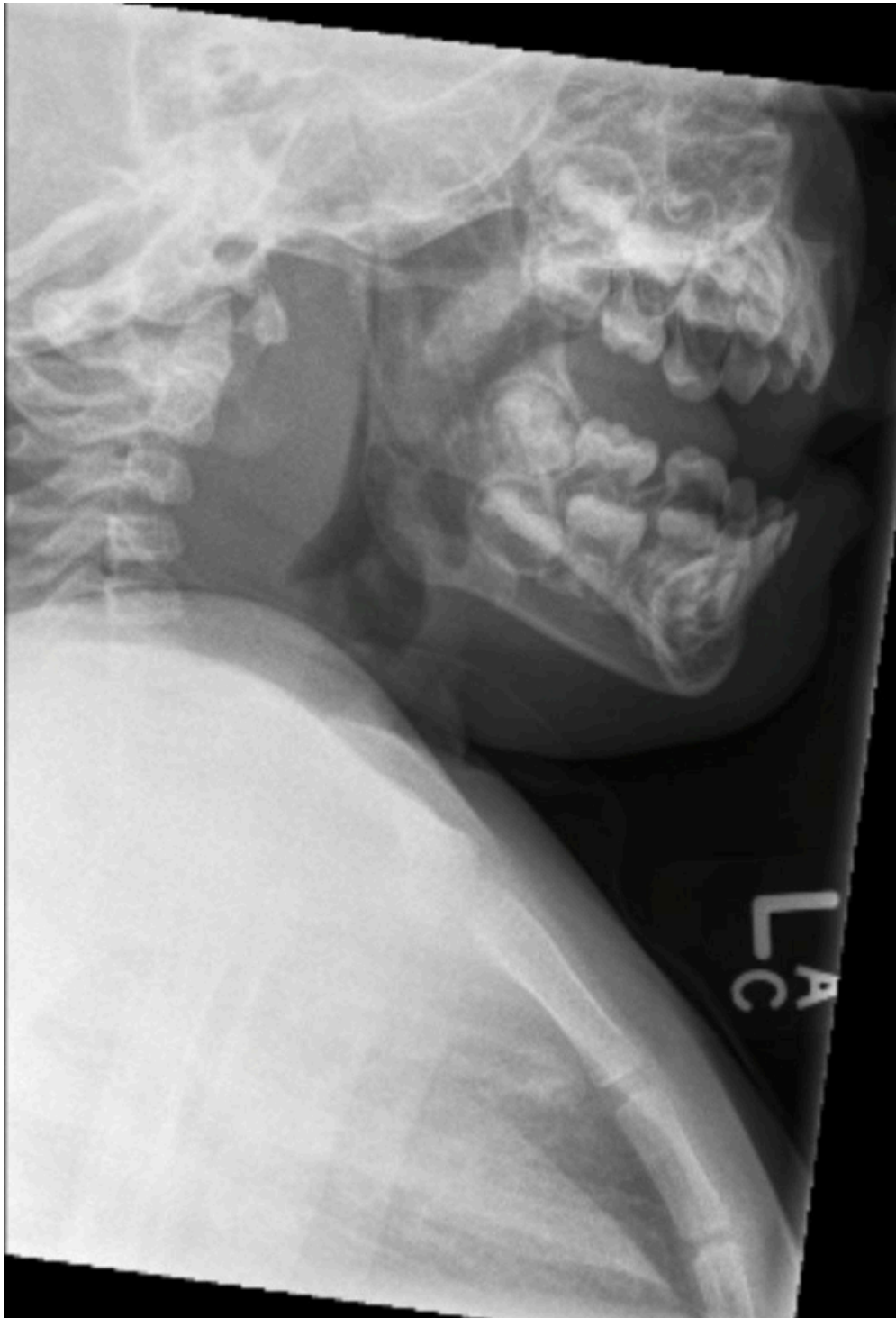


Figure 12.6A Lateral x-ray of the neck demonstrating pre-vertebral soft tissue swelling

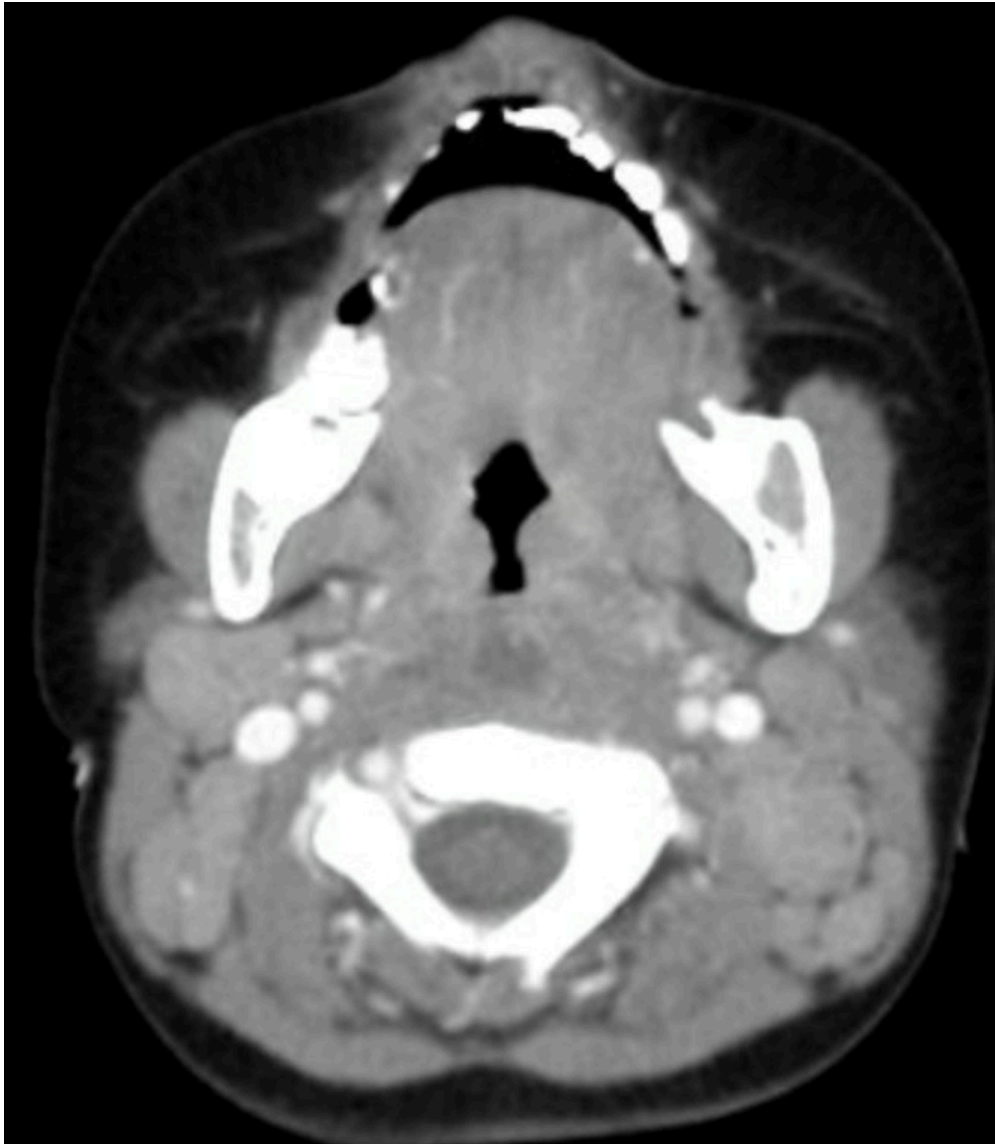

Figure 12.6B Axial CT Scan of the Head and Neck revealing a retropharyngeal abscess.

Imaging Assessment

X-Rays:

Findings:

The pre-vertebral soft tissues were massively, uniformly swollen.

Interpretation:

Probable pre-vertebral/retropharyngeal abscess. Emergent CT was recommended.

Computed Tomography:

Findings:

Images were acquired with intravenous contrast. The pre-vertebral soft tissues were thickened. There was a central low density area in the thickened tissue. This low density area demonstrated rim enhancement with intravenous contrast. There was scalloping of the wall of the low density tissue.

Interpretation:

Retropharyngeal abscess.

Diagnosis:

Retropharyngeal abscess.

Discussion:

Retropharyngeal and lateral pharyngeal infections are most often polymicrobial; the usual pathogens include group A streptococcus, oropharyngeal anaerobic bacteria, and Staphylococcus aureus. In children younger than age 2 yrs., there has been an increase in the incidence of retropharyngeal abscess, particularly with S. aureus, including methicillin-resistant strains. Mediastinitis may be identified on CT in some of these patients. Other pathogens can include Haemophilus influenzae, Klebsiella, and Mycobacterium avium-intracellulare.

Imaging findings include:

- Soft-tissue neck films taken during inspiration with the neck extended might show increased width of the pre-vertebral soft tissue and/or an air–fluid level in the retropharyngeal space.
- CT with contrast medium enhancement can reveal central lucency, ring enhancement, or scalloping of the walls of a lymph node.
- Scalloping of the wall of a lymph node or of the fluid containing space, is thought to be a late finding and predicts abscess formation.

Attributions

Figure 12.6A Lateral x-ray of the neck demonstrating pre-vertebral soft tissue swelling by Dr. Brent Burbridge MD, FRCPC, University Medical Imaging Consultants, College of Medicine, University of Saskatchewan is used under a [CC-BY-NC-SA 4.0](#) license.

Figure 12.6B Axial CT Scan of the Head and Neck revealing a retropharyngeal abscess by Dr. Brent Burbridge MD, FRCPC, University Medical Imaging Consultants, College of Medicine, University of Saskatchewan is used under a [CC-BY-NC-SA 4.0](#) license.

Epiglottitis – Child

Case

Epiglottitis

Clinical:

History – Sore throat and drooling.

Symptoms– This 5 year old reported severely sore throat and difficulty swallowing.

Physical– The child was sitting up on the stretcher drooling and was showing signs of mild respiratory distress with inspiratory stridor and grunting. Fever, with temperature of 40.5C.

DDx:

Tonsillitis

Pharyngitis

Epiglottitis

Imaging Recommendation

Upright, lateral, soft-tissue x-ray of the pharynx

ODIN Link for Epiglottitis images (x-rays), Figure 12.7: <https://mistr.usask.ca/odin/?caseID=20170424101758702>

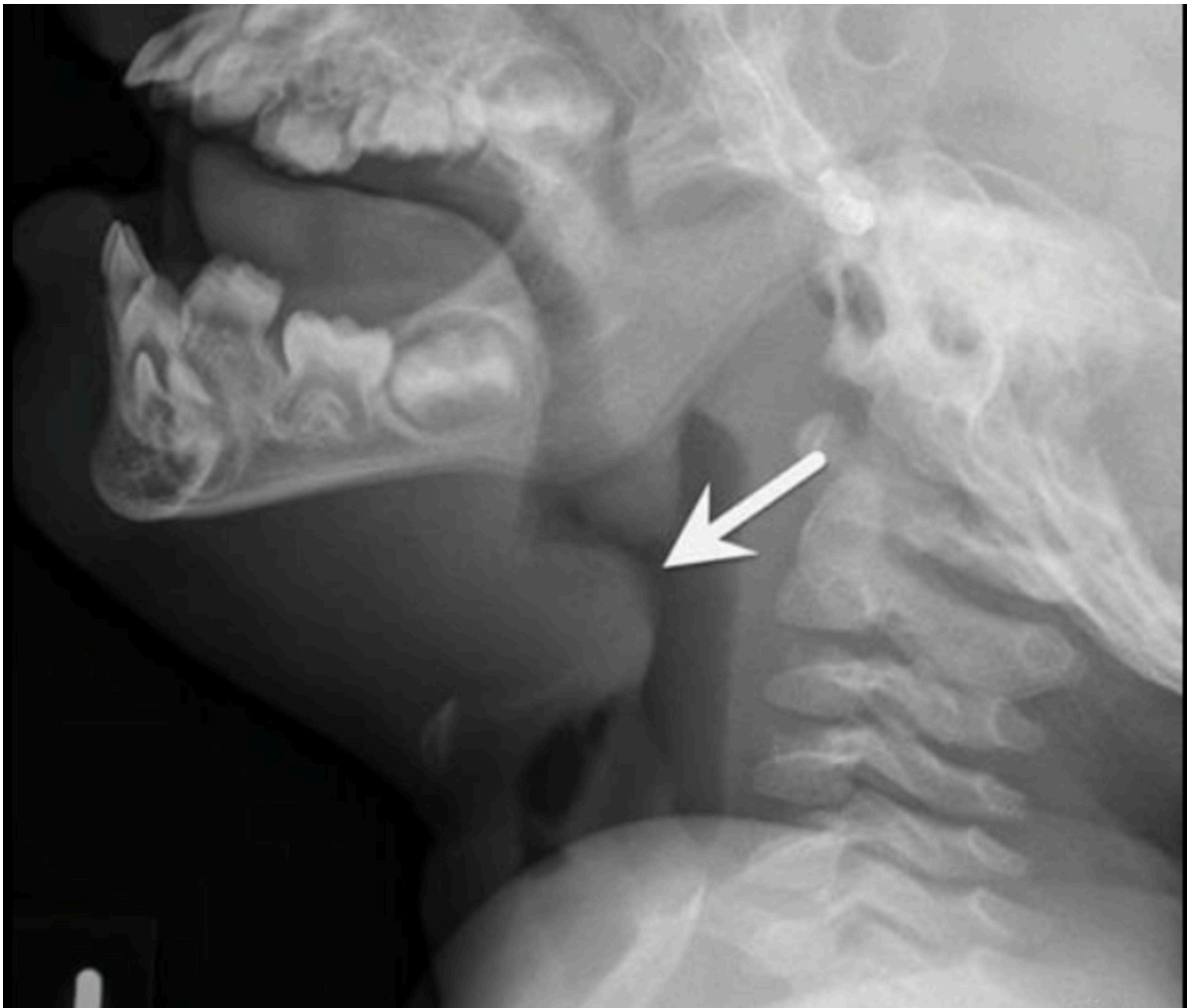


Figure 12.7 Lateral x-ray of the neck with an arrow pointing to the enlarged epiglottis

Imaging Assessment

Findings:

The epiglottis and the aryepiglottic folds were severely swollen creating a thumb-like projection that was partially occluding the trachea. The adenoid tissue was normal for a child this age.

Interpretation:

Epiglottitis

Diagnosis:

Epiglottitis

Discussion:

Acute bacterial epiglottitis can be a life-threatening medical emergency, leading to airway obstruction caused by infection, with edema of the epiglottis and aryepiglottic folds.

The most frequent causative organism had previously been *Haemophilus influenzae* type B, but introduction of the vaccine in 1985 has led to a marked decrease in the number of cases of epiglottitis. Other, rarer, causative may include: *Pneumococcus*, *Streptococcus* group A, viral infection such as herpes simplex 1, parainfluenza, thermal injury, or angioneurotic edema.

Epiglottitis typically has a peak incidence from about 3 to 6 years of age. Clinically epiglottitis resembles croup, but the clinician should think of epiglottitis if the child cannot breathe unless sitting up, if what appears to be croup seems to be worsening, or the child cannot swallow saliva and drools. Cough is rare. The classical triad of epiglottitis is drooling, severe dysphagia, and respiratory distress with inspiratory stridor.

The imaging study of choice is the lateral neck radiograph, which should be exposed in the upright position only as the supine position may precipitate airway occlusion. The patient should be accompanied everywhere by someone experienced in endotracheal intubation. Imaging studies are not always necessary for the diagnosis and may be falsely negative in early stages.

Imaging findings may include:

- Enlargement of the epiglottis.
- There is thickening of the aryepiglottic folds (which is an important component of airway obstruction and the true cause of stridor).
- Sometimes circumferential narrowing of the subglottic portion of the trachea is seen during inspiration.

Treatment of Epiglottitis

- Securing the airway, which may require intubation or emergency tracheostomy;
- Start empiric antibiotic therapy;
- Corticosteroids may be added to minimize swelling of the epiglottis.

Attributions

Figure 12.7 Lateral x-ray of the neck with an arrow pointing to the enlarged epiglottis by Dr. Brent Burbridge MD, FRCPC, University Medical Imaging Consultants, College of Medicine, University of Saskatchewan is used under a [CC-BY-NC-SA 4.0](https://creativecommons.org/licenses/by-nc-sa/4.0/) license.

Head and Neck – References

- 1) ACR Thyroid Imaging, Reporting and Data System (TI-RADS): White Paper of the ACR TI-RADS Committee. JCAR 2017, In Press.
- 2) [Learning radiology : recognizing the basics](#). William Herring author. Elsevier 2016, *Online access University of Saskatchewan Library*. http://usl-primo.hosted.exlibrisgroup.com/primo_library/libweb/action/search.do?vid=USASK Accessed, June 30, 2017.
- 3) [Grainger and Allison's diagnostic radiology : a textbook of medical imaging](#). Andy Adam editor.; Adrian K. Dixon editor.; Jonathan H. Gillard 1964- editor.; Cornelia Schaefer-Prokop editor.; David J Allison; Elsevier (Firm) 2015, *Online access University of Saskatchewan Library*. http://usl-primo.hosted.exlibrisgroup.com/primo_library/libweb/action/search.do?vid=USASK Accessed June 30, 2017.

Chapter 13 – Interventional / Vascular (Invasive)

Percutaneous Biopsy

Case 1

Ultrasound Guided Biopsy

Clinical:

History – This 66 year old female was found to have a palpable mass in the breast.

Symptoms – Palpable mass in the right breast.

Physical – A firm, non-mobile, mass was detected in the right breast. It was not fixated to the chest wall, or skin, and there were no palpable lymph nodes.

DDx:

Breast mass, BiRads 4b

Imaging Recommendation

Ultrasound Guided Needle Biopsy of the Mass

ODIN Link for Breast Mass Needle Biopsy images (Ultrasound), Figure 13.1: <https://mistr.usask.ca/odin/?caseID=20151202232017924>

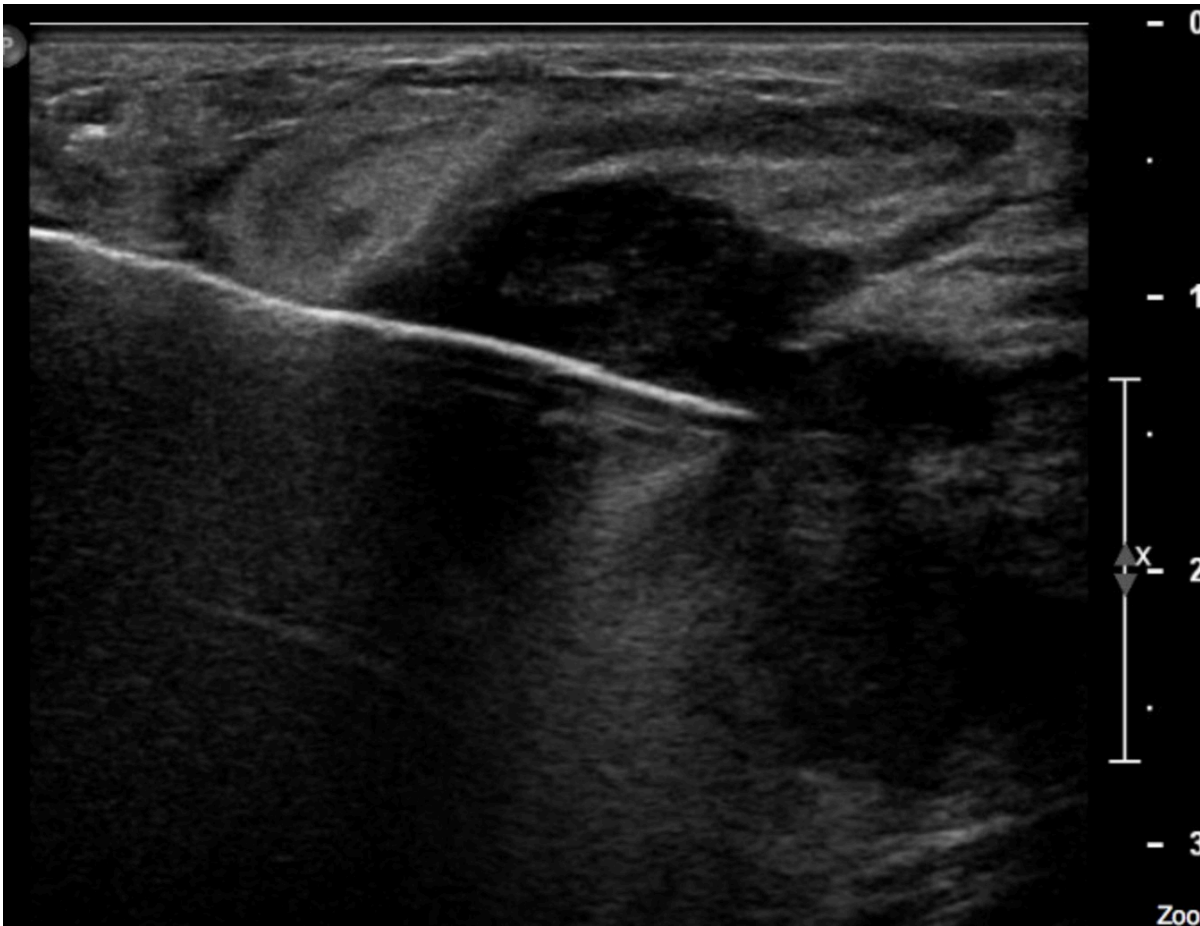


Figure 13.1 Ultrasound guided biopsy of a breast mass

Imaging Assessment

Findings:

Both mammography and breast ultrasound were used to evaluate a mass in the right breast. It was considered to be of intermediate risk for malignancy and was classified as a BiRads 4c lesion. Biopsy was recommended.

Interpretation:

The ultrasound images demonstrated the large caliber, 14g, needle in the breast mass.

Diagnosis:

Adenocarcinoma of the breast.

Discussion:

Ultrasound guided biopsy is warranted for the diagnosis of malignancy or infection. The abnormality in question must be visible with ultrasound, can be safely accessed, and be anatomically accessible for biopsy. Ultrasound affords real-time visualization of the needle tip which facilitates accurate biopsy sample acquisition.

Case 2

CT Guided Biopsy

Clinical:

History – Weight loss, fatigue, cough, and hemoptysis.

Symptoms – The patient complained of a chronic cough with hemoptysis.

Physical – There was evidence of chronic obstructive lung disease. The patient was cachectic and pale.

DDx:

Tuberculosis

Lung Abscess

Cavitating Lung Malignancy

Imaging Recommendation

CT Guided Lung Biopsy

ODIN Link for Left Upper Lobe Lung Mass Biopsy images (CT), Figure 13.2: <https://mistr.usask.ca/odin/?caseID=20170118173043442>

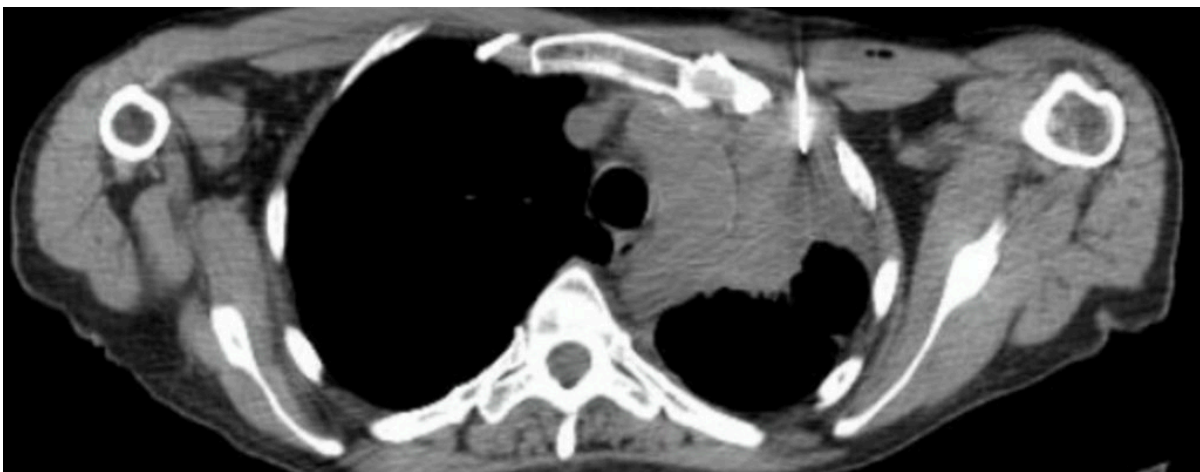


Figure 13.2 CT guided biopsy of a left lung mass

Imaging Assessment

Findings:

The patient had a cavitating mass in the left upper lobe. CT guidance was utilized to obtain a core needle biopsy specimen from the periphery of the mass where the tissue was more likely to be viable, not necrotic.

Interpretation:

Successful needle biopsy of the left upper lung mass.

Diagnosis:

Adenocarcinoma of the Lung, Non-small cell

Discussion:

CT guided biopsy is commonly used when the abnormality cannot be biopsied using ultrasound guidance. For the most part, CT biopsy is not a real-time imaging modality and multiple image acquisitions are required to position the needle for the biopsy.

Attributions

Figure 13.1 Ultrasound guided biopsy of a breast mass by Dr. Brent Burbridge MD, FRCPC, University Medical Imaging Consultants, College of Medicine, University of Saskatchewan is used under a [CC-BY-NC-SA 4.0](https://creativecommons.org/licenses/by-nc-sa/4.0/) license.

Figure 13.2 CT guided biopsy of a left lung mass by Dr. Brent Burbridge MD, FRCPC, University Medical Imaging Consultants, College of Medicine, University of Saskatchewan is used under a [CC-BY-NC-SA 4.0](https://creativecommons.org/licenses/by-nc-sa/4.0/) license.

Percutaneous Fluid Drainage

ACR – Interventional – Radiologic Management of Infected Fluid Collections

Case 1

Abscess Drain – CT Guided

Clinical:

History – 1 month in ICU after right hemi-colectomy for an obstructing colonic malignancy. The patient has had multiple intra-abdominal abscesses due to an anastomotic dehiscence.

Symptoms – Fever, on ventilator, septic.

Physical – The patient was intubated and septic. He was hemodynamically very fragile due to his advanced age of 86 year.

DDx:

Peri-hepatic abscess, deep.

[ACR – Radiologic Management of Infected Fluid Collections](#)

This fluid collection could not be seen well with ultrasound. CT guided, transhepatic abscess drain was requested due to his poor clinical status and ineligibility for surgical drain insertion.

CT Guided Abscess Drainage

ODIN Link for CT Abscess Drainage images, Figure 13.3A and B: <https://mistr.usask.ca/odin/?caseID=20170404111333875>

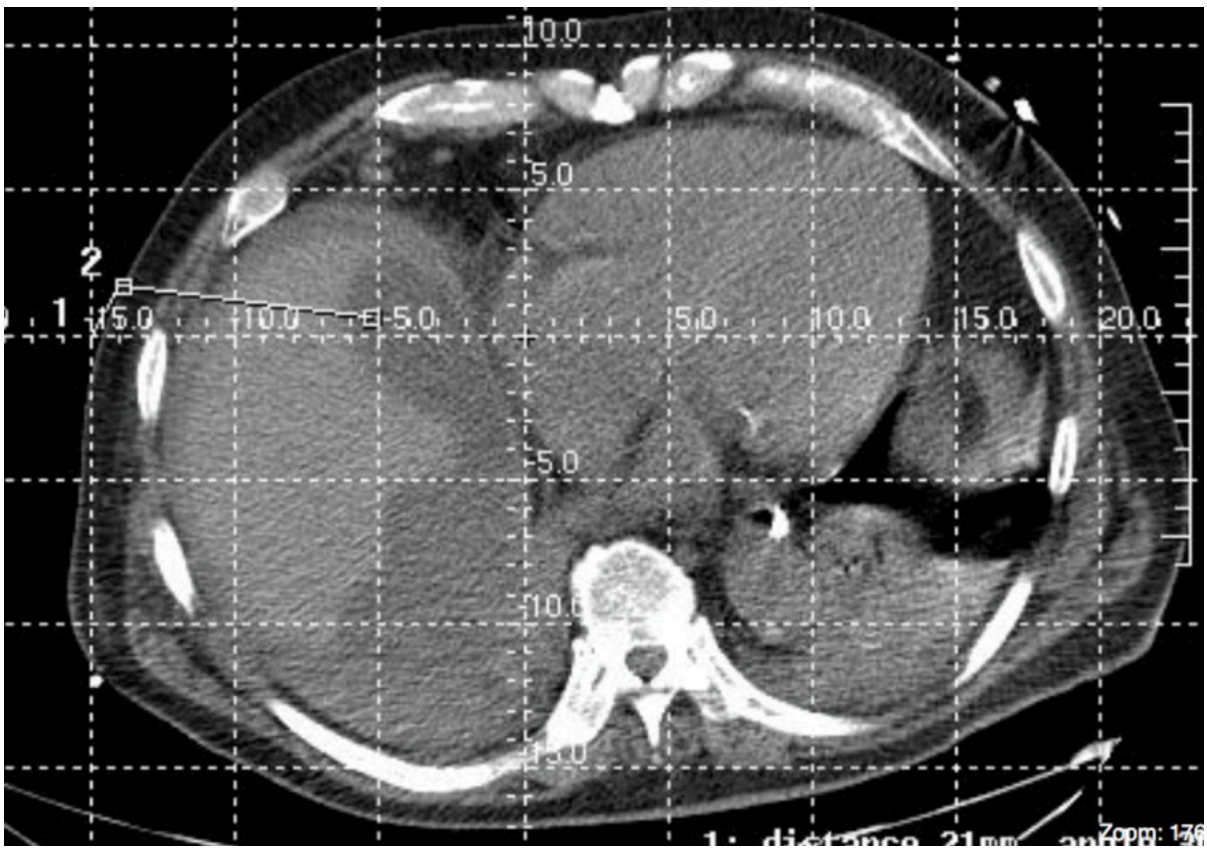


Figure 13.3A CT scan of abdomen with a grid and measurements to plan drainage

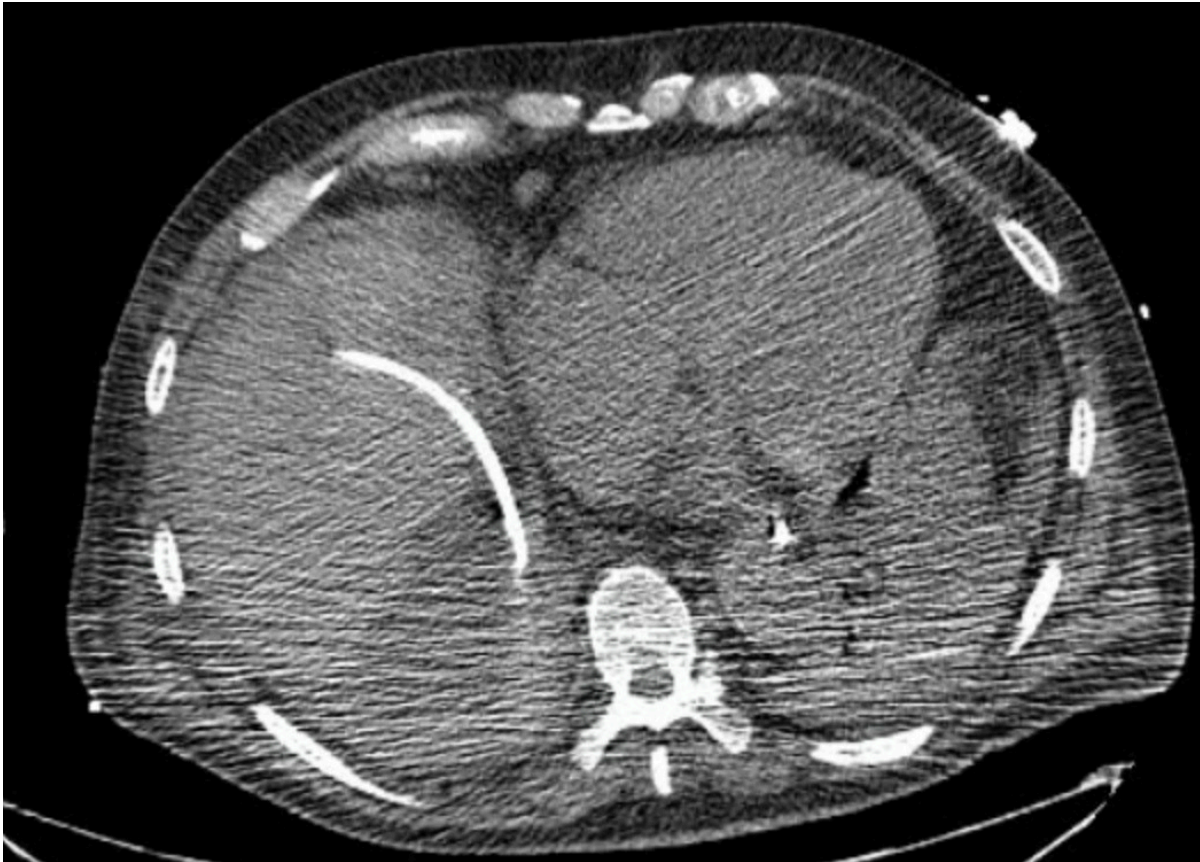

Figure 13.3B CT scan of a guided drainage of perihepatic abscess

Imaging Assessment

Findings:

There was a low attenuation collection in the upper abdomen that was medial to the cranial liver. A route of needle access was planned via a transhepatic route. Needle insertion was CT guided and followed by insertion of a 12F drainage catheter.

Interpretation:

Successful insertion of a 12F, transhepatic, abscess drain resulted in drainage of thick, foul-smelling, green fluid.

Diagnosis:

Perihepatic Abscess

Discussion:

The elevated risk of this procedure was explained to the family and the patient. There are additional risks of hepatic venous or arterial bleeding due to the drain route through the liver and for the development of intrahepatic abscesses along the drain tract. The surgical team could not offer this man any treatment options that were safer

and his potential morbidity and mortality from an open surgical drainage was felt to be greater than the risk of CT guided drainage.

Drainage of fluid can be performed utilizing needle aspiration and/or small or large caliber drainage tubes. The use of imaging guidance i.e. ultrasound, CT, and/or fluoroscopy facilitates accurate and safe insertion of the needle into the fluid collection. The drainage tube follows the positioning of a guidewire into the fluid via the puncture needle. The tract in the soft tissues can then be sequentially dilated to accommodate the small or large draining catheter based upon the location of the tube and the viscosity of the draining fluid. The process of needle, guidewire, dilation, drainage tube, is called the Seldinger Technique. It is widely used for interventional radiology procedures.

Case 2

Infected Polycystic Kidney Cyst, Drained, Ultrasound Guided

Clinical:

History – Autosomal Dominant Polycystic Kidney Disease

Symptoms – Left Flank and upper abdominal pain. Fever.

Physical – The kidneys were massively enlarged and palpable on physical examination. The patient was tender in the left upper quadrant. The patient's temperature was 39.5C.

Laboratory – The white blood cell count was elevated.

DDx:

Renal Cyst Hemorrhage

Renal Cyst Infection

[ACR – Radiologic Management of Infected Fluid Collections](#)

Ultrasound Guided Fluid Drainage

ODIN Link for Kidney Cyst Drainage images (CT and Ultrasound), Figure 13.4A and B:

<https://mistr.usask.ca/odin/?caseID=20161107172446656>

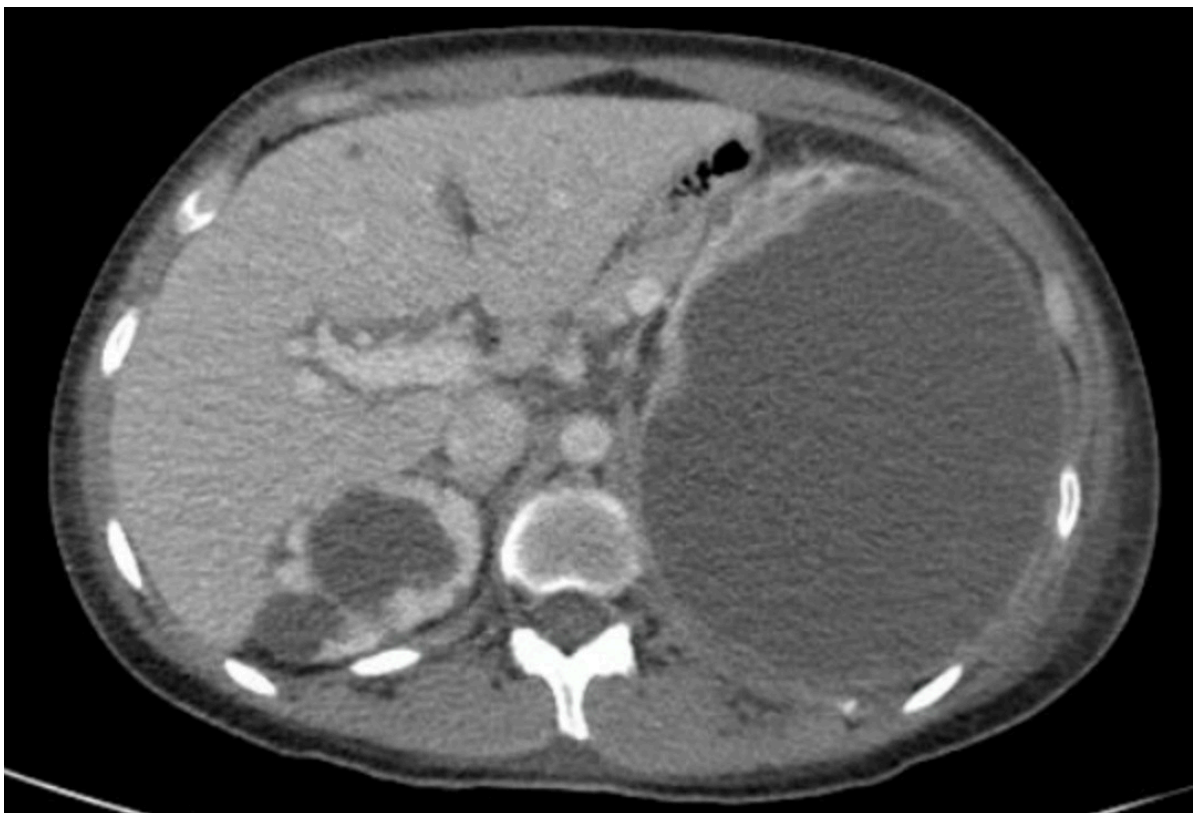

Figure 13.4A CT scan of polycystic kidneys with a very large cyst on the left.

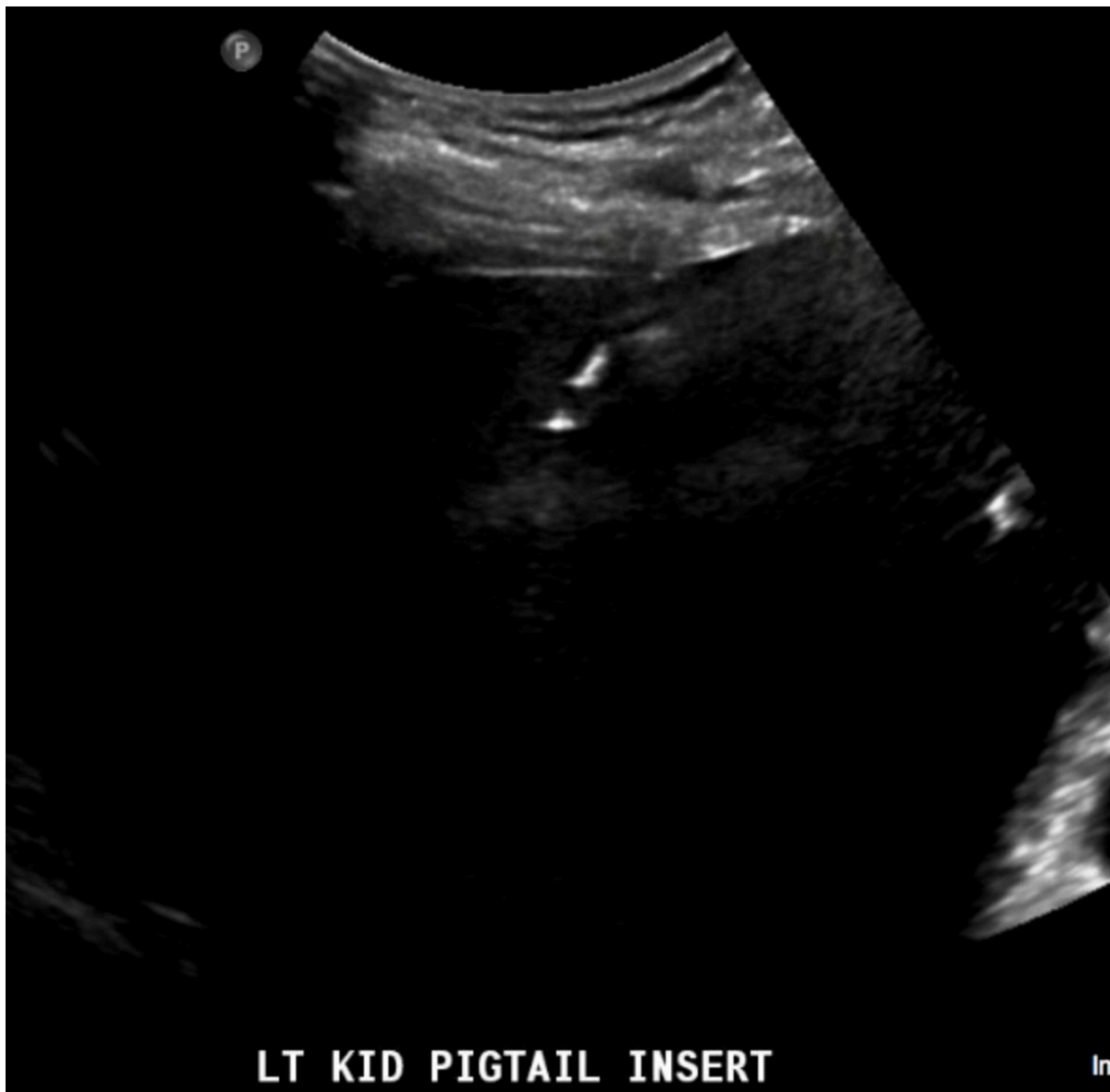

Figure 13.4B Ultrasound guided drainage of the left kidney cyst. Needle visualized with ultrasound.

Imaging Assessment

Findings:

CT

The patient had polycystic kidneys. There was a massive cyst in the left upper kidney. No fluid/fluid levels or unusual internal attenuation of this large cyst.

Given the CT findings of the massive cyst, aspiration with Ultrasound guidance was suggested as draining this cyst may improve the patient's condition and samples could be sent for culture and sensitivity.

Ultrasound

Ultrasound was used to aspirate some fluid from the largest cyst on the left. It was frankly purulent and a 10F drain was inserted.

Interpretation:

Polycystic kidney with an infected cyst in the left upper kidney.

Diagnosis:

Secondary infection of a left renal cyst.

Attributions

Figure 13.3A CT scan of abdomen with a grid and measurements to plan drainage by Dr. Brent Burbridge MD, FRCPC, University Medical Imaging Consultants, College of Medicine, University of Saskatchewan is used under a [CC-BY-NC-SA 4.0](#) license.

Figure 13.3B CT scan of a guided drainage of perihepatic abscess by Dr. Brent Burbridge MD, FRCPC, University Medical Imaging Consultants, College of Medicine, University of Saskatchewan is used under a [CC-BY-NC-SA 4.0](#) license.

Figure 13.4A CT scan of polycystic kidneys with a very large cyst on the left by Dr. Brent Burbridge MD, FRCPC, University Medical Imaging Consultants, College of Medicine, University of Saskatchewan is used under a [CC-BY-NC-SA 4.0](#) license.

Figure 13.4B Ultrasound guided drainage of the left kidney cyst. Needle visualized with ultrasound by Dr. Brent Burbridge MD, FRCPC, University Medical Imaging Consultants, College of Medicine, University of Saskatchewan is used under a [CC-BY-NC-SA 4.0](#) license.

Venous Access

Peripherally Inserted Central Catheter (PICC), Dialysis Catheter, Tunneled Catheter

Case 1

Peripherally Inserted Central Vein Catheter (PICC)

Clinical:

This 55 year old male required intravenous antibiotics for osteomyelitis for 6 weeks. A PICC was inserted. The patient had known COPD.

ODIN Link PICC image, Figure 13.5: <https://mistr.usask.ca/odin/?caseID=20150915220832233>

Chest x-ray, PICC

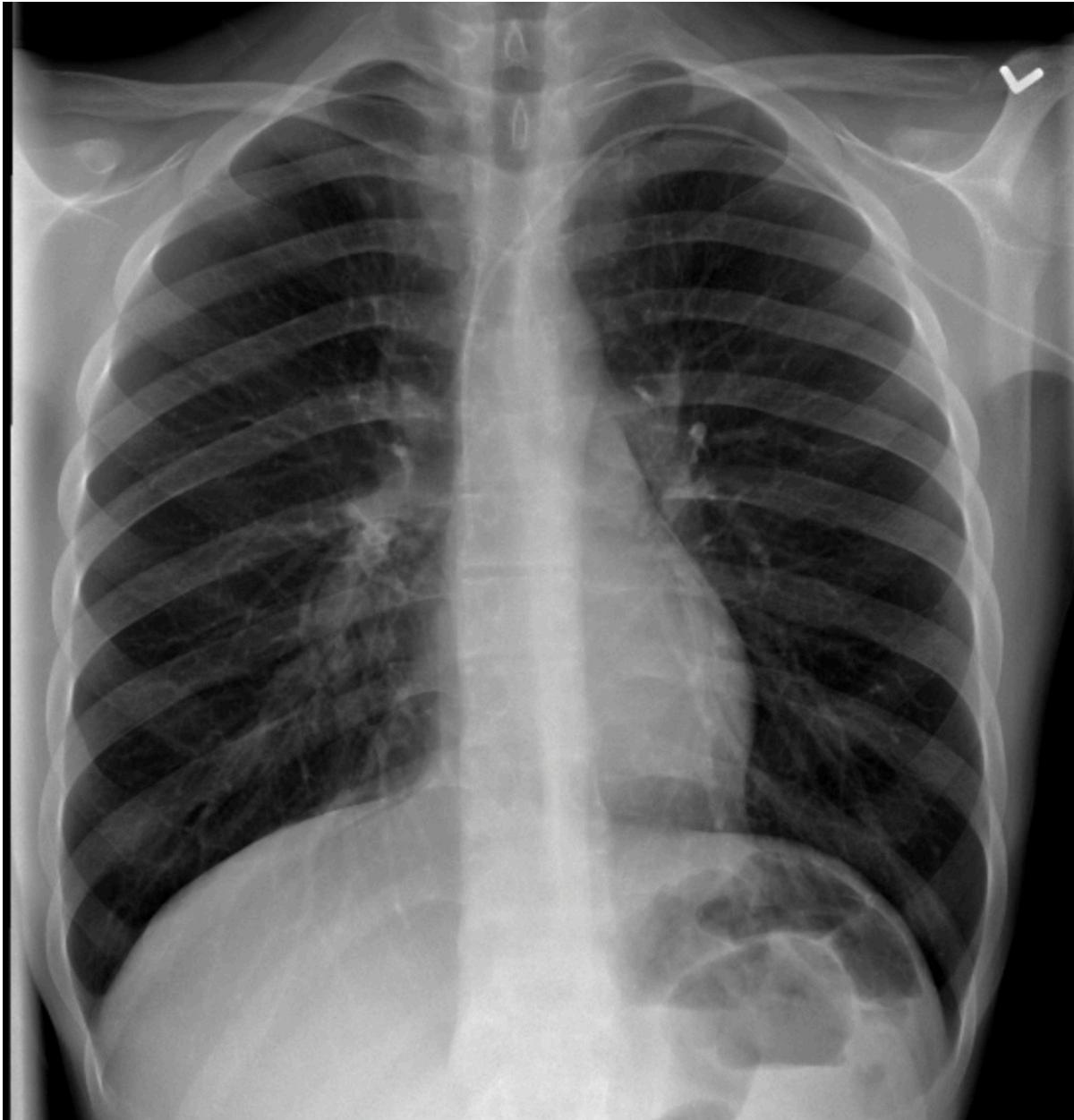


Figure 13.5 Chest x-ray of a PICC line

A small caliber venous catheter was seen entering from the left arm. The tip was at the SVC-Right atrial junction. This was a peripherally inserted central vein catheter (PICC).

Case 2

Jugular Catheter

Clinical:

This 45 year old patient required urgent dialysis after developing an immune mediated glomerulonephritis.

ODIN Link for Jugular Line images, Figure 13.6: <https://mistr.usask.ca/odin/?caseID=20170407155334051>

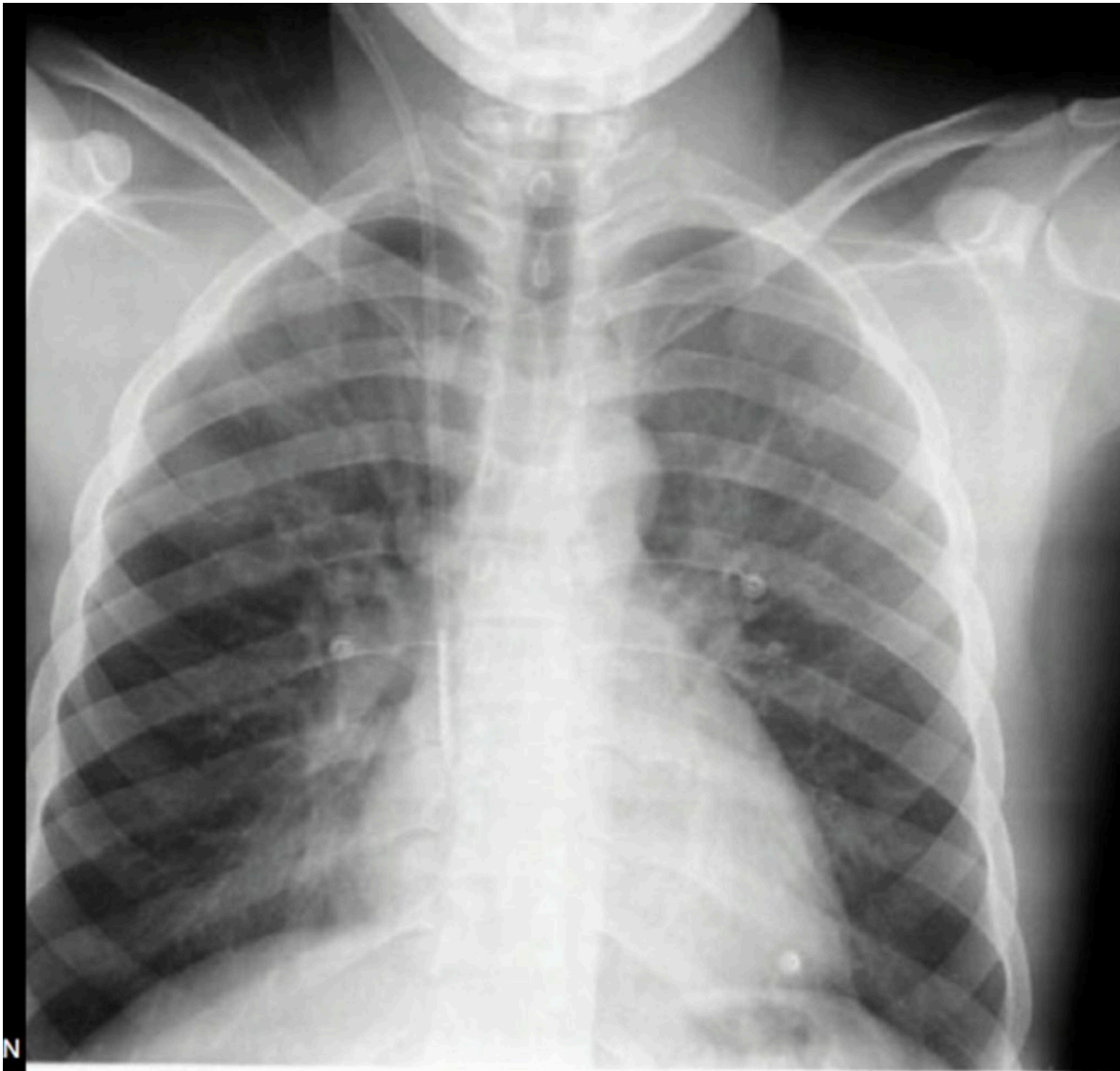
Chest x-ray, Jugular Line

Figure 13.6 Chest x-ray of a Jugular Catheter

A larger caliber catheter was seen. This was a 13F catheter suitable for dialysis. The tip position was satisfactory. This was not a tunneled catheter.

Case 3

Tunneled Central Line

Clinical:

This 73 year old male required a tunneled line for long-term treatment related to a Stem-Cell Transplant.

ODIN Link for Tunneled Catheter image, Figure 13.7: <https://mistr.usask.ca/odin/?caseID=20160203133046908>

Chest x-ray, Tunneled Catheter

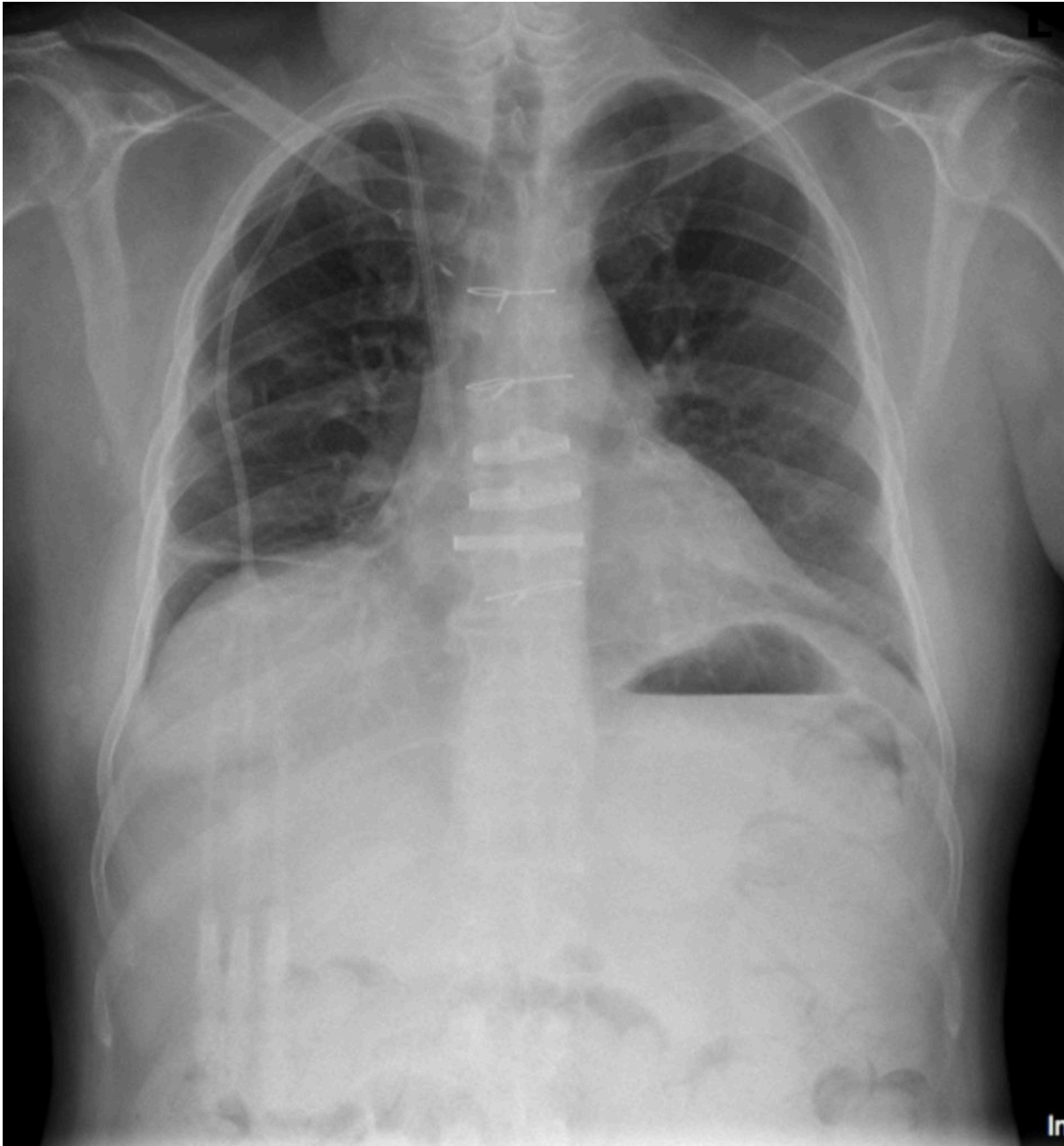


Figure 13.7 Chest x-ray of a Tunneled Catheter

A large caliber, triple lumen, catheter was seen superimposed on the upper right chest and neck. The tip of the catheter was at the SVC-Right atrial junction. This was a tunneled catheter implanted for long-term treatment related to a stem cell transplant.

Discussion:

With the benefit of sonography and fluoroscopy, Interventional Radiology (IR) can insert central venous catheters faster and more safely than physicians who rely on anatomic landmarks.

Central venous catheters can be broadly categorized into four groups:

- Peripherally inserted central catheters (PICC),
- Temporary (non-tunneled) central venous catheters,
- Long-term (tunneled) central venous catheters, and
- Implantable ports.

Each of these devices may be used for specific indications, but many indications are not mutually exclusive i.e. antibiotics via one lumen and total parenteral nutrition via a second lumen. In many instances, catheters of more than one type may be inserted for similar indications.

- Peripherally inserted central catheters are essentially long IVs (Case 1). These catheters typically range from 3 to 7 French and are inserted in a forearm or upper arm vein. The catheter may have one or two lumens and extends from the puncture site to the superior vena cava. This type of catheter is ideal for administration of intermediate-term medications such as antibiotics or chemotherapy.
 - Temporary (non-tunneled) subclavian, femoral, and internal jugular vein catheters are commonly used for medication delivery, central venous pressure monitoring, and short-term hemodialysis (Case 2). Many temporary catheters are constructed of polyurethane. This material is relatively rigid at room temperature but softens when placed in the body. Temporary catheters typically range from 6 to 13 French and are most often used for several days to several weeks.
 - Long-term (tunneled) catheters are composed of Silastic (silicone elastomer) or polyurethane (Case 3). Silastic is compliant and easily passes through tortuous vessels. Tunneled catheters travel through a short (8 to 15 cm) subcutaneous tunnel before entry into an accessed vein. A polyester cuff on the catheter becomes incorporated into the subcutaneous tissues and helps secure the catheter in place. Although somewhat controversial, the theoretical benefits of the tunneled catheter include decreased risk of infection compared with non-tunneled catheters and decreased risk of inadvertent catheter removal. Unequivocal benefits of tunneled internal jugular vein catheters include improved cosmetic appearance and patient comfort. In general, tunneled catheters are preferred to non-tunneled catheters in patients who require central venous access for longer than 2 weeks.
 - Implantable ports consist of a single or dual-lumen reservoir attached to a catheter. The port reservoir is implanted in the arm or chest, and the catheter is tunneled to the accessed vein. These devices are typically used for long-term, intermittent, venous access such as that required for chemotherapy. The port is accessed using a Huber (non-coring) needle. Some radiologists prefer chest implantation of these devices while other radiologists prefer arm ports, particularly in young women because of better cosmetic appearance. Among central venous catheters, ports have the lowest incidence of infection because they are implanted completely beneath the skin.
-

Attributions

Figure 13.5 Chest X-ray of a PICC line by Dr. Brent Burbridge MD, FRCPC, University Medical Imaging Consultants, College of Medicine, University of Saskatchewan is used under a [CC-BY-NC-SA 4.0](#) license.

Figure 13.6 Chest X-ray of a Jugular Catheter by Dr. Brent Burbridge MD, FRCPC, University Medical Imaging Consultants, College of Medicine, University of Saskatchewan is used under a [CC-BY-NC-SA 4.0](#) license.

Figure 13.7 Chest X-ray of a Tunneled Catheter by Dr. Brent Burbridge MD, FRCPC, University Medical Imaging Consultants, College of Medicine, University of Saskatchewan is used under a [CC-BY-NC-SA 4.0](#) license.

Inferior Vena Cava Filter

ACR – Interventional – Radiologic Management of Inferior Vena Cava Filters

Case

Inferior Vena Cava Filter

Clinical:

History – Surgical treatment of an intracranial aneurysm 1 day ago. CT PE study revealed bilateral pulmonary arterial thromboemboli.

Symptoms – Shortness of breath, pleuritic chest pain, pleural effusions.

Physical – Tachypnea and tachycardia. Left pleuritic rub detected.

DDx:

Pulmonary Thromboembolism with a contraindication to anticoagulation

[ACR – Radiologic Management of Inferior Vena Cava Filters](#)

Imaging Recommendation

Optional (Retrievable), Inferior Vena Cava Filter

ODIN Link to IVC Filter images, Figure 13.8A and B: <https://mistr.usask.ca/odin/?caseID=20170216144042087>

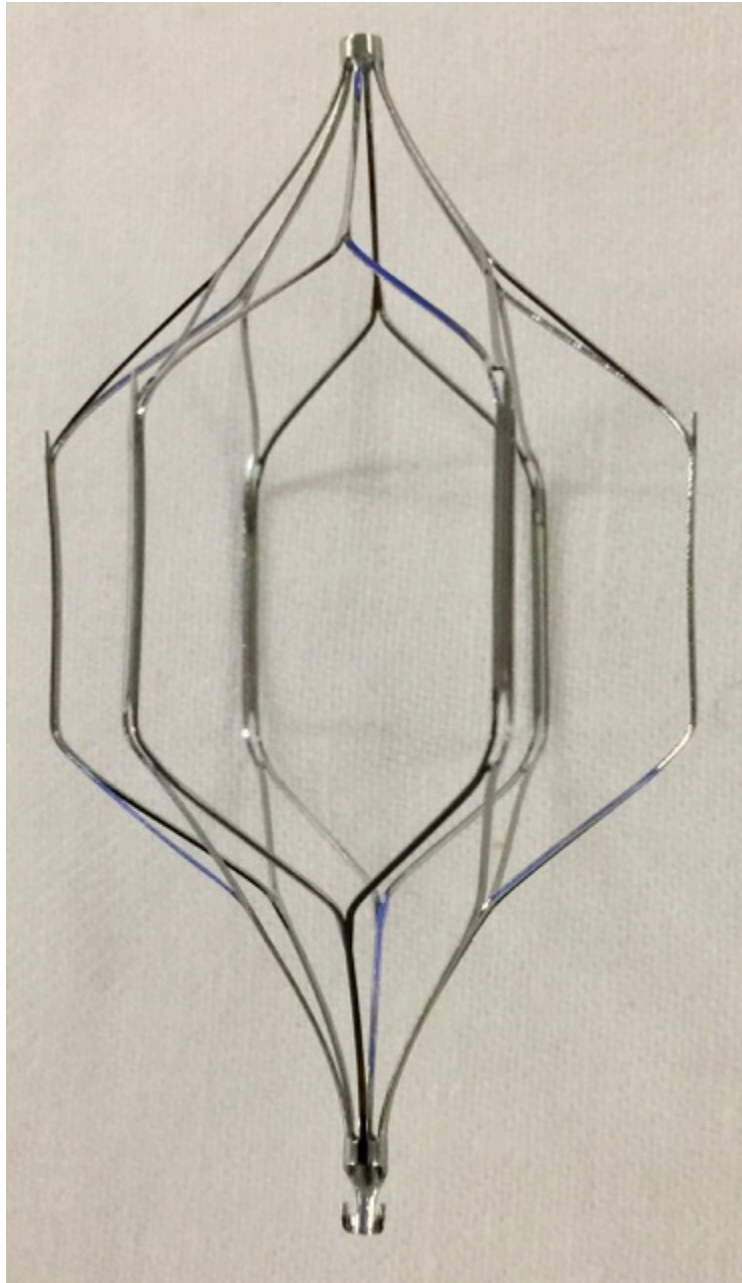


Figure 13.8A Cordis IVC Filter

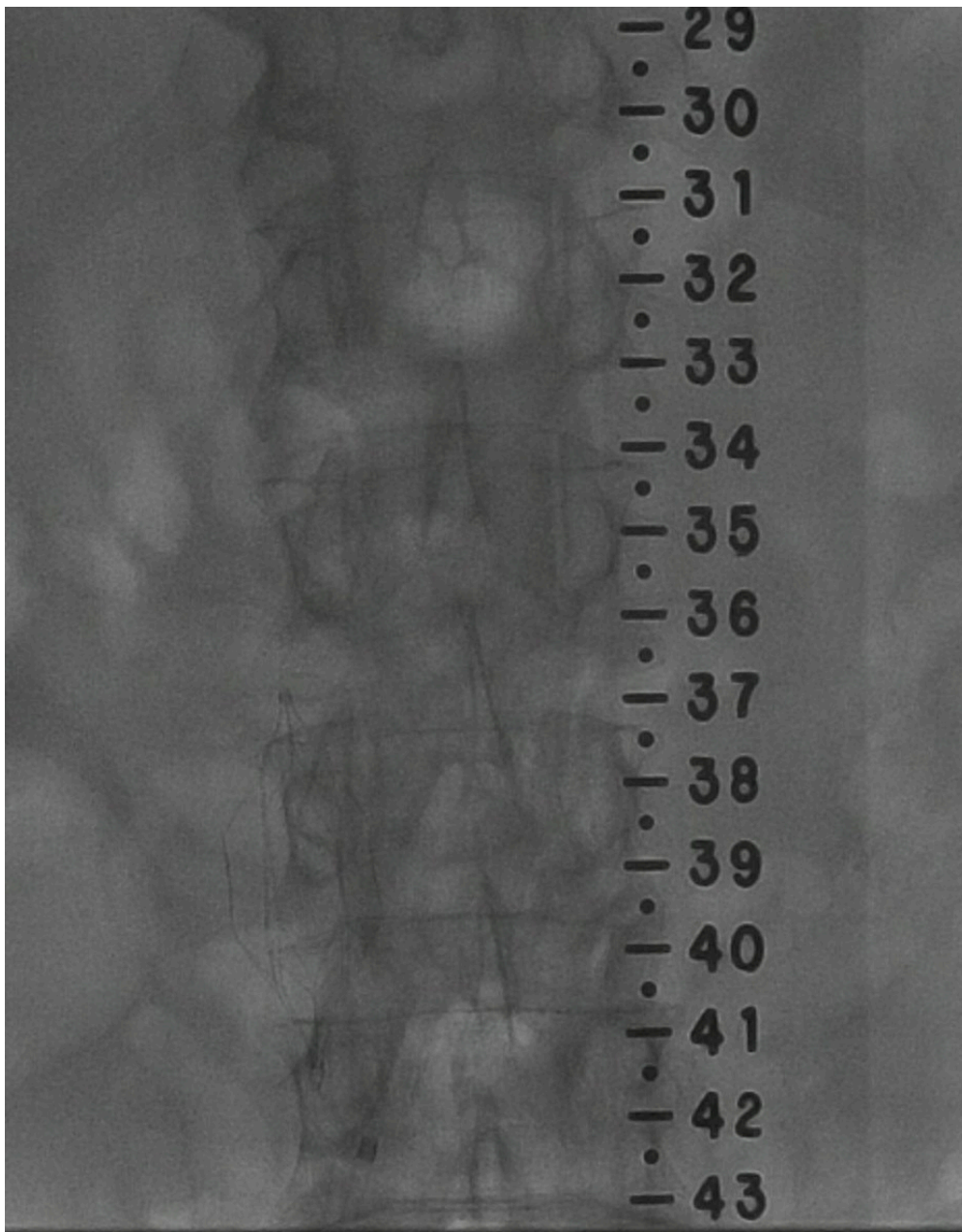


Figure 13.8B Cordis IVC Filter Placement in situ.

Imaging Assessment

Findings:

A common femoral vein access site was used for catheterization of the venous circulation. An inferior vena cavagram revealed no evidence of thrombus and an appropriate vena caval diameter for filter insertion. The renal veins were localized and the Cordis filter was implanted in an infra-renal location in the inferior vena cava. No complications.

Interpretation:

Successful implantation of a retrievable Cordis IVC filter.

Diagnosis:

Inferior Vena Cava Filter

Discussion:

Pulmonary embolus (PE) and deep venous thrombosis (DVT) represent the clinical spectrum of venous thromboembolism (VTE), which remains a major cause of morbidity and mortality in hospitalized patients. VTE occurs spontaneously or as a common complication during and after hospitalization for an acute medical or surgical illness.

PE accounts for 5%-10% of deaths in hospitalized patients and is the most common preventable cause of in-hospital death. Recent studies have emphasized that a significant number of medicine and surgery patients are not receiving adequate prophylaxis against VTE. More than 50% are at risk of VTE, and only half of those patients are receiving prophylaxis.

The primary prophylaxis and therapy for VTE are pharmacologic, including intravenous (IV) heparin, oral warfarin, subcutaneous low-dose heparin (LDH), or low-molecular-weight heparin (LMWH).

Vena cava filters do not prevent or treat DVT. The sole function of inferior vena cava (IVC) filters is prevention of clinically significant and potentially life-threatening PE by preventing the passage of emboli into the pulmonary arterial circulation by trapping the embolus as it passes from the iliofemoral venous system to the filter.

Hypercoagulable states must be excluded prior to filter placement in order to avoid significant patient morbidity.

The Most Common Indications for Vena Caval Filter Insertion

1) Pulmonary Embolism with a Contraindication to Anticoagulation

- Absolute contraindications to anticoagulation. These include unsecured intracranial aneurysm after subarachnoid hemorrhage, acute intracerebral hemorrhage, current or recent major gastrointestinal hemorrhage or lesions at high risk of bleeding (e.g., esophageal varices).
- Relative contraindication to anticoagulation including recent (within two weeks) major surgery; major trauma, including cardiopulmonary resuscitation (CPR) or deep biopsy; uncontrolled hypertension; renal or hepatic disease; current guaiac-positive stools; and known bleeding diatheses.

2) Major Complication of Anticoagulation

- Major bleeding is the most significant complication of anticoagulation. It is defined as intracranial or retroperitoneal bleeding or bleeding that requires hospitalization or transfusion while the patient is on therapeutic levels of anticoagulants. When anticoagulation therapy for VTE must be stopped because of major bleeding, placement of an IVC filter may be considered.

- Heparin-induced thrombocytopenia – defined as platelet count below 50,000/L, with or without arterial thrombosis – is also considered to be a complication of heparin therapy, and placement of an IVC filter should be considered after heparin therapy is discontinued.

3) Inability to Adequately Anticoagulate

- Lack of patient compliance, medication incompatibilities, other medical conditions making anticoagulation more difficult, i.e. liver or renal dysfunction, can result in inadequate anticoagulation.

4) Progression or Recurrence of Venous Thromboembolism despite Adequate Anticoagulation.

- Although VTE can progress during adequate anticoagulation, it is unusual and therefore it is critical to fully evaluate whether therapeutic levels have been consistently achieved.
- Raising the target INR (international normalized ratio) is preferable to placing a filter in the setting of inadequate anticoagulation.

Attributions

Figure 13.8A Cordis IVC Filter by Dr. Brent Burbridge MD, FRCPC, University Medical Imaging Consultants, College of Medicine, University of Saskatchewan is used under a [CC-BY-NC-SA 4.0](#) license.

Figure 13.8B Cordis IVC Filter Placement in situ by Dr. Brent Burbridge MD, FRCPC, University Medical Imaging Consultants, College of Medicine, University of Saskatchewan is used under a [CC-BY-NC-SA 4.0](#) license.

Interventional/Vascular – References

- 1) M. Lorenz, MD; Waddah B. Al-Refaie, MD; Brooks D. Cash, MD, et al. ACR Appropriateness Criteria® Radiologic Management of Infected Fluid Collections. Available at <https://acsearch.acr.org/docs/69345/Narrative/> Accessed June 30, 2017.
- 2) Catheter Replacement of the Needle for Arteriography. Seldinger, S. I. Acta Radiologica, 1953: 39 (5); 368 – 376.
- 3) Thomas B. Kinney, MD; Hamed Aryafar, MD; Charles E. Ray, Jr, MD, PhD, et al. ACR Appropriateness Criteria® Management of Inferior Vena Cava Filters. Available at <https://acsearch.acr.org/docs/69342/Narrative/> American College of Radiology. Accessed June 30, 2017
- 4) [Learning radiology:recognizing the basics](#). William Herring author. Elsevier 2016, Online access University of Saskatchewan Library. http://usl-primo.hosted.exlibrisgroup.com/primo_library/libweb/action/search.do?vid=USASK Accessed, June 30, 2017.
- 5) [Grainger and Allison’s diagnostic radiology : a textbook of medical imaging](#). Andy Adam editor.; Adrian K. Dixon editor.; Jonathan H. Gillard 1964- editor.; Cornelia Schaefer-Prokop editor.; David J Allison; Elsevier (Firm) 2015, *Online access University of Saskatchewan Library*. http://usl-primo.hosted.exlibrisgroup.com/primo_library/libweb/action/search.do?vid=USASK Accessed June 30, 2017.

Chapter 14 – Musculoskeletal

Clavicle Fracture

ACR – MSK – Acute Shoulder Pain

Case
Clavicle fracture

Clinical:

History – This 32 year old male was checked into the boards during a hockey game. He had immediate pain in his left shoulder.

Symptoms – The patient had severe pain in his left shoulder region. It was difficult for him to move his arm due to pain. Range of motion of the gleno-humeral joint was mildly limited due to pain.

Physical – There was soft tissue swelling over the lateral clavicle and there was a hard protuberance in this region as well.

DDx:

Hematoma

Acromio-Clavicular joint dislocation

Clavicle fracture

Imaging Recommendation

[ACR – MSK – Acute Shoulder Pain, Variant 1](#)

Shoulder X-rays

ODIN Link for Clavicle Fracture images, Figure 14.1A and B: <https://mistr.usask.ca/odin/?caseID=20161219111639935>

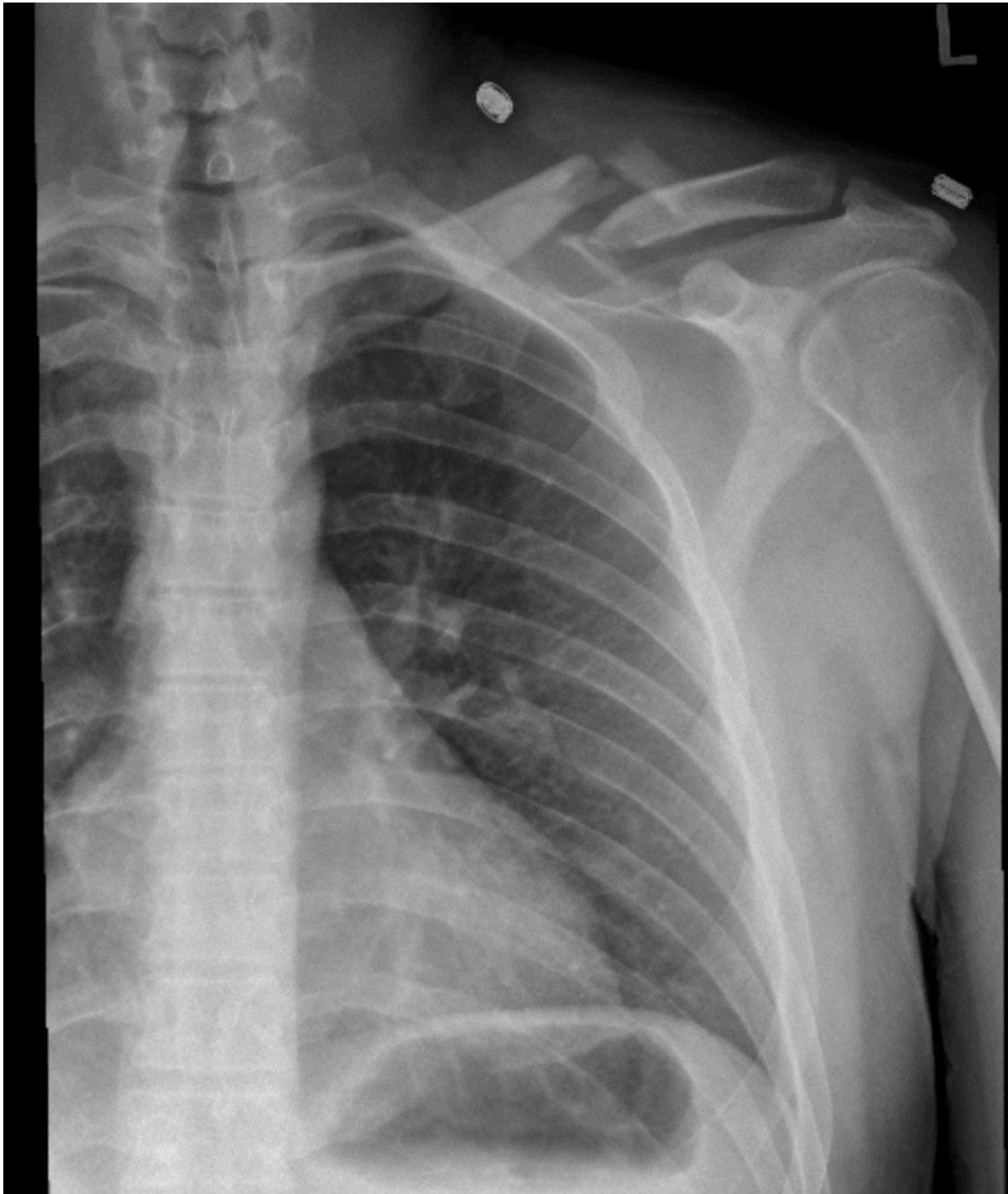


Figure 14.1A X-ray of the left shoulder, pre-operative, clavicle fracture.

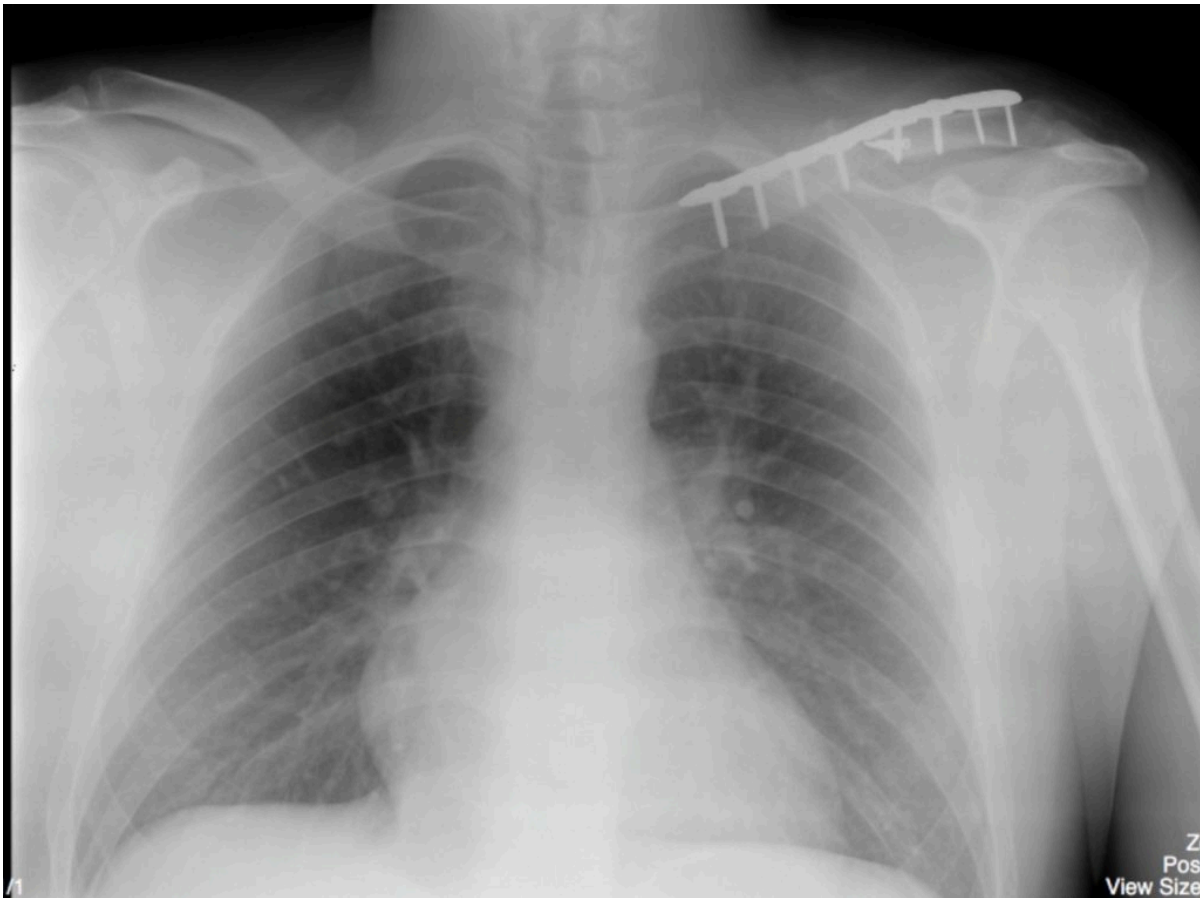

Figure 14.1B X-ray of the left shoulder, post-operative, clavicle fracture.

Imaging Assessment

Findings:

There was a comminuted, impacted, fracture of the left clavicle at the junction of the middle 1/3 and the lateral 1/3. The angle formed at the fracture site was mild to moderate and directed cranially. The angle created at the fracture site is due to the attachment of the sternocleidomastoid muscle pulling the medial fragment in a cranial direction.

Interpretation:

Impacted, comminuted, left clavicle fracture.

Diagnosis:

Clavicle fracture

Discussion:

Radiography is a useful initial screening modality for acute shoulder pain of all causes. Radiography is useful in the evaluation of fractures of the shoulder girdle. All radiographic shoulder studies should include frontal exam-

inations. The frontal views can be straight antero-posterior projection (AP) with the humerus in neutral position or with the humerus in internal and/or without external rotation. Local protocols for radiographic evaluation of the shoulder for trauma vary widely. However, the shoulder trauma protocol should have at least three views, of which two views are orthogonal.

X-ray findings may include:

- The most common location for a clavicular fracture is at the junction of the lateral 1/3 and the middle 1/3.
- In children there may be an incomplete or greenstick type of fracture.
- Clavicle fractures may occur in the newborn with difficult deliveries.
- The medial clavicular fragment is typically cranially displaced due the pull of the sternocleidomastoid muscle.
- In most circumstances there is either a fracture of the clavicle or an acromio-clavicular joint dislocation and the two injuries are usually mutually exclusive.

Attributions

Figure 14.1A X-ray of the left shoulder, pre-operative, clavicle fracture by Dr. Brent Burbridge MD, FRCPC, University Medical Imaging Consultants, College of Medicine, University of Saskatchewan is used under a [CC-BY-NC-SA 4.0](#) license.

Figure 14.1B X-ray of the left shoulder, post-operative, clavicle fracture by Dr. Brent Burbridge MD, FRCPC, University Medical Imaging Consultants, College of Medicine, University of Saskatchewan is used under a [CC-BY-NC-SA 4.0](#) license.

Acromioclavicular Joint Separation

Acromioclavicular (AC) Joint Separation/Dislocation

Case

Acromioclavicular joint dislocation

Clinical:

History – 21 year old female injured her shoulder while wrestling.

Symptoms – This patient complained of a deformed, painful, end of her right collar bone.

Physical – There was swelling and tenderness of the region of the acromioclavicular joint.

DDx:

Acromioclavicular Joint Separation

Clavicle Fracture

Acromion Fracture

Hematoma

Imaging Recommendation

[ACR – MSK – Acute Shoulder Pain, Variant 1](#)

Shoulder X-ray

ODIN Link to AC Joint Separation images, Figure 14.2A and B: <https://mistr.usask.ca/>

[odin/?caseID=20150209202015857](#)

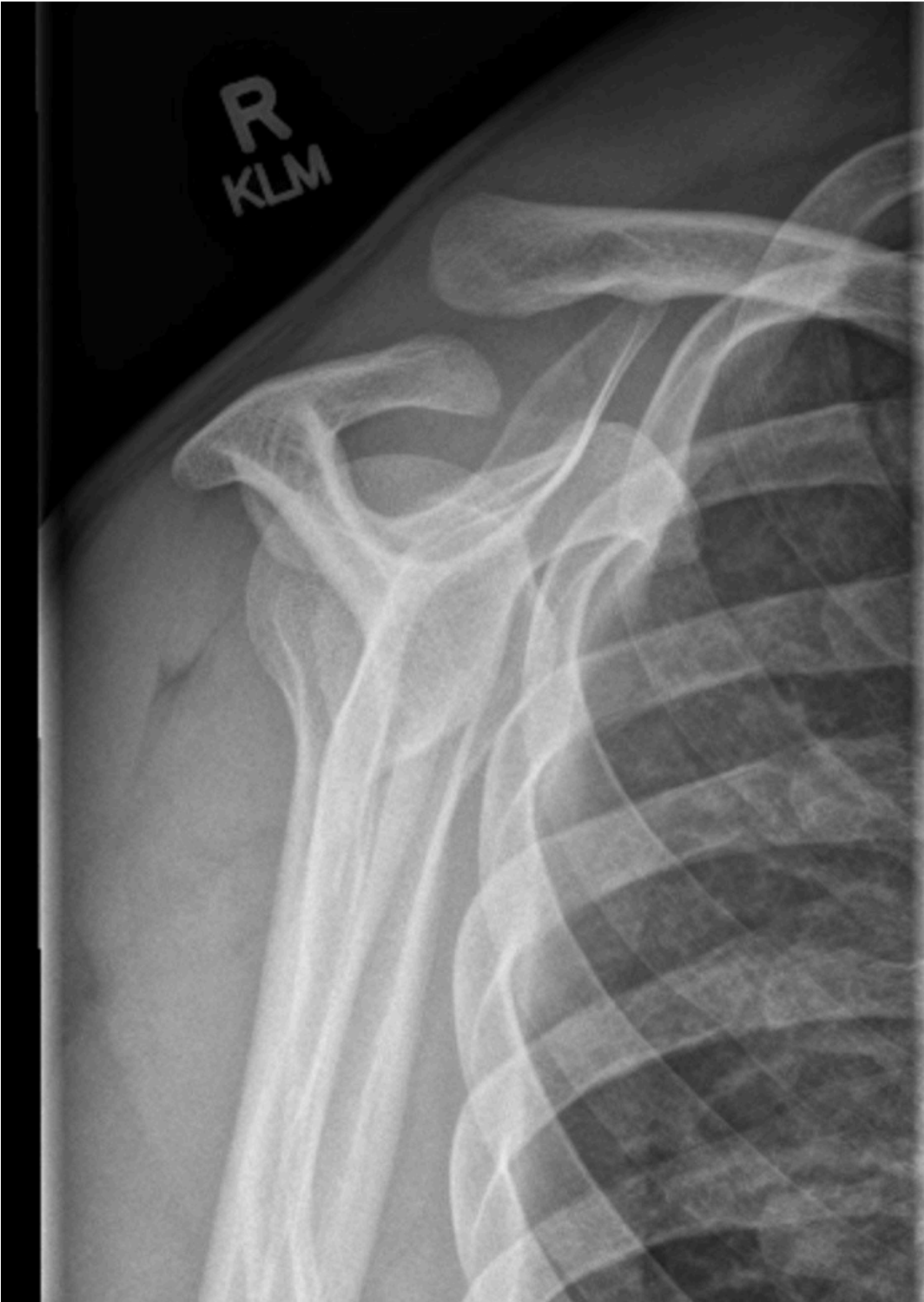

Figure 14.2A X-ray of the right shoulder, Y-view, with AC joint separation

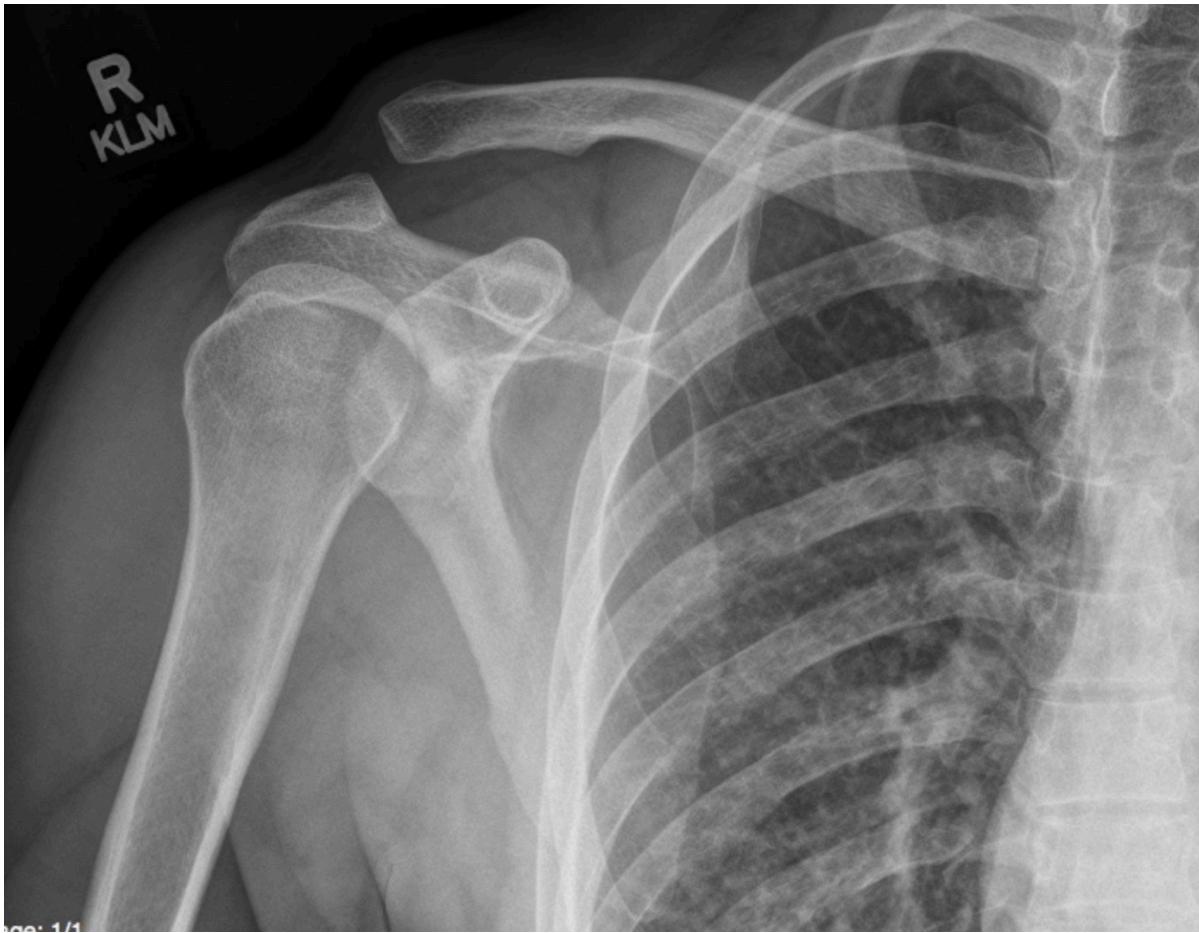


Figure 14.2B X-ray of the right shoulder, AP, with AC joint separation

Imaging Assessment

Findings:

The lateral clavicle was displaced cranially and the acromioclavicular joint was widened. The coracoclavicular distance was also widened.

Interpretation:

Acromioclavicular joint dislocation, Type 3.

Diagnosis:

Acromioclavicular joint dislocation

Discussion:

Acromioclavicular joint injuries can be graded on the 6-point Rockwood scale:

Type	AC Joint	CC Joint	Reducibility	Treatment
I	Sprain	Normal	NA	Conservative
II	Torn	Sprain – CC distance <25% of the contralateral side	Reducible	Conservative
III	Torn	Torn – CC distance increased 25 – 100 % of the contralateral side	Reducible or Non-Reducible	Conservative or Surgical
IV	Torn	Torn – Posterior displacement of clavicle into the trapezius muscle	Not Reducible	Surgery
V	Torn	Torn – CC distance > 100% of the contralateral side with the clavicle protruding through the delto-trapezial fascia	Not Reducible	Surgery
VI	Torn	Torn – Clavicle caudal to the subacromial or subcoracoid	Not Reducible	Surgery

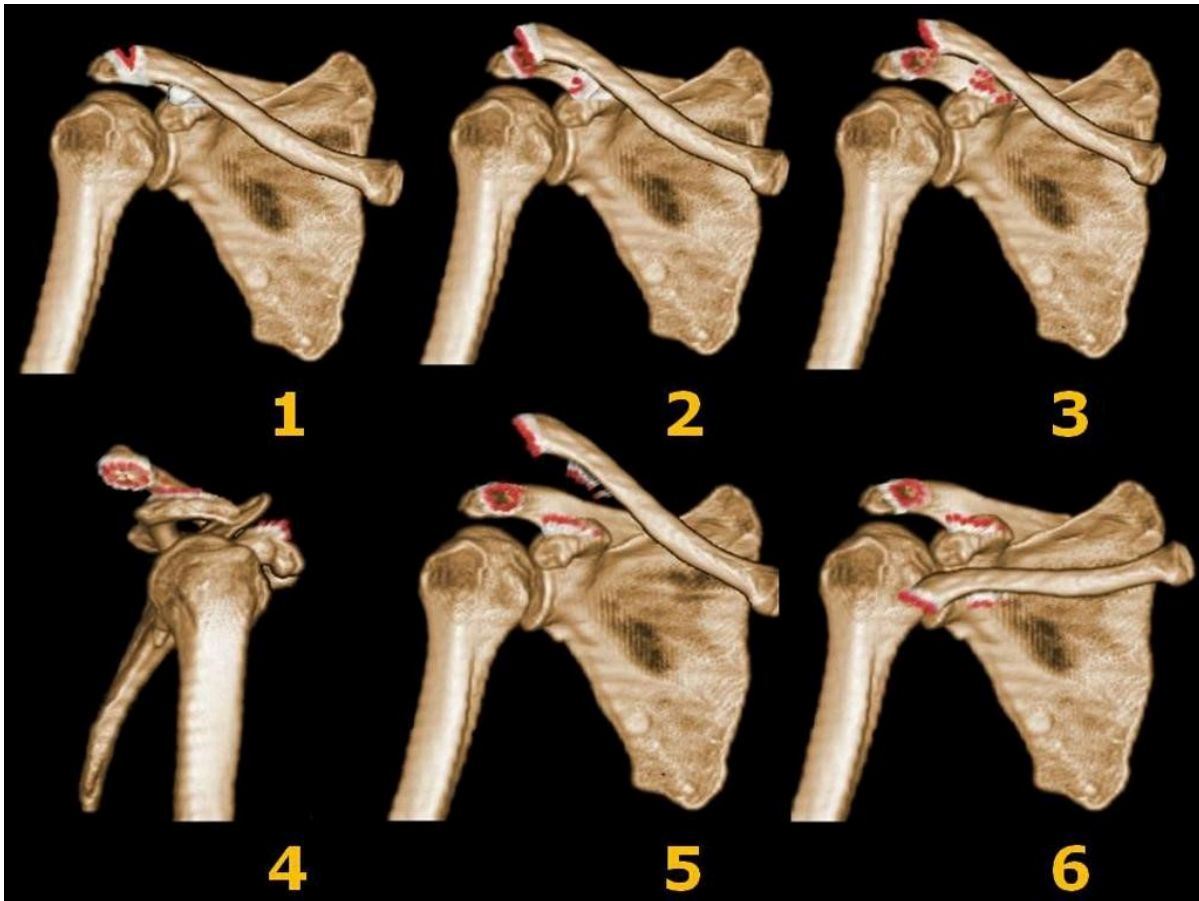


Figure 14.3 Acromioclavicular injury classification

X-ray findings may include:

- Minor injuries of this joint space usually involve only the joint capsule and the acromioclavicular ligament.
- With more severe injuries the coracoclavicular ligament may be torn leading to a more displaced clavicle and a wider coracoclavicular distance.
- Severe injuries can involve the coracoclavicular ligament, the deltoid muscle and the trapezius muscle.

Attributions

Figure 14.2A X-ray of the right shoulder with AC joint separation by Dr. Brent Burbridge MD, FRCPC, University Medical Imaging Consultants, College of Medicine, University of Saskatchewan is used under a [CC-BY-NC-SA 4.0](#) license.

Figure 14.2B X-ray of the right shoulder with AC joint separation by Dr. Brent Burbridge MD, FRCPC, University Medical Imaging Consultants, College of Medicine, University of Saskatchewan is used under a [CC-BY-NC-SA 4.0](#) license.

Figure 14.3 Acromioclavicular injury classification. Courtesy of Dr. Roberto Schubert, Radiopaedia.org, RID: 19124. Originally published at <https://radiopaedia.org/cases/rockwood-classification-system-of-acromioclavicular-joint-injuries> under a [Creative Commons Attribution-Non-commercial-Share Alike 3.0 License](#).

Rotator Cuff

ACR – MSK – Acute Shoulder Pain

Case

Rotator Cuff, Torn Supraspinatus Tendon

Clinical:

History – This 77 year old male slipped while exiting his truck. He felt a tearing sensation in the upper shoulder region as he grasped the door frame, while falling to the ground. He states that he really pulled his shoulder in the process.

Symptoms – The shoulder was acutely painful and there was limited, painful, range of motion, especially with abduction. No other issues.

Physical – Range of motion was very limited. There was swelling over the greater tuberosity of the humerus.

DDx:

AC joint dislocation

Clavicle fracture

Injured rotator cuff

Imaging Recommendation

[ACR – MSK – Acute Shoulder Pain, Variant 5](#)

Shoulder Ultrasound – after normal shoulder radiographs

ODIN for Rotator Cuff Tear images (Ultrasound), Figure 14.4A and B: <https://mistr.usask.ca/odin/?caseID=20170330175438744>

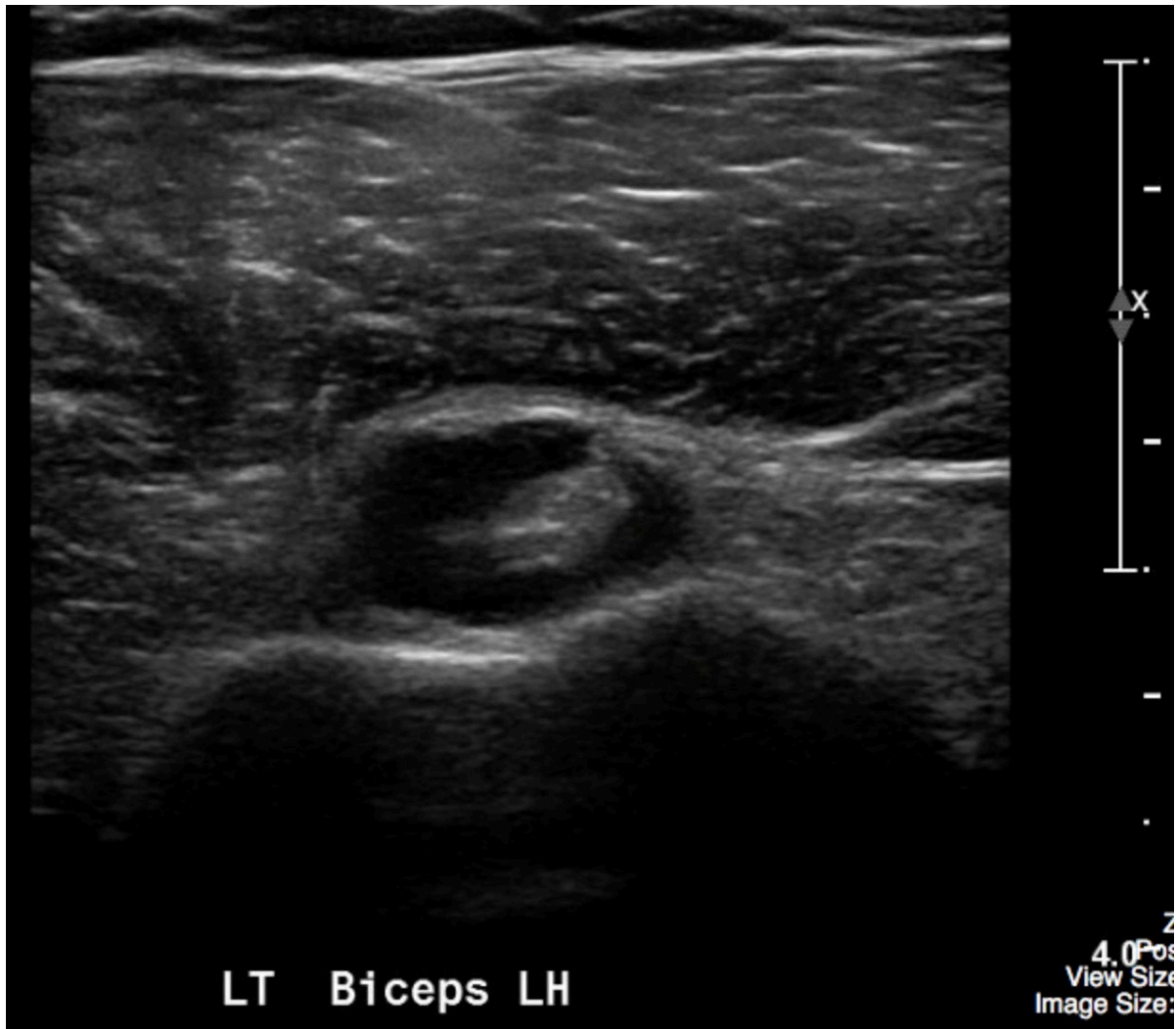


Figure 14.4A Ultrasound of the left biceps long head tendon, transverse, displaying fluid

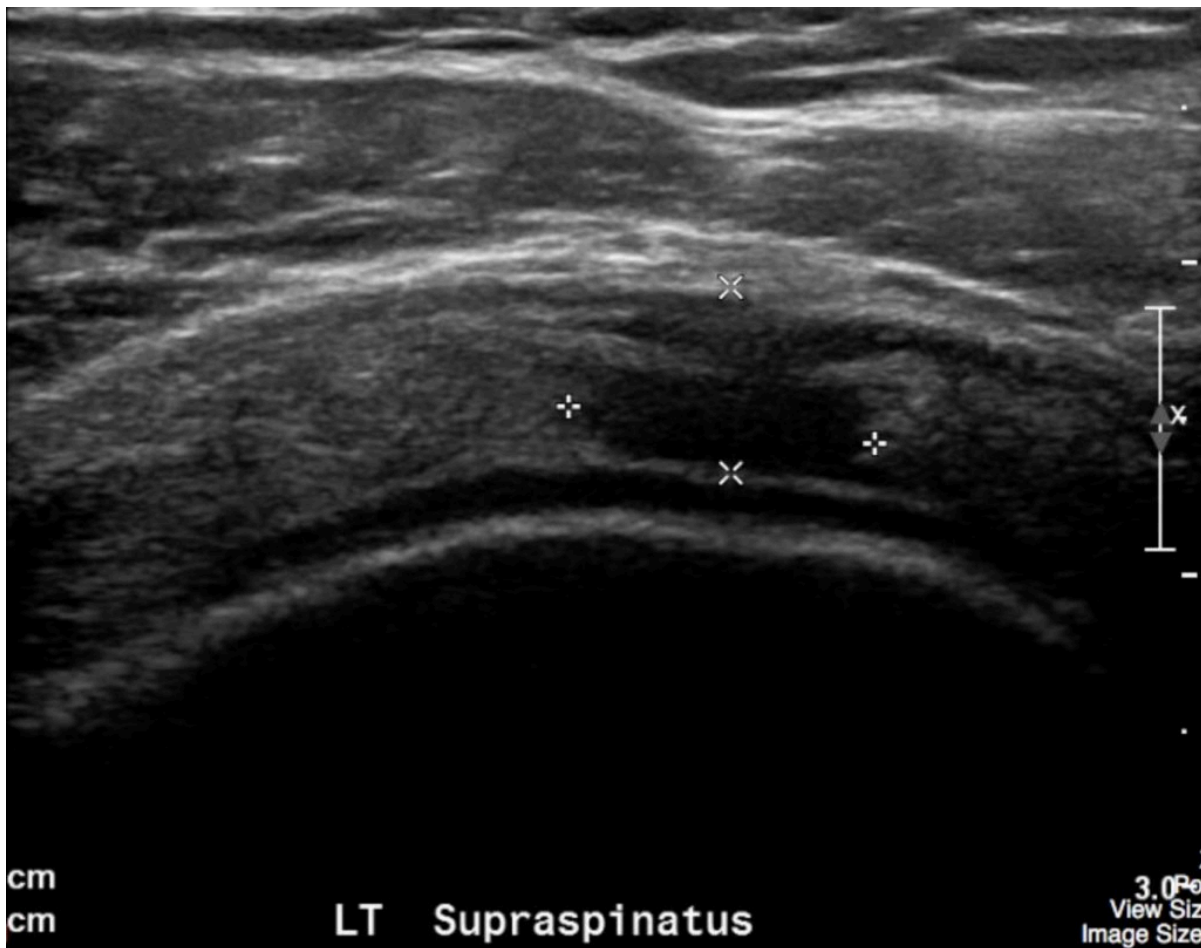

Figure 14.4B Ultrasound of the left supraspinatus tendon displaying a full thickness tear

Imaging Assessment

Findings:

There was a moderate amount of fluid associated with an intact bicep muscle long – head tendon. Dense calcifications were seen in the subscapularis tendon. There was a full-thickness partial tear of the supraspinatus tendon with a small amount of fluid seen in the subacromial-subdeltoid bursa.

Interpretation:

Long head of bicep tendonitis, calcific tendonitis of the subscapularis tendon, partial tear of the supraspinatus tendon.

Diagnosis:

Torn Supraspinatus Tendon

Discussion:

Fluoroscopic arthrography was the mainstay of evaluation for rotator cuff tear until the advent of shoulder ultra-

sound and magnetic resonance imaging (MRI). Fluoroscopic arthrography is now only used for patients with suspected rotator cuff disease who have a contraindication to MRI and when shoulder ultrasound (US) expertise is not available. Fluoroscopic radiography is a useful modality for directing shoulder injections and aspirations. Aspirations are useful in diagnosing inflammatory, or septic arthroplasty.

Partial-thickness tears of the rotator cuff can be seen inferiorly at the articular surface, superiorly at the bursal surface, or within the tendon substance. Tears at the articular surface are the most common type of partial-thickness tears. Full-thickness tears of the rotator cuff tendon can be accurately identified using conventional non-arthrographic MRI with high sensitivity and specificity.

MRI can aid in detecting osseous and soft-tissue abnormalities that may predispose to, or be the result of, shoulder impingement. The soft-tissue abnormalities in the supraspinatus tendon, subacromial bursa, and biceps tendon are well seen. The osseous lesions include morphologic abnormalities of the acromion and acromioclavicular joint.

The ACR Guidelines suggest MR as the best diagnostic test (*priority score 9*) versus Ultrasound (*priority score 8*), however, ultrasound is *cheaper* and *easier* to obtain than MRI and is an excellent screening strategy to allocate patients to surgical or non-surgical treatment. If surgery is contemplated the Orthopedic specialist will determine if a shoulder MR is warranted.

Attributions

Figure 14.4A Ultrasound of the left biceps long head tendon displaying fluid by Dr. Brent Burbridge MD, FRCPC, University Medical Imaging Consultants, College of Medicine, University of Saskatchewan is used under a [CC-BY-NC-SA 4.0](#) license.

Figure 14.4B Ultrasound of the left supraspinatus tendon displaying a full thickness tear by Dr. Brent Burbridge MD, FRCPC, University Medical Imaging Consultants, College of Medicine, University of Saskatchewan is used under a [CC-BY-NC-SA 4.0](#) license.

Glenohumeral Dislocation – Anterior and Posterior

ACR – MSK – Acute Shoulder Pain

Case 1

Anterior Dislocation

Clinical:

History – This patient collided with another player on the soccer field. He immediately experienced moderate right shoulder pain. He has never had shoulder problems before.

Symptoms – He reports having a painful right shoulder with limited range of motion.

Physical – The shoulder was deformed and there is a vacant space where the humeral head should be. There was very limited, painful, range of motion.

DDx:

Humeral Dislocation

Humeral Fracture

Imaging Recommendation

[ACR – MSK – Acute Shoulder Pain, Variant 1](#)

X-rays

ODIN Link for Anterior Humeral Dislocation images, Figure 14.5A and B: <https://mistr.usask.ca/odin/?caseID=20150209141141444>

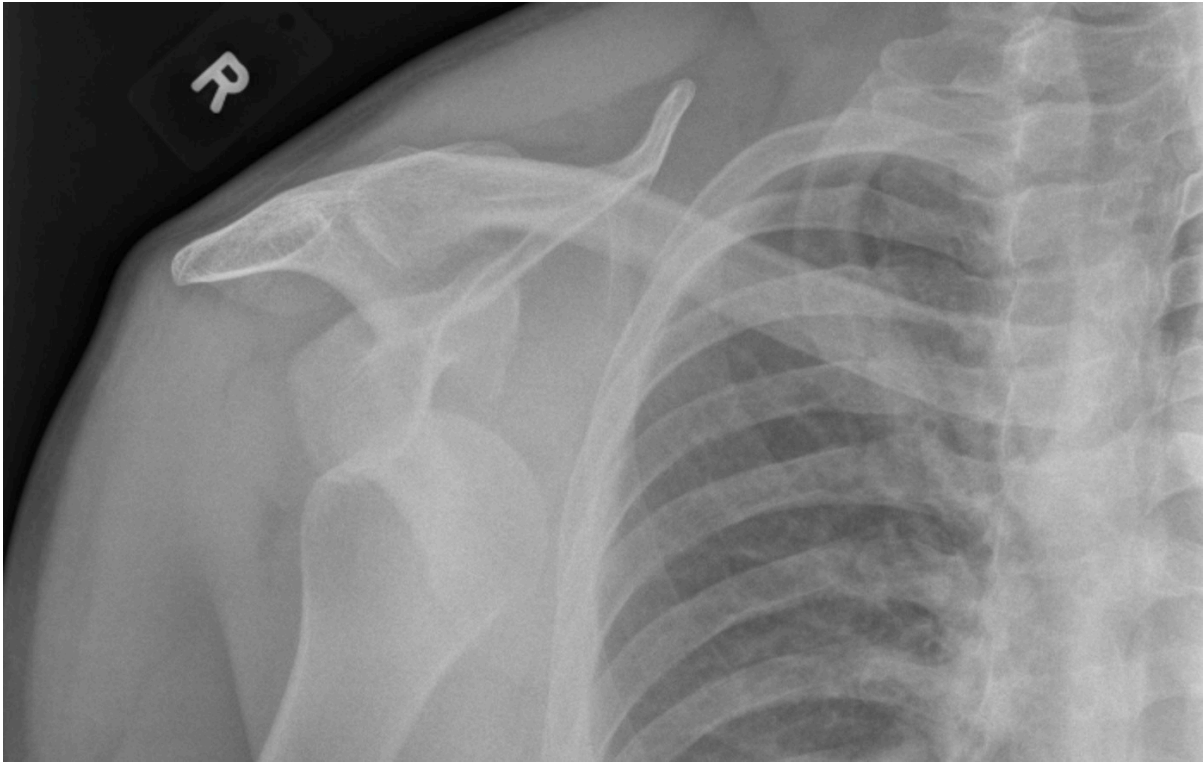


Figure 14.5A X-ray of the shoulder displaying dislocation of the humeral head

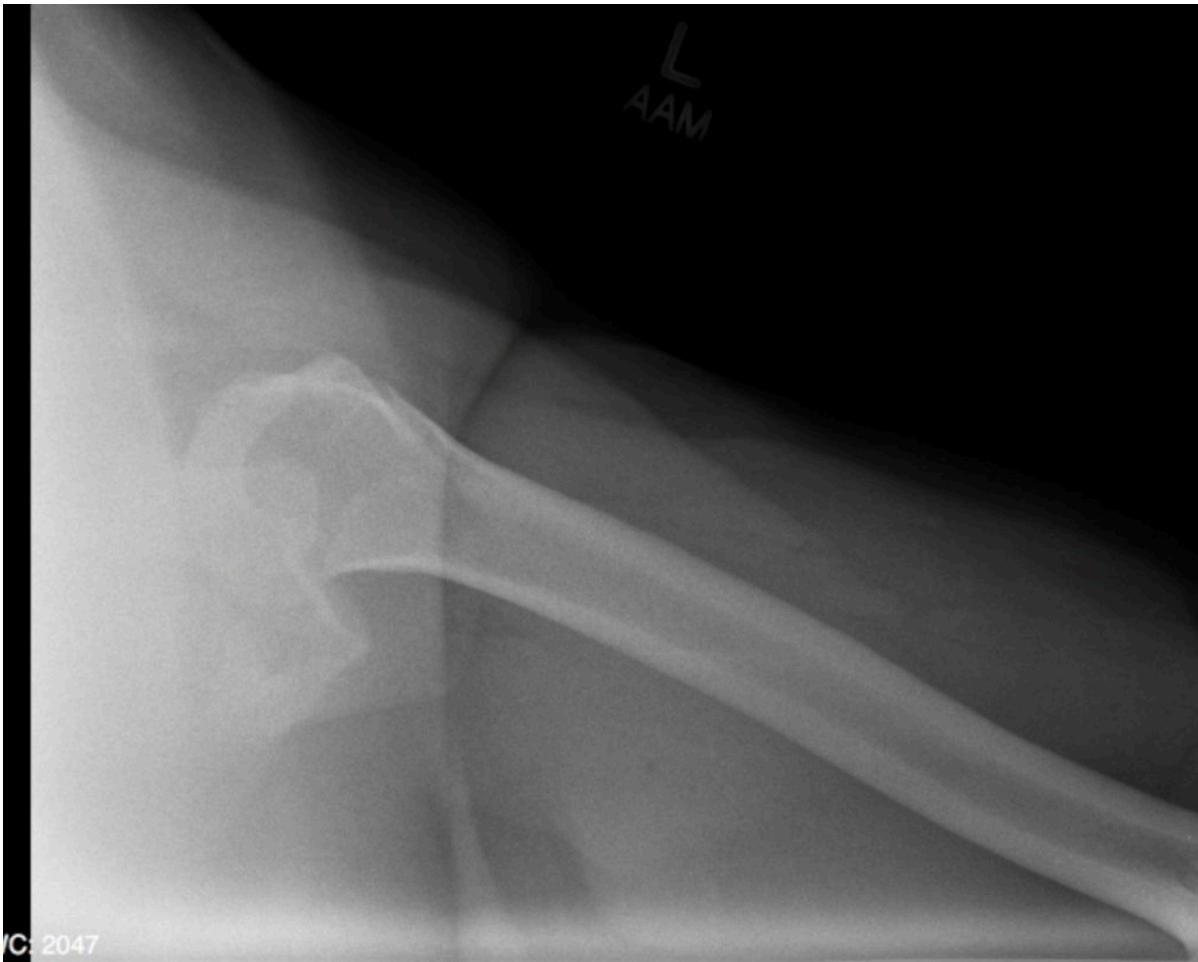

Figure 14.5B X-ray of the humerus and glenohumeral joint, axillary view, displaying anterior dislocation of the humeral head

Imaging Assessment

Findings:

The humerus was dislocated anteriorly and resides in a subcoracoid location. No fractures identified.

Interpretation:

Anterior humeral dislocation

Diagnosis:

Anterior Dislocation of the Humerus

Discussion:

Glenohumeral joint dislocation accounts for >50% of all dislocations in the body. Anterior/subcoracoid shoulder dislocation is most common form of shoulder dislocation (96%).

Mechanism: Direct blow to a externally rotated, abducted, and extended arm.

Age – Younger individuals

Anterior humeral dislocation may be associated with:

- Hill-Sachs defect (50%), is a depression fracture of the posterolateral surface of the humeral head from impaction of the head against the glenoid rim. Best demonstrated on the anteroposterior projection with the arm internally rotated.
- Bankart lesion is a fracture of anterior aspect of inferior glenoid rim. Only the cartilaginous portion of the glenoid labrum may be injured, which may only be visible on MRI.
- Fracture of greater tuberosity (15%).

Case 2

Posterior Dislocation

Clinical:

History – This patient was accidentally electrocuted while installing an oven. He has had recurrent shoulder dislocations secondary to a seizure disorder.

Symptoms – Burns on his hands from the cross-current. Confusion. Painful, immobile right shoulder.

Physical – The shoulder was deformed and almost immobile. Mobility attempts cause severe pain.

Laboratory – None.

DDx:

Posterior humeral dislocation

Humeral fracture

Imaging Recommendation

[ACR – MSK – Acute Shoulder Pain, Variant 1](#)

X-rays

ODIN Link for Posterior Humeral Dislocation images, Figure 14.6A and B: <https://mistr.usask.ca/odin/?caseID=20150209145146474>

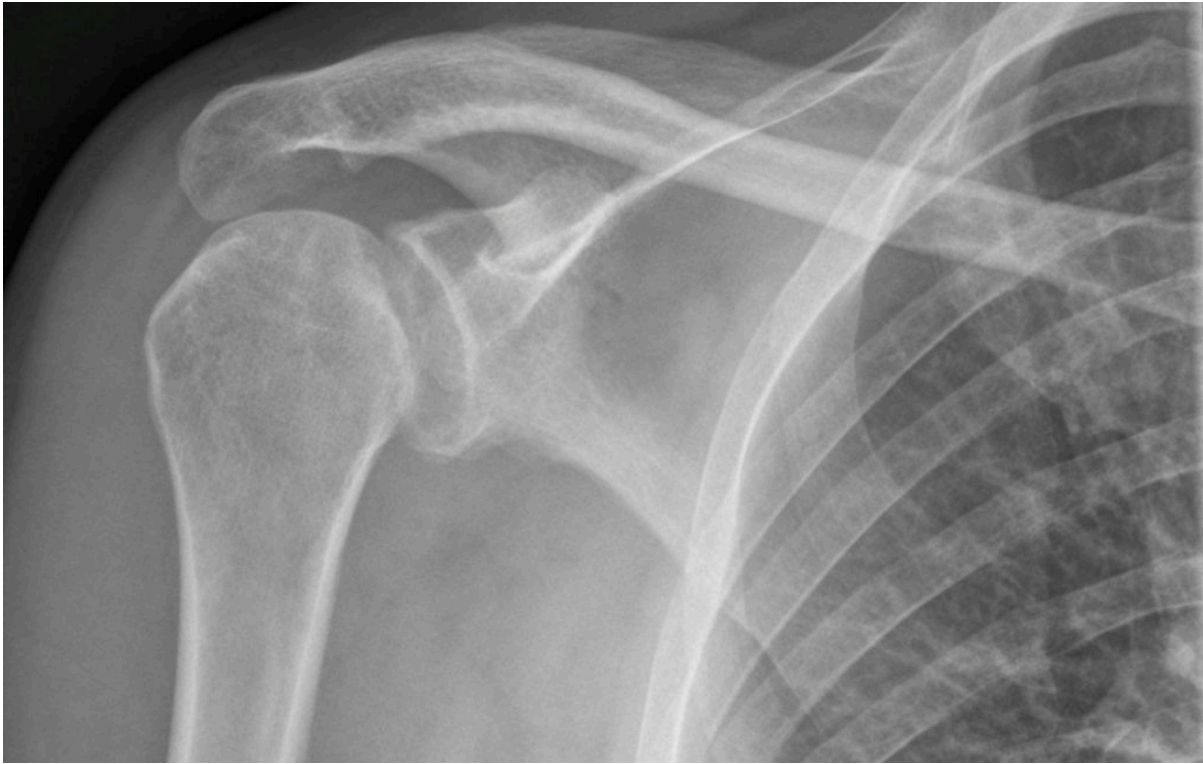


Figure 14.6A X-ray of the shoulder displaying dislocation of the humeral head

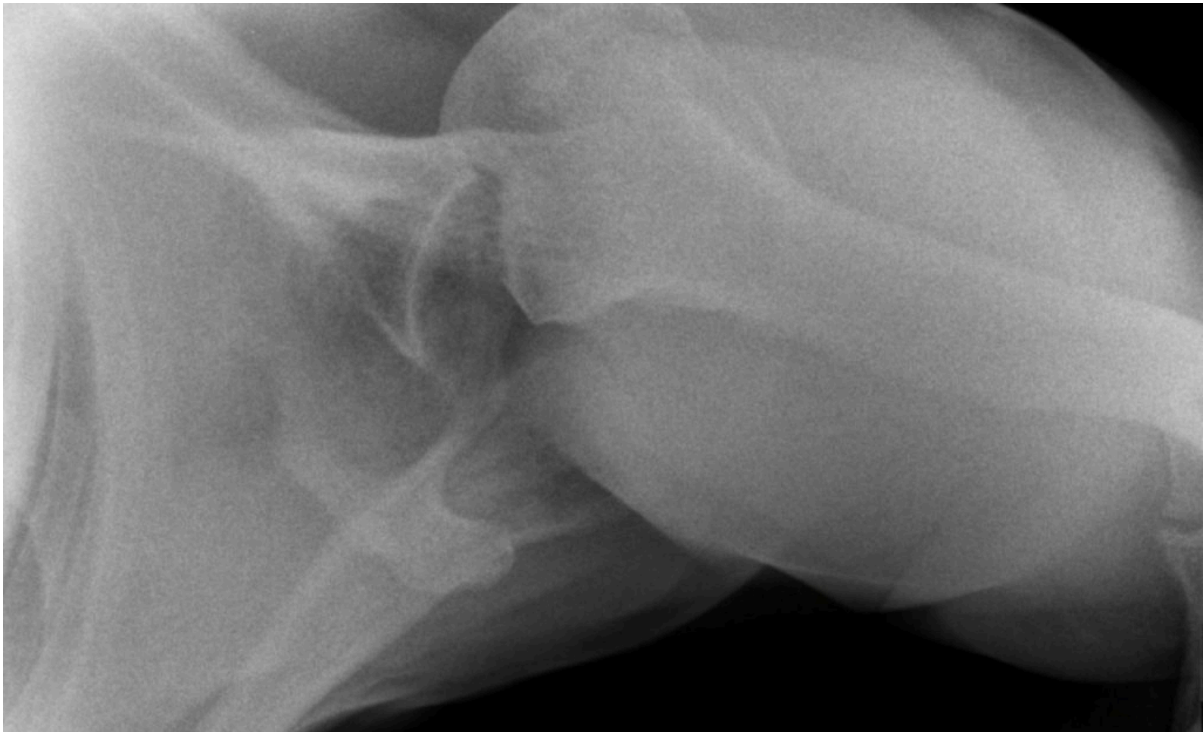

Figure 14.6B X-ray of the glenohumeral joint displaying posterior dislocation

Imaging Assessment

Findings:

The humerus was vertically oriented and had the appearance of a light bulb on the AP view. There was a posterior dislocation of the humerus. The head/neck junction was sclerotic and had a deep groove where it had chronically impacted the glenoid rim at the time of previous dislocations. The acromioclavicular joint was fused due to arthritic change.

Interpretation:

Posterior Dislocation of the Humerus

Diagnosis:

Posterior Dislocation with Reverse Hills-Sachs Deformity

Discussion:

Posterior humeral dislocations account for 14% of all glenohumeral dislocations. The patient most often has a seizure disorder.

The humeral head is fixed in internal rotation and looks like a light bulb on all views of the shoulder. Look at the axillary or Y-view to see if the head still lies within the glenoid fossa. On the Y-view (an oblique view of the shoulder), the head will lie lateral to the glenoid in a posterior dislocation.

May be associated with:

A Reverse Hills-Sachs deformity where an anterior-medial humeral head depression is formed from chronic impaction of the humeral head upon the glenoid.

Attributions

Figure 14.5B X-ray of the shoulder displaying dislocation of the humeral head by Dr. Brent Burbridge MD, FRCPC, University Medical Imaging Consultants, College of Medicine, University of Saskatchewan is used under a [CC-BY-NC-SA 4.0](#) license.

Figure 14.5C X-ray of the humerus and glenohumeral joint displaying anterior dislocation of the humeral head by Dr. Brent Burbridge MD, FRCPC, University Medical Imaging Consultants, College of Medicine, University of Saskatchewan is used under a [CC-BY-NC-SA 4.0](#) license.

Figure 14.6A X-ray of the shoulder displaying dislocation of the humeral head by Dr. Brent Burbridge MD, FRCPC, University Medical Imaging Consultants, College of Medicine, University of Saskatchewan is used under a [CC-BY-NC-SA 4.0](#) license.

Figure 14.6B X-ray of the glenohumeral joint displaying posterior dislocation by Dr. Brent Burbridge MD, FRCPC, University Medical Imaging Consultants, College of Medicine, University of Saskatchewan is used under a [CC-BY-NC-SA 4.0](https://creativecommons.org/licenses/by-nc-sa/4.0/) license.

Elbow Fractures

Case 1

Radial Head Fracture

Clinical:

History – This patient fell forward after tripping on a curb.

Symptoms – Very painful elbow.

Physical – Forearm movements were painful and limited. Tenderness was elicited over the radial head distal to the lateral epicondyle on palpation.

DDx:

Radial, ulnar, or humeral fracture

Elbow dislocation

Soft tissue trauma

Imaging Recommendation

X-ray

ODIN Link for Radial Head Fracture images (X-rays and CT), Figure 14.7A and B
– <https://mistr.usask.ca/odin/?caseID=20151214145114601>

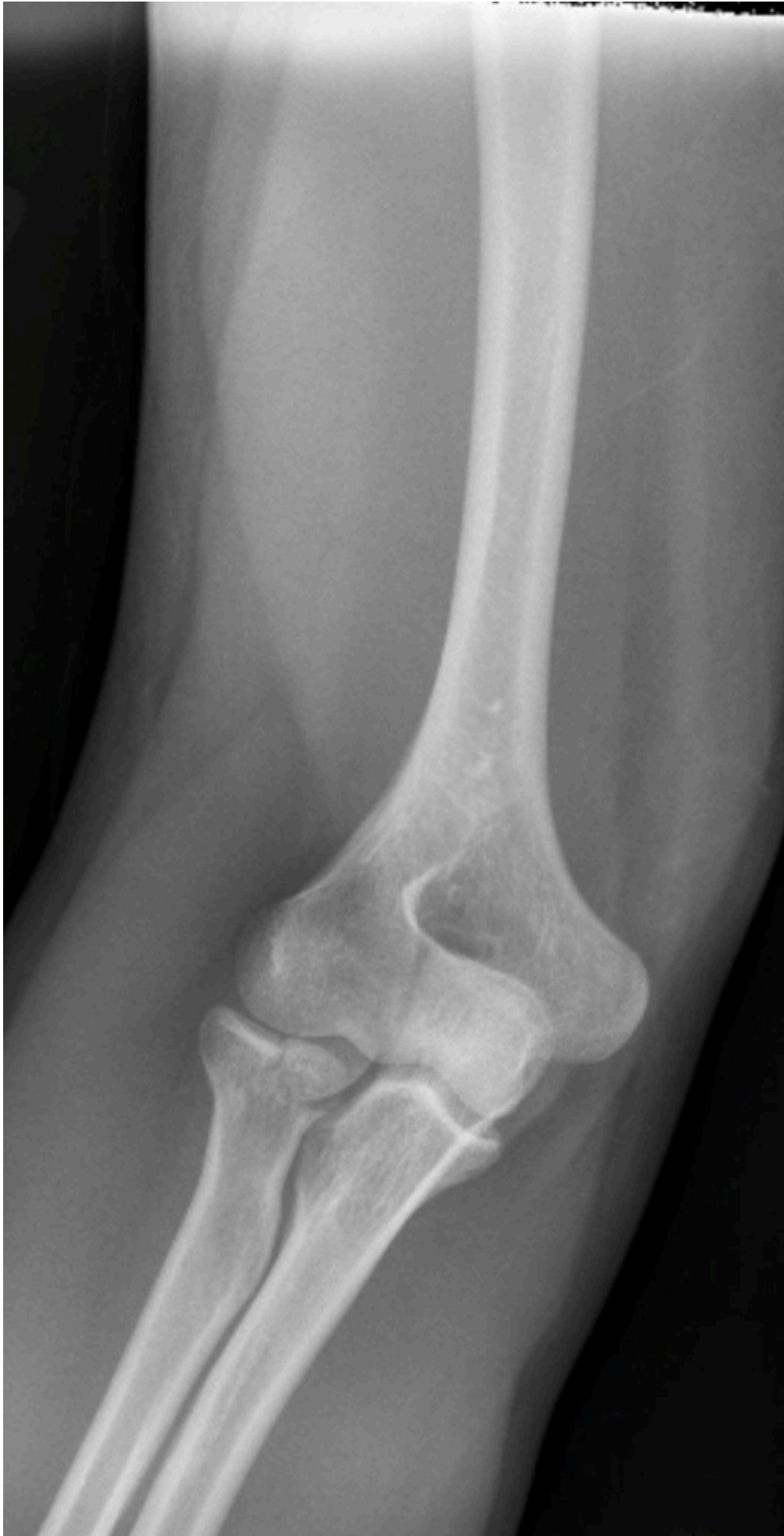

Figure 14.7A X-ray of the elbow displaying a radial head fracture

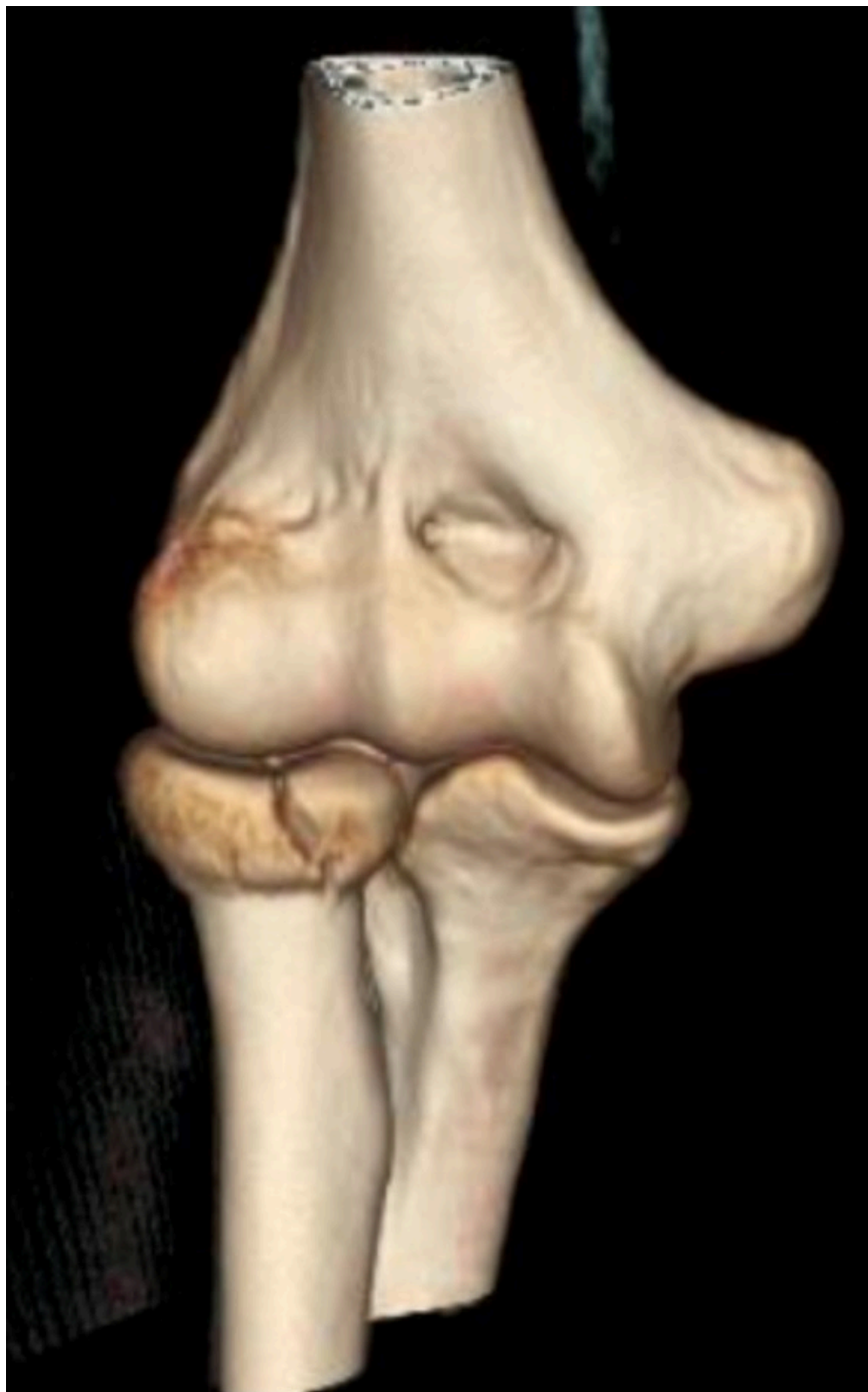

Figure 14.7B CT 3D imaging of the elbow with a radial head fracture

Imaging Assessment**Findings:**

There was a comminuted radial head fracture. This was an intra-articular fracture. No obvious loose bone fragments in the joint space on the subsequent CT.

Interpretation:

Radial head fracture, intra-articular, comminuted.

Diagnosis:

Radial head fracture, type 3, comminuted.

Discussion:

Radial head fractures are usually caused by a fall on an outstretched hand with a pronated forearm, or with the elbow in slight flexion, or a direct blow to the lateral elbow. Standard radiography is generally adequate, although an oblique or radio-capitellar view may be necessary.

X-ray findings may include:

- A variety of fracture orientations may be seen consisting of a transverse neck fracture, linear or oblique fractures in any plane, triangular or quadrangular fragments.
- There will be a joint effusion.
- There may be impaction and angulation of the radial head.

Radial head fractures are classified using the **Mason system**:

Type	Description
1	Undisplaced fracture, no mechanical obstruction
2	Presence of displacement, (>2mm) or angulation > 30 degrees
3	Comminuted fracture
4	Fracture with elbow dislocation

Table 14.1 Classification of radial head fractures based on the Mason System

Mason type I fractures are generally treated conservatively and can be managed in the primary care setting. For these fractures, the elbow is placed in a posterior splint for five to seven days, followed by early mobilization and a sling for comfort. There is some evidence supporting the immediate initiation of elbow motion in patients with

a Mason type I fracture. Imaging of Mason type I fractures should be repeated after one to two weeks to ensure appropriate alignment. Physical therapy may be added to encourage range of motion.

Orthopedic consultation is generally warranted for treatment of Mason type II through IV fractures.

Case 2

Supracondylar Fracture

Clinical:

History – This 5 year old male fell off the monkey bars.

Symptoms – Painful deformed elbow.

Physical – The elbow was swollen and very tender.

DDx:

Fracture or dislocation of the elbow

Imaging Recommendation

X-rays

ODIN Link for Supracondylar Humeral Fracture images, Figure 14.8A and B: <https://mistr.usask.ca/odin/?caseID=20150422195638755>

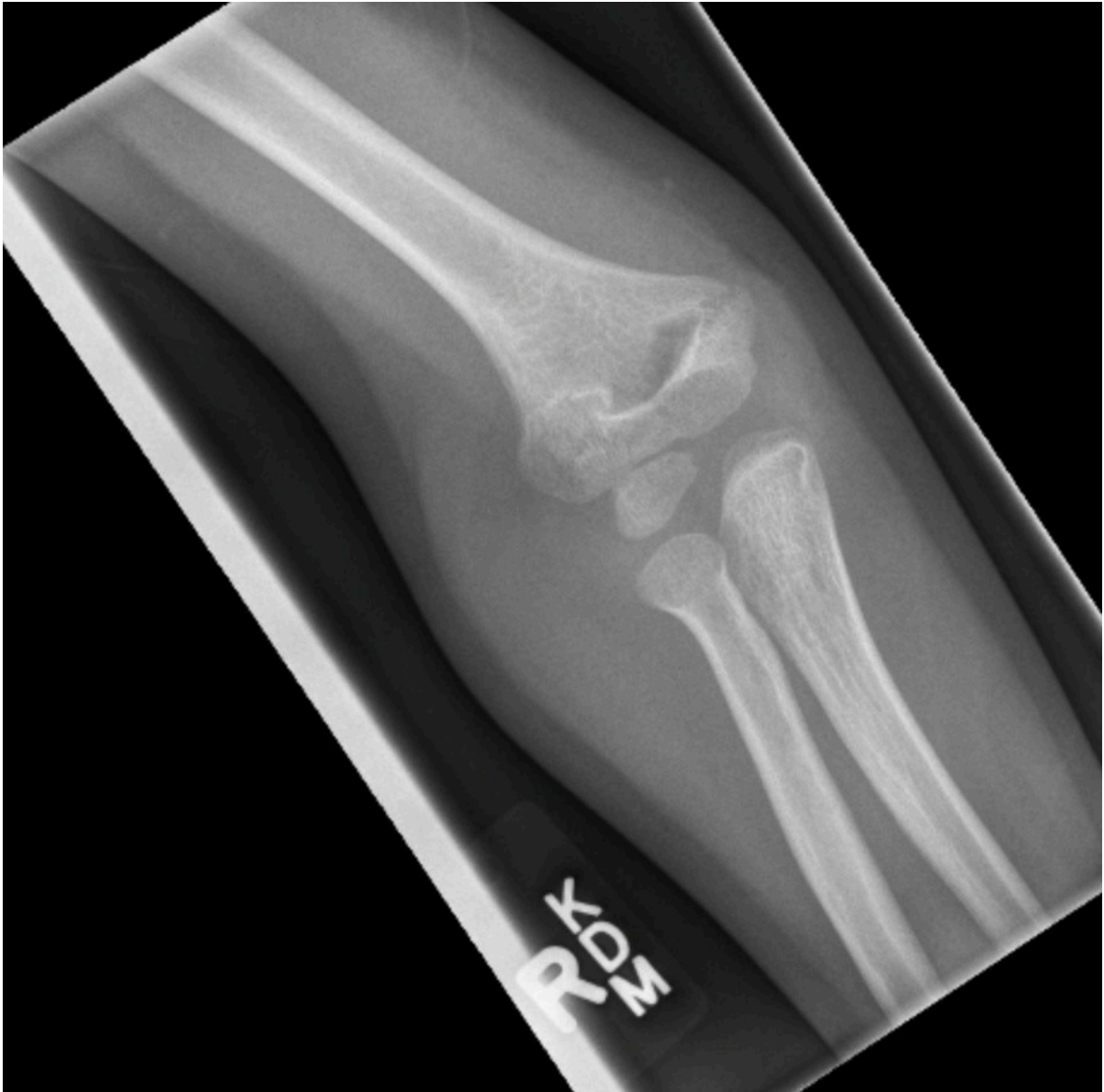


Figure 14.8A X-ray of the elbow displaying a humeral fracture

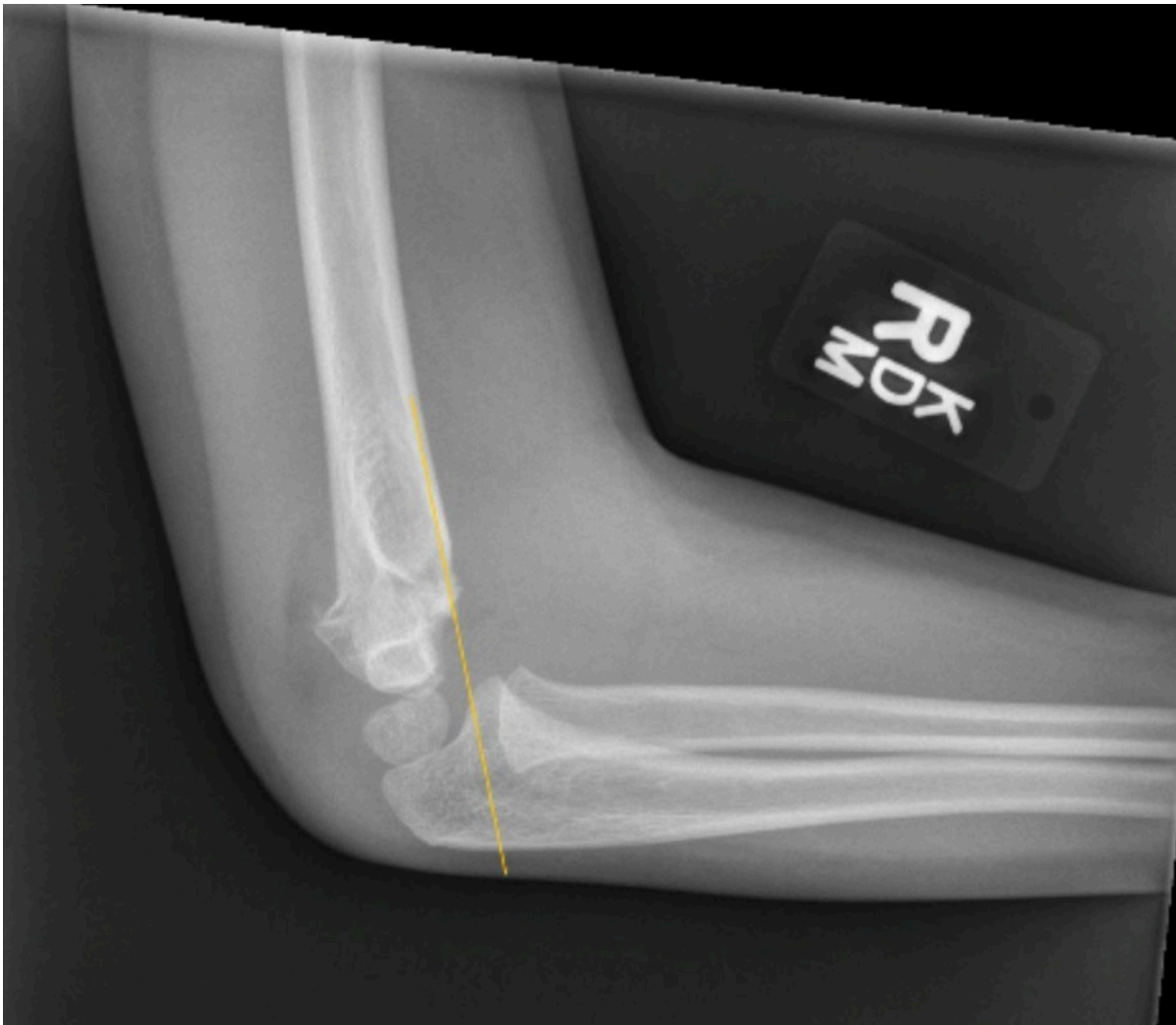


Figure 14.8B Lateral x-ray of the elbow displaying a humeral fracture. The anterior humeral line has been drawn on the image.

Imaging Assessment

Findings:

There was a displaced fracture of the distal humerus, with ventral displacement of the anterior fat pad, consistent with a joint effusion.

Interpretation:

Supracondylar humeral fracture. Orthopedic consult was recommended.

Diagnosis:

Supracondylar Humeral Fracture

Discussion:

Simple supracondylar fractures are typically seen in younger children (90%, and are uncommon in adults. These fractures are more commonly seen in boys. These injuries are almost always due to accidental trauma, such as falling from a moderate height with a hyper-extended elbow (e.g. bunk bed or monkey-bars).

Mechanism

The fracture results in an intra-articular fracture line, and when displaced there is posterior displacement of the distal humeral component.

Radiographic classification

Type I	Undisplaced
Type II	Displaced with intact cortex
Type III	Complete displacement

Table 14.2 Radiographic classification of supracondylar humeral fracture

X-ray findings may include:

- Lateral and AP radiographs are usually sufficient, and in many instances demonstrate an obvious fracture.
- Often, however, no fracture line can be identified. In such cases assessing for indirect signs is essential:
 - a) Anterior fat pad sign (sail sign): the anterior fat pad is elevated by a joint effusion and appears as a ventral, lucent triangle on the lateral projection
 - b) A visible posterior fat pad may also be seen but this is less common
 - b) Anterior humeral line should intersect the middle third of the capitellum in most children.

Treatment and prognosis

Although in many cases the fracture is easily seen, in some instances all that may be seen is soft tissue swelling or an anterior fat pad sign. Even in the absence of an obvious fracture, the patient needs to be treated with a cast. Repeating radiographs after inflammation has subsided may be helpful in demonstrating the fracture; this is typically done 7-10 days later.

Management by Type

Type I (undisplaced) fractures are stable and can be treated with a cast for approximately 3 weeks.

Type II usually require reduction (especially when angulation is more than 20 degrees). Traditionally these frac-

tures were treated with casting, however, increased risk of ischemic contracture (Volkmann contracture), has led to a higher frequency of percutaneous pinning and cast immobilization.

Type III fractures can sometimes be treated similarly to type II (closed reduction and percutaneous pinning) although frequently the fracture is held open by interposed soft tissues requiring open reduction.

Attributions

Figure 14.7A X-ray of the elbow displaying a radial head fracture by Dr. Brent Burbridge MD, FRCPC, University Medical Imaging Consultants, College of Medicine, University of Saskatchewan is used under a [CC-BY-NC-SA 4.0](#) license.

Figure 14.7B 3D imaging of the elbow with a radial head fracture by Dr. Brent Burbridge MD, FRCPC, University Medical Imaging Consultants, College of Medicine, University of Saskatchewan is used under a [CC-BY-NC-SA 4.0](#) license.

Figure 14.8A X-ray of the elbow displaying a humeral fracture by Dr. Brent Burbridge MD, FRCPC, University Medical Imaging Consultants, College of Medicine, University of Saskatchewan is used under a [CC-BY-NC-SA 4.0](#) license.

Figure 14.8B Lateral x-ray of the elbow displaying a humeral fracture. The anterior humeral line has been drawn on the image by Dr. Brent Burbridge MD, FRCPC, University Medical Imaging Consultants, College of Medicine, University of Saskatchewan is used under a [CC-BY-NC-SA 4.0](#) license.

Hand and Wrist Fractures

ACR – MSK – Acute Hand and Wrist Trauma

Case 1

Scaphoid Fracture

Clinical:

History – This patient fell and jammed her wrist while dancing.

Symptoms – Aching pain in the wrist at the base of the thumb.

Physical – There was point tenderness in the anatomic snuff box. No deformity seen.

DDx:

Thumb fracture

Scaphoid fracture

Wrist, soft tissue injury

Imaging Recommendation

[ACR – MSK – Hand and Wrist Trauma, Variant 1](#)

X-rays with a scaphoid view

ODIN Link for Scaphoid Bone Fracture images (X-rays and CT), Figure 14.9A and B:
<https://mistr.usask.ca/odin/?caseID=20150311232713868>

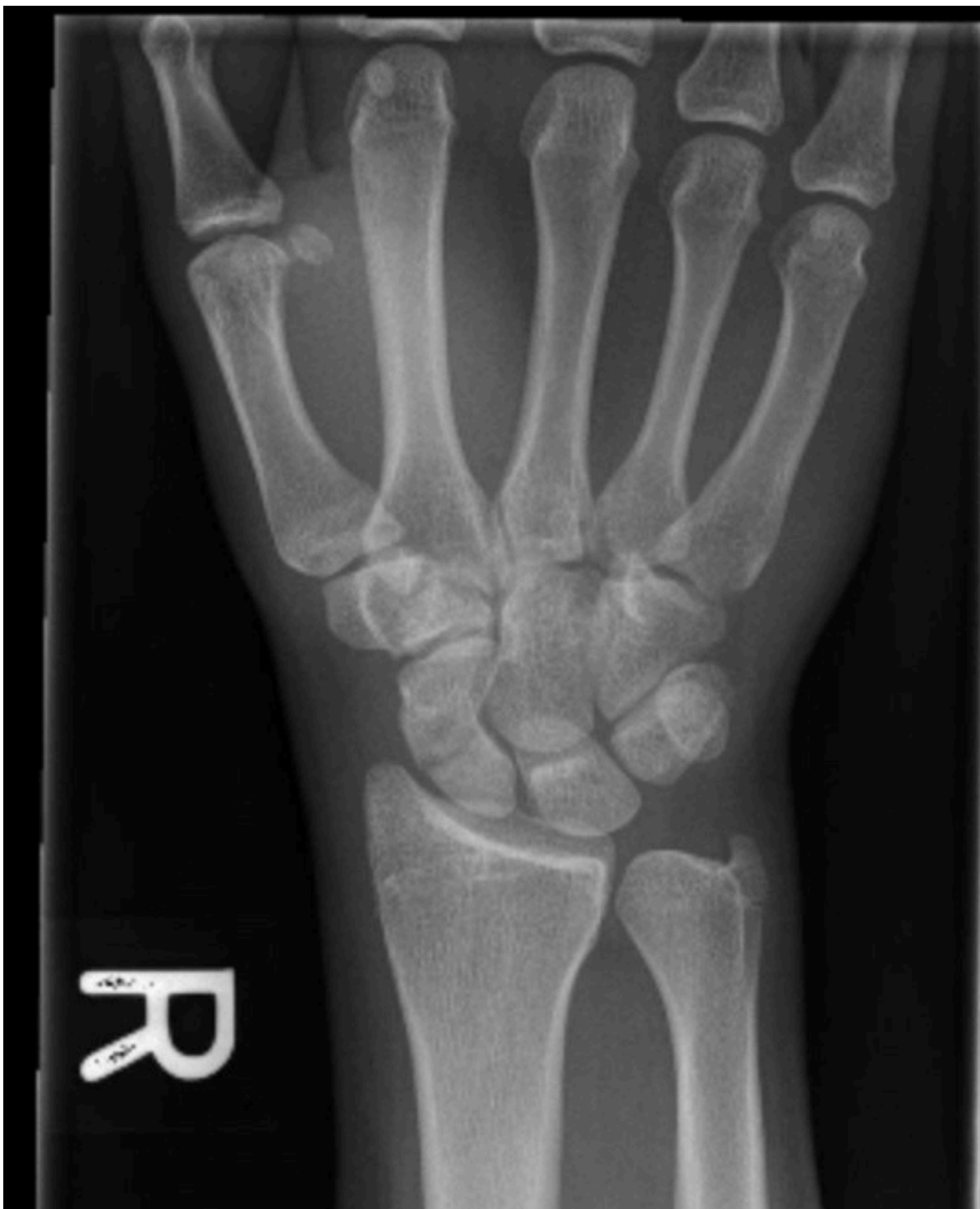

Figure 14.9A X-ray of the wrist displaying a scaphoid bone fracture

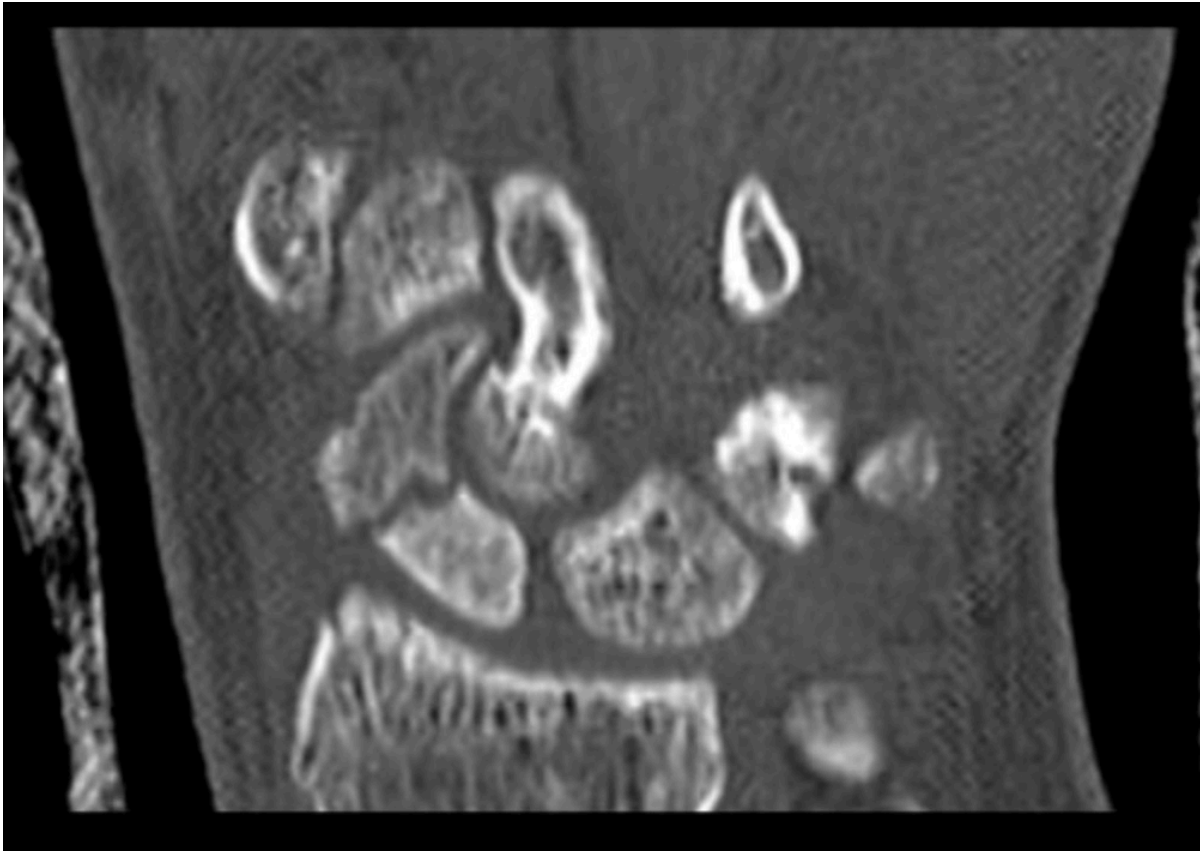


Figure 14.9B CT scan of the wrist displaying a scaphoid bone fracture.

Imaging Assessment

Findings:

X-rays – The x-rays demonstrated a transverse scaphoid fracture. The patient was casted. Follow-up x-rays 4 weeks later were suspicious for non-union. CT was requested.

CT – The CT images revealed two complications of the scaphoid fracture: a) proximal scaphoid sclerosis secondary to avascular necrosis; b) widening of the scapho-lunate distance consistent with ligamentous injury.

Interpretation:

Scaphoid fracture with non-union, avascular necrosis, and ligamentous injury.

Diagnosis:

Scaphoid fracture with complications

Discussion:

The primary mechanism of injury is a fall on the outstretched hand with an extended, radially deviated wrist,

which results in extreme dorsiflexion at the wrist and compression to the radial side of the hand. Forces are transmitted from the hand proximally to the arm through the scaphoid.

An additional fourth radiographic projection (scaphoid view)—an elongated PA view with approximately 30° of cephalad beam angulation and the wrist positioned in 10°–15° of ulnar deviation—is routinely recommended whenever there is clinical suspicion of a scaphoid fracture.

X-ray findings may include:

- A lucent fracture line. This is usually in the waist of the bone.
- Widened joint spaces consistent with inter-carpal ligament tears.
- A step deformity in the cortex of the scaphoid bone due to a fracture.

Scaphoid fractures are notoriously difficult to see on initial radiographs (regardless of the views) and are radiographically occult in up to 20% of cases. Standard practice in patients with clinically suspected scaphoid fractures, but normal initial radiographs, is to apply a cast and to repeat the clinical evaluation and radiographs in 10–14 days when resorption at the fracture line may make previously occult fractures visible. If the repeat radiographs are still normal or equivocal at that time and there continues to be a strong clinical suspicion of scaphoid fracture, imaging with a second modality – bone scintigraphy, CT, or MRI – may be indicated.

There is less evidence favouring either scintigraphy vs. CT in this scenario, although a recent meta-analysis found that MRI was superior to scintigraphy although many hospitals still perform CT or scintigraphy, and the choice of modality often depends on local preferences, expertise, and imaging modalities.

Case 2

Fifth Metacarpal Fracture

ACR – MSK – Acute Hand and Wrist Trauma

Clinical:

History – This patient accidentally punched a cement wall during a bar fight.

Symptoms – Painful hand.

Physical – The dorsum of the hand was mildly swollen. There was point tenderness overlying the distal fifth metacarpal.

DDx:

Fifth Metacarpal fracture

Other fractures

Fifth Metacarpal dislocation

Soft Tissue injury

Imaging Recommendation

[ACR – MSK – Hand and Wrist Trauma, Variant 1](#)

X-rays

ODIN Link for Fifth Metacarpal Fracture images, figure 14.10A and B: <https://mistr.usask.ca/odin/?caseID=20161129152213974>

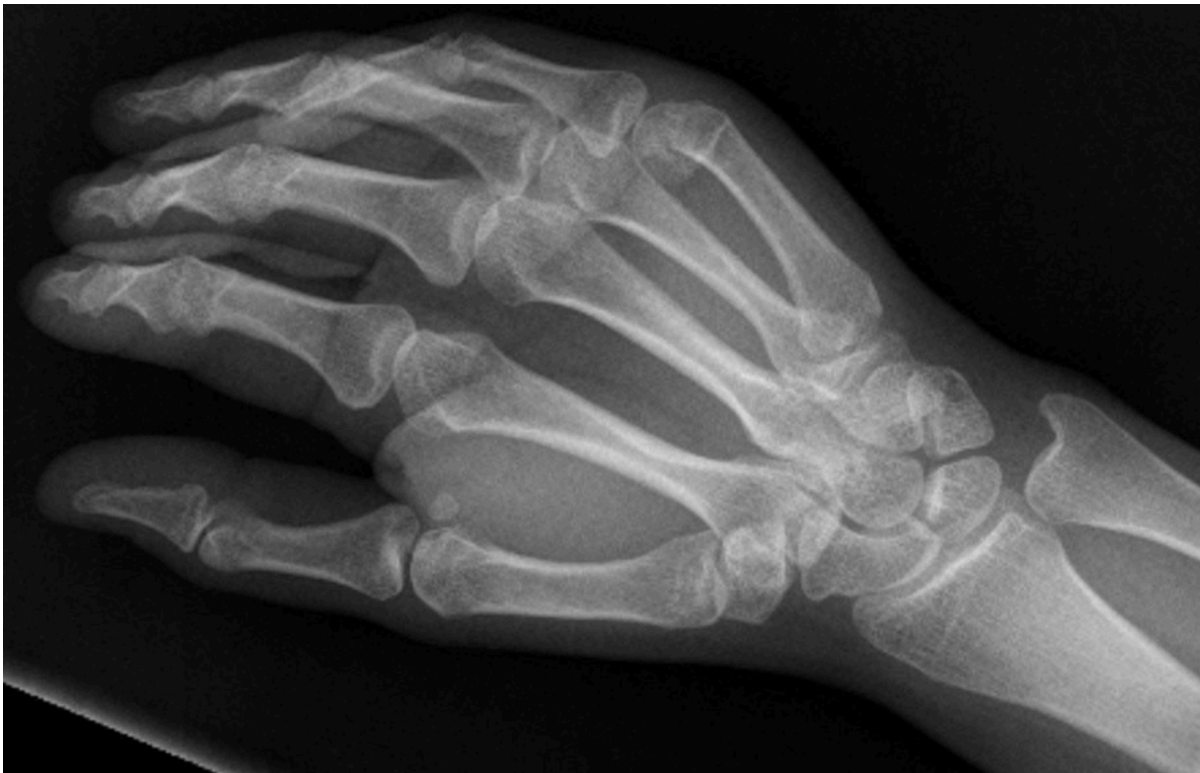

Figure 14.10A X-ray of the hand and wrist, displaying a neck of fifth metacarpal fracture.

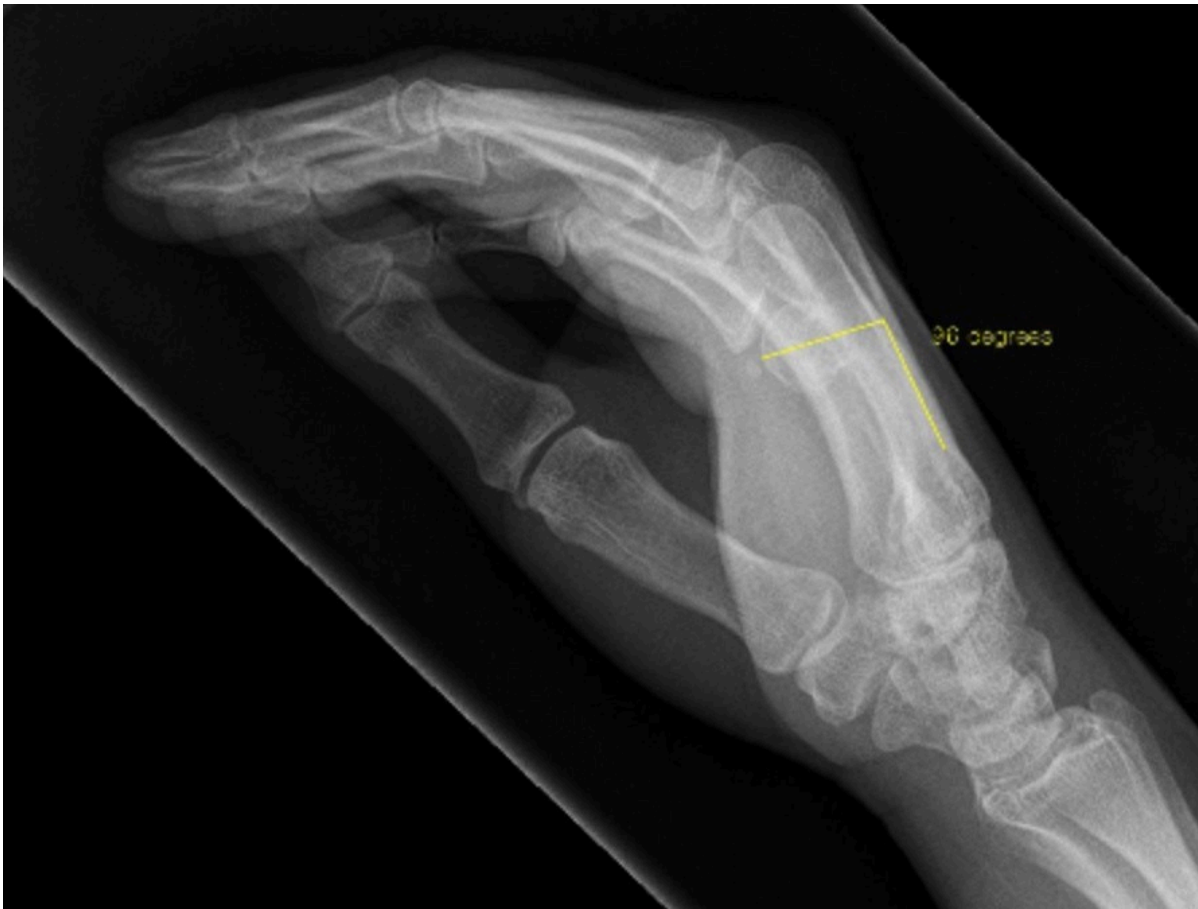

Figure 14.10B X-ray of the hand and wrist displaying a neck of fifth metacarpal fracture with the fracture angle measured.

Imaging Assessment

Findings:

The neck of the fifth metacarpal was fractured. There was significant angulation of the fracture, 80 degrees. No intra-articular abnormality.

Interpretation:

Fifth metacarpal neck fracture. Orthopedic Surgery consultation was warranted due to the angulation of the fracture.

Diagnosis:

Fifth Metacarpal Neck Fracture

Discussion:

Fifth metacarpal neck fractures occur frequently in the general population and account for around 20% of all fractures of the hand.

X-ray findings may include:

- A fracture of the neck of the bone.
- A measurement of the fracture angle should be performed.
- There may be comminution and extension of the fracture into the joint space.
- Overlying soft tissue swelling is common in acute injuries.

Clinical evaluations on patients with these fractures take into consideration shortening, rotation and angular deviation during flexion.

The closed reduction technique most used is the Jahss maneuver, which improves the degree of angulation of the distal fragment of the fracture. The decision to implement surgical treatment depends on clinical, radiographic parameters, and also on the patient's age, profession, activity level and handedness.

Attributions

Figure 14.9A X-ray of the wrist displaying a scaphoid bone fracture by Dr. Brent Burbridge MD, FRCPC, University Medical Imaging Consultants, College of Medicine, University of Saskatchewan is used under a [CC-BY-NC-SA 4.0](#) license.

Figure 14.9B CT scan of the wrist displaying a scaphoid bone fracture by Dr. Brent Burbridge MD, FRCPC, University Medical Imaging Consultants, College of Medicine, University of Saskatchewan is used under a [CC-BY-NC-SA 4.0](#) license.

Figure 14.10A X-ray of the hand and wrist, displaying a neck of fifth metacarpal fracture by Dr. Brent Burbridge MD, FRCPC, University Medical Imaging Consultants, College of Medicine, University of Saskatchewan is used under a [CC-BY-NC-SA 4.0](#) license.

Figure 14.10B X-ray of the hand and wrist displaying a neck of fifth metacarpal fracture with the fracture angle measured by Dr. Brent Burbridge MD, FRCPC, University Medical Imaging Consultants, College of Medicine, University of Saskatchewan is used under a [CC-BY-NC-SA 4.0](#) license.

Pelvic Fracture

ACR – MSK – Acute Hip Pain – Suspected Fracture Pelvic Trauma

Case

Complex pelvic bone fractures

Clinical:

History – This 27 year old male was crushed between two vehicles at a remote northern construction site. The patient required air transportation to the nearest trauma centre with CT. Immediate trauma imaging requires a portable cervical spine, chest and pelvic x-rays.

Symptoms – Major trauma. Unconscious. Intubated.

Physical – There was subcutaneous emphysema of the lower abdomen. There was severe bruising of the pelvis due to the crush injury.

DDx:

Isolated or multiple pelvic bone fractures

SI-joint diastasis

Soft tissue injury

Imaging Recommendation

[ACR – MSK – Acute Hip Pain – Suspected Fracture, Variant 1](#)

Given the severity of the injuries, CT of the abdomen and pelvis was also required (See ODIN).

ODIN Link for Pelvic Fracture images (Pre-Op x-rays, CT, Post-Op x-rays), Figure 14.11A and B:
<https://mistr.usask.ca/odin/?caseID=20160331233028913>

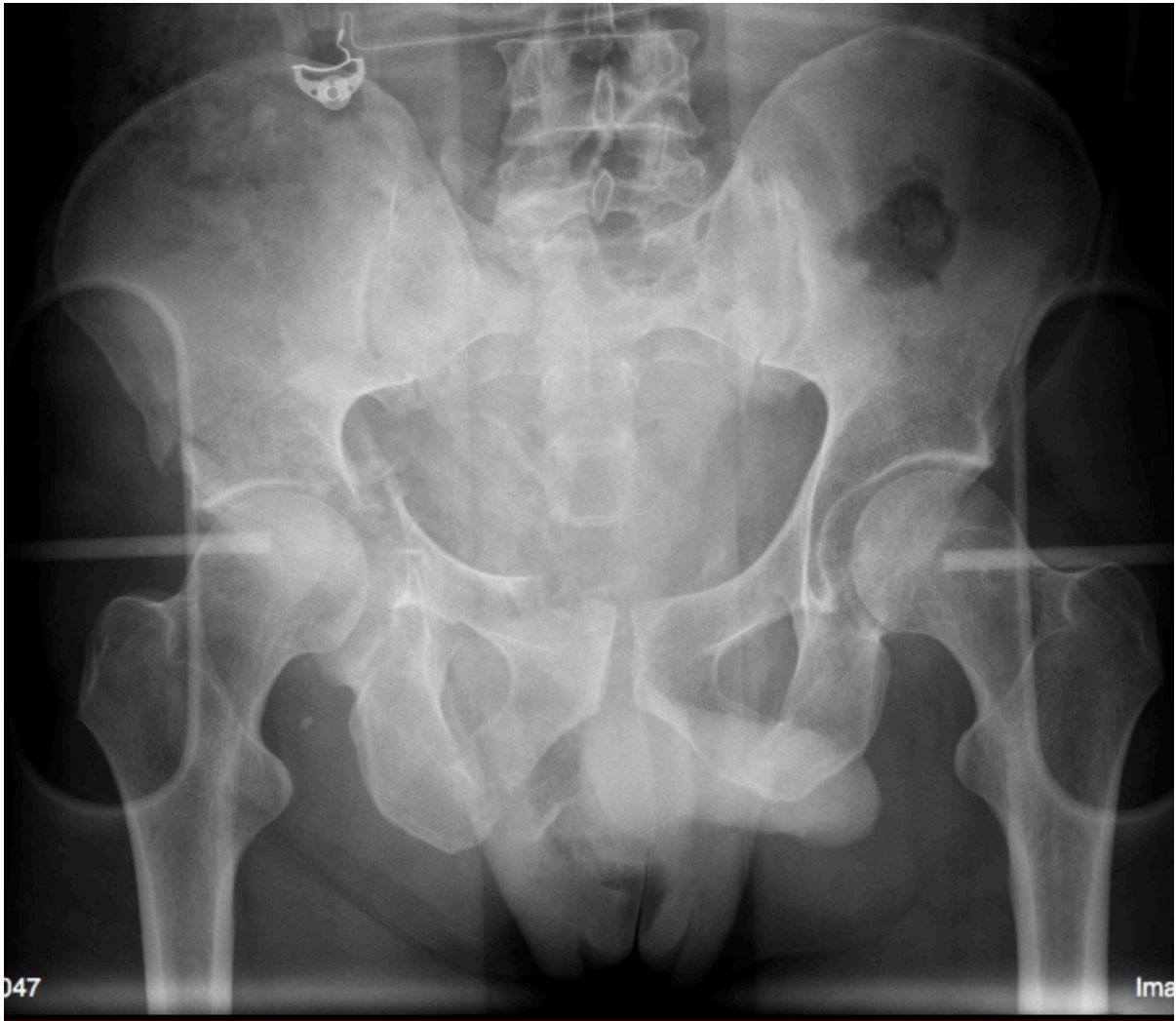

Figure 14.11A X-ray of the pelvis, pre-operative, displaying a variety of pelvic fractures.

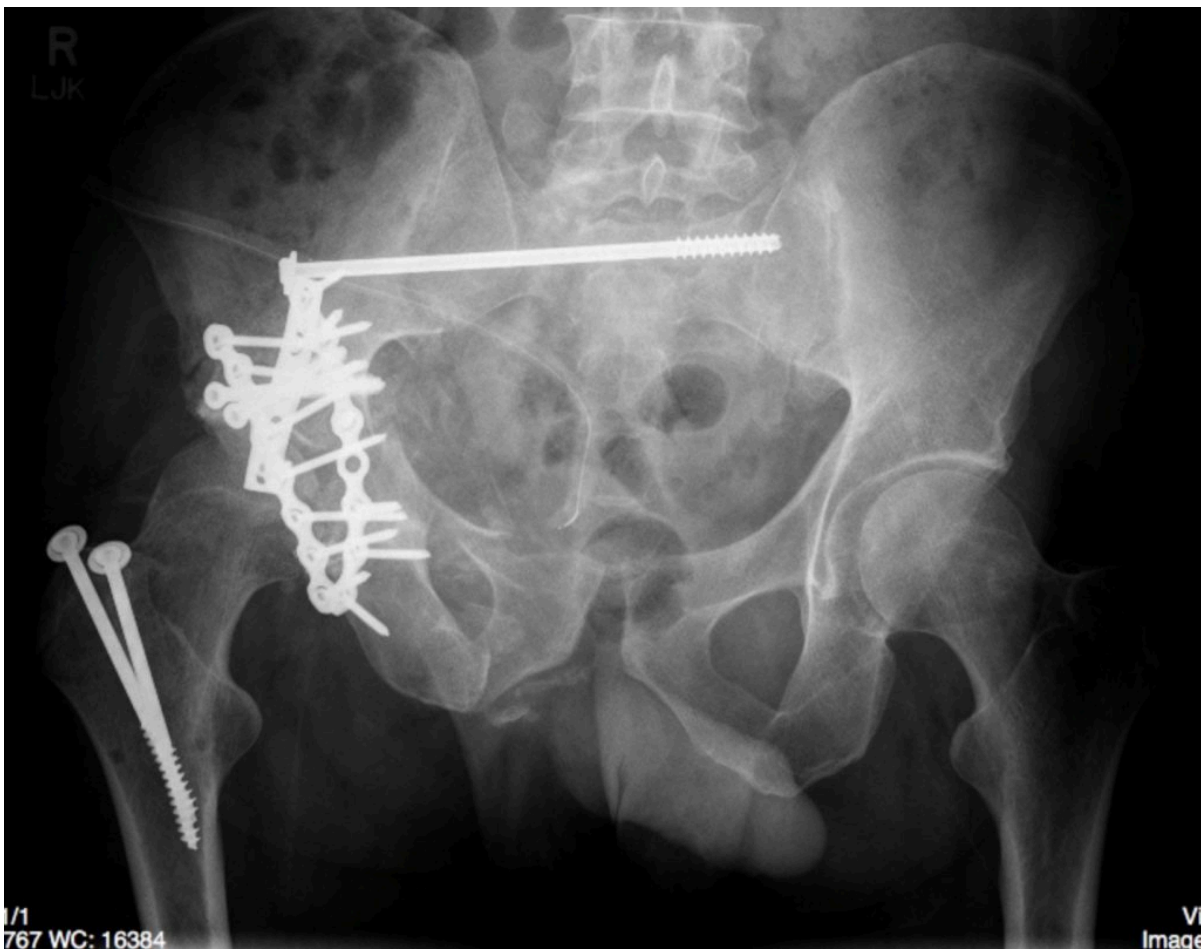

Figure 14.11B X-ray of the pelvis, post-operative fixation of pelvic fractures.

Imaging Assessment

Findings:

X-rays – The pelvic x-ray revealed fractures of the iliac bone, the acetabulum, the inferior and superior pubic rami and possibly the sacrum.

CT scanning was required. The patient required air transportation to the nearest hospital with CT.

CT – The CT revealed abdominal wall gas due to the associated chest injuries. There were multiple fractures of the pelvic bones, including the right sacrum. Right hemi-pelvic hematoma was seen. Orthopedic consultation was made urgently.

Interpretation:

Complex pelvic fractures requiring surgical management.

Diagnosis:

Complex pelvic bone fractures

Discussion:

Severe pelvic fractures are very often associated with a poly-traumatized patient with multiple injuries. Severe pelvic fractures put the patient at risk for pelvic arterial and venous bleeding. This is usually managed with external or surgical fixation of the fractures, but rarely pelvic angiography will be required to control active arterial hemorrhage.

In addition, bladder rupture and male urethral injuries are possible in the setting of the pelvic trauma.

X-ray findings may include:

- Lucent fracture lines in a variety of bones. Extension of these fractures into the hip joints and SI-joints should be assessed for.
- The SI-joints and pubic symphysis may be disrupted. As such, one side of the pelvis may be more cranially or caudally situated due this disruption.
- There may be more than one fracture with significant pelvic deformity.
- There may be significant soft tissue and pelvic tissue swelling due to edema and hematoma.

Management at a tertiary care, Trauma Centre, is imperative.

Attributions

Figure 14.11A X-ray of the pelvis, pre-operative, displaying a variety of pelvic fractures by Dr. Brent Burbridge MD, FRCPC, University Medical Imaging Consultants, College of Medicine, University of Saskatchewan is used under a [CC-BY-NC-SA 4.0](#) license.

Figure 14.11B X-ray of the pelvis, post-operative fixation of pelvic fractures by Dr. Brent Burbridge MD, FRCPC, University Medical Imaging Consultants, College of Medicine, University of Saskatchewan is used under a [CC-BY-NC-SA 4.0](#) license.

Hip Fracture – Femoral Neck Fracture

ACR – MSK – Acute Hip Pain – Suspected Fracture

Case

Femur fracture

Clinical:

History – This 88 year old male fell at the Nursing Home and had right hip pain.

Symptoms – The hip was painful and the patient couldn't weight bear.

Physical – The right leg was shorter than the left and the right foot was turned in a lateral direction. The leg pulses were normal. Range of motion of the left hip was limited by severe pain.

DDx:

Hip fracture

Hip dislocation

Femur fracture

Pelvic fracture

Imaging Recommendation

[ACR – MSK – Acute Hip Pain – Suspected Fracture, Variant 1](#)

X-Rays

ODIN Link for Femoral Fracture images (Pre and Post-Op), Figure 14.12A and B: <https://mistr.usask.ca/odin/?caseID=20150311233222626>

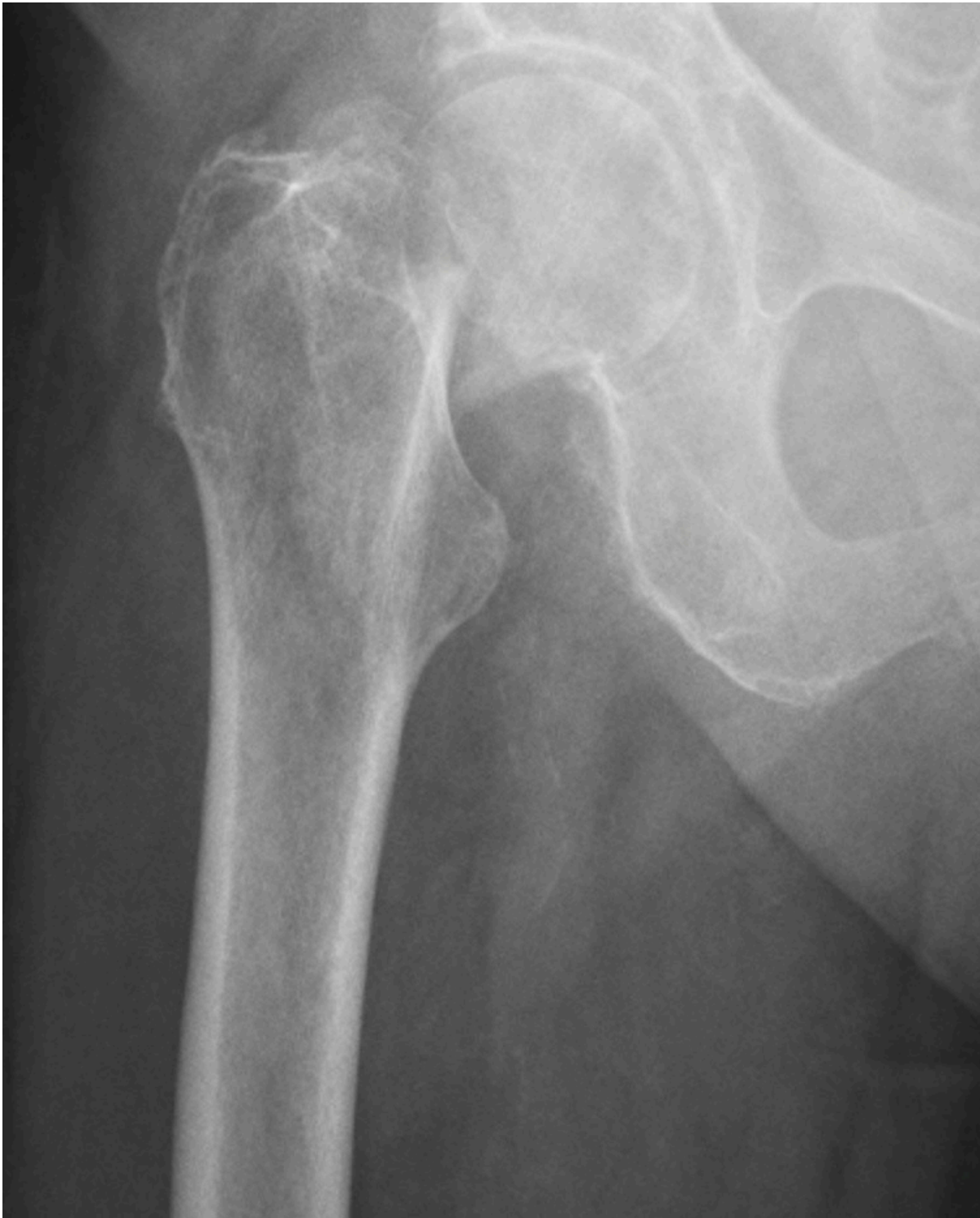

Figure 14.12A X-ray of the femur, pre-operative femoral neck fracture

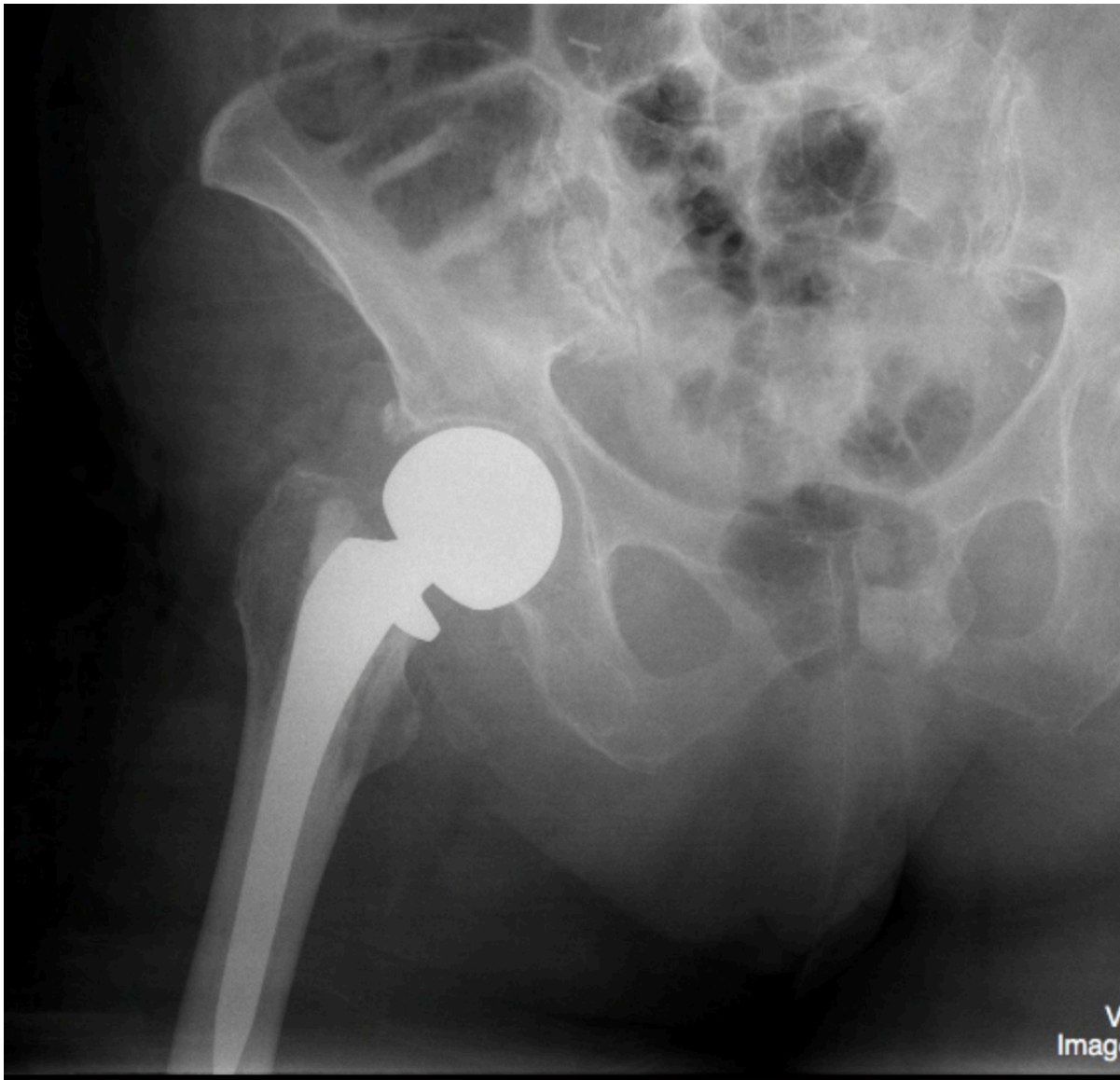


Figure 14.12B X-ray of the femur, post-operative arthroplasty

Imaging Assessment

Findings:

There was a fracture of the high femoral neck on the right. This fracture was impacted. The distal femur was displaced cranially and laterally.

Interpretation:

Femoral Neck fracture.

Subsequent images revealed that the patient had surgical management of this fracture resulting in the placement of an Austin-Moore prosthesis.

Diagnosis:

Femur fracture

Discussion:

Femoral neck fractures are a subset of proximal femoral fractures. The femoral neck is the weakest part of the femur. Since disruption of blood supply to the femoral head causes significant morbidity, diagnosis and classification of these fractures is important. Avascularity of the femoral head is more common with fractures that are cranially situated in the femoral neck. Neck of femur fractures are considered intracapsular fractures.

Intracapsular fractures include:

- Subcapital: femoral head/neck junction
- Transcervical: mid-portion of femoral neck
- Basicervical: base of femoral neck

Mechanism:

- Falls in the elderly;
- Trauma (e.g. motor vehicle collisions) in younger patients.

In elderly patients, the mechanism of injury varies from falls directly onto the hip to a twisting mechanism in which the patient's foot is planted and the body rotates. The mechanism in young patients is predominantly axial loading during high energy trauma, with an abducted femur position resulting in a femoral neck fracture while an adducted femur position often results in a fracture-dislocation of the hip with secondary acetabular injury.

X-ray findings may include:

- Shenton's line disruption: loss of contour between normally continuous line from medial edge of femoral neck and inferior edge of the superior pubic ramus
- Lesser trochanter is more prominent due to external rotation of femur
- Femur often positioned in flexion and external rotation (due to unopposed iliopsoas)
- Asymmetry of lateral femoral neck/head
- Sclerosis in fracture plane
- Smudgy sclerosis from impaction
- Bone trabeculae angulated
- Non-displaced fractures may be subtle on x-ray

Treatment:

Significant complications such as avascular necrosis (AVN) and non-union are very common without surgical intervention. The treatment options include non-operative management, internal fixation or prosthetic replacement.

Internal fixation can be performed with multiple pins, intramedullary hip screw (IMHS), crossed screw-nails or compression with a dynamic screw and plate.

Replacing the femoral head is achieved with either hemiarthroplasty or total hip arthroplasty.

Prognosis is varied, but is complicated by advanced age, as hip fractures increase the risk of death and major morbidity in the elderly. High morbidity and mortality associated with hip and pelvic fractures after trauma has been well documented.

The risk of AVN depends on the fracture. The Delbet classification correlates with the risk of AVN:

Type	Description	Risk of AVN
Type 1	Transphyseal	~ 90%
Type 2	Subcapital	~ 50%
Type 3	Basicervical / transcervical	~ 25%
Type 4	Intertrochanteric	~ 10%

Table 14.3 Delbet Classification for risk of AVN with femoral neck fracture. <https://radiopaedia.org/articles/femoral-neck-fracture>

As a general rule, internal fixation is recommended for young, otherwise fit patient with small risk for AVN. While prosthetic replacement is reserved for fractures with high risk of AVN and the elderly.

Attributions

Figure 14.12A X-ray of the femur, pre-operative femoral neck fracture by Dr. Brent Burbridge MD, FRCPC, University Medical Imaging Consultants, College of Medicine, University of Saskatchewan is used under a [CC-BY-NC-SA 4.0](https://creativecommons.org/licenses/by-nc-sa/4.0/) license.

Figure 14.12B X-ray of the femur, post-operative arthroplasty by Dr. Brent Burbridge MD, FRCPC, University Medical Imaging Consultants, College of Medicine, University of Saskatchewan is used under a [CC-BY-NC-SA 4.0](https://creativecommons.org/licenses/by-nc-sa/4.0/) license.

Knee Trauma – Acute Fractures

ACR – MSK – Acute Knee Trauma

Case

Comminuted, Intra-articular, Tibial Fractures

Clinical:

History– This 18 year old male injured his knee in a trampoline accident.

Symptoms – Painful, swollen knee. Unable to weight bear.

Physical – The knee was swollen and there was tenderness of the tibia below the joint line. An effusion was present. There was a sense of crepitation with knee range of motion.

DDx:

Femur fracture

Tibia fracture

Knee dislocation

Imaging Recommendation

[ACR – MSK – Acute Knee Trauma, Variant 2](#)

X-rays

CT will be required if there is intra-articular bone injury.

MR is the best modality for suspected ligamentous injury.

ODIN Link for Knee Trauma images (X-rays and CT), Figure 14.13A and B: <https://mistr.usask.ca/odin/?caseID=20150320080231242>

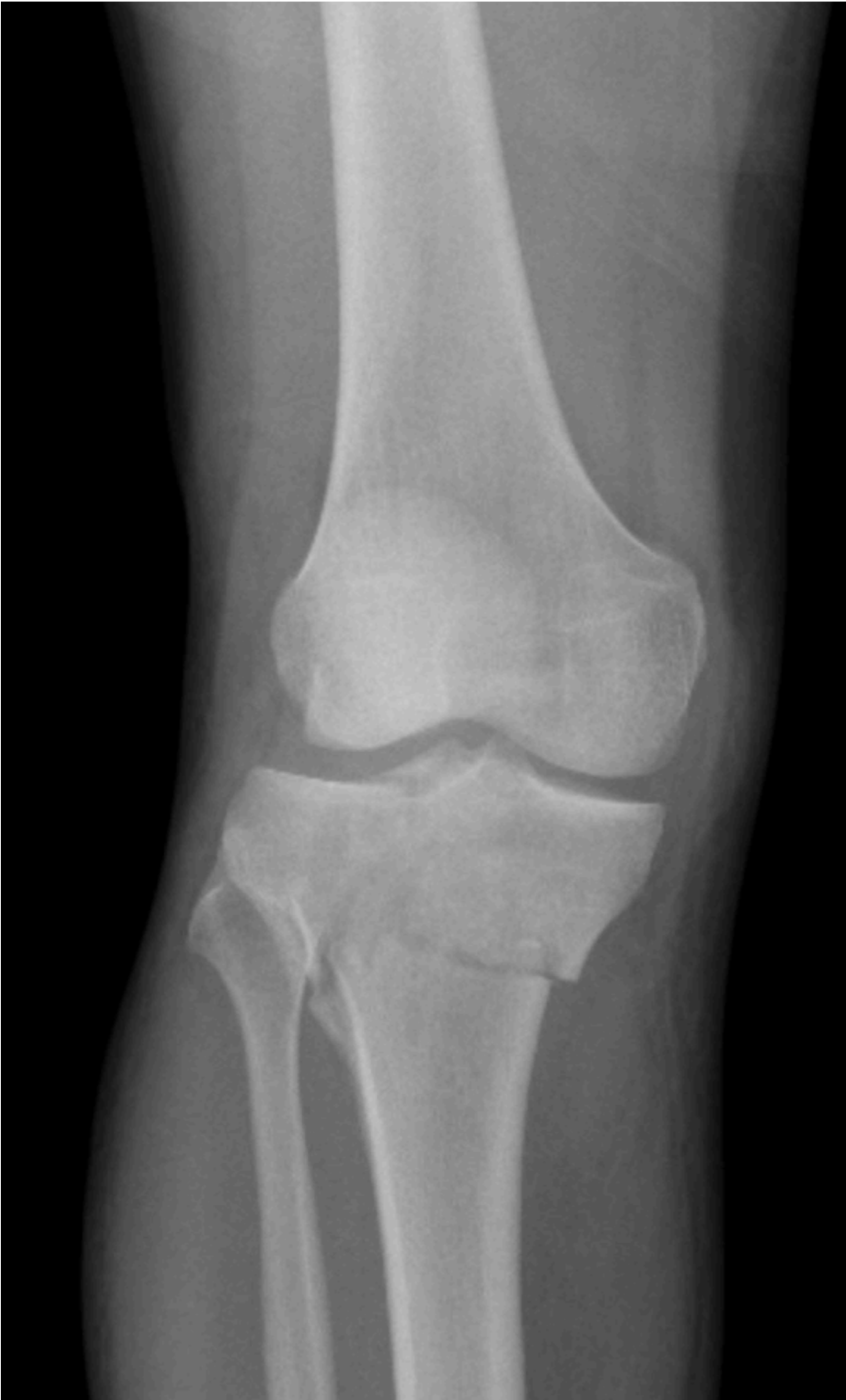

Figure 14.13A X-ray of the knee displaying a complex tibial fracture

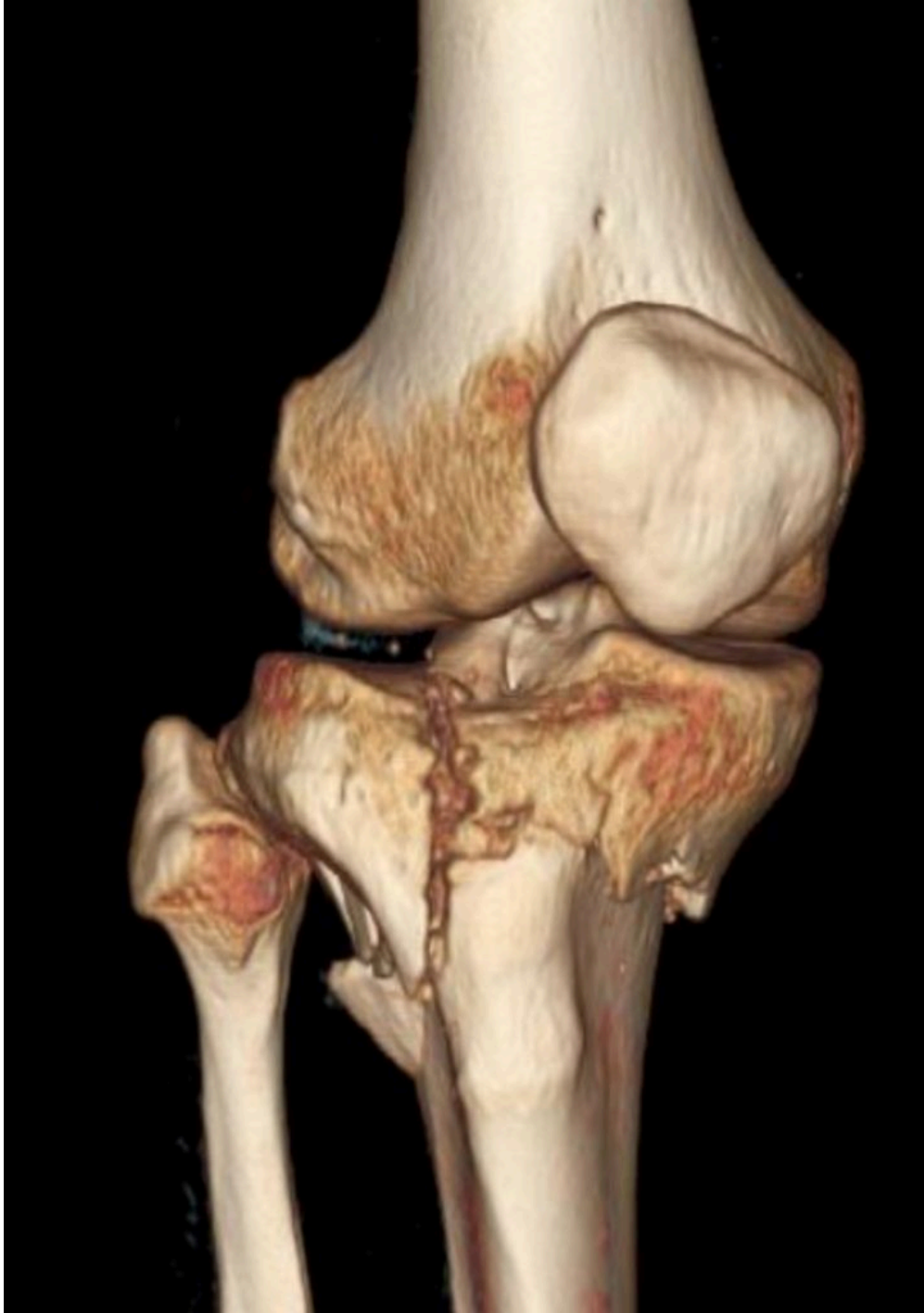

Figure 14.13B 3D image of the knee, displaying a complex tibial fracture

Imaging Assessment

Findings:

X-ray – There was a comminuted, intra-articular fracture of the tibia. A fat-fluid level was seen in the knee joint due to marrow from the tibia communicating with the joint fluid. Alignment was satisfactory.

Interpretation:

Comminuted Tibial fracture. CT was recommended.

Diagnosis:

Comminuted, Intra-articular, Tibial Injury

CT Findings –

There was an intra-articular fracture of the tibia with joint fluid, fat, and blood. The fracture was complex and therefore it required surgical fixation in the operating room.

Discussion:

Clinical decision rules for the acutely injured knee suggest that radiographic examination of the knee following acute injury can be eliminated in many instances by applying specific clinical guidelines. A commonly used clinical decision rule is the Ottawa Knee Rule.

The **Ottawa Knee Rule** states that patients ≥ 18 years old with acute knee pain should have knee radiographs if they meet any of the following criteria:

- Are 55 years of age or older,
- Have palpable tenderness over the head of the fibula,
- Have isolated patellar tenderness,
- Cannot flex the knee to 90° ,
- Cannot weight bear immediately following the injury, or
- Cannot walk in the emergency room i.e. can't take 4 steps.

X-ray findings may include:

- Visible fractures of the patella, femur, or tibia (multiple bones fractured possible).
- Generalized soft tissue swelling.
- Joint effusion may be present.
- If fat has entered the joint space from the marrow of a bone a fat-fluid level will be present.
- Angulation of the bones should be assessed.
- The knee joint, and patella, may be subluxated or dislocated.

Clinical decision rules, such as the **Ottawa Knee Rule**, are well validated and have been shown to reduce the number of radiographs obtained for acute knee trauma while still identifying almost all patients who have a fracture. It is generally agreed that radiographs should be obtained and the clinical decision rule should not be applied for patients with gross deformity, a palpable mass, a penetrating injury, prosthetic hardware, an unreliable clinical history or physical examination secondary to multiple injuries, altered mental status (e.g., head injury, drug or alcohol use, dementia), neuropathy (e.g., paraplegia, diabetes), or a history suggesting increased risk of fracture. The physician's judgment and common sense, however, should supersede clinical guidelines.

Attributions

Figure 14.13A X-ray of the knee displaying a complex tibial fracture by Dr. Brent Burbridge MD, FRCPC, University Medical Imaging Consultants, College of Medicine, University of Saskatchewan is used under a [CC-BY-NC-SA 4.0](#) license.

Figure 14.13B 3D image of the knee, displaying a complex tibial fracture by Dr. Brent Burbridge MD, FRCPC, University Medical Imaging Consultants, College of Medicine, University of Saskatchewan is used under a [CC-BY-NC-SA 4.0](#) license.

Ankle Trauma, Fractures

ACR – MSK – Acute Ankle Trauma

Case

Tri-malleolar fracture of the ankle

Clinical:

History – This 27 year old male caught the toe of his shoe under third base when sliding. He was in severe pain.

Symptoms – The patient was in severe pain. He reported that he could not bear weight on his ankle.

Physical – He had a deformed ankle with fracture blisters present. Severe tenderness was detected on palpation. Pulses were normal.

DDx:

Ankle dislocation

Ankle fracture

Imaging Recommendation

[ACR – MSK – Acute Trauma to the Ankle, Variant 1](#)

X-rays

ODIN Link for Ankle Fracture images, Figure 14.14A and B: <https://mistr.usask.ca/odin/?caseID=20150317215510072>

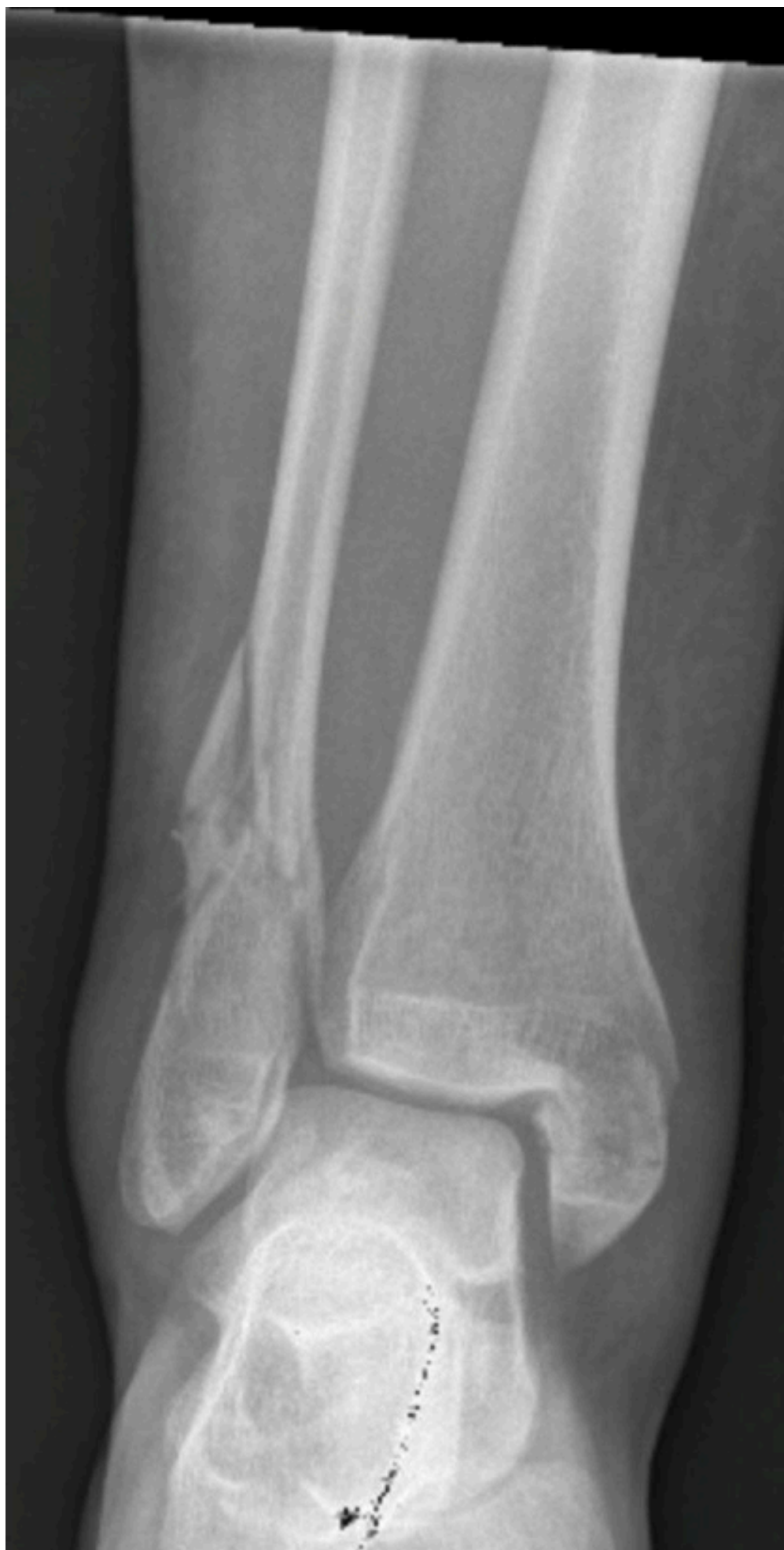

Figure 14.14A X-ray of the ankle, displaying fractures

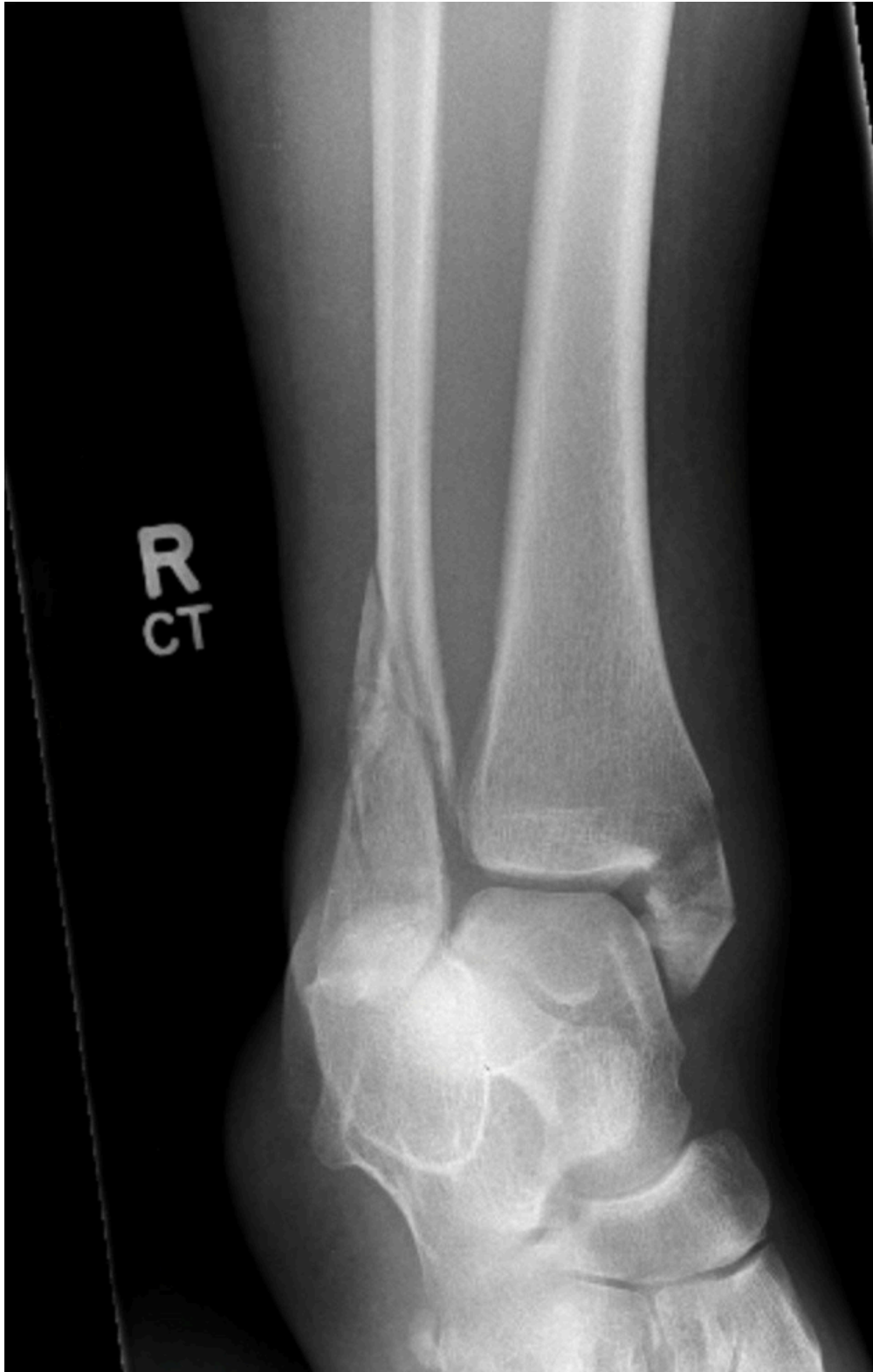

Figure 14.14B X-ray of the ankle, displaying fractures

Imaging Assessment

Findings:

There was a transverse fracture of the medial malleolus associated with an oblique fracture of the fibula above the level of the ankle joint. A small, minimally displaced, posterior malleolar fracture was also seen on the lateral view. The fibular fracture was mildly laterally displaced.

Interpretation:

Tri-malleolar fracture of the ankle

Diagnosis:

Tri-malleolar fracture of the ankle

Discussion:

Given the relatively low incidence of fracture in patients experiencing ankle trauma, the **Ottawa Ankle Rule (OAR)** criteria were established to identify those patients with sufficiently low probability of fracture that they can safely be treated without radiographic evaluation. Subsequently, the validation and cost-effectiveness of these guidelines have been confirmed in numerous studies and have been extended to a variety of outpatient practice settings.

The OAR guidelines recommend ankle radiographs in patients with the following clinical findings:

- 1) **inability to bear weight** immediately after the injury and take 4 steps in the ED or;
- 2) **bone tenderness** at the posterior edge and tip of either malleolus.

An evaluation of the traumatized ankle should consist of anteroposterior (AP), lateral, and mortise views of the ankle. Additional views can be added to the minimal series in questionable cases. In the setting of suspected deltoid ligament disruption following supination-external rotation injuries of the ankle, a gravity-stress view has been shown to be as reliable and is perceived to be more comfortable than x-rays obtained with manual stress. The fifth metatarsal base distal to the tuberosity should be seen on at least one projection. The use of a pertinent clinical history for the site of point tenderness will decrease the miss rate for subtle fractures by approximately 50%.

X-ray findings may include:

- Generalized or localized soft tissue swelling.
- Fractures may be seen in the medial malleolus, the lateral malleolus, the posterior tibia and in the fibula.
- Joint space widening, the ankle mortice, may be present.

- A joint effusion may be seen.
- The relationship of the fibula to the distal tibia may be disrupted.

Attributions

Figure 14.14A X-ray of the ankle, displaying fractures by Dr. Brent Burbridge MD, FRCPC, University Medical Imaging Consultants, College of Medicine, University of Saskatchewan is used under a [CC-BY-NC-SA 4.0](#) license.

Figure 14.14B X-ray of the ankle, displaying fractures by Dr. Brent Burbridge MD, FRCPC, University Medical Imaging Consultants, College of Medicine, University of Saskatchewan is used under a [CC-BY-NC-SA 4.0](#) license.

Degenerative Joint Diseases – Hip

ACR – MSK – Chronic Extremity Joint Pain

Case

Hip Osteoarthritis.

Clinical:

History – This elderly patient had chronic hip pain, right worse than left.

Symptoms – The chronic pain was limiting the patients activities.

Physical – Limited, painful, range of motion. Limp when walking. Stiffness upon arising from a chair or bed.

DDx:

Degenerative arthritis (Osteoarthritis) of the hip

Imaging Recommendation

[ACR – MSK – Chronic Extremity Joint Pain](#)

X-rays

ODIN Link for Hip Joint Degeneration, Mild, images, Figure 14.15A and B: <https://mistr.usask.ca/odin/?caseID=20150318110848871>

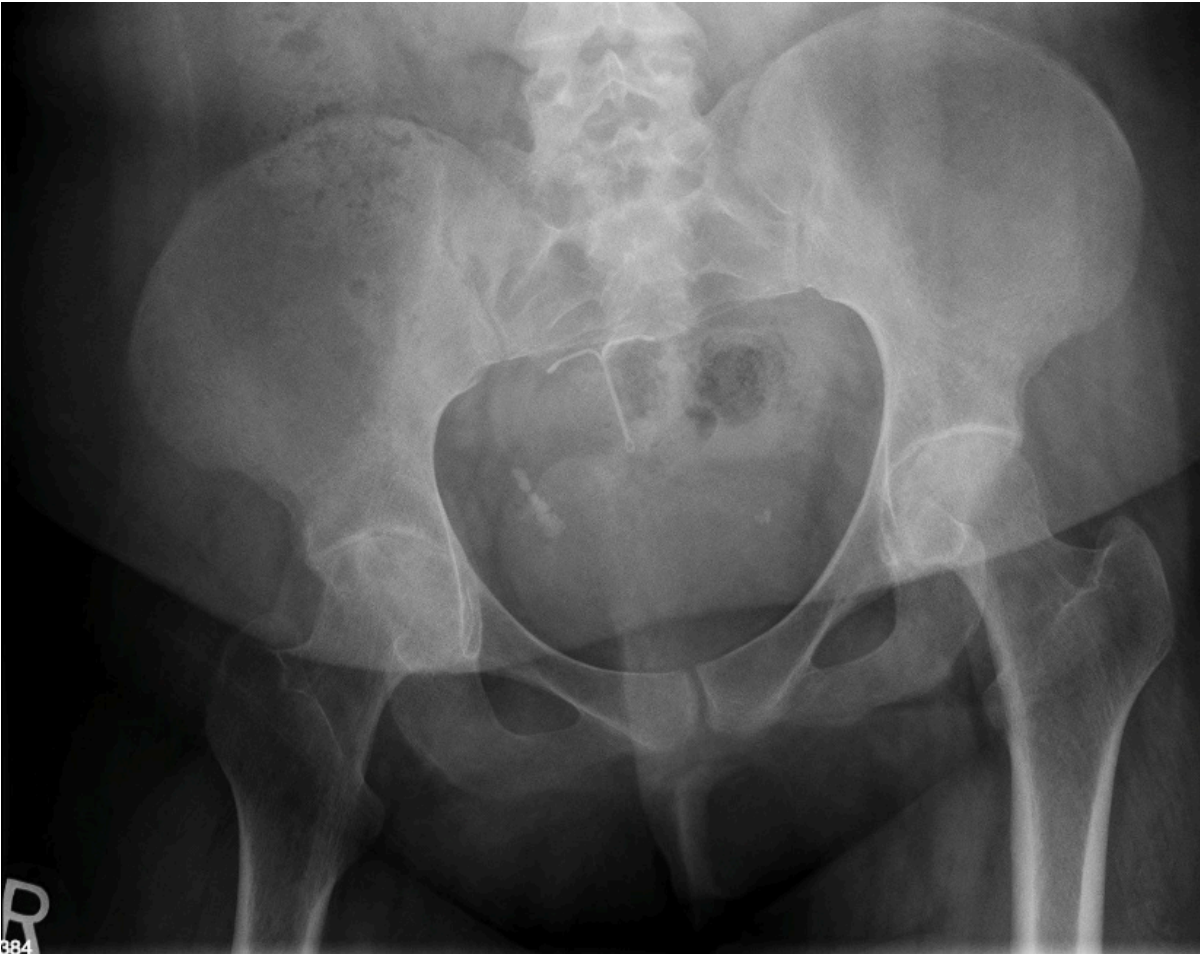


Figure 14.15A X-ray of the pelvis

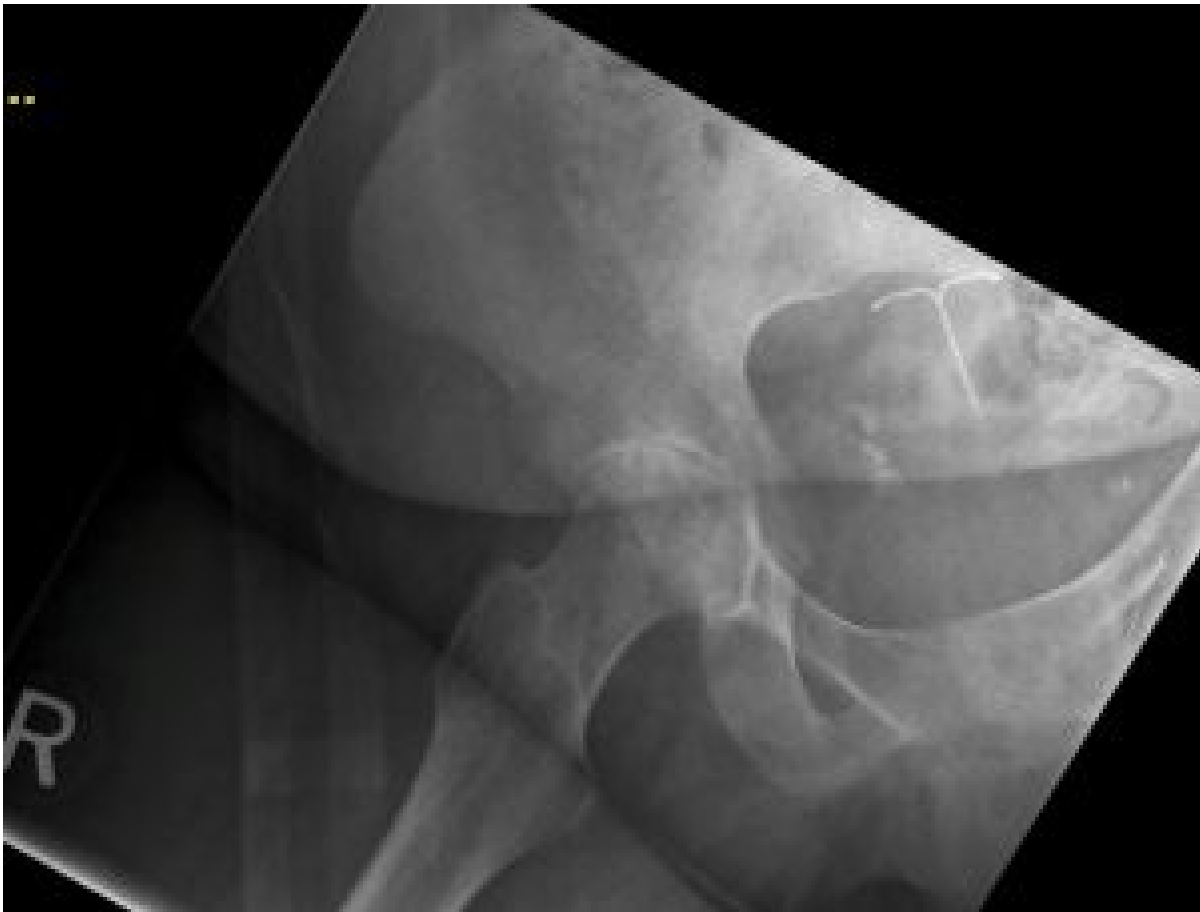


Figure 14.15B X-ray of the femur and hip joint

Imaging Assessment

Findings:

Severe right hip joint narrowing was present. There was moderate hip joint degeneration on the left. Bone density was normal. Small marginal joint osteophytes were seen on the right and there is subchondral sclerosis and subchondral cysts in the right joint space. Incidental note was made of an intra-uterine contraceptive device in this 59 year old female.

Interpretation:

Moderate to severe right hip osteoarthritis

Diagnosis:

Hip osteoarthritis. Treatment planning included, physiotherapy, pain management and eventual planning for a hip replacement.

Discussion:

Osteoarthritis (degenerative) is the most common form of arthritis. It results from intrinsic degeneration of the

articular cartilage, mostly from the mechanical stress of excessive wear and tear on weight-bearing joints. It mostly involves the hips, knees, and hands and increases in prevalence with increasing age.

X-ray findings may include:

- Marginal osteophyte formation. A hallmark of hypertrophic arthritis, osseous transformation of cartilaginous excrescences, and metaplasia of synovial lining cells leads to the production these bone protrusions at or near the joint.
- Subchondral sclerosis. This is a reaction of the bone to the mechanical stress to which it is subjected when its protective cartilage has been destroyed.
- Subchondral cysts. As a result of chronic impaction, necrosis of bone, and/or imposition of synovial fluid into the subchondral bone, cysts of varying sizes form in the subchondral bone.
- Narrowing of the joint space. Seen in all forms of arthritis.

Attributions

Figure 14.15A X-ray of the pelvis by Dr. Brent Burbridge MD, FRCPC, University Medical Imaging Consultants, College of Medicine, University of Saskatchewan is used under a [CC-BY-NC-SA 4.0](#) license.

Figure 14.15B X-ray of the femur and hip joint by Dr. Brent Burbridge MD, FRCPC, University Medical Imaging Consultants, College of Medicine, University of Saskatchewan is used under a [CC-BY-NC-SA 4.0](#) license.

Erosive Arthritic Condition – RA

ACR – MSK – Chronic Extremity Joint Pain

Case

Rheumatoid Arthritis

Clinical:

History – This patient had a long history of polyarthritis.

Symptoms – Painful deformed joints.

Physical – There were deformed joints in the hands and feet that are symmetrical. Joint swelling was noted in the fingers and toes. There was minimal erythema of multiple finger joints.

DDx:

Poly-arthritis – erosive

Imaging Recommendation

[ACR – MSK – Chronic Extremity Joint Pain](#)

X-rays

ODIN Link for Erosive Arthritis images, Figure 14.16B and C: <https://mistr.usask.ca/odin/?caseID=20150320230005810>

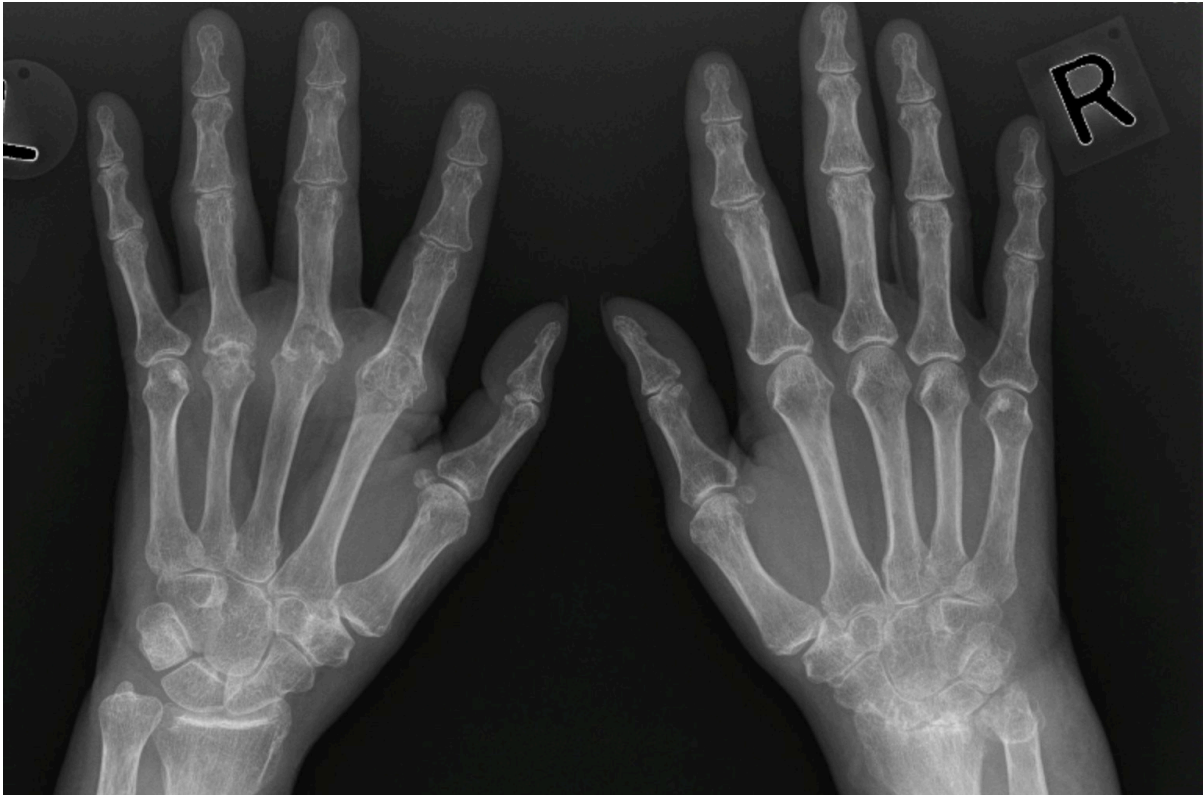

Figure 14.16A X-rays of both hands displaying erosive arthritis and joint deformity

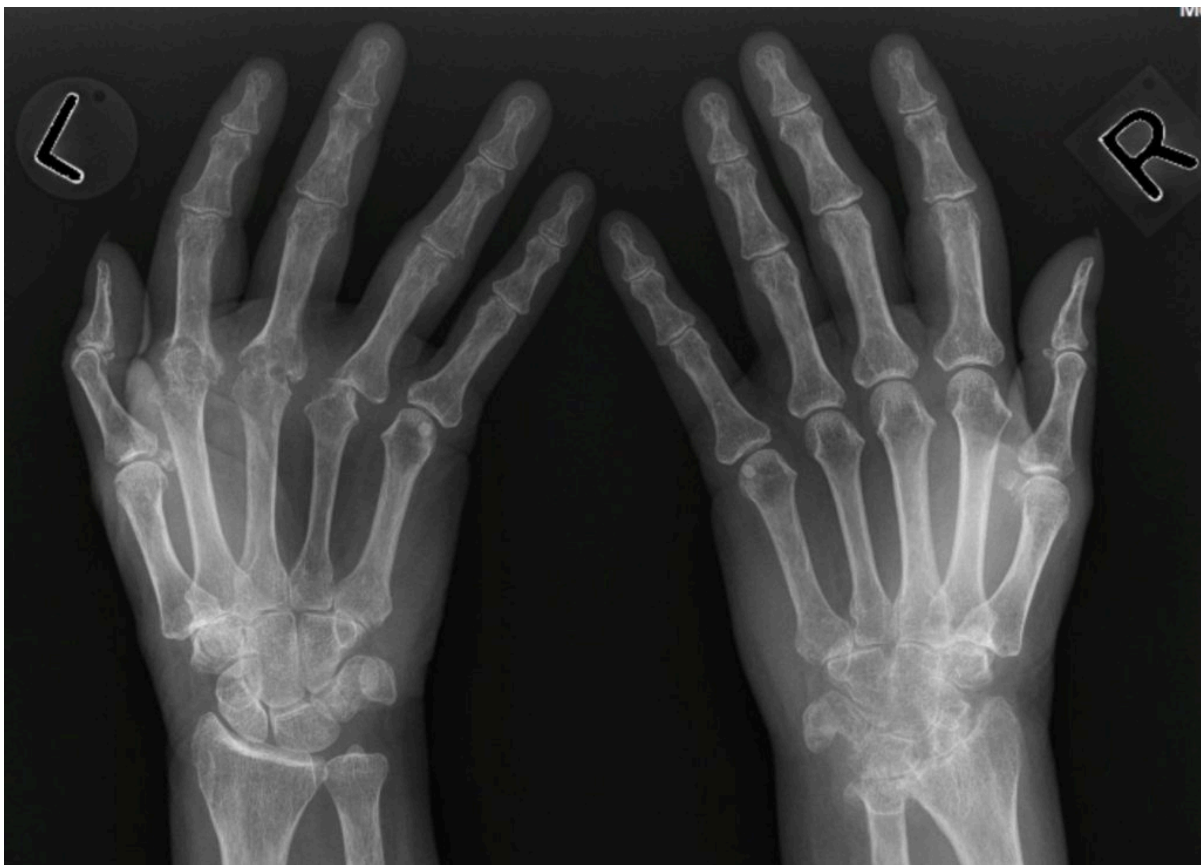

Figure 14.16B X-rays of both hands displaying erosive arthritis and joint deformity.

Imaging Assessment

Findings:

The radiographs demonstrated an erosive, symmetrical, polyarthritis of the hands and carpus. The joint deformities were moderate to severe. The bones were diffusely osteopenic, but were especially so in the peri-articular region.

Interpretation:

Symmetrical Polyarthritis – Rheumatoid Arthritis (RA)

Diagnosis:

Rheumatoid Arthritis

Discussion:

Rheumatoid arthritis is more common in females, frequently involving the proximal joints of the hands and wrists. Conventional radiographs remain the study of first choice for imaging RA.

X-ray findings may include:

- Bilateral and symmetrical imaging findings.
- The earliest radiographic changes are soft tissue swelling of the affected joints and osteoporosis, which tends to be most severe on both sides of the joint space (peri-articular osteoporosis or peri-articular demineralization).
- In the hand, the erosions tend to involve the proximal joints: the carpal-metacarpal joints, metacarpal-phalangeal joints, and proximal interphalangeal joints.
- Late findings in the hands include deformities such as ulnar deviation of the fingers at the MCP joints, subluxation of the MCP joints, and ligamentous laxity, leading to deformities of the fingers (swan-neck and boutonnière deformities).
- In the wrist, erosions of the carpals, ulnar styloid, and narrowing of the radiocarpal joint space are frequently seen.
- Elsewhere in the body, the larger joints usually do not show erosions, but there may be marked uniform narrowing of the joint space with little or no subchondral sclerosis.
- In the cervical spine, RA may uniquely involve the transverse ligament that stabilizes the odontoid resulting in ventral subluxation of C1 on C2 (atlantoaxial subluxation). Atlantoaxial subluxation can produce cord compression if severe.
- RA may also cause narrowing, deformity, and eventual fusion of the facet joints in the spine.

Attributions

Figure 14.16A X-rays of both hands displaying erosive arthritis and joint deformity by Dr. Brent Burbridge MD, FRCPC, University Medical Imaging Consultants, College of Medicine, University of Saskatchewan is used under a [CC-BY-NC-SA 4.0](#) license.

Figure 14.16B X-rays of both hands displaying erosive arthritis and joint deformity by Dr. Brent Burbridge MD, FRCPC, University Medical Imaging Consultants, College of Medicine, University of Saskatchewan is used under a [CC-BY-NC-SA 4.0](#) license.

Musculoskeletal Radiology – References

- 1) James N. Wise, MD; Richard H. Daffner, MD; Barbara N. Weissman, MD, et al. ACR Appropriateness Criteria®, MSK – Acute Shoulder Pain. Available at <https://acsearch.acr.org/docs/69433/Narrative/> American College of Radiology. Accessed June 30, 2017.
- 2) Radiopaedia.org – <https://radiopaedia.org/articles/rockwood-classification-of-acromioclavicular-joint-injury> Rockwood classification of AC-Joint injuries. Accessed June 30, 2017.
- 3) Common Forearm Fractures in Adults. American Family Physician 2009; 80 (10): 1096 – 1102.
- 4) Diagnosis and Management of Scaphoid Fractures. American Family Physician 2004; 70 (5); 879 – 884.
- 5) Michael A. Bruno, MD; Barbara N. Weissman, MD; Mark J. Kransdorf, MD, et al. MSK – Hand and Wrist Trauma. Available at <https://acsearch.acr.org/docs/69418/Narrative/> American College of Radiology. Accessed June 30, 2017.
- 6) Robert J. Ward, MD, CCD; Barbara N. Weissman, MD; Mark J. Kransdorf, MD., et al. ACR Appropriateness Criteria®, MSK – Acute Hip Pain – Suspected Fracture. Available at <https://acsearch.acr.org/docs/3082587/Narrative/> American College of Radiology. Accessed June 30, 2017.
- 7) Radiopaedia.org – <https://radiopaedia.org/articles/femoral-neck-fracture> Accessed June 30, 2017.
- 8) Michael J. Tuite, MD; Mark J. Kransdorf, MD; Francesca D. Beaman, MD, et al. ACR Appropriateness Criteria®, MSK – Acute Trauma to the Knee. Available at <https://acsearch.acr.org/docs/69419/Narrative/> American College of Radiology. Accessed June 30, 2017.
- 9) Ottawa Knee Rule – Stiell IG, Wells GA, Hoag RH, Sivilotti ML, et al (1997). “Implementation of the Ottawa Knee Rule for the use of radiography in acute knee injuries.”. JAMA. 278 (27): 2075–9. [PMID 9403421](https://pubmed.ncbi.nlm.nih.gov/9403421/). [doi:10.1001/jama.1997.03550230051036](https://doi.org/10.1001/jama.1997.03550230051036). Accessed June 30, 2017.
- 10) Ottawa Ankle Rule – Stiell IG, McKnight RD, Greenberg GH, et al. (March 1994). “Implementation of the Ottawa ankle rules”. JAMA. 271 (11): 827–32. [PMID 8114236](https://pubmed.ncbi.nlm.nih.gov/8114236/). [doi:10.1001/jama.1994.03510350037034](https://doi.org/10.1001/jama.1994.03510350037034). Accessed June 30, 2017.

11) Jon A. Jacobson, MD; Catherine C. Roberts, MD; Jenny T. Bencardino, MD, et al. ACR Appropriateness Criteria®, MSK – Chronic Extremity Joint Pain Available at <https://acsearch.acr.org/docs/3097211/Narrative/> American College of Radiology. Accessed June 30, 2017.

Chapter 15 – Pediatric

Non-Accidental and Accidental Trauma

ACR – Pediatric – Suspected Physical Abuse

Case 1

Non-Accidental Trauma

Imaging Recommendation

Clinical:

History – This 2 year old child was brought to ER for lethargy and failure to thrive.

Symptoms – None

Physical – The child was undernourished and looked unwell. The child was lethargic and irritable. There were multiple painful bones and joints, especially the knees. There were multiple bruises and abrasions, including bruises on the face. The back of the head was swollen and tender.

DDx:

Suspected non-accidental trauma

Imaging Recommendation

[ACR – Pediatric – Suspected Physical Abuse, Variant 3](#)

Skeletal survey (x-rays)

CT Head

ODIN Link for Non-Accident Trauma images (X-rays), Figure 15.1A and B: <https://mistr.usask.ca/odin/?caseID=20170308120519686>

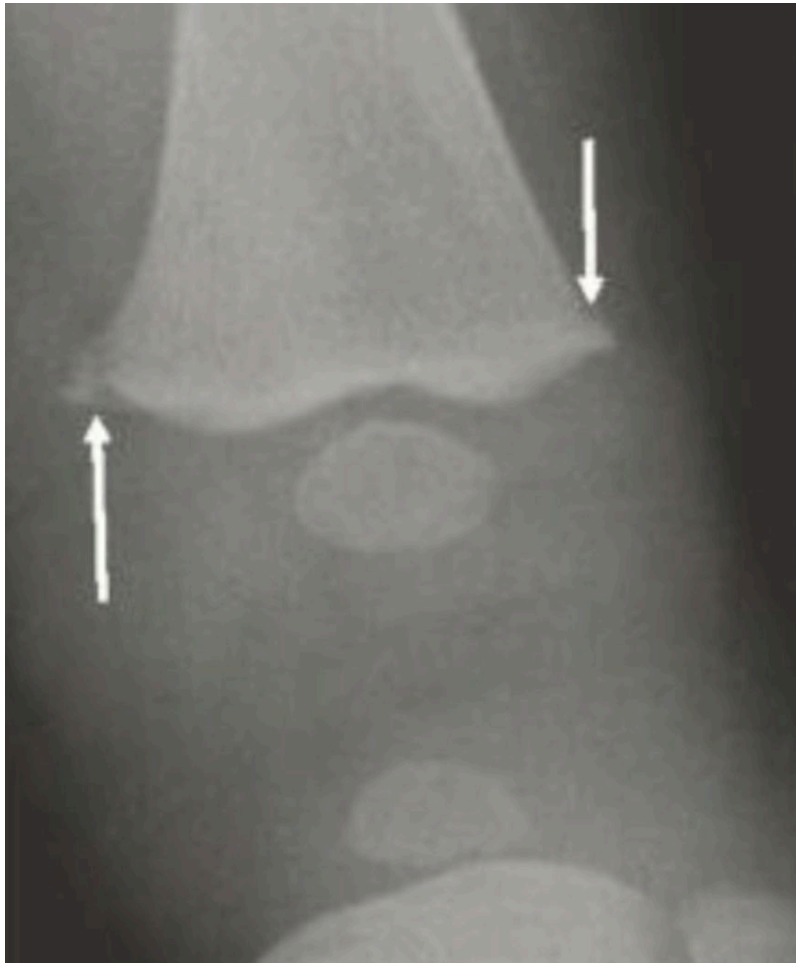


Figure 15.1A X-ray of pediatric metaphyseal fractures associated with non-accidental trauma.

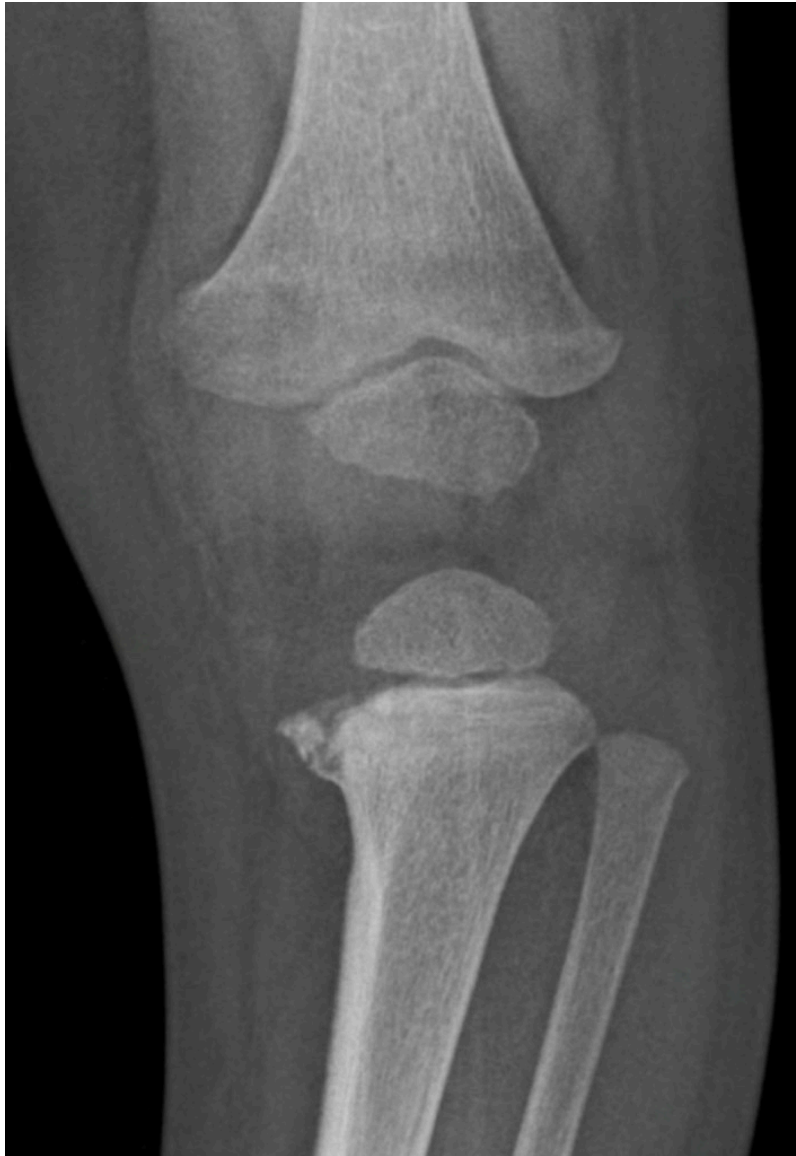

Figure 15.1B X-ray of a pediatric metaphyseal fracture associated with non-accidental trauma.

ODIN Link for CT Head, Non-Accidental Trauma images (CT), Figure 15.2A and B:
<https://mistr.usask.ca/odin/?caseID=20160412165157138>

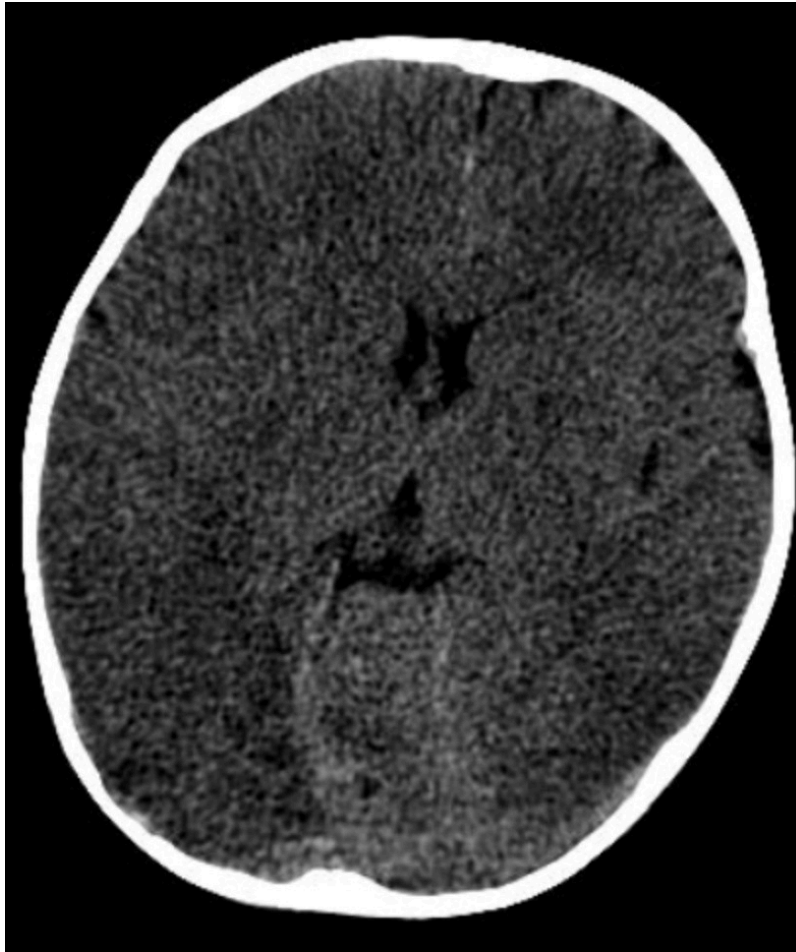


Figure 15.2A CT scan of the head and brain revealing brain infarction and generalized brain edema.

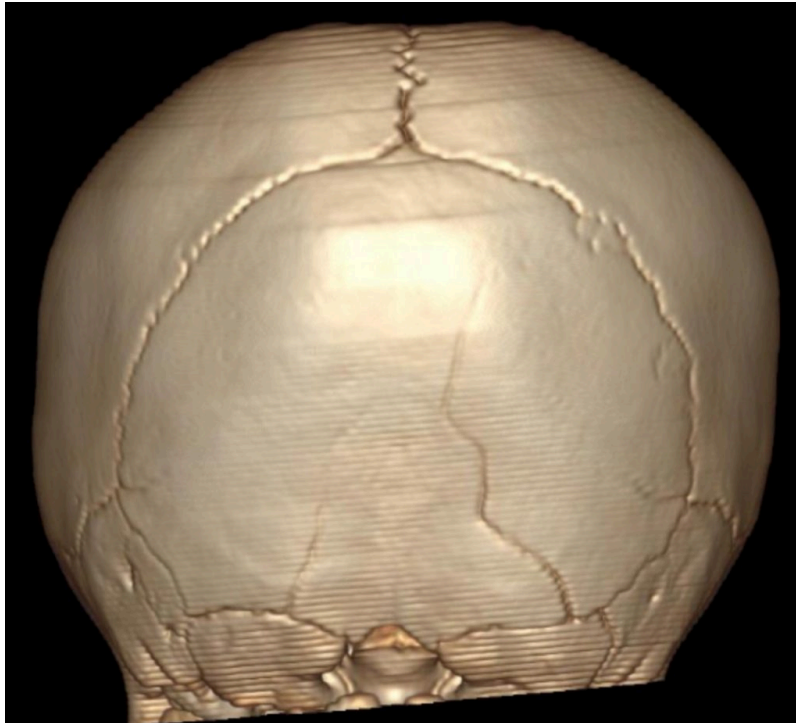


Figure 15.2B 3D rendering of the skull demonstrating skull fractures in a child.

Imaging Assessment

X-Rays

Findings:

Limited x-rays were initially performed. There were classical, metaphyseal, bucket handle type fractures. This was also seen involving the distal tibia.

Interpretation:

High suspicion for non-accidental trauma. Full skeletal survey recommended.

Computed Tomography

Findings:

There was generalized cerebral edema. A small subdural hematoma was seen in the right frontal region. Occipital bone fractures were present.

Interpretation:

Probable shaken child syndrome. Non-accidental trauma.

Diagnosis:

Non-accidental trauma

Discussion:

Physically abused children may present with neurological injuries, hollow viscus and solid-organ injuries, superficial and deep soft-tissue injuries, thermal injuries, and/or fractures. Fractures highly suggestive of physical abuse include rib fractures, classic metaphyseal lesions, those unsuspected or inconsistent with the history or age of the child, multiple fractures involving more than one skeletal area, and fractures of differing ages.

In some children, physical examination and history may clearly indicate that physical abuse has occurred. In other children, however, the diagnosis of abuse is not so straight forward and requires clinical, laboratory, imaging, pathological, and forensic evaluation and usually relies on the findings of a multidisciplinary team that includes physicians, social workers, and legal authorities.

Imaging often plays a major role in the detection and documentation of physical injury. The type and extent of imaging performed in a child who is a suspected victim of abuse depends on the child's age, signs, symptoms, and other social considerations, such as being the twin or sibling of a physically abused infant. Making the diagnosis of child abuse requires differentiation from anatomical and developmental variants and possible underlying metabolic and genetic conditions.

Recommended Imaging:

Skeletal survey:

The radiographic skeletal survey is the primary imaging examination for detecting fractures. The skeletal survey should be composed of frontal and lateral views of the skull, lateral views of the cervical spine and thoraco-lumbosacral spine, and single frontal views of the long bones, hands, feet, chest, and abdomen. Oblique views of the ribs should be obtained to increase the accuracy of diagnosing rib fractures, which are strong positive predictors and may be the only skeletal manifestation of abuse.

The images should be obtained using high-detail imaging systems and coned to the specific area of interest for each of the body parts, with separate views of each arm, forearm, thigh, leg, hand, and foot to improve image quality and diagnostic accuracy.

Fractures most often involve the long bones and ribs, with lesser involvement of the skull and clavicles and even less frequent involvement of the pelvis, spine, hands, and feet. It has therefore been questioned whether the radiation exposure outweighs the potential benefit of imaging the pelvis, spine, hands, and feet on initial skeletal survey.

CT Head without contrast:

Unenhanced computed tomography (CT) of the head is the examination of choice to evaluate children with suspected abusive head trauma (AHT). These include children who had skeletal survey for suspected child abuse,

children with neurological changes, and children with facial injuries raising concern for abuse. Multi-planar reformations and 3-D volume rendering of the skull increase sensitivity for fracture and intracranial hemorrhage.

Imaging findings may include:

- Metaphyseal corner fractures – small, avulsion-type fractures of the metaphysis, caused by rapid rotation of ligamentous insertions; corner fractures are considered diagnostic of physical abuse. They parallel the metaphysis and can have a bucket-handle appearance.
- Rib fractures, especially multiple fractures, and/or fractures of the posterior ribs (which rarely fracture, even by accidental trauma).
- Head injuries are the most common cause of death in child abuse under the age of two years. Findings include subdural and subarachnoid hemorrhage and cerebral contusions.
- Skull fractures tend to be comminuted, bilateral, and may cross suture lines.

Case 2

Skeletal trauma – growth plate injury Salter – Harris Skeletal Injuries

Clinical:

History – Injured her knee ski-doing.

Symptoms – Painful knee.

Physical – The patient was limping and reluctantly put weight on the leg. Minimal knee swelling was seen and there was some minimal bruising present.

DDx:

Contusion

Femur fracture

Tibial fracture

Imaging Recommendation

X-rays

ODIN Link to Accidental Bone Trauma images, Figure 15.3A and B: <https://mistr.usask.ca/odin/?caseID=20170227150802087>

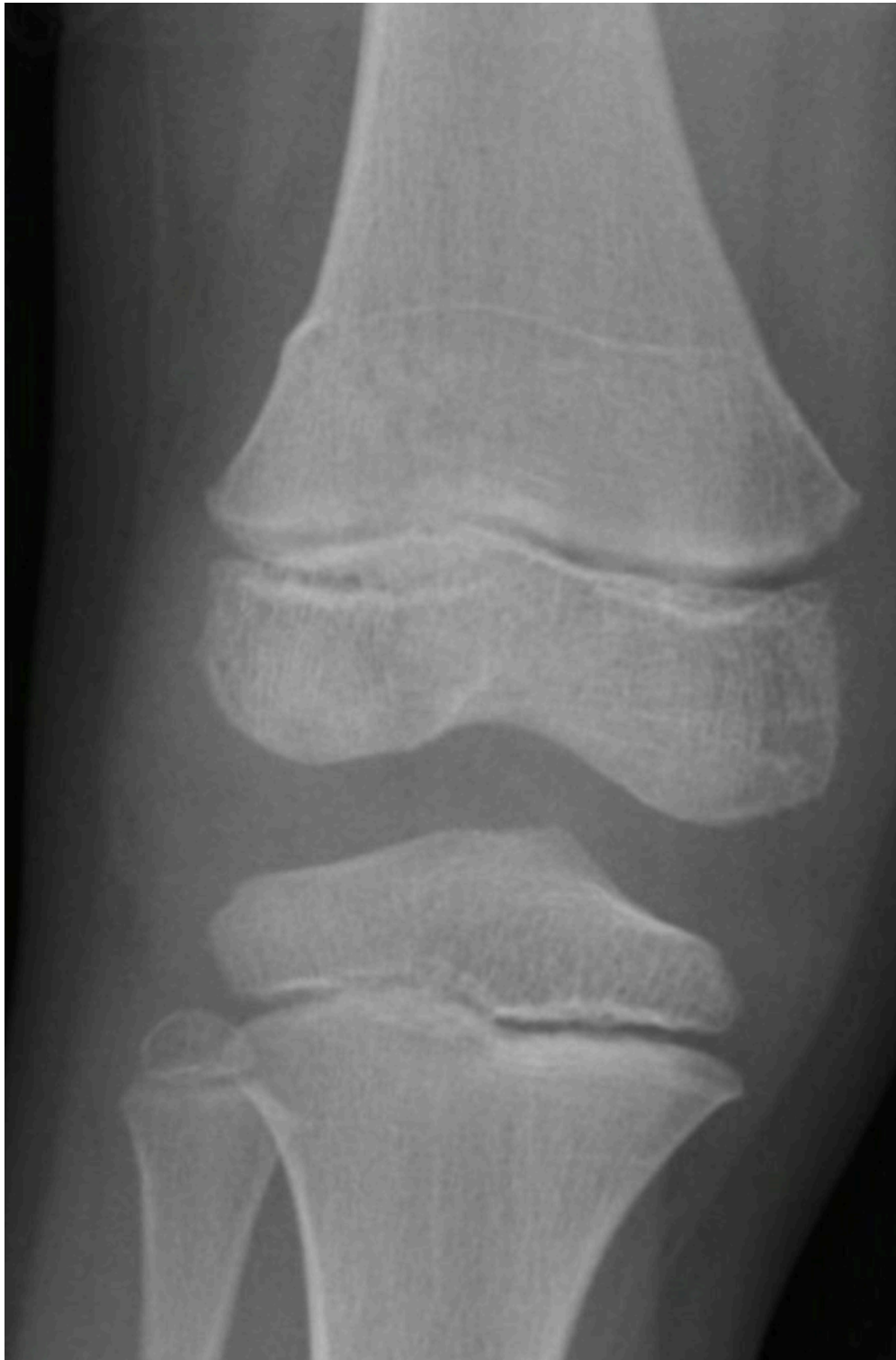

Figure 15.3A X-ray of the pediatric knee revealing a distal femoral fracture.

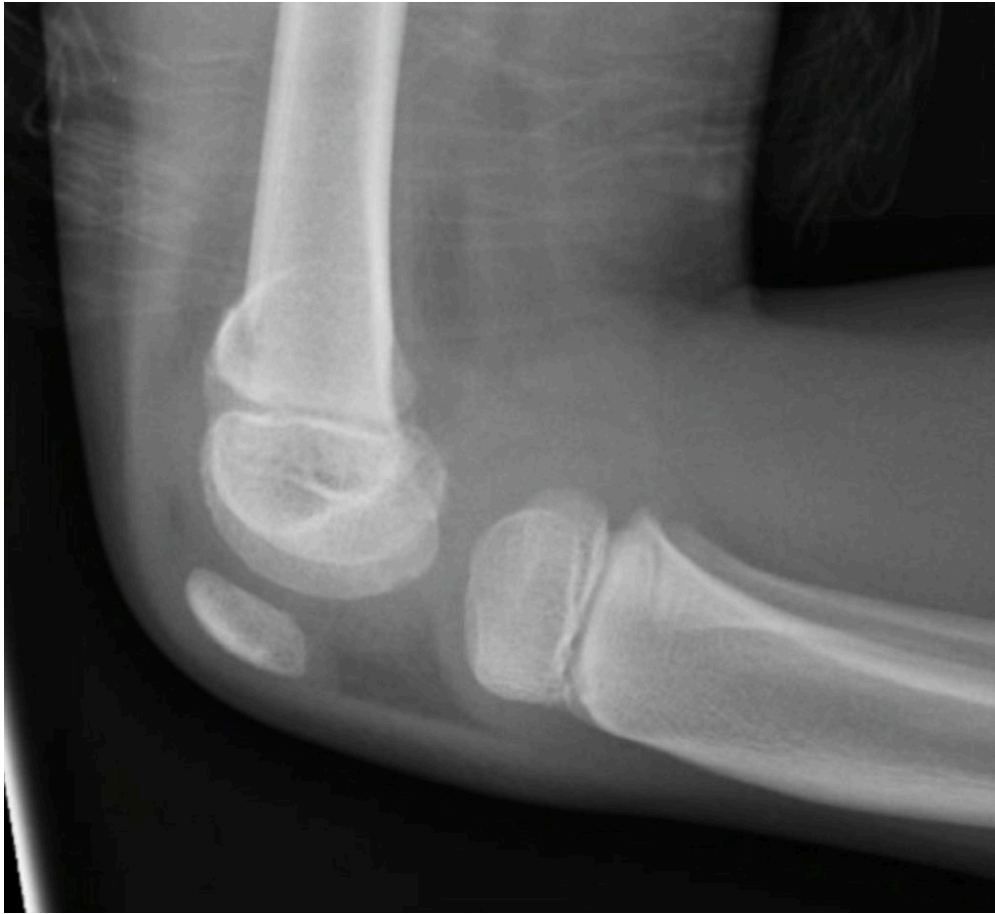

Figure 15.3B Lateral x-ray of the knee associated with a femoral fracture.

Imaging Assessment

Findings: The femoral growth plate was widened. There was a metaphyseal fracture that exited laterally. Minimal swelling was noted.

Interpretation:

Salter-Harris type 2 fracture of the distal femur.

Diagnosis:

Salter-Harris, type 2, fracture

Discussion:

- The epiphyseal plate (physis or growth plate) is the weakest part of the bone and is prone to shearing injuries.
- The Salter-Harris classification is a means of categorizing epiphyseal plate fractures and provides clues to their prognosis.

- All such fractures, by definition, involve or extend through the epiphyseal plate and therefore all such fractures occur in children before the epiphyseal plate fuses.

Salter-Harris, type II fracture:

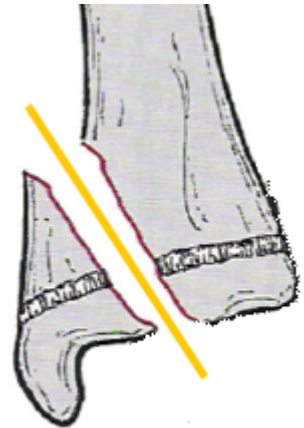
- Most common Salter-Harris fracture—85%.
- Involves both the epiphyseal plate and the metaphysis.
- A corner of metaphysis that is usually fractured produces the “corner sign”.
- Rarely produces complications.

Salter-Harris Classification of Growth Plate Injuries (Description, Frequency, and Prognosis):

Type	Description	Image
I	<p>The fracture plane extends completely through the growth plate. This type of fracture can be minimally displaced, making detection challenging. Repeated x-rays in 7 days will demonstrate periosteal new bone if a subtle fracture is suspected.</p> <p>5 – 7% frequency.</p> <p>Good prognosis.</p>	
II	<p>The fracture plane leaves a small, triangular or quadrangular portion of the metaphysis in contact with the growth plate. This is the most common type of Salter-Harris injury.</p> <p>75% frequency.</p> <p>Good prognosis.</p>	
III	<p>A quadrangular fragment of the epiphysis is isolated from the adjacent bone.</p> <p>7 – 10% frequency.</p> <p>Poorer prognosis.</p>	

A triangular fragment of epiphysis, growth plate, and metaphysis is separated from the adjacent bone.

- IV 10% frequency.
Poorer prognosis.



This injury is focal and results in delayed abnormal bone growth in a focal region of the bone due to crushing type of damage to the growing bone.

- V 1% frequency.
Worst prognosis.

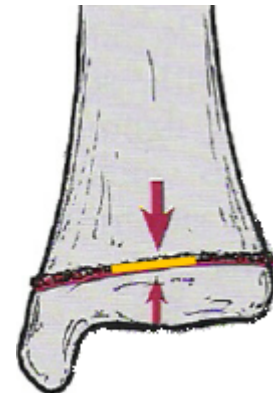


Table 15.1 Description, frequency, and prognosis of Salter-Harris Classification of Growth Plate Injuries by Dr. Brent Burbridge MD, FRCPC, University Medical Imaging Consultants, College of Medicine, University of Saskatchewan is used under a [CC-BY-NC-SA 4.0](#) license.

Attributions

Figure 15.1A X-ray of pediatric fractures associated with non-accidental trauma by Dr. Brent Burbridge MD, FRCPC, University Medical Imaging Consultants, College of Medicine, University of Saskatchewan is used under a [CC-BY-NC-SA 4.0](#) license.

Figure 15.1B X-ray of pediatric fracture associated with non-accidental trauma by Dr. Brent Burbridge MD, FRCPC, University Medical Imaging Consultants, College of Medicine, University of Saskatchewan is used under a [CC-BY-NC-SA 4.0](#) license.

Figure 15.2A CT scan of the head and brain revealing brain infarction and edema by Dr. Brent Burbridge MD, FRCPC, University Medical Imaging Consultants, College of Medicine, University of Saskatchewan is used under a [CC-BY-NC-SA 4.0](#) license.

Figure 15.2B 3D rendering of the skull demonstrating skull fractures in a child by Dr. Brent Burbridge MD,

FRCPC, University Medical Imaging Consultants, College of Medicine, University of Saskatchewan is used under a [CC-BY-NC-SA 4.0](#) license.

Figure 15.3A X-ray of the pediatric knee revealing a distal femoral fracture by Dr. Brent Burbridge MD, FRCPC, University Medical Imaging Consultants, College of Medicine, University of Saskatchewan is used under a [CC-BY-NC-SA 4.0](#) license.

Figure 15.3B Lateral x-ray of the knee associated with a femoral fracture by Dr. Brent Burbridge MD, FRCPC, University Medical Imaging Consultants, College of Medicine, University of Saskatchewan is used under a [CC-BY-NC-SA 4.0](#) license.

Foreign Body Ingestion/Aspiration

Case 1

Ingestion

Clinical:

History – This 5 year old girl swallowed two magnets.

Symptoms – None.

Physical – No significant findings.

DDx:

Swallowed foreign body

Imaging Recommendation

X-rays

ODIN Link for Ingested Foreign Body images, Figure 15.4A and B: <https://mistr.usask.ca/odin/?caseID=20160401141550510>

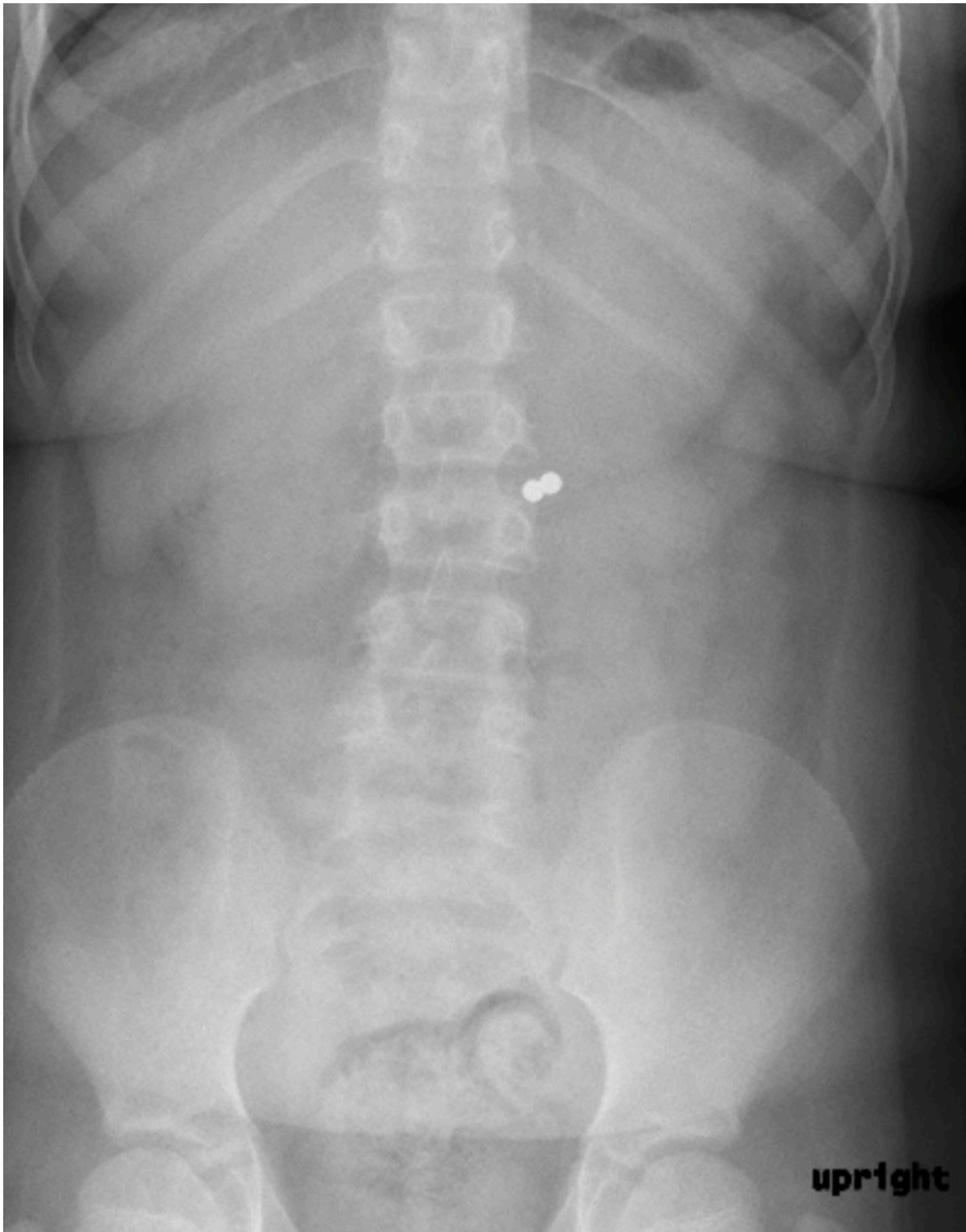


Figure 15.4A AP Abdominal x-ray, supine, of a foreign body

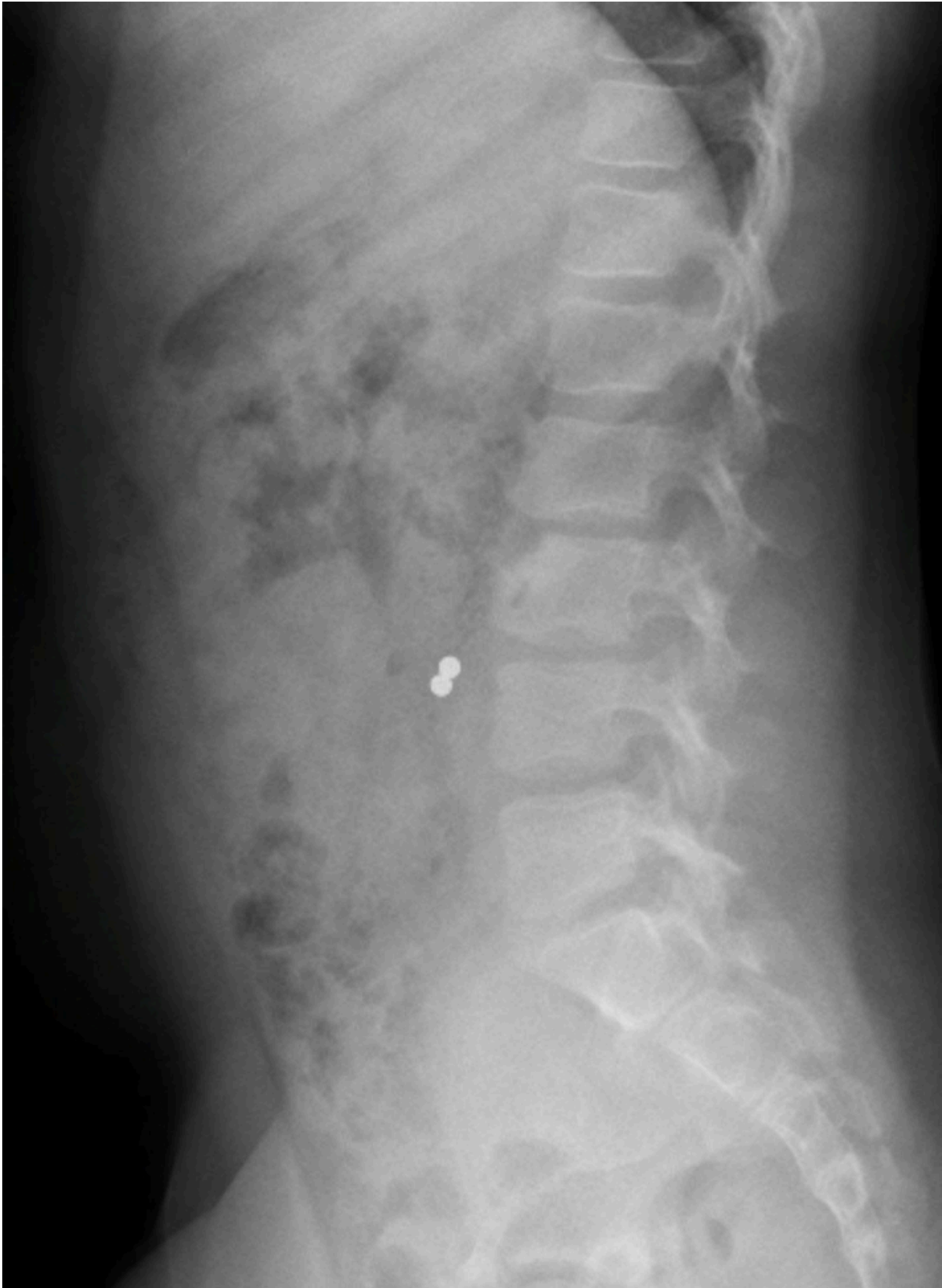

Figure 15.4B Lateral abdominal x-ray, lateral, of a foreign body

Imaging Assessment

Findings:

Two small metallic opacities were seen on the x-rays in the mid-abdomen. They were persistently, apparently, connected to to each other on all images. There was no interposed space or soft tissue between the two opacities

Interpretation:

Swallowed small magnets.

Diagnosis:

Swallowed foreign bodies.

Discussion:

- The majority of swallowed foreign bodies occur between the ages of 6 months and 6 years. Over 80% pass through the intestinal tract spontaneously.
- Food or true foreign body ingestions include, coins, toys, chicken bones (opaque), and fish bones (non-opaque).
- Most often, ingested foreign bodies impact just below the cricopharyngeus at the level of C5-C6 (70%), the level of the thoracic inlet, at the aortic arch (20%), or at the level of the esophagogastric junction (10%). Once past the esophagus, most foreign bodies will pass through the gastrointestinal tract.
- The major complications of ingested foreign bodies are perforation, obstruction, or stricture formation. Disk batteries and magnets pose particular hazards. Button batteries should be removed from the esophagus urgently because of their ability to produce perforation. Multiple small magnets also pose the risk of perforation by drawing apposing segments of bowel together and should be removed, if possible.

X-ray findings may include:

- The ability to detect a foreign body on x-rays depends upon the amount of metal it contains and whether it can be surrounded by, or contain gas, inside of it.
- Some foreign bodies will not be visible on x-rays but they may be associated with bowel obstruction.

Case 2

Aspiration

Clinical:

History – Choking/coughing spell. This 14 year old girl had piece of carrot in her mouth and experienced a prolonged choking/coughing spell (10 – 15 minutes). The carrot was not expelled with coughing. The patient was not sure if she had swallowed the carrot fragment.

Symptoms – Mild shortness of breath.

Physical – There was no air movement heard in the right hemithorax. Rhonchi were heard, loudest over the right hemithorax. Nil else.

DDx:

Aspirated foreign body

Swallowed foreign body

Normal

Imaging Recommendation

Chest x-ray – Inspiration/Expiration

ODIN for Aspirated Foreign Body images, Figure 15.5A and B: <https://mistr.usask.ca/odin/?caseID=20170317223802811>

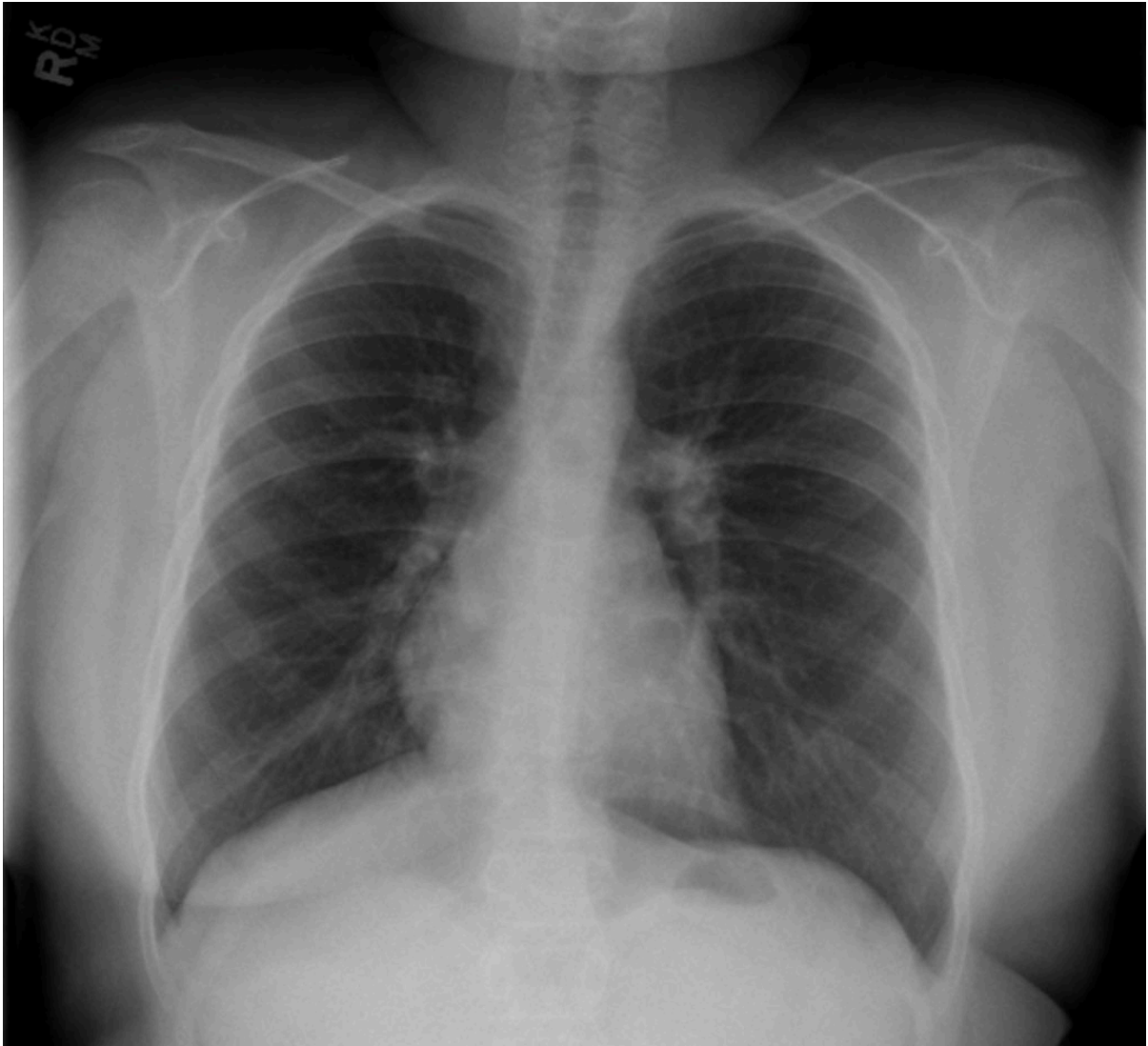


Figure 15.5A Inspiration chest x-ray for a suspected foreign body aspiration.

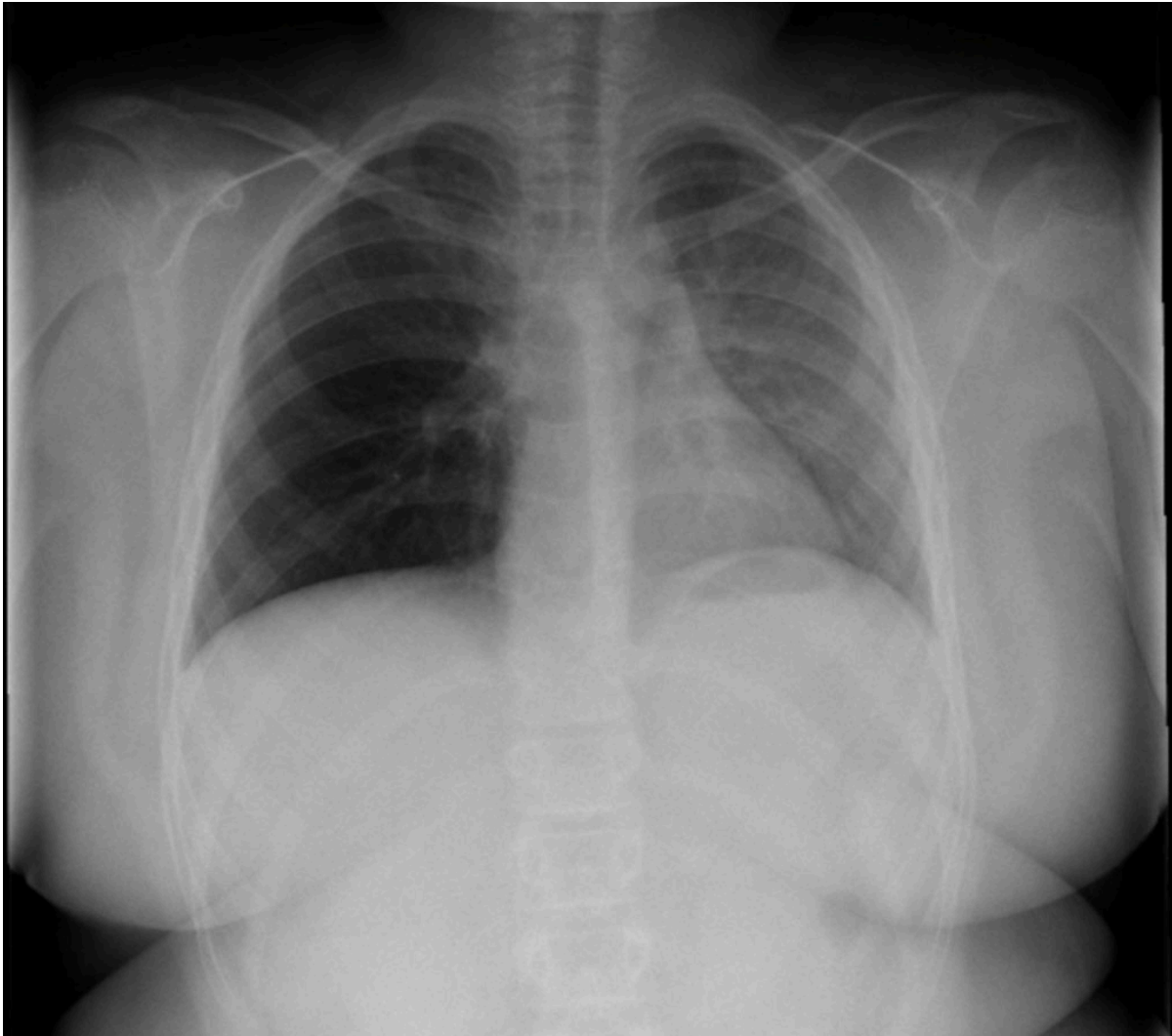


Figure 15.5B Expiration chest x-ray for a suspected foreign body on aspiration.

Imaging Assessment

Findings:

There was diminished vascularity in the right lung. The right lung was hyperinflated on the inspiration view. With expiration the right lung remains aerated and does not deflate.

Interpretation:

The patient has a non-visible foreign body in the right bronchial tree that created a check-valve obstruction, allowing air to enter the lung on inspiration but then obstructed the bronchus on expiration.

Diagnosis:

Check-valve foreign body in the right bronchial tree

Discussion:

Foreign body aspiration is seen for the most part in older infants and toddlers. The story is usually one of a sudden choking episode while the child was eating, possibly something that they were not mature enough to masticate. Aspirated substances include nuts, seeds, popcorn, raw vegetables, such as carrots and celery, and hot dogs. On occasion, the episode occurs when the child is chewing on a small object, a toy, or a detachable portion of a toy. If the object lodges in the larynx, asphyxiation results unless the Heimlich maneuver or back blows are performed promptly.

In the majority of cases the foreign material clears the larynx and lodges in the trachea or a bronchus (more commonly, the right main because of its more vertical orientation). After the choking/coughing spell, there is a silent period usually lasting up to several hours (occasionally days or weeks), after which the child develops cough, stridor (if the object is lodged in the trachea) or wheezing (if it is lodged in a bronchus), and respiratory distress. In this acute phase, when the object is situated in a bronchus, wheezing may be unilateral and associated with decreased breath sounds. Later, diffuse wheezing may be heard, simulating asthma or bronchiolitis.

Lateral neck and chest radiographs may reveal aspirated objects that are radiopaque or outlined by the air column, enabling localization before endoscopy. However, most cases involve materials not visible on radiographs, although other radiographic clues may be present.

Partial obstruction of a bronchus creates a check-valve effect, allowing air in during inspiration but preventing its egress on expiration. This produces hyperinflation of one or more lobes of the lung on the same side as the foreign body, which may be evident on the plain chest film. The check-valve effect is accentuated on expiration.

X-ray findings may include:

- The ability to detect a foreign body is dependent upon how much metal it contains, if it can be outlined by gas, or it contains gas inside a visible wall.
- If the patient has wheezing or one of the lungs is under or over inflated expiration chest images should be obtained to determine if there is a ball-valve, or check-valve, type of obstruction.
- Resorptive atelectasis may occur if the bronchus is totally obstructed.

Attributions

Figure 15.4A AP Abdominal X-ray of a foreign body by Dr. Brent Burbridge MD, FRCPC, University Medical Imaging Consultants, College of Medicine, University of Saskatchewan is used under a [CC-BY-NC-SA 4.0](#) license.

Figure 15.4B Lateral abdominal x-ray of a foreign body by Dr. Brent Burbridge MD, FRCPC, University Medical

Imaging Consultants, College of Medicine, University of Saskatchewan is used under a [CC-BY-NC-SA 4.0](#) license.

Figure 15.5A Chest x-ray of foreign body on inspiration by Dr. Brent Burbridge MD, FRCPC, University Medical Imaging Consultants, College of Medicine, University of Saskatchewan is used under a [CC-BY-NC-SA 4.0](#) license.

Figure 15.5B Chest x-ray of foreign body on expiration by Dr. Brent Burbridge MD, FRCPC, University Medical Imaging Consultants, College of Medicine, University of Saskatchewan is used under a [CC-BY-NC-SA 4.0](#) license.

Urinary Tract Infection and Suspected Vesico-Ureteral Reflux

ACR – Pediatric – Urinary Tract Infection

Case
Vesico-ureteric reflux

Clinical:

History – This 3 year old female has had 2 culture proven urinary tract infections.

Symptoms – None at present.

Physical – No abnormalities.

DDx:

Normal

Vesico-ureteric reflux

Urinary tract calculus

Bladder diverticulum

Imaging Recommendation

[ACR – Pediatric – Urinary Tract Infection](#)

Renal ultrasound was normal.

Cysto-urethrography.

ODIN for Cysto-Urethrogram images, Figure 15.6A and B: <https://mistr.usask.ca/odin/?caseID=20160503232955033>

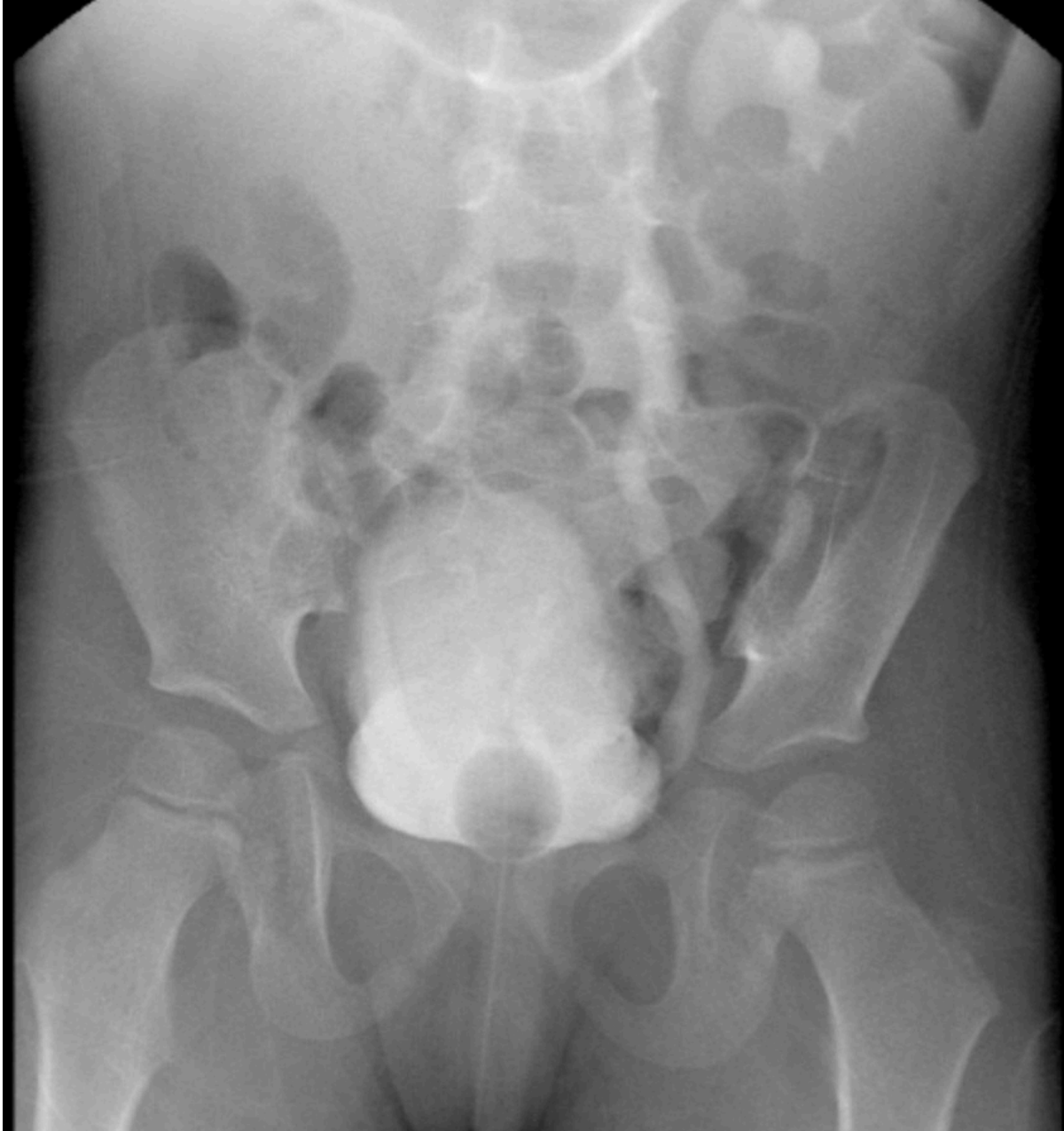


Figure 15.6A Pelvic x-ray of the bladder filled with contrast during a voiding cysto-urethrogram. Ureteric contrast is also evident in the both ureters.

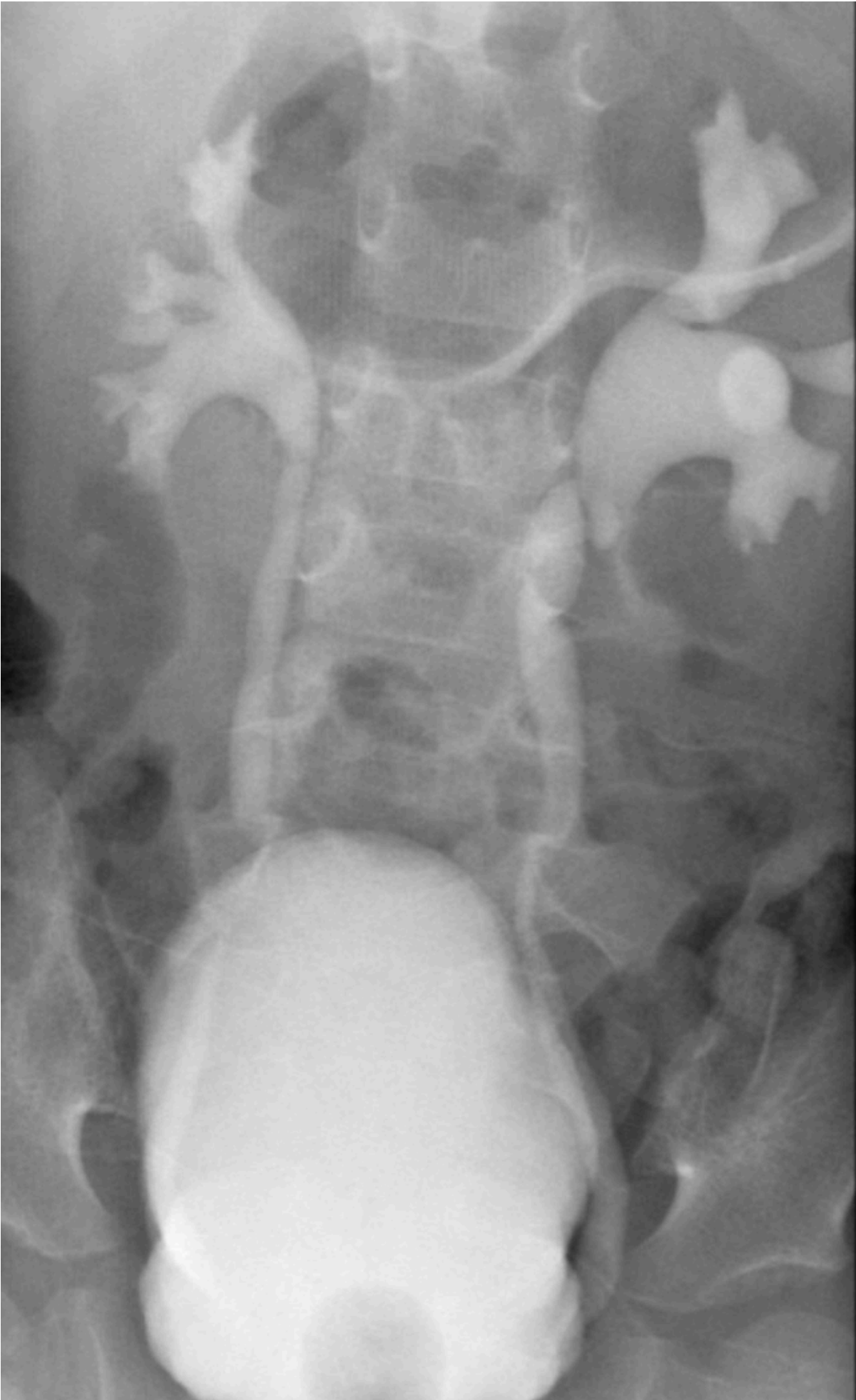

Figure 15.6B Pelvic x-ray of the bladder with contrast and major bilateral vesico-ureteric reflux.

Imaging Assessment

Findings:

There was ureteric reflux as the bladder progressively filled. The collecting system on the left was more dilated and the fornices of the calyces were blunted. No other bladder abnormalities. The bladder emptied completely on voiding.

Interpretation:

Vesico-ureteric reflux. Grade 3 on the left and Grade 2 on the right.

Diagnosis:

Vesico-ureteric reflux.

Discussion:

Urinary tract infection (UTI) is a common disease of childhood. The investigation of UTI in children has been the subject of debate and controversy for many years. Most agree that the first imaging modality to be used should be an ultrasound examination to exclude obstruction, structural abnormalities, or renal calculi.

The role of ^{99m}Tc dimercaptosuccinic acid scintigraphy (DMSA) in the diagnosis of acute pyelonephritis is becoming increasingly important. Many argue that if the DMSA study is normal at the time of acute UTI, no further investigation is required because the kidneys have not been involved and thus there will be no late sequelae. Others use the acute DMSA study to determine the intensity of antibiotic therapy.

The importance of the role of vesico-ureteric reflux (VUR) is being debated. Some physicians will only proceed to cystography to detect VUR if the DMSA study is abnormal, whereas others advocate a more aggressive approach and employ cystography for recurrent infection. VUR can be identified using radiological and scintigraphic techniques. Although the radiological cystogram is the gold standard and in a male patient it is the optimal imaging study to exclude posterior urethral valves, radionuclide cystograms are advantageous in other situations.

Grading of the vesico-ureteric reflux helps to determine treatment strategies i.e. medical vs. surgical.

Vesico-ureteric Reflux Grading

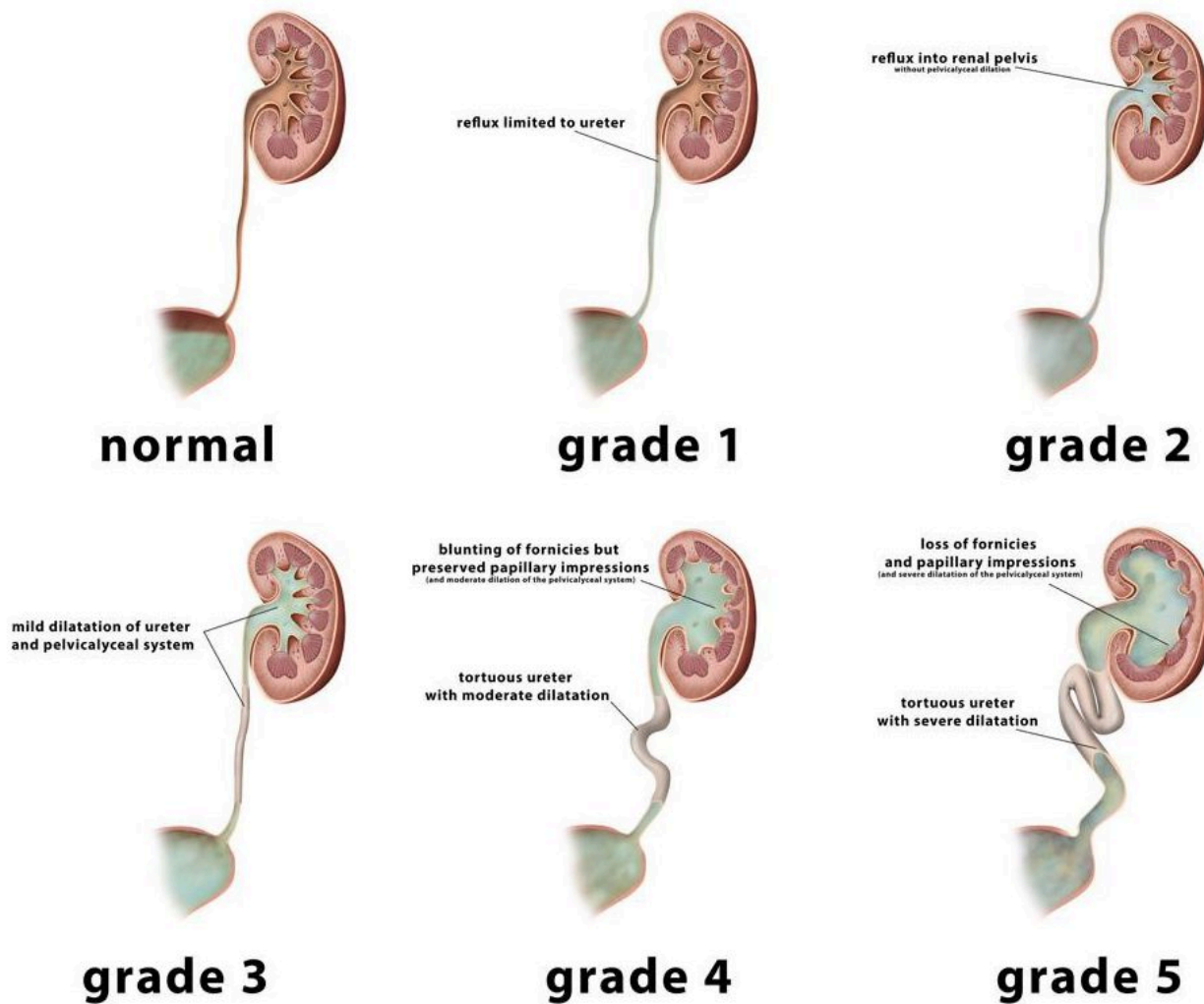


Figure 15.7 Vesico-ureteric reflux grading

Attributions

Figure 15.6A Pelvis x-ray of the bladder filled with contrast by Dr. Brent Burbridge MD, FRCPC, University Medical Imaging Consultants, College of Medicine, University of Saskatchewan is used under a [CC-BY-NC-SA 4.0](https://creativecommons.org/licenses/by-nc-sa/4.0/) license.

Figure 15.6B Pelvis x-ray of the bladder with contrast and bilateral vesico-ureteric reflux by Dr. Brent Burbridge MD, FRCPC, University Medical Imaging Consultants, College of Medicine, University of Saskatchewan is used under a [CC-BY-NC-SA 4.0](https://creativecommons.org/licenses/by-nc-sa/4.0/) license.

Figure 15.7 Vesico-ureteric reflux grading. Originally published at <https://radiopaedia.org/cases/illustration-vesicoureteric-reflux-grading> under a [Creative Commons Attribution-Non-commercial-Share Alike 3.0 Unported License](https://creativecommons.org/licenses/by-nc-sa/4.0/).

Pyloric Stenosis

ACR – Pediatric – Vomiting in Infants Up to 3 Months of Age

Case

Probable HPS

Clinical:

History – This three month old male had developed non-bilious vomiting.

Symptoms – There was repetitive, projectile vomiting in the recent few days. The child was loosing weight.

Physical – There was suspicion for a palpable olive.

Laboratory – Metabolic alkalosis was identified.

DDx:

Pylorospasm

Hypertrophic Pyloric Stenosis

Annular Pancreas

Imaging Recommendation

[ACR – Pediatric – Vomiting in Infants Up to 3 Months of Age, Variant 4](#)

Ultrasound

Link to ODIN Images , Figures 15.8A and B- <https://mistr.usask.ca/odin/?caseID=20170330230714063>

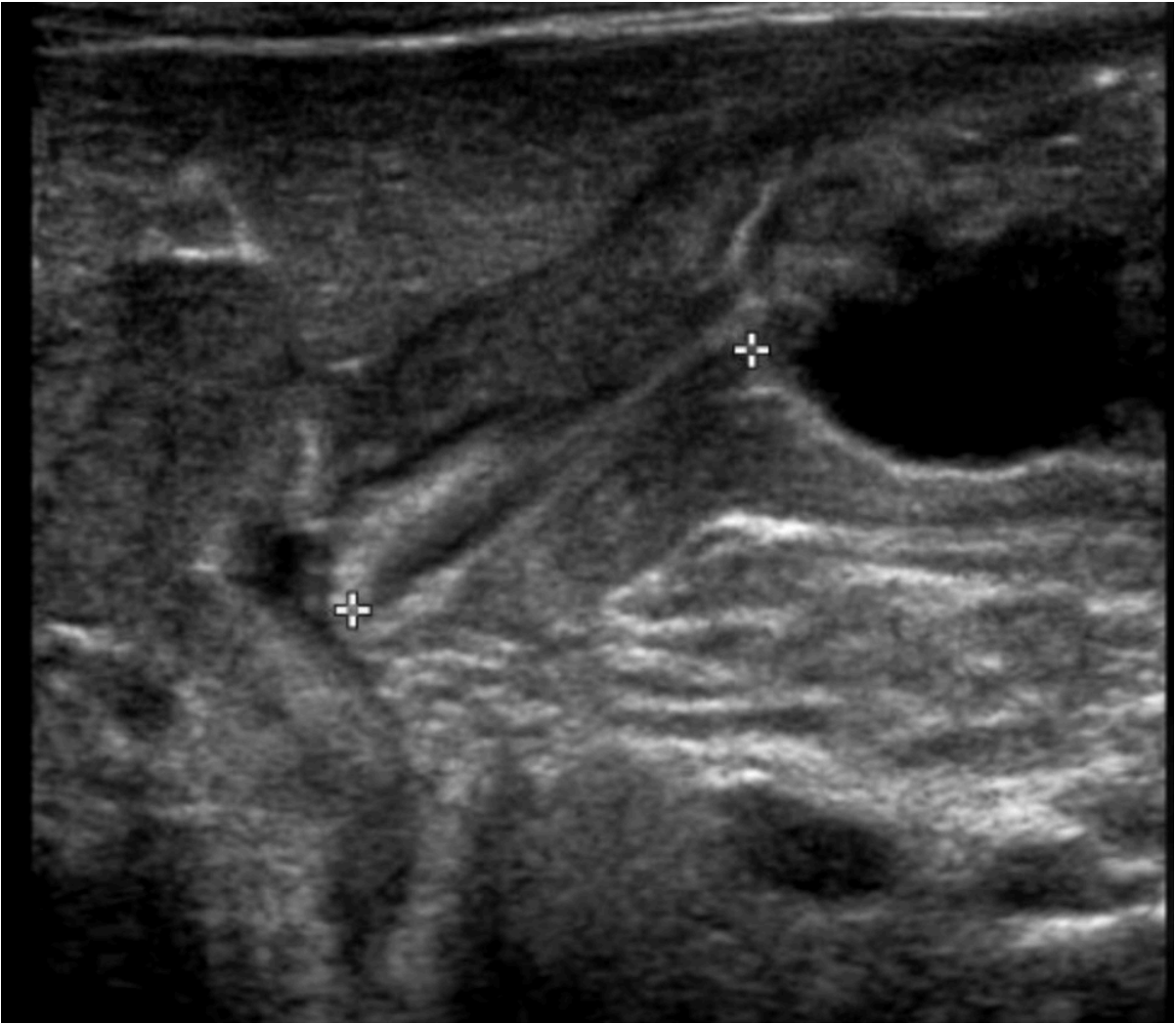


Figure 15.8A Abdominal ultrasound of the pylorus, longitudinal measurement.

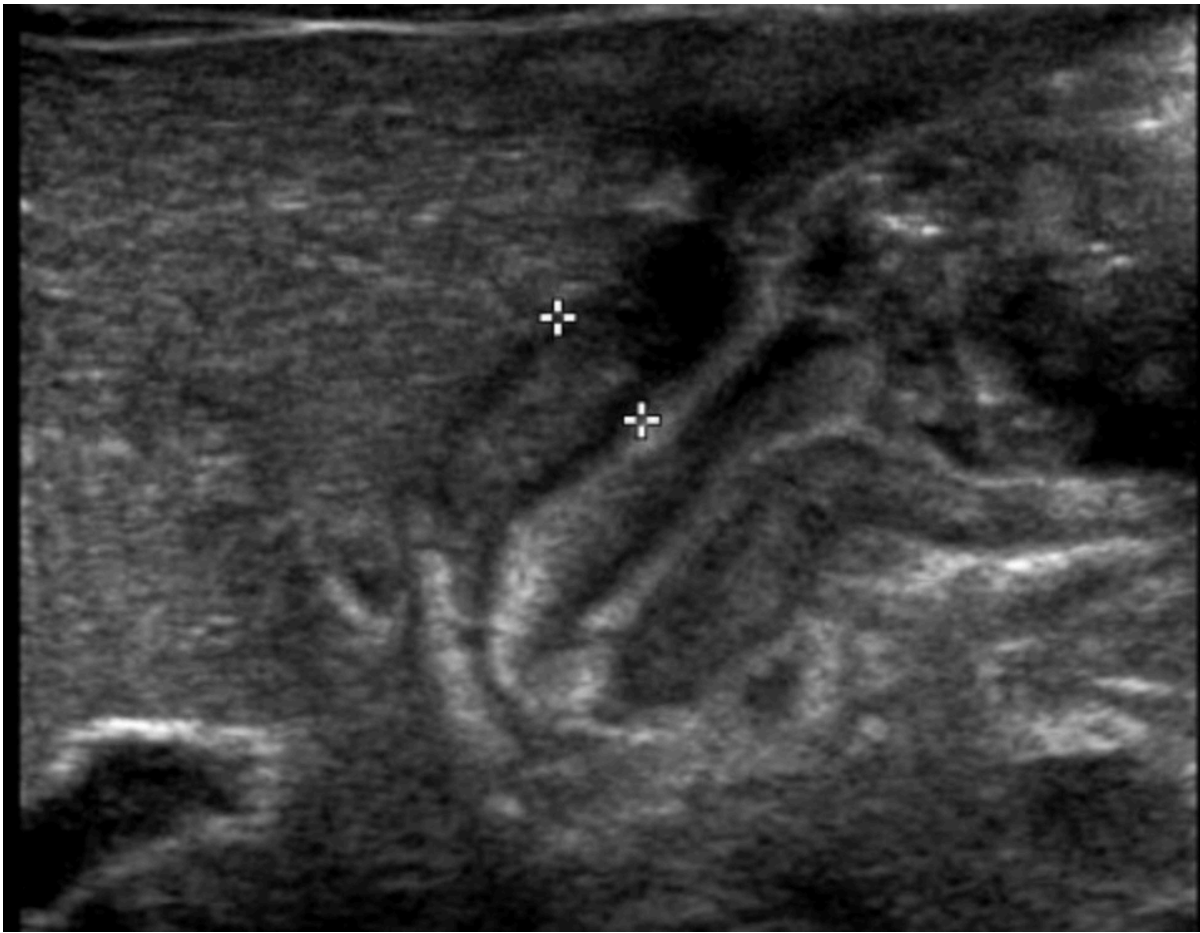


Figure 15.8B Abdominal ultrasound of the pylorus, transverse measurement.

Imaging Assessment

Findings:

The stomach was filled with fluid. The short axis and long axis measurements of the pyloric channel were at the upper limits of normal. There was hyperperistalsis of the stomach. Fluid was not seen leaving the stomach and entering the duodenum.

Interpretation:

High suspicion for hypertrophic pyloric stenosis (HPS).

Diagnosis:

Probable HPS.

Discussion:

The most common conditions to produce acute non-bilious vomiting during infancy are gastroesophageal reflux (GER), viral gastroenteritis, pylorospasm, and hypertrophic pyloric stenosis (HPS). HPS is typically suggested by

forceful bile-free emesis in a previously healthy infant around 6 weeks of age. Forceful vomiting may be reported in patients with GER, particularly in overfed patients.

When a classical “olive” of hypertrophied pyloric muscle is palpated, the diagnosis of HPS can be made clinically, and the patient can be sent to surgery for a pyloromyotomy (Heller’s myotomy) without the need for imaging examinations.

Recent advances in laparoscopic surgery suggest that accurate measurements of pyloric muscle thickening are useful in the planning of surgery, even when the diagnosis is clinically evident. When no “olive” is palpated, imaging by US or an UGI series can be performed for diagnosis.

X-ray findings may include:

- Abdominal radiography may show gastric distension with HPS.
- On occasion, mass impression of the thickened pyloric muscle on an air-filled gastric antrum may be noted.
- However, radiographs are most often not helpful in the diagnosis of HPS.

Upper Gastrointestinal Series findings may include:

- Though the contrast UGI series is excellent for diagnosing obstructive causes of vomiting in this age group it has the limitation of using ionizing radiation and therefore is less ideal than US as an initial screening test if HPS is a strong consideration.
- When doing an UGI in cases of HPS one can note the mass impression of the hypertrophied pyloric muscle on the barium-filled antrum (“shoulder sign”) or the filling of the proximal pylorus (“beak sign”) or the entire elongated pylorus (“string sign”) with barium.
- Because of the delayed gastric emptying present in cases of HPS the demonstration of the beak and string signs can be difficult to identify, often requiring considerable fluoroscopic time with a resultant increase in radiation exposure.

Ultrasonography findings may include:

- US has become a standard and highly accurate method for diagnosing HPS without the need for radiation exposure.
- It allows real-time imaging of the pyloric muscle and channel.
- The diagnosis of HPS is based on imaging of a constant elongated, thick-walled pylorus with no passage of gastric content.

- The diagnosis is supported by measurements of pyloric channel length and muscle thickness.
- Muscle thickness of ≥ 4 mm with an a length of >18 mm are considered positive for HPS, but measurements between 3 and 4 mm may also be positive, particularly in the premature or younger neonate.
- Muscle thickness measurement may be obtained on transverse or longitudinal views of the pylorus.

For some patients there is overlap of these measurements, most notably between patients with pylorospasm and patients with evolving HPS. Diagnostic caution with careful clinical follow-up has been suggested for the diagnosis of pylorospasm to avoid the possibility of under diagnosing cases evolving into HPS. Pylorospasm is said to be the most common cause of gastric outlet obstruction in this age group and, unlike HPS, it is treated conservatively.

Attributions

Figure 15.8A Abdominal ultrasound of the pylorus, longitudinal measurement by Dr. Brent Burbridge MD, FRCPC, University Medical Imaging Consultants, College of Medicine, University of Saskatchewan is used under a [CC-BY-NC-SA 4.0](#) license.

Figure 15.8B Abdominal ultrasound of the pylorus, transverse measurement by Dr. Brent Burbridge MD, FRCPC, University Medical Imaging Consultants, College of Medicine, University of Saskatchewan is used under a [CC-BY-NC-SA 4.0](#) license.

Tumors Unique to Children – Wilms Tumour

Case

Tumors Unique to Children, Wilms Tumor

Clinical:

History – Failure to thrive. Enlarging abdominal girth in a 3 year old male.

Symptoms – Lethargic. Enlarging abdomen.

Physical – The abdomen was distended and firm. Palpation of the abdomen was difficult due to the severe distention but there was suspicion for an extremely large mass in the left upper quadrant/left mid abdomen.

DDx:

Adrenal mass

Renal mass

Mesenteric mass

Pancreatic mass

Imaging Recommendation

X-rays, chest and abdomen

Ultrasound.

CT and/or MR for further characterization and staging.

ODIN Link for Wilms Tumor images (Chest x-ray, Ultrasound and CT – Chest, Abdomen, and Pelvis),
Figure 15.9A and B: <https://mistr.usask.ca/odin/?caseID=20170308141800583>

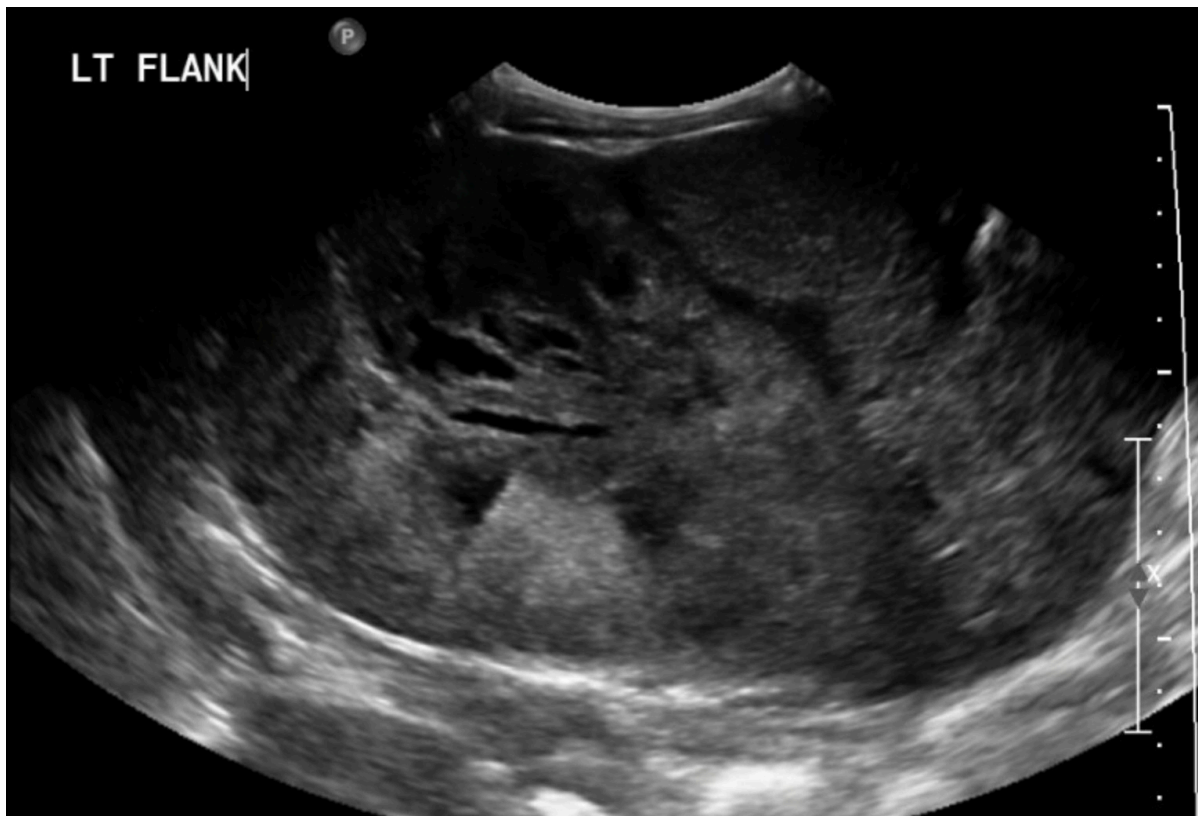


Figure 15.9A Abdominal ultrasound of the left flank/renal region demonstrating a mass.

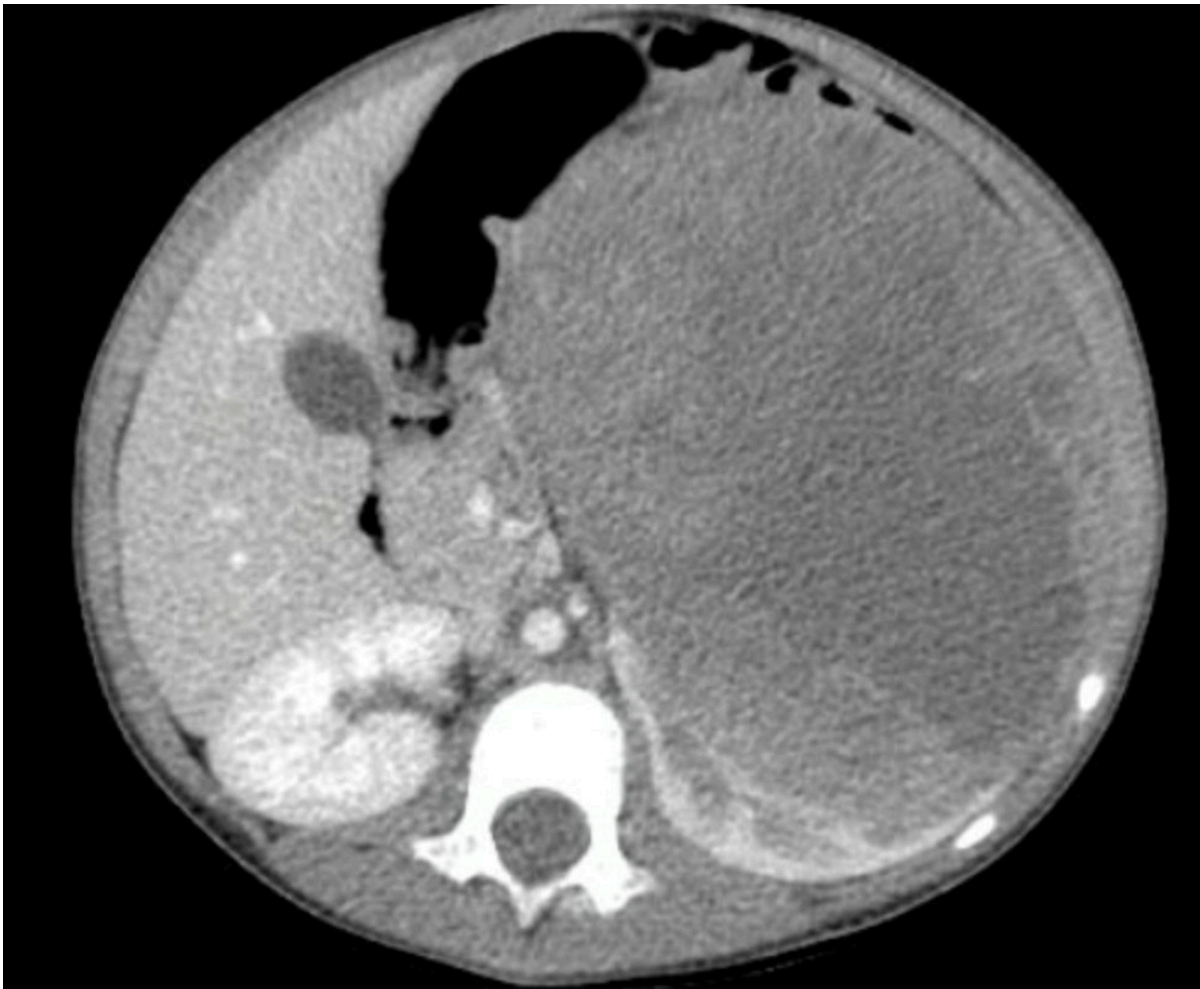

Figure 15.9B Axial CT of the abdomen revealing a very large mass.

Imaging Assessment

Findings:

Chest and abdomen x-rays

The chest x-ray was normal. There was a large mass in the left upper abdomen that obscured the fat plane between the kidney and the spleen. The mass pushed the stomach and the colon to the right. The abdomen was distended.

Ultrasound

There was a reniform shaped mass in the left upper abdomen with areas of low attenuation throughout the mass.

Computed Tomography

Multiple lung nodules were seen. There was a mixed density mass in the left upper abdomen that was pushing a small amount of normal renal parenchyma posteriorly. The renal vein could not be visualized. No obvious adenopathy.

Interpretation:

Large mass arising from the left kidney. Stage 4, metastatic lung nodules.

Diagnosis:

Wilms tumor of the left kidney – Pathology proven

Discussion:

Wilms tumor (WT), also known as *nephroblastoma*, is an embryonal renal neoplasm consisting of metanephric blastema; it accounts for 85% of cases. It represents 5.9% of all pediatric malignant tumors and has an annual incidence of 7.6 cases/million children younger than 15 years. The peak incidence occurs at 2 to 3 years. Of all patients, 13% can present with bilateral tumors.

Clinical Presentation

WT is typically discovered incidentally during a physical examination or because parents palpate an abdominal mass. Other presenting symptoms include abdominal pain and hematuria, which may signify tumor invasion into the collecting system or ureter. Another 25% develop hypertension, which is thought to occur secondary to disturbances in the renin-angiotensin feedback loop. Less than 10% of patients have atypical presentations.

Imaging findings may include:

- X-rays of the abdomen may reveal a large mass. This mass may displace the stomach or colon. The fat margin between the spleen and the liver may be obscured by the mass.
- Ultrasonography is initially performed to determine whether the tumor is of renal origin, is cystic or solid, or extends into the renal vein or IVC.
- A CT scan is useful to delineate Wilms tumor from neuroblastoma and also to evaluate for regional adenopathy, contralateral kidney involvement, and metastatic disease.
- MRI is a useful adjunct for evaluating intravascular invasion; however, an ultrasound study may be preferred.
- Lung metastases, which are present in 8% at the time of diagnosis, can be identified on an initial chest radiograph, but CT scan is obtained routinely and will be more sensitive.

Pathology

- The histology of Wilms tumor is categorized as favorable or unfavorable. Favorable histology is more common, characterized by the presence of three elements—blastemal, stromal, and epithelial cells.
- Wilms tumor with predominantly epithelial differentiation behaves less aggressively and tends to be stage I when it is diagnosed early.

- Blastemal-predominant tumors tend to be clinically aggressive and are associated with advanced disease.
- Outcomes are correlated with histopathologic features and tumor stage. Unfavorable histology is defined by the presence of anaplasia, clear cell sarcoma, or rhabdoid tumor.

Staging

The **International Society of Pediatric Oncology (SIOP)** staging system is based on pre-operative chemotherapy but is applied after resection. The presence of metastases is evaluated at presentation, relying on imaging studies, and chemotherapy is instituted before operative intervention. The National Wilms Tumor Study Group (NWTSG) has also developed a staging system that incorporates the clinical, surgical, and pathologic information that was obtained at the time of resection but stratifies patients before the initiation of chemotherapy. The advantage of this system is that it favors stage-based therapy, thereby avoiding unnecessary chemotherapy in patients who might not otherwise benefit from it.

Attributions

Figure 15.9A Abdominal ultrasound of the left flank/renal region demonstrating a mass by Dr. Brent Burbridge MD, FRCPC, University Medical Imaging Consultants, College of Medicine, University of Saskatchewan is used under a [CC-BY-NC-SA 4.0](#) license.

Figure 15.9B Axial CT of the abdomen revealing a very large mass by Dr. Brent Burbridge MD, FRCPC, University Medical Imaging Consultants, College of Medicine, University of Saskatchewan is used under a [CC-BY-NC-SA 4.0](#) license.

Pediatric – References

- 1) Sandra L. Wootton-Gorges, MD ; Bruno P. Soares, MD; Adina L Alazraki, MD, et al. ACR Appropriateness Criteria® , Pediatric – Suspected Physical Abuse Available at <https://acsearch.acr.org/docs/69443/Narrative/> American College of Radiology. Accessed June 30, 2017.
- 2) Gaillard, F. Salter-Harris Classification, Radiopaedia.org. <https://radiopaedia.org/articles/salter-harris-classification>
- 3) Boaz K. Karmazyn, MD; Adina L Alazraki, MD; Sudha A. Anupindi, MD, et al. ACR Appropriateness Criteria® Pediatric – Urinary Tract Infection. Available at <https://acsearch.acr.org/docs/69444/Narrative/> American College of Radiology. Accessed June 30, 2017.
- 4) Urinary Tract Infection: Clinical Practice Guideline for the Diagnosis and Management of the Initial UTI in Febrile Infants and Children 2 to 24 Months. Pediatrics 2011, 128 (3): 595 – 610.
- 5) Dr. Matt Skalski, Ureteric reflux, Radiopaedia.org. “<https://radiopaedia.org/> From the case “<https://radiopaedia.org/cases/22569> rID: 22569
- 6) Molly E. Raske, MD; Molly E. Dempsey, MD; Jonathan R. Dillman, MD, et al. ACR Appropriateness Criteria® Pediatric – Vomiting in Infants Up to 3 Months of Age. Available at <https://acsearch.acr.org/docs/69445/Narrative/> American College of Radiology. Accessed June 30, 2017.
- 7) [Learning radiology : recognizing the basics](#). William Herring author. Elsevier 2016 *Online access University of Saskatchewan Library*. http://usl-primo.hosted.exlibrisgroup.com/primo_library/libweb/action/search.do?vid=USASK Accessed, June 30, 2017.
- 8) [Grainger and Allison’s diagnostic radiology : a textbook of medical imaging](#). Andy Adam editor.; Adrian K. Dixon editor.; Jonathan H. Gillard 1964- editor.; Cornelia Schaefer-Prokop editor.; David J Allison; Elsevier (Firm) 2015, *Online access University of Saskatchewan Library*. http://usl-primo.hosted.exlibrisgroup.com/primo_library/libweb/action/search.do?vid=USASK Accessed June 30, 2017.

Chapter 16 – Urogenital

Urinary Tract Calculus

ACR – Urologic – Acute Onset of Flank Pain – Suspicion of Urolithiasis

Case

Left ureteric calculus

Clinical:

History – Left flank pain in a 55 year old female. The patient had a history of uterine fibroids.

Symptoms – The patient presents with persistent left flank pain that seems to come in waves. She thinks there was blood in her urine. She says the pain radiated from the left back to the left groin.

Physical – Left costophrenic angle tenderness was identified. Nil else. Macroscopic blood was seen in her urine.

Laboratory – Hematuria was definitely present.

DDx:

Renal mass

Urinary tract infection

Urinary tract calculus

Imaging Recommendation

[ACR – Urologic – Acute Onset Flank Pain – Suspicion for Urolithiasis, Variant 1](#)

CT of Abdomen and Pelvis

ODIN Link for Ureteric Calculus images (CT), Figure 16.1A and B: <https://mistr.usask.ca/odin/?caseID=20151222091749379>

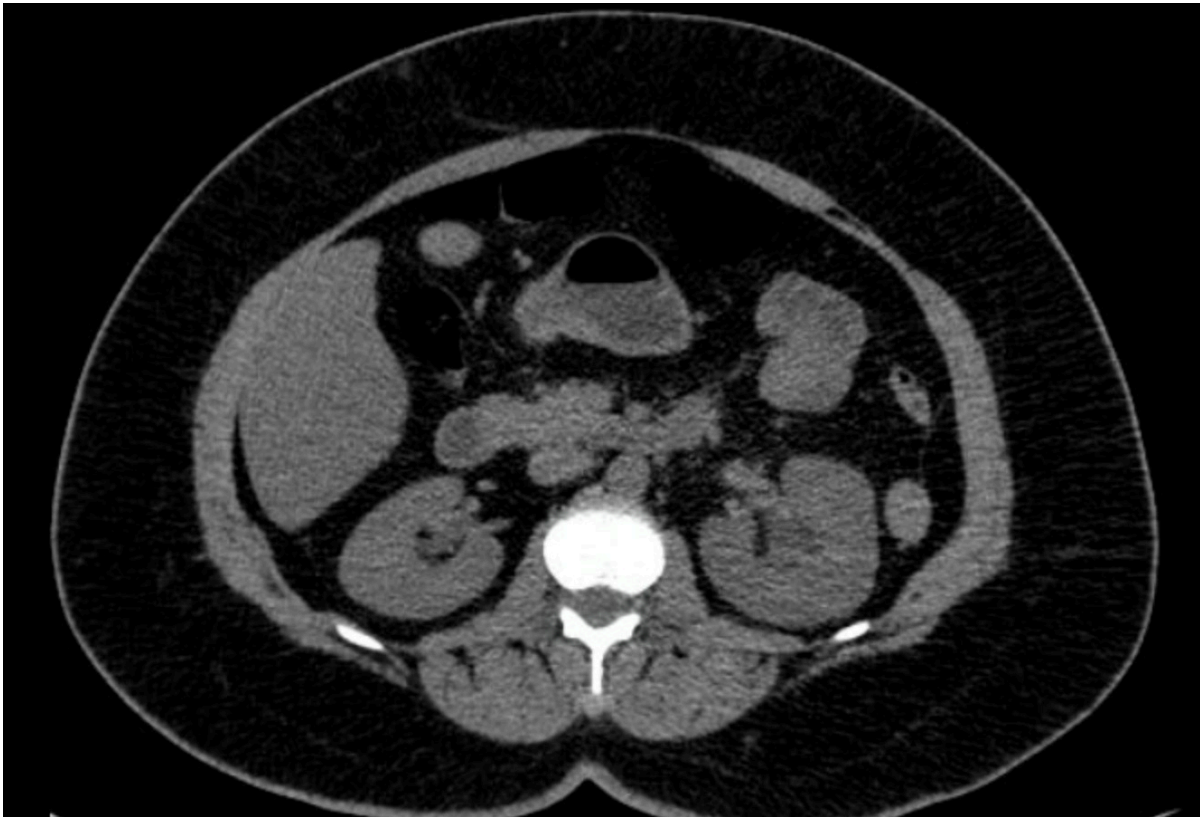


Figure 16.1A Axial CT of the abdomen

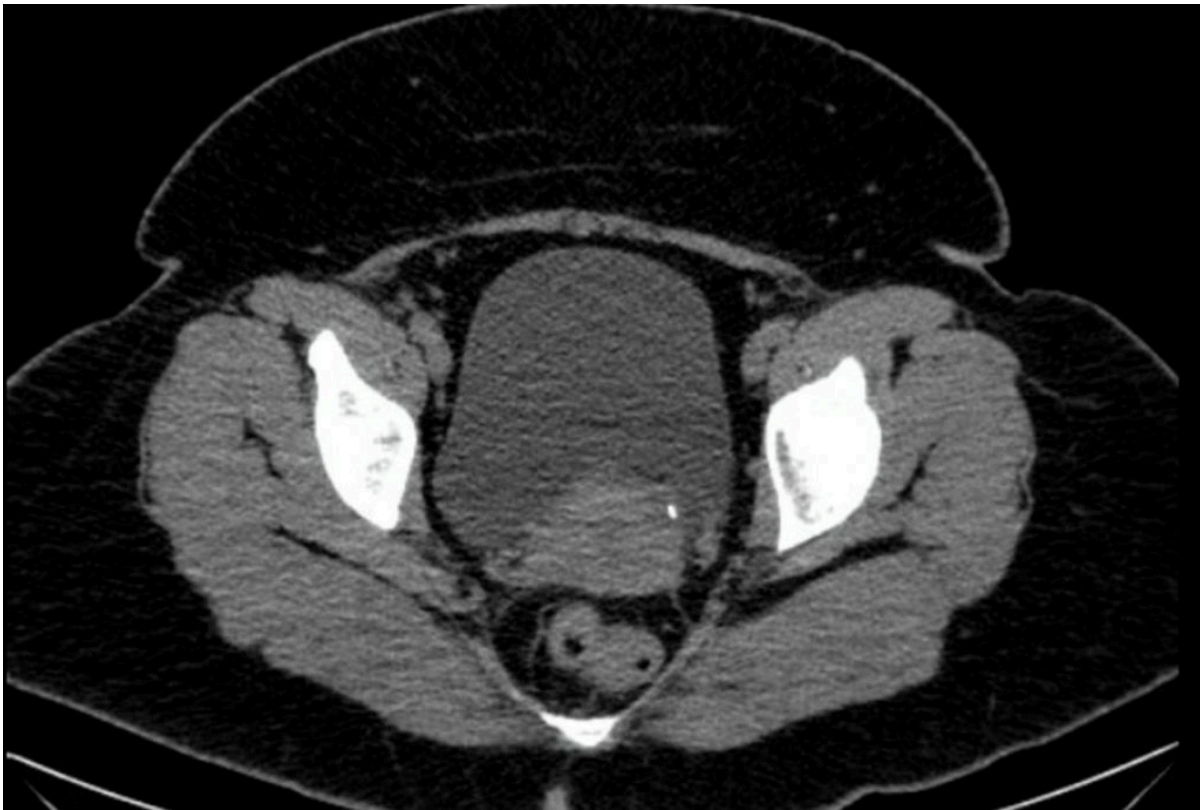

Figure 16.1B Axial CT of the pelvis displaying a left ureteric calculus.

Imaging Assessment

Findings:

The left kidney was mildly hydronephrotic and there was mild perinephric fat stranding. The left ureter was mildly prominent. A dense, small (5mm), calcification was seen at the left vesico-ureteric junction. Calcified fibroids were seen in the uterus. Nil else.

Interpretation:

Left ureteric calculus

Diagnosis:

Left ureteric calculus

Discussion:

Urinary tract calculi are thought to result from either excessive excretion and precipitation of salts in the urine or a relative lack of inhibiting substances. Men are more commonly affected than women, and the incidence increases with age until age 60 years. Children are affected less frequently. Calculi (stones) tend to be recurrent, and flank pain is a nonspecific symptom that may be associated with other entities; therefore, evaluation with imaging is recommended at the initial presentation.

A stone small enough to pass into the ureter may cause blockage of urine flow with distension of the upper urinary

tract. The ureter contains several areas where stones commonly become lodged (e.g., at the ureteropelvic junction, the iliac vessels, and the ureterovesical junction). Ureteral hyperperistalsis occurs, resulting in the acute onset of sharp, spasmodic flank pain. Irritation of and trauma to the ureter may also result in hematuria.

The probability of spontaneous passage of a stone is size dependent, and the probability is inversely proportional to stone size. A meta-analysis yielded an estimate that a calculus ≤ 5 mm has a 68% probability of spontaneous passage. A 10-mm stone, however, was very unlikely to pass spontaneously. Therefore, the treating physician wants to know the size of the stone as well as its location.

Since the introduction of helical (spiral) CT as the initial study in evaluating flank pain, numerous investigations have confirmed it to be the study with the highest (>95%) sensitivity and specificity for urolithiasis. Virtually all stones are radiopaque on CT, and stone size can be measured accurately in multiple planes, aiding in predicting outcome.

Concerns over radiation exposure, especially in young stone patients, have led to the development of reduced-dose CT regimens. If CT is being performed to evaluate for renal or ureteral stones, a low dose protocol should be performed. Techniques for lowering dose include using a lower kVp, lower tube current, use of automated tube current modulation, and use of iterative reconstruction.

X-ray findings may include:

- Urinary tract calculi frequently contain calcium (70 – 80%). Thus, they may be seen on radiographs.
- The calculus may be anywhere in the distribution of the collecting system, ureter, or bladder.
- Small calculi may be difficult to see or may be confused with ingested pills, lymph node calcification, vascular calcification, or phleboliths.

Attributions

Figure 16.1A Axial CT of the abdomen by Dr. Brent Burbridge MD, FRCPC, University Medical Imaging Consultants, College of Medicine, University of Saskatchewan is used under a [CC-BY-NC-SA 4.0](#) license.

Figure 16.1B Axial CT of the pelvis displaying a left ureteric calculus by Dr. Brent Burbridge MD, FRCPC, University Medical Imaging Consultants, College of Medicine, University of Saskatchewan is used under a [CC-BY-NC-SA 4.0](#) license.

Renal Tumour

ACR – Urologic – Indeterminate Renal Mass

Case

Renal Cell Carcinoma

Clinical:

History – A mass in the vicinity and probably involving the left kidney was incidentally discovered during an abdominal ultrasound for right upper quadrant pain.

Symptoms – None

Physical – None

Laboratory – Microscopic hematuria was detected.

DDx:

Adrenal mass

Renal mass

Splenic mass

Adenopathy

Imaging Recommendation

[ACR – Urologic – Indeterminate Renal Mass, Variant 1](#)

CT Abdomen

ODIN Link for Renal Mass images (Ultrasound and CT), Figure 16.2A and B: <https://mistr.usask.ca/odin/?caseID=20151216124857470>

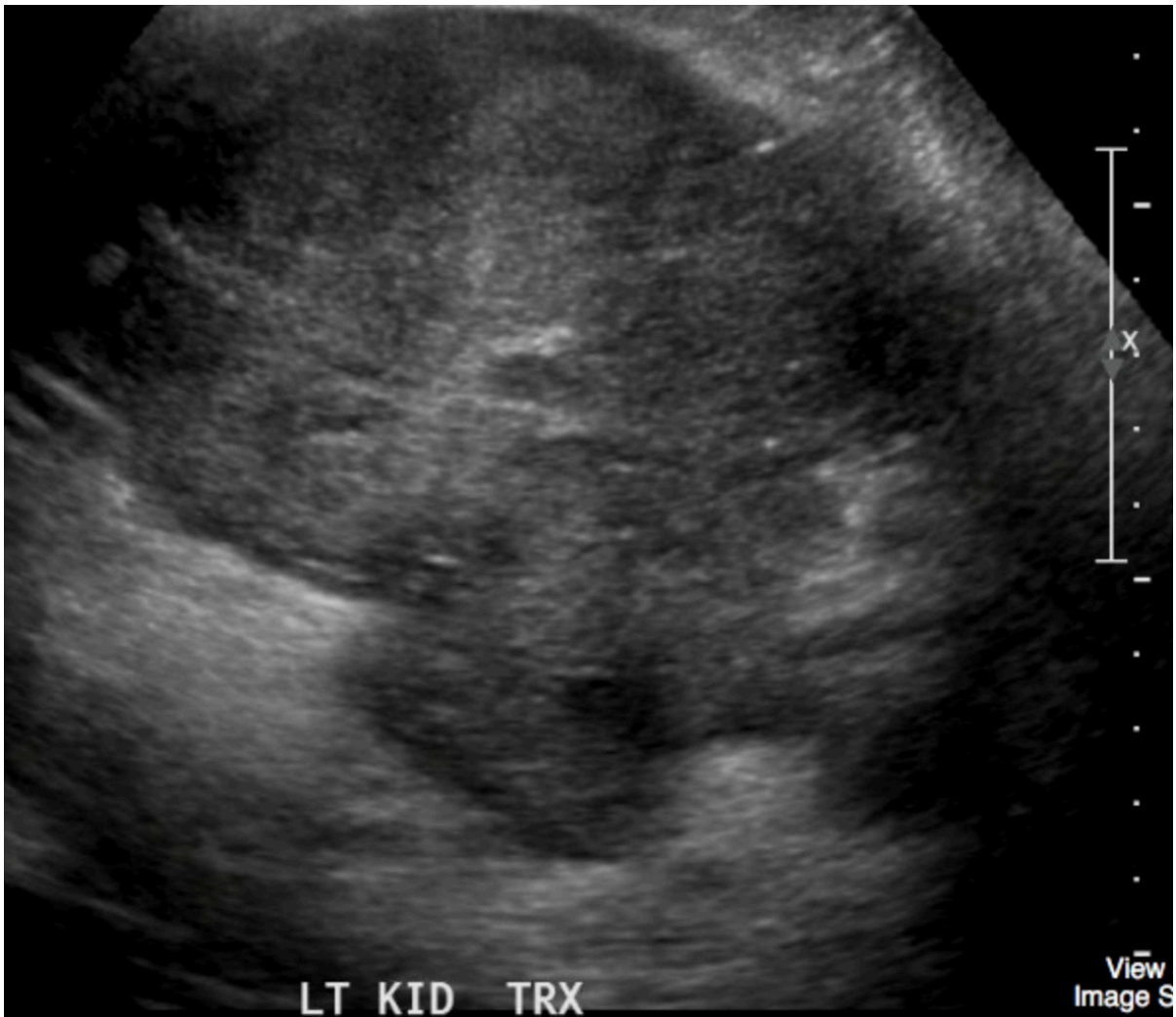


Figure 16.2A Transverse ultrasound of the left kidney mass.

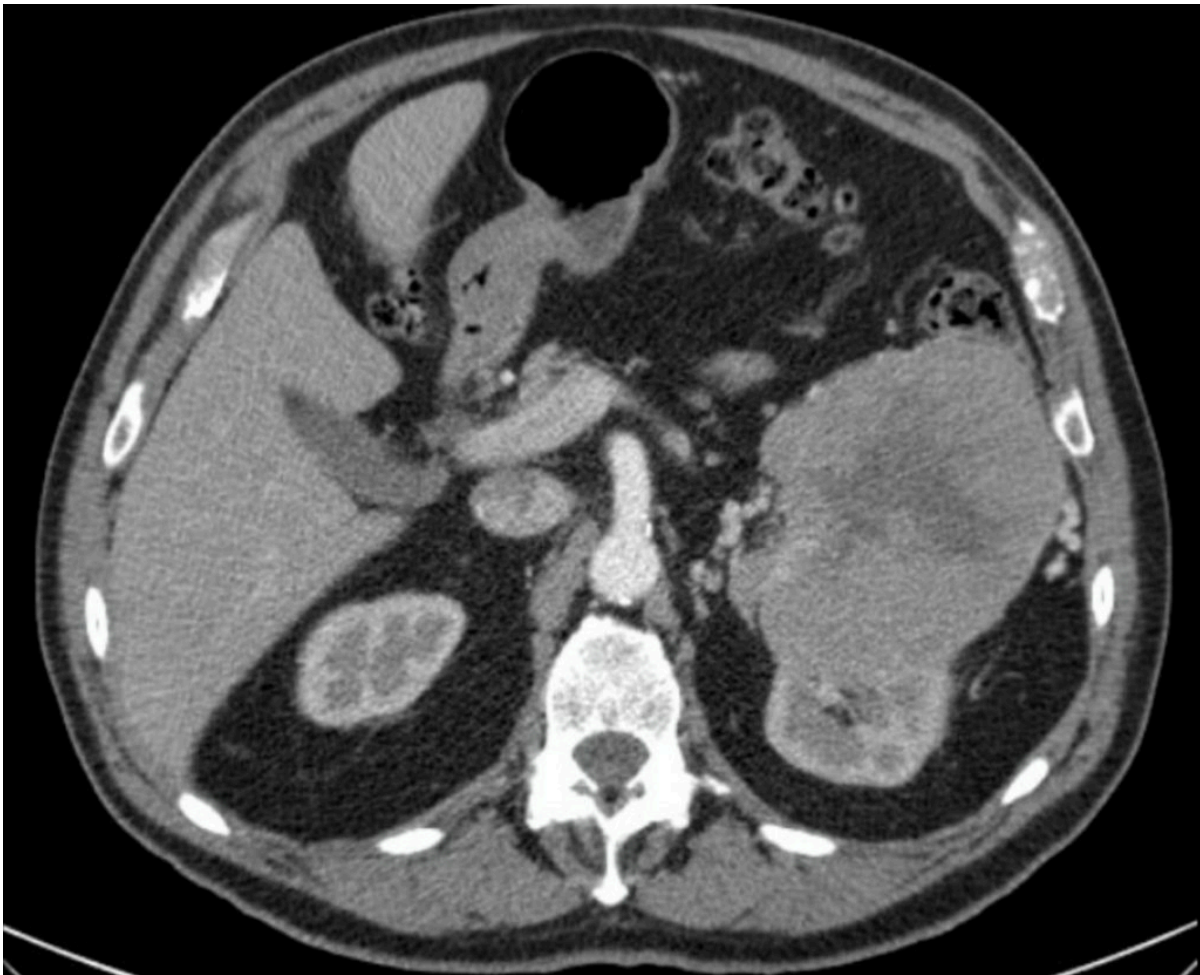


Figure 16.2B Axial CT of the abdomen revealing a renal tumour.

Imaging Assessment

Findings:

Ultrasound

An inhomogeneous mass was seen in the vicinity of the pancreatic tail and left kidney. The organ of origin was not easily determined. No other findings. CT was recommended.

Computed Tomography

The large, exophytic, mass arose from the cranial left kidney. It was of inhomogeneous density with some low density in the centre. The mass poorly contrast enhanced. No lymphadenopathy. The left renal vein was normal in appearance.

Interpretation:

Renal mass – High suspicion for renal carcinoma.

Diagnosis:

Renal Cell Carcinoma (Chromophobe subtype) – Biopsy proven

Discussion:

An indeterminate renal mass is one that cannot be diagnosed confidently as benign or malignant at the time it is discovered. Renal masses are increasingly detected in asymptomatic individuals as incidental findings. Computed tomography (CT), ultrasonography (US), and magnetic resonance imaging (MRI) of renal masses with fast-scan techniques and intravenous (IV) gadolinium are the mainstays of evaluation.

Dual-energy CT, contrast-enhanced US, positron emission tomography PET/CT, and percutaneous biopsy are all technologies that are gaining traction in the characterization of the indeterminate renal mass.

Computed Tomography

CT is the most utilized imaging technique for evaluating the indeterminate renal mass, playing an important role in the characterization of both solid and cystic lesions. Although the majority of lesions are characterized on initial imaging, one definition for the indeterminate renal mass is a lesion containing areas that measure 20–70 Hounsfield units (HU) on non-contrast imaging.

Homogeneous lesions measuring <20 HU or >70 HU can be considered benign, whereas lesions either entirely or partially within the 20–70 HU range should be considered indeterminate and warrant further evaluation.

For those lesions requiring further evaluation, enhancement after IV contrast is key in determining if a renal mass warrants treatment. Enhancing solid renal masses or enhancing components in cystic masses indicates a vascularized mass and, therefore, a possible malignancy. The degree of renal enhancement is dependent on many factors, including the amount and rate of contrast material injection, the timing of contrast-enhanced imaging, and the intrinsic characteristics of both the mass and the adjacent renal parenchyma.

Proper characterization of a renal mass includes at least 3 phases: non-contrast imaging followed by contrast-enhanced imaging in corticomedullary and nephrographic phases.

Attributions

Figure 16.2A Transverse ultrasound of the left kidney mass by Dr. Brent Burbridge MD, FRCPC, University Medical Imaging Consultants, College of Medicine, University of Saskatchewan is used under a [CC-BY-NC-SA 4.0](#) license.

Figure 16.2B Axial CT of the abdomen revealing a renal tumor by Dr. Brent Burbridge MD, FRCPC, University Medical Imaging Consultants, College of Medicine, University of Saskatchewan is used under a [CC-BY-NC-SA 4.0](#) license.

Hematuria

ACR – Urologic – Hematuria

Case

Transitional Cell Carcinoma

Clinical:

History – Macroscopic hematuria.

Symptoms – This 66 year old female reported macroscopic hematuria. She also feels that she is not completely emptying her bladder.

Physical – None

DDx:

Cystitis

Bladder mass

Bladder dystonia

Imaging Recommendation

[ACR – Urologic – Hematuria, Variant 3](#)

CT Abdomen and Pelvis

ODIN Link for Bladder Mass images, Figure 16.3A and B: <https://mistr.usask.ca/odin/?caseID=20170311002429649>

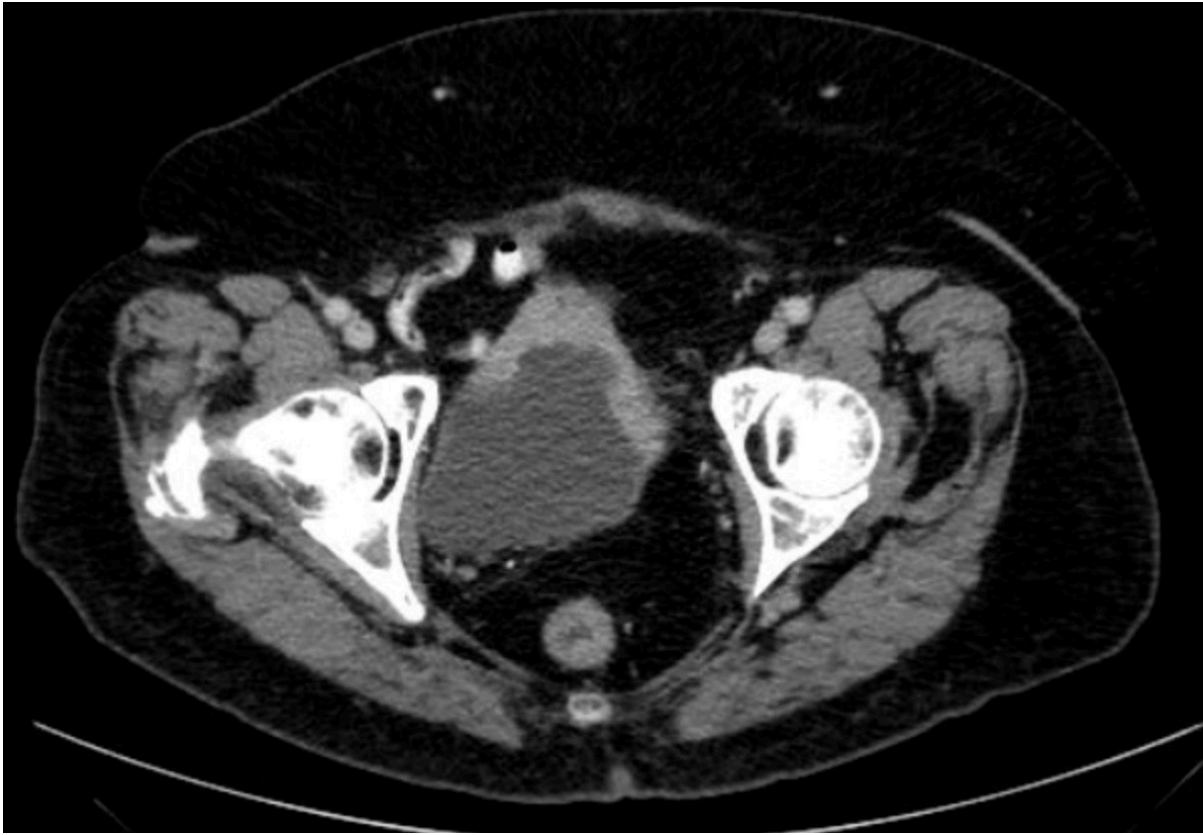

Figure 16.3A Axial CT of the pelvis without contrast. The bladder wall was thickened.

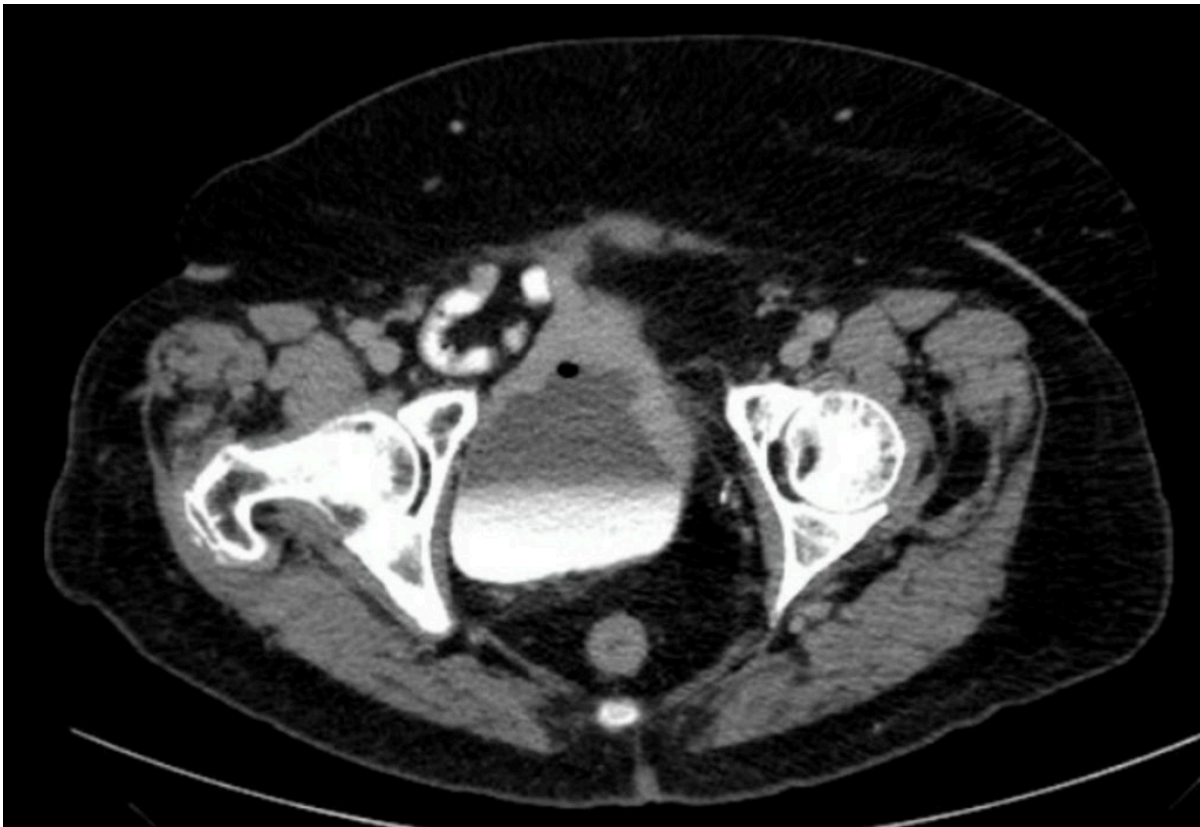


Figure 16.3B Axial CT of the pelvis with contrast demonstrating the bladder wall mass.

Imaging Assessment

Findings:

The CT revealed a thick, irregular, ventral wall of the bladder. This thick wall contrast enhanced. No other findings.

Interpretation:

Bladder wall mass

Diagnosis:

Transitional Cell Carcinoma – Biopsy proven

Discussion

Hematuria is one of the most common presentations of patients with urinary tract diseases and of patients referred for urinary imaging. This discussion describes a radiologic approach to such patients. It is limited to adults and does not refer to patients whose hematuria coexists with other clinical situations reviewed in other ACR Appropriateness Criteria® topics, including acute trauma, infection, renal failure, symptoms of acute stone disease, known renal masses, and prostatism.

The initial decision to be made is whether all patients with any degree of hematuria need imaging evaluation. Hematuria can originate from any site in the urinary tract but can be roughly divided into renal, urothelial, or prostatic causes. Thorough evaluation of gross hematuria is recommended, and this is usually done with a combination of clinical examination, cystoscopic evaluation, and urinary tract imaging. Patients on anticoagulants who present with gross or microscopic hematuria have a sufficiently high prevalence of important diseases including renal and uroepithelial tumors that workup cannot be forgone.

The imaging evaluation will almost always be accompanied by cystoscopy to evaluate the urinary bladder, since many bleeding urinary tract lesions arise in the urinary bladder, and imaging procedures are not yet conclusively proven to be as sensitive as cystoscopy in diagnosing most of them. Multi-detector-row computed tomography (CT) has been evaluated in detecting bladder cancers, and reports suggest a sensitivity and specificity of 95% and 92%, respectively. One retrospective study reports that computed tomography urography (CTU) and cystoscopy had similar diagnostic accuracy for detection of bladder cancer in patients with hematuria alone; however, cystoscopy remains superior in patients with prior urothelial malignancy.

Computed Tomography

Until the mid -1990's, excretory urography (IVU) was the imaging study used in evaluating hematuria, but development of multidetector CT and the excretory phase CT urogram, also known as CTU, have supplanted IVU over the past 15 years.

Attributions

Figure 16.3A Axial CT of the pelvis without contrast. The bladder wall was thickened by Dr. Brent Burbridge MD, FRCPC, University Medical Imaging Consultants, College of Medicine, University of Saskatchewan is used under a [CC-BY-NC-SA 4.0](#) license.

Figure 16.3B Axial CT of the pelvis with contrast demonstrating the bladder wall mass by Dr. Brent Burbridge MD, FRCPC, University Medical Imaging Consultants, College of Medicine, University of Saskatchewan is used under a [CC-BY-NC-SA 4.0](#) license.

Testicular Tumour

Case

Mixed Germ Cell Tumour, Testicle

Clinical:

History – This 45 year old male discovered a testicular mass.

Symptoms – Scrotal mass

Physical – The left testicle was enlarged and lobulated.

DDx:

Testicular mass

Epididymal mass

Testicular appendix

Imaging Recommendation

Scrotal Ultrasound

ODIN Testicular Mass images (Ultrasound), Figure 16.4A and B: <https://mistr.usask.ca/odin/?caseID=20170311000709570>

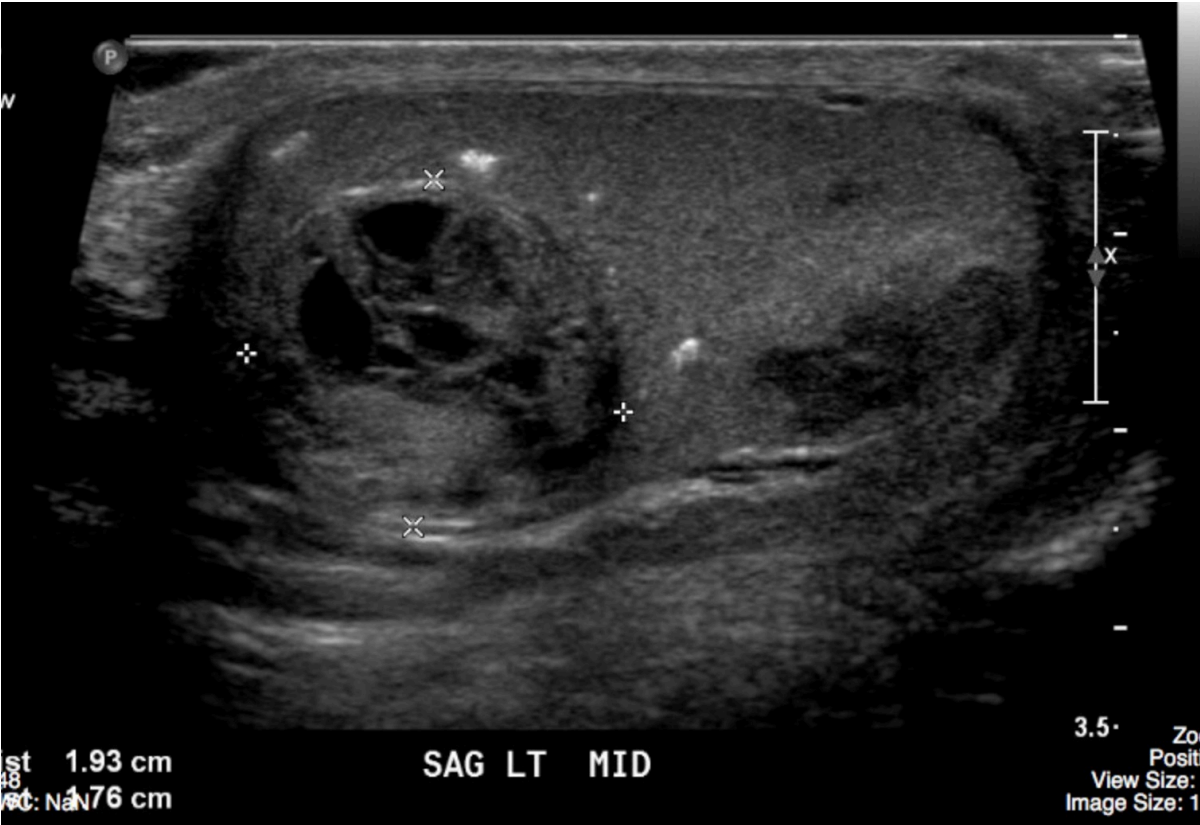

Figure 16.4A Sagittal ultrasound of the left testicle revealed a cystic and solid mass.

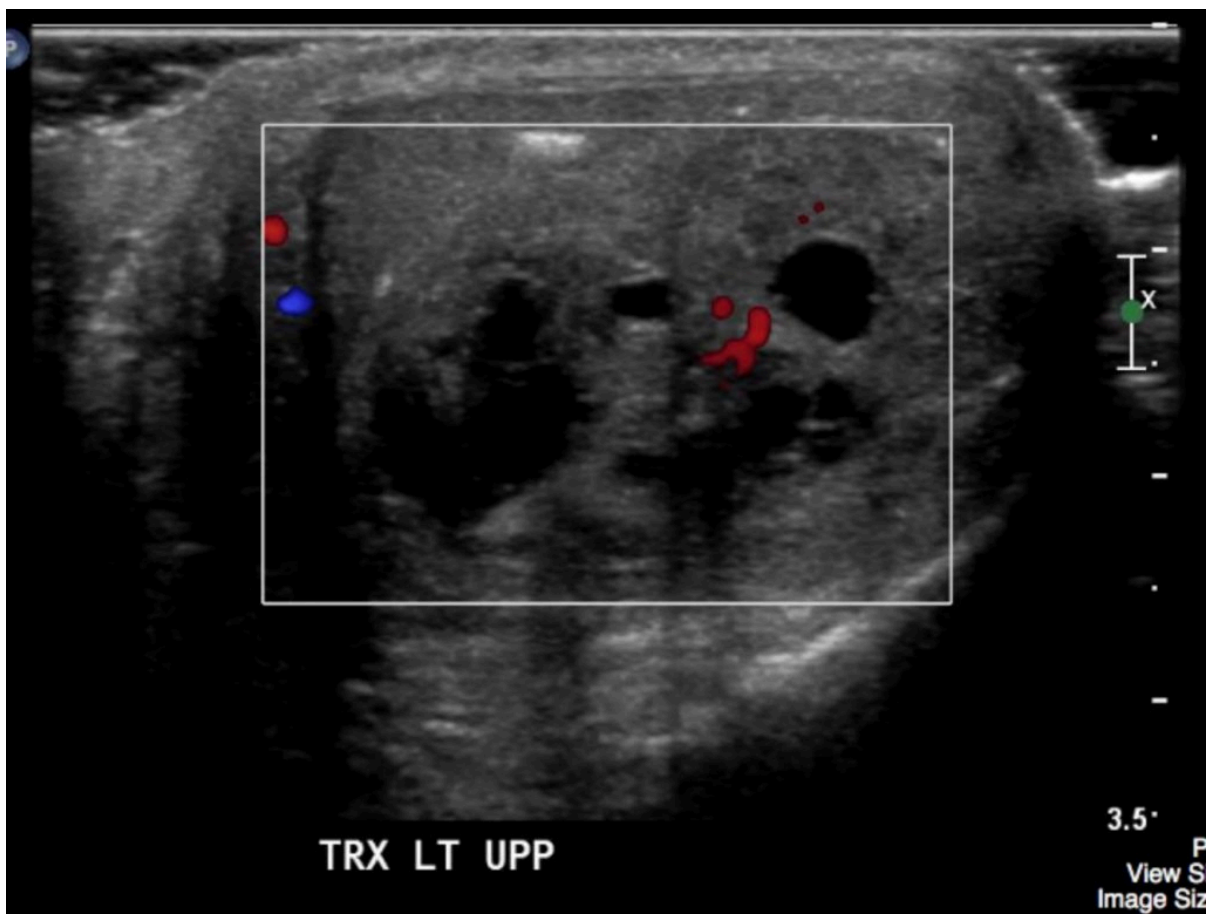


Figure 16.4B Transverse Doppler ultrasound of the left testicular tumour.

Imaging Assessment

Findings:

The images revealed a mixed cystic and solid mass of the left testicle with increased Doppler signal associated with the mass.

Interpretation:

Testicular mass

Diagnosis:

Mixed Germ Cell Tumour – Pathology proven

Discussion:

Although carcinoma of the testicle is relatively uncommon, representing only 1% of all malignancies occurring in men, it is the most frequent malignancy in men between the ages of 20 and 34, accounting for 10% to 14% of cancer incidence in that age group. The National Cancer Institute estimates that there will be about 8,430 new cases of testicular cancer in the U.S. and about 380 deaths from the disease in 2015.

Over 90% of testicular tumors are of germ cell origin and are malignant. Of these, 40% are seminomas. The nonseminomatous tumours are clinically more aggressive and include embryonal cell carcinoma (15% to 20%), teratoma (5% to 10%), and choriocarcinoma (<1%). Testicular cancer has an excellent prognosis, with 10-year survival rates exceeding 96%. Non-germ-cell tumours are typically benign and have their origin from the Leydig and Sertoli cells or from connective tissue stroma.

Scrotal US is frequently used, and should always be the initial imaging modality in assessing patients with scrotal masses. This study can often differentiate fluid-filled spermatoceles and hydroceles from solid intratesticular tumours. Often times, the diagnosis of a testicular mass is apparent by clinical evaluation, and US can be used for confirmation.

US findings may include:

- US is used to distinguish between intra-testicular masses, which are more commonly malignant, and extra-testicular masses, which are more commonly benign.
- US can also be used to accurately differentiate intra-testicular solid masses, which are often malignant, from cystic lesions, which are usually benign and may include tubular ectasia of the rete testes, simple cysts, and tunica albuginea cysts.
- Solid masses usually appear hypoechoic relative to the adjacent testicular parenchyma, and internal vascularity is usually detectable with color Doppler imaging.
- In comparison, cysts appear anechoic, with no internal vascularity, and usually demonstrate posterior acoustic enhancement.
- At imaging, a solid intra-testicular mass with internal vascularity is suggestive of a testicular tumor in the appropriate clinical setting.
- US has been shown to have a 92%–98% sensitivity and a 95%–99.8% specificity for testicular malignancy.

Attributions

Figure 16.4A Sagittal ultrasound of the left testicle revealed a cystic and solid mass by Dr. Brent Burbridge MD, FRCPC, University Medical Imaging Consultants, College of Medicine, University of Saskatchewan is used under a [CC-BY-NC-SA 4.0](#) license.

Figure 16.4B Transverse doppler ultrasound of the left testicular tumor by Dr. Brent Burbridge MD, FRCPC, University Medical Imaging Consultants, College of Medicine, University of Saskatchewan is used under a [CC-BY-NC-SA 4.0](#) license.

Testicular Torsion

ACR – Urologic – Acute Scrotal Pain, Without Trauma

Case

Testicular Torsion

Clinical:

History – This 15 year old male presented with severe right scrotal pain.

Symptoms – Severe right scrotal pain.

Physical – The right testicle was mildly enlarged and very tender.

DDx:

Epididymitis

Orchitis

Testicular torsion

Imaging Recommendation

[ACR – Urologic – Acute Scrotal Pain, Without Trauma, Variant 1](#)

Doppler Ultrasound of the Scrotum

ODIN Link for Testicular Tortion images (Ultrasound), Figure 16.5A and B: <https://mistr.usask.ca/odin/?caseID=20170310235217099>

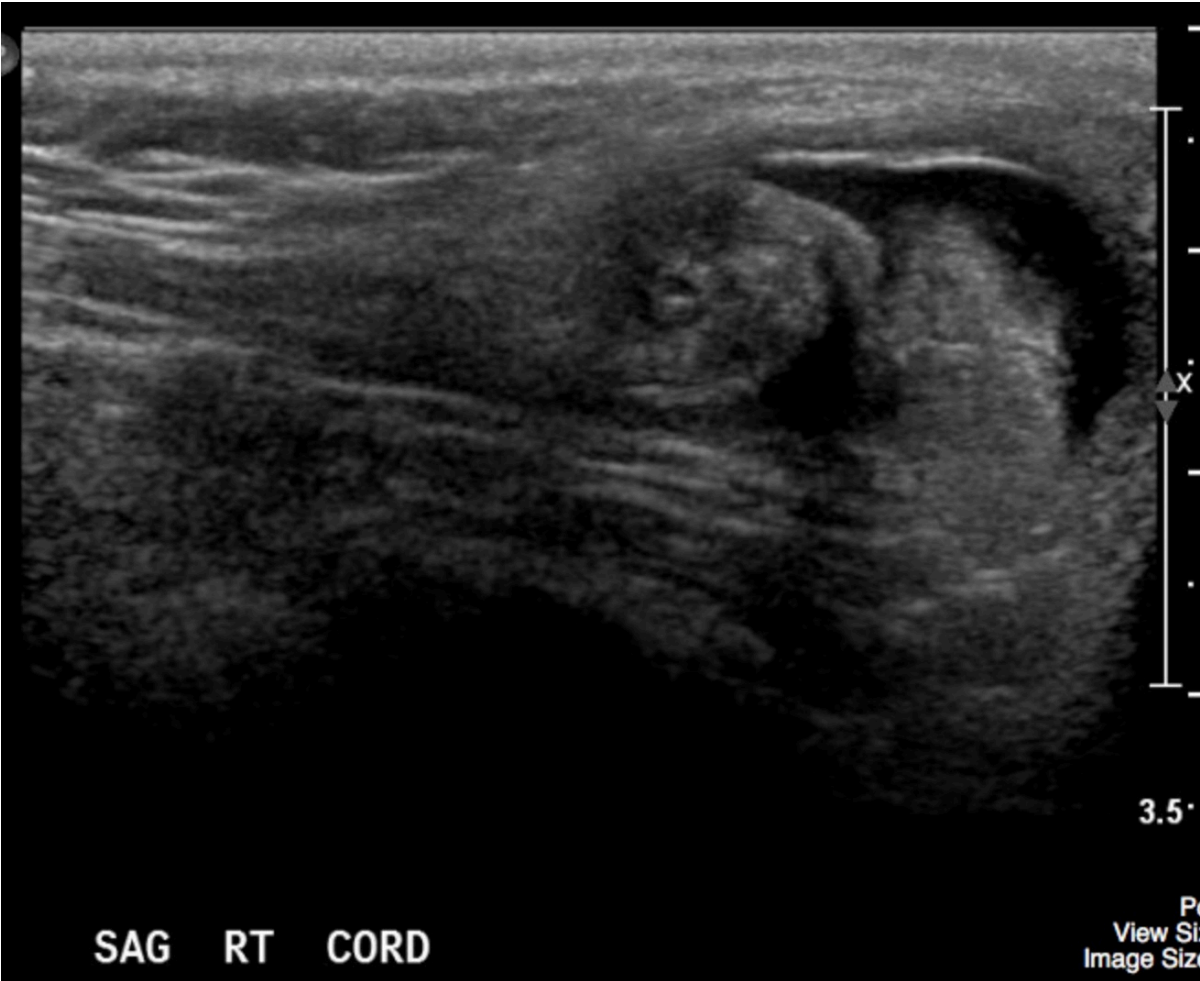

Figure 16.5A Sagittal ultrasound of right spermatic cord demonstrating the “whirlpool sign”.

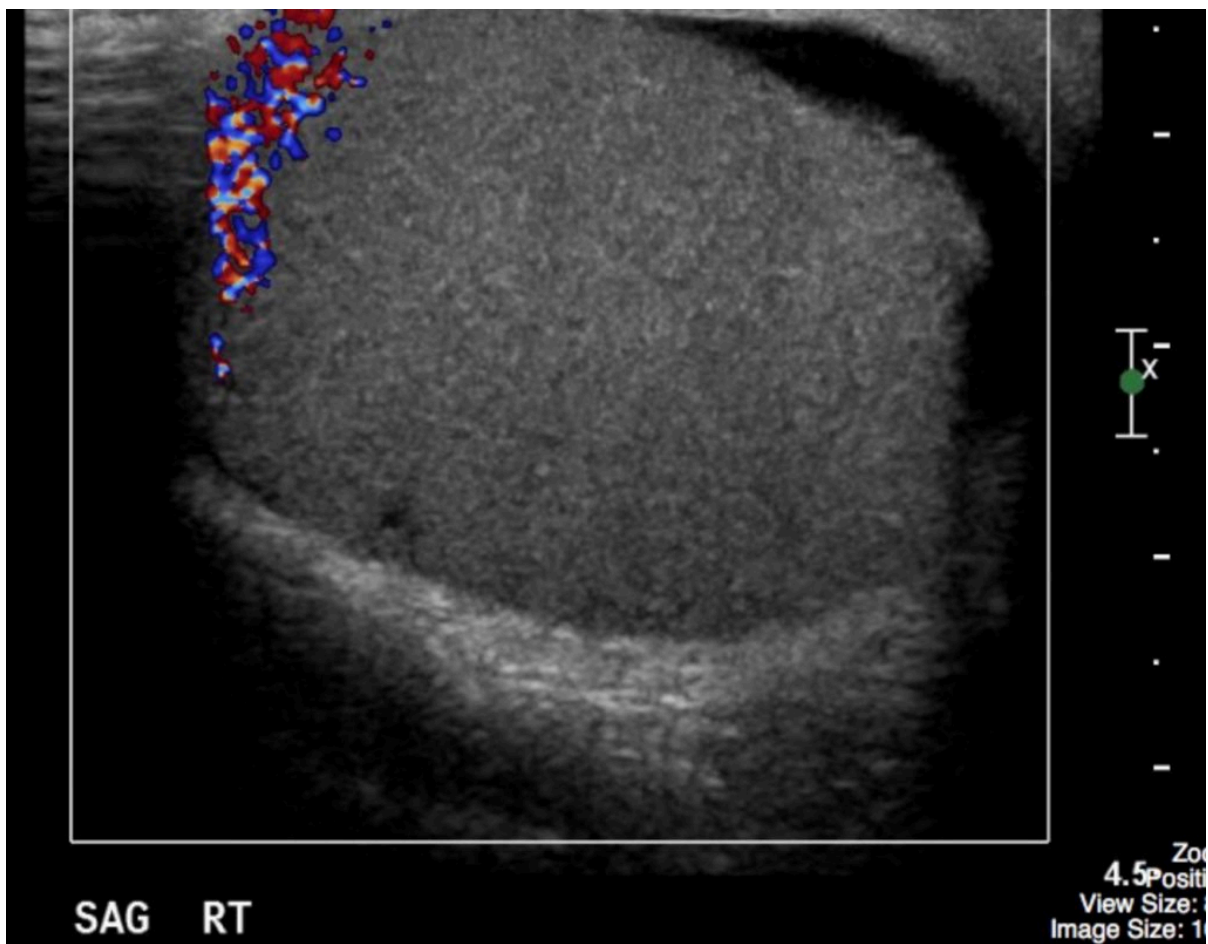


Figure 16.5B Sagittal Doppler ultrasound of right testicle revealed no detectable blood flow in the testicle.

Imaging Assessment

Findings:

The right testicle was uniform in appearance. There was no Doppler flow to the right testicle. A ‘whirlpool’ appearance to the spermatic cord was visualized.

Interpretation:

Right testicular torsion

Diagnosis:

Testicular torsion

Discussion:

The ability to confidently establish a surgical versus a nonsurgical diagnosis for acute scrotal pain is important. The benefits of early surgery for testicular salvage in ischemic disease, primarily torsion of the spermatic cord,

are well known, but must be balanced against the costs of operating unnecessarily on a large number of patients with nonsurgical disease, primarily acute epididymitis.

The most common differential diagnoses of the acute scrotum include 1) torsion of the spermatic cord, 2) torsion of the testicular appendages, and 3) acute epididymitis or epididymo-orchitis. Less common diagnoses include strangulated hernia, segmental testicular infarction, trauma, testicular tumor, and idiopathic scrotal edema.

Acute epididymitis is commonly the cause of acute scrotal pain in adults and should be differentiated from testicular torsion. Testicular torsion is rare in patients older than age 35. Acute epididymitis is commonly the cause of acute scrotal pain in patients younger than age 18, very common in patients age 19 to 25, and overwhelmingly the etiology in patients older than age 25.

Acute scrotal pain in prepubertal boys occurs most commonly from torsion of the testicular appendages, a process that may clinically mimic testicular torsion or epididymo-orchitis.

Patients with testicular torsion typically present with abrupt scrotal pain, whereas those with epididymitis have a more gradual onset of pain. Patients with torsion will have a normal urinalysis, whereas those adults (but not children) with epididymitis will have an abnormal urinalysis. There is, however, overlap in the clinical presentation of the different causes of acute scrotal pain.

Imaging in clinically equivocal cases may lead to an early diagnosis of testicular torsion and thus decrease the number of unnecessary surgeries.

US findings may include:

- Grayscale US is most sensitive to the earliest changes resulting from decreased or absent testicular perfusion.
- In patients with torsion, however, a normal homogenous echo pattern is likely to indicate a viable testis, whereas a hypoechoic or inhomogeneous testis is likely to be nonviable.
- The finding of a twisted cord has been referred to as the “whirlpool sign” and can be found at the external inguinal ring, above the testis, and posterior to the testis.
- Color Doppler US (CDU) is a valuable examination for evaluating testicular perfusion.
- Color duplex Doppler involves the simultaneous acquisition and display of color Doppler and spectral Doppler waveforms in conjunction with grayscale sonographic imaging. Settings optimized to detect slow flow include use of a small color-sampling box, lowest pulse repetition frequency, and lowest possible threshold.
- CDU is readily available and can be done quickly without any specific preparation.

Attributions

Figure 16.5A Sagittal ultrasound of right spermatic cord demonstrating the “whirlpool sign”, by Dr. Brent Burbridge MD, FRCPC, University Medical Imaging Consultants, College of Medicine, University of Saskatchewan is used under a [CC-BY-NC-SA 4.0](#) license.

Figure 16.5B Sagittal doppler ultrasound of right testicle revealed no detectable blood flow in the testicle by Dr. Brent Burbridge MD, FRCPC, University Medical Imaging Consultants, College of Medicine, University of Saskatchewan is used under a [CC-BY-NC-SA 4.0](#) license.

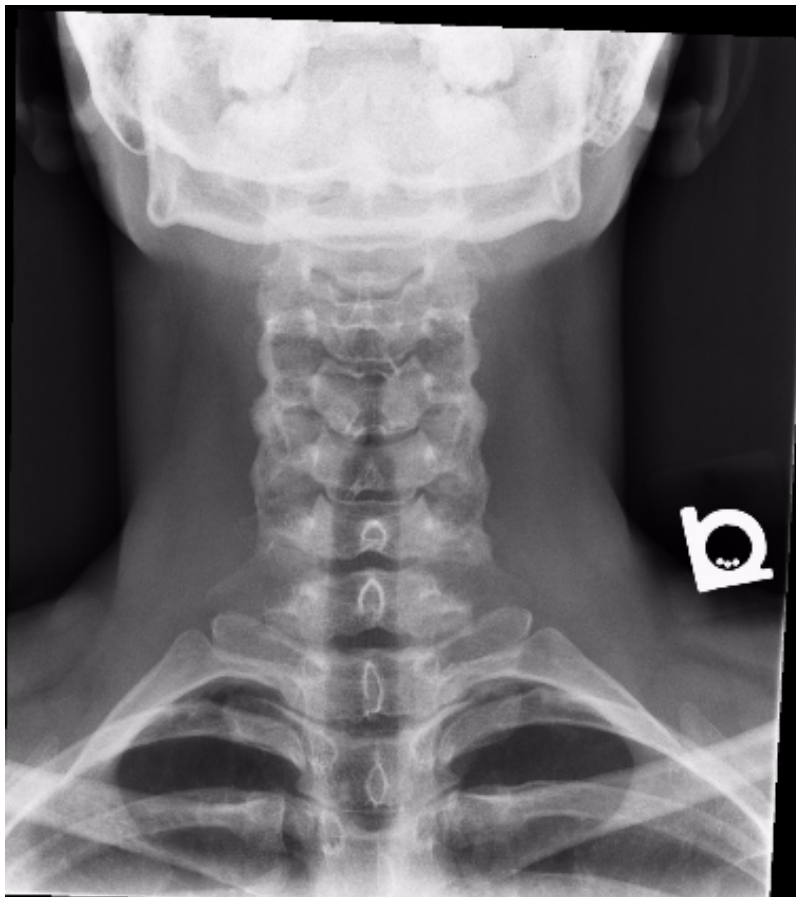Urogenital – References

- 1) Courtney Coursey Moreno, MD; Michael D. Beland, MD; Stanley Goldfarb, MD, et al. ACR Appropriateness Criteria®, Urologic – Acute Onset Flank Pain – Suspicion of Urolithiasis. Available at <https://acsearch.acr.org/docs/69362/Narrative/> American College of Radiology. Accessed, June 30, 2017.
- 2) Marta E. Heilbrun, MD; David D. Casalino, MD; Michael D. Beland, MD, et al. ACR Appropriateness Criteria®, Urologic – Indeterminate Renal Mass. Available at <https://acsearch.acr.org/docs/69367/Narrative/> American College of Radiology. Accessed, June 30, 2017.
- 3) Luyao Shen, MD; Steven S. Raman, MD; Michael D. Beland, MD, et al. ACR Appropriateness Criteria®, Urologic – Hematuria Available at <https://acsearch.acr.org/docs/69490/Narrative/> American College of Radiology. Accessed, June 30, 2017.
- 4) Matthew S. Hartman, MD; John R. Leyendecker, MD; Barak Friedman, MD, et al. ACR Appropriateness Criteria®, Urologic – Acute Scrotal Pain, Without Trauma. Available at <https://acsearch.acr.org/docs/69363/Narrative/> American College of Radiology. Accessed, June 30, 2017.
- 5) [Learning radiology : recognizing the basics](#). William Herring author. Elsevier 2016 *Online access University of Saskatchewan Library*. http://usl-primo.hosted.exlibrisgroup.com/primo_library/libweb/action/search.do?vid=USASK Accessed, June 30, 2017.
- 6) [Grainger and Allison's diagnostic radiology : a textbook of medical imaging](#). Andy Adam editor.; Adrian K. Dixon editor.; Jonathan H. Gillard 1964- editor.; Cornelia Schaefer-Prokop editor.; David J Allison; Elsevier (Firm) 2015, *Online access University of Saskatchewan Library*. http://usl-primo.hosted.exlibrisgroup.com/primo_library/libweb/action/search.do?vid=USASK Accessed June 30, 2017.

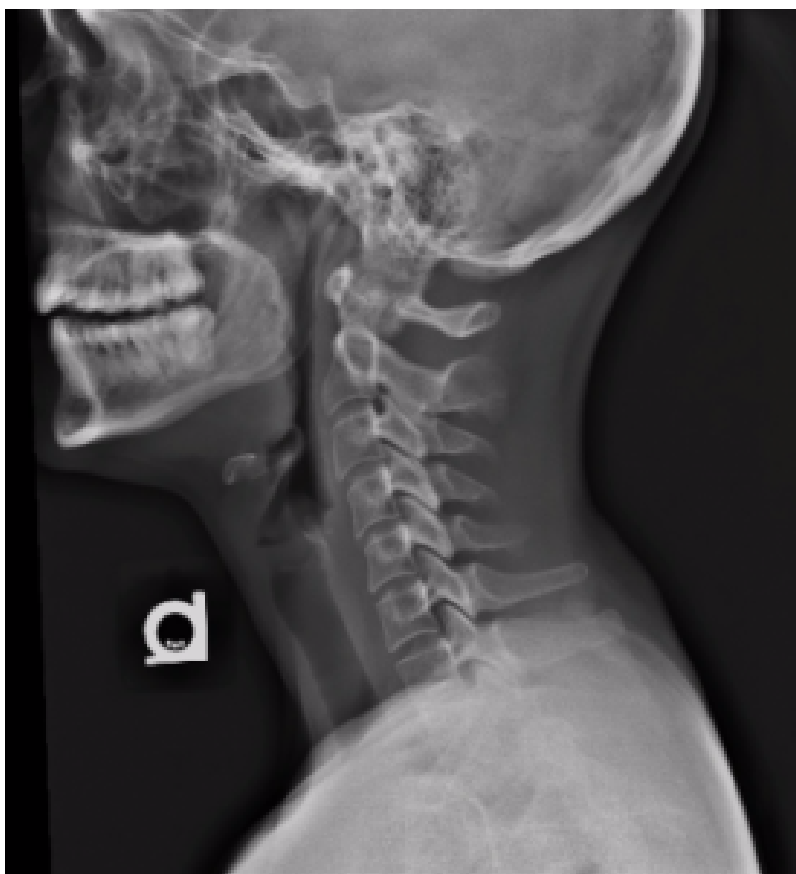Chapter 17 – Normal, Reference Images, Unlabelled and Labelled

Head and Neck

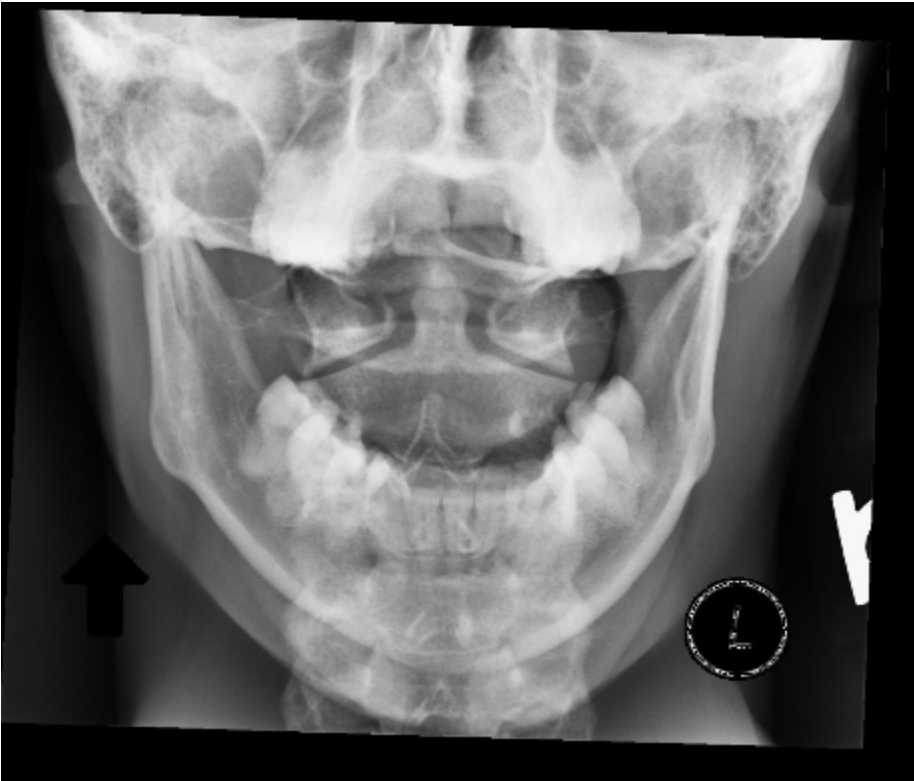
The following are normal x-rays of the cervical spine (*C-spine*):

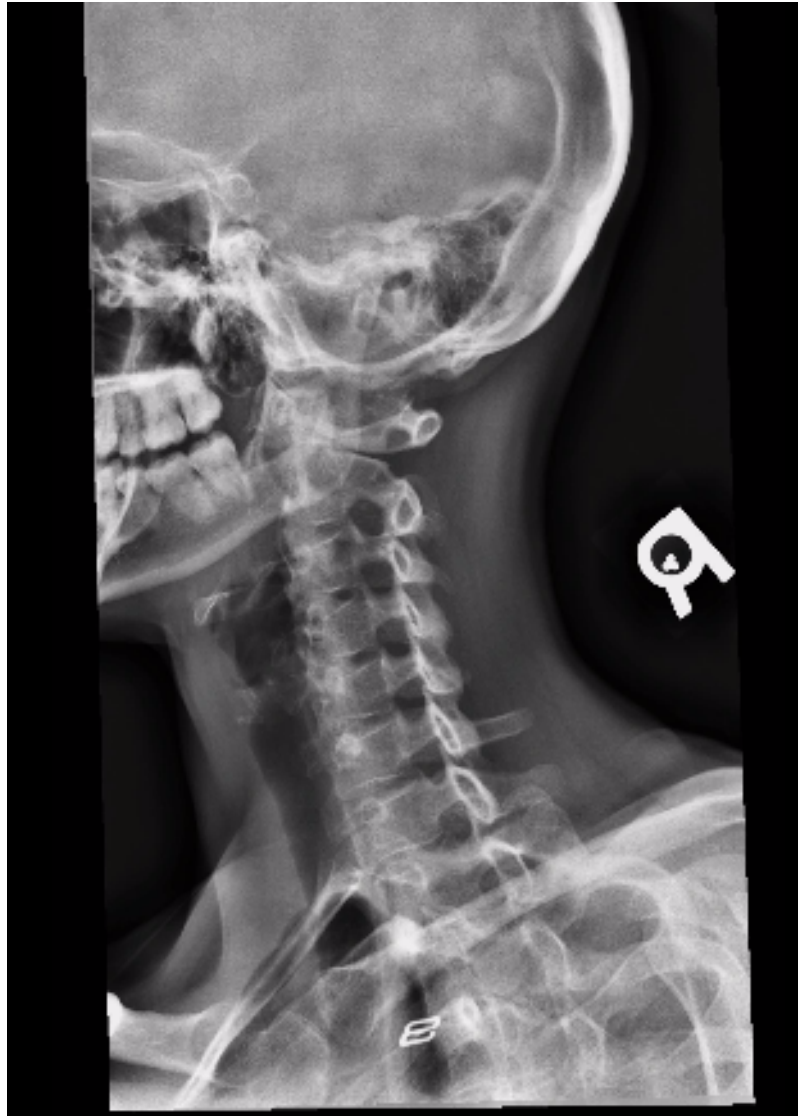

Posterior-Anterior



Lateral

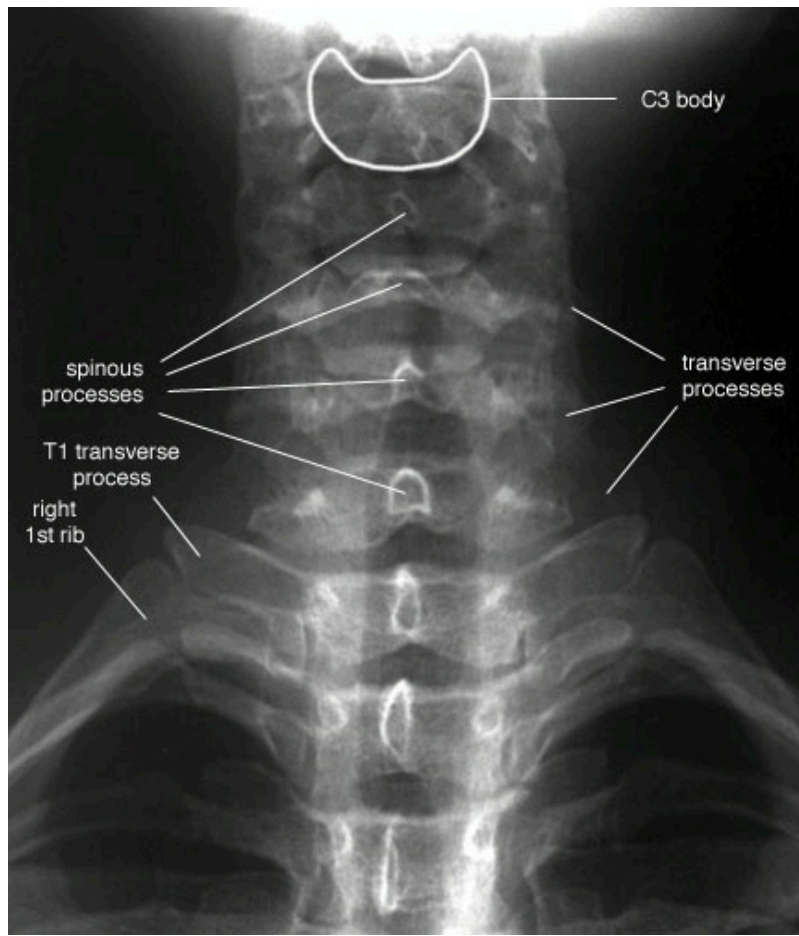




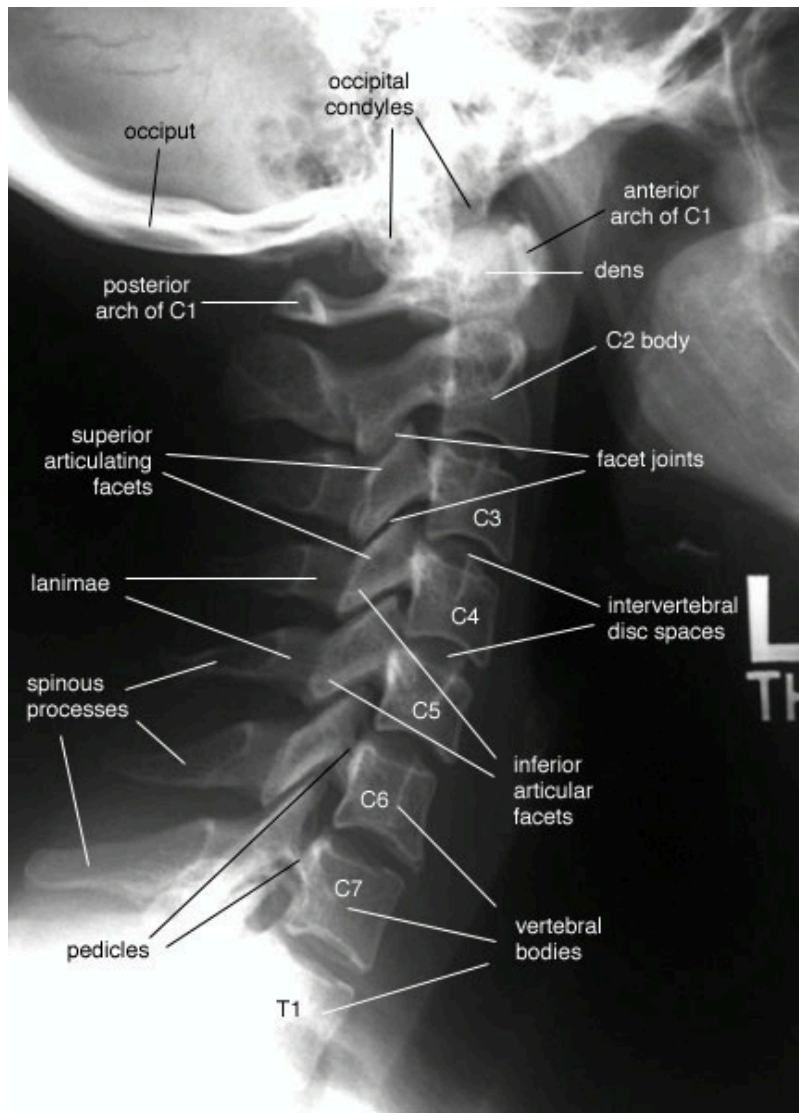
Oblique view

ODIN Link to C-Spine X-Rays – <https://mistr.usask.ca/odin/?caseID=20160503232057810>

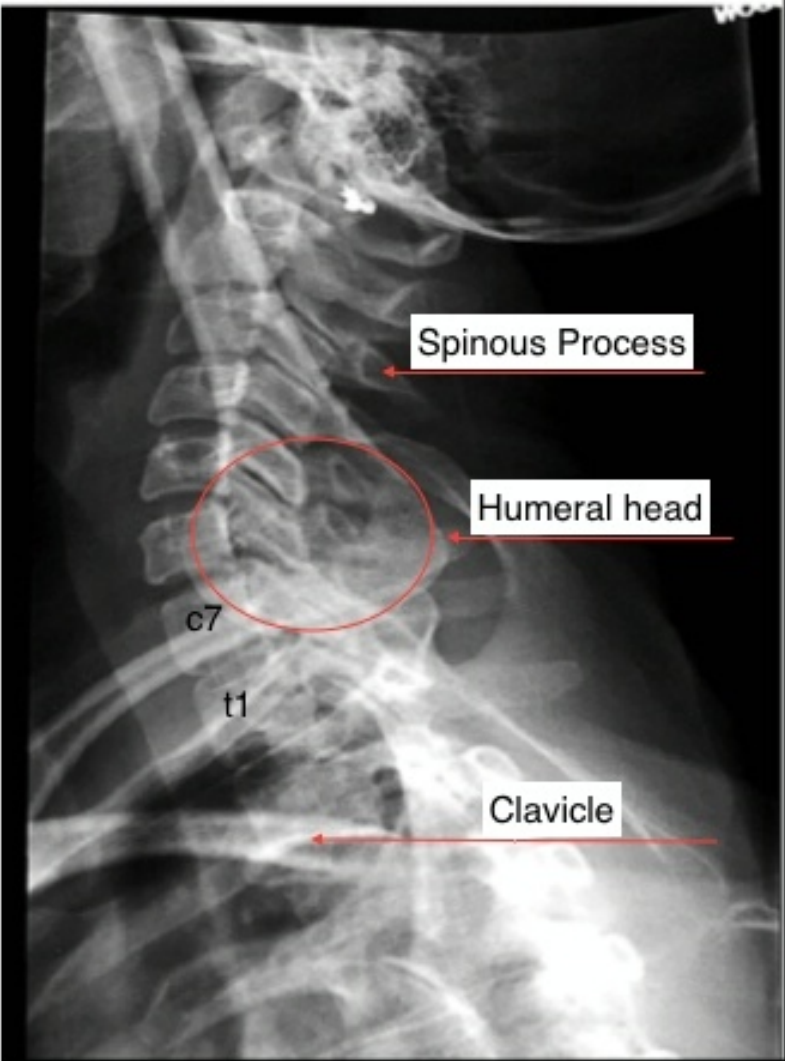Normal Adult C-Spine, Labelled



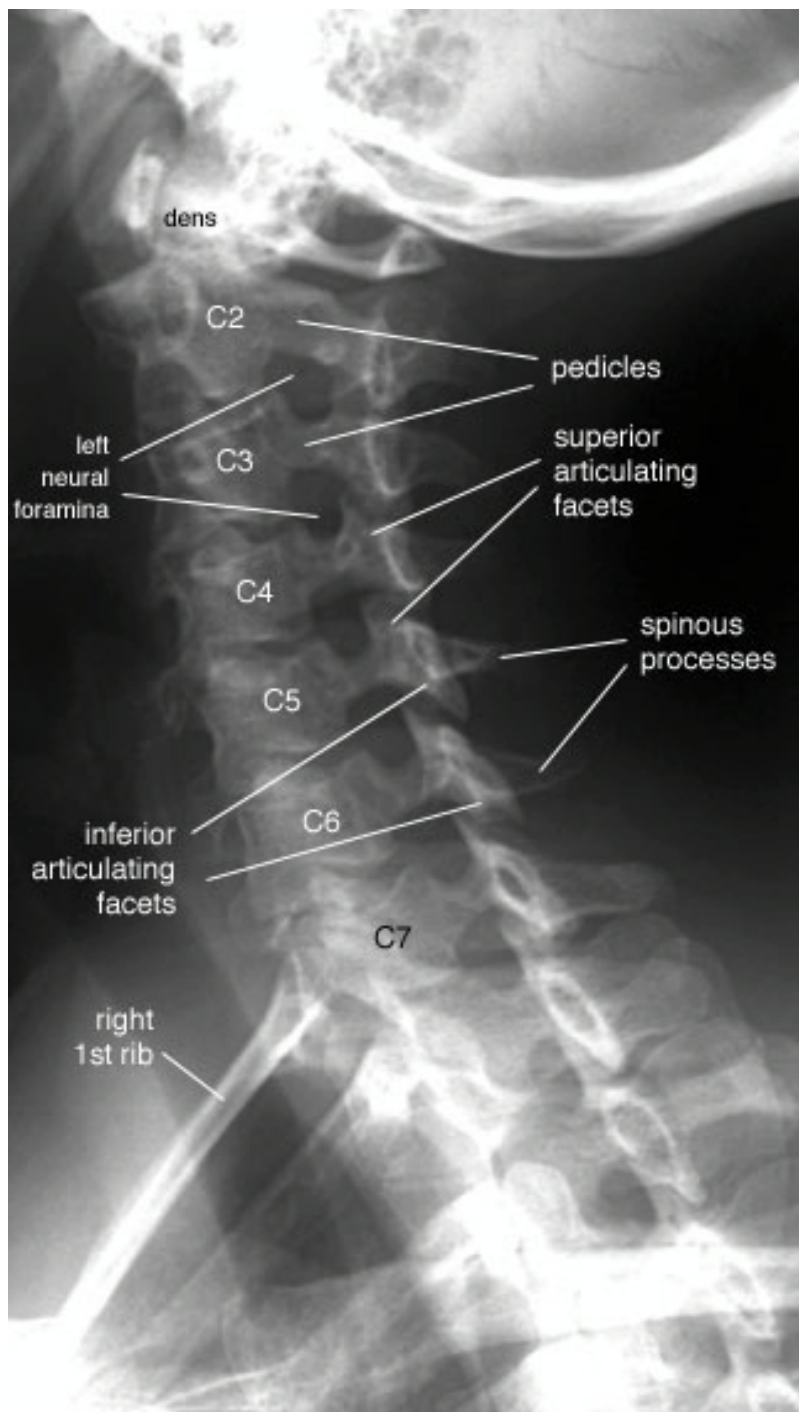
AP Adult C-spine, Labelled



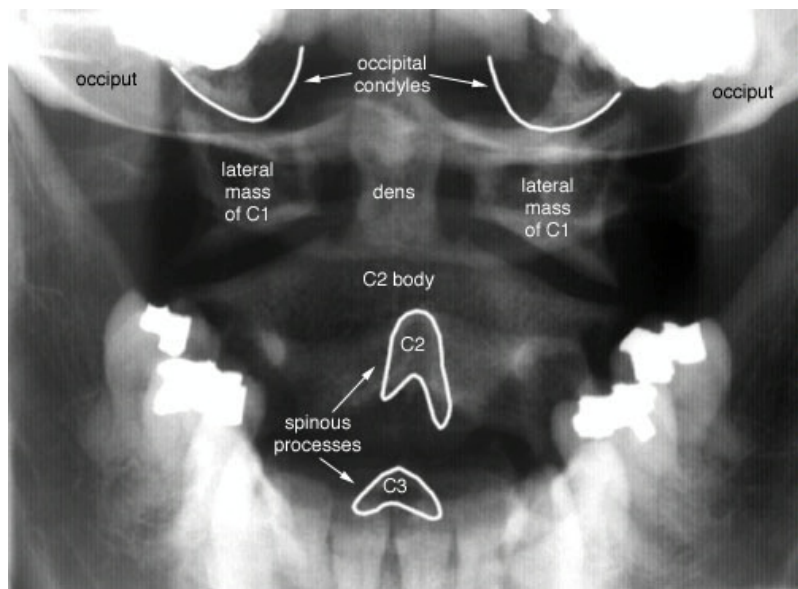
Lateral Adult C-spine, Labelled



Swimmer's View Adult C-spine, Labelled



Oblique View Adult C-spine, Labelled



Open Mouth, Odontoid, Adult C-spine, Labelled

ODIN Link to Normal, Adult Cspine Images, Labelled: <https://mistr.usask.ca/odin/?caseID=20170406001750724>

The following are normal images of the Pediatric C-Spine, unlabelled and labelled:

Modality:

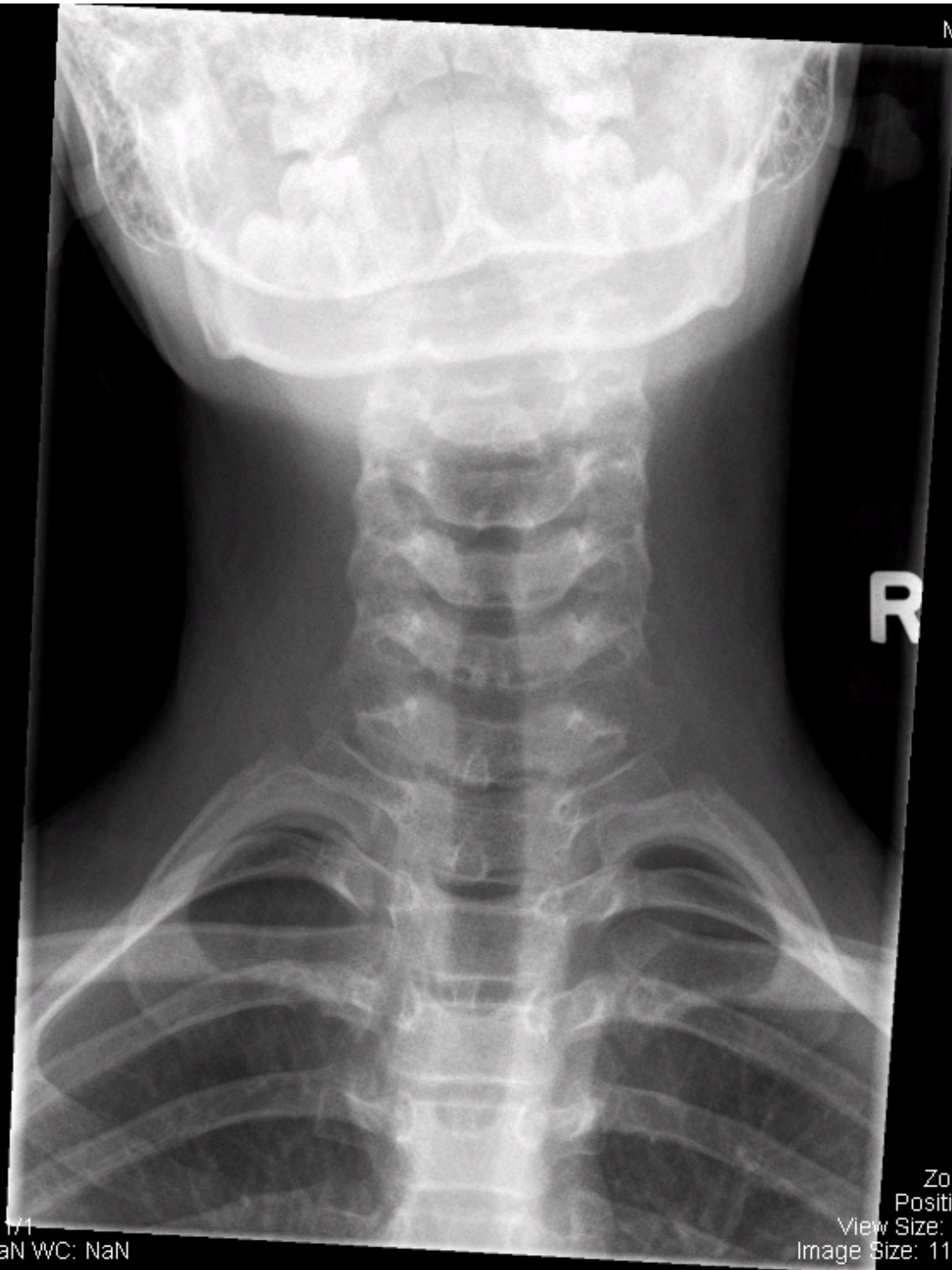


Image: 1/1
WW: NaN WC: NaN

Zoom: 49%
Position: (0,0)
View Size: 675x742
Image Size: 1145x1526

Modality:

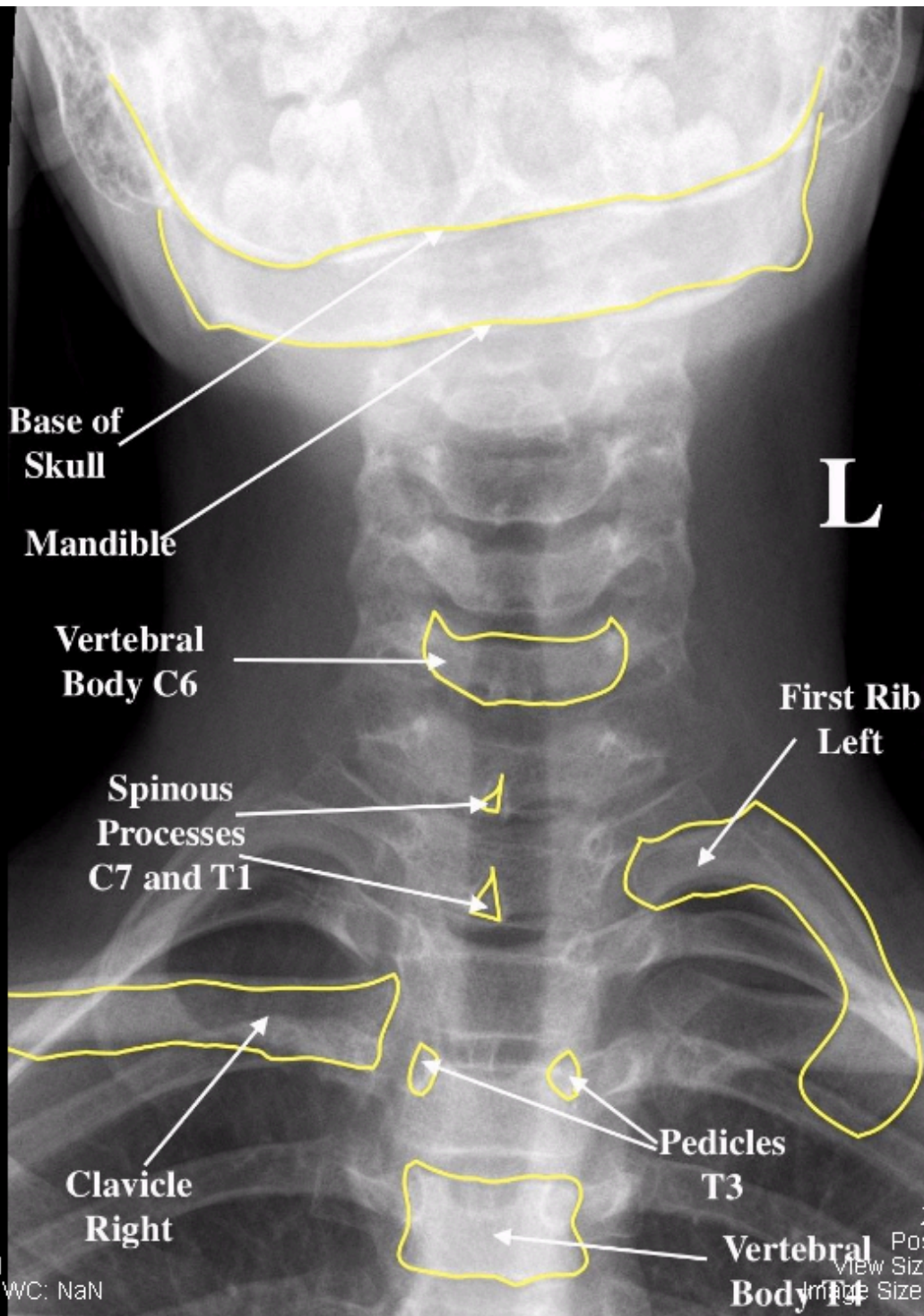


Image: 1/1
WWW: NaN WC: NaN

Zoom: 54%
Position: (0,0)
View Size: 675x742
Image Size: 970x1380

Modality:

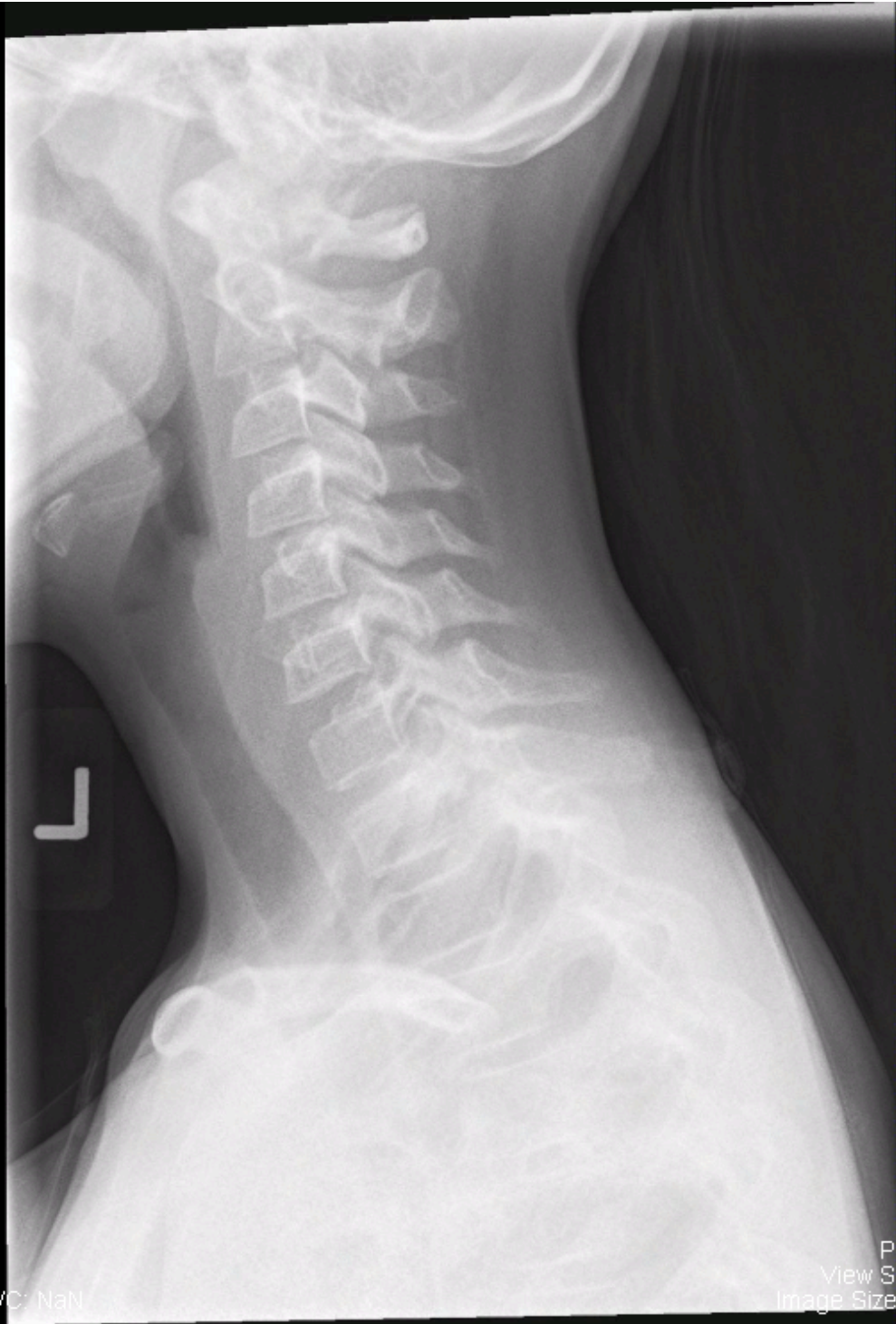

Image: 1/1
WW: NaN WC: NaN

Zoom: 49%
Position: (0,0)
View Size: 675x742
Image Size: 1032x1526

Modality:

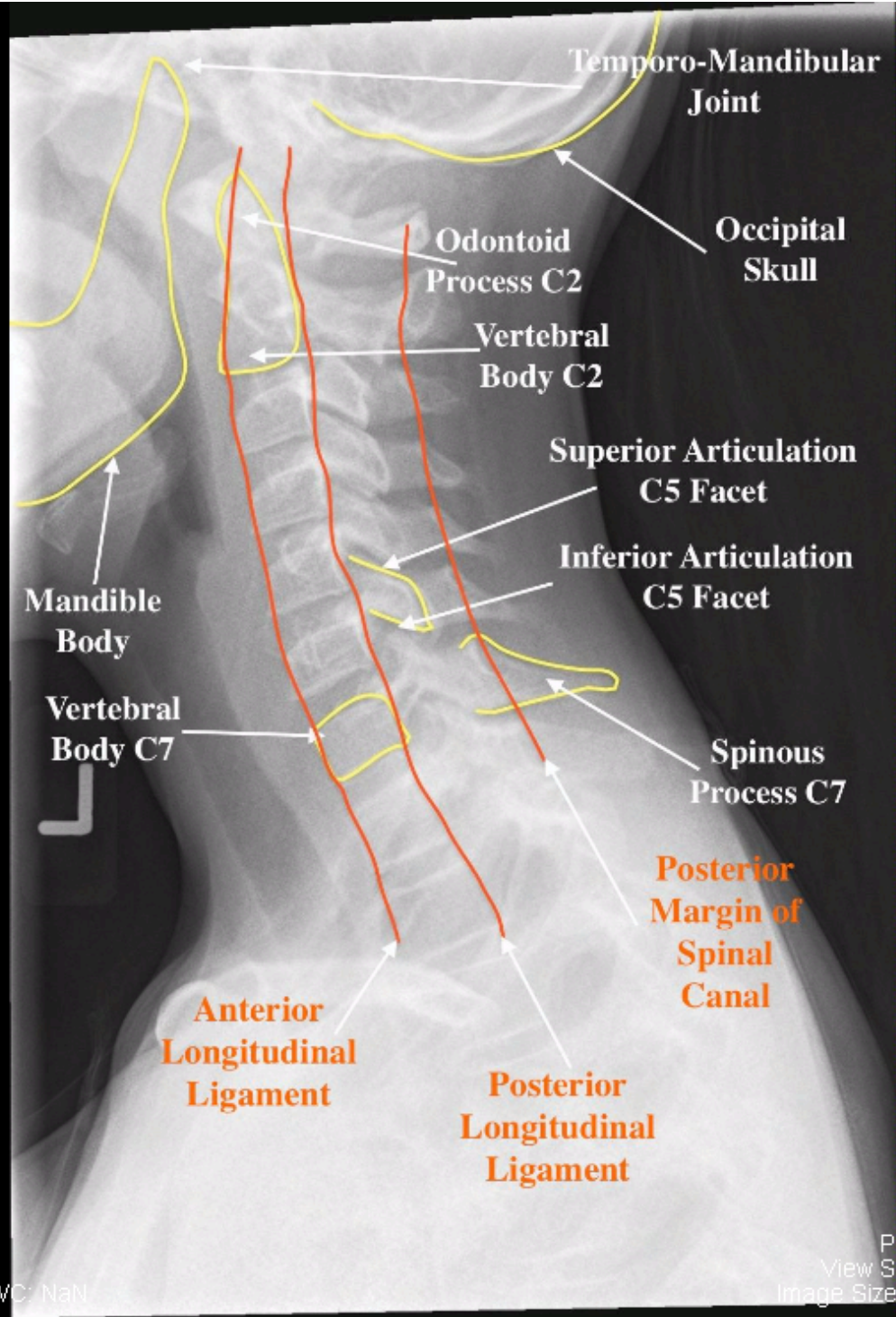
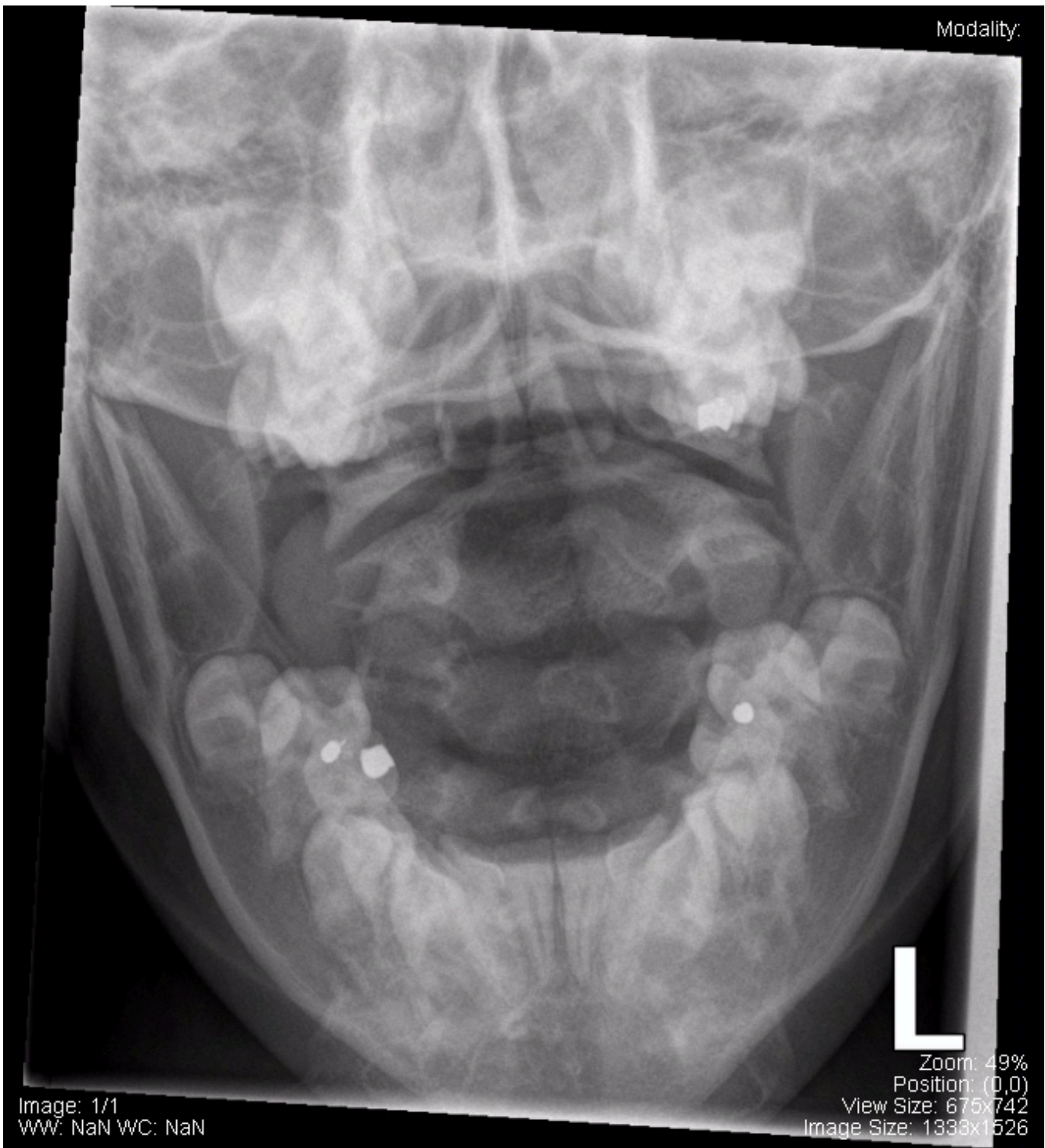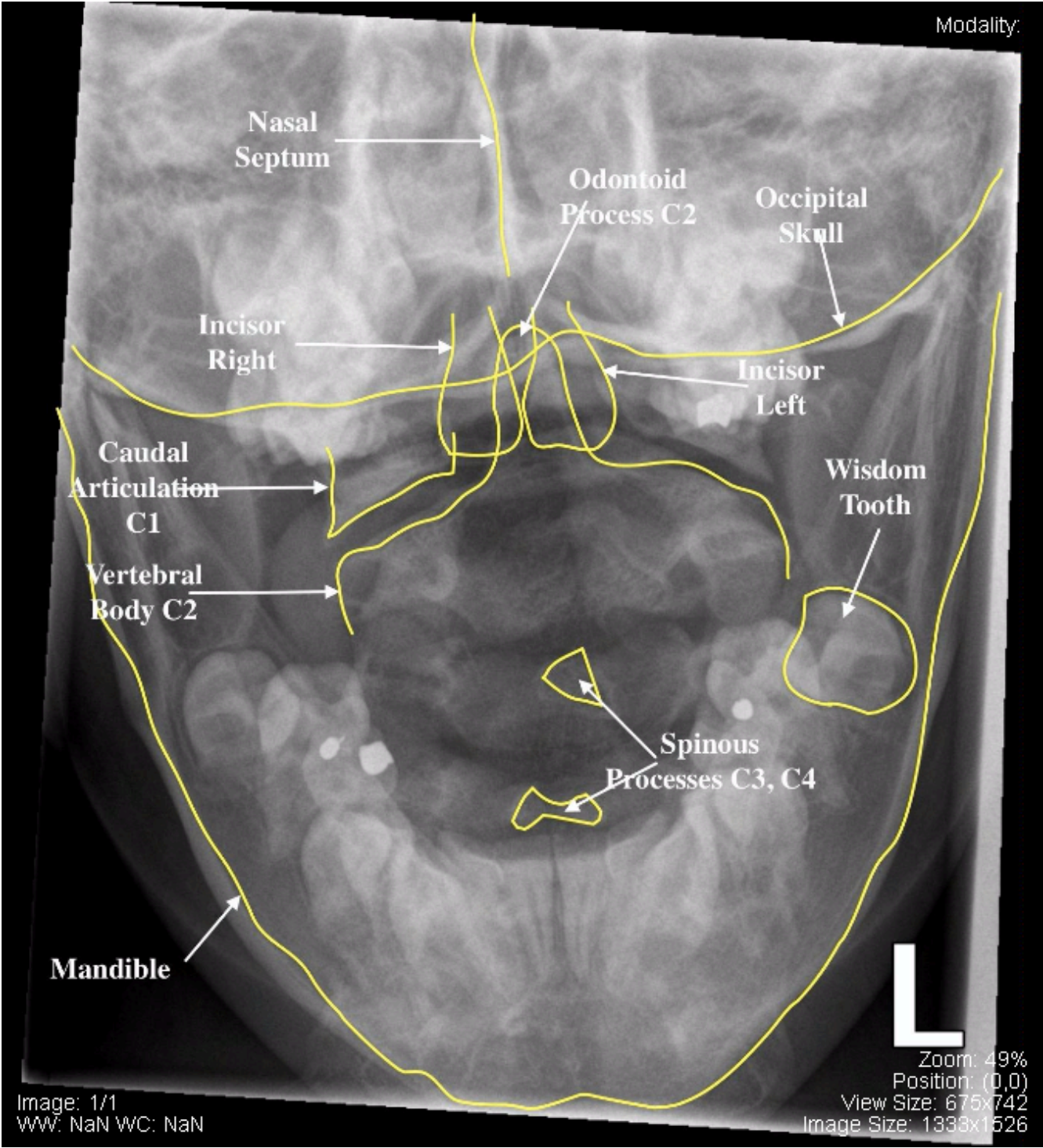


Image: 1/1
WWW: NaN WC: NaN

Zoom: 49%
Position: (0,0)
View Size: 675x742
Image Size: 1032x1526

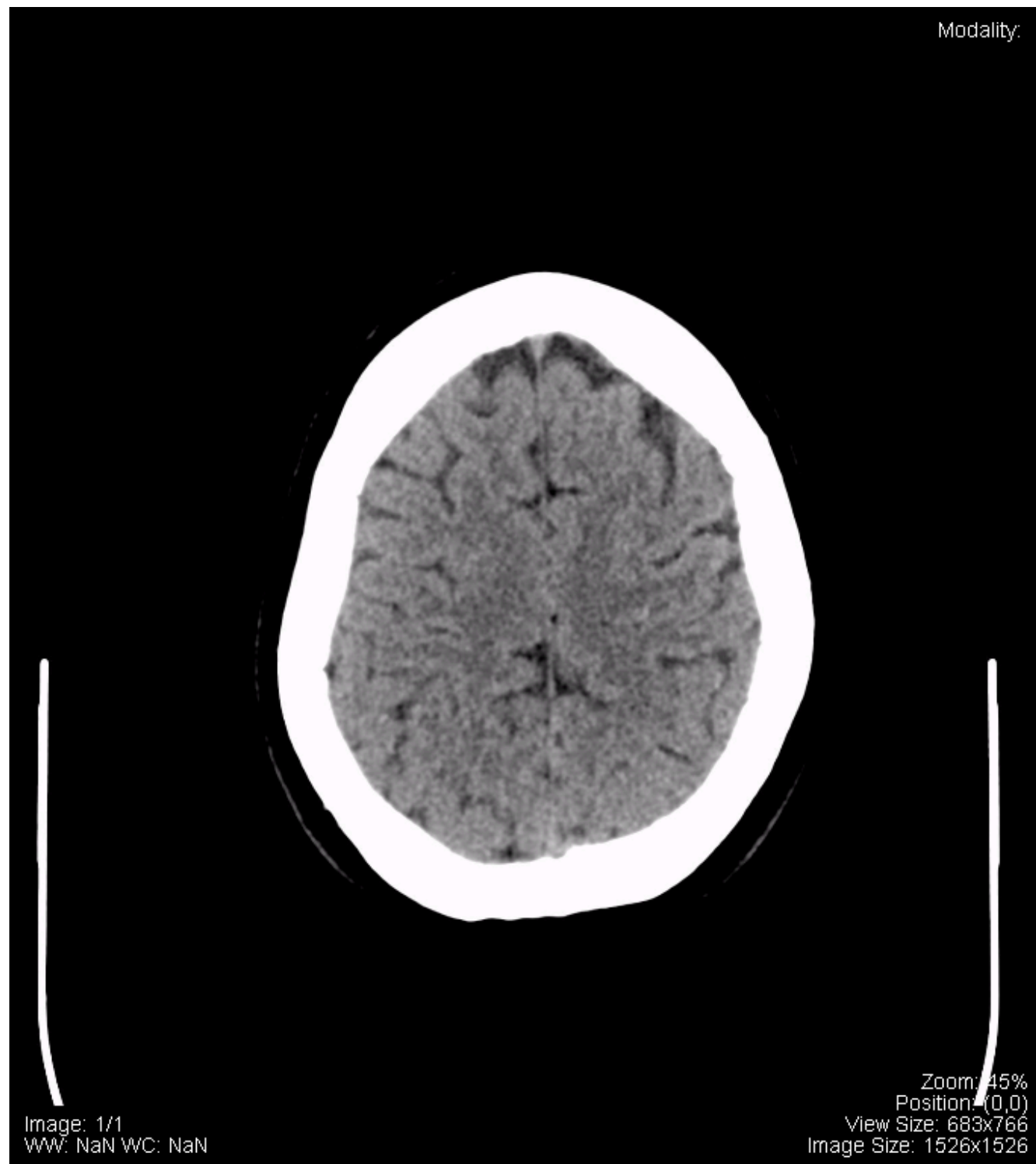Modality:





ODIN Link to Pediatric C-Spine – <https://mistr.usask.ca/odin/?caseID=20170825145159975>

The following are normal CT images of the brain:



Modality:

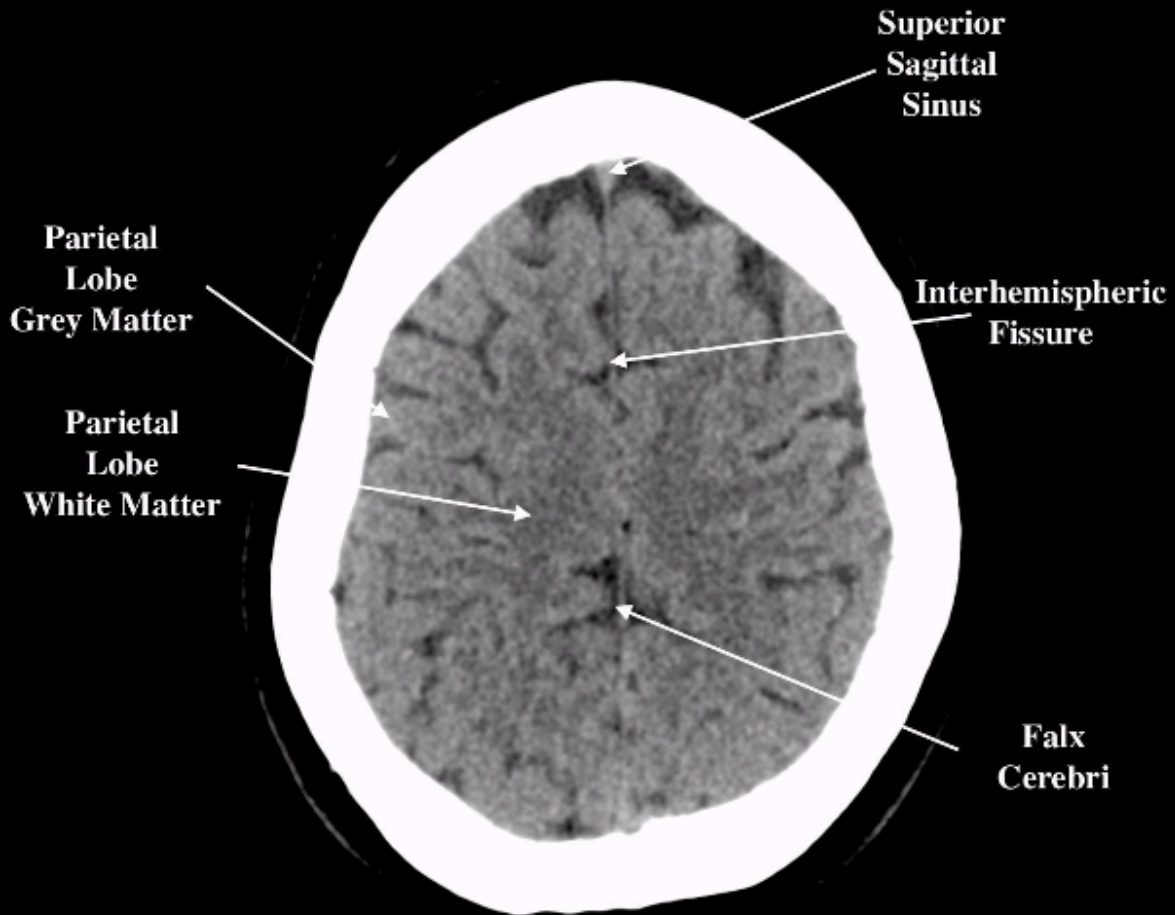


Image: 1/1
WW: NaN WC: NaN

Zoom: 45%
Position: (0,0)
View Size: 683x766
Image Size: 1526x1526

Modality:

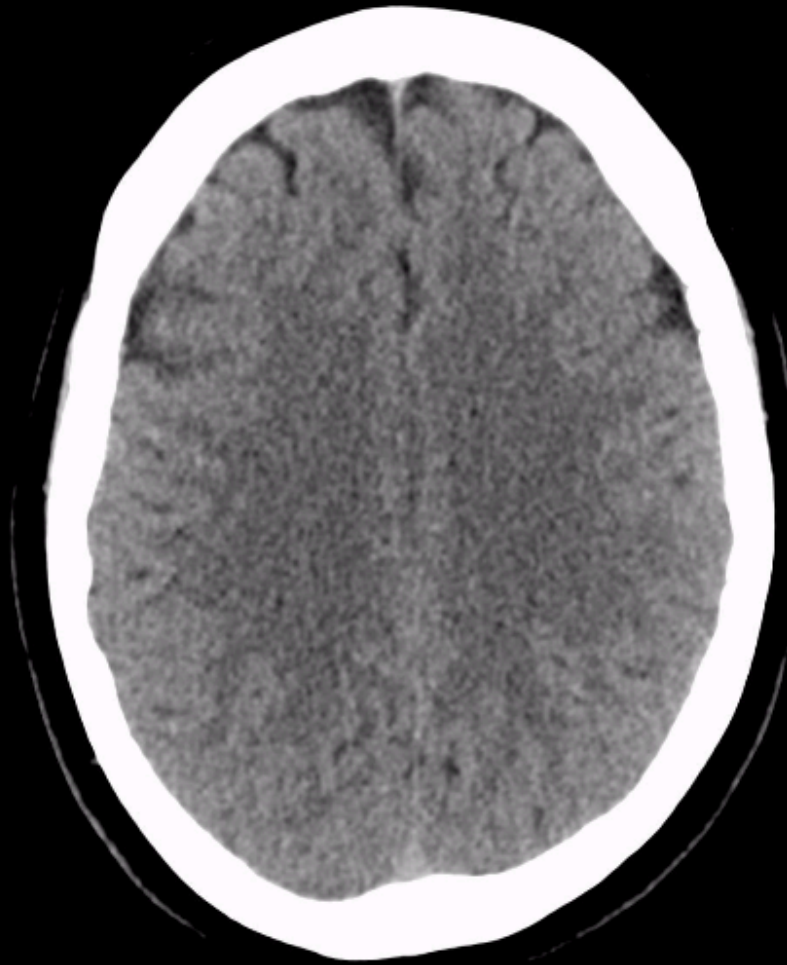

Image: 1/1
WW: NaN WC: NaN

Zoom: 45%
Position: (0,0)
View Size: 683x766
Image Size: 1526x1526

Modality:

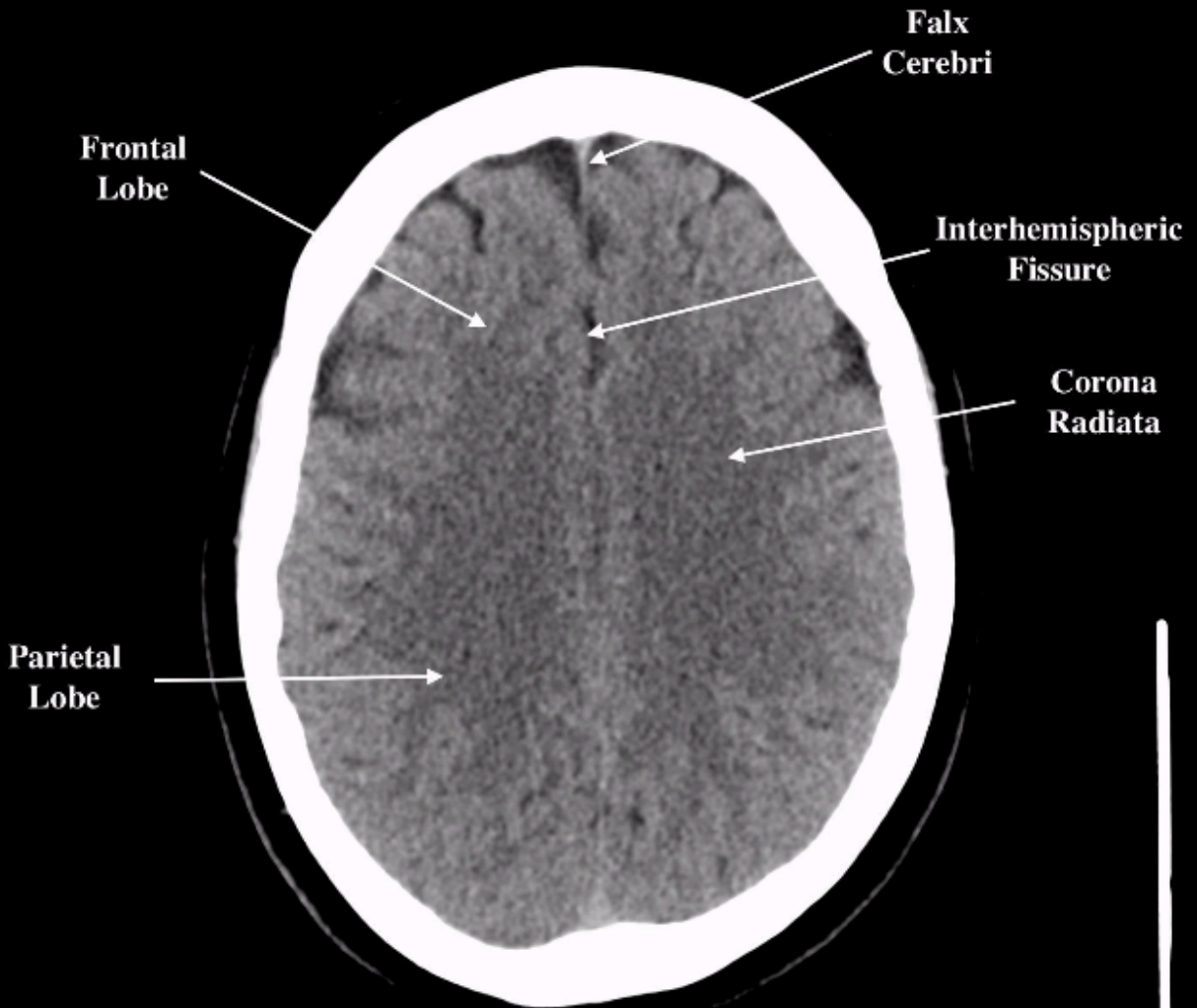


Image: 1/1
WW: NaN WC: NaN

Zoom: 45%
Position: (0,0)
View Size: 683x766
Image Size: 1526x1526

Modality:

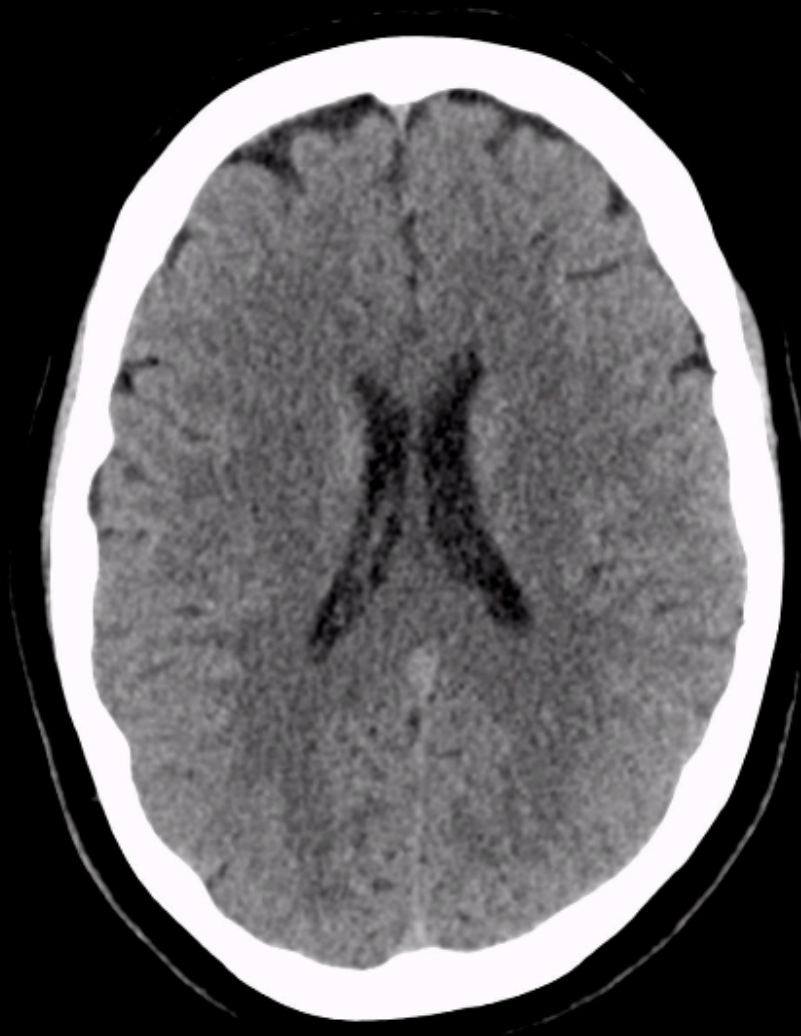


Image: 1/1
WW: NaN WC: NaN

Zoom: 45%
Position: (0,0)
View Size: 683x766
Image Size: 1526x1526

Modality:

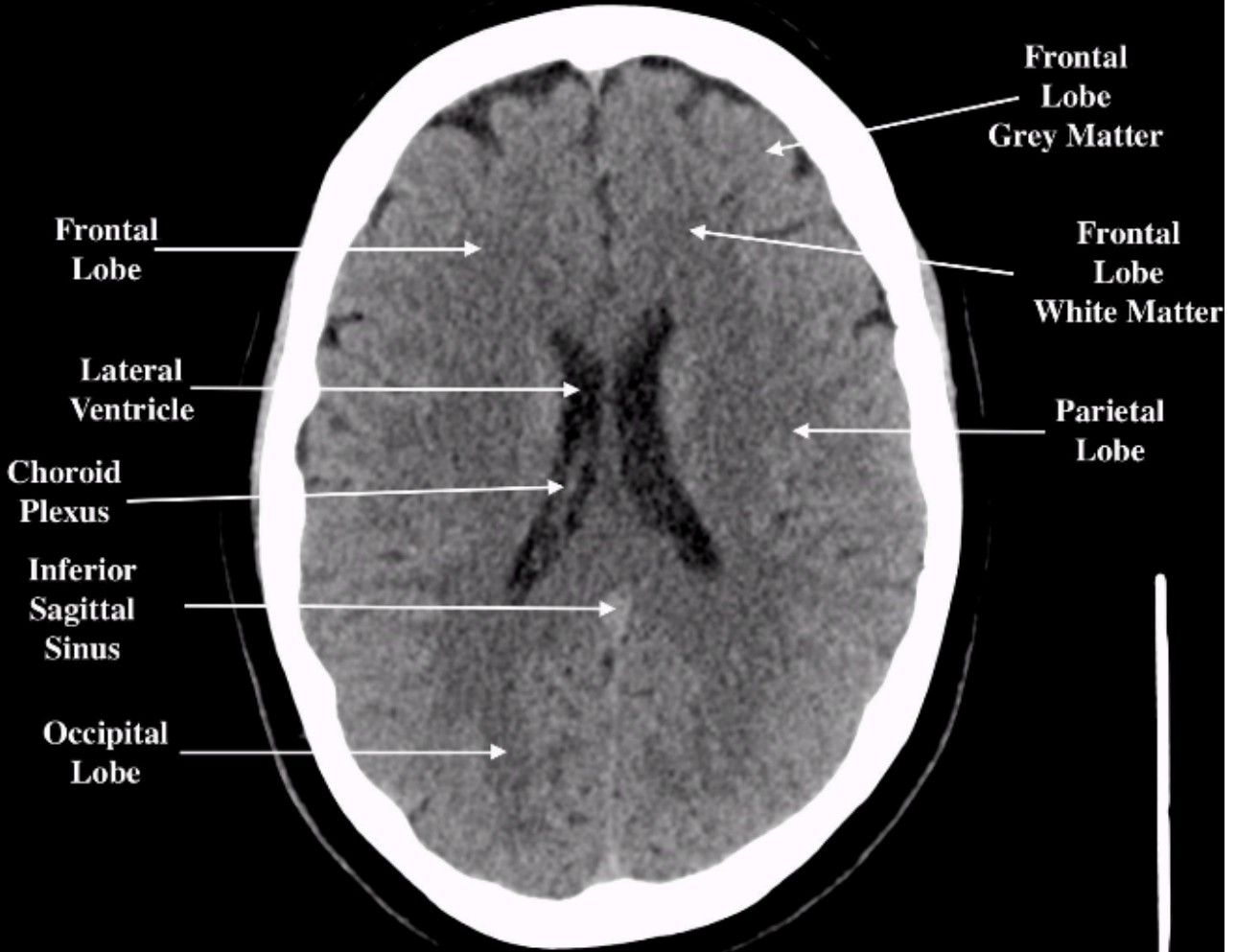


Image: 1/1
WW: NaN WC: NaN

Zoom: 45%
Position: (0,0)
View Size: 683x766
Image Size: 1526x1526

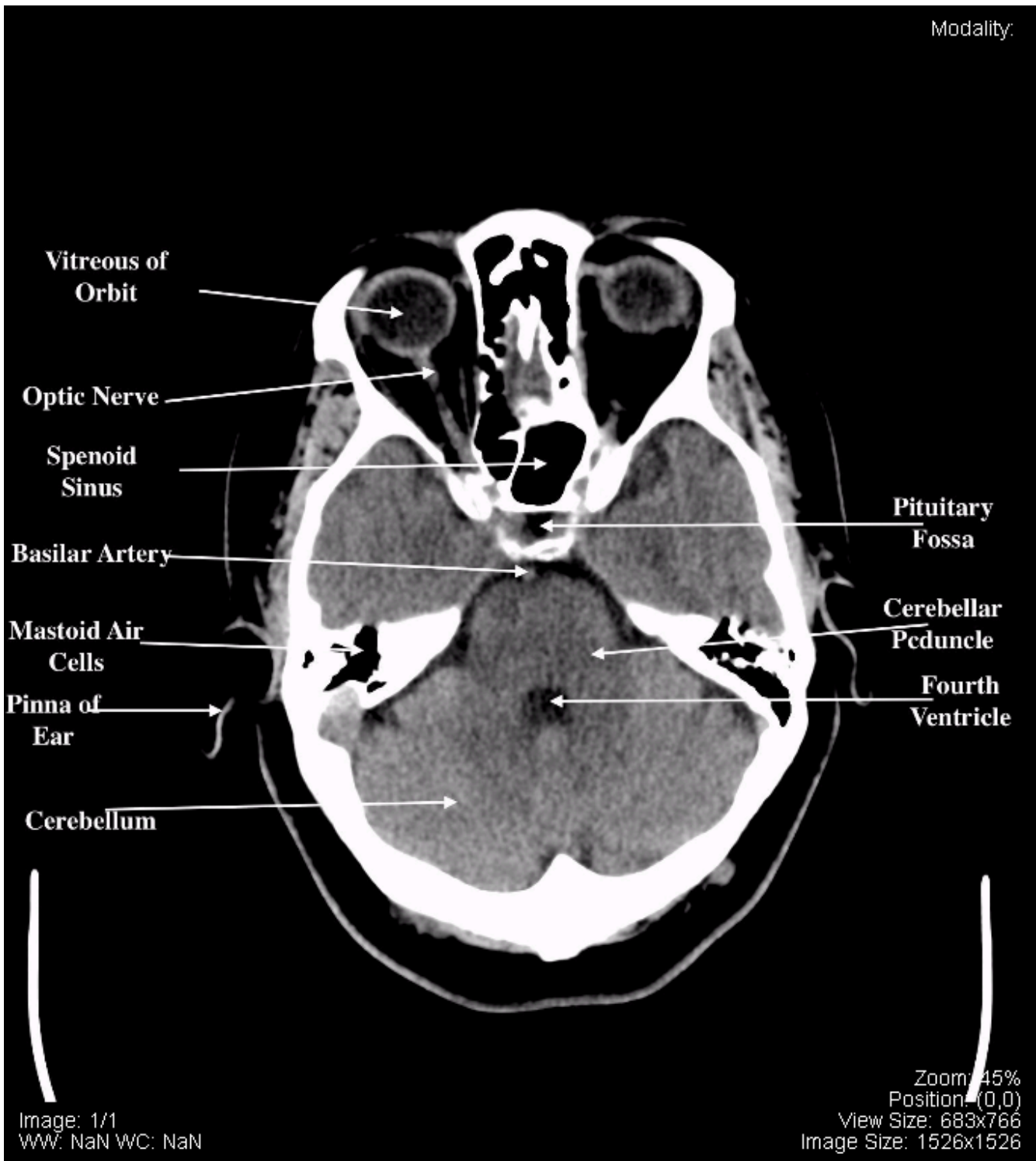
Modality:

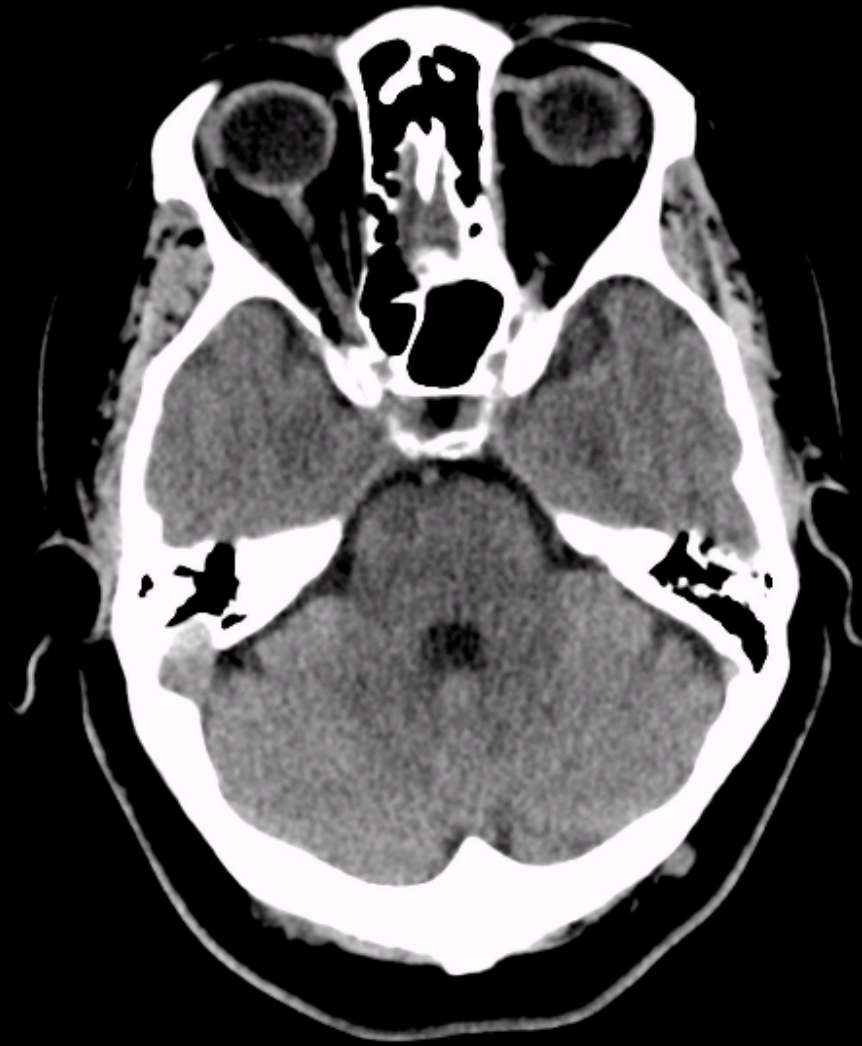

Image: 1/1
WW: NaN WC: NaN

Zoom: 45%
Position: (0,0)
View Size: 683x766
Image Size: 1526x1526

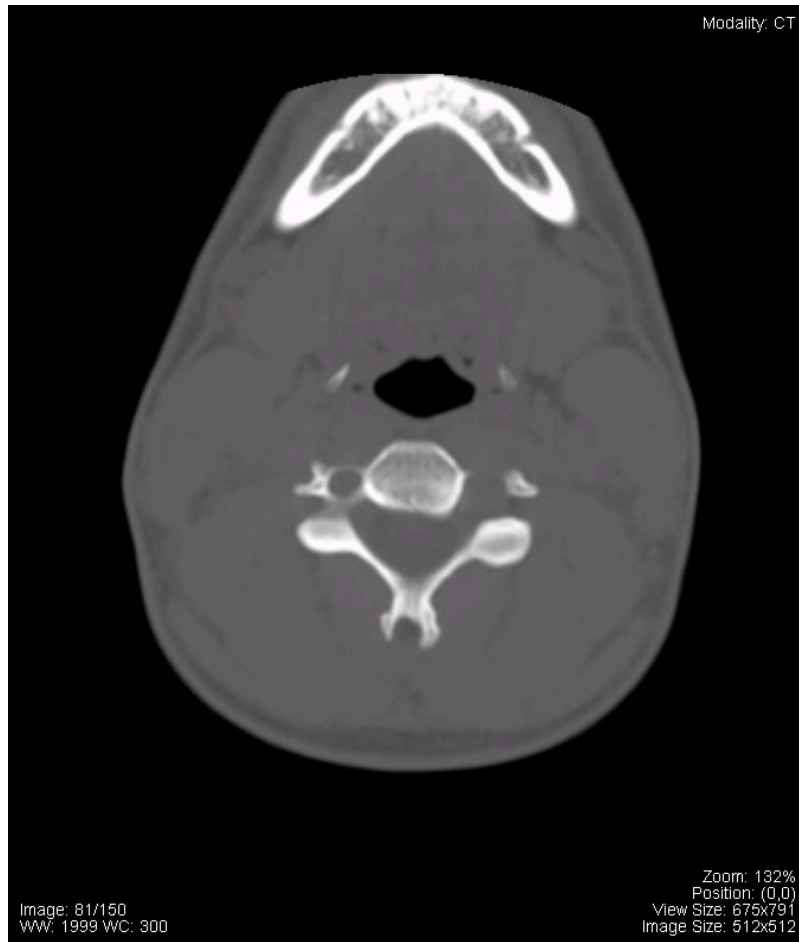
Modality:



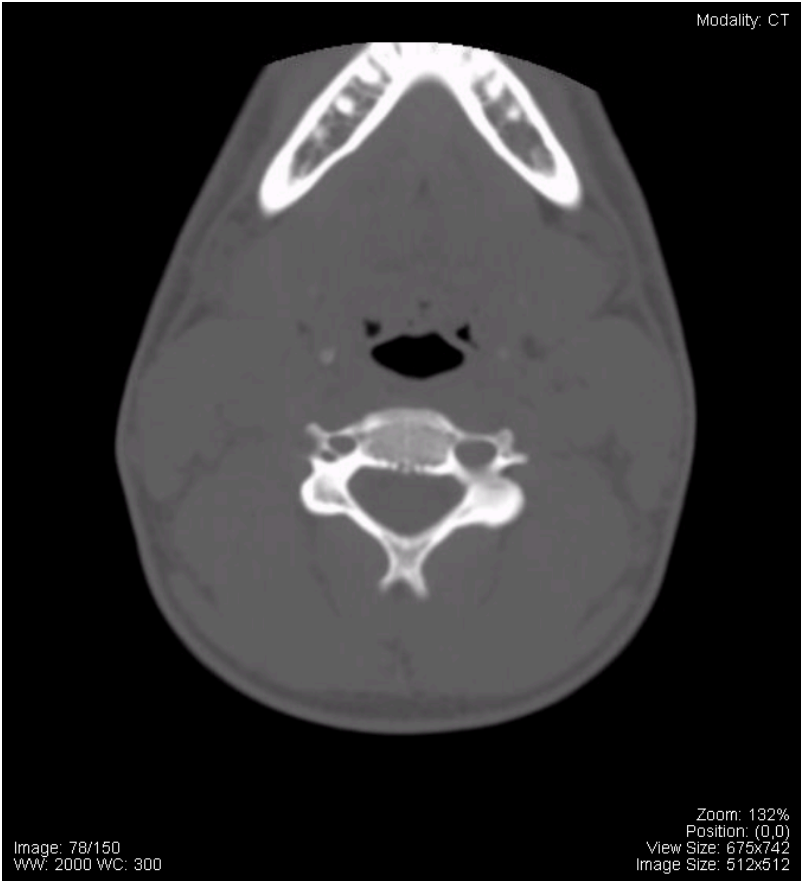
The ODIN link provides the full set of images and they can be viewed with different level/window settings. The brain level and window was utilized for the labelled brain CT images (including labelled and unlabelled). The images above are sample thumbnails.

ODIN Link to Brain CT – <https://mistr.usask.ca/odin/?caseID=20170825124325726>

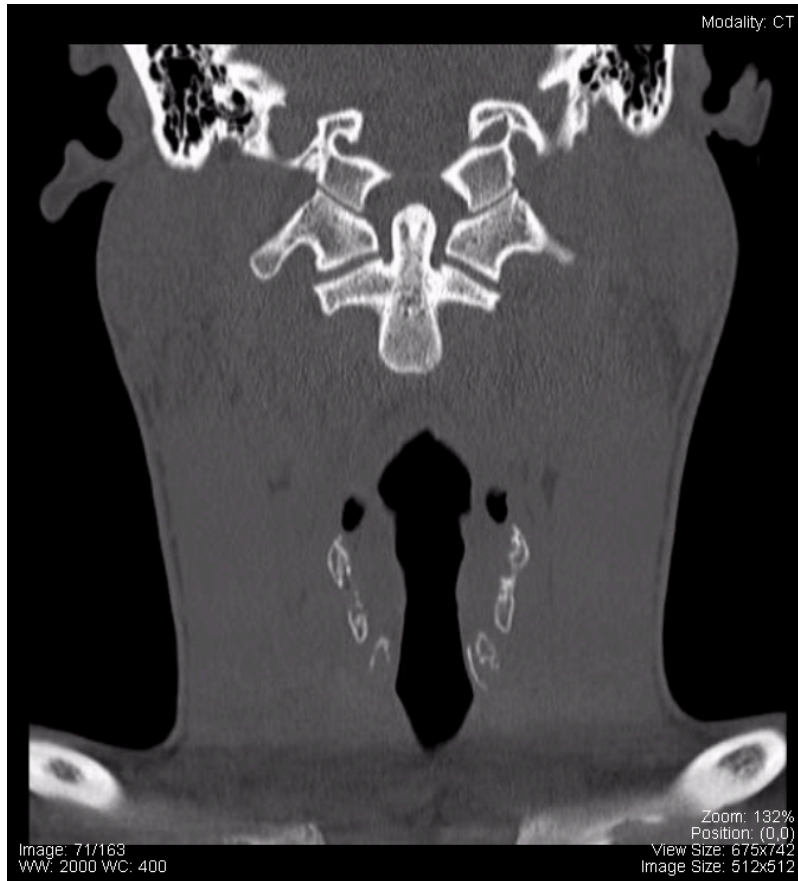The following are normal CT images of the C-Spine (axial, coronal, and sagittal):



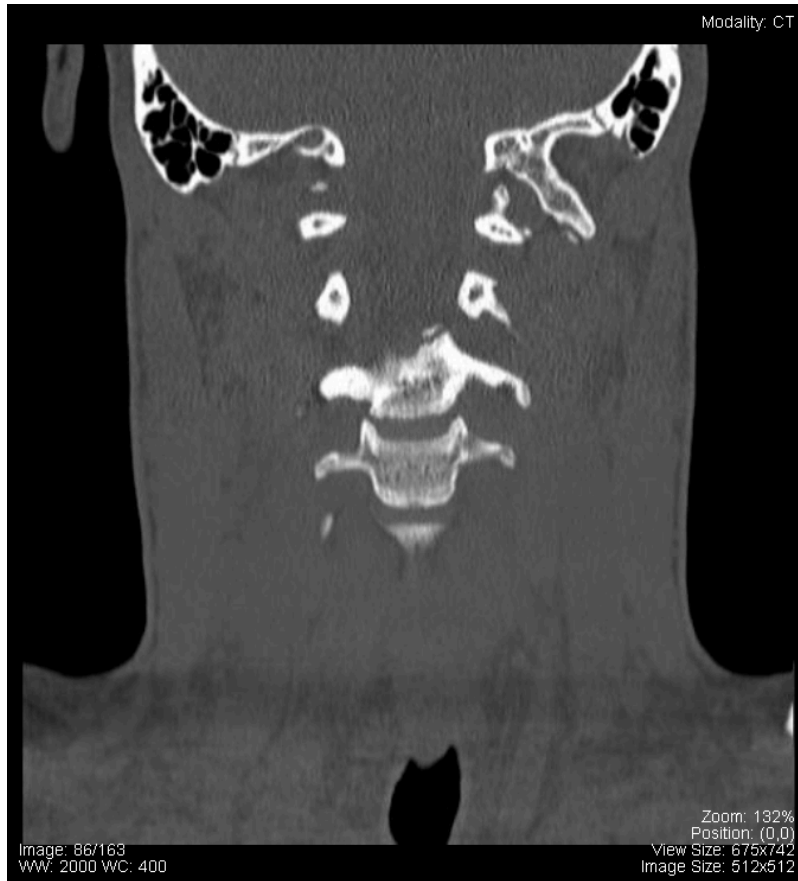
Axial CT 1



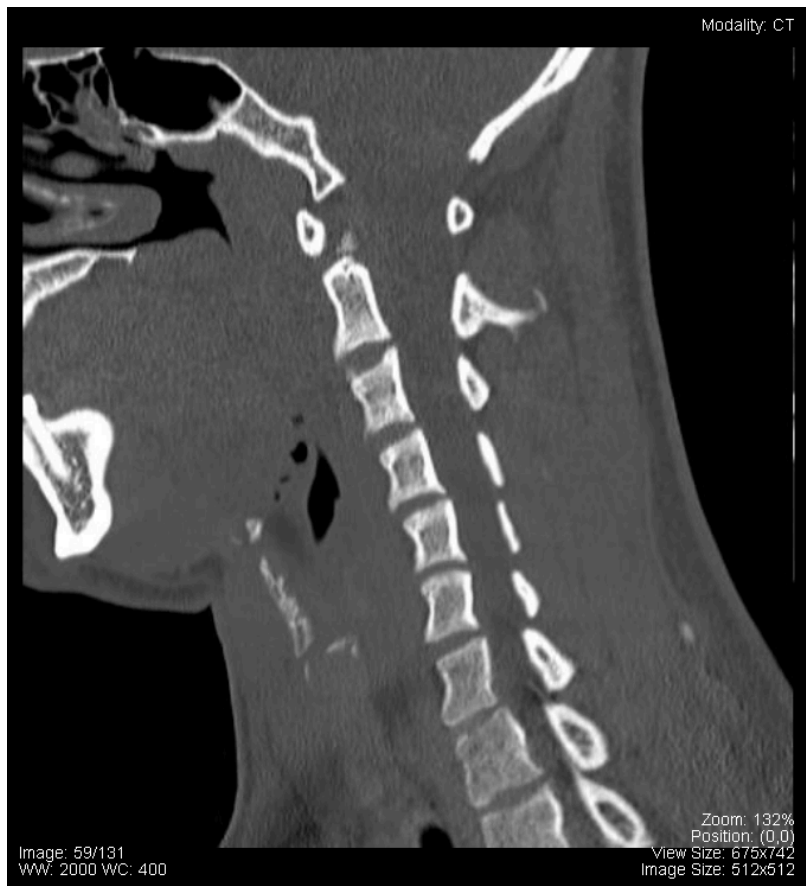Axial CT 2



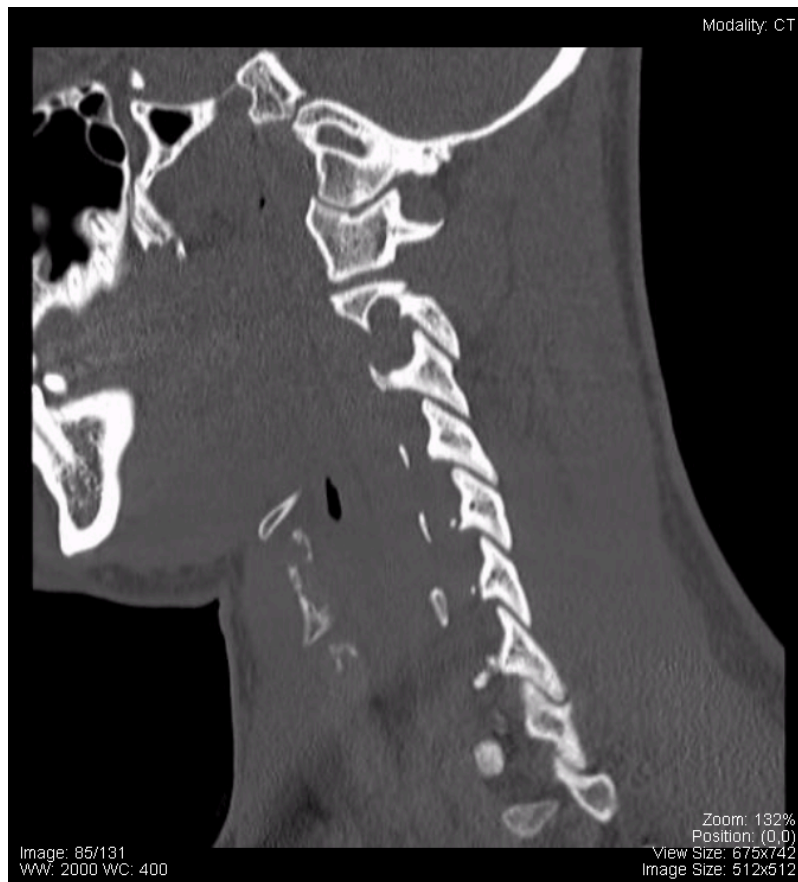
Coronal CT 1



Coronal CT 2



Sagittal CT 1

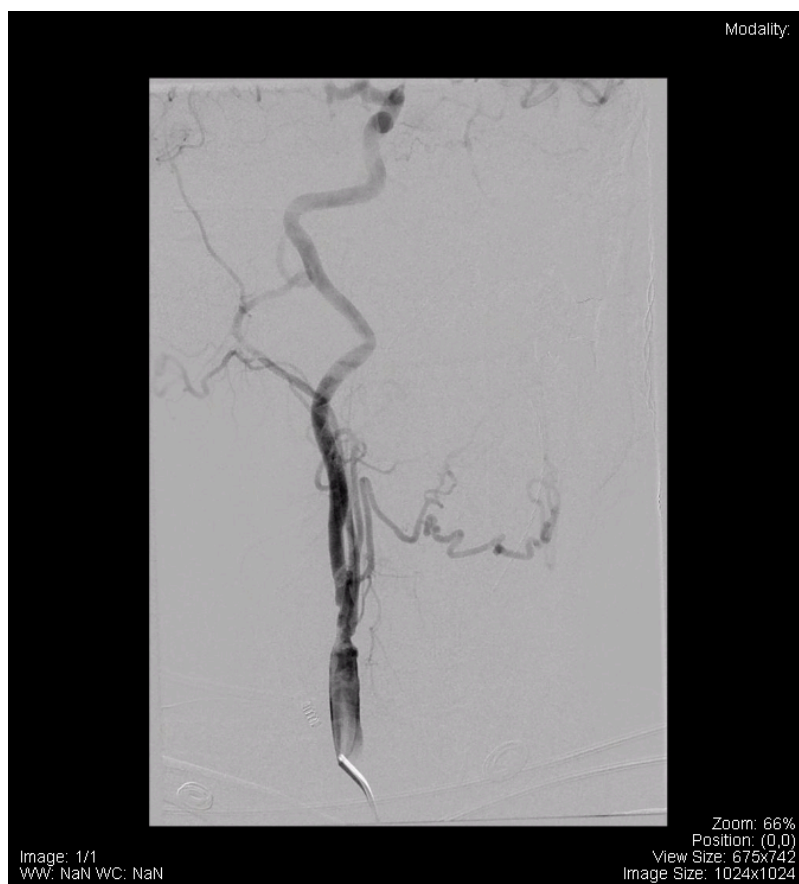


Sagittal CT 2

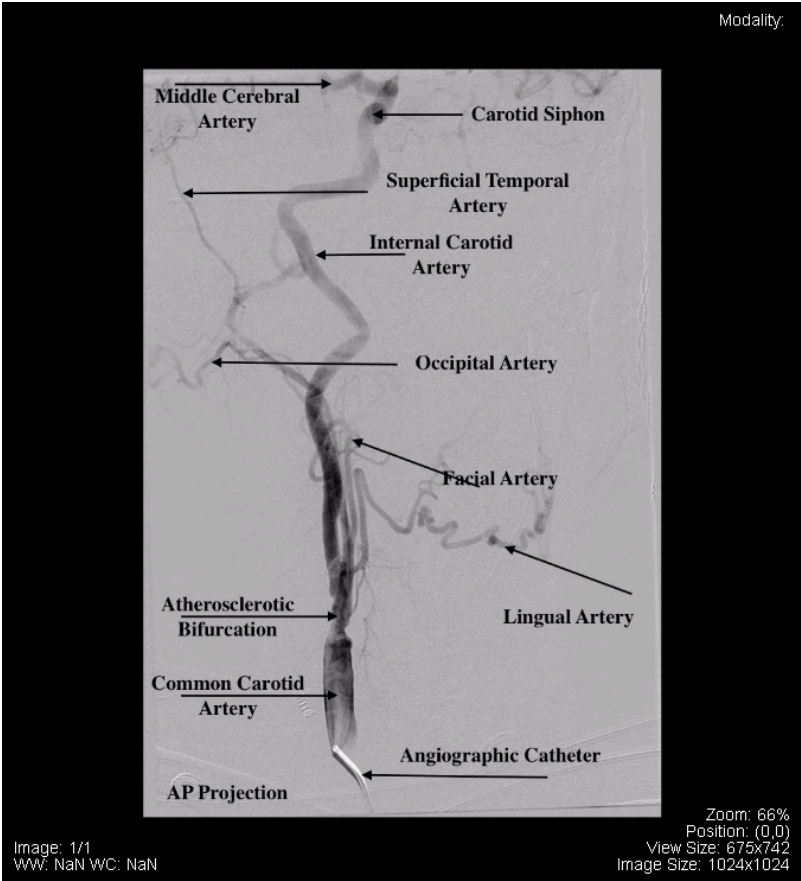
The ODIN link provides the full set of images and they can be viewed with different level/window settings. The brain level and window was utilized for the labelled brain CT images (including labelled and unlabelled). The images above are sample thumbnails.

ODIN Link to C-Spine CT – <https://mistr.usask.ca/odin/?caseID=20170724143602846>

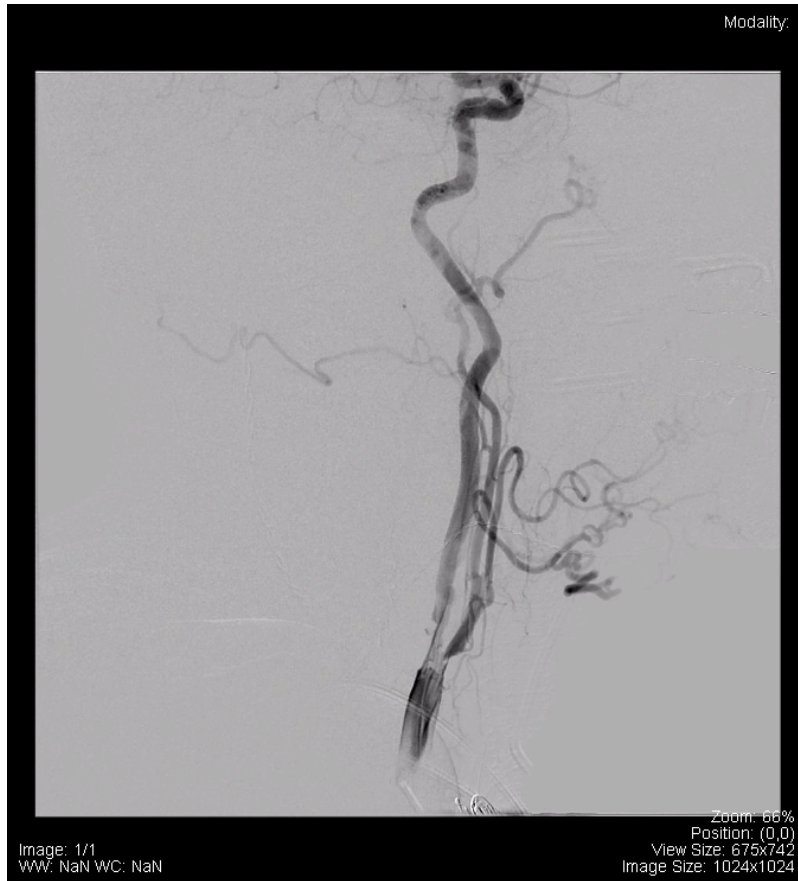The following Digital Subtraction Angiography (DSA) is not normal because of the Stenotic Carotid Artery. Otherwise, the following DSA displays the vasculature in the head and neck:



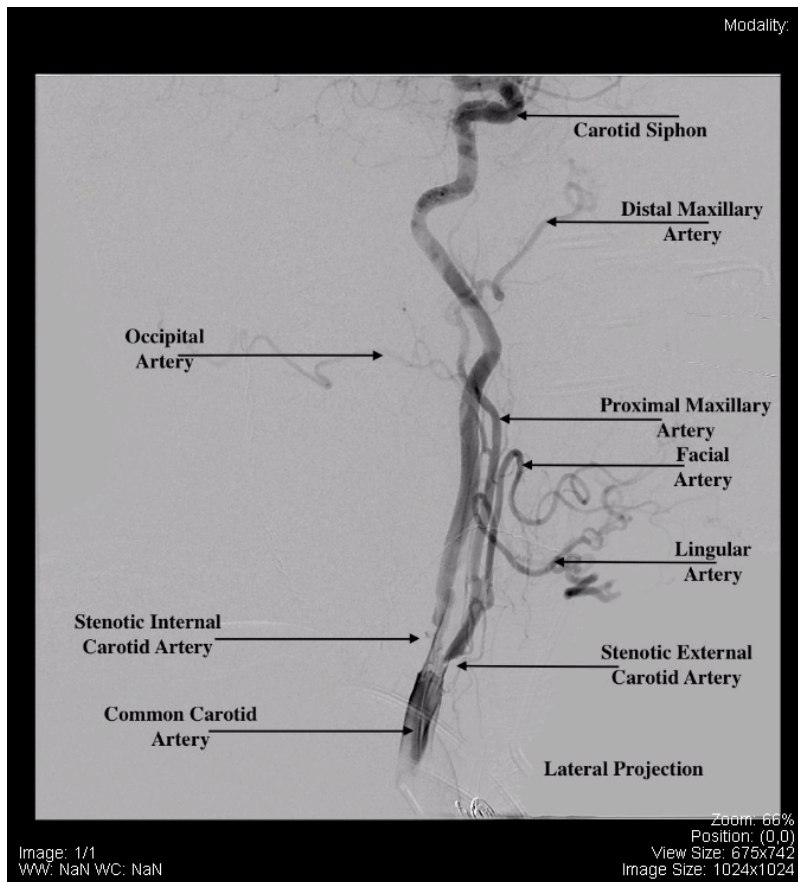
Abnormal CTA 1



Abnormal CTA 2



Abnormal CTA 3



Abnormal CTA 4

ODIN Link to Images – <https://mistr.usask.ca/odin/?caseID=20170825125327526>

Attributions

All figures in “**Chapter 17: Head and Neck**” by Dr. Brent Burbridge MD, FRCPC, University Medical Imaging Consultants, College of Medicine, University of Saskatchewan is used under a [CC-BY-NC-SA 4.0](https://creativecommons.org/licenses/by-nc-sa/4.0/) license.

Chest

The following are normal PA and Lateral x-ray images of the chest:

Modality:

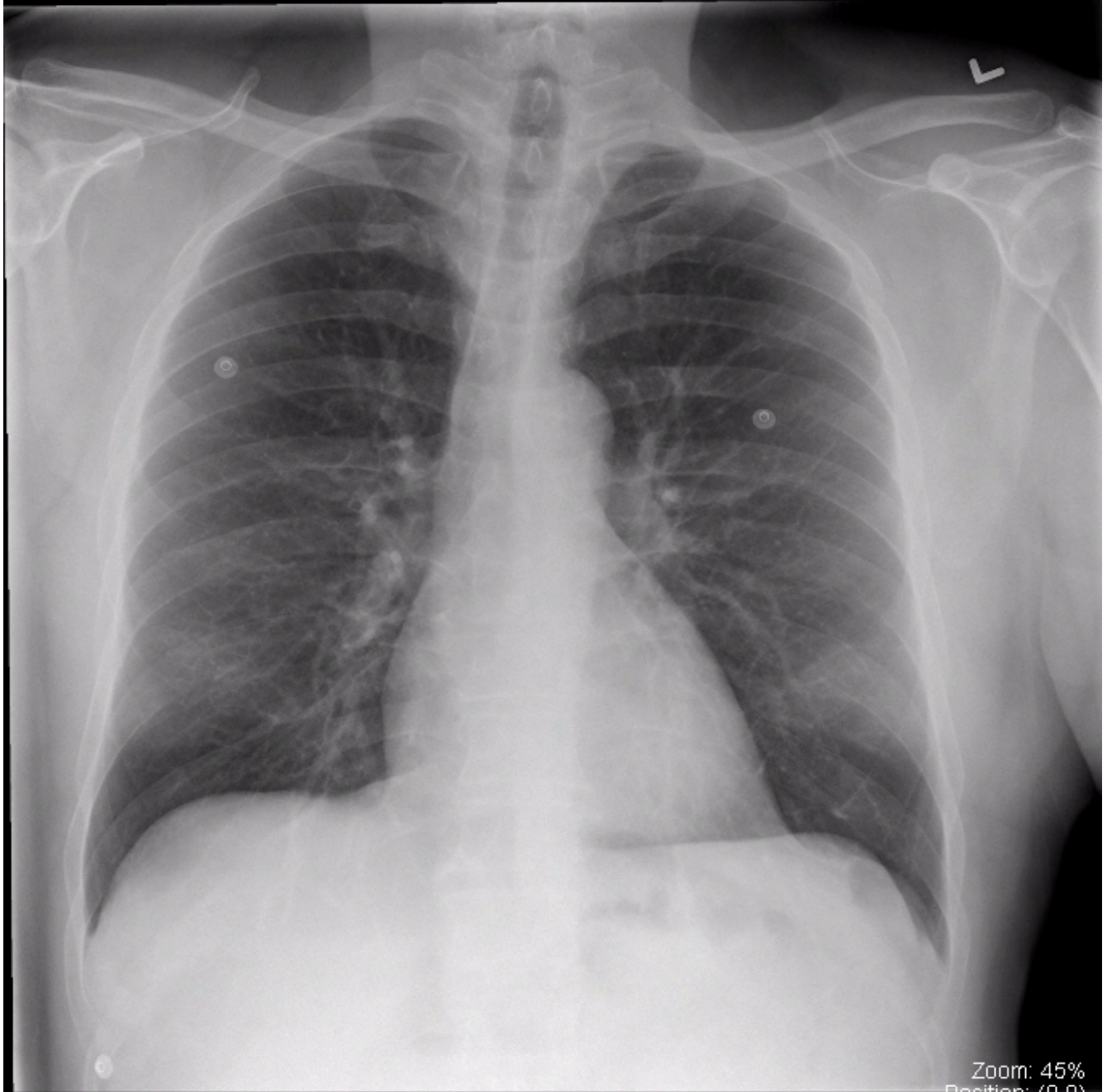
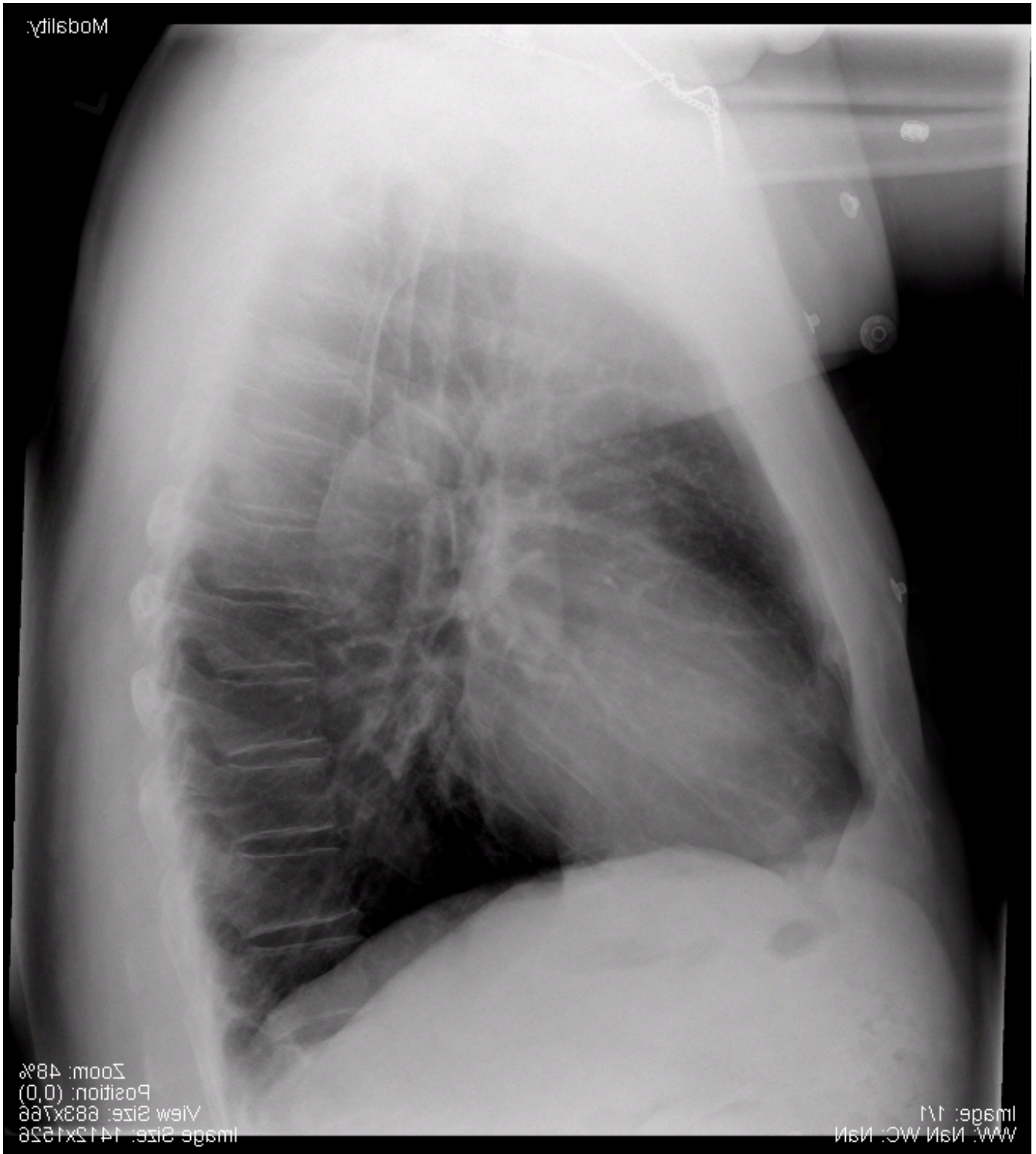


Image: 1/1
WW: NaN WC: NaN

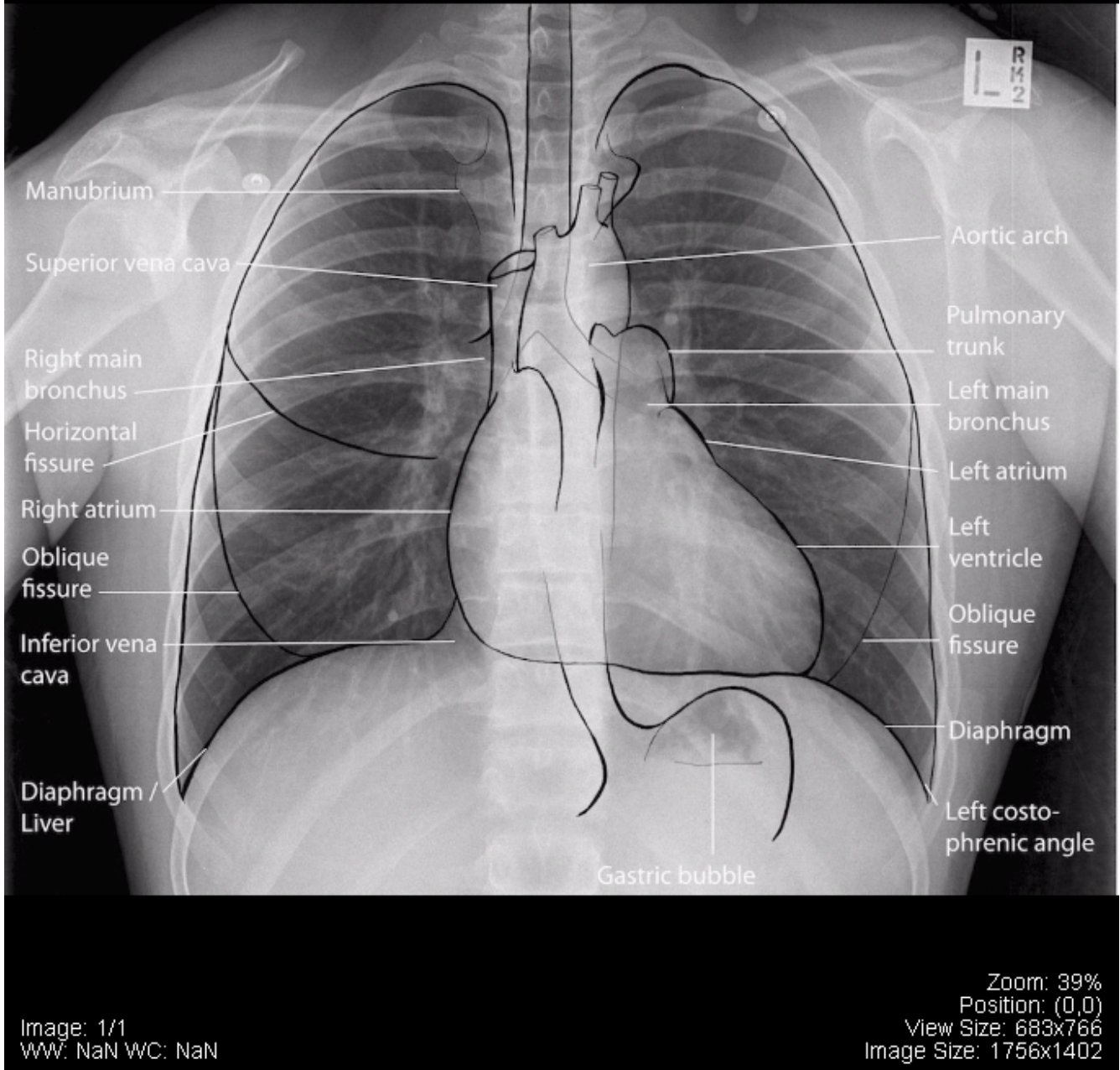
Zoom: 45%
Position: (0,0)
View Size: 683x766
Image Size: 1533x1526

Normal PA Chest x-ray



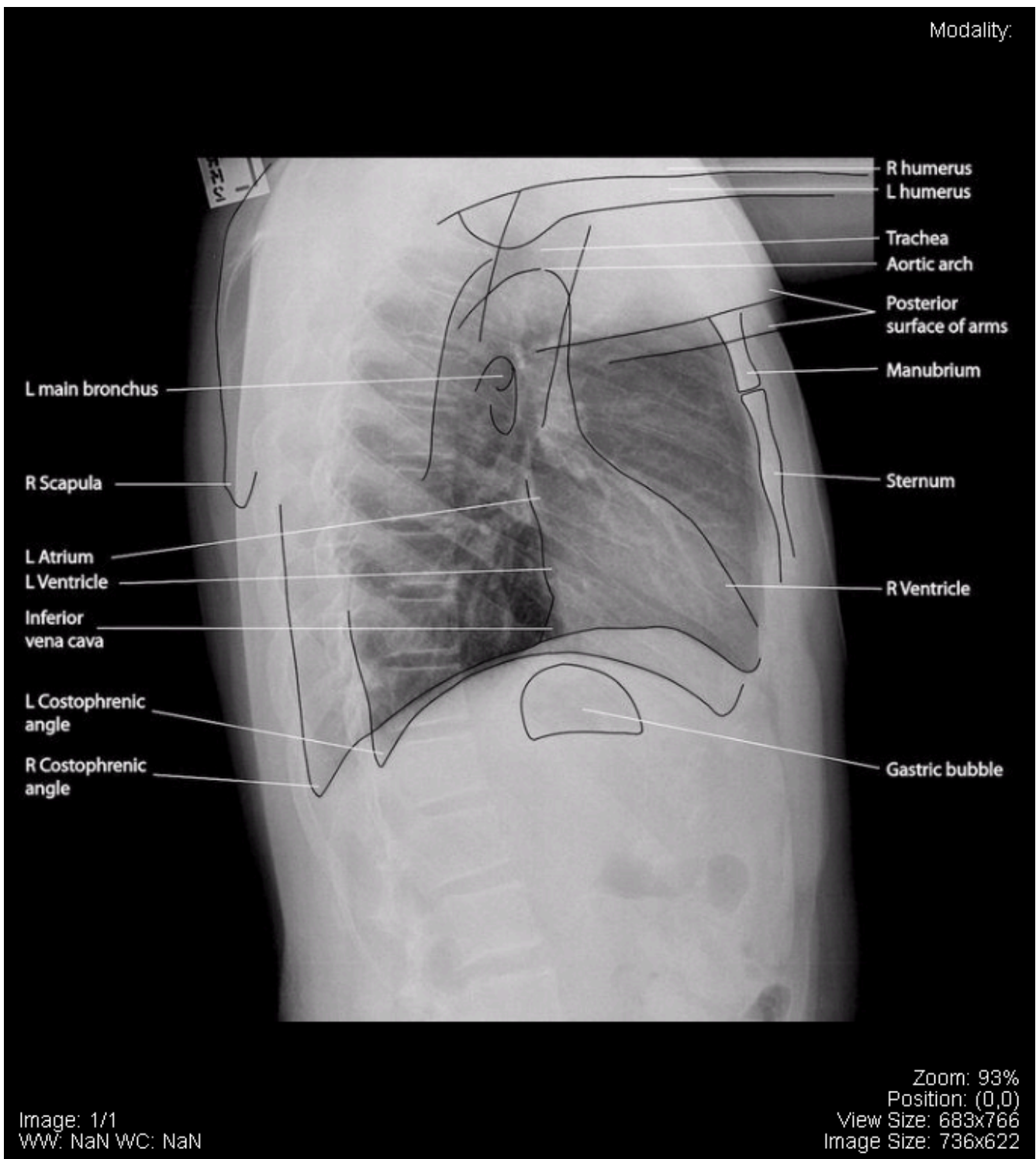
Normal Lateral Chest x-ray

Modality:



PA Chest x-ray labelled

Modality:

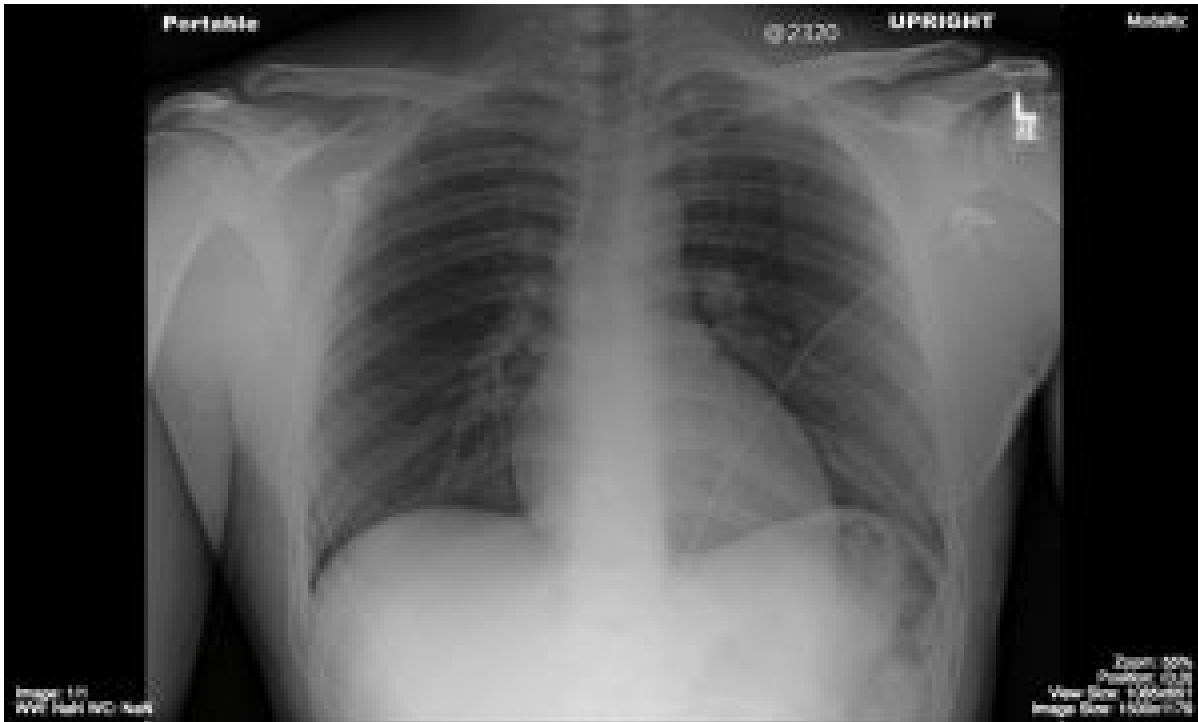

Lateral Chest x-ray labelled

ODIN Link to Unlabelled Chest x-ray Images – <https://mistr.usask.ca/odin/?caseID=20170402103011944>

ODIN Link to Labelled Chest x-ray Images – <https://mistr.usask.ca/odin/?caseID=20170103165555291>

The following is a normal AP (Portable) x-ray of the chest:



Normal AP (portable) chest x-ray

ODIN Link to Normal AP (Portable) Chest x-ray – <https://mistr.usask.ca/odin/?caseID=20170114100724626>

The following are normal pediatric chest x-rays:

Modality:

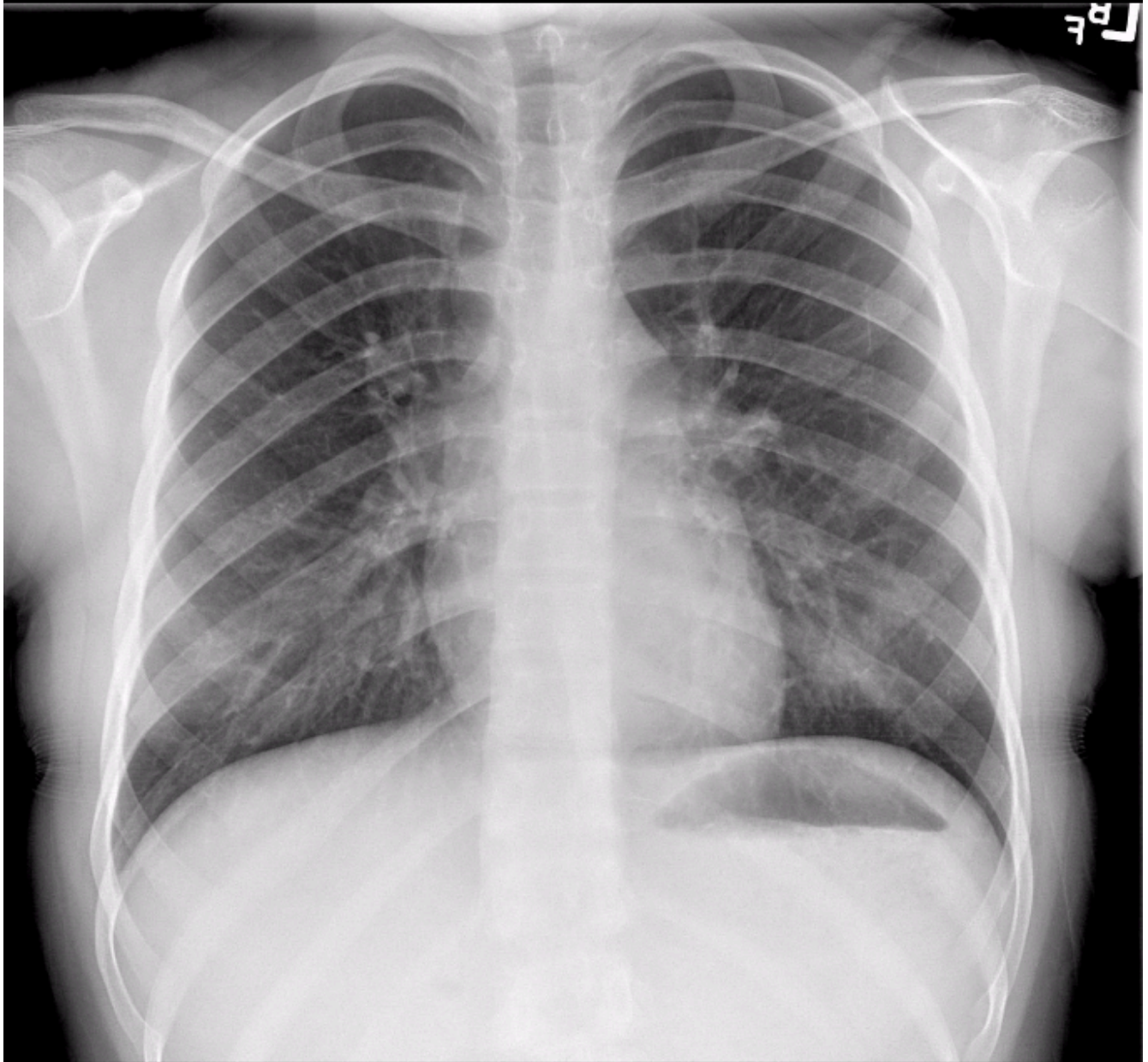


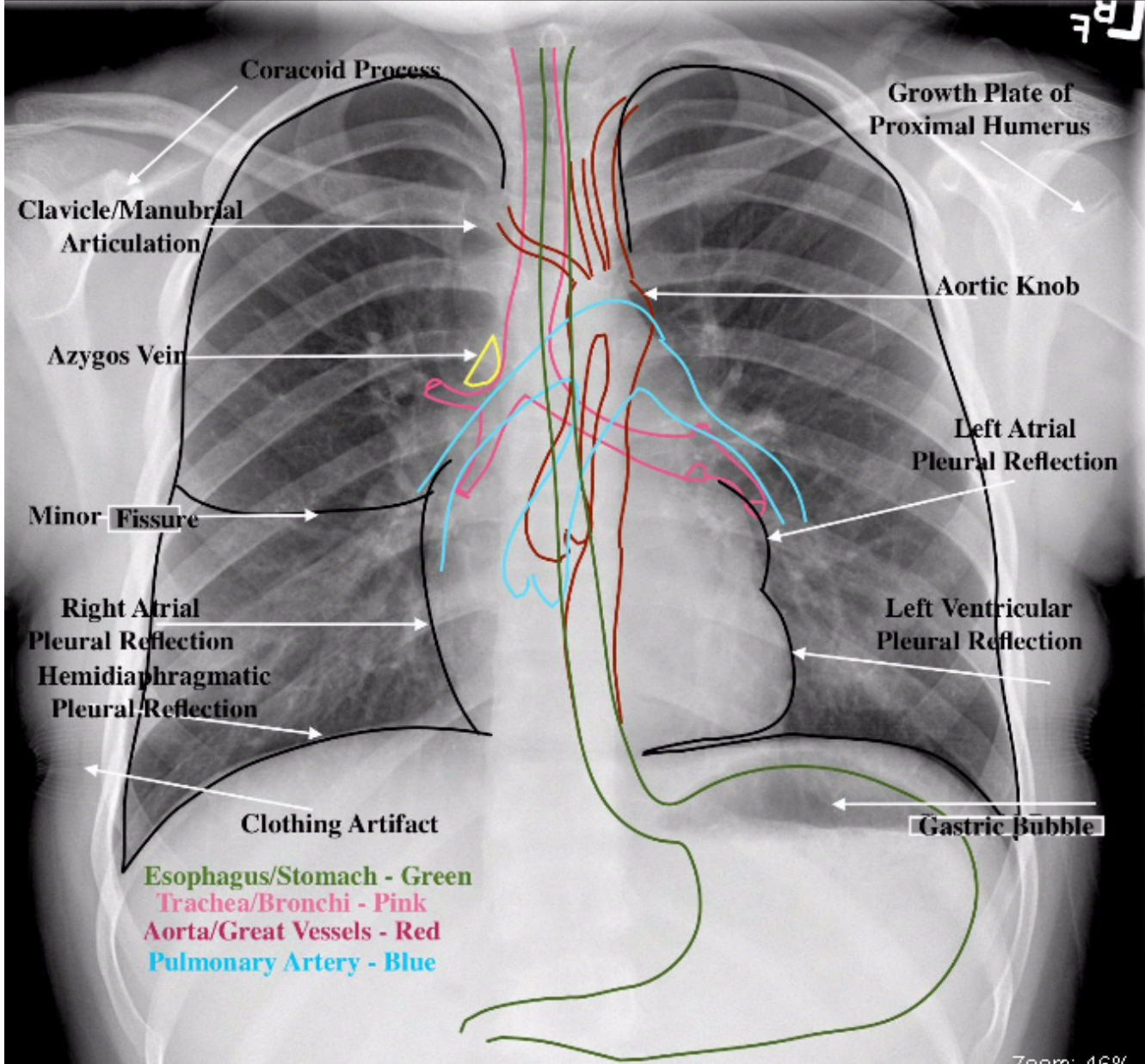
Image: 1/1
WW: NaN WC: NaN

Zoom: 47%
Position: (0,0)
View Size: 683x766
Image Size: 1452x1350

Normal Pediatric PA Chest x-ray

Modality:

RF

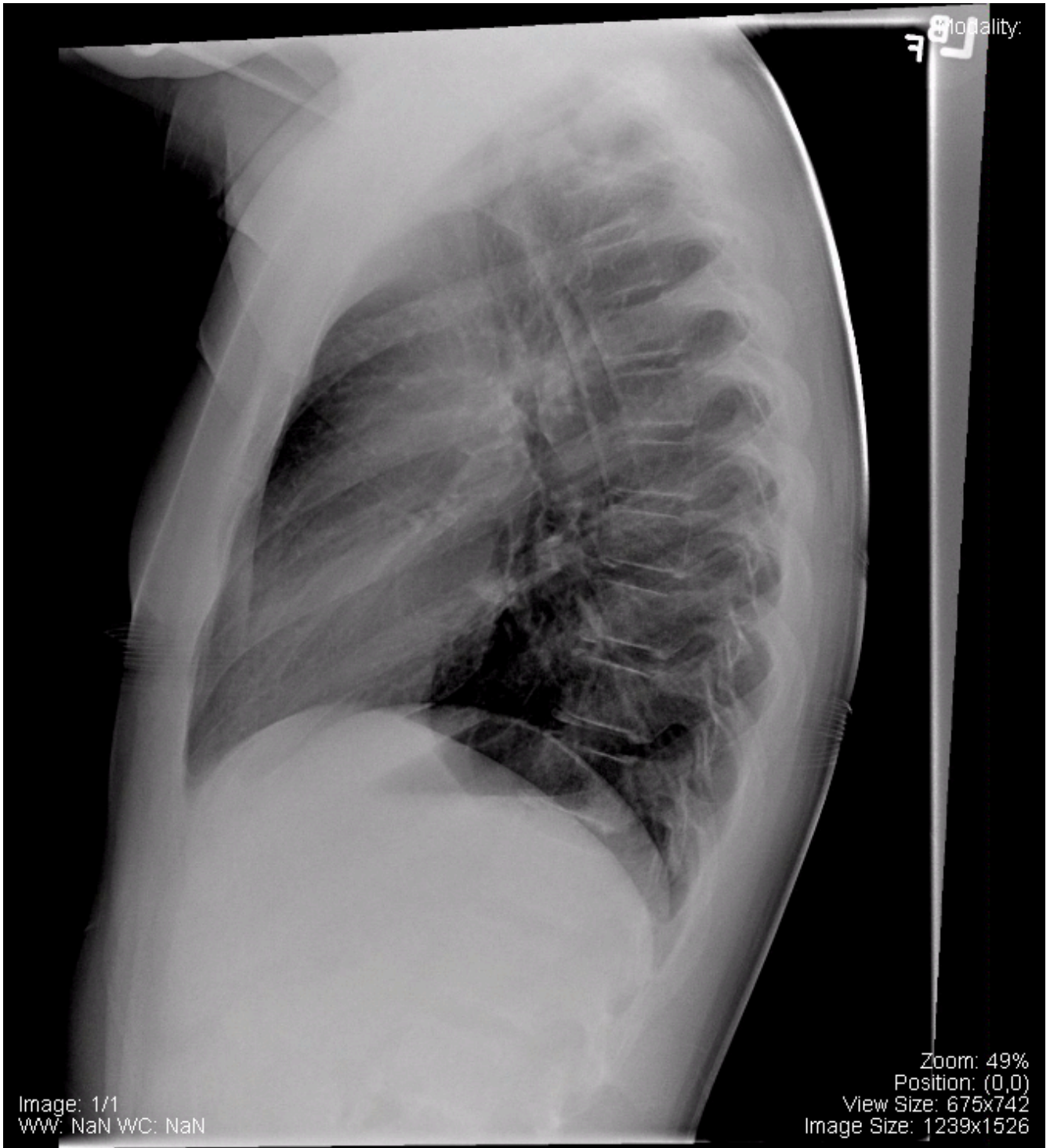


Esophagus/Stomach - Green
Trachea/Bronchi - Pink
Aorta/Great Vessels - Red
Pulmonary Artery - Blue

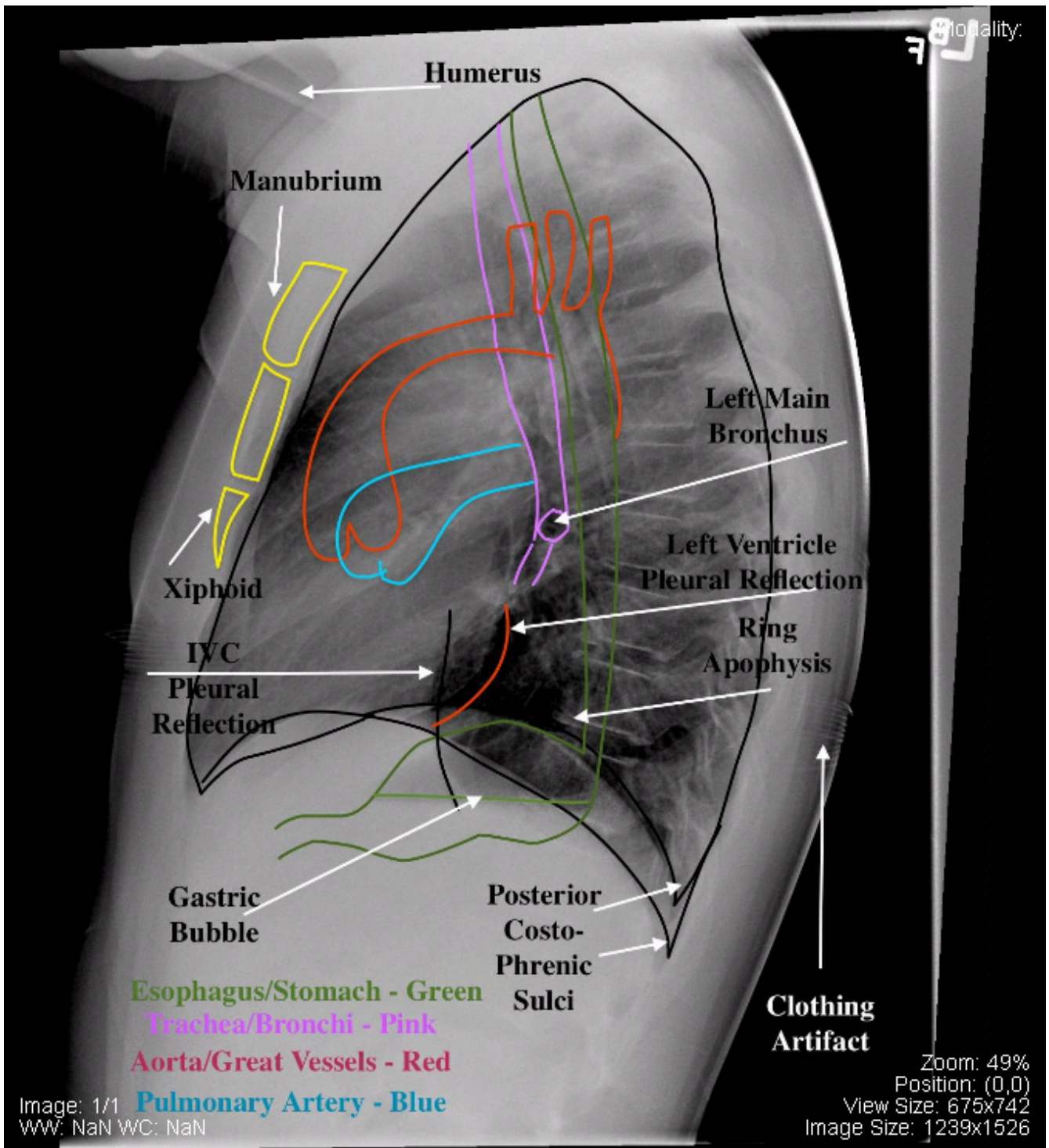
Zoom: 46%
Position: (0,0)
View Size: 675x742
Image Size: 1452x1350

Image: 1/1
WWW: NaN WC: NaN

Annotated Normal Pediatric PA Chest x-ray



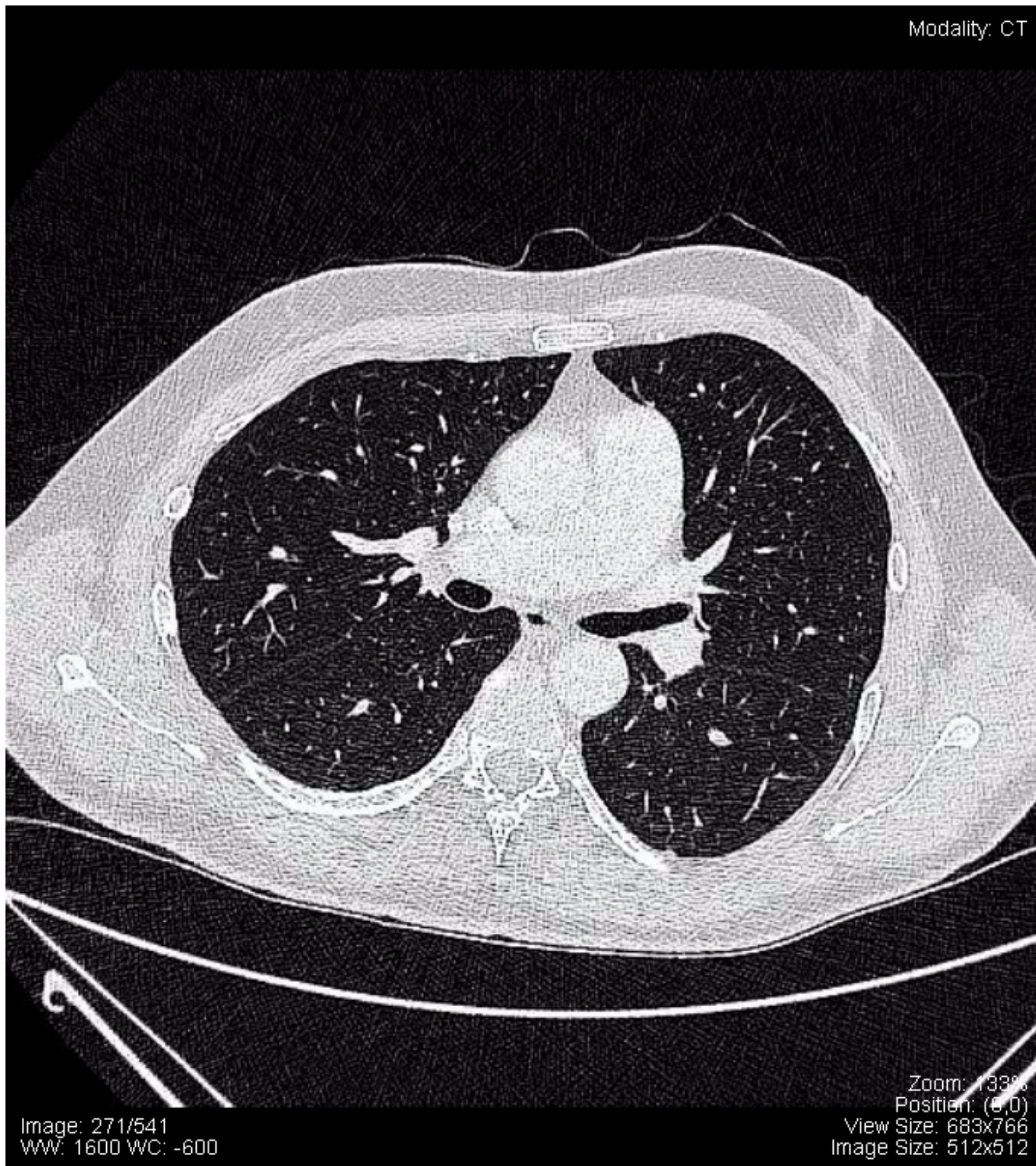
Normal Lateral Pediatric Chest x-ray



Annotated Normal Pediatric Lateral Chest x-ray

ODIN Link to Images – <https://mistr.usask.ca/odin/?caseID=20170825125714420>

The following are sections from a High Resolution CT (HRCT) of a normal chest:



ODIN Link to HRCT Images – <https://mistr.usask.ca/odin/?caseID=20170731230443139>

The following is a normal CT Angiography (CTA) of the Pulmonary Arteries:

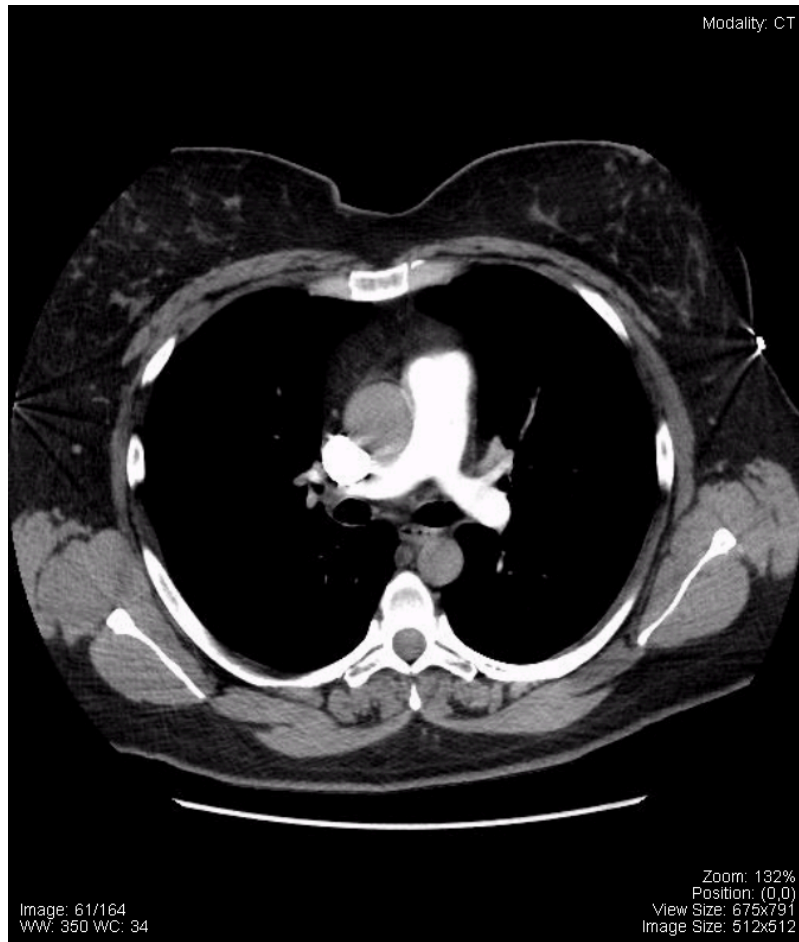


Fig 17.40A Normal CTA of Chest

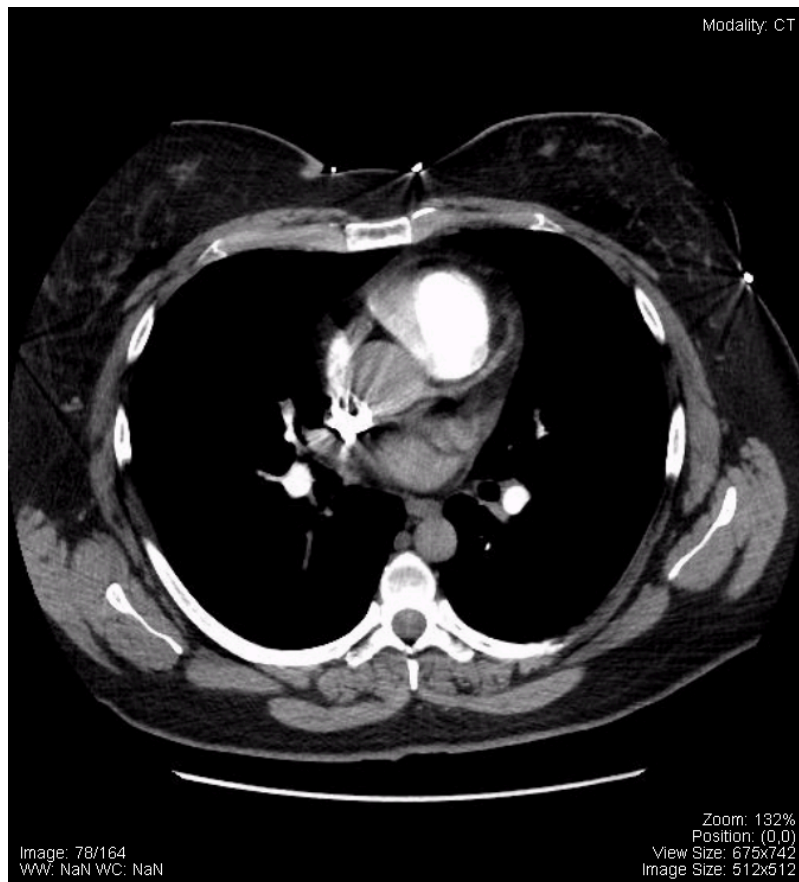


Fig 17.40B Normal CTA of Chest

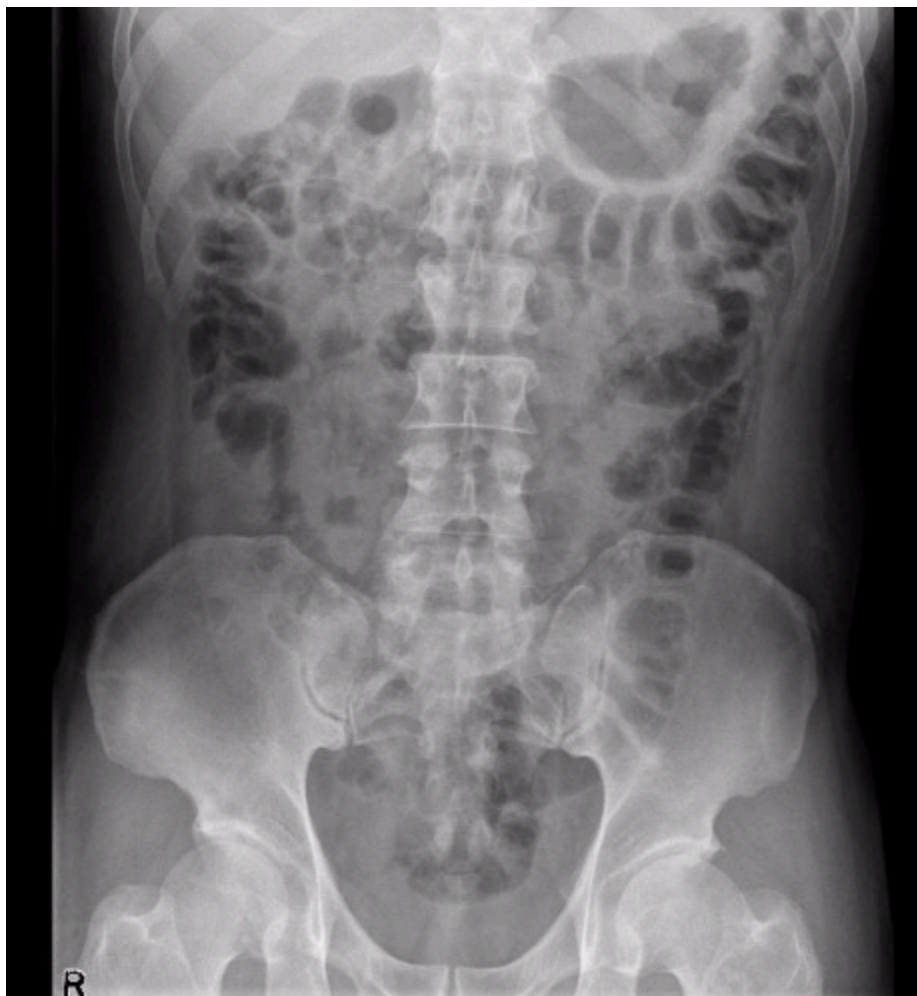ODIN Link to CTA – <https://mistr.usask.ca/odin/?caseID=20170803170331806>

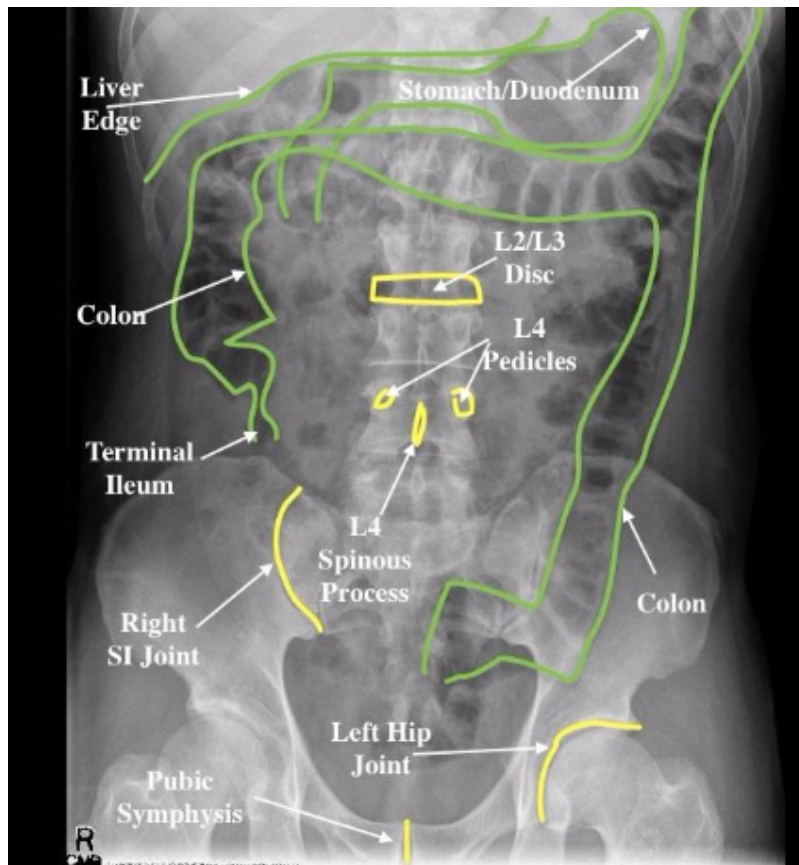
Attributions

All figures in “**Chapter 17: Chest**” by Dr. Brent Burbridge MD, FRCPC, University Medical Imaging Consultants, College of Medicine, University of Saskatchewan is used under a [CC-BY-NC-SA 4.0](https://creativecommons.org/licenses/by-nc-sa/4.0/) license.

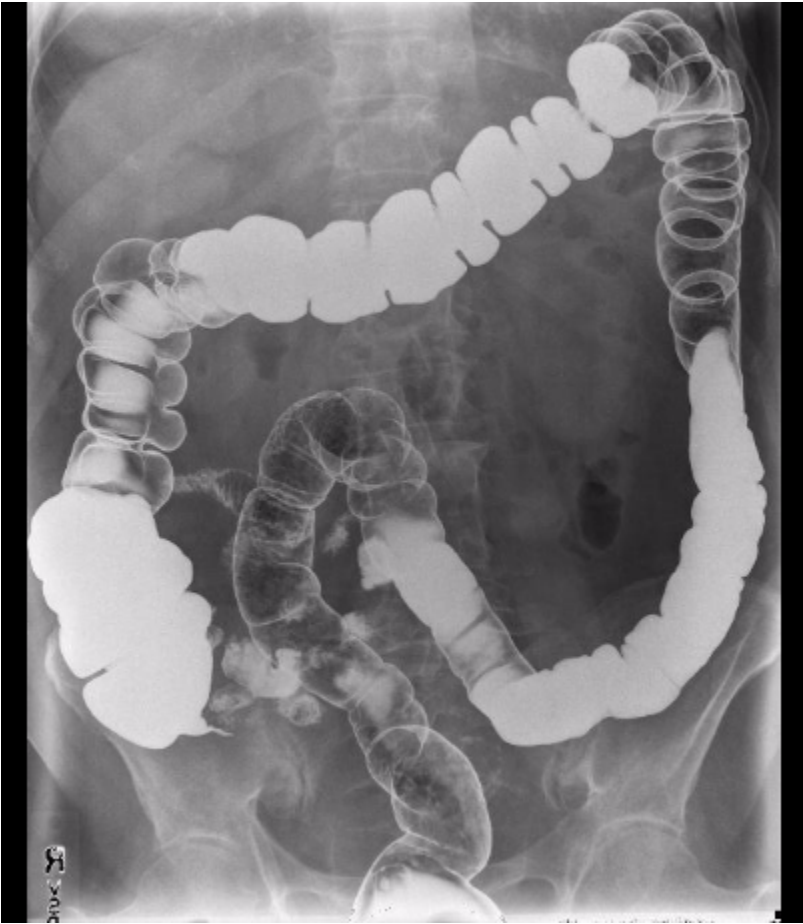Abdomen

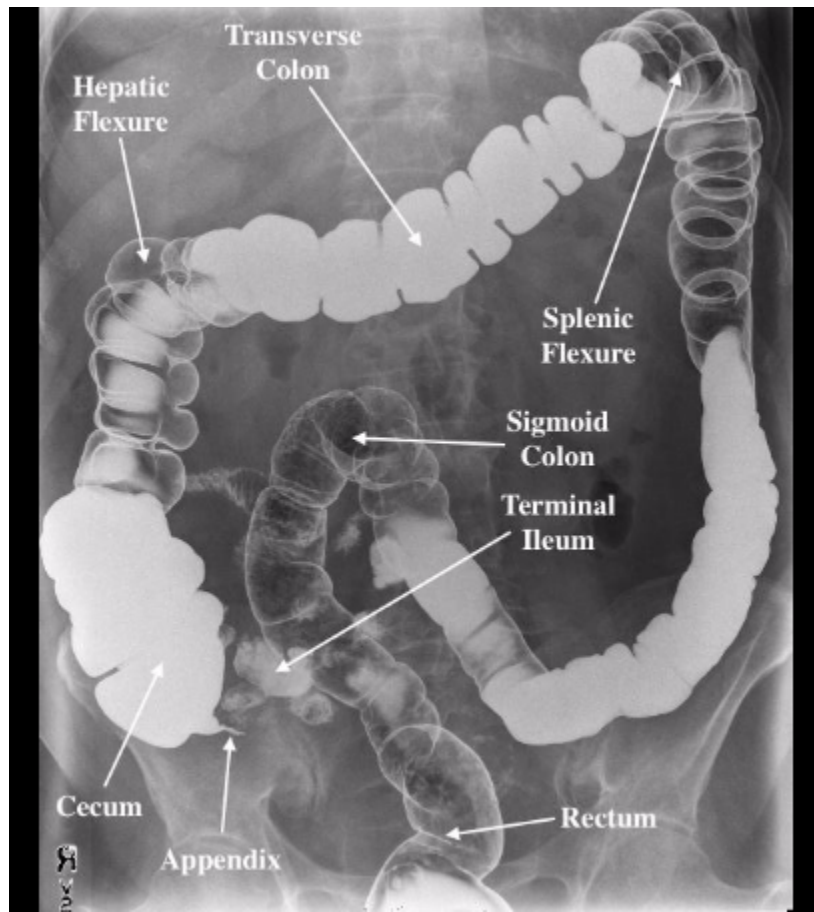
The following images are references for x-rays of the abdomen:





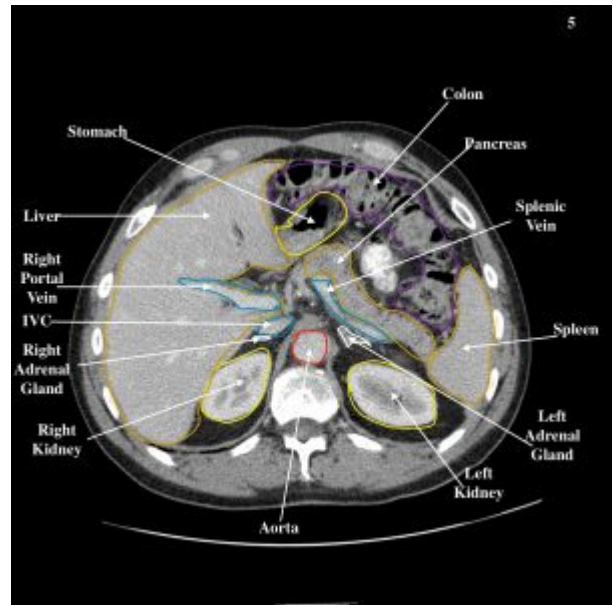
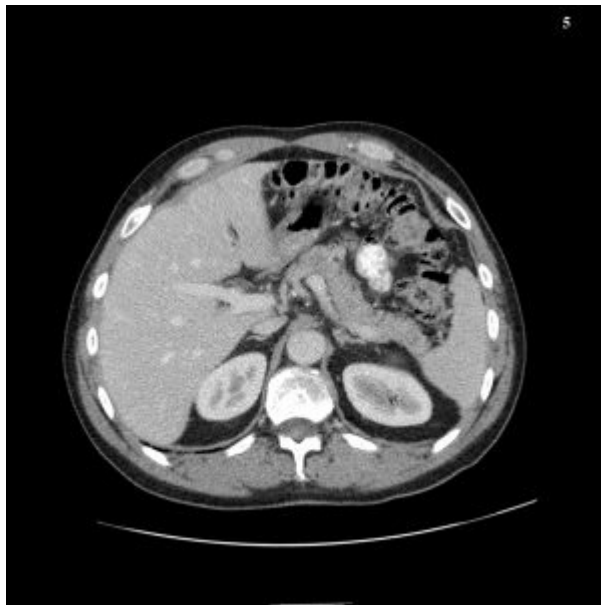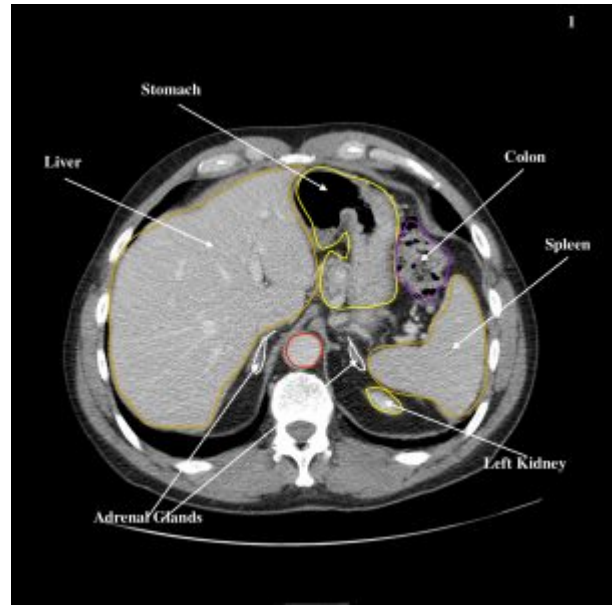
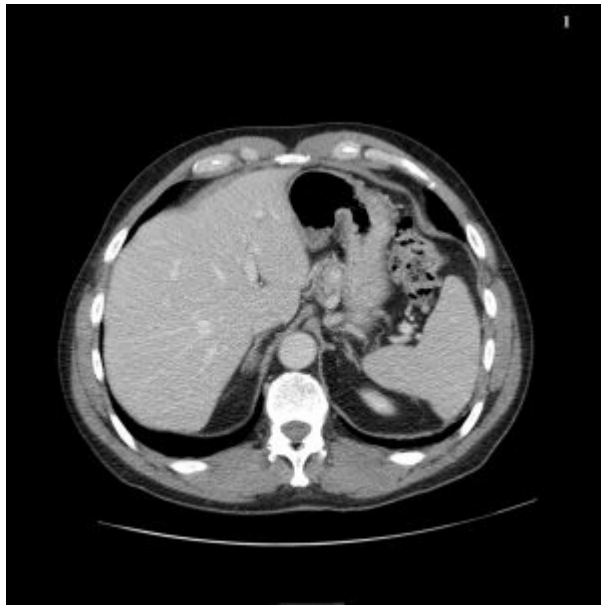Abdomen Plain x-ray, Labelled

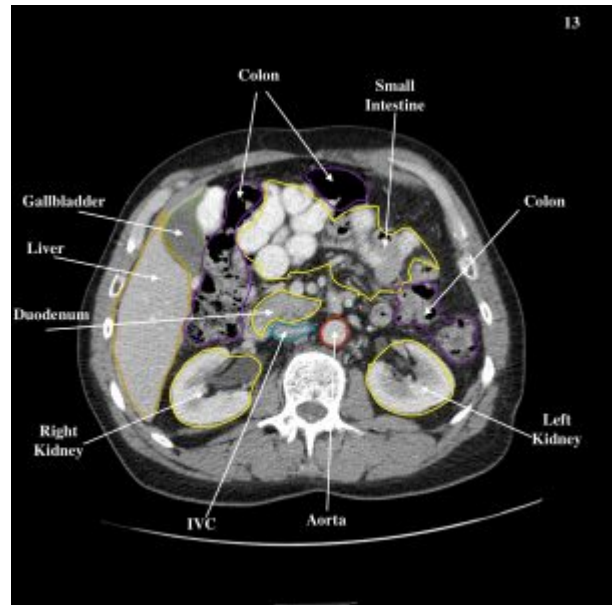
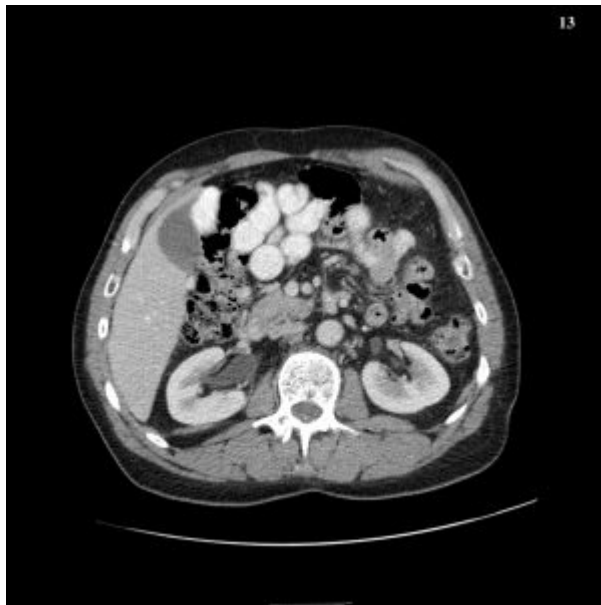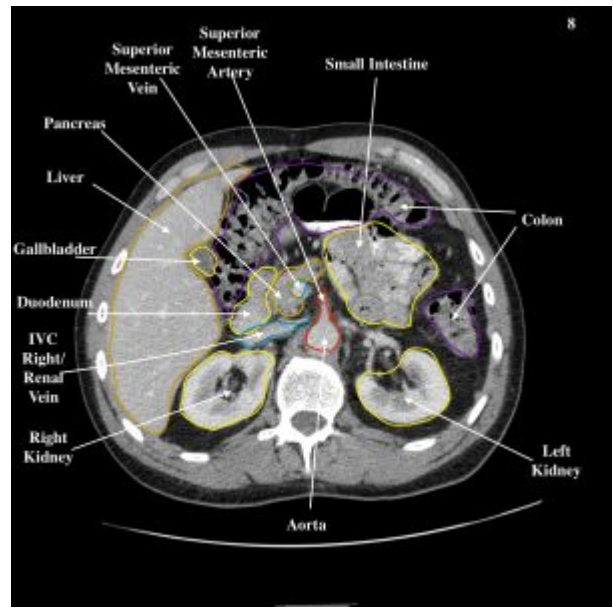

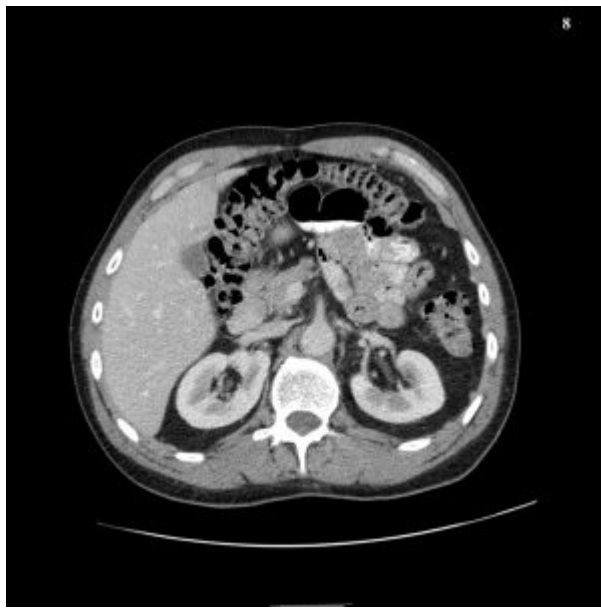
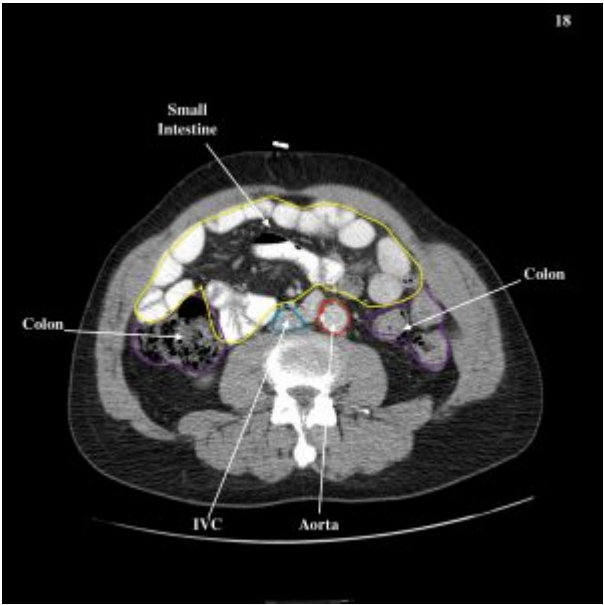
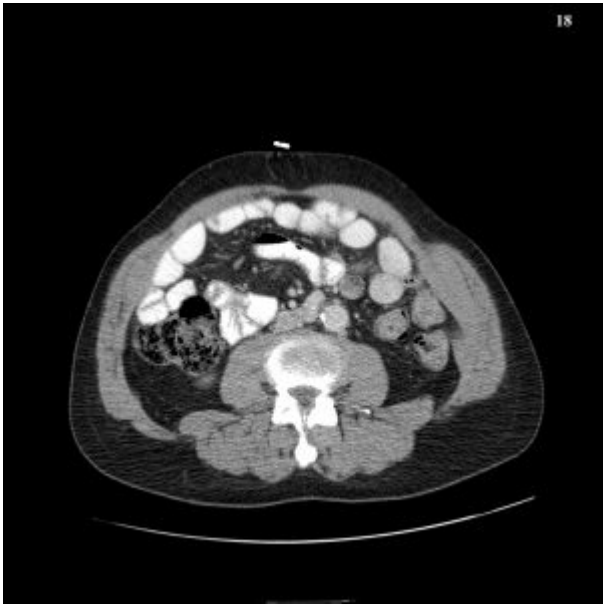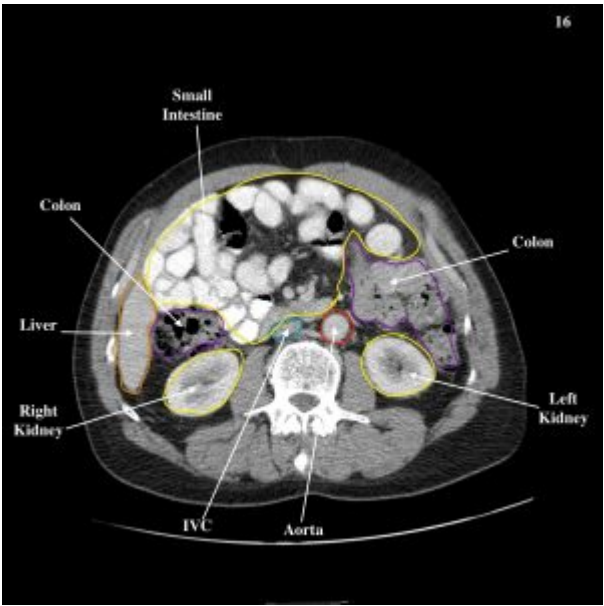


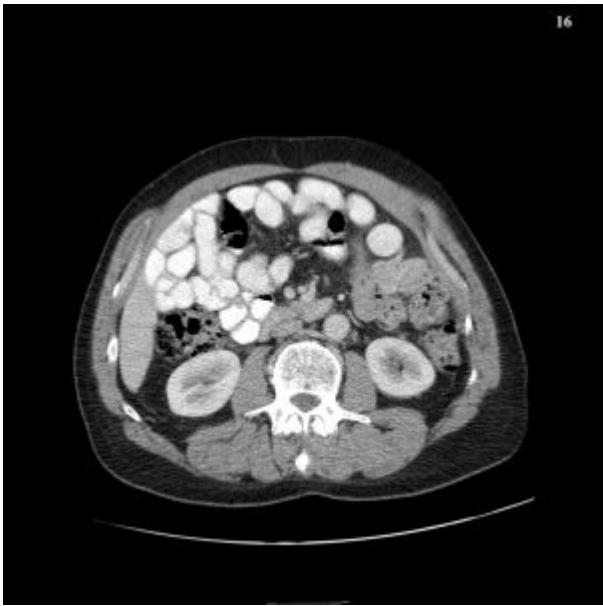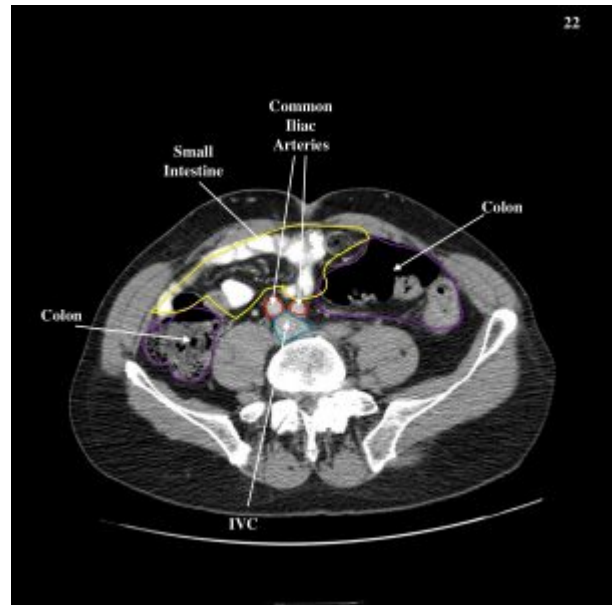
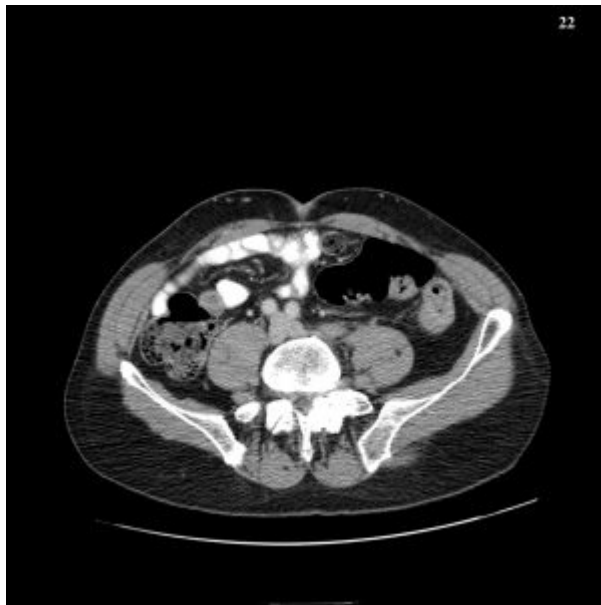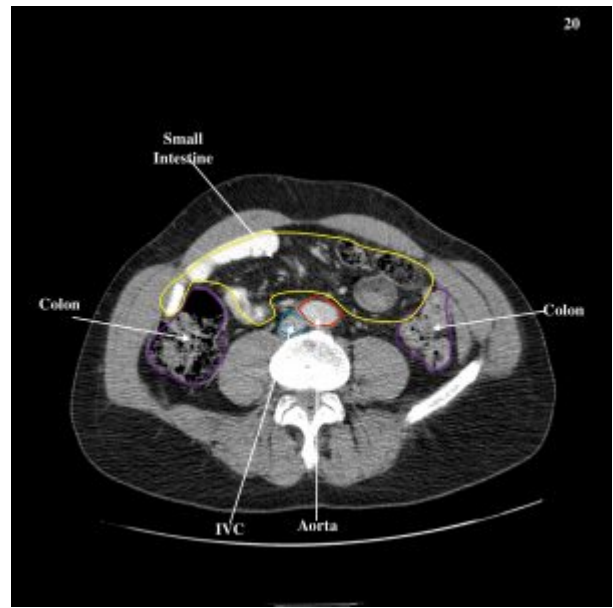
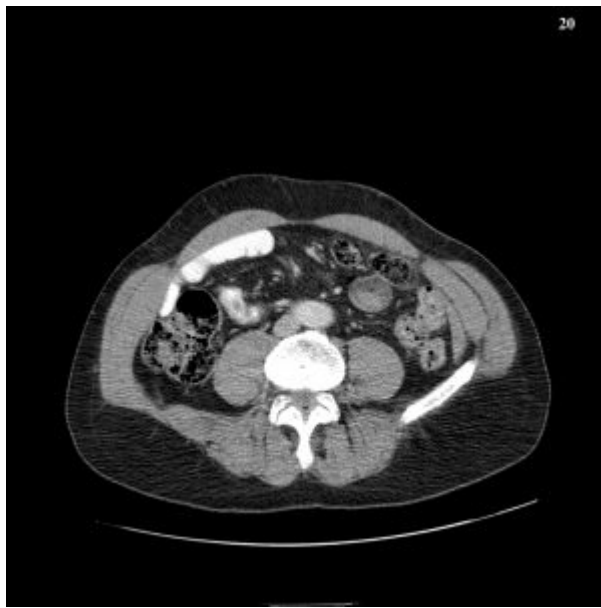ODIN Link for Abdomen x-rays – <https://mistr.usask.ca/odin/?caseID=20170825121322404>

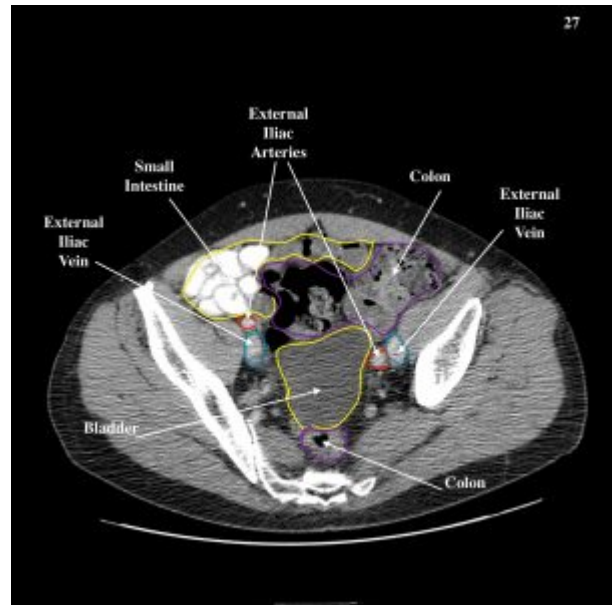
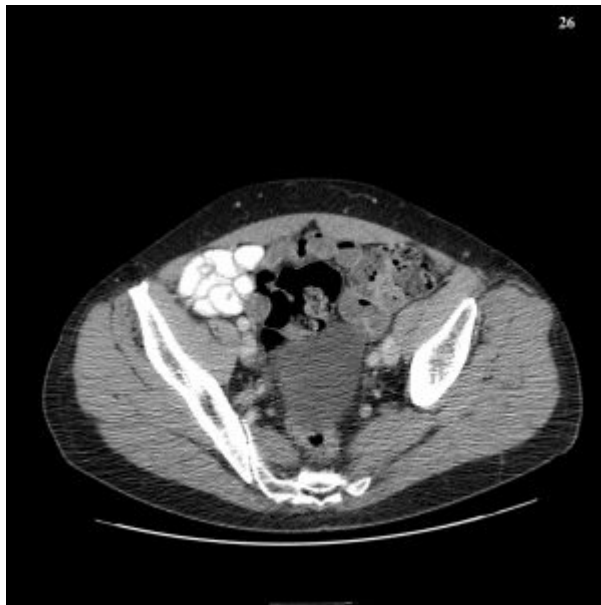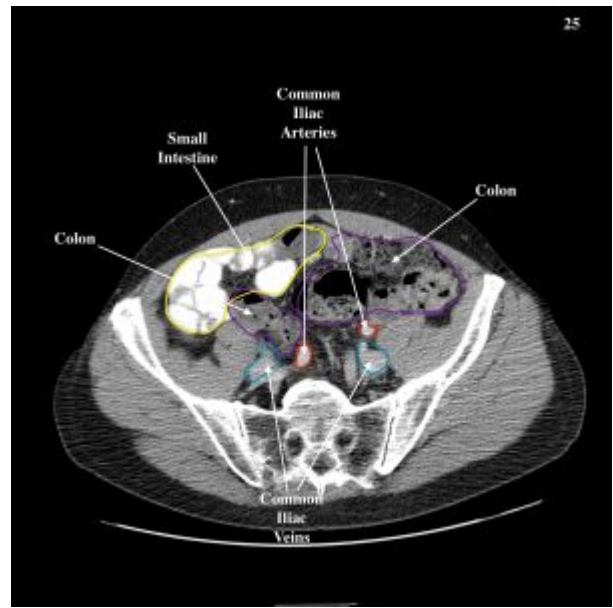
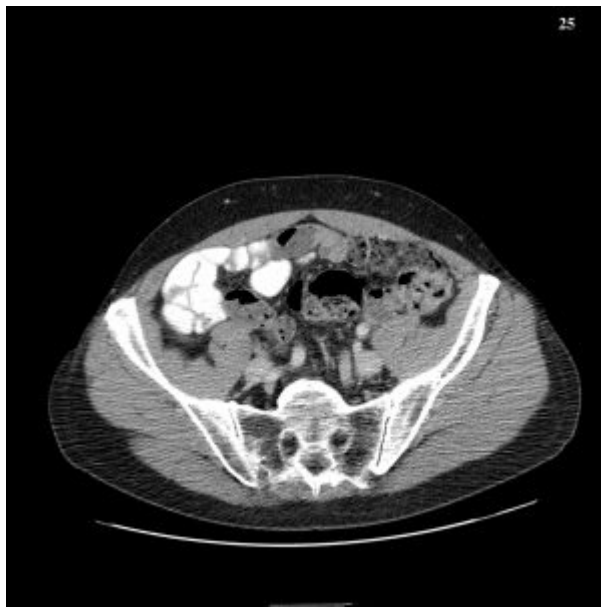The following are CT Abdomen images, unlabelled and labelled. This is a sample of the available images. Please see the ODIN link for the full image set.





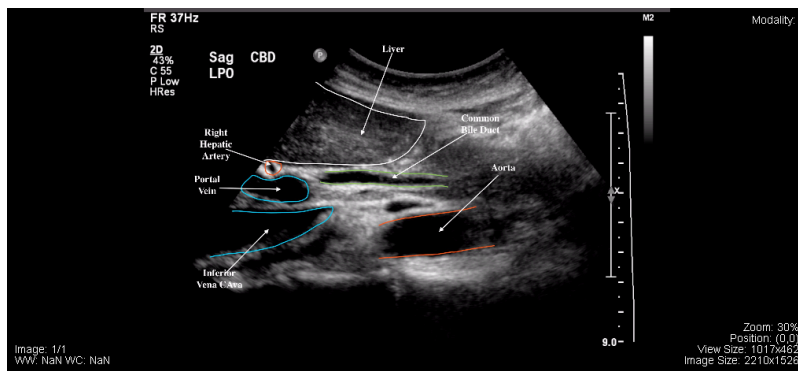
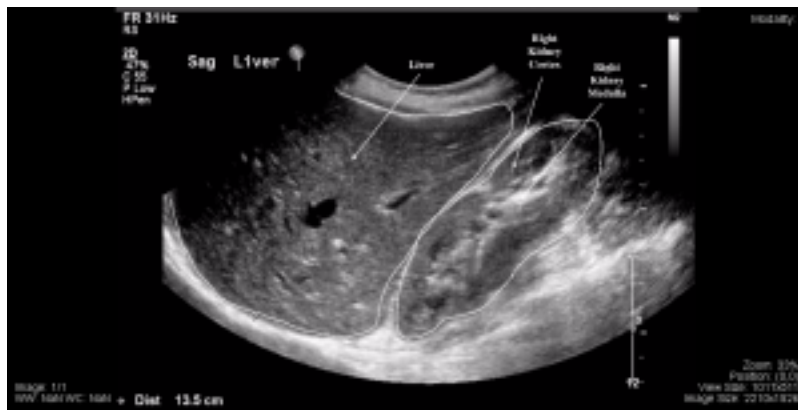




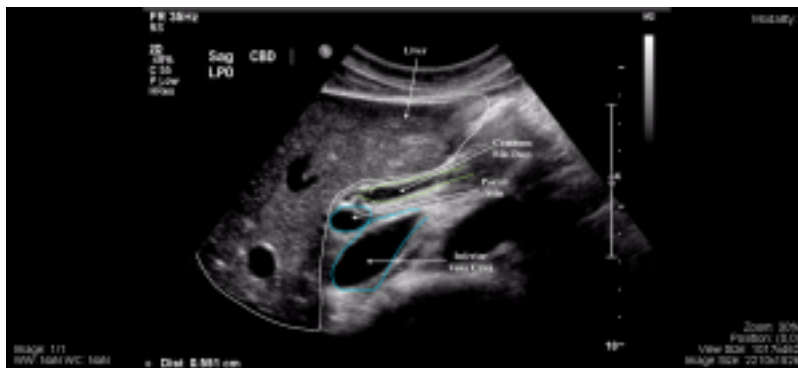

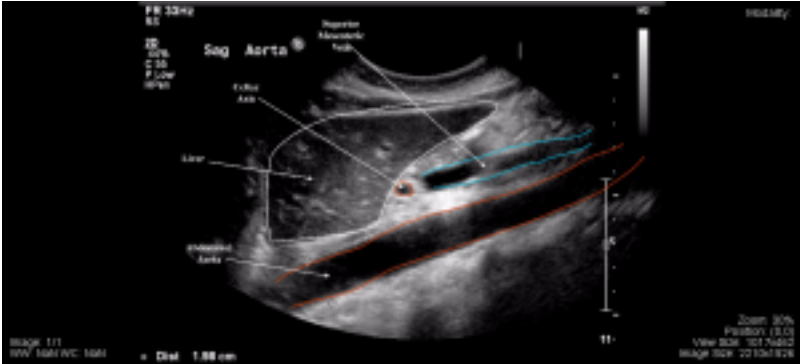
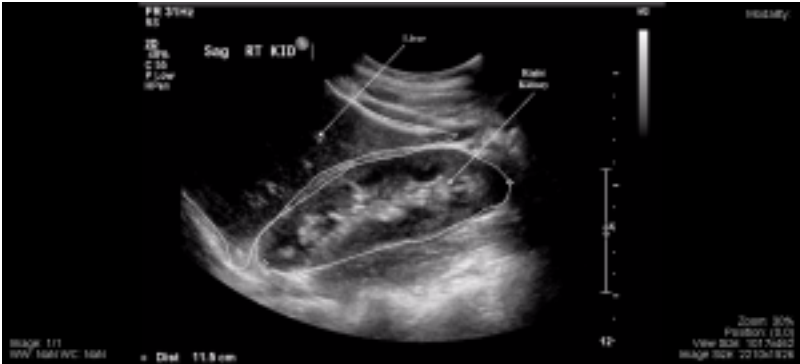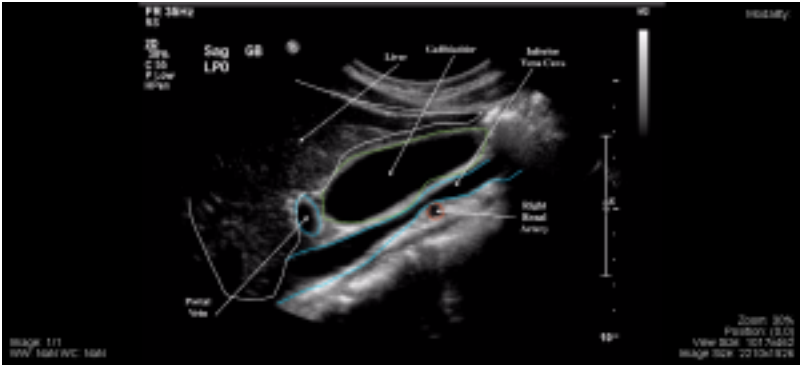
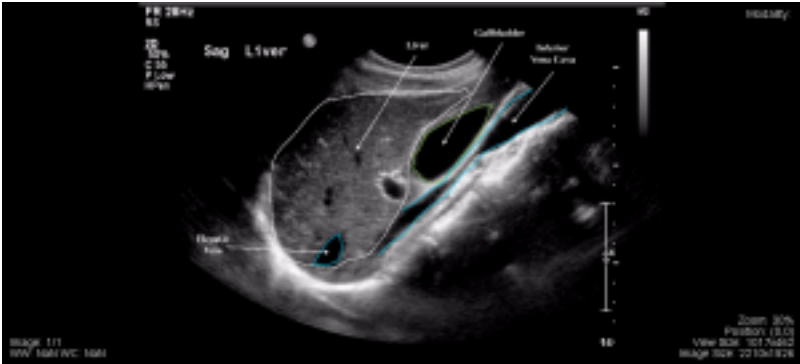
ODIN Link for CT images of the Abdomen, unlabelled and labelled- <https://mistr.usask.ca/odin/?caseID=20171002123606662>

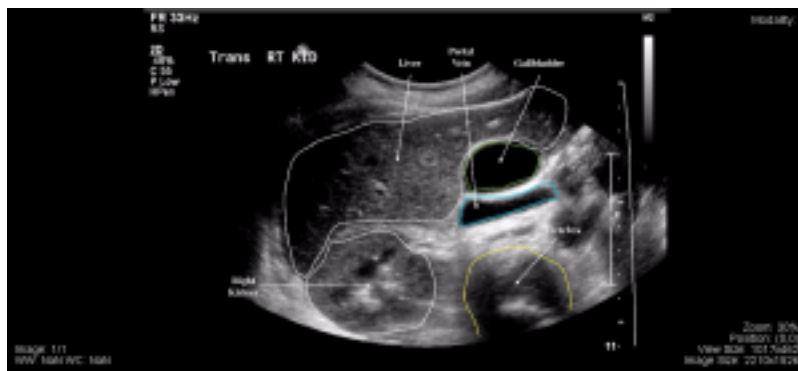
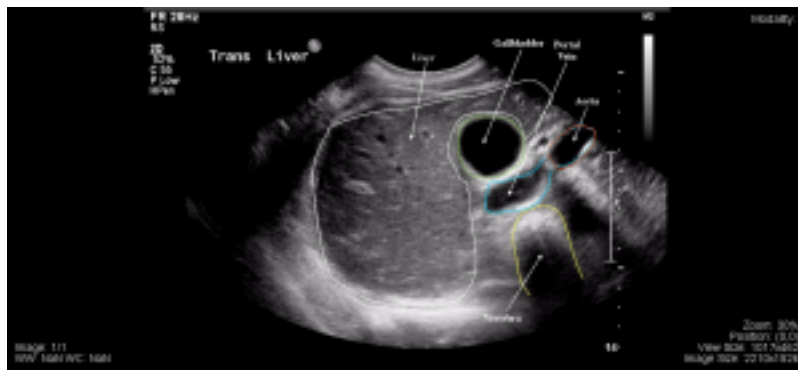
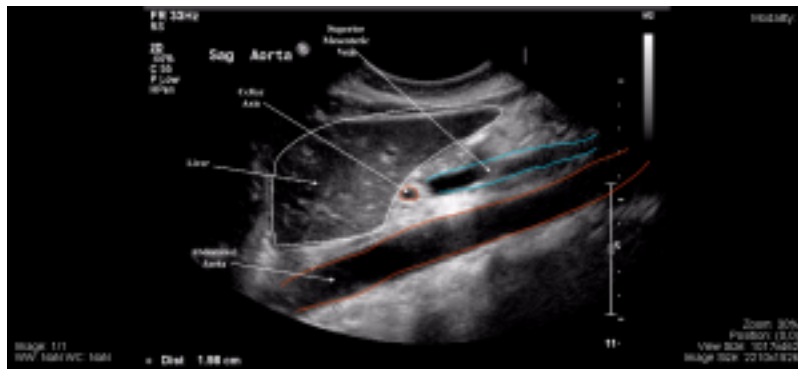
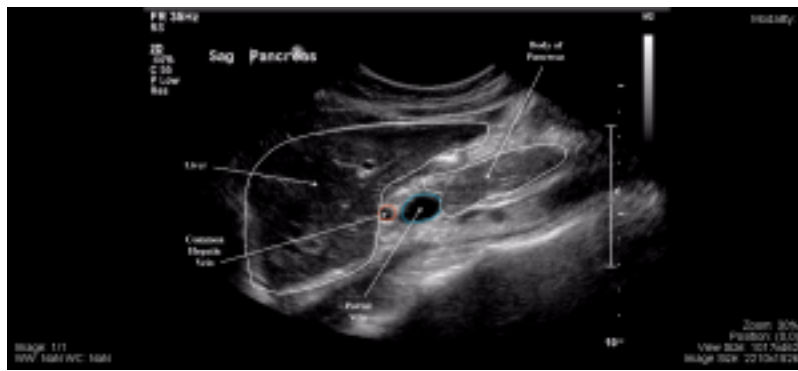
The following images are of Ultrasound images of the abdomen. Please see the ODIN link for the full image set.

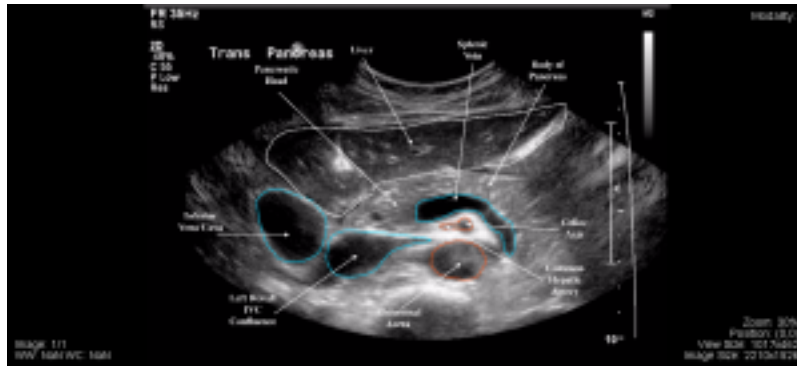


Abdomen US – Liver and Abdominal Midline





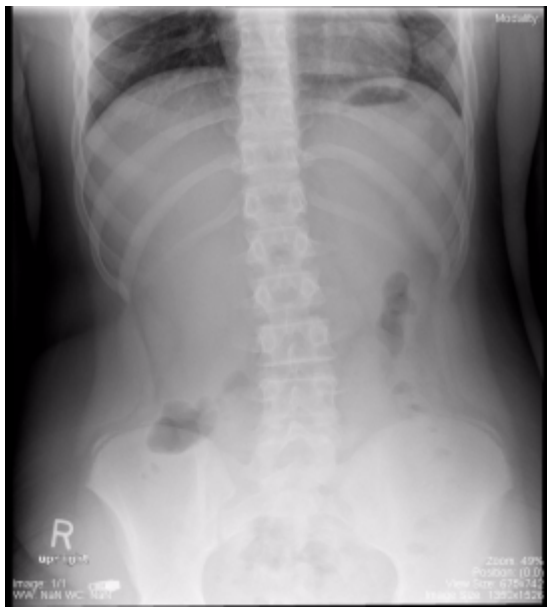




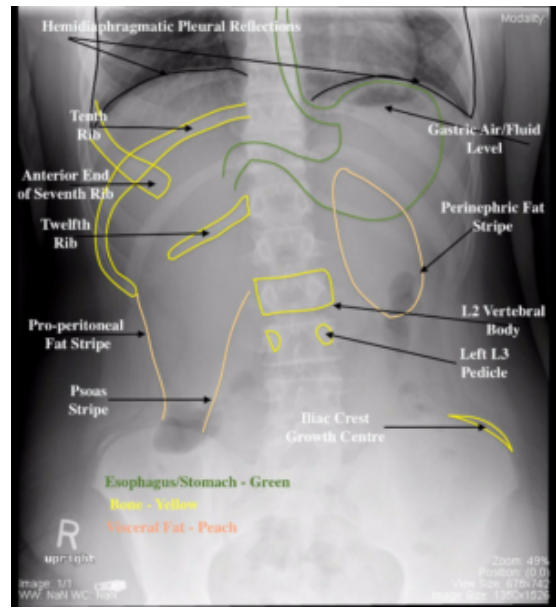
ODIN Link for Normal Abdomen U/S, unlabelled and with labels – <https://mistr.usask.ca/odin/?caseID=20170825121827828>

ODIN Link for Normal Abdomen U/S – <https://mistr.usask.ca/odin/?caseID=20141112102809335>

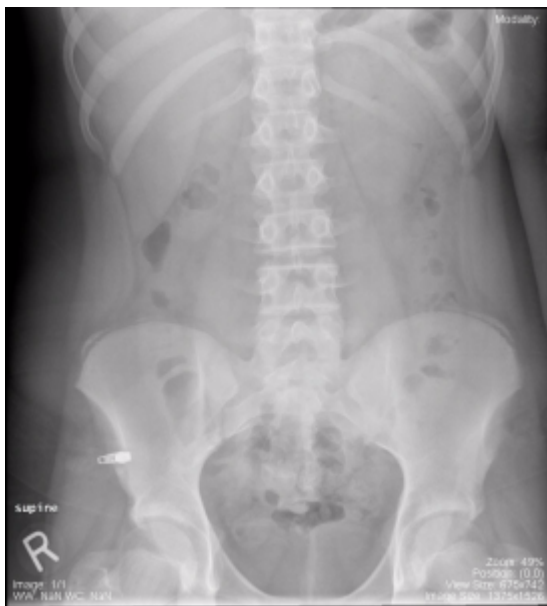The following are normal pediatric abdominal x-rays:



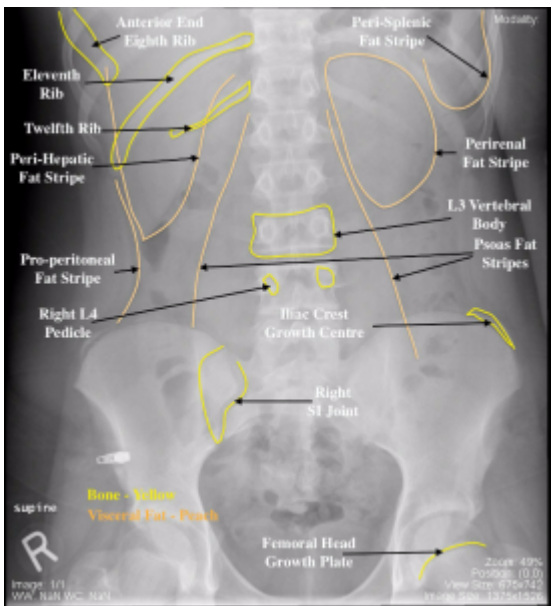
Pediatric Abdomen 1



Pediatric Labelled Abdomen 2



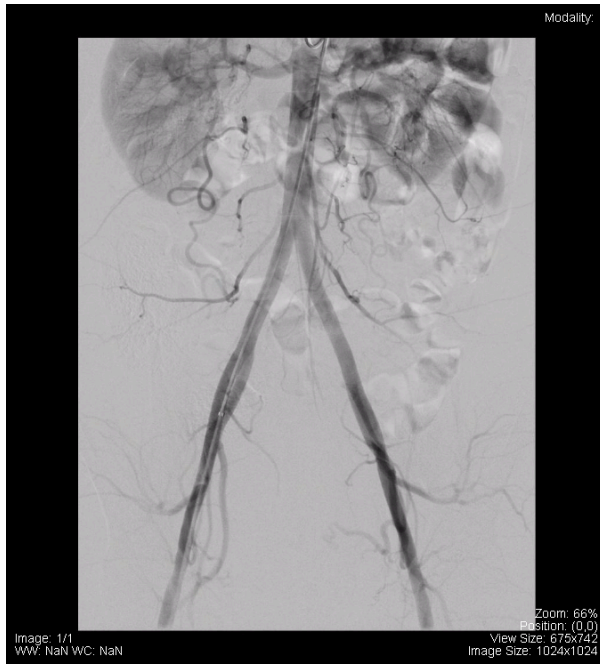Pediatric Abdomen 2



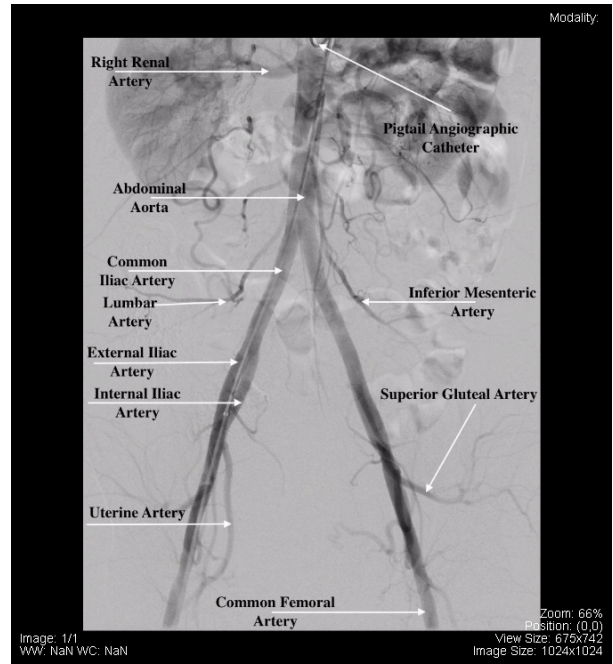
Pediatric Labelled Abdomen 2

ODIN Link for Pediatric Abdomen Images – <https://mistr.usask.ca/odin/?caseID=20170825130032521>

The following is a normal Digital Subtraction Angiography (DSA) of the abdomen vasculature:



DSA of Abdomen



DSA Labelled Abdomen

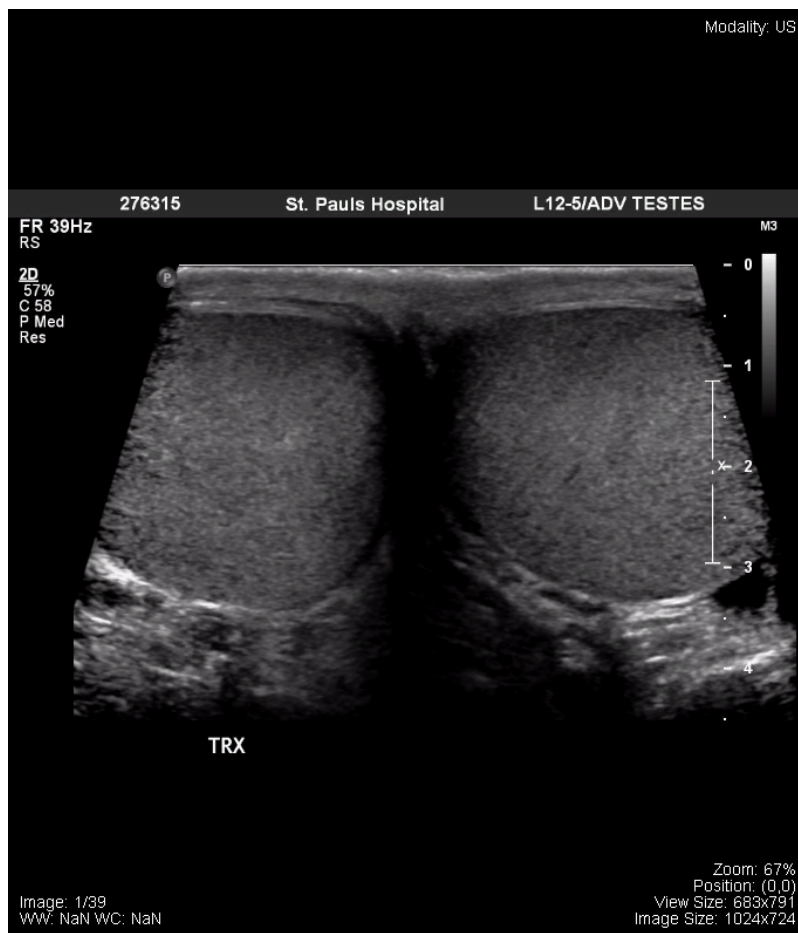
ODIN Link to Images – <https://mistr.usask.ca/odin/?caseID=20170825124857516>

Attributions

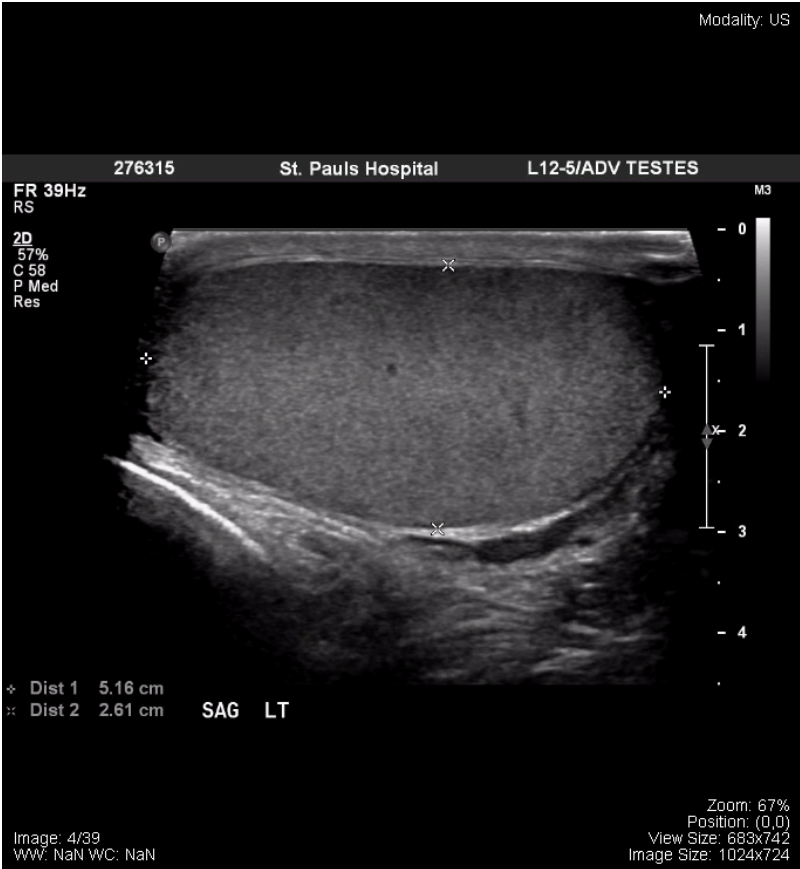
All figures in “**Chapter 17: Abdomen**” by Dr. Brent Burbridge MD, FRCPC, University Medical Imaging Consultants, College of Medicine, University of Saskatchewan is used under a [CC-BY-NC-SA 4.0](https://creativecommons.org/licenses/by-nc-sa/4.0/) license.

Pelvis

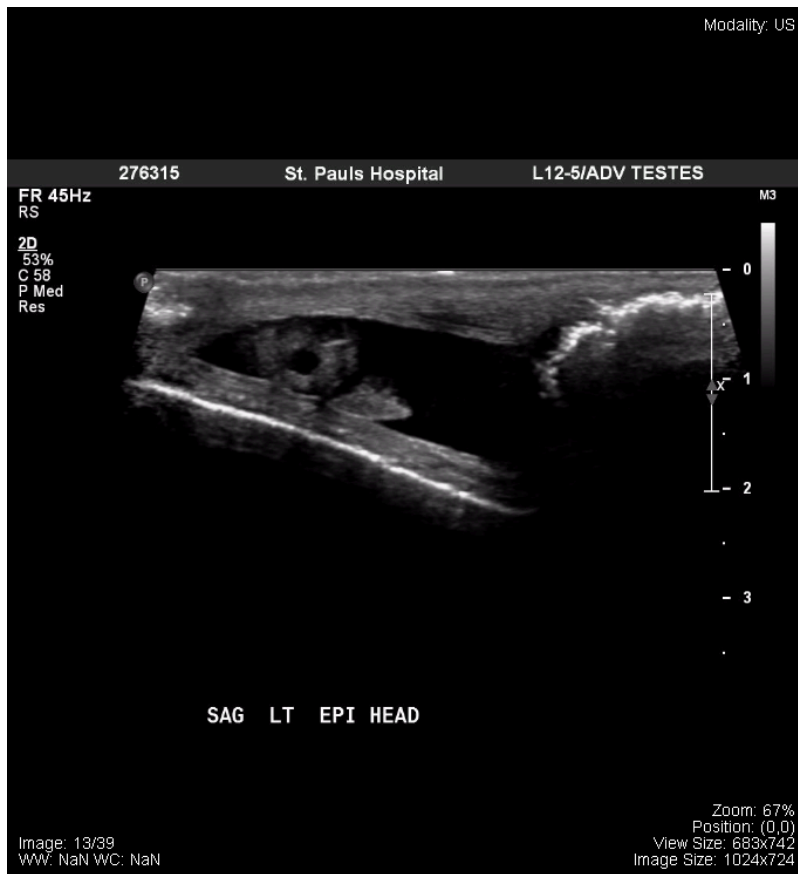The following is a normal ultrasound of the testicles:



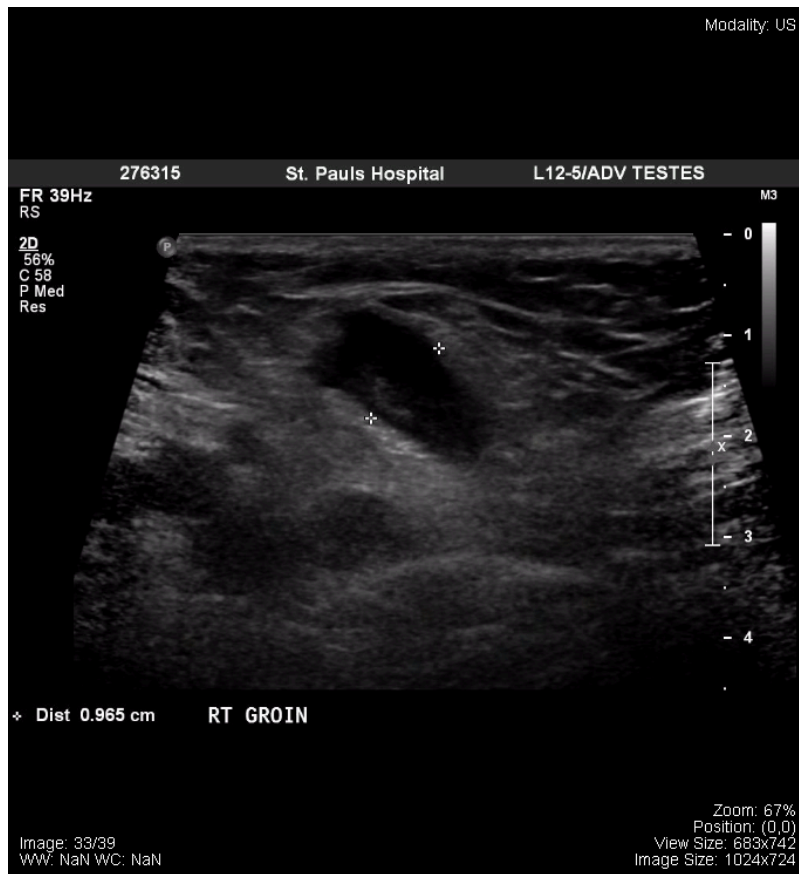
Transverse – both testicles



Sagittal view, left testicle, with measurements



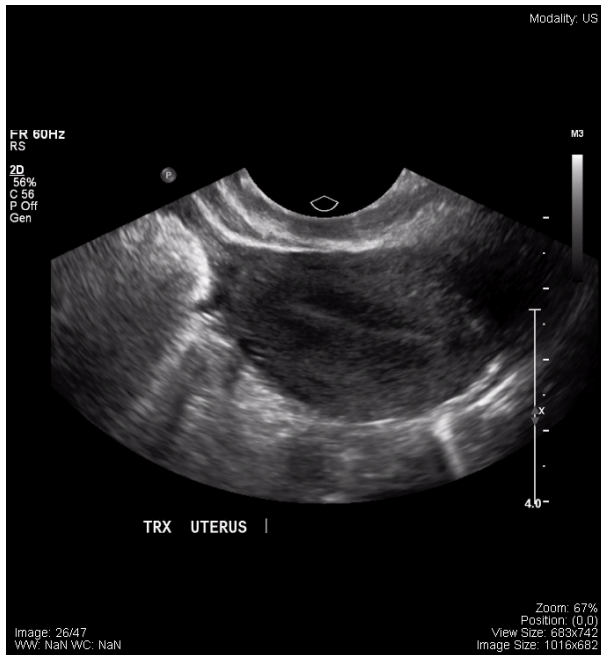
Sagittal view, left epididymis, head



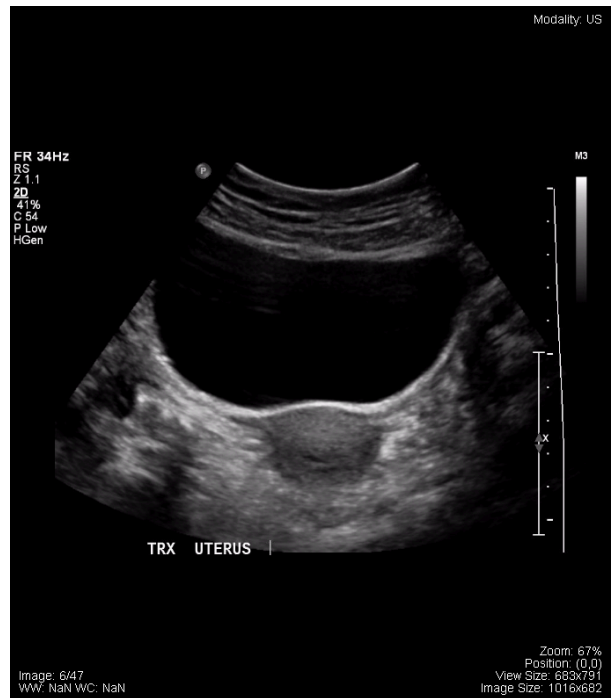
Right Groin

ODIN Link to Images: <https://mistr.usask.ca/odin/?caseID=20170803094403042>

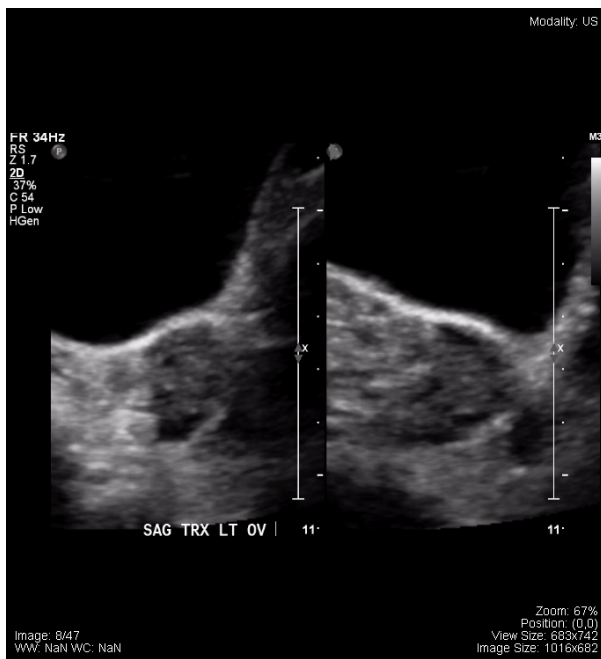The following are from a normal female pelvic ultrasound:



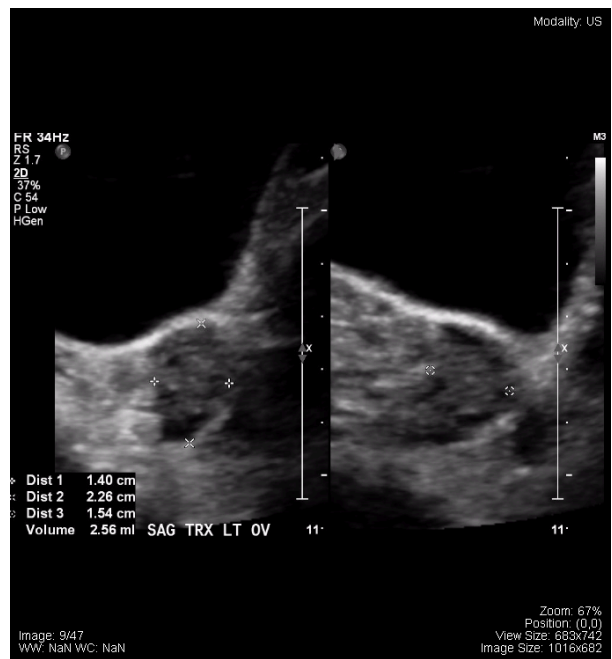Transverse Uterus



Transverse Uterus 2



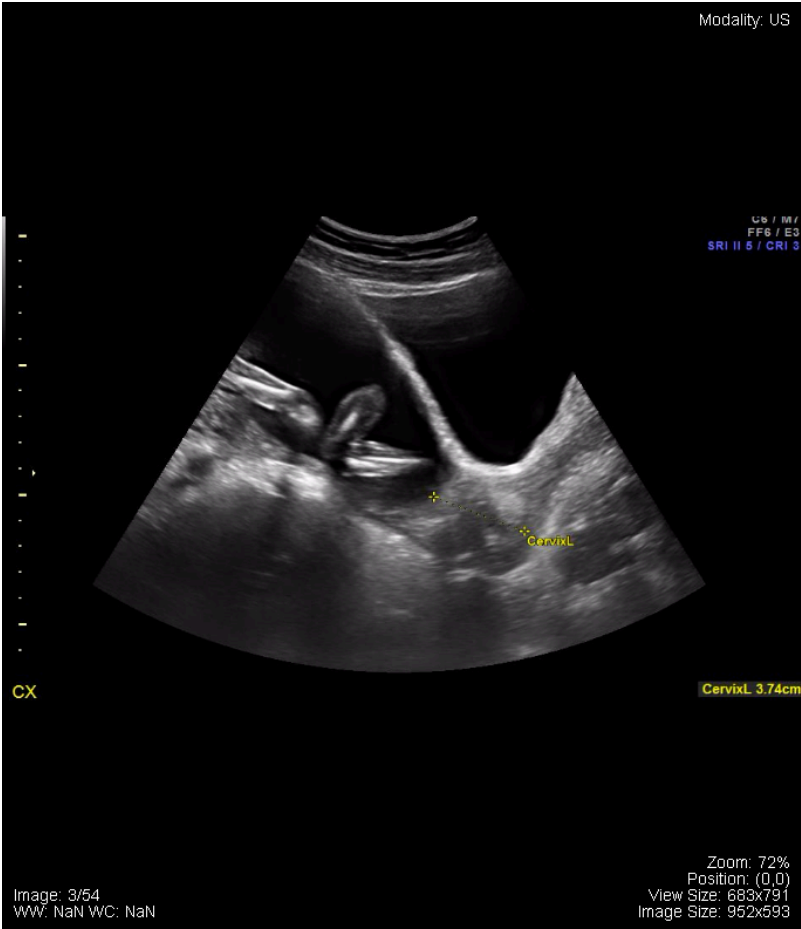
Sagittal Ovary



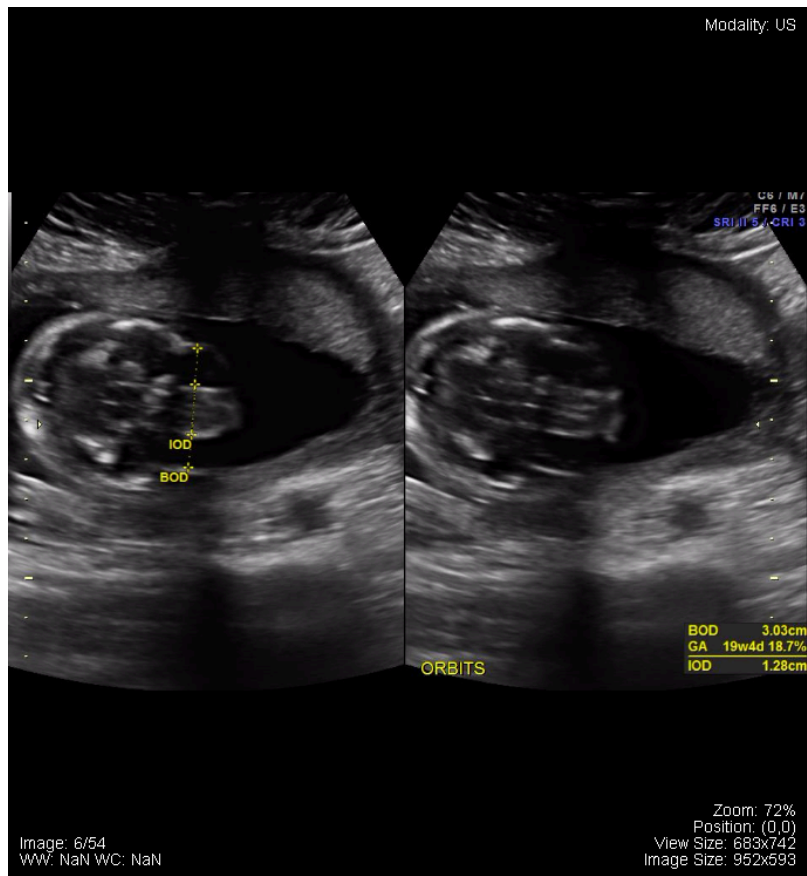
Sagittal Ovary, with measurements

ODIN Link to Images: <https://mistr.usask.ca/odin/?caseID=20170731231759071>

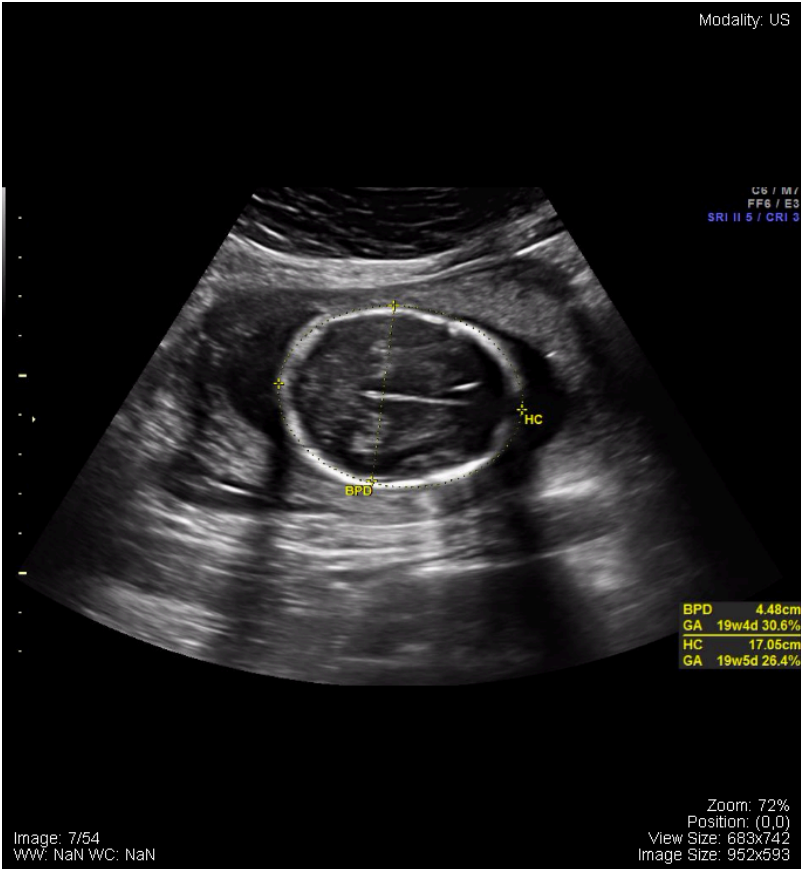
The following are samples from a normal pregnancy ultrasound:



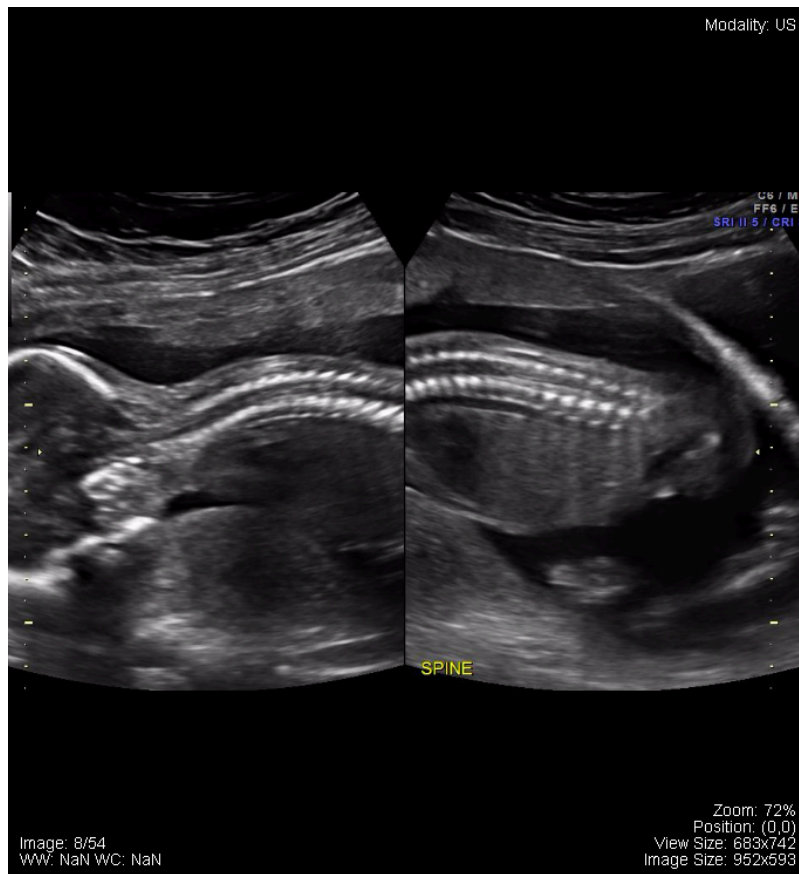
Pregnancy Ultrasound



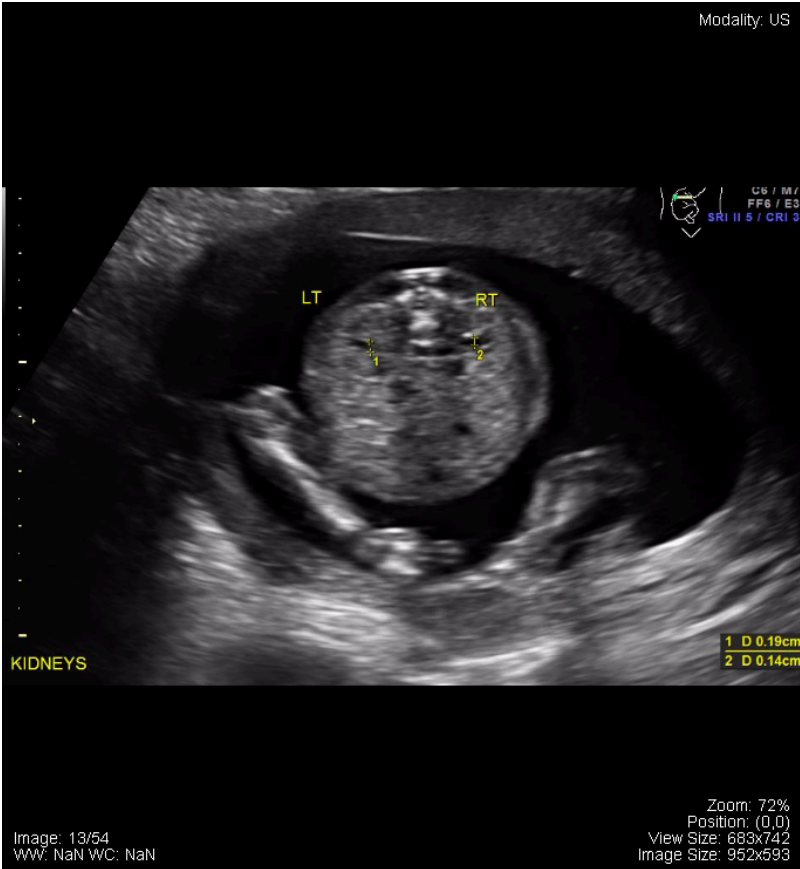
Fetal Orbits with measurements



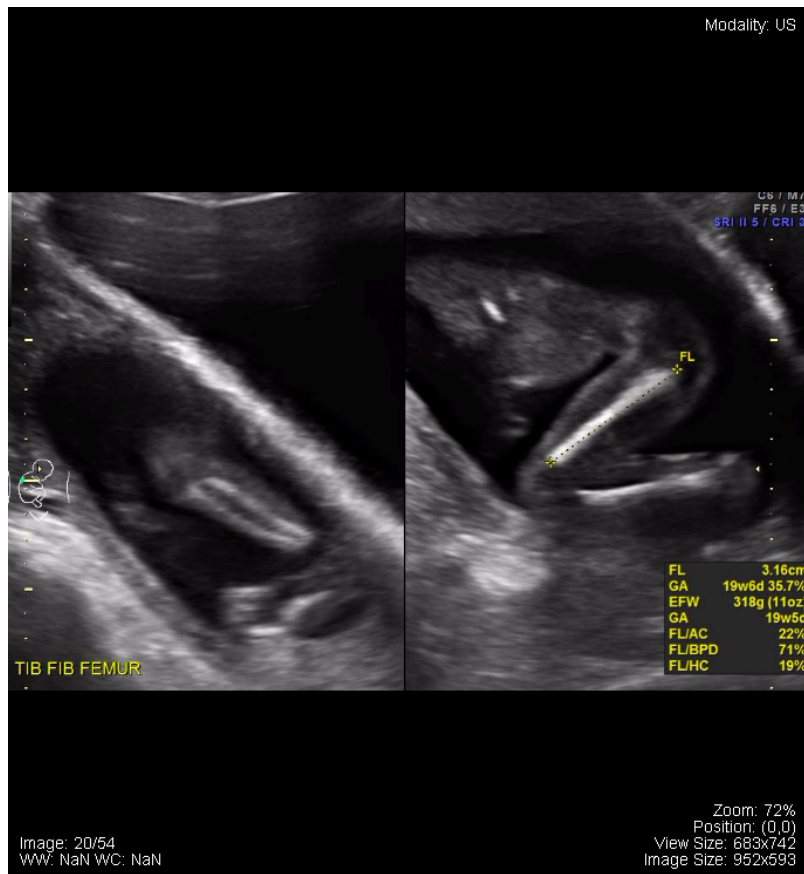
Fetal Head with measurements



Fetal spine with measurements



Fetal Kidneys with measurements



Fetal Legs with femur measurements

ODIN Link to Images: <https://mistr.usask.ca/odin/?caseID=20170126222052150>

Attributions

All figures in “**Chapter 17: Pelvis**” by Dr. Brent Burbridge MD, FRCPC, University Medical Imaging Consultants, College of Medicine, University of Saskatchewan is used under a [CC-BY-NC-SA 4.0](https://creativecommons.org/licenses/by-nc-sa/4.0/) license.

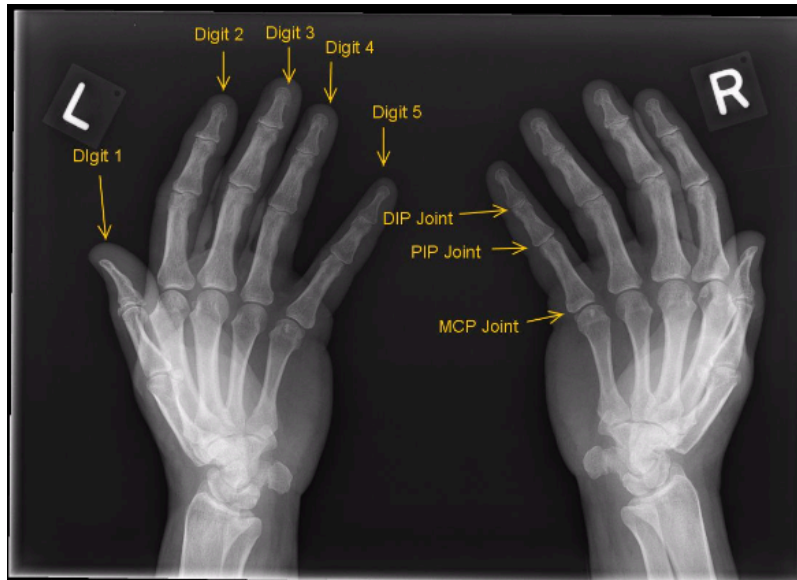
Musculoskeletal

Table of Contents

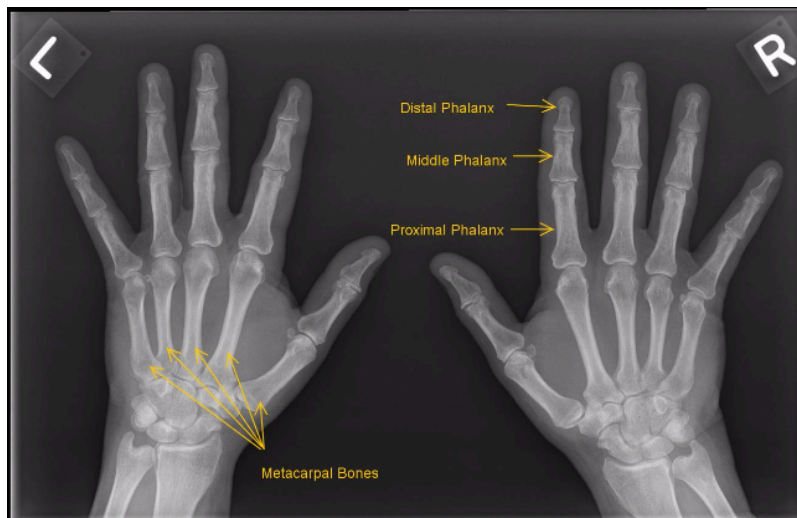
1. Hand
2. Wrist
3. Elbow
4. Shoulder
5. Pelvis
6. Knee
7. Ankle
8. Foot

1. Hand

The following is a normal, labelled, hand x-ray:



Labelled Hand

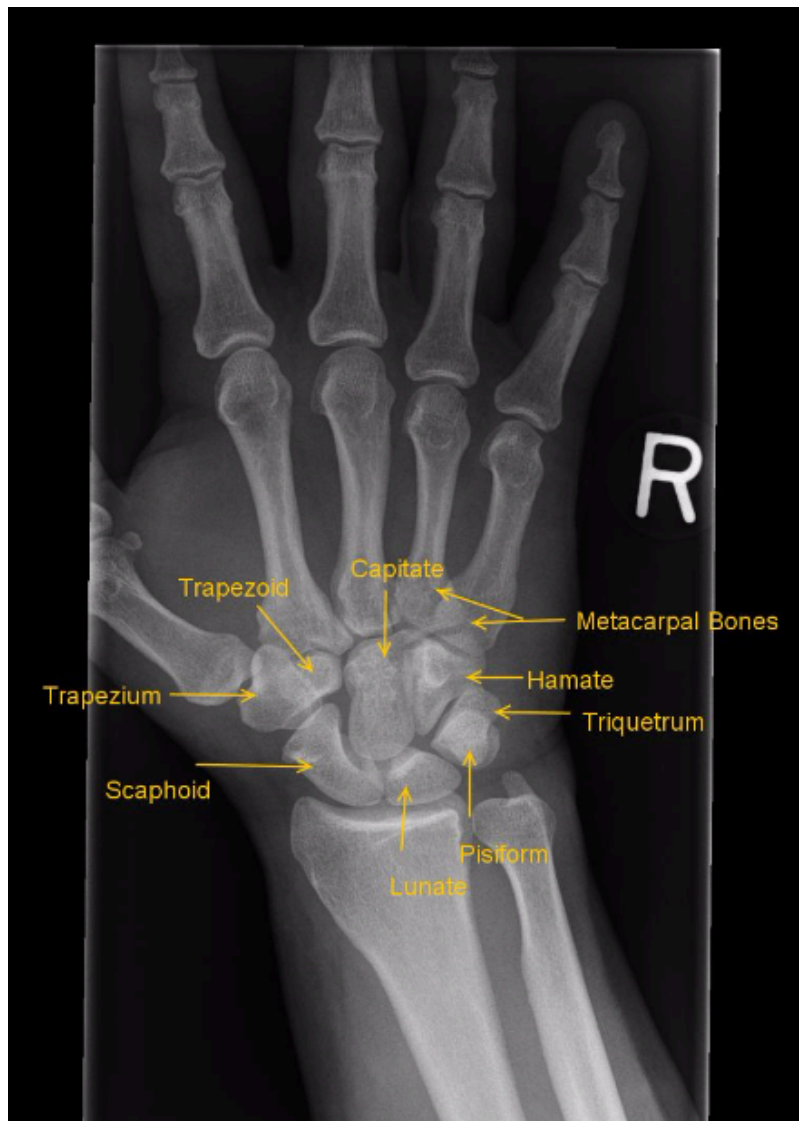

Labelled Hand

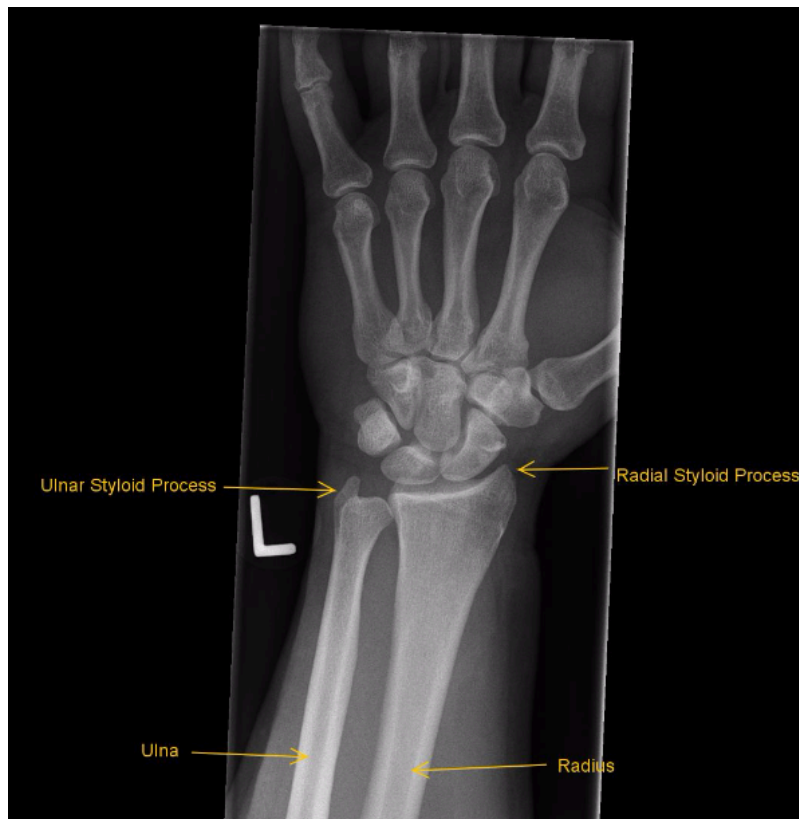ODIN Link to Labelled Images – <https://mistr.usask.ca/odin/?caseID=20110802102214107>

2. Wrist

The following is a normal, labelled, wrist x-ray:



Labelled Wrist

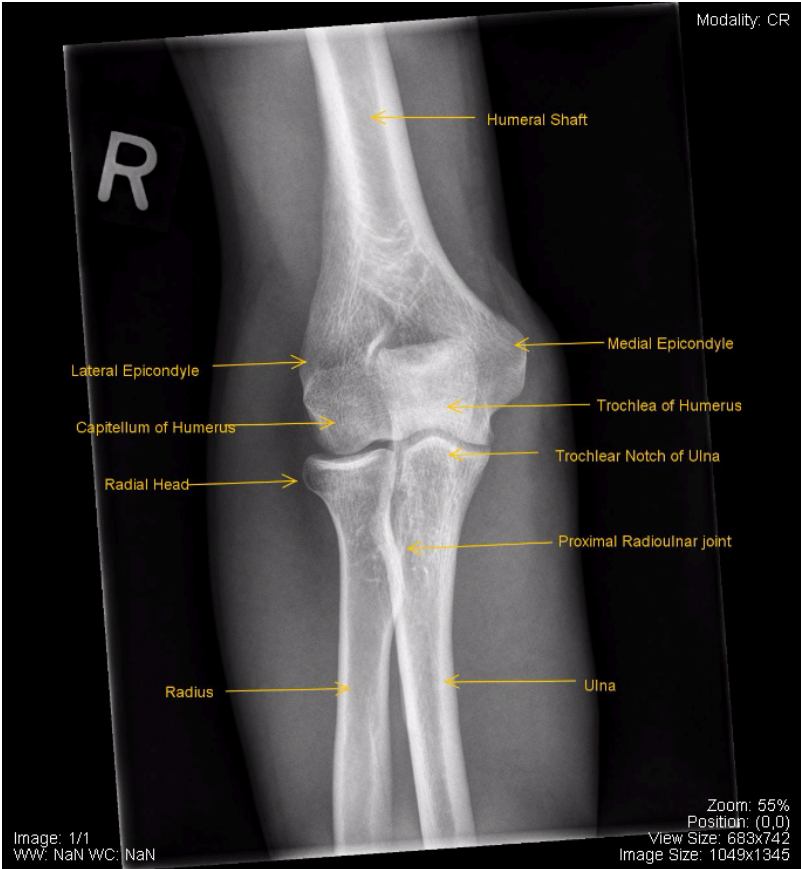


Labelled Wrist

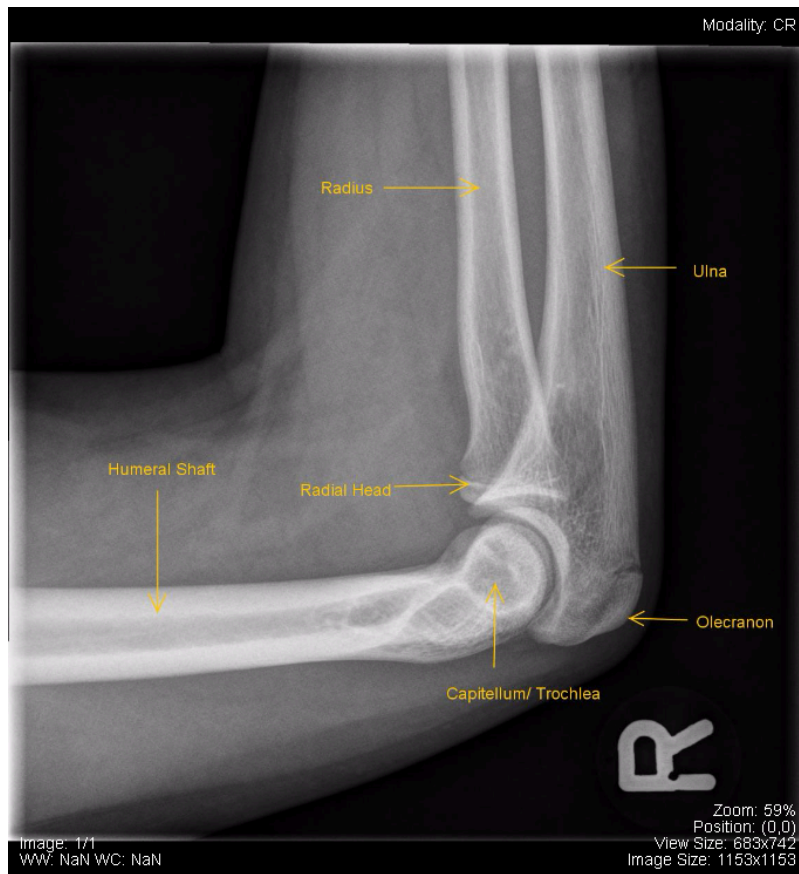
ODIN Link to Labelled Images – <https://mistr.usask.ca/odin/?caseID=20110802102041021>

3. Elbow

The following is a normal, labelled, elbow x-ray:



Labelled Elbow

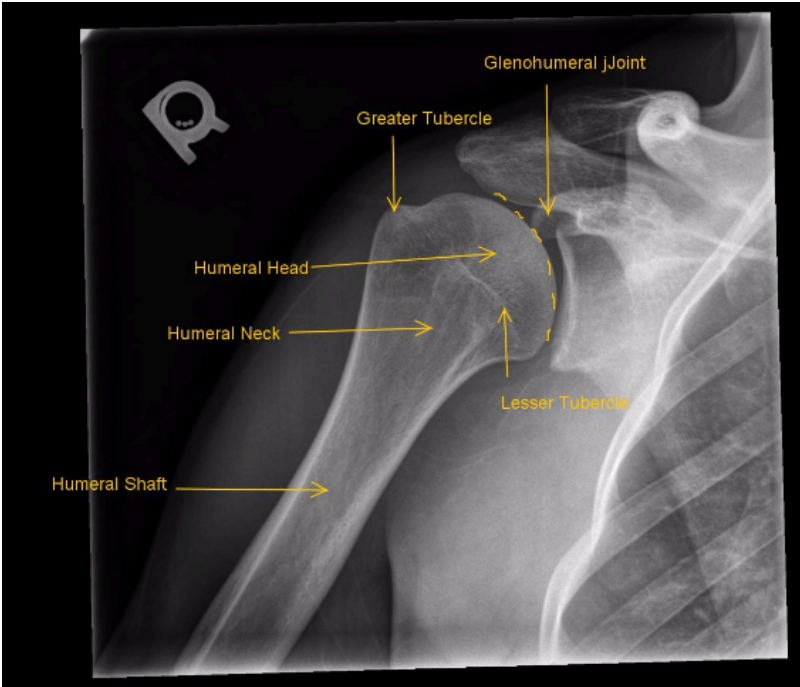


Labelled Elbow

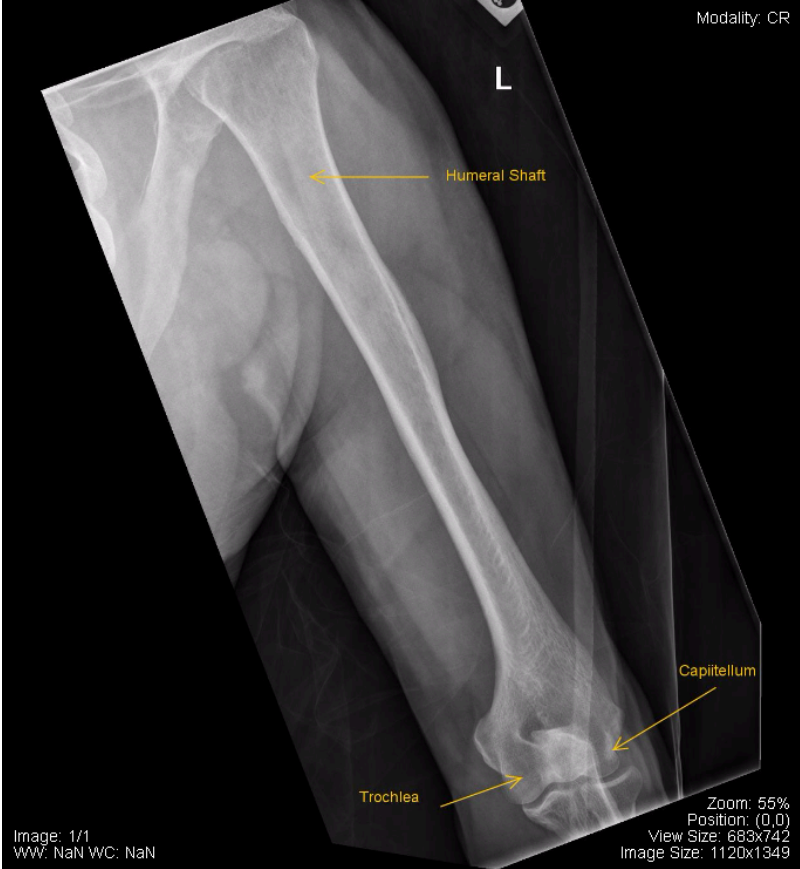
ODIN Link to Labelled Images – <https://mistr.usask.ca/odin/?caseID=20110802101653618>

4. Shoulder

The following is a normal, labelled, shoulder x-ray:



Labelled Shoulder

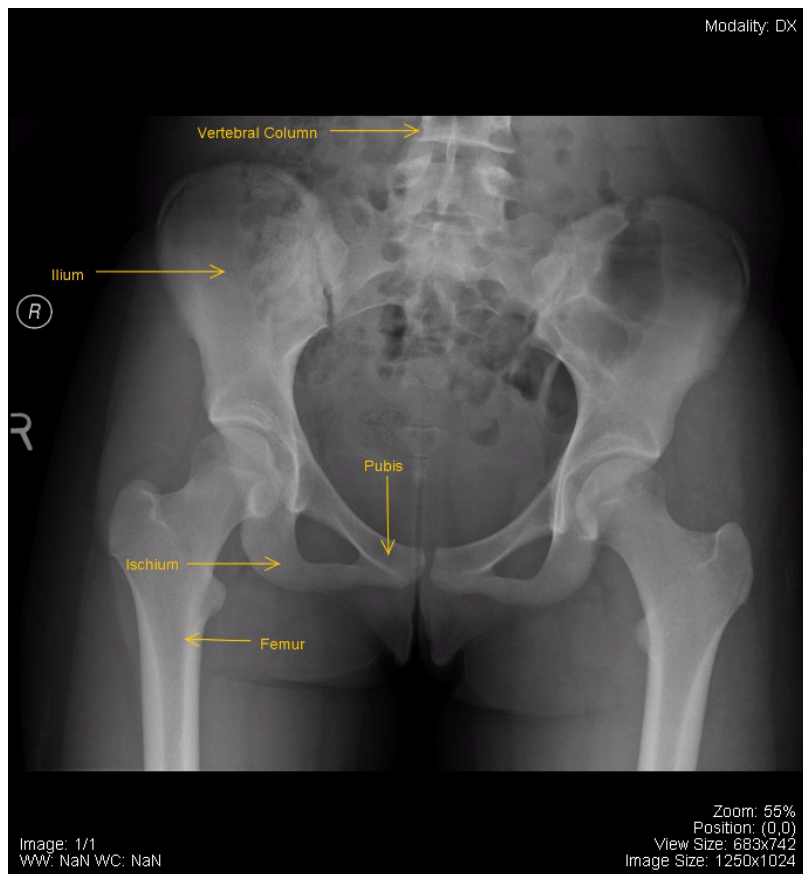


Labelled Shoulder

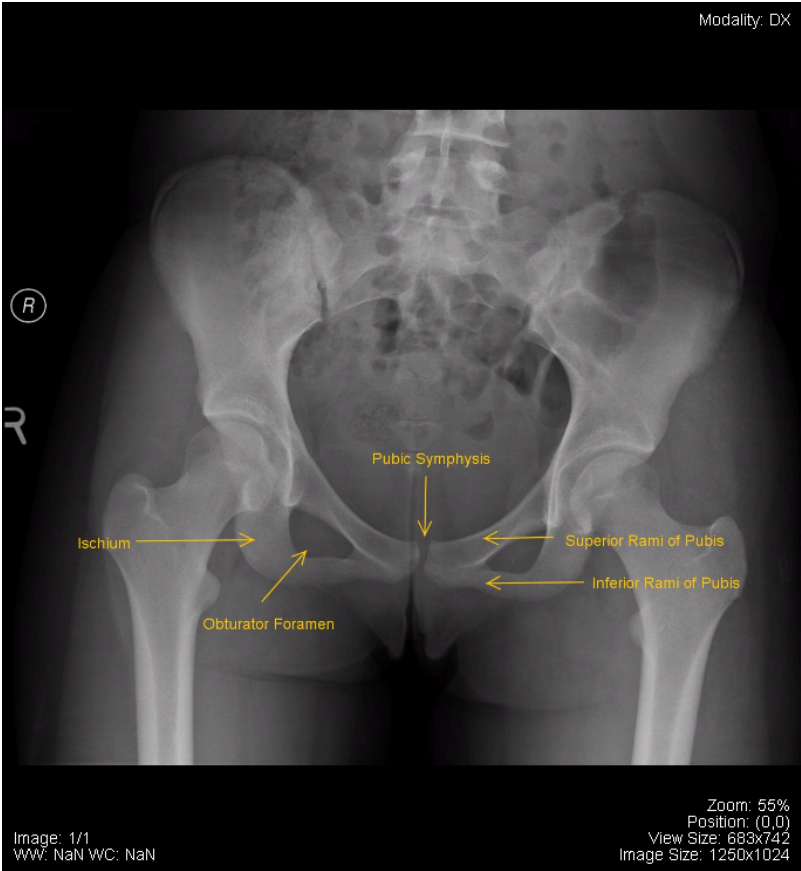
ODIN Link to Labelled Images – <https://mistr.usask.ca/odin/?caseID=20110802100739113>

5. Pelvis

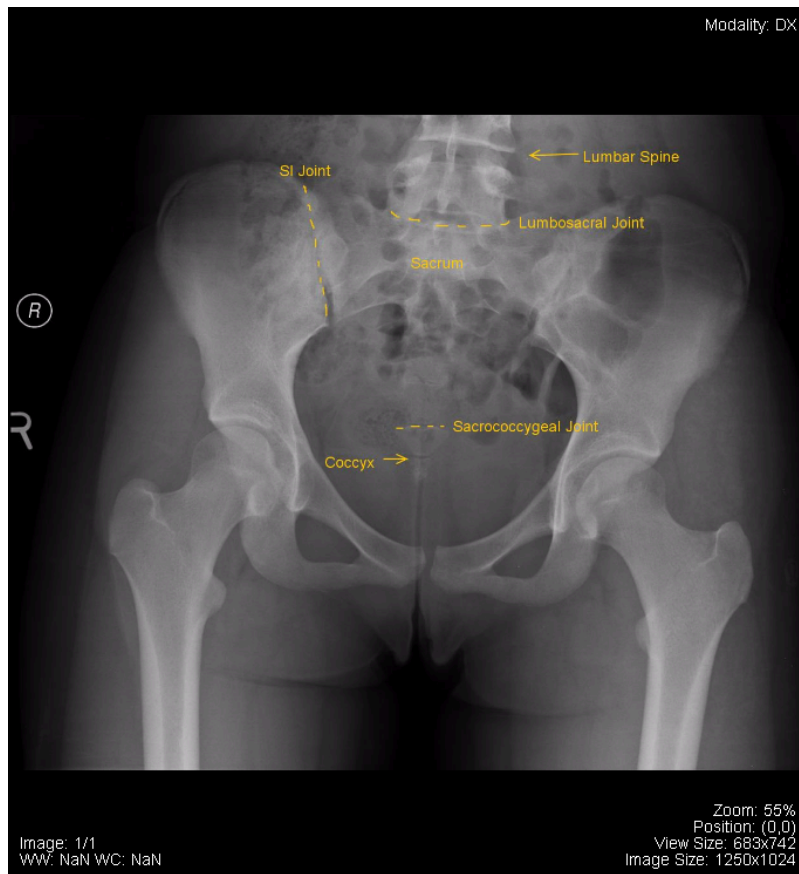
The following is a normal, labelled, pelvis x-ray:



Labelled Pelvis – Major Bones



Labelled Pelvis – Pubic Bones

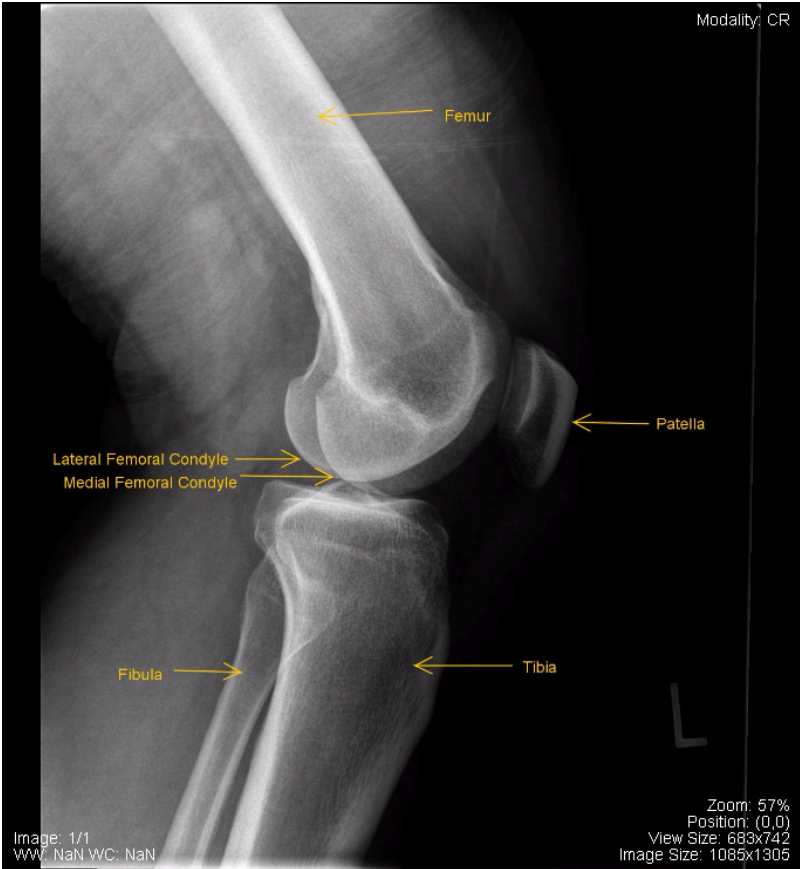

Labelled Pelvis – Major Joints

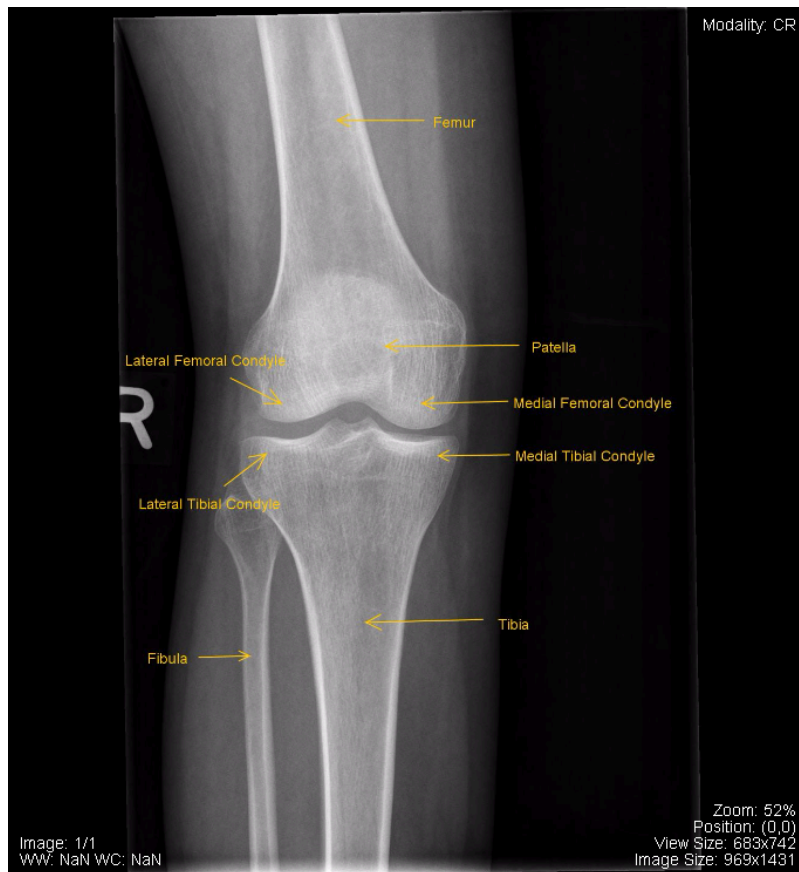ODIN Link to Labelled Images – <https://mistr.usask.ca/odin/?caseID=20110822103233339>

6. Knee

The following is a normal, labelled, knee x-ray:



Labelled Lateral Knee

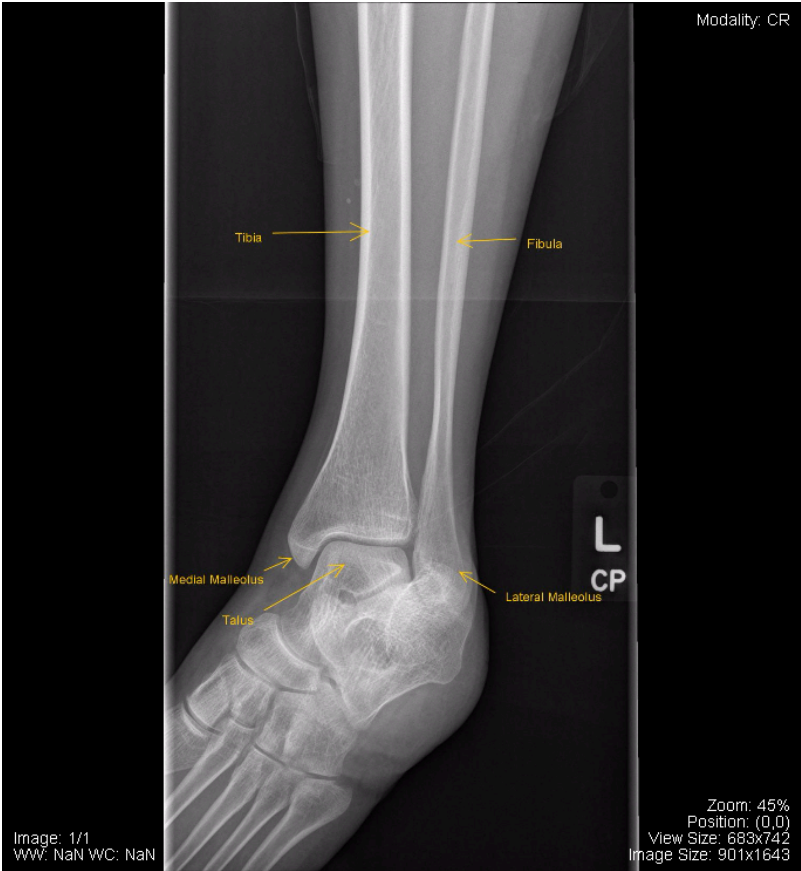


Labelled AP Knee

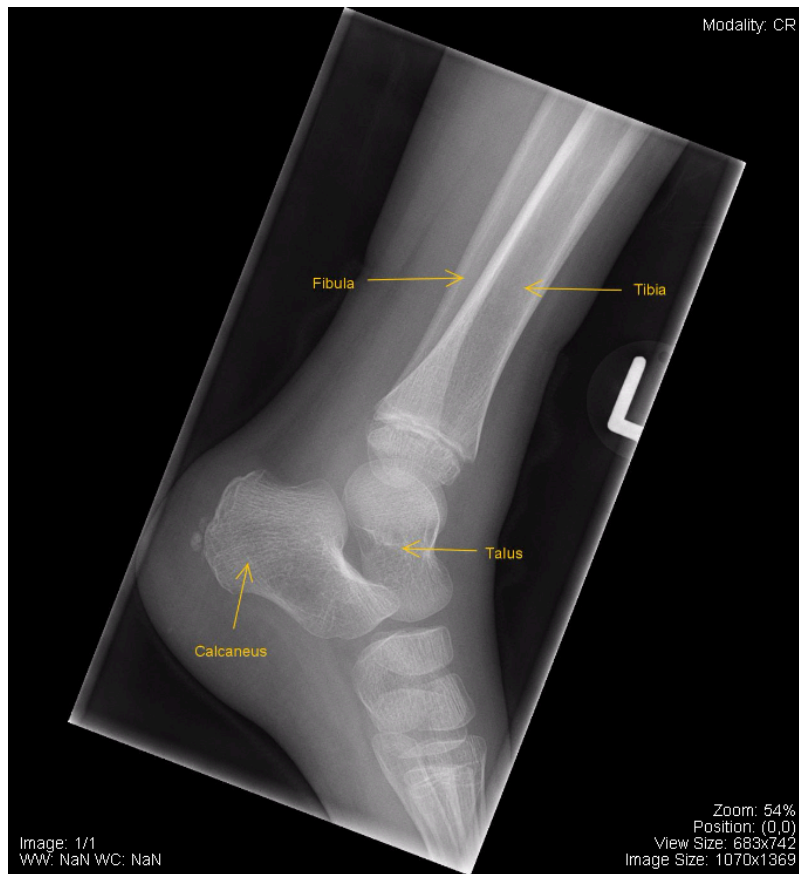ODIN Link to Labelled Images – <https://mistr.usask.ca/odin/?caseID=20110802103332758>

7. Ankle

The following is a normal, labelled, ankle x-ray:



Labelled Ankle

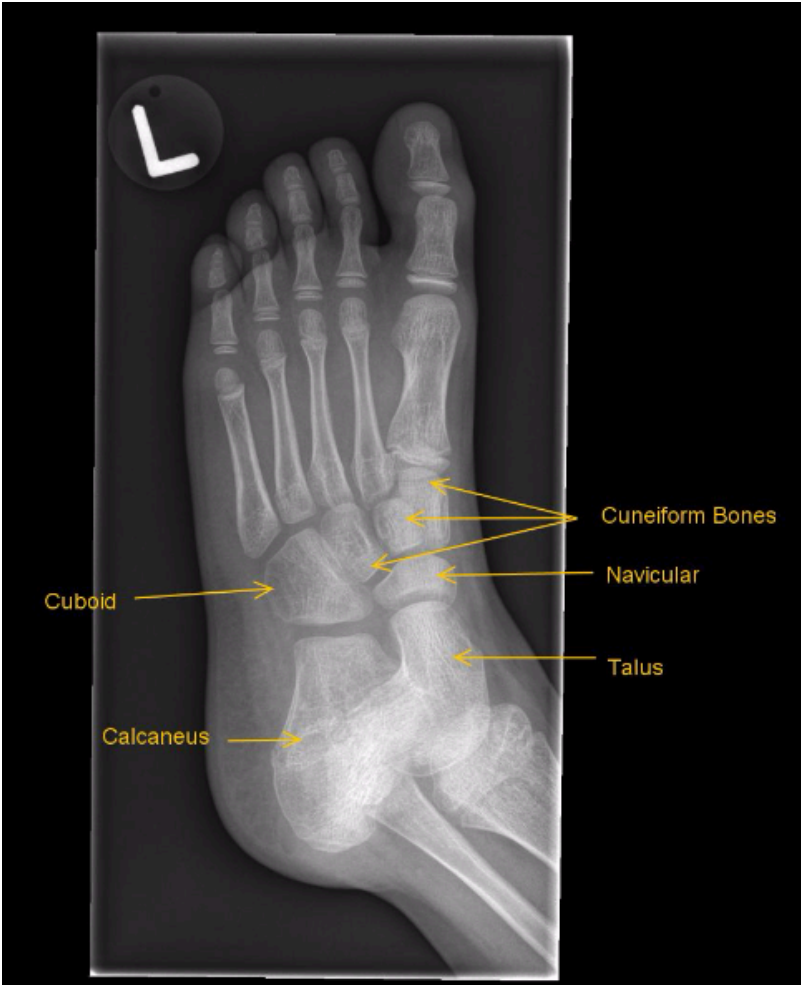

Labelled Lateral Ankle

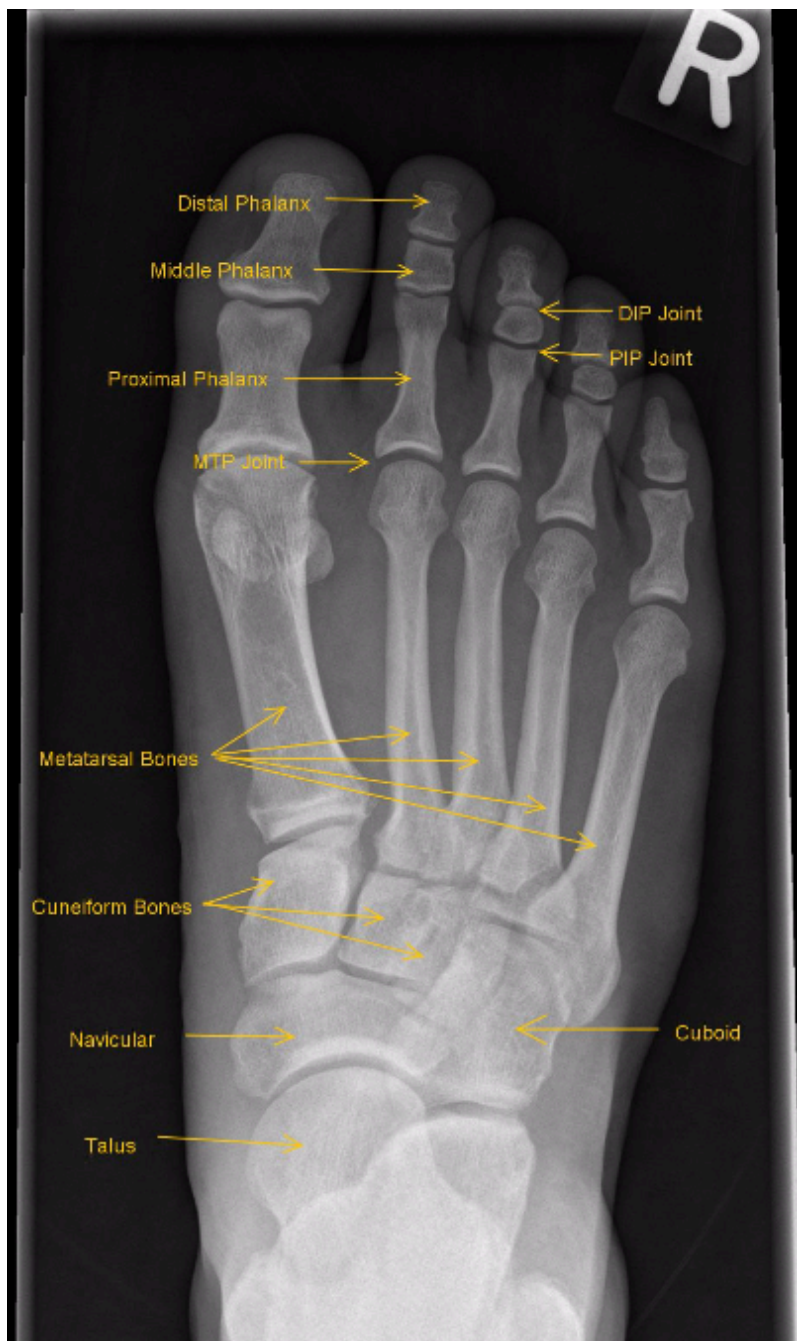ODIN Link to Labelled Images – <https://mistr.usask.ca/odin/?caseID=20110802104923756>

8. Foot

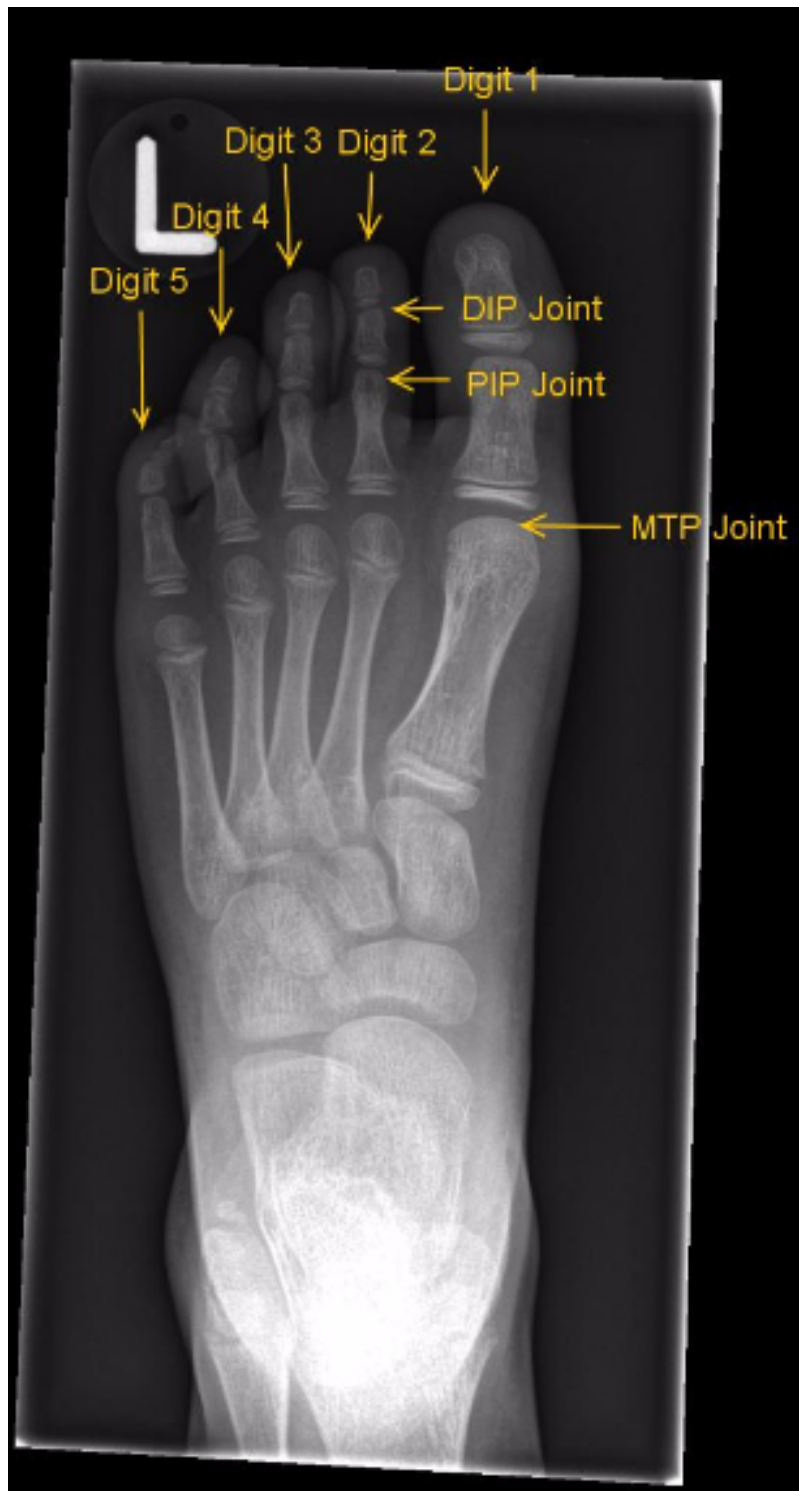
The following is a normal, labelled, foot x-ray:



Labelled Foot



Labelled Foot



Labelled Foot

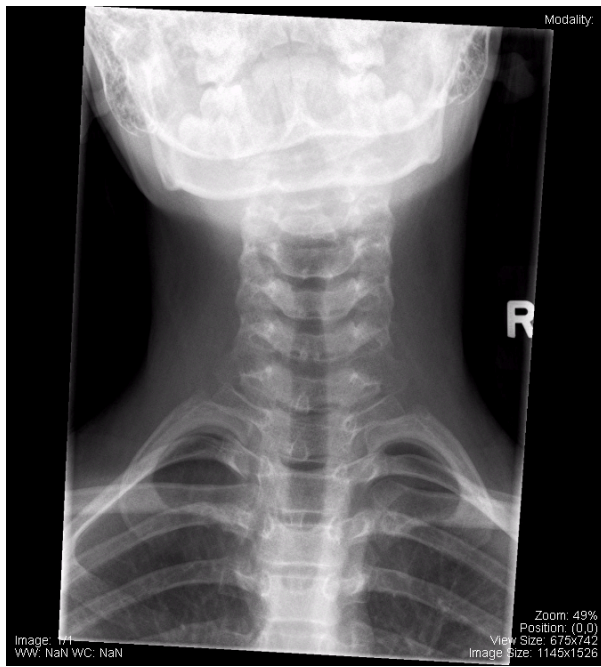ODIN Link to Labelled Images – <https://mistr.usask.ca/odin/?caseID=20110802105108604>

Attributions

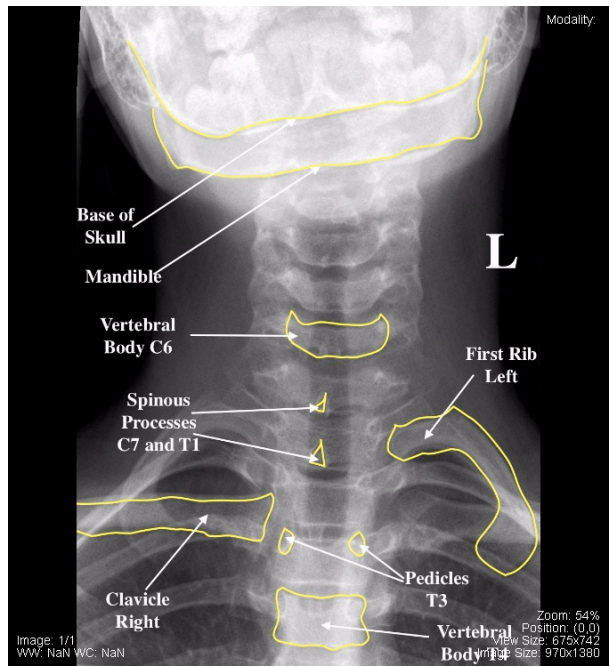
All figures in “**Chapter 17: Musculoskeletal**” by Dr. Brent Burbridge MD, FRCPC, University Medical Imaging Consultants, College of Medicine, University of Saskatchewan are used under a [CC-BY-NC-SA 4.0](https://creativecommons.org/licenses/by-nc-sa/4.0/) license.

Pediatric

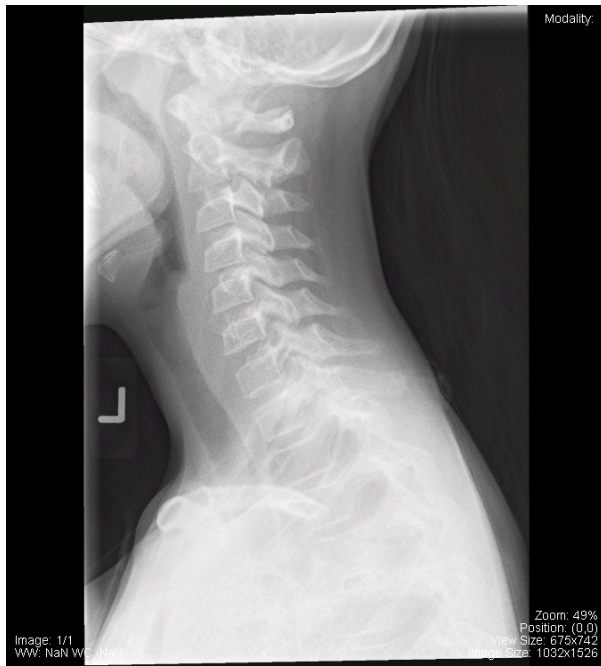The following is a normal pediatric c-spine x-ray:



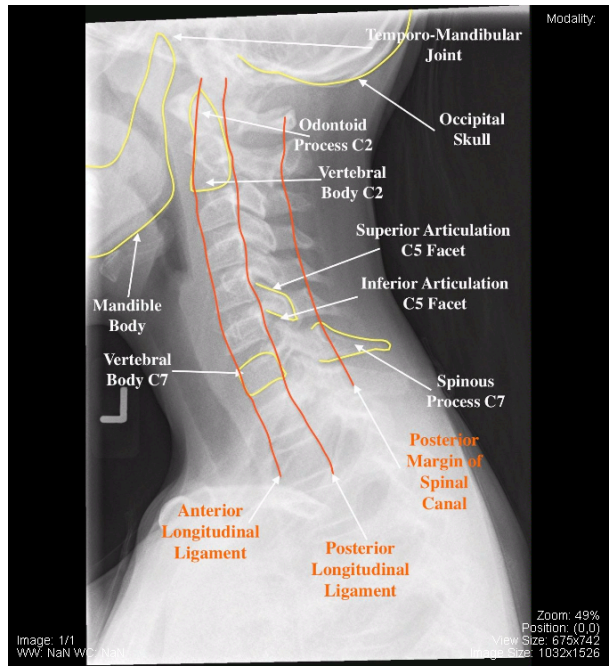
Pediatric PA C Spine



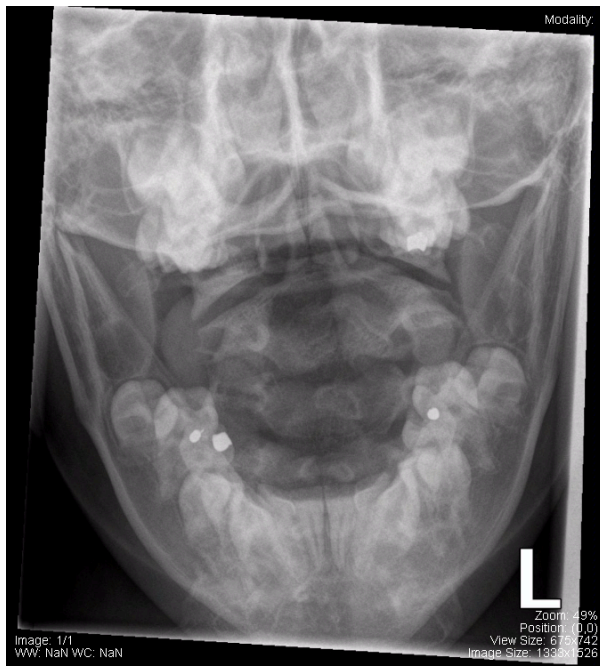Pediatric PA C Spine Labelled



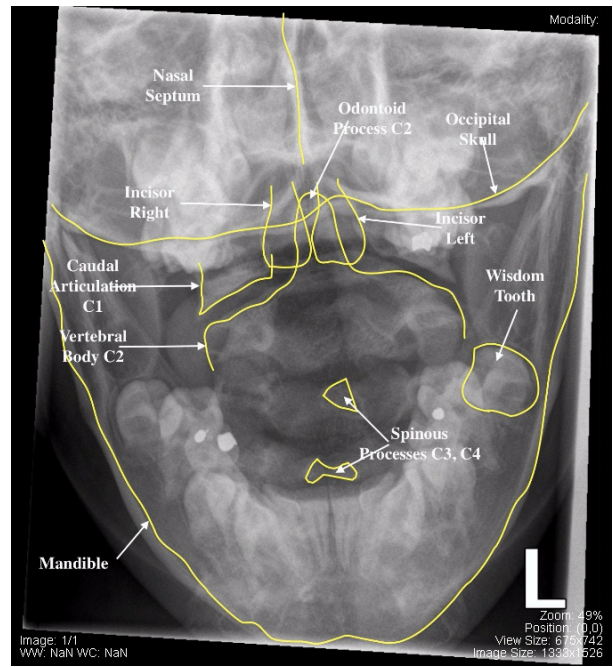
Pediatric Lateral C-Spine



Pediatric Lateral C-Spine Labelled



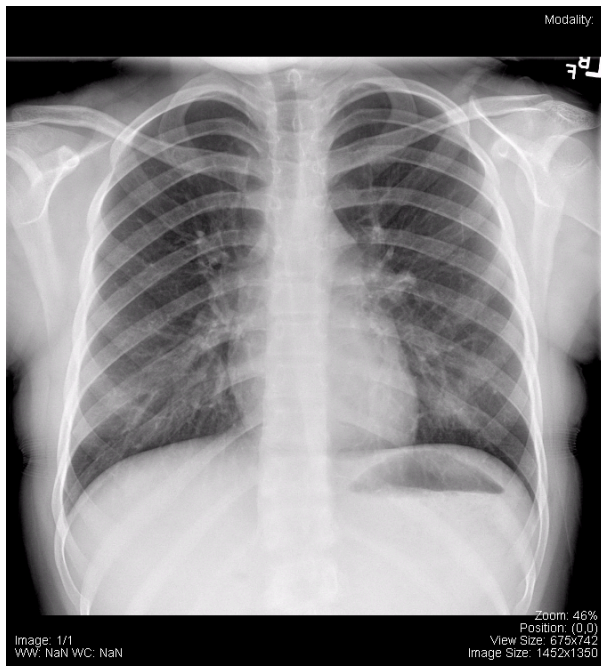
Pediatric AP C-Spine



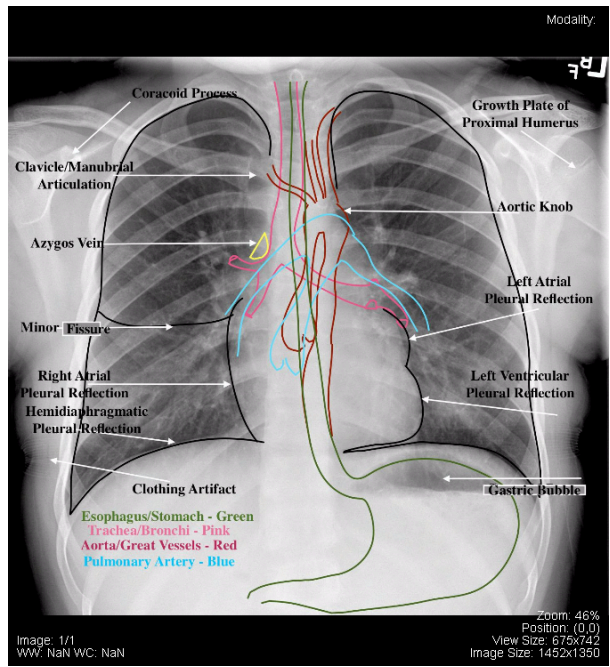
Pediatric Labelled AP C-Spine

ODIN Link to C-Spine Images – <https://mistr.usask.ca/odin/?caseID=20170825145159975>

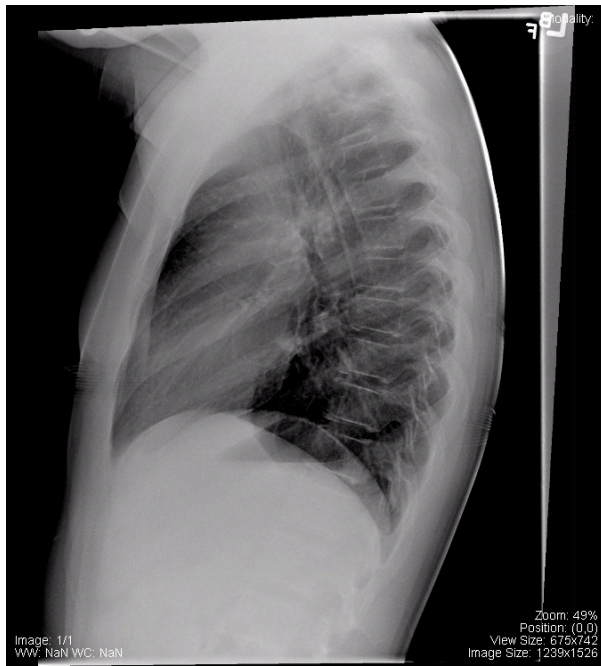
The following are normal pediatric chest x-rays (unlabelled and labelled):



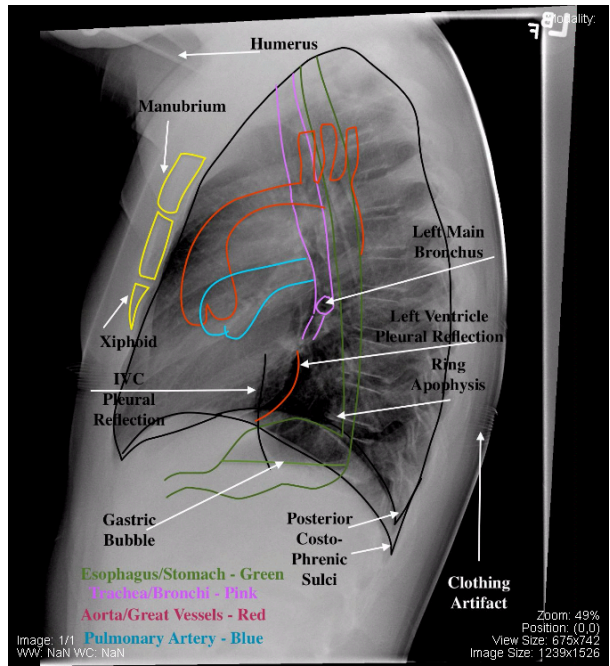
Pediatric PA Chest



Pediatric Labelled PA Chest



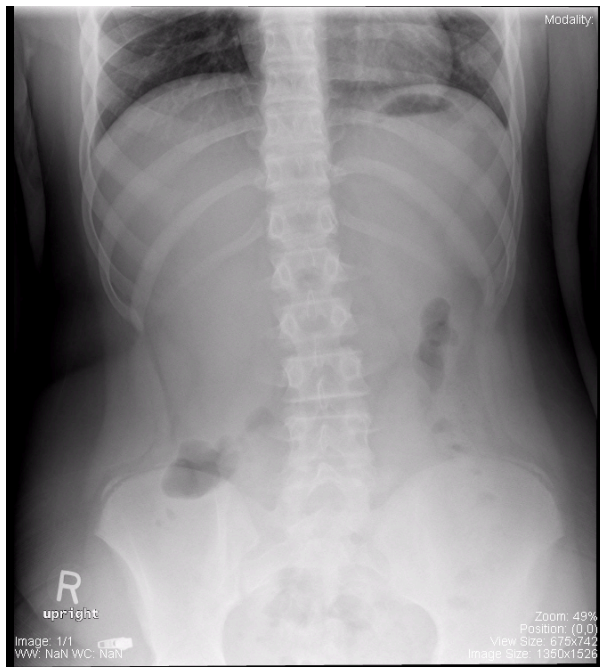
Pediatric Lateral Chest



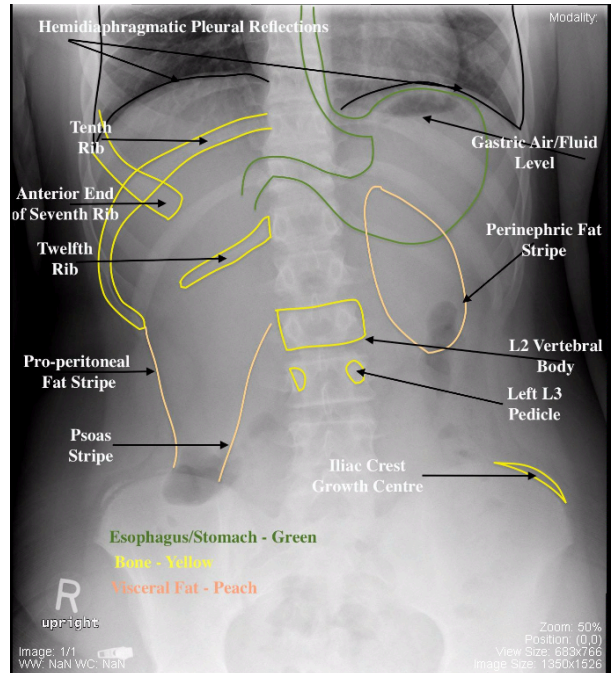
Pediatric Labelled Lateral Chest

ODIN Link to Chest Images – <https://mistr.usask.ca/odin/?caseID=20170825125714420>

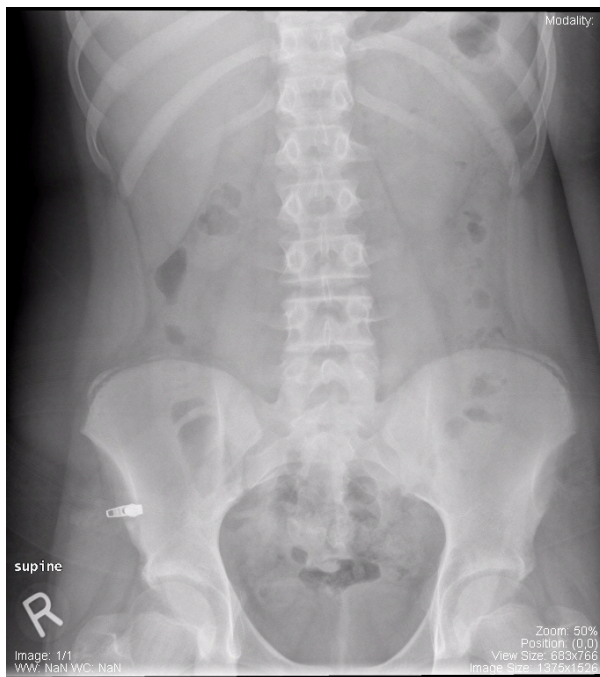The following is a normal pediatric abdominal x-ray:



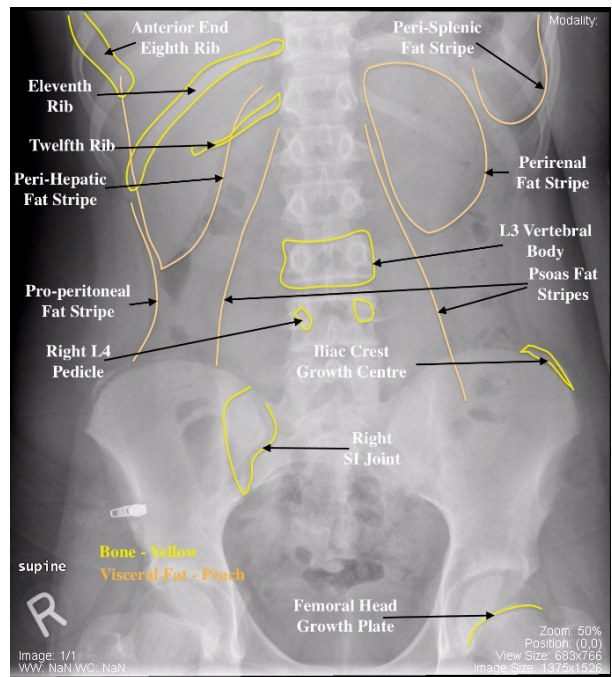
Pediatric Abdomen



Pediatric Labelled Abdomen



Pediatric Abdomen 2



Pediatric Labelled Abdomen 2

ODIN Link to Abdomen Images – <https://mistr.usask.ca/odin/?caseID=20170825130032521>

Attributions

All figures in “**Chapter 17: Pediatric**” by Dr. Brent Burbridge MD, FRCPC, University Medical Imaging Consultants, College of Medicine, University of Saskatchewan are used under a [CC-BY-NC-SA 4.0](https://creativecommons.org/licenses/by-nc-sa/4.0/) license.

Permissions

Royal College of Physicians and Surgeons of Canada – CanMEDS Framework and Diagram

Permission obtained from CanMEDS (canmeds@royalcollege.ca) on May 24, 2017 via email request (Permission #17-412).

The material is to be used for personal, educational, non-commercial purposes only. Written permission from the Royal College is required for all other uses.

No changes may be made to the CanMEDS Diagram without the explicit permission of the Royal College.

Principles of Radiation Biology and Radiation Protection – Canadian Association of Radiologists (CAR)

Permission obtained from CAR (www.car.ca) on September 1, 2017 via email.

Mammogram

Positioning for a Cranial-Caudal (CC) Mammogram by [Sonia](#). Used with Permission. All rights reserved. Can be accessed at <http://lifeloveandhiccups.blogspot.ca/search?q=mammogram>