

Large Animal Surgery

Large Animal Surgery

Erin Malone, DVM, PhD

UNIVERSITY OF MINNESOTA LIBRARIES PUBLISHING
MINNEAPOLIS



Large Animal Surgery by Erin Malone, DVM, PhD is licensed under a [Creative Commons Attribution-NonCommercial 4.0 International License](https://creativecommons.org/licenses/by-nc/4.0/), except where otherwise noted.

Horse doctor giving medicine to a horse, German, 18th century;<https://wellcomecollection.org/works/wb4aqmdf>

Contents

Introduction	1
Finding Resources	3
General Surgery	
Suture material	7
Suture table	11
Suture choice practice	13
Suturing - Instrument holding	15
Suturing - tension relieving suture patterns	19
Suturing - inverting suture patterns	23
Suturing - split thickness and corner stitch	27
Suturing- intradermal/subcuticular pattern	31
Knots - Forwarder and Aberdeen	33
Knots - burying the knot	39
Knots - finishing the Ford Interlocking	43
General pharmacology	
Pharmacology basics	47
Perioperative antibiotics	49
Local anesthesia	51
Drug Concentrations and Recipes	59
Food Animal Drugs	
Food Animal Analgesics	63
Food Animal Antibiotics	67
For Future Reference - Create a drug reference table	71
Exercise 1. Adjusting drug frequency and doses for neonates	73
Food Animal Sedatives and Tranquilizers	75
Food Animal Standing Sedation Protocols	79
Food Animal General Anesthesia Protocols	81
Camelid Sedation and Anesthesia	85
Swine Sedation and Anesthesia	87
Small ruminant sedation and anesthesia	91

FA GI Diagnostics & GI Surgery Principles

<u>Ruminant Pings</u>	97
<u>Abdominal ultrasound</u>	101
<u>How to - Standing GI Surgery</u>	107
<u>How to - Bovine Abdominal Exploratory- Right</u>	117
<u>How to - Bovine Abdominal Exploratory- Left</u>	123

FA GI Topics

<u>Hardware disease</u>	129
<u>How to - Rumenotomy</u>	131
<u>How to - Rumenostomy</u>	139
<u>Abomasal displacement</u>	147
<u>How to - Right flank omentopexy/antropexy</u>	155
<u>Cecal dilatation</u>	167
<u>How to - Typhlotomy</u>	169
<u>Rectal and perirectal disorders</u>	175
<u>Practice</u>	177

Female urogenital surgery

<u>Perineal analgesia</u>	181
<u>Perineal anatomy, trauma and repair</u>	183
<u>How to - Caslick's suture</u>	191
<u>How to - Perineal body reconstruction</u>	195
<u>Urine pooling, perineal body transection and urethral extension</u>	199
<u>How to - Perineal body transection</u>	203
<u>How to - Urethral extension</u>	207
<u>Rectovaginal lacerations</u>	213
<u>How to - 3rd degree rectovaginal tear repair</u>	215
<u>Vaginal prolapses</u>	219
<u>How to - Buhner stitch</u>	227
<u>How to - Minchev pexy</u>	231
<u>How to - Cervicopexy</u>	237
<u>Ovariectomy</u>	241
<u>How to : Colpotomy</u>	243
<u>Teat and udder diagnostics</u>	245
<u>Udder disorders and surgery</u>	249
<u>How to - Surgical Mastectomy</u>	251
<u>Other stuff</u>	253
<u>Practice</u>	255

Food/Fiber Cesarean Sections

<u>Left flank Cesarean section</u>	259
<u>How to - Left Flank Csection</u>	263
<u>Other approaches and species</u>	271
<u>Uterine torsions</u>	275
<u>Pregnant anesthesia animal sedation and anesthesia</u>	279
<u>Exercises - Bovine standing Csection</u>	283

FA male urogenital surgery

<u>Teaser animals</u>	287
<u>How to - Epididymectomy</u>	291
<u>How to - Vasectomy</u>	299
<u>How to - Unilateral castration</u>	305
<u>Preputial issues</u>	309
<u>Practice</u>	311

Urogenital wounds

<u>Teat trauma</u>	315
<u>Teat laceration repair</u>	317
<u>Preputial wounds</u>	319
<u>Preputial surgery</u>	321
<u>Penile injury</u>	323

Bladder, Urethra and Umbilicus

<u>Umbilical hernias</u>	327
<u>Exercise 1</u>	333
<u>Umbilical infections</u>	335
<u>Exercise 2</u>	341
<u>Patent urachus</u>	343
<u>Ruminant urolithiasis</u>	345
<u>How to - Tube cystotomy</u>	353
<u>Ruptured bladders</u>	361
<u>Ruptured urethras</u>	367
<u>Exercise 3</u>	369
<u>Exercise 4</u>	371
<u>Equine hematuria</u>	373
<u>Equine urolithiasis</u>	375
<u>Exercise 5</u>	379

[FA youngstock processing](#)

Bovine castration	383
Small ruminant castration	391
Piglet castration	393
How to - Open castration	397
FA Inguinal Hernias	401
FA cryptorchidism	405
Disbudding and dehorning	407
Tail docks	413
How to - Tail Dock - Adult	415
Challenge yourself!	417

[Eye surgery](#)

Ocular blocks	421
Enucleations	425
How to - Exenteration	429
Eyelid lacerations	437
Entropion	441
Eyelid mass removal	443
Practice	445

[LA Respiratory Issues](#)

Anatomy Review - Nasal Discharge	449
Nostrils and nasal conchae	451
Paranasal sinus disease	453
Pharyngeal disorders	457
Guttural pouch disorders	459
Laryngeal disorders	465
Tracheal disorders	467
Pleural space disorders	469
Diagnostics	471
Exercise 1	473
Exercise 2	475
Exercise 3	477
Dental disorders supplement	479
How to - Temporary tracheotomy	481
Exercise 4	487
Upper respiratory endoscopy supplement	489
Exercise 5	491

Exercise 6	495
Exercise 7	499
Exercise 8	501
 Bovine Lameness	
 Bovine Lameness	
Bovine Lameness	505
Bovine Foot Conditions	509
Joint issues	517
Tendon and ligament issues	519
Neuromuscular conditions	521
Calving injuries	523
Adult fractures and luxations	525
Calf injuries	527
 Food Animal Drug Regulations	
 Regulatory Concerns	
Regulatory Concerns	531
Navigating FARAD	533
Exercise 1 Finding approved drugs	535
Exercise 2 AMDUCA	537
Exercise 3 Illegal and restricted use drugs	539
Exercise 4 Identifying withholding times	543
Exercise 5 MUMS Act	547
Exercise 6 Extrapolating withholding data	549
Exercise 7 Understanding half lives	551
Challenge yourself!	553
FA Drug Regulation Summary	555
 Large animal masses	
 Differentials and diagnostics	
Differentials and diagnostics	559
Cysts	561
Granulomas	563
Hematomas	565
Hernias	567
Abscesses	569
Abscesses related to systemic infections	573
Resources	575

Large Animal Cutaneous Neoplasia

<u>Diagnostics</u>	579
<u>Sarcoids</u>	581
<u>Squamous cell carcinoma</u>	583
<u>Melanomas</u>	585
<u>Lymphosarcoma</u>	587
<u>Papillomatosis aka warts</u>	589
<u>Field treatment options</u>	591
<u>Resources</u>	593
<u>Practice</u>	595

Equine Castration

<u>Castration planning</u>	599
<u>Field anesthesia for equine castration</u>	603
<u>Recumbent equine castration</u>	609
<u>Standing equine castration</u>	613
<u>Postoperative care for equine castration</u>	615
<u>Donkey castration</u>	619
<u>Cryptorchidism</u>	621
<u>Inguinal hernias</u>	623
<u>Castration complications</u>	625
<u>Castration Summary Points</u>	629
<u>Challenge yourself!</u>	631
<u>For Future Reference I Castration planning</u>	633
<u>For Future Reference Field Anesthesia</u>	635
<u>For Future Reference I Postcastration Instructions</u>	637

Equine wounds

<u>Evaluation</u>	641
<u>Acute wound management</u>	649
<u>Chronic wound management</u>	653
<u>Managing complications</u>	655
<u>The swollen limb</u>	657

Equine Drugs

<u>Equine Analgesics</u>	661
<u>Exercises</u>	665
<u>Equine Antibiotics</u>	667

Equine Sedatives and Tranquilizers	671
Equine Standing Sedation Protocols	675
Equine General Anesthesia Protocols	677
Equine (and LA) Colic	
Anatomy review in video	683
Physiology review	687
Diagnostics	689
Small intestinal lesions	693
Cecal lesions	695
Large colon lesions	699
Small colon lesions	701
Field colics	703
Referral colics	707
Preventing colic	711
Colic Pathophysiology	713
Impactions - stomach and small intestine	717
Impactions - Cecal, colon and small colon	721
Gas colics and Displacements	729
Torsions and entrapments (hernias)	733
Inflammation related colics	741
Infarctions and intussusceptions	745
Motility disorders	749
Neonatal colics	753
Perirectal and rectal disorders	755
Practice	757
Camelid castration	
Field anesthesia for camelid castration	761
Camelid Castration	763
Equine GI Topics	
Therapeutics	767
Equine Lameness	
Lameness diagnosis	771
Lameness examination form	773
Biomechanics for lameness evaluation	777

Distal limb bones review	779
Palpation anatomy- forelimb	783
Palpation anatomy- hindlimb	787
Lameness skills self assessment	791
Forelimb nerve anatomy	793
Nerve and joint blocks	795
Nerve block challenge questions	797
Nerve block challenge answers	799
Special gaits	801
Practice	803
Joint Disorders	
Osteochondrosis	807
Osteoarthritis	809
Physeal disorders	811
Hock joint problems	815
Carpal joint problems	819
Joint therapy	821
Practice	823
Tendons and ligaments	
Tendon and ligament anatomy	827
Flexural limb deformities	831
Flexural deformity pathogenesis	835
Tendonitis and bowed tendons	837
Reciprocal apparatus	839
Practice	841
The foot	
Foot anatomy	845
Foot anatomy and imaging	849
Subsolar (hoof) abscesses	853
Solar bruising	857
Thrush	859
Laminitis	863
Other foot conditions	865
Navicular syndrome	867
Navicular syndrome cases	875
Whiskey	877

Li'l Bit	879
Apollo	881
Red	883
Buttons	885
Practice	887
Swine and poultry lameness	
Poultry	891
Equine female urogenital surgery	
Equine male urogenital surgery	
Penile and preputial neoplasia	897
LA Orthopedic Emergencies	
Arterial damage	903
Tendon and ligament lacerations	905
Limb fractures	907
Lacerations involving synovial structures	909
Practice	911
Limb changes	
Swollen limb	915

Introduction

Half of what you'll learn in [medical] school will be shown to be either wrong or out of date within five years of graduation; the trouble is that nobody can tell you which half, so the important thing to learn is how to learn on your own." –David L Sackett

Being a competent veterinarian isn't easy. You are licensed to handle many different species and issues, some of the latter won't even exist during the time you are in veterinary school. Some conditions and situations you will only encounter after graduation. You may switch career paths and see species you never intended to see. Many times the answers aren't in the book or the book is outdated. Dr. Google provides many "answers", not all of which are helpful. Hopefully this resource will give you a starting place to understand the common conditions encountered by veterinarians working on large animal species and the exercises will help you expand your capabilities for sorting through the myriad "answers" out there. Your wonderful brains can help you put them together. It just needs practice.

This resource is not intended to read cover to cover. When you have a question, check the table of contents on the right of each page and head to that section! Save the cover to cover reading for something more fun.

Comments and/or suggestions? [Please fill out this survey!](#)

Finding Resources

One of the biggest challenges in the digital age is sorting out answers you can find online. Over time, each of us develops our “go to” resources for things at two levels:

- basic information for new or unfamiliar topics
- advanced, detailed or updated information for more familiar topics

These are rarely the same.

For starter explanations, try these:

- [Wikipedia](#)– useful for physiology, unknown terms and other more general knowledge questions
- [Vetfolio](#) – has been free for students; great summaries of topics and conditions
- [Merck Veterinary Manual](#) online- good for pathogenesis and presentation; not as good for therapies
- Vet Clinics of North America [Equine, Food Animal, and Exotics](#)– see the search function at the top left. Does require a subscription. Available through many University libraries. Peer-reviewed summaries of topics.
- [VIN](#) – abstracts are posted in related feeds. Free for students and contains a variety of other resources (3D anatomy, drug calculators, financial aid info). The help from the boards is variable; sometimes excellent, sometimes dangerous.
- Specialty sites with info for animal owners (many are free for students): [ACVS.org](#), [ACVIM.org](#), [AAEP.org](#), [AASRP.org](#), [AABP.org](#), [AASV.org](#), sites with .gov or .edu
- Plumb’s Veterinary Drug Handbook and app (lots of versions out there in different formats and prices)
- [SCOVE Edu+](#) – online source of online resources

For more detailed explanations or comparison of therapies, diagnostic tools etc:

- [Google scholar](#)– look for the ones with a pdf. You can sort by year, type of article etc using the left hand bar
- [Veterinary medical library](#) Pub Med and other databases; [video how to](#) for UMN system; or go visit the librarian in person
- [UMN library search](#)– For articles and books. Great for specific articles you are trying to access or specific topics, particularly if not likely to be in pubmed.
- [Ivis](#) – international veterinary information service – is a great place to find specific meeting proceedings
- [Extreme googling](#)

4 Large Animal Surgery

- Surgery textbooks- great for how to perform surgery and the perioperative care required
- Revisit sites above

Unless it is fiction or for fun, don't read every word.

- Textbooks – read the chapter summary and/or skim the headings; then read the applicable sections.
- Journal articles – start with the abstract and/or introduction, follow with the last paragraph, finish with any middle bits that are useful
- Online materials – start with Ctrl-F if you have a specific question; otherwise go with the section headings and introductory sections as above.

General Surgery

Suture material

Choosing suture material can seem overwhelming at first. There are a myriad of suture types out there, all with different needles and packaging. However, most times, our choices are more limited.

Suture related factors

Absorbable or not absorbable

Suture material such as polyglactin 910 (Vicryl) is absorbable. Nylon is not absorbable.

Absorbable suture materials are hydrolyzed by the body and dissolve over time. Absorbable suture is typically preferred when the sutures won't be removed (eg inner layers of the skin or body). The body typically reacts to suture, seeing it as a foreign body. The problem is resolved as the suture is dissolved.

Nonabsorbable suture material is used externally (skin) and when maintained strength or security is essential (eg tendon replacement). Most of these are fairly inert so the foreign body reaction is minimal.

Monofilament or braided

Monofilament sutures are single stranded. Such suture material tends to glide through tissue better than multifilament suture. However, many of these are more likely to fatigue and break. Braided suture is stronger but tends to wick fluids. This can lead to infections when braided suture is used in contaminated environments.

Chromic gut is extruded. It is multifilament but not braided. However, the filaments are easily damaged and lead to a rough surface that can potentiate infection similar to braided suture material. For this reason, surgeon's knots are not recommended when working with chromic gut.

Duration and strength of duration

The suture needs to last long enough but not too long. Nonabsorbable suture materials last at least 6 months. Other suture materials vary in duration of relevant strength. In some instances, this is confounded by the environment. Eg Dexon dissolves rapidly in urine, monocril in milk and many suture types in pus or infected fluids.

Reactivity

Some suture is minimally reactive (stainless steel) while other suture is highly reactive (Vetafil). In many instances, one or the other is preferred. If we would like to create an adhesion quickly, reactive material is typically good.

8 Large Animal Surgery

Size availability

Not all suture is manufactured in all sizes. Suture sizes range from 9-0 and smaller (ophthalmological, vascular surgery, etc) to 5 Vetafil (cow hide). Veterinary suture typically ranges from 4-0 to 3 in general practice. Only polyglactin 910 (Vicryl) currently comes in size 3.

Packaging

Suture on reels can be cut to a desired length but is sometimes only cold sterilized and may not be acceptable for all situations. Most other suture is packaged in smaller lengths. The suture may also be swedged onto a needle or be needle-less. The type of needle attached can also vary widely. Typically cutting needles are needed for skin and tough tissue; taper needles are safer for delicate tissues. Finding the right suture in the right length with the right needle on it can be challenging.

Price

Particularly due to the type of needle attached (and if a needle is attached), price can vary between manufacturers and suture sizes.

Surgeon preference

This category is typically called knot security or ease of use, but really each of us likes different suture material. If you are comfortable with a suture material, you use it more often and adjust to its quirks. Change is hard.



The suture packet will include many of the factors listed here

Patient related factors

External or internal

Is the suturing taking place in the skin or elsewhere? Will it need to stay permanently?

Duration of healing

How long will it take the tissue to heal? How long does the suture need to maintain strength?

Forces on the tissue (strength)

How much force is typically on the tissue? How strong does the suture need to be?

Risk of infection

Is the procedure clean, contaminated, or dirty? Is wicking an issue?

Needle and suture length

What are the needs of the procedure? How big/small a needle is desired to get through the tissue? How delicate is the tissue? How long a section of suture is required?

Other factors

Are there other factors that will alter healing or suture function? Is it in the bladder, the teat or the tendon? Is milk, urine or pus potentially in contact with the suture? Are adhesions desired or something to be avoided?

Suture table

Create a table for future reference, comparing the suture types in the clinic (UMN or other site)

Suture material	Absorbable?	Mono or multifilament?	Strength/duration	Knots/ease of use	Size available	Cost for 2-0 with needle	Reactivity	Misc/comments

Suture choice practice



An interactive or media element has been excluded from this version of the text. You can view it online here:
<https://open.lib.umn.edu/largeanimalsurgery/?p=2902>



An interactive or media element has been excluded from this version of the text. You can view it online here:
<https://open.lib.umn.edu/largeanimalsurgery/?p=2902>



An interactive or media element has been excluded from this version of the text. You can view it online here:
<https://open.lib.umn.edu/largeanimalsurgery/?p=2902>



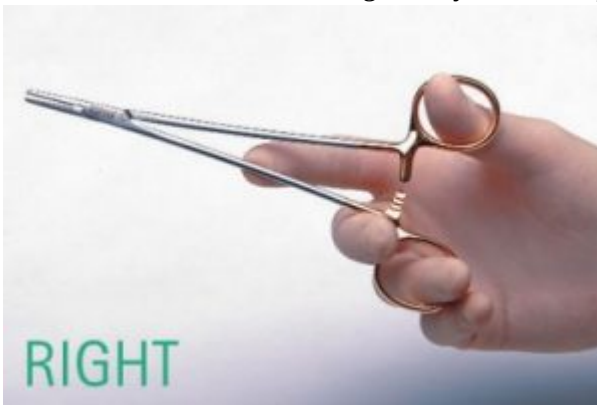An interactive or media element has been excluded from this version of the text. You can view it online here:
<https://open.lib.umn.edu/largeanimalsurgery/?p=2902>

Suturing - Instrument holding

Key principles

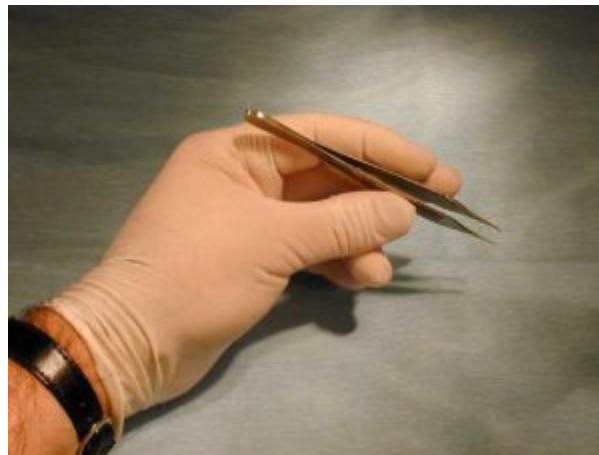Maintain a light grip on the needle holders

- Thumb and ring finger, first knuckle only
- Not a death grip!
- Advanced: no thumb in the ring – use your thumb pad to open and close the ratchet



Thumb forceps held like tweezers or a pencil

- No overhand grips
- Advanced: don't set them down



Rotate arm and wrist to move the needle

- Avoid pushing the needle through with a straight force


16 Large Animal Surgery

- If your needle is straightening on you, you aren't rotating your arm



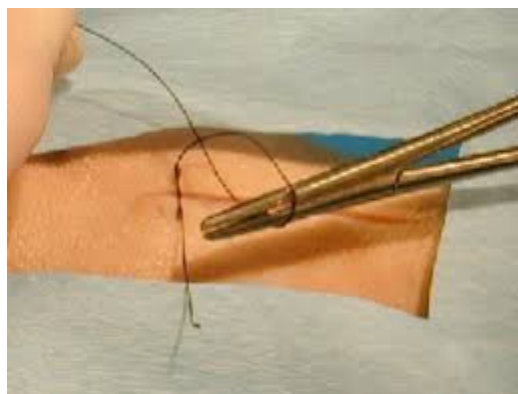
Needle holders are positioned over the knot for tying

- Between the strands of suture
- Not underneath either strand



Don't pull up on the knot

- Keep needle holders close to the skin
- Don't move the needle holders up and down
- Use your opposite hand to wrap the suture around the needle holders



Control your suture

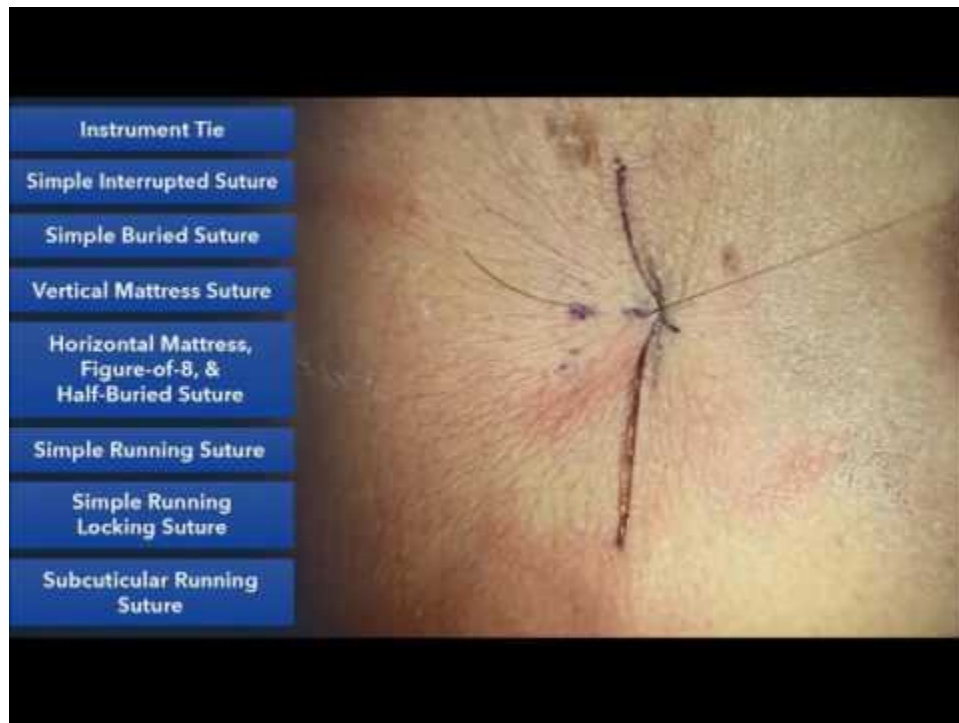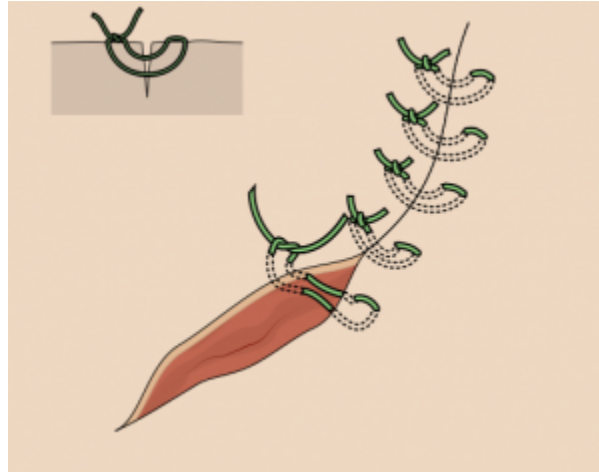
- Keep your hands where you can see them
- Wrap or fold the suture into your other hand to keep it under control



A YouTube element has been excluded from this version of the text. You can view it online here: <https://open.lib.umn.edu/largeanimalsurgery/?p=2931>

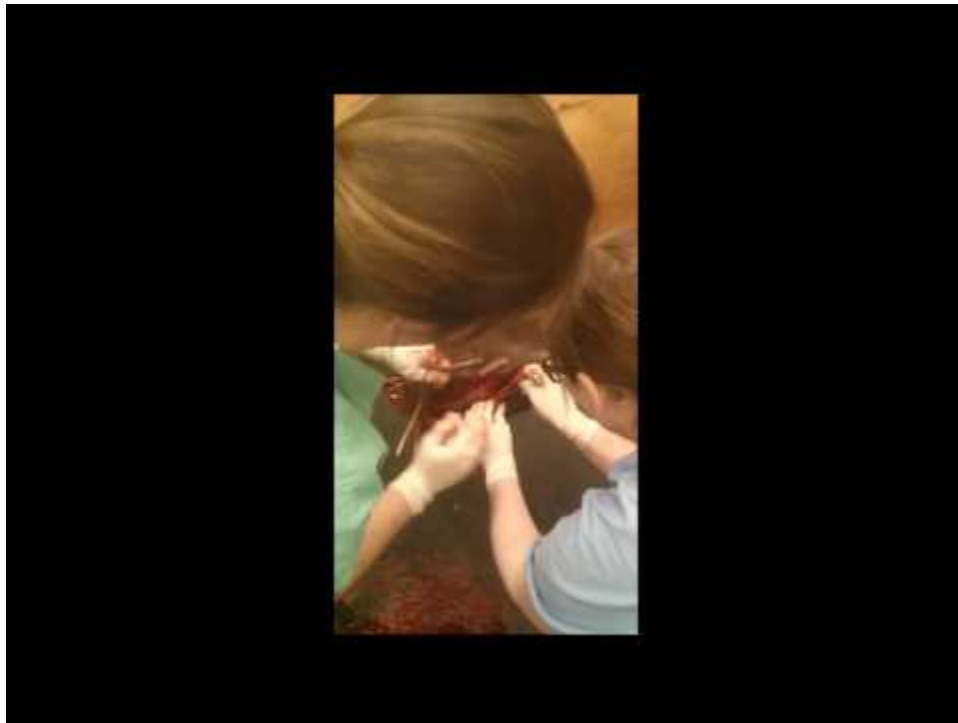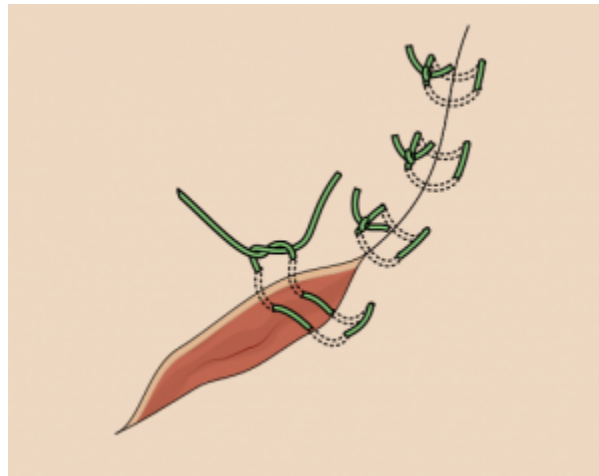
Suturing - tension relieving suture patterns

Vertical mattress



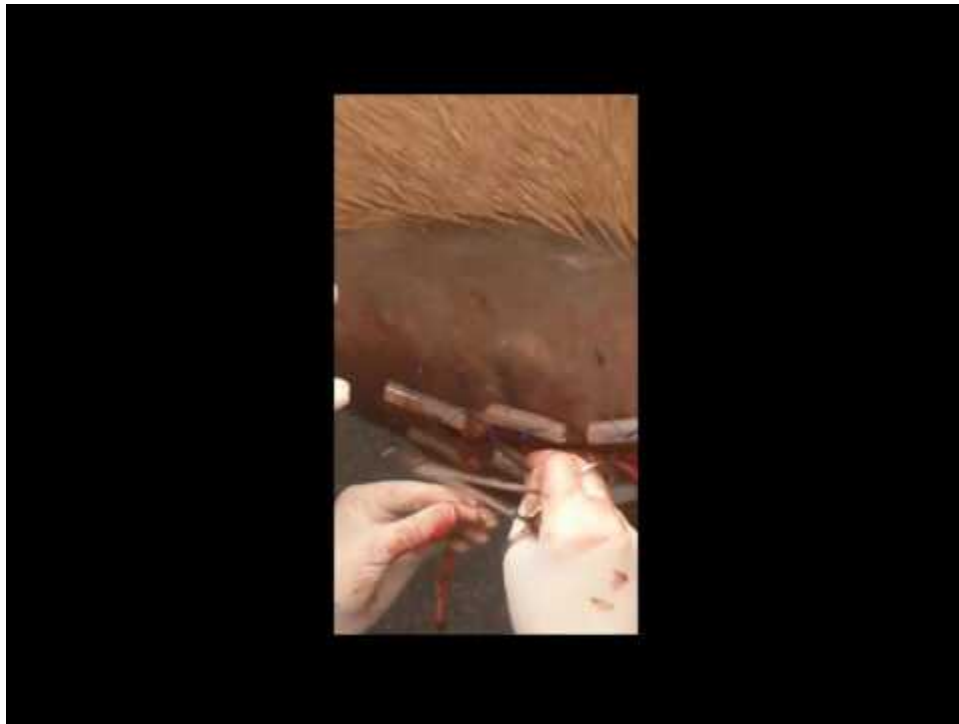
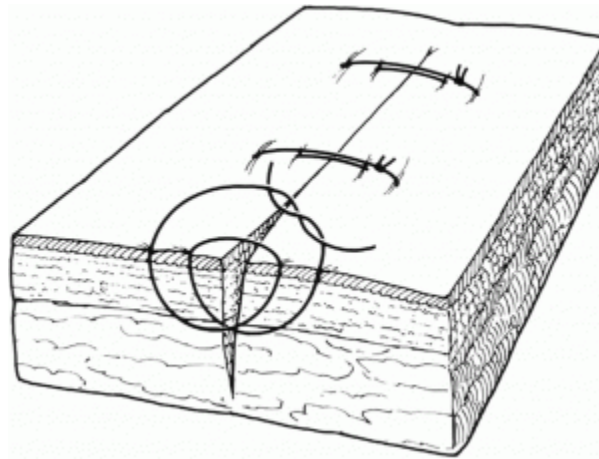
A YouTube element has been excluded from this version of the text. You can view it online here: <https://open.lib.umn.edu/largeanimalsurgery/?p=2940>

Horizontal mattress



A YouTube element has been excluded from this version of the text. You can view it online here: <https://open.lib.umn.edu/largeanimalsurgery/?p=2940>

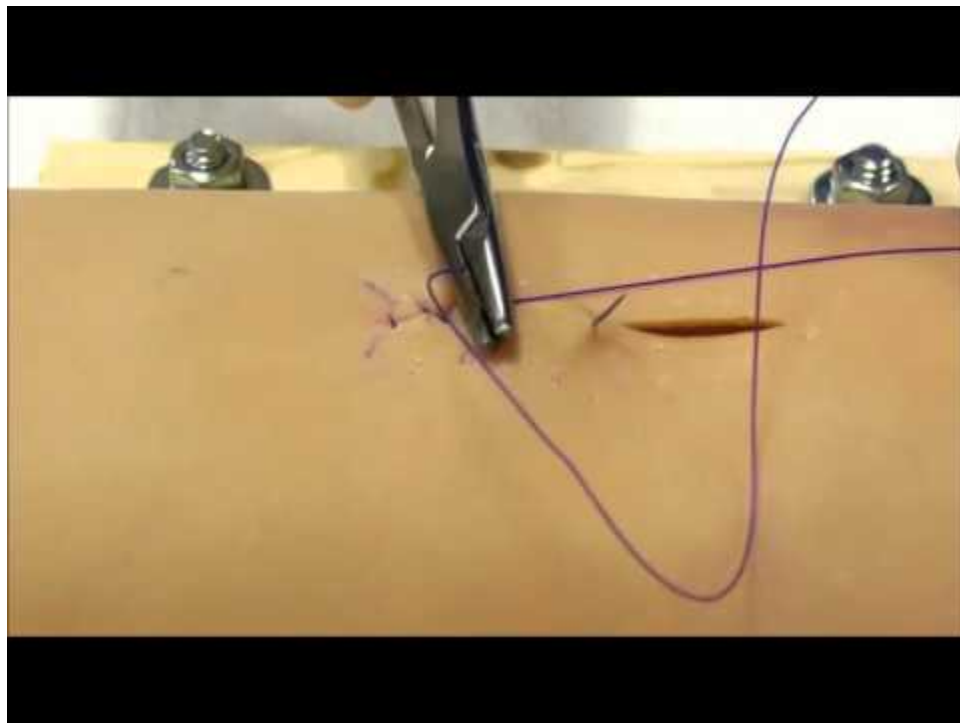
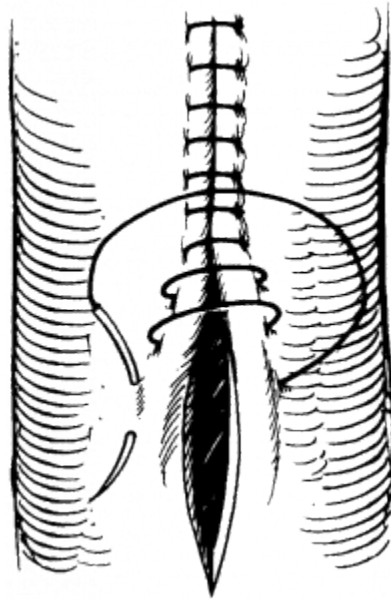
Near-far-far-near



A YouTube element has been excluded from this version of the text. You can view it online here: <https://open.lib.umn.edu/largeanimalsurgery/?p=2940>



Suturing - inverting suture patterns

Cushing



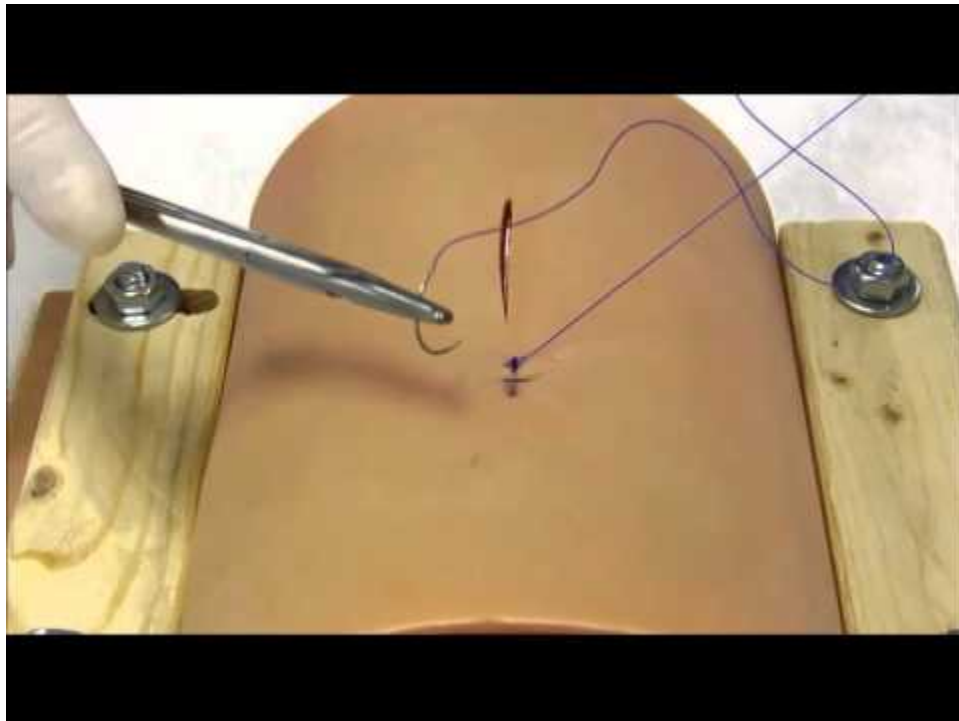
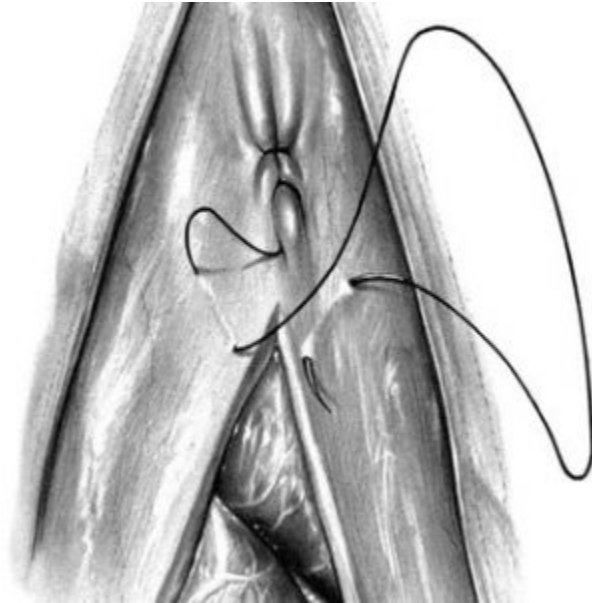
A YouTube element has been excluded from this version of the text. You can view it online here: <https://open.lib.umn.edu/largeanimalsurgery/?p=2948>

Lembert



A YouTube element has been excluded from this version of the text. You can view it online here: <https://open.lib.umn.edu/largeanimalsurgery/?p=2948>

Utrecht



26 Large Animal Surgery

A YouTube element has been excluded from this version of the text. You can view it online here: <https://open.lib.umn.edu/largeanimalsurgery/?p=2948>

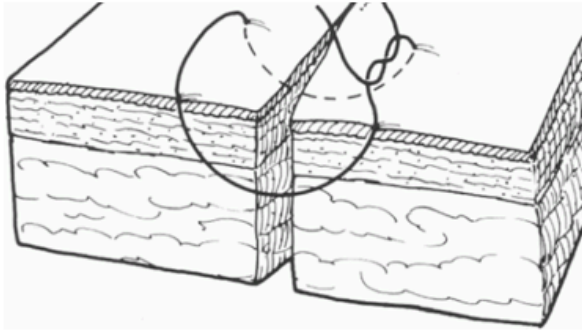
Resources

Newman and Anderson. [Cesarean section in cows](#) 2005 VCNA 21(1):73-100


Suturing - split thickness and corner stitch

Split thickness

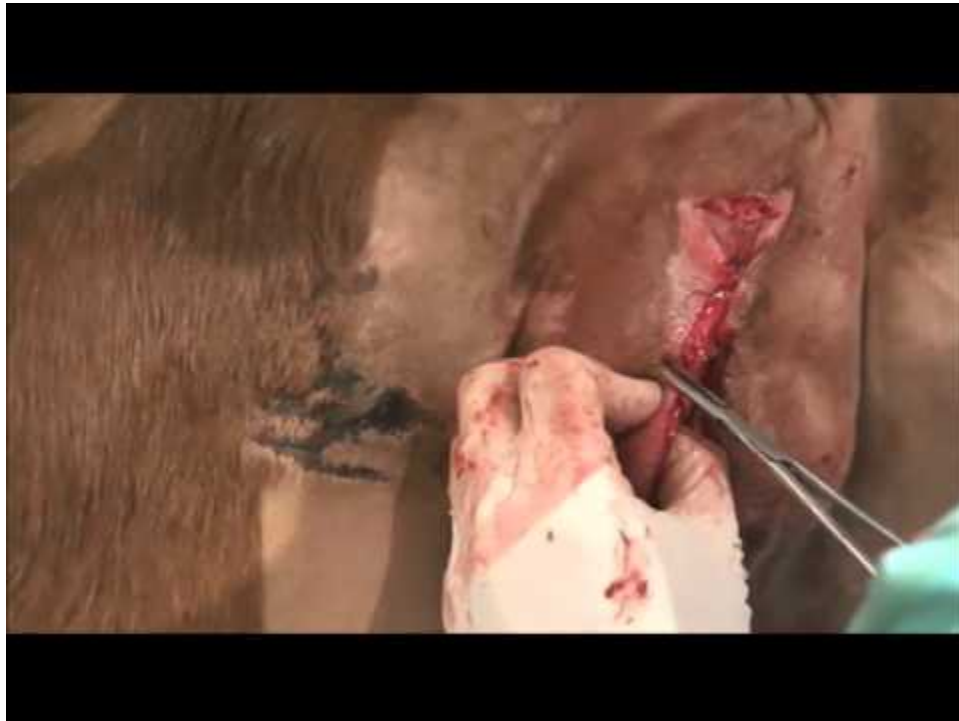Using split thickness bites creates very cosmetic skin closures.



Full thickness bite enters SQ



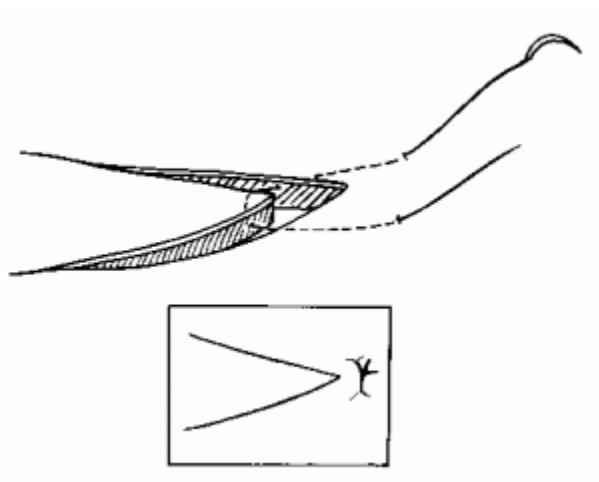
Partial thickness bite stays in dermis



A YouTube element has been excluded from this version of the text. You can view it online here: <https://open.lib.umn.edu/largeanimalsurgery/?p=2957>

Corner bites

Corner bites are a split thickness version that helps preserve vascular supply





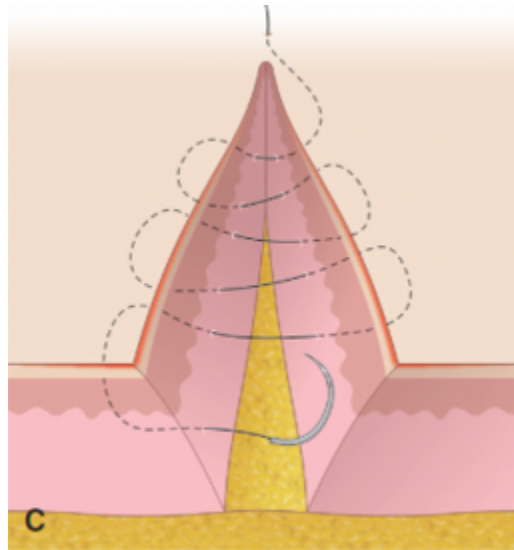
A video element has been excluded from this version of the text. You can watch it online here:

<https://open.lib.umn.edu/largeanimalsurgery/?p=2957>


[The buried horizontal suture](#)

Suturing- intradermal/subcuticular pattern

Subcuticular closure



Source: Jonathan Kantor: Atlas of Suturing Techniques: Approaches to Surgical Wound, Laceration, and Cosmetic Repair, AccessEmergencyMedicine Copyright © McGraw-Hill Education. All rights reserved.



32 Large Animal Surgery

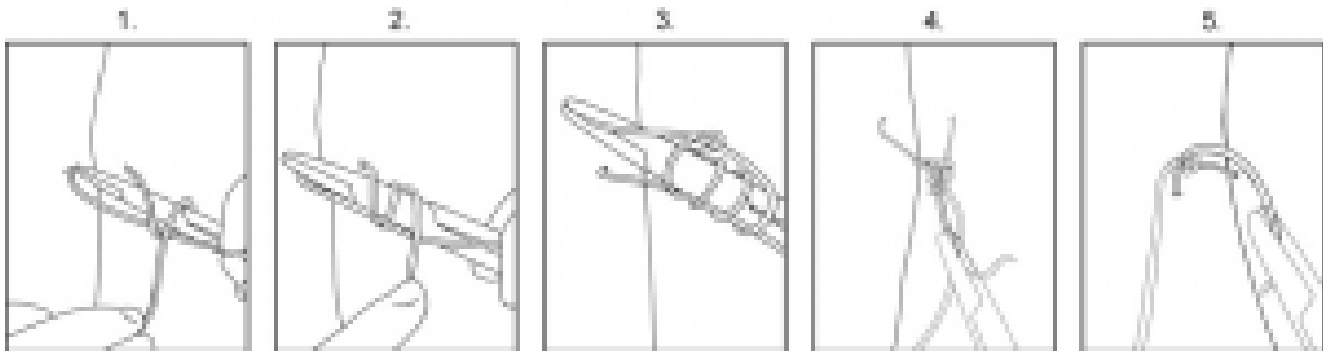
A YouTube element has been excluded from this version of the text. You can view it online here: <https://open.lib.umn.edu/largeanimalsurgery/?p=2963>

Knots - Forwarder and Aberdeen

Forwarder knots

Forwarder knots are more secure than square knots for the start of continuous runs and function well in fat and fluid media.

Forwarder Knot



1. Take a bite through the tissue from left to right
2. Hold the working end of the suture in the left hand; needle holder and free end of the suture in the right hand.
3. Turn the working end around both the needle holder and the free end of the suture. Repeat twice more, creating three throws about the combination.
4. Grasp the working end with the needle holders, pulling the working end through the looped throws as the needle holder is withdrawn
5. Pull the working end and free end in opposite directions, tightening and locking the knot

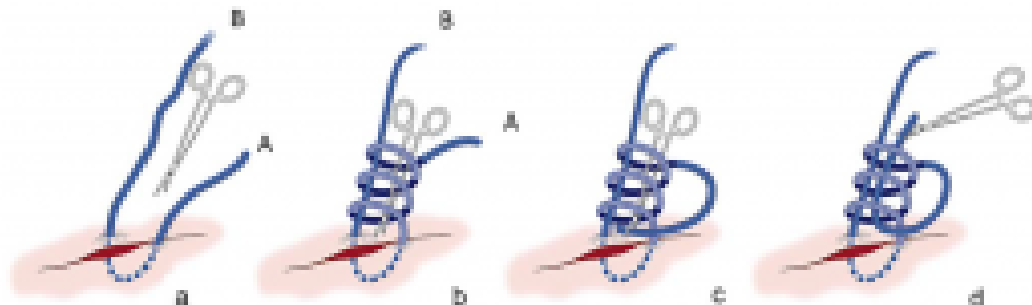



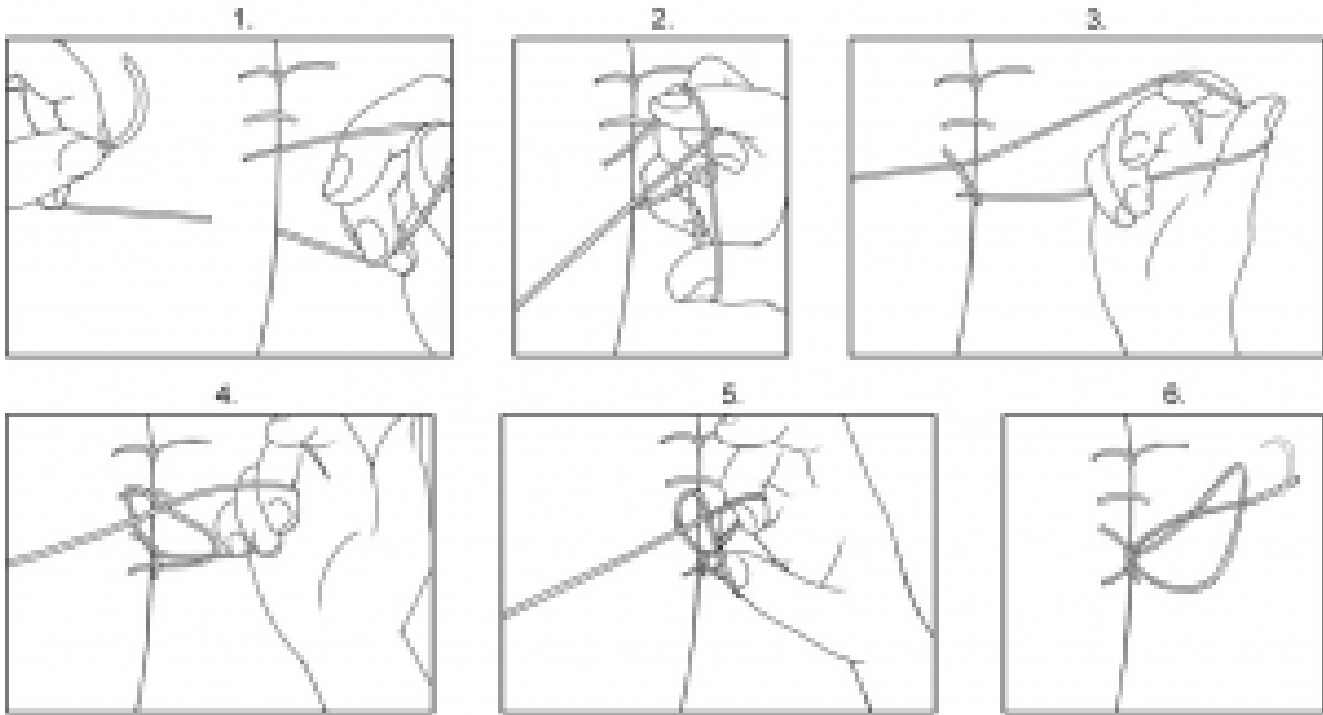
Figure 1 Formation of a forwarder knot. (a) A bite is taken through the tissue. The standing end (B) and the working end (A) of the suture are placed adjacent to each other and the needle holders. (b) The working end (A) of the suture is then turned around the needle holders and standing end (B) of the suture. The number of times this is performed depends on surgeon preference. (c) The working end of the suture is then grasped by the needle holders through the placed loops. (d) The needle holders are withdrawn, pulling the working end of the suture through the loops and locking the forwarder knot.



A YouTube element has been excluded from this version of the text. You can view it online here: <https://open.lib.umn.edu/largeanimalsurgery/?p=2923>

Aberdeen knots

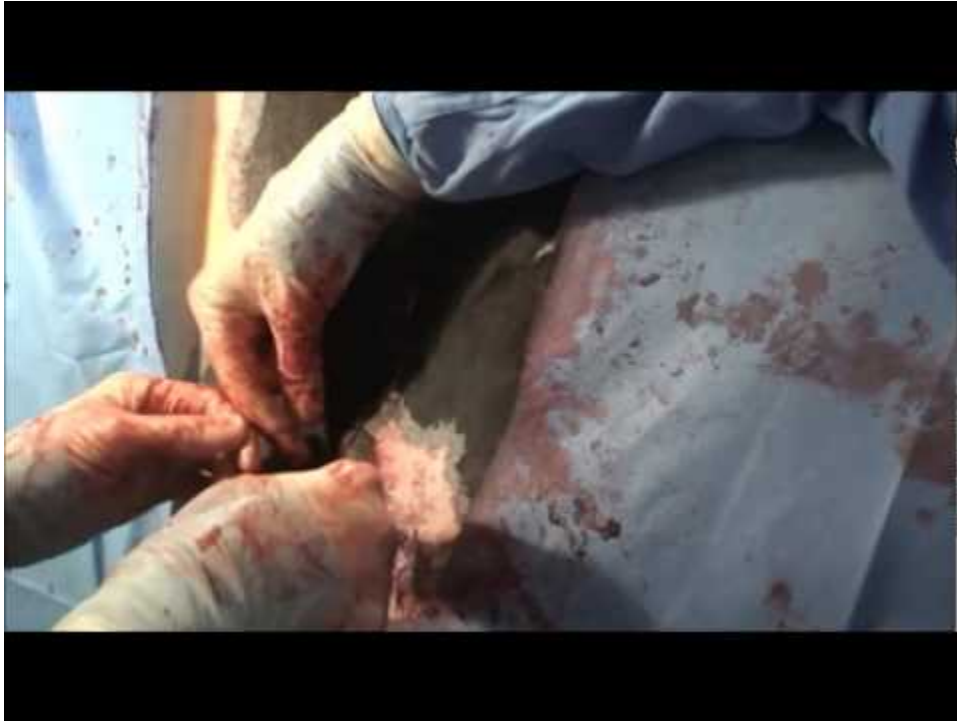Aberdeen knots are used at the end of a continuous run. They result in better security with less bulk than square knots, particularly in continuous runs.

Aberdeen Knot

1. Take the final bite of the continuous pattern through the tissue from right to left, leaving a large loop
2. Hold the working end of the suture (needle attached) in the left hand
3. Create a second loop in the working end and pass it through the first loop, while maintaining tension. This equals one throw
4. Repeat for 4 throws
5. Pull the working end through the final loop and tighten to lock the knot



A YouTube element has been excluded from this version of the text. You can view it online here: <https://open.lib.umn.edu/largeanimalsurgery/?p=2923>



A YouTube element has been excluded from this version of the text. You can view it online here: <https://open.lib.umn.edu/largeanimalsurgery/?p=2923>

They are also an easier way to bury your knot



A YouTube element has been excluded from this version of the text. You can view it online here: <https://open.lib.umn.edu/largeanimalsurgery/?p=2923>

Resources

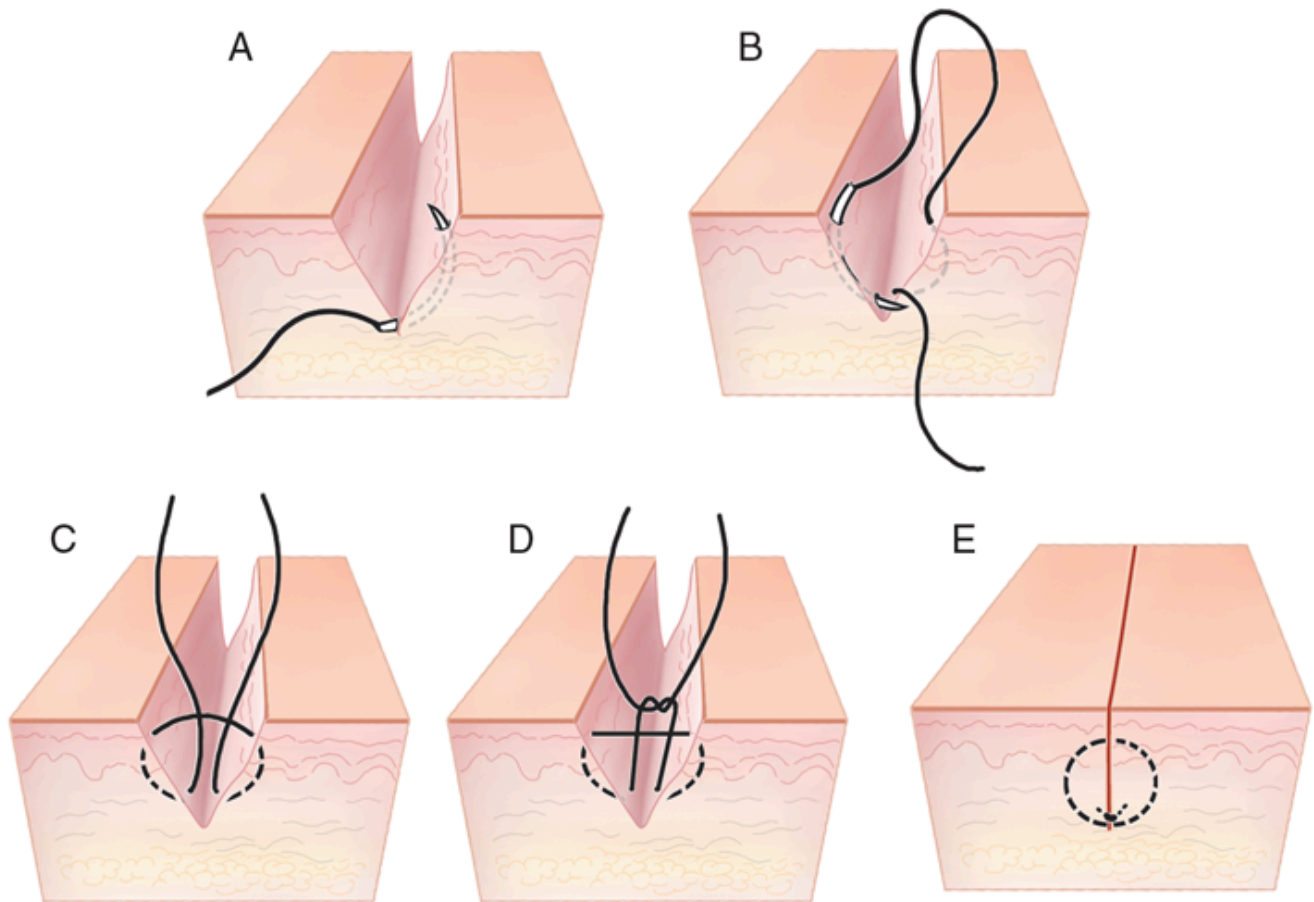
McGlinchey L et al. [Bursting strength of surgeon's and self-locking knots for closure of ventral midline celiotomy in horses](#). Vet Surg 2018, 47(8):1080-1086

Gillen AM et al. [In Vitro Evaluation of the Size, Knot Holding Capacity, and Knot Security of the Forwarder Knot Compared to Square and Surgeon's Knots Using Large Gauge Suture](#). Vet Surg 2016, 45:1034-1040

Knots - burying the knot

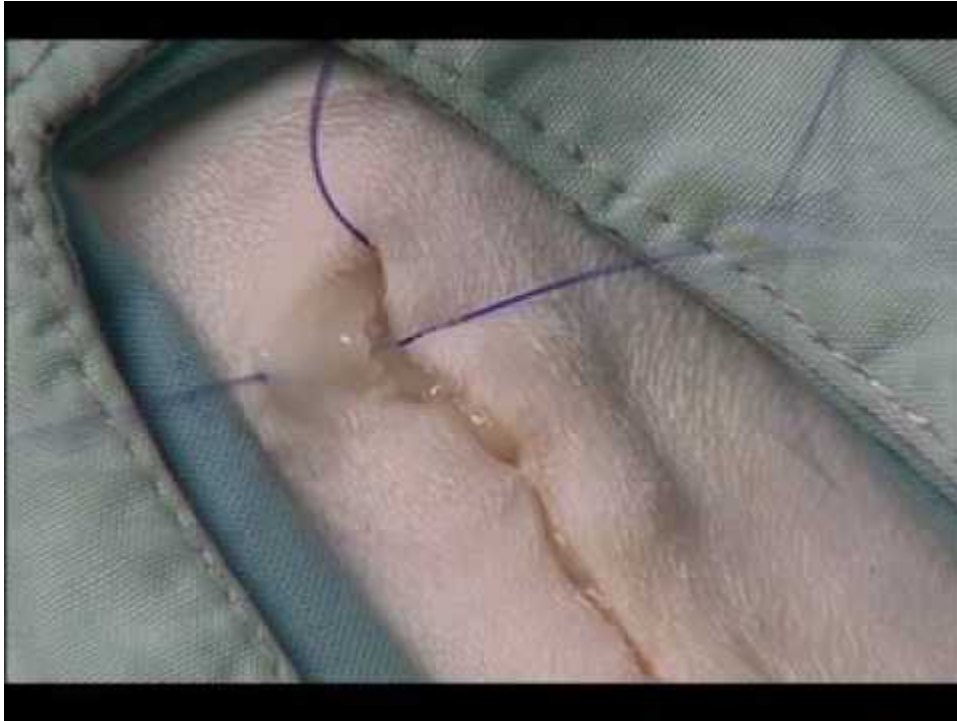Techniques are similar between these two types. For skin – deep to superficial, superficial to deep. For lumen closure – near to far, far to near.

Burying the knot – skin version

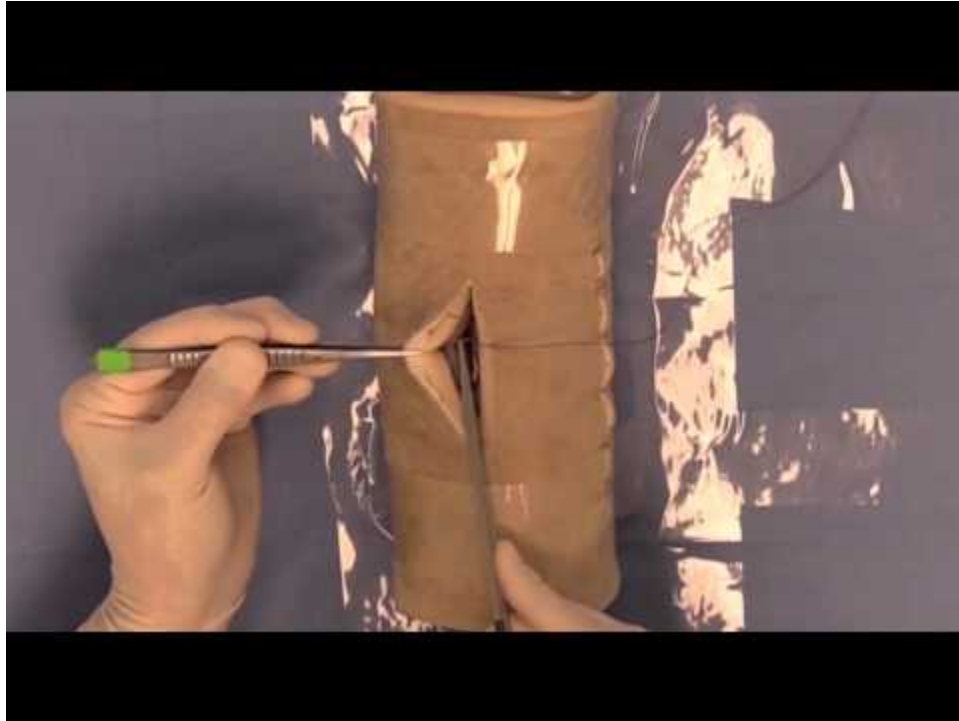

Source: Reichman EF: *Emergency Medicine Procedures*,
Second Edition: www.accessemergencymedicine.com
Copyright © The McGraw-Hill Companies, Inc. All rights reserved.

[University of Saskatchewan Lab](#) – step by step

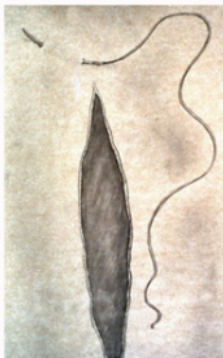

A YouTube element has been excluded from this version of the text. You can view it online here: <https://open.lib.umn.edu/largeanimalsurgery/?p=2966>



A YouTube element has been excluded from this version of the text. You can view it online here: <https://open.lib.umn.edu/largeanimalsurgery/?p=2966>

Burying the knot – lumen closure (inverting patterns)



Utrecht Pattern - First Stitch.

The Utrecht pattern for uterine closure is a modified Cushing pattern, a continuous infolding pattern whereby the individual stitches are placed diagonally rather than parallel to the line of incision. The first stitch is placed just above the (dorsal) commissure, at the apex of an inverted, obtuse triangle.

Utrecht (1976)



Utrecht Pattern - First Knot.

The second bite returns to the apex of the triangle.

Utrecht (1976)



Utrecht Pattern - First Tie.

As the ends of the suture are pulled tight, the base of the triangle folds in.

Utrecht (1976)

42 Large Animal Surgery



Utrecht Pattern - Ending the Incision.

The closure of the incision is ended with another triangle. The apex is where the needle last exited. The needle is essentially re-inserted in the same location, as shown in the illustration.

Utrecht (1976)



Utrecht Pattern - Final Knot.

The needle end of the suture is tied to the loop left behind at the apex of the triangle.

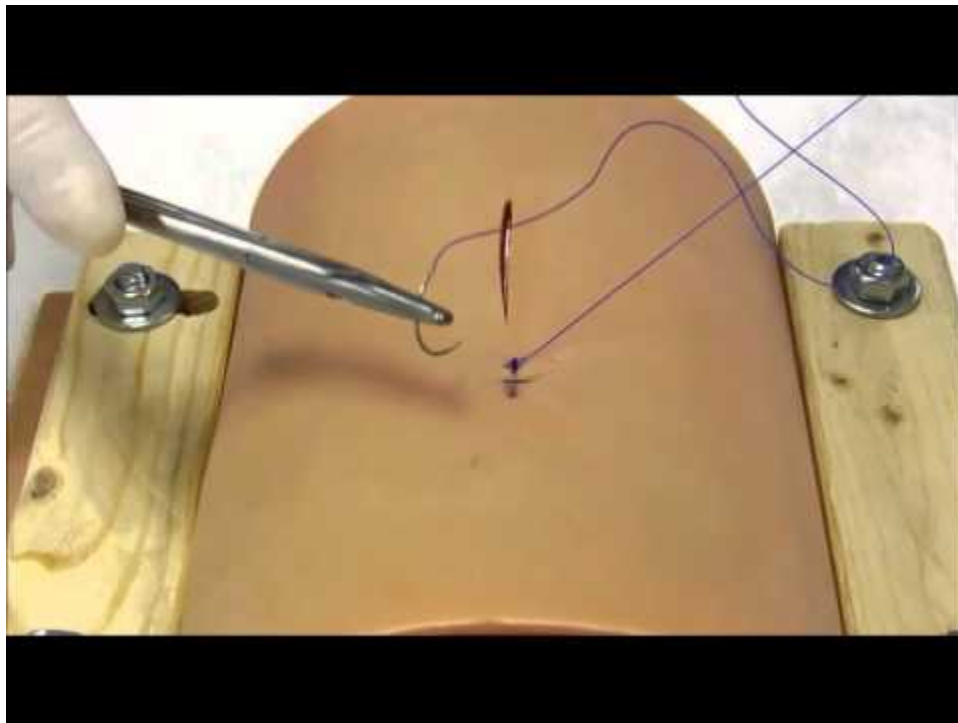
Utrecht (1976)



Utrecht Pattern - Final Tie.

By pulling up on both ends of the suture material the base line of the triangle folds in and the knot is buried.

Utrecht (1976)

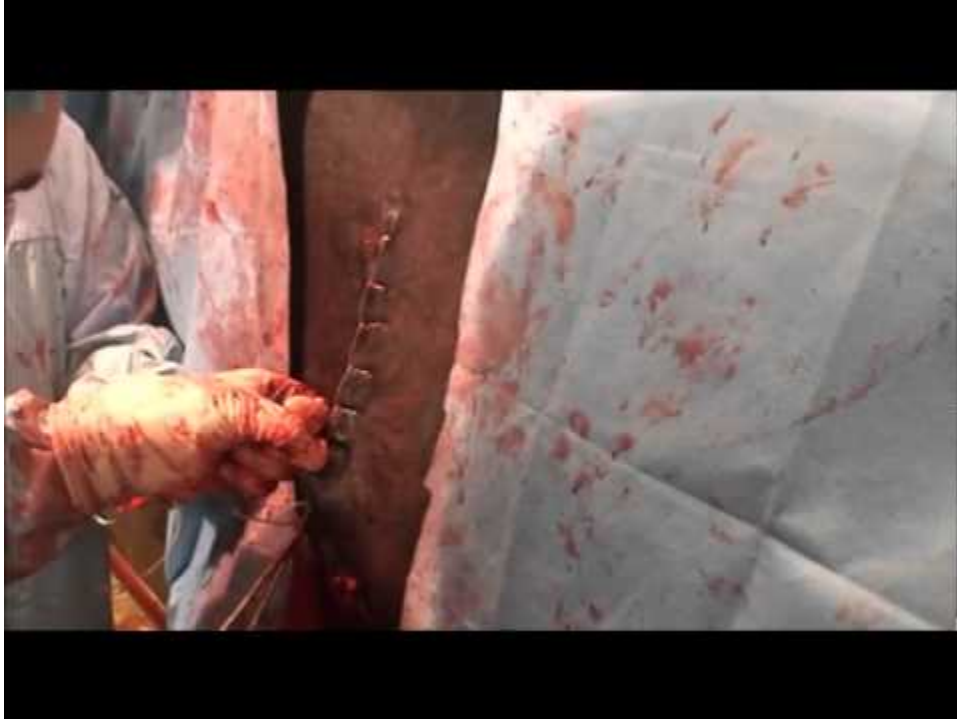

A YouTube element has been excluded from this version of the text. You can view it online here: <https://open.lib.umn.edu/largeanimalsurgery/?p=2966>

Knots - finishing the Ford Interlocking

If you have a swedged on needle, just go backwards for the last bite.

If you don't you can do this version or the Aberdeen knot



A YouTube element has been excluded from this version of the text. You can view it online here: <https://open.lib.umn.edu/largeanimalsurgery/?p=3236>

General pharmacology

Basic principles, drug formulations and local blocks that cross species

Pharmacology basics

Dr. Alex Bianco

Use this section as a resource for interpreting articles and advanced materials.

Definitions

Pharmacokinetics =What the body does to the drug. E.g. Metabolism, elimination

Pharmacodynamics =What the drug does to the body. E.g. Desired effects + adverse effects (AE)

Dosage =Amount of drug administered per unit body weight. Mg/kg, mg/lb, IU/kg

Dose =The amount of drug the animal receives. Total mg/tablets/mL

Initial concentration (C_0)= [Drug] at first time point after administration ($t=0$)

Maximum concentration (C_{max}) = The highest [drug] obtained after a single dose of drug

Concentration at steady state (C_{ss}) =Applies to repeated drug administration or CRI; the [drug] where drug administration and clearance equilibrate

CRI -constant rate infusion (an iv drip)

Terminal half life ($t_{1/2}$) = The amount of time it takes to decrease the plasma [drug] by 50%

$$t_{1/2} = (0.693 * Vd) / Cl = 0.693 / k \quad \text{where } k = \text{the elimination rate constant (slope of the elimination curve)}$$

Clearance (Cl) = Rate at which drugs are eliminated from the body (urine or feces). Cl is inversely proportional to half-life

$$Cl = (0.693 * Vd) / (t_{1/2})$$

Volume of distribution (Vd) =Amount of drug in body relative to plasma volume

↑ $V_{d_{ss}}$ = more drug NOT IN plasma

↓ $V_{d_{ss}}$ = more drug IN plasma

$$Vd = (\text{Dose (mg)}) / C_0 \quad \text{Can only calculate from iv parameters}$$

Time to maximum concentration (t_{max}) = How long it takes before reaching C_{max} . Depends on rate of

absorption vs. clearance

t_{max} always = 0 when given IV : highest drug concentration is immediately after administration

Bioavailability (F%) =Percentage of drug administered that is ultimately absorbed in to bloodstream.

Calculated by comparing to same dose given IV (100% bioavailable). Measured by comparing area under the curve using trapezoidal rule (fancy math)

Routes of administration

IV administration

$$C_0 = C_{max}$$

C_{max} after IV dosing will ALWAYS be higher than other route of administration

A drug given IV will always have a shorter withdrawal time than when given by other routes

Other routes

Once drug enters blood, it should behave as with IV dosing

Rate of absorption (k_a) = the time it takes to reach the blood

Bioavailability is never 100%. Drug is simultaneously being cleared/absorbed

PO is generally a lower peak (C_{max}) and a longer elimination

Some drug is never absorbed when given po.

Parameters of interest

Time dependent antibiotics – we care about time above MIC

Concentration dependent antibiotics – we care about C_{max} : MIC ratio and AUC: MIC ratio

Perioperative antibiotics

Antibiotics should be used only when necessary. Sometimes you don't know if it will be necessary. Preoperative antibiotics that are at high levels at the time of any "surprise" is more effective use of the drugs than treating after the fact.

Getting high levels at the time of surgery

Timing of drugs depends on the route. IV medications are usually at peak levels within 15 minutes. IM medications in 20-30 minutes. SQ administration is variable and can be challenging to predict; this makes SQ antibiotics not a great option for preop medication. Oral medications typically need at least 2 hours.

Choosing drugs

When we don't know what sort of surprises we will encounter, we err on the side of broad spectrum bacteriocidal but first line drugs, rather than those restricted for use in cases of resistance.

In horses, we typically use penicillin/gentamicin or a cephalosporin.

In small ruminants, ampicillin or cephalosporins are used.

In lactating cattle, typically ceftiofur is first choice due to the limited withholding.

In beef cattle, ceftiofur is still a reasonable choice.

Local anesthesia

We use local blocks very commonly in food animal species. Often bovine standing surgery can be performed without sedation and just with local anesthesia. Epidurals are also relatively easy in dairy cattle and can help with many perineal procedures.

Drugs

Lidocaine – Lidocaine is the predominant local anesthetic agent used. Species sensitivity varies with small ruminants and camelids much more sensitive. The following guidelines are useful to consider as high end doses. Calculate how much you can give and then decide if you need to dilute the drug. Diluted drug still works but has a shorter duration. Hint: 2% lidocaine is 20mg/ml.

Species	Max dose
Cats	2 mg/kg
Sheep and goats	4-5 mg/kg
Camelids	4-5 mg/kg +
Horses	8 mg/kg
Cattle	8 mg/kg +
Swine	8 mg/kg

Mepivacaine lasts longer than lidocaine and can be used for longer procedures if needed. Bupivacaine can be more tissue toxic is typically isn't used in our food animal species.

Types of blocks

Nerve blocks: If we know where the nerve is, we can just put local anesthetic near the nerve. Eg dehorning blocks and paravertebral blocks

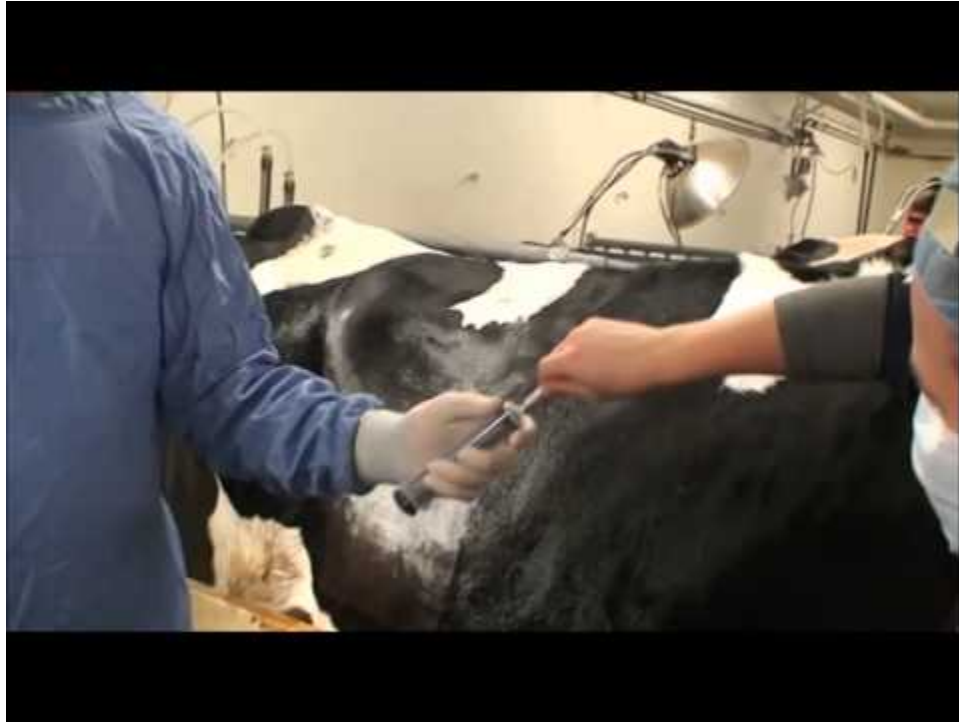Line blocks: Local anesthetic is injected in the line of the planned incision. This does deform the tissue planes but is the easiest to control.

Field blocks: The nerves to a region are blocked using specific types of line blocks. An L block is used in the flank to block the regional paravertebral nerves

Ring blocks: A specific type of field block. The entire limb is encircled with subcutaneous local anesthetic to reach any and all nerves

Regional iv blocks: A tourniquet is placed on the limb and local anesthetic injected into a vessel below the tourniquet. The local anesthetic is diluted to the level that it pushes out of the vasculature and into the tissues (typically 20 cc +).

Sterile block: for top ups



A YouTube element has been excluded from this version of the text. You can view it online here: <https://open.lib.umn.edu/largeanimalsurgery/?p=2471>

Epidurals

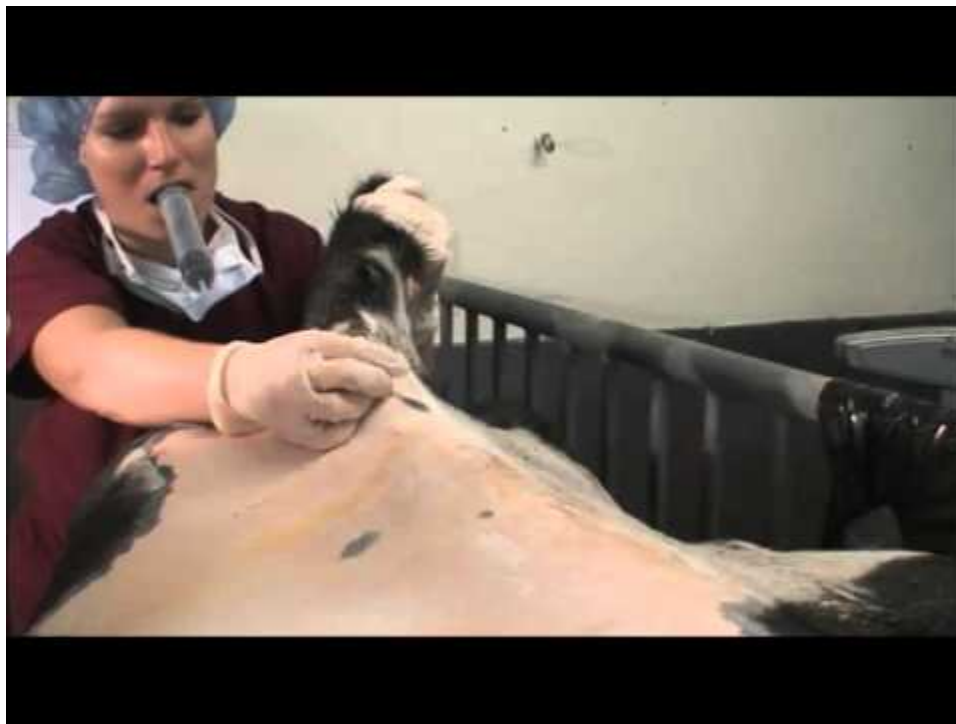The most common epidural agent is again lidocaine. We typically use 2-8 mg/kg BW, or 5 cc as starting amount in a standard size dairy cow. Lidocaine epidurals can cause ataxia and even recumbency. Lidocaine can be combined with xylazine for longer duration epidural with less risk of recumbency. Detomidine leaves the epidural space quickly so more resembles im detomidine than epidural detomidine. Ketamine and morphine are other options for epidurals.

Lidocaine/xylazine combo – lidocaine 0.22mg/kg + xylazine 0.05 mg/kg, saline added to total volume of 5.7ml

Combination lasts about 300 minutes vs 80 minutes for lidocaine alone

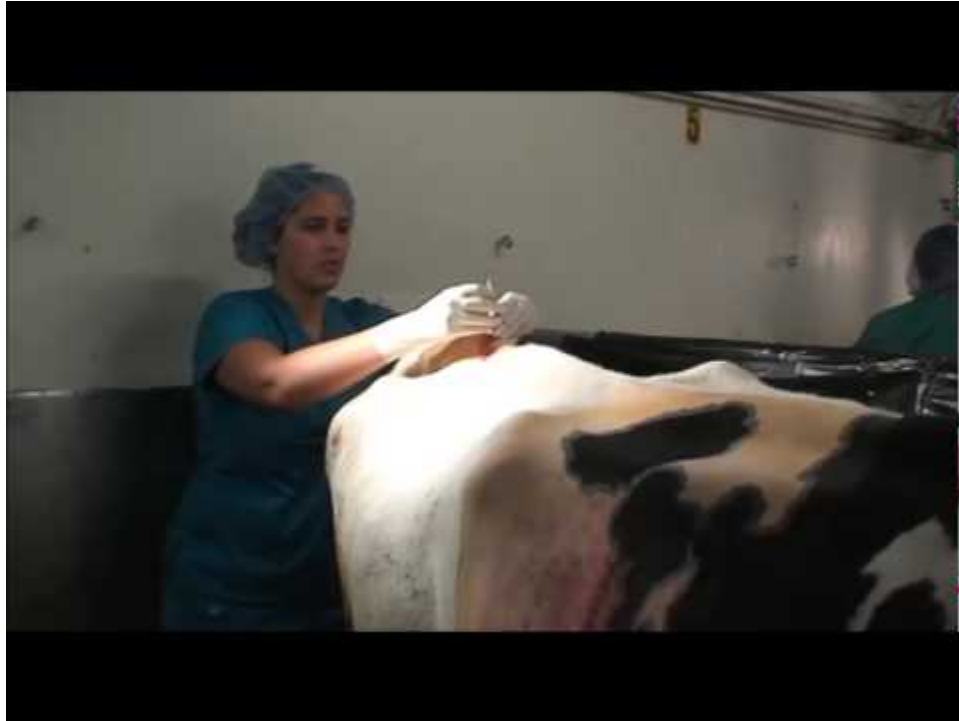Epidurals are typically performed in the lumbosacral space (the most movable space when the tail is pumped up and down). In dairy cattle, a 1.5" 18 ga needle is inserted in that space at a 45° angle so that the hub is angled toward the tail. A drop of lidocaine is put in the needle hub and should be sucked down into the needle when the epidural space is reached. This is known as the hanging drop technique. It works well in most dairy cattle but isn't as useful in obese animals.

If the needle is positioned so the bevel is up, the drug will diffuse further forward. If the bevel is pointed down, this will tend to keep the drug in the caudal region.



A YouTube element has been excluded from this version of the text. You can view it online here: <https://open.lib.umn.edu/largeanimalsurgery/?p=2471>

The needle in this video is way longer than it needs to be but it shows a great hanging drop technique



A YouTube element has been excluded from this version of the text. You can view it online here: <https://open.lib.umn.edu/largeanimalsurgery/?p=2471>

Flank anesthesia

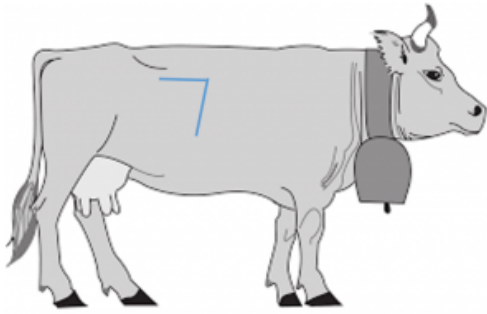
Flank surgery is common in cattle and requires good local block. Options include a line block (at the incision site), an inverted L and paravertebral blocks

Line block

A line block is an injection of subcutaneous lidocaine along the site of the incision. Relatively straightforward, it is often used when nothing else is working. The block can be easier on the animal if a longer needle is used and is inserted through the site of the last injection. This minimizes the number of pokes in unblocked skin. For flank incisions, it is important to also place lidocaine deeper in the muscle layers.

The main disadvantage of a line block is distortion of the surgery field.

Inverted L block



This block is similar to the line block but is used to block the nerves as they come down the flank and avoids lidocaine directly in the surgery field. The lidocaine is injected in two long lines – one just behind the last rib and one below the transverse processes of the vertebrae. The injection must be deep enough to get the deeper nerves and typically does not block the peritoneum.

Proximal paravertebral block

For this block, the spinal nerves T13, L1 and L2 are blocked as directly as possible as they exit the spinal cord. This creates a more

effective block. When the block is working, the cow will bend toward the opposite side as muscles are relaxed. The flank will also be warmer due to related vasodilation.

At each site, ~20 ml of lidocaine is injected. Needles are inserted above the transverse processes T13, L1 and L2 and walked off the dorsal margin of each bone. A long needle is used to block the nerve branches both

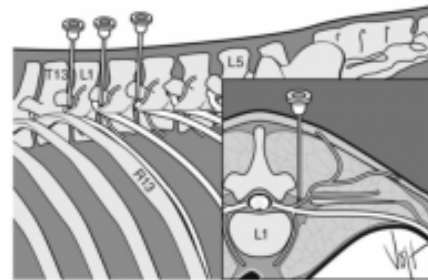


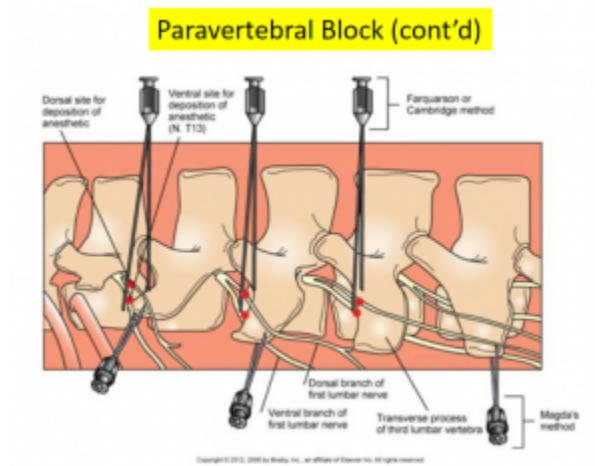
FIG. 9.7 Needle placement for proximal paravertebral nerve block in cattle. Left: lateral aspect and cross-section of a thoracic vertebra at the location of the intercostal foramen. T13 is the last rib. T13, L1, and L2 are the spinous processes of the last thoracic and the first and 10th lumbar vertebrae, respectively.

from *Veteriankey*

This block can be challenging in very large beef breeds due to difficulty palpating landmarks.

Distal paravertebral block

This block is also aimed at spinal nerves T13, L1 and L2 but is coming at them from a more distal position. As the nerves traverse caudally, the injection sites are at the tips of L1, L2 and L4. At each site, 10-20 ml of lidocaine is injected.



from <https://slideplayer.com/slide/7545976/>

Resources

[Ocular blocks](#) chapter

[Perineal blocks](#) chapter

[Local, Regional, and Spinal Anesthesia in Ruminants](#), 2016 VCNA- lots of blocks with good diagrams

[Local blocks](#), Kathy Whitman, Great Plains Education Center (ppt will download)

[Comparison of lidocaine, xylazine, and lidocaine-xylazine for caudal epidural analgesia in cattle](#). Vet Anaes Analg 2002

[Epidural analgesia in cattle, buffalo and camels](#), 2016 Vet World

[Local anesthesia/analgesia](#) – OSU – all species



A YouTube element has been excluded from this version of the text. You can view it online here: <https://open.lib.umn.edu/largeanimalsurgery/?p=2471>

Drug Concentrations and Recipes

Drugs	Concentration	Bottle Size
Acepromazine	10mg/ml	50ml
Butorphanol	10mg/ml	10ml
Detomidine	10mg/ml	50ml
Ketamine	100mg/ml	10ml/bt
Lidocaine	20mg/ml (2%)	250ml
Midazolam (or Diazepam)	5mg/ml	10ml
Penicillin-G (Procaine)	300,000 IU/ml	250ml
Sterile Diluent (for Telazol)		
Telazol	100mg/ml	5ml
Xylazine (Equine version)	100 mg/ml	100ml
Xylazine (SA or ruminant version)	20mg/ml	20ml
Morphine	10mg/ml	1ml vials

Midazolam drip recipe: 5ml (25 mg) midazolam + 20 ml (2 g) ketamine +5 ml (100 mg) 20mg/ml xylazine in 1 liter bag fluids.

Xylazine/ketamine drip recipe: 50 mg xylazine and 1.0 to 1.5 g ketamine added to 1 L electrolyte solution

Muscle relaxation should be satisfactory if an adequate dose of xylazine is used at induction, or it can be improved by administering 25 to 50 mg of midazolam or diazepam intravenously as a bolus or by increasing the infusion rate of xylazine and ketamine.

Food Animal Drugs

This section discusses choosing antibiotics, analgesics, NSAIDs, sedatives and anesthetic agents for food and fiber species.

Food Animal Analgesics

Analgesics need to be given prior to the pain stimulus to prevent [hyperalgesia](#) and [wind-up](#) phenomenon. This preemptive analgesia decreases the amount of pain produced but does not prevent pain. Analgesics should also be used after the stimulus to control the resultant pain. Pain is generally but not always related to the release of inflammatory mediators.

Our current practice “standards” are to 1) give nothing or 2) give it after the procedure. *Neither of these make economic or physiological sense.* It makes more sense to give the drug before the procedure, particularly if a single dose. The same dose given after the procedure has less effect. We have spent the same amount of money and effort for less result. Since our goal is generally production, avoiding drugs is also nonsensical. When drugs are given, production losses due to withholding are typically minimal and are offset by minimized drop in production of milk or meat related to pain.

Flunixin meglumine is the only NSAID currently (6/2018) approved in food animals in the USA. In cattle, it needs to be given intravenously unless in the new topical formulation (below). Besides being off label, intramuscular injections are very irritating to tissues and can lead to Blackleg. Standard doses are 1.1 mg/kg iv BID or 2.2 mg/kg iv SID. You will find references for 2.2 mg/kg BID but that dose increases the risk of side effects.

[FDA Approves First Medication for Pain Control in a Food-producing Animal](#)

July 25, 2017

The U.S. Food and Drug Administration announces the approval of Banamine Transdermal (flunixin transdermal solution), an animal drug approved for the control of pain associated with foot rot and the control of pyrexia (fever) associated with bovine respiratory disease.

Meloxicam is an NSAID that has gained widespread popularity. It seems to have better analgesic properties than flunixin meglumine. It is being used under ELDU (extralabel drug use) regulations for its analgesic effects. This does require a VCPR (veterinarian-client-patient relationship)/

[Castration and dehorning Guidelines- AABP.org](#)

There are no approved pain drugs for use in cattle in the US. The AMDUCA allows extralabel drug use (ELDU) provided a valid VCPR exists and the drug selection decision process is followed. Although flunixin meglumine is an NSAID labeled for use in cattle and has been shown to have short acting analgesic effects, long acting NSAID analgesics, such as meloxicam, are more desirable to mitigate the pain associated with castration and dehorning.

While most oral medications are not effective in ruminants and camelids due to passage through the forestomachs, meloxicam is effective when given orally to both cattle and camelids. It may also be effective in piglets if fed to the sow.

[Impact of Transmammary-Delivered Meloxicam on Biomarkers of Pain and Distress in Piglets after Castration and Tail Docking-2014, PLoS One](#)

The objectives of the study were to demonstrate meloxicam transfer from sows to piglets via milk and to describe the analgesic effects in piglets after processing through assessment of pain biomarkers and infrared thermography (IRT)... This study demonstrates the successful transfer of meloxicam from sows to piglets through milk and corresponding analgesia after processing, as evidenced by a decrease in cortisol and PGE₂ levels and maintenance of cranial skin temperature.

FARAD suggests 21 days meat withholding after a single dose of 1mg/kg meloxicam po or 0.05 mg/kg im or iv: [Considerations for extralabel drug use in calves, FARAD Digest, 2017](#)

Narcotics are increasingly used for pain in ruminants and camelids. None are approved so AMDUCA guidelines must be followed. These are the most common choices:

Butorphanol

Used for acute pain, generally perioperatively. The short duration of action makes it expensive and challenging to use long term. Provides sedation when combined with other drugs.

Minimal side effects.

Morphine

Commonly used in ruminants for pain. Inexpensive and lasts 8 hours. Does decrease GI motility and is a schedule II drug so requires careful monitoring of access to the drug.

Buprenorphine

Most commonly used for postoperative pain management in goats. Should be used with caution in sick animals due to side effects. Relatively expensive but a single dose is often effective.

Fentanyl

May be used iv for perioperative pain control. The patches are more useful for control of camelid pain.

One more transdermal option for poultry:



A YouTube element has been excluded from this version of the text. You can view it online here: <https://open.lib.umn.edu/largeanimalsurgery/?p=134>

RESOURCES

[Clinical Pharmacology of Analgesic Drugs in Cattle](#), 2015 VCNA

[A Review of Analgesic Compounds Used in Food Animals in the United States](#), 2013 VCNA Vol.29(1), pp.11-28

[Anesthesia and Analgesia in Sheep and Goats](#), 2011 VCNA Vol.27(1), pp.47-59

[Pain Management](#), Sarel van Amstel & Jan Shearer

[The efficacy of preemptive analgesia for acute postoperative pain management: a meta-analysis](#). Anesth Analg 2005

Food Animal Antibiotics

Due to the restrictions on antimicrobial use, choosing antimicrobials for food and fiber animals is somewhat simpler than in dogs and cats in many regards.

Primary considerations:

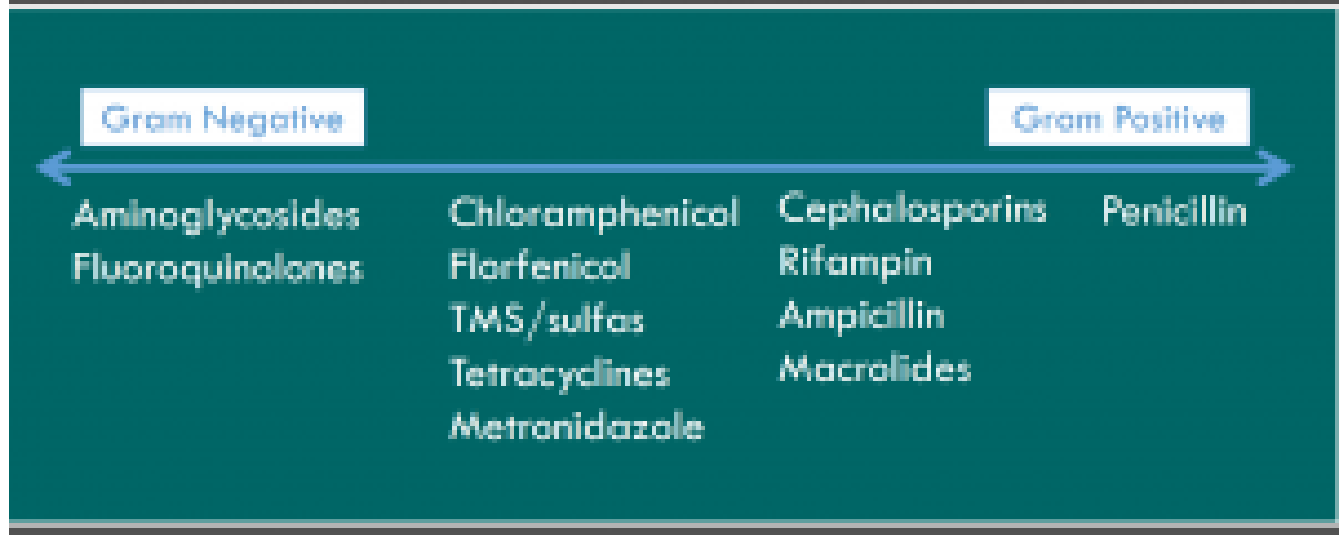
- are you likely dealing with gram positive, gram negative or both types of organisms?
- is there a drug labeled for the species and the disease?
- what drugs are legal in the species?
- where is the infection? can the antibiotics reach it? what drugs will be effective in that environment?
- how sick is the animal? can you use a bacteriostatic drug or do you need a bacteriocidal drug?
- does the animal have any other conditions that would increase the risk of certain drugs? e.g. renal disease or liver failure
- what drugs should you avoid using in order to save them for human use?

Secondary considerations

- is the animal milking or likely to go to market soon? what is your withholding window?
- how valuable is the animal and how expensive is the drug?
- what routes of administration are available to you and how frequently can the drug be administered?
- what are the resistance patterns in your area? can you assume certain drugs will be more effective than others?

Selecting antimicrobials (Dr. Alex Bianco)

Antibiotic Spectrum



Antibiotic MOA



Drug	IV	IM/ SQ	PO	Anaerobes	Good penetration	Use in a dairy cow
Penicillin	x	x		x		x
Ampicillin	x	x				x
Cephalosporins	EQ/ SRC	x				x (on label only)
Fluoroquinolones	EQ	FA	EQ			
Macrolides		FA	FA/ foals			
Chloramphenical/ Florfenicol		FA	EQ	x	x	
Tetracyclines	x	FA				x


[Swine Antibiotherapy Handbook](#): (also has good info for other species)


LIBRARIES

Home Read Sign out

Swine Antibiotherapy Handbook

Part 2/3
All Rights Reserved





RESOURCES

[Food Animal Drug Regulations](#)

[PRUDENT ANTIMICROBIAL USE GUIDELINES FOR CATTLE](#)

[PHARMACOLOGY MODULE](#)

70 Large Animal Surgery

[Wikipedia](#)– often has very good pharmacological information

[For Future Reference | Create a drug reference table](#)

Pharmacology course notes and the online drug monographs

For Future Reference - Create a drug reference table

Exercises

Choose a species of interest (swine, beef cattle, dairy cattle, small ruminants, camelids) and create a table for the following drug classes to enable you to find drugs based on the criteria given on the preceding page. Not all drugs will be useful in all species.

Suggested table template:

Drug	Gram +/-	Static/ cidal	Indications	Distribution	Routes	Side effects	Restrictions

Amoxicillin			Oxytetracycline				
Ampicillin			Penicillin				
Ceftiofur (several formulations)			Sulfadimethoxine				
Enrofloxacin			Sulfamethazine				
Erythromycin			Tetracycline				
Florfenicol			Tilmicosin				
Gamithromycin			Tulathromycin				
Lincomycin			Tylosin				

RESOURCES

[Antimicrobial resistance learning site](#)

[Medications for camelids](#), P Walker- good summary of drugs

[Injectable antibiotics approved for use in beef cattle](#)

[Considerations for extralabel drug use in calves](#), FARAD Digest

[Small Ruminant Clinical Diagnosis and Therapy](#), S Haskell – starts with formulary

72 Large Animal Surgery

[Swine antibiotics summary](#), Dr. Zhitnitskiy

[Amoxicillin- current use in swine medicine](#), 2018 J Vet Pharm Therap – good discussion of first and second line drugs

Exercise 1. Adjusting drug frequency and doses for neonates

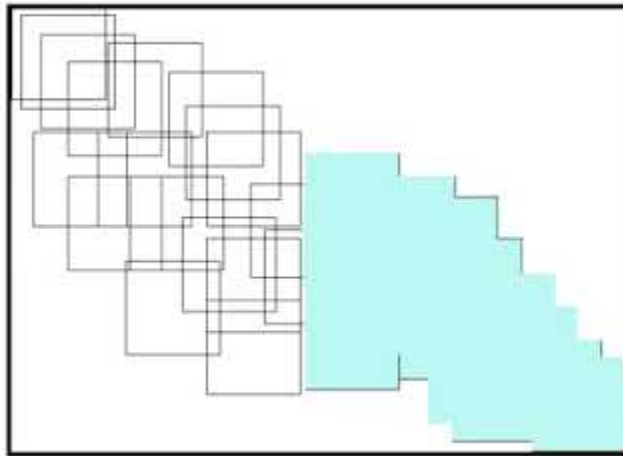
Exercises

What happens if you have a neonate? Neonates are mostly water (much more so than adults) and often don't have normal drug elimination due to immature kidneys.

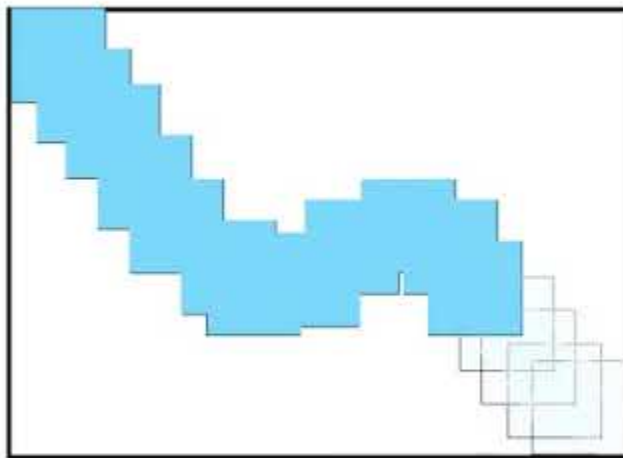


An interactive or media element has been excluded from this version of the text. You can view it online here: <https://open.lib.umn.edu/largeanimalsurgery/?p=122>

RESOURCES



A YouTube element has been excluded from this version of the text. You can view it online here: <https://open.lib.umn.edu/largeanimalsurgery/?p=122>



A YouTube element has been excluded from this version of the text. You can view it online here: <https://open.lib.umn.edu/largeanimalsurgery/?p=122>

Neonatal adjustments, 2003 VCNA

Note: the same principles apply for liver dysfunction and in neonates of other species:

[Effect of age on the pharmacokinetics of a single daily dose of gentamicin sulfate in healthy foals .](#)

Intravenous administration of gentamicin at a dose of 12 mg/kg bwt q. 36 h would be required in foals less than 2 weeks of age. In foals 2 weeks of age or older, a lower dose of 6.6 mg/kg bwt given q. 24 h was predicted to be adequate.

Food Animal Sedatives and Tranquilizers

The following are commonly used sedatives and tranquilizers in ruminants:

Acepromazine

Acepromazine is a tranquilizer or calming agent. It does not have analgesic properties. It can be given im or iv. It does a delayed onset of action; 10-15 minutes may be required even for iv administration. Ace is used for standing sedation protocols in cattle, rarely in SRC (small ruminants and camelids). Ace is very useful in bulls needing penile or preputial examination as the drug can be given im and the penis extrudes when the drug takes effect.

Dose iv or im: 10-40 mg (10mg/ml) per cow or bull or • 0.025 – 0.05 mg/kg IV

Side effects: Ace is safe in most healthy animals. Caution is needed in animals in shock or with anemia. Ace lowers blood pressure and hematocrit. While the penis does exteriorize in bulls, persistent erection is not a common problem.

<https://www.sciencedirect.com/topics/pharmacology-toxicology-and-pharmaceutifcal-science/acepromazine>

Xylazine

Xylazine is the most commonly used sedative in ruminants. Cattle and small ruminants are very sensitive to xylazine. Generally give these animals 1/10 the dose of a horse. Camelids are less sensitive than ruminants but more sensitive than horses. It can be given iv, im or sq and acts on alpha 2 receptors. It also provides analgesia and is synergistic with opioids for both sedation and analgesia.

Dose in cattle : 0.01 – 0.1 mg/kg IV or 0.02-0.2 mg/kg IM for standing sedation

- generally this is up to 20mg im in cattle.
- 0.2 mg/kg SQ xylazine resulted in similar effects to 0.2 mg/kg IM xylazine in calves.

Dose in camelids : 0.1 mg/kg IV provides sedation without recumbency

Side effects include decreased GI motility, bradycardia, nasal congestion, and decreased thermoregulation. Xylazine also causes hyperglycemia and increased urine production (this can be a problem in animals with urinary obstruction).

Xylazine can cause fatal pulmonary edema, particularly in sheep.

Xylazine stimulates uterine contractility and may cause abortion in late gestation cattle. It also makes Csections harder due to the increased uterine tone.

Detomidine

Detomidine is another alpha-2 agonist with longer duration effects than xylazine. Ruminants are NOT more sensitive to detomidine than horses, making dosing very similar in the two species. Because of the reduced sensitivity, detomidine

may be preferred if very low dosages are needed. Small amounts of xylazine are hard to administer and mistakes may lead to accidental overdose. Detomidine is safer in those situations. It can be given iv, im or sq.

Dose for sedation is 2.5 – 10 mcg/kg IV

Side effects are the same as for xylazine but more significant due to the longer duration. Detomidine does NOT stimulate uterine contractility and can be used in late gestation cattle.

Dexmedetomidine can be used very effectively in swine

<http://vetmed.illinois.edu/pot-bellied-pig-sedation-fast-facts-drug-protocols/>

Butorphanol

Schedule IV narcotic

Butorphanol (partial narcotic agonist/antagonist) is reported to provide sedation in ruminants and camelids but this effect is inconsistent. It is best used in combination with another sedative.

Dose: . 0.02 – 0.05 mg/kg IV may provide sedation in cattle that are sick

Side effects: May induce behavioral alteration such as restless and bellowing. Minimal change in heart rate, blood pressure or cardiac output when given alone

Reversal: naloxone (0.005-0.04 mg/kg in swine)

Diazepam and Midazolam

Schedule IV drugs.

Diazepam and midazolam are primarily used to relieve anxiety and enhance the sedative effects of other drugs. These drugs are more effective as sedatives in geriatric or ill small ruminants. The drugs are also used as anticonvulsants, muscle relaxants and appetite stimulants.

Diazepam and midazolam are the preferred sedatives for neonates. Neonates cannot adjust stroke volume so have significant cardiovascular depression with the alpha-2 agents. (Cardiac output = Stroke volume * Heart rate)

These benzodiazepenes are used interchangeably. Price variations are common so the cheapest drug is generally the one used.

Diazepam must go iv, is light sensitive and cannot be stored in plastic (syringes). It generally cannot be mixed with other drugs (ketamine is okay).

Midazolam can be given im and does not bind to plastic. It can be mixed with most other drugs and rectal administration may be effective.

Dose: 0.02 – 0.1 mg/kg IV

Side effects: both drugs are metabolized by the liver and the cytochrome P450 system. As such, they can be affected and can affect the metabolism of other drugs.

Reversal : flumazenil . (0.05 mg/kg im in swine)

Alpha agonist reversal agents

Due to the sensitivity of the ruminants to xylazine and other alpha agonists, it is important to know how to reverse accidental overdoses. However, the reversal agents carry risks as well. Generally give these drugs im or at a reduced dose slowly iv. Due to the short half life of these drugs, animals can also resedate when the reversal agent is given iv- the reversal agent wears off before the sedative does. The reversal dose can be split between iv and im routes to speed recovery and minimize resedation. Give the im dose first.

Yohimbine is not very effective in ruminants. Standard dose is 0.125-0.2 mg/kg. It does not reverse the GI inhibition effects of the alpha agonists. However, it is the cheapest.

Tolazoline is more effective at reversing the full effects of the alpha agonists and is the most commonly used agent. Standard dose in cattle is 1.1-2.2 depending on how long it has been since the xylazine was given. Administer slowly as it produces strong peripheral vasodilation and histamine-like reactions; rapid iv administration can cause death.

Camelids are very sensitive to the effects of tolazoline; use cautiously and keep animals intubated through recovery. IM or SQ routes should be safer than IV administration.

Atipamezole (20-60 ug/kg) tends to be cost-prohibitive but is effective at reversing full effects of alpha agonists. Used at 0.2 mg/kg im in pot-bellied pigs.

Idazoxan is dosed at 0.05 mg/kg iv

Overdosage or rapid iv administration effects the cardiovascular, respiratory and CNS systems. The biggest complication is hypotension from peripheral vasodilation.

Ket stuns and drug combos

See the [following chapter](#)

Reminder: When used, clients should be given withholding directions.

RESOURCES

[Podcasts](#), 2019

[Field Sedation and Anesthesia of Ruminants](#), VCNA 2016 – has good information on duration of effect of various protocols

[Ruminant and swine anesthesia](#), 2006

[Guidelines for anesthesia and analgesia in ruminants](#), 2017

Plumb's Veterinary Drug Handbook and app (lots of versions out there in different formats and prices)

Food Animal Standing Sedation Protocols

Most small ruminant procedures are performed with the patient recumbent.

Camelids will tend to [kush](#) (lie down) regardless of what you do but some will stay standing.

Pigs do the opposite of whatever you want and noisily.

Cattle are generally happy with standing sedation using only a local block or an epidural. Any surgical procedure in a non-anesthetized cow (standing or recumbent) involves some form of local analgesia. We typically use lidocaine as a local infusion, inverted “L” block, or paravertebral block for abdominal surgeries. An epidural block with lidocaine may be used for rectal or vaginal procedures.

The following protocols are useful for those dairy and beef cattle that are a bit more restless, worried or aggressive but not so recalcitrant that they throw themselves down on the ground (Scottish Highlanders) or so tired of life that they just lie down (pregnant Jerseys):

Acepromazine/Butorphanol or Acepromazine/Morphine

This combination provides neuroleptanalgesia for moderately to lengthy procedures. It is very useful for C-sections or penile exams/surgery in healthy animals that aren't hypotensive.

The onset of action is slow. Anticipate at least 20 minutes, even with iv administration. The drugs can be given iv, im or sq.

Acepromazine 0.035 mg/kg im + Butorphanol 0.05 mg/kg im or Morphine 0.1 mg/kg im (500kg cow = ~7.5 mg ace + ~10 mg butorphanol iv)

Xylazine/Butorphanol

This combination provides synergistic sedation + analgesia for shorter to midlength procedures.

The onset of action is rapid. The drugs can be given iv, im or sq. Too much sedation will lead to recumbency.

Xylazine 0.05 mg/kg im + Butorphanol 0.05 mg/kg im or Morphine 0.1 mg/kg im (500kg cow = ~10mg xylazine + ~10 mg butorphanol iv)

Acepromazine/Xylazine

This combination provides sedation for moderate to lengthy procedures. It does cause significant cardiovascular depression; animals must be healthy. It avoids narcotics and narcotic management.

The full onset of action is delayed up to 20 minutes.. The drugs can be given iv, im or sq. Too much sedation will lead to recumbency.

Xylazine 0.05 mg/kg im + Acepromazine 0.05 mg/kg im (500kg cow = ~10mg xylazine + ~10 mg acepromazine iv)

Standing Ketamine Stun (xylazine, ketamine, butorphanol)

This combination provides dissociative anesthesia and analgesia. Cattle get a stunned effect and don't seem to care about much of anything. Higher doses can lead to recumbency. Unfortunately, stunned cattle are resistant to attempts to make them stand up again.

The bovine standing ket stun is basically Llama lullaby with lower xylazine amounts.

Bovine ketamine standing stun:

- IV: xylazine 0.02 mg/kg, butorphanol 0.01 mg/kg, ketamine 0.05-0.1 mg/kg
 - for a 500-600kg cow, this is ~ 5 mg butorphanol, 10 mg xylazine and 20 mg ketamine (25-50 mg)
- Double the doses for im or sq stuns (less intense, longer duration). Try SQ unless the animal is very unruly.
- Morphine can be used in cattle instead of butorphanol (0.05 mg/kg iv).

[Cow prestun](#)

[Cow poststun](#)

Remember withholding requirements apply!

RESOURCES

[Chemical restraint of ruminants- ketamine stun techniques](#), Abrahamsen circa 2008

[Field sedation and anesthesia of ruminants](#), Seddighi and Doherty, VCNA 2016

[Local blocks](#), Kathy Whitman, Great Plains Education Center (ppt will download)

Food Animal General Anesthesia Protocols

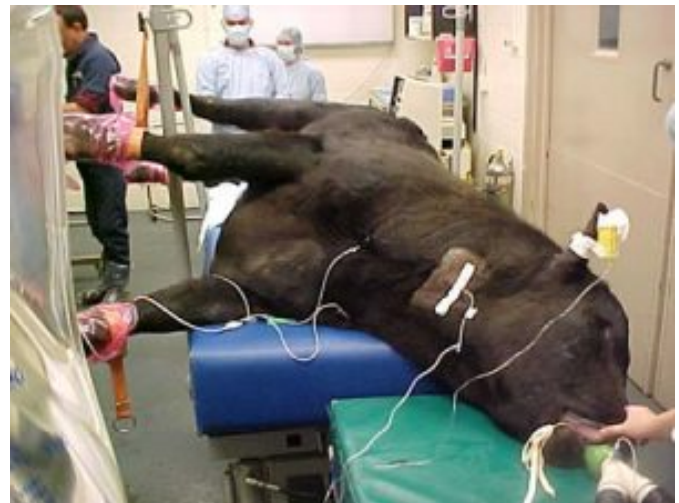As with other species, anesthesia involves

- **sedation** – xylazine (occasionally detomidine, dexmedetomidine, romifidine or acepromazine)
 - optional additional sedatives or analgesics -butorphanol or acepromazine (given with sedatives) AND/OR diazepam or midazolam (given at induction)
- **induction** – ketamine, telazol, guaifenesin
- **maintenance** – repeated doses of sedatives and induction agents or infusion of drugs and drug combinations

Ruminants, camelids and pigs are generally **not** intubated or maintained on inhalant anesthetic agents except in specialty or referral settings.

Ruminants do like to regurgitate and drool during anesthesia. Atropine only makes the drool thicker so we don't use it. It is important to ensure that drool and rumen contents drain out. The nose should be lower than the poll, often with the neck elevated with a pad to ensure everything runs downhill and out, not back into the airways.

Ruminants also like to bloat when sedated. This impairs respiration as the rumen compresses diaphragmatic vessels and impairs return of blood to the heart. To minimize rumen fill, adult large ruminants are held off feed for ~ 24 hours when possible (small ruminants need ~18 hours). Many references recommend removal of water. This may not be necessary unless animals are drinking excessively.



<https://instruction.cvhs.okstate.edu/vmed5412/FoodAnimals.htm>

Monitoring is typically through vital signs (pulse quality and rate, respiratory quality and rate, ocular reflexes and positioning). Pulse oximeters are portable and easy to use. Doppler blood pressure monitoring is useful particularly in smaller patients.

Common induction and maintenance agents:

Ketamine

Schedule III

Ketamine is a dissociative anesthetic agent used to induce recumbency after sedation when given at higher doses.

It is commonly combined with other drugs (xylazine, diazepam or midazolam, guaifenesin) to prolong the anesthetic duration and to enhance relaxation.

Ketamine is a relatively safe drug with minimal cardiovascular or respiratory depressant effects. "It is hard to kill with ketamine." Unlike in horses, there is minimal excitement phase in ruminants. Both the sedative and induction agents can be combined in the same syringe (eg ketamine/diazepam or xylazine/ketamine) and given at the same time.

Cattle:

- xylazine 0.05-0.1 mg/kg and ketamine 2 mg/kg iv (double for im administration)
- diazepam/midazolam 0.1 mg/kg and ketamine 2 mg/kg iv
- recumbent iv ketamine stun: xylazine 0.05 mg/kg + butorphanol 0.05- 0.1 mg/kg + ketamine 0.5 -1 mg/kg
 - for a 500-600kg cow, this 20/25/250 mg of B/X/K
- infusion: 1-1.5g ketamine added to 1L electrolyte solution along with 50 mg xylazine or with 25-50 mg benzodiazepenes administered as iv drip

Llamas: xylazine 0.4-0.5 mg/kg and ketamine 4-6 mg/kg im

Alpacas: xylazine 0.6-0.8 mg/kg and ketamine 6-8 mg/kg im

Swine: xylazine 2 mg/kg and ketamine 20 mg/kg im

Telazol and Telazol combinations

Schedule III

Telazol is a combination of tiletamine (dissociative agent like ketamine) and zolazepam (benzodiazepene like diazepam). It lasts longer than ketamine/diazepam but is more expensive.

The drug needs to be reconstituted prior to use and then has a limited shelf life.

Telazol-xylazine: reconstitute telazol with 500 mg xylazine instead of the standard diluent. Give 3-5ml to large bulls im.

TKX: reconstitute telazol with 100-150mg xylazine and add ketamine to total volume of 5 ml. Useful with pole syringe administration or dart gun for wild or aggressive cattle (5ml/600-800 kg).

Other example protocols

cattle: 0.1 mg/kg xylazine + 1-2 mg/kg telazol iv

sheep: 2-4 mg/kg telazol iv

llama: 0.25 mg/kg xylazine + 2 mg/kg telazol im

swine: 2.2 mg/kg xylazine + 4.4 mg/kg telazol im

GG and Triple Drip

Triple drip is a combination of xylazine, ketamine and guaifenesin used to maintain anesthesia.

Xylazine (50-100 mg), ketamine (1000 mg or 1 g), in a liter of 5% guaifenesin (50mg/ml), given at 1ml/lb/hr.

Guafenesin (GG) is a muscle relaxant that helps counteract the rigidity associated with ketamine. The combination must be compounded and can be explosive if done incorrectly.

It can be used for induction (0.5-2 ml/kg) but has a slightly delayed effect so overdosing is a risk. However, the gradual induction minimizes the apnea risk.

Maintenance with triple drip is relatively easy in cattle. The anesthetic plane is rapidly adjusted by changing the drip rate (0.5-2 ml/kg/hr).

Side effects : Very irritating perivascularly. Use a catheter. Overdoses of GG can lead to increased muscle tone, making the animal appear too light vs too deep. Ruminants are sensitive to xylazine and xylazine may cause pulmonary edema, especially in sheep.

Double drip

Double drip infusion avoids the risk of xylazine for ruminant anesthesia maintenance.

Ketamine (1mg/ml or 1g/L) is added to 5% Guafenesin.

Butorphanol or morphine should be added for analgesia. Butorphanol (0.05-0.1 mg/kg IV or IM in smaller ruminants, 0.02-0.05 mg/kg IV or IM in larger ruminants) or morphine (0.05-0.1 mg/kg IV or IM).

<https://www.acvs.org/files/proceedings/2011/data/papers/211.pdf>

Llama lullaby

To one bottle of ketamine (10 ml of 100 mg/ml) add 1 ml of 100 mg/ml xylazine and 1 ml of 10 mg/ml butorphanol. Given 1 ml /50 lbs BW IM for 40-50 min procedures.

More specific doses of ket stuns for camelids:

- xylazine 0.22-0.55 mg/kg + ketamine 0.22-0.55 mg/kg + butorphanol 0.08-0.11 mg/kg im

Please double check all doses in these protocols before using. Withholding requirements do apply to these drugs! Nothing is approved so AMDUCA rules also apply

RESOURCES

[Podcasts](#), 2019

UMN Students can self enroll in the [anesthesia moodle site](#). Key word is sleepy

[Chemical restraint of ruminants- ketamine stun techniques](#), Abrahamsen circa 2008

[Field sedation and anesthesia of ruminants](#), Seddighi and Doherty, VCNA 2016

[Ruminant and swine anesthesia](#). OK State, Lyon Lee

84 Large Animal Surgery

[Guidelines on Anesthesia and Analgesia in Ruminants](#), UMI, 2018

[Large Ruminant Anesthesia](#), 2012 ACVS

[Allweiler FA anesthesia lecture](#) ppt

Plumb's Veterinary Drug Handbook and app (lots of versions out there in different formats and prices)

Camelid Sedation and Anesthesia

Camelid sedation



A YouTube element has been excluded from this version of the text. You can view it online here: <https://open.lib.umn.edu/largeanimalsurgery/?p=1063>

Camelid GA

General off feed 12-18 hours, free choice water.

Camelids can regurgitate and aspirate so head position should be managed to ensure any regurgitation drains out of the mouth, not back down the throat, similar to small ruminants.

Sick camelids tend to develop metabolic issues after anesthesia so should be carefully monitored.

The alpha₂ agents may be reversed in camelids but yohimbine is expensive and tolazoline has significant side effects. Most use atipamezole and cautiously.

PS : It is really hard to open the mouth wide enough for intubation if the halter is still on. Just saying.

Llama lullaby

To one bottle of ketamine (10 ml of 100 mg/ml) add 1 ml of 100 mg/ml xylazine and 1 ml of 10 mg/ml butorphanol. Given 1 ml /50 lbs BW IM for 40-50 min procedures.

More specific doses of ket stuns for camelids:

xylazine 0.22-0.55 mg/kg + ketamine 0.22-0.55 mg/kg + butorphanol 0.08-0.11 mg/kg im



A YouTube element has been excluded from this version of the text. You can view it online here: <https://open.lib.umn.edu/largeanimalsurgery/?p=1063>

Resources

[New World Camelids](#), UTenn, Tom Doherty, 2011

[Chemical restraint, anesthesia and analgesia for camelids](#), Abrahamsen, VCNA 2009

[Camelid anesthesia and drugs](#)– Merck Manual

[Medications for Camelids](#), PG Walker


Swine Sedation and Anesthesia

“Piggy Magic” intramuscular sedation.

- Butorphanol 0.2 mg/kg
- Midazolam 0.2 mg/kg
- Ketamine 2-6 mg/kg

We typically use the higher end of the ketamine dose. Mix together in a syringe and give im. This protocol provides a decent plane of sedation for minor procedures and lasts about 30-45 minutes. Good for casting, radiographs – basically for anything that requires them to lie still.

Also try [forking](#) – it really works to calm them and has a slight residual. Useful for injections, temperature taking, listening to hearts, etc.



A YouTube element has been excluded from this version of the text. You can view it online here: <https://open.lib.umn.edu/largeanimalsurgery/?p=1071>

[Pot-bellied pig sedation](#), 2017

[Anesthesia of pot-bellied pigs](#), 1998

[Ruminant and swine anesthesia](#), 2006

[Guidelines on Anesthesia and Analgesia in Swine](#), UMI, 2018

[Practical sedation and anaesthesia of pigs](#), In practice, 2007

SEDATIVE AGENTS COMMONLY USED IN THE PIG		
Agent	Dose rate	Route of administration
Azaperone	1 to 8 mg/kg	Deep intramuscular
Azaperone and ketamine	1 mg/kg 5 mg/kg	Together deep intramuscular
Azaperone, ketamine and butorphanol	1 to 2 mg/kg 5 mg/kg 0.1 to 0.2 mg/kg	All together deep intramuscular
Acepromazine	0.03 to 0.1 mg/kg	Deep intramuscular
Acepromazine and ketamine	0.03 to 0.05 mg/kg 5 mg/kg	Together deep intramuscular
Midazolam	0.1 to 0.5 mg/kg	Deep intramuscular or intravenous
Midazolam and ketamine	0.2 mg/kg 5 mg/kg	Together deep intramuscular
Diazepam	0.5 to 2 mg/kg 1 to 10 mg/kg	Intravenous Deep intramuscular
Diazepam and ketamine	2 mg/kg 5 to 10 mg/kg	Intravenous followed by intravenous to effect
Xylazine, ketamine and butorphanol	1 to 3 mg/kg 5 mg/kg 0.1 to 0.2 mg/kg	Together deep intramuscular

Note that none of the drugs listed above are licensed for use in pigs. An agent can only be used if it appears in one of the annexes (I to IV) of the Council Regulation (EEC) 2377/90

[Anesthesia agents and complications in VPBP](#) (vietnamese pot bellied pigs), JAVMA 2011

Objective—To document complications associated with preanesthetic and anesthetic agents used in Vietnamese potbellied pigs and identify predictors of complications.

Design—Retrospective case series.

Animals—27 potbellied pigs (14 female and 13 male) ranging in age from 0.25 to 15 years old and ranging in body weight from 5.9 to 169 kg (13.0 to 371.8 lb) that were anesthetized on 32 occasions between 1999 and 2006.

Procedures—Data, including perianesthetic management, anesthetic agents and dosages, complications, and outcome, were retrieved from medical records. Patient information, anesthetic agents, and duration of anesthesia were evaluated as predictors for development of complications.

Results—Anesthesia was maintained with isoflurane or sevoflurane during 30 anesthetic episodes. Commonly used premedicants were butorphanol, atropine, and midazolam administered in combination with xylazine or medetomidine and a combination of tiletamine-zolazepam and butorphanol. Anesthesia was induced with an

inhalation agent on 15 occasions, via injection of ketamine on 10 occasions, and via injection of propofol on 3 occasions. Complications included hypoventilation (16/24 [67%]), hypotension (16/25 [64%]), hypothermia (15/31 [48%]), bradycardia (9/32 [28%]), and prolonged recovery time (7/32 [22%]). None of the factors evaluated were associated with development of these complications. All pigs survived anesthesia.

Conclusions and Clinical Relevance—Results suggested that a variety of anesthetic agent combinations can be used to provide anesthesia in potbellied pigs with satisfactory outcomes. Although there were high incidences of hypoventilation, hypotension, and hypothermia, no specific anesthetic agent was associated with development of these complications.

Small ruminant sedation and anesthesia

Drugs

Typical general anesthesia protocols for healthy small ruminants

ANESTHESIA	Drug	Dose (mg/kg)	Route
Pre-operative analgesia	Flunixin meglumine	1.1 mg/kg	Iv
Sedative (if needed)	Acepromazine	0.2 mg/kg	im
Induction protocol option 1	Xylazine	0.05 mg/kg	iv
	Butorphanol	0.05-1 mg/kg	iv
	Ketamine	0.5-0.1 mg/kg	Iv
Induction protocol option 2	Midazolam	0.1-0.2 mg/kg	Iv
	Ketamine	2-5 mg/kg	iv
Maintenance	Redosing, iv infusions, inhalant anesthesia		

Remember : the alpha2 agonists (xylazine, detomidine) can cause fatal pulmonary edema in sheep! If you must use it, give it slowly and be prepared to reverse it.

Xylazine also stimulates urine production and is not ideal in blocked goats unless you can perform cystocentesis or surgery.

Local blocks are good things and can minimize the need for general anesthesia. Go easy. Assume maximum dose of 6 mg/kg.

Atropine is not useful in stopping salivation and can be detrimental as it makes the saliva thicker.

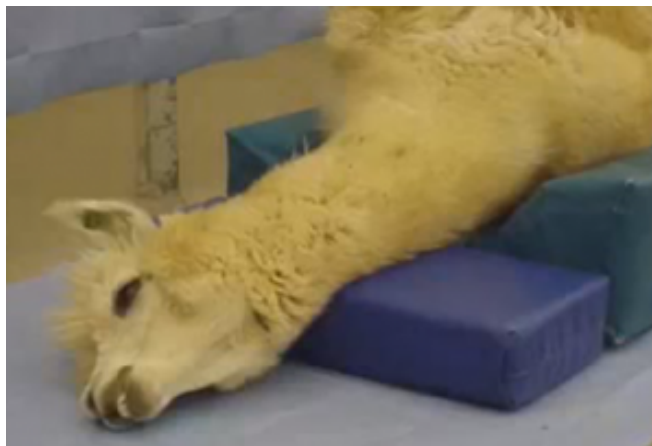Peri-anesthetic Support

Food should be withheld for 12-18 hours to minimize bloating in adult animals. Neonates should not be fasted more than 4 hours. Because of the danger of pregnancy toxemia in late gestation, those animals should be minimally fasted or carefully supported.

Young small ruminants can become hypothermic; this is usually not a problem in older ruminants.

Hypoventilation and apnea are not uncommon. Fluid therapy and supplemental oxygen should be considered for longer procedures.

Due to copious salivation and high risk of regurgitation, animals should be positioned so the head is tilted downward. It can help to elevate the neck, creating a “V” at the poll or withers.



head tilted down for drainage of saliva and regurgitant

Monitoring

Pulse oximetry and other monitoring devices can be very useful in small ruminants. Without these tools, monitoring is challenging and requires careful attention. If in doubt, reduce the anesthetic depth until signs of light anesthesia become apparent.

For most anesthesia, the pupil should be central and moderately constricted. Rotation of the globe is not useful for monitoring and the corneal reflex should be maintained.

Too light:

- Mydriasis is observed at a light plane and again at a deep plane.

- Chewing, esophageal activity and limb movement indicates too light of a plane.
- Increased muscle tone (jaw tone)
- Nystagmus

Too deep:

- Mydriasis combined with no palpebral reflex is likely a deep plane.
- Decreased muscle tone (jaw tone); some jaw tone persists even at deep planes
- Slowed heart rate
- Shallow or paradoxical respiration (chest contracts during inhalation vs expands)

Recovery

Recovery from anesthesia is usually uneventful. Hypothermia will prolong recovery so animals should be kept warm and dry. Animals should be placed in sternal recumbency and, if used, the endotracheal tube left in position with the cuff inflated until the animal can swallow. Once the animal can cough and swallow the tube can be removed; the cuff can be left inflated during removal if regurgitation occurred.

Resources

Seddighi and Doherty. [Field sedation and anesthesia of ruminants](#), VCNA 2016

[Anesthesia and Pain Management](#) Goplen 2016

AD Galatos. [Anesthesia and Analgesia in Sheep and Goats](#). Vet Clin Food Anim 27 (2011) 47–59

[Drugs approved for small ruminants](#), JAVMA 2004


[Small ruminant clinical diagnosis and therapy](#), 2001 (starts with a formulary)

FA GI Diagnostics & GI Surgery Principles


Ruminant Pings

Left sided pings


- Rumen
- LDA
- Uterus (bilateral)
- Pneumoperitoneum (bilateral)



Rumen or pneumoperitoneum ping.




LDA




Uterus

Right sided pings


- duodenum
- abomasum
- small intestine
- cecum
- spiral colon
- uterus (bilateral)
- pneumoperitoneum (bilateral)
- rectum (post palpation)



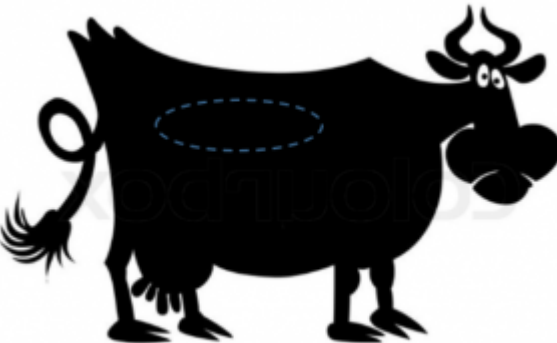
RDA




Duodenal ping




Spiral colon or small intestinal pings



cecum or pneumoperitoneum



rectal ping



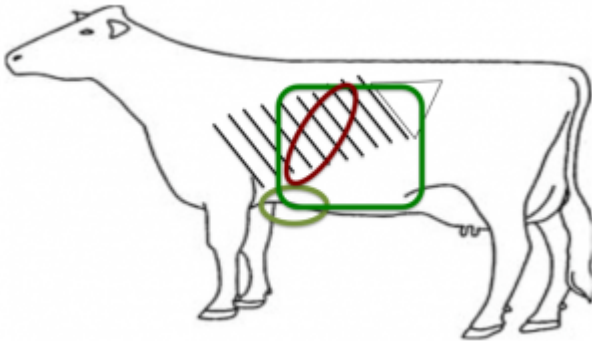
uterus

Abdominal ultrasound

Ultrasound is a valuable tool for identifying peritoneal and GI tract abnormalities in cattle. Many structures look similarly when normal; location is an important key as is knowing the normal sonographic appearance. Most of these evaluations can be performed with a linear probe.

Start by scanning ventrally for fluid pockets. Check to the right of midline and under the flank fold, just beside the udder.

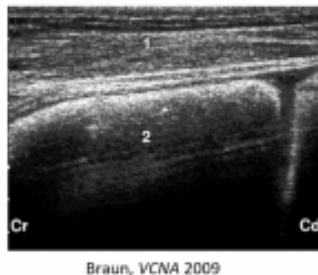
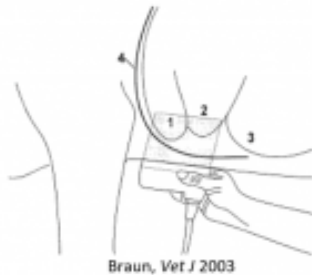
Left side evaluation



Left side structures are the **reticulum**, **rumen**, and **spleen**.

Reticulum

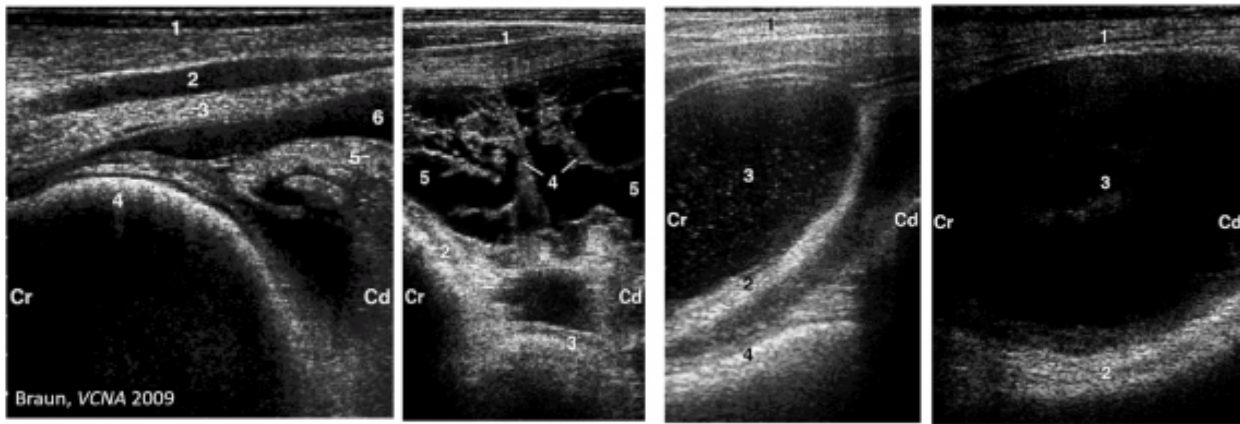
The reticulum can be visualized both the left and right of the sternum, ventral to the point of the elbow.



The reticulum normally has a half-moon shape. Due to the gas content, foreign bodies and magnets are not visible. In this diagram, 1 is the reticulum, 2 is the craniodorsal blind sac of the rumen, and 3 is the ventral sac of the rumen. Regular contractions that can be evaluated to determine whether motility is normal. The reticulum should have one biphasic contraction per minute; this is

typically immediately followed by a rumen contraction.

Scan the caudoventral reticular wall to evaluate for hardware related reticuloperitonitis and reticular abscesses.

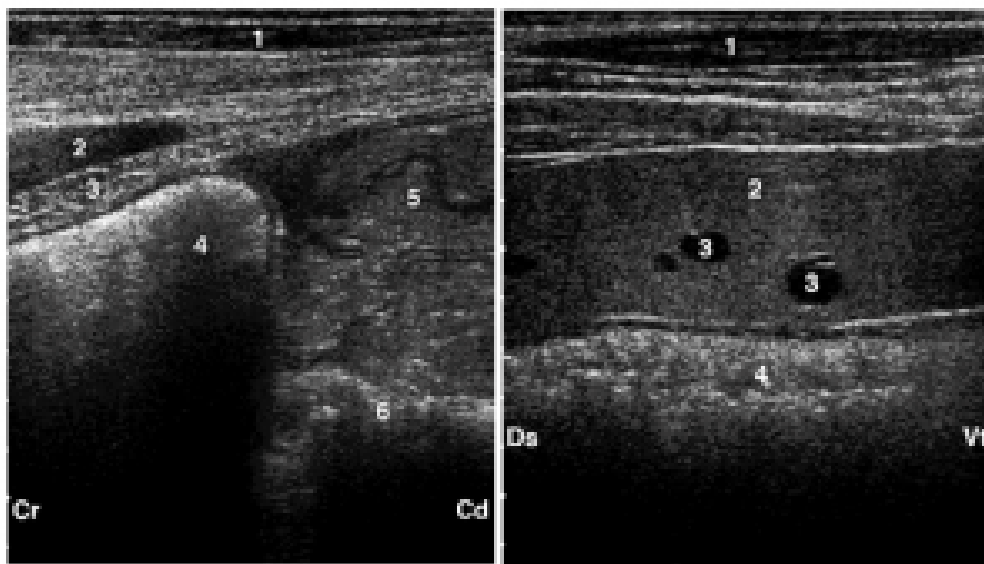


Reticuloperitonitis

Reticular abscess

Rumen

The rumen is visible along most of the left side. The gas cap means only the external layer is visible dorsally. More fluid contents can be seen ventrally.



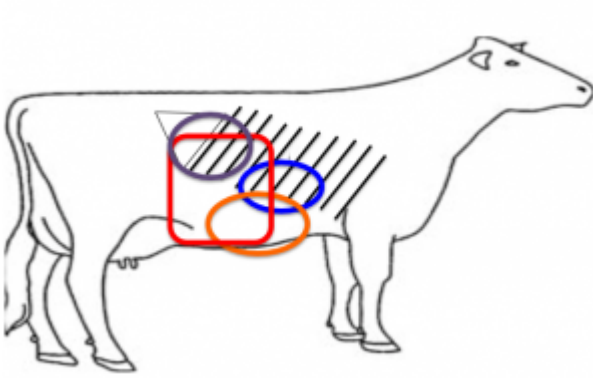
From Braun, VCNA 2009. 6 is rumen

4 is rumen, 2 is spleen

Spleen

The spleen has a hyperechoic texture with prominent vessels. Occasional abscesses can be observed within the spleen.

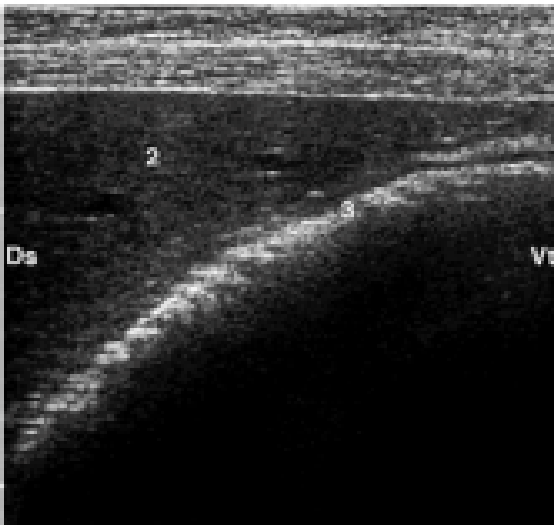
Right side evaluation



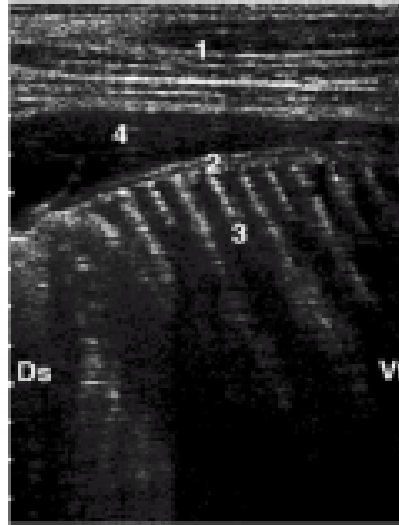
Structures on the right side include the **omasum**, **abomasum**, **small intestine** and **large intestine**.

Omasum

The omasum is a crescent shaped structure on the right, in the 6th to 11th intercostal spaces (ICS). It is easiest to see in the 9th ICS since it is closest the body wall in the 8th-9th ICS. The omasum should not contract. The leaves are not visible unless there is fluid reflux from the abomasum.



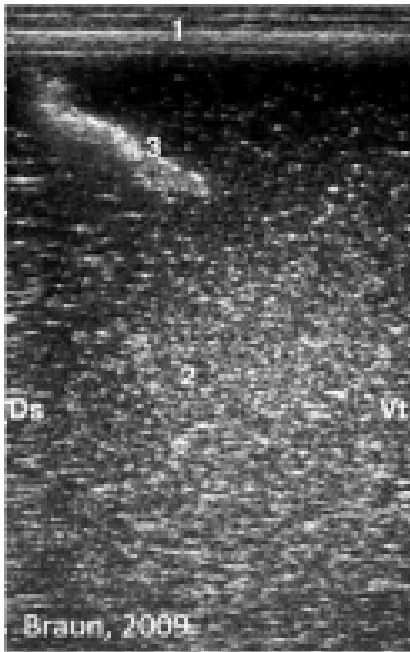
Normal omasum



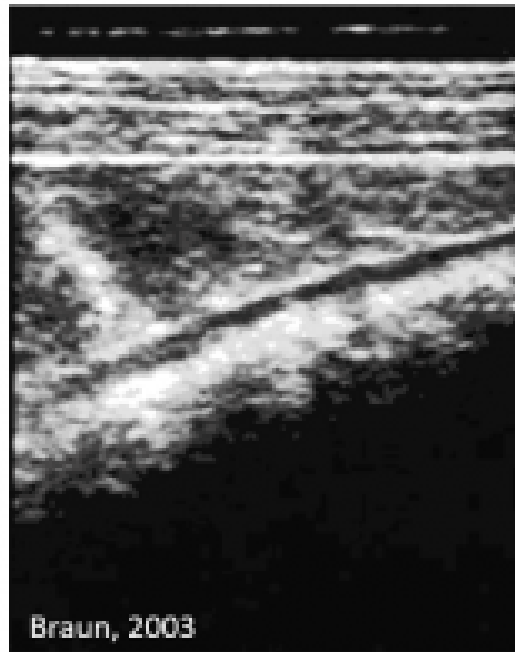
Omasum with fluid reflux

Abomasum

The abomasum is typically found 10 cm caudal to xiphoid on the midline and just to either side. Contents have a heterogenous echogenicity. A dorsal gas cap may be evident normally and is typically the only change seen with displaced abomasum. Location is important for diagnosis. With an RDA, the normal liver is blocked by the displaced gas filled abomasum. No obvious changes are visible with abomasal ulceration unless peritonitis occurs.



Normal abomasum

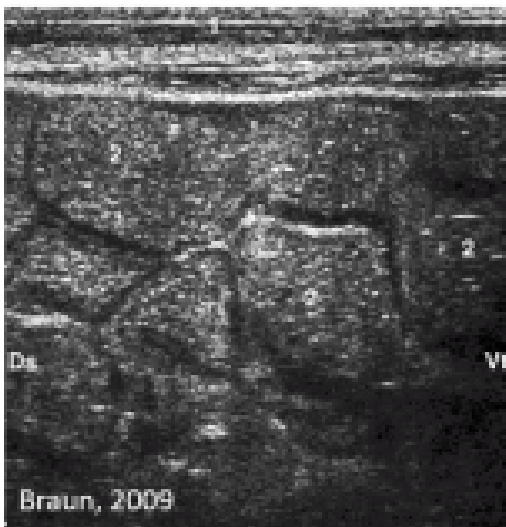


Displaced abomasum with gas cap

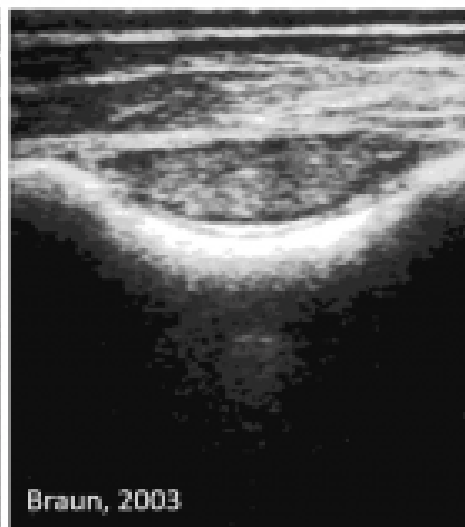Small Intestine

Small intestine is visible ultrasonographically from the tuber coxae to the 8th ICS ranging from the transverse processes dorsally to the midline ventrally.

The duodenum is wrapped in omentum in the central aspect of the right paralumbar fossa.

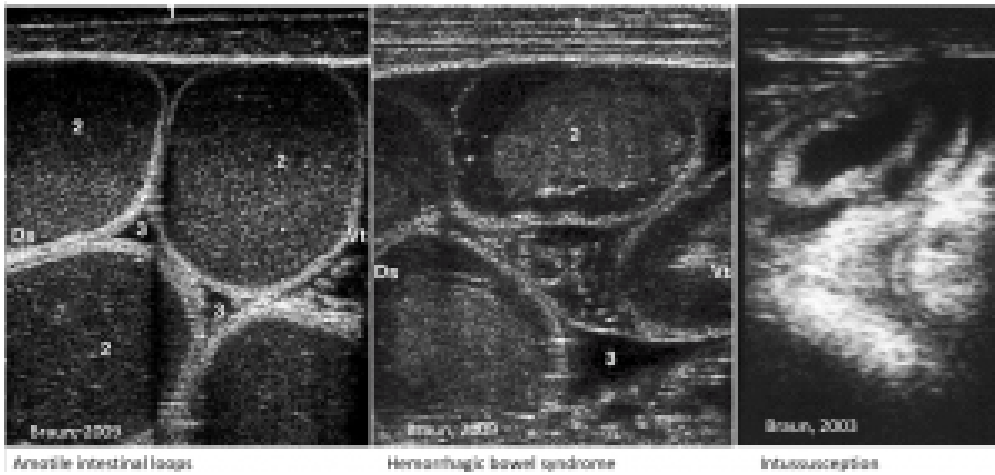


Normal small intestines



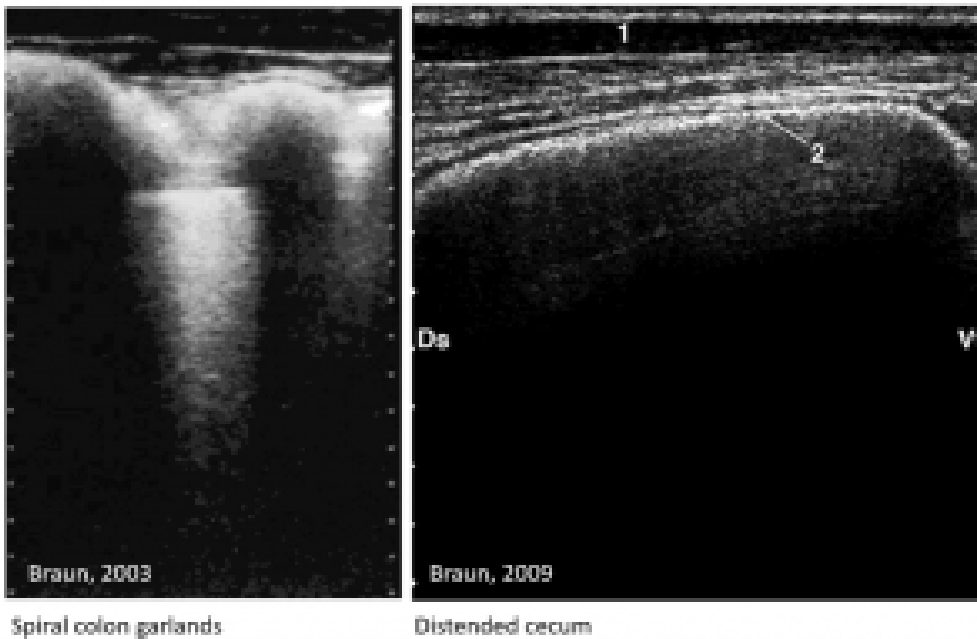
Normal duodenum

Detectable abnormalities include intestinal ileus or motility disturbances, hemorrhagic bowel syndrome and intussusceptions.

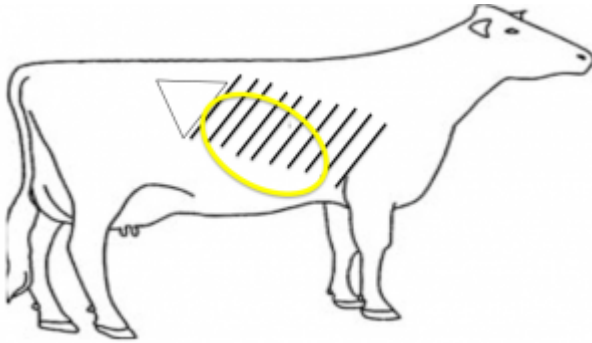


Large Intestine and Cecum

The large intestine is a gas filled structure medial to the descending duodenum. The spiral colon will often have a garland appearance. The cecum is nondescript but can be identified when distended and resonant.

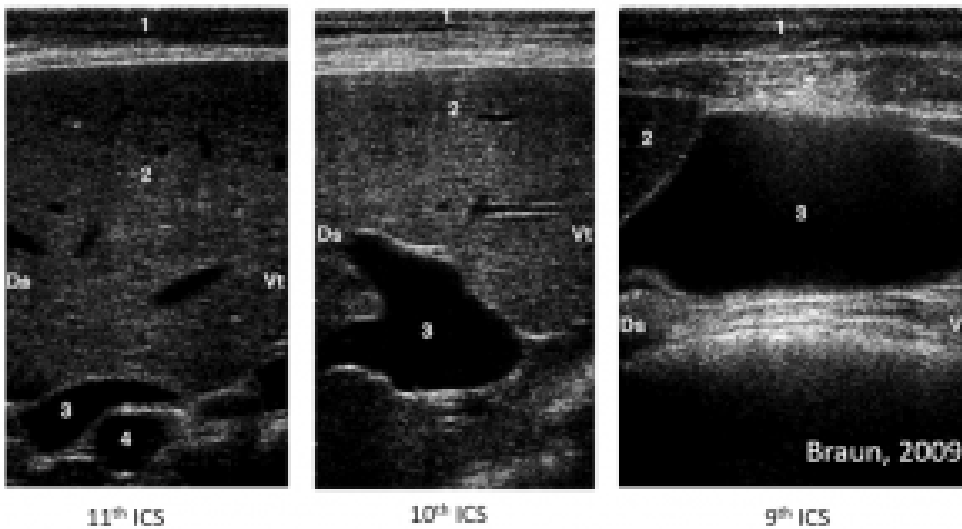


Liver



The liver is visible ultrasonographically on the right, extending from just caudal to the last rib up to the 5th ICS. It is often partially obscured by the lung.

Normal liver is fairly homogenous with visible gall bladder and biliary tree.



Resources

Braun. [Ultrasonography of the Gastrointestinal Tract in Cattle](#). VCNA 25 (2009) 567–590

Braun. [Ultrasonography of the Liver in Cattle](#), VCNA 25(2009) 591-609

Braun. [Ultrasonography in gastrointestinal disease in cattle](#). The Veterinary Journal, 2003, Vol.166(2), pp.112-124

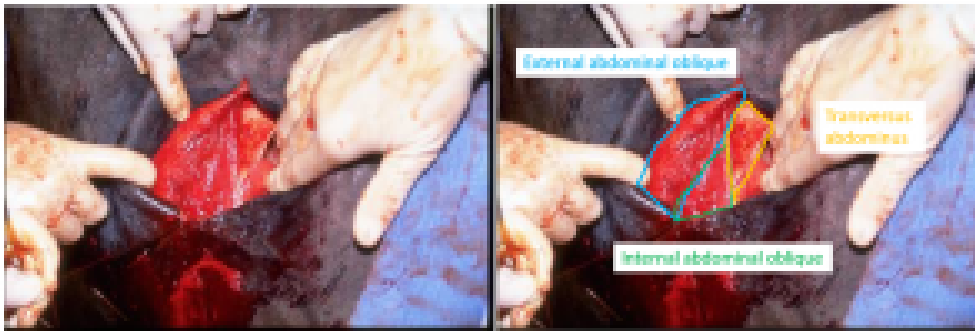How to - Standing GI Surgery

Indications

Standing GI surgery is a common field and referral procedure in cattle. Right flank approaches allow for abdominal exploratory, correction of abomasal displacements, typhlotomy and other procedures. Left flank approaches allow for rumenotomy, Csection and correction of LDAs.

Relevant anatomy

The musculature of the flank includes the exterior abdominal oblique, the internal abdominal oblique and the transversus. Each muscle layer becomes progressively thinner, with the transversus muscle usually being a fibrous sheath. There is no strength layer in the flank – muscles tear easily.

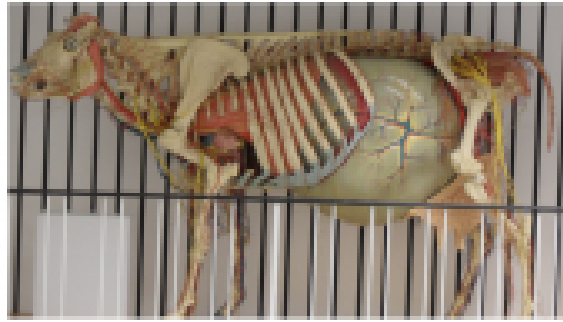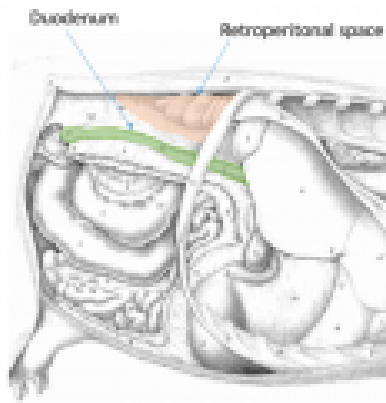


The nerve sensation to the flank muscles comes from the spinal nerves T13, L1 and L2. These can be blocked using local infiltration or paravertebral blocks. The peritoneum is difficult to numb.

The vasculature supply for the area is robust, leading to good healing.

The abdominal cavity is under negative pressure normally. When the peritoneum is opened, air flows in, creating an audible noise. If air does not flow in, the main differentials are recent abdominal surgery or a ruptured viscus (leaking air).

The retroperitoneal space is relatively large in cattle. If an incision is made too dorsally, this space will be visible. The surgeon may feel they have encountered lots of adhesions. In the peritoneal cavity, the duodenum should be directly visible in the incision on the right and the rumen on the left.



Preoperative management

Food restrictions: NA

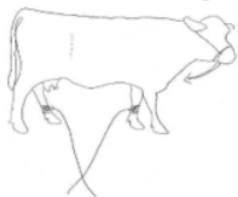
NSAIDs/analgesics: Recommended preoperatively. Flunixin meglumine 1.1-2.2 mg/kg iv is standard.

Antibiotics: Recommended. As cows can wall off infection, there can be surprises inside. If milking, ceftiofur 2.2 mg/kg im is standard. In beef or non-lactating cattle, other options do exist. Remember: the label dose of procaine penicillin is ineffective!

Local blocks: A [line block](#), [inverted L](#) or [paravertebral](#) are all reasonable options.


Position/preparation: Healthy cows tolerate standing surgery very well. Many do not need sedation but will do fine with just a local block. If the cow is hypocalcemic or if the mesentery is stretched (by lesion or by exposure for evaluation), the cow may lie down. If this is a concern, we try to make it more likely that she will land incision side up.

Head toward incision; ropes
between outside legs



Place ropes on the far legs and tie her head toward the incision. If she starts to lie down, nonsurgical personnel pull on the ropes and pull her legs out from under her. With the head tied in this direction, she is also more likely to fold that way and stay incision side up.

The flank is clipped, scrubbed, and the block performed.




Clipping over the backbone makes cleaning easier. Prep is usually a degreaser, 3 scrubs with water rinses. After the block, a final scrub and alcohol rinse.

Usually the most challenging part of the procedure is the block. Cows do not like needles. Options include a tail jack, towel over the face, or [sedation](#). Or all 3. The [EasyBossE](#) is another humane restraint device that may help.



mad cow



stunned cow

A sterile paper drape can be clipped to the skin of the back

using towel clamps. This is a cheap way to keep things clean and to minimize suture contamination. Gowns are less useful than the drape...



Putting the clamps on at the same time minimizes injury as the doesn't know who to kick. A nonsterile tech can help. Positioning the towel clamps as far apart on the back of the cow keeps the drape useful and not in your way

Surgeons should wear gloves and sterile sleeves. Double gloves are useful if a contaminated procedure is expected as the top layer of gloves can be removed quickly. Caps and masks are recommended but not often worn. Gowns are not helpful for sterility unless water impermeable but do help keep the surgeon a bit cleaner and warmer.

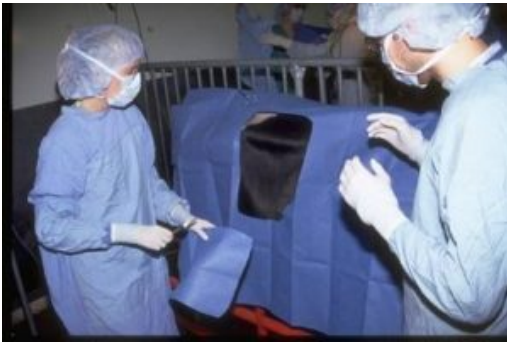Surgery Supplies:

- Standard surgery pack

- Sterile sleeves for internal palpation
- Scalpel blade and handle
- 2 or 3 absorbable suture material for muscle closure
- 3+ nonabsorbable suture material for skin closure
- Biopsy instruments and formalin- optional
- DA simplex – long flexible tubing attached to a 10ga needle for viscus decompression -optional

Surgical procedure

After the cow is prepped, blocked and draped, a large window is cut in the drape. This window should be as large as possible without exposing any hair or facilities (side gate etc).




A vertical incision is made, typically in the center of the paralumbar fossa, starting about 10 cm below the transverse processes and extending about 20 cm. [If you are struggling later, make the incision longer. It heals side to side, not end to end.]

Incise through the external abdominal oblique.

To safely and quickly cut through each muscle layer:

the hole should be big enough to not be in your way

- First determine how thick a muscle is by starting with a 3 cm incision at the top, shaving until you reach the white fascia layer.
- Once the fascia is seen, slide a set of long thumb forceps under the external abdominal oblique and above the fascia (it should go easily), and turn these so the tongs are flat, creating a “groove director” between them.
- Use the center “groove director” as a guide for your incision. If the cow moves, the thumb forceps will help protect the deeper layers from accidental incision and enable you to incise without worry.



Incise the internal abdominal oblique (it will be thinner). Tent the transversus and cut with scissors or with the blade turned so the cutting edge is facing the surgeon. This is to ensure you don't cut too deeply.

Alternative to avoid: occasionally the muscles are split along their fibers rather than being cut. This is referred to as gridding. It is useful in rumenostomies but otherwise not useful. It creates a small deep hole that is very difficult to close.

Incise the peritoneum, listening to see if air rushes in. Extend the peritoneal opening to allow easy palpation with one arm.

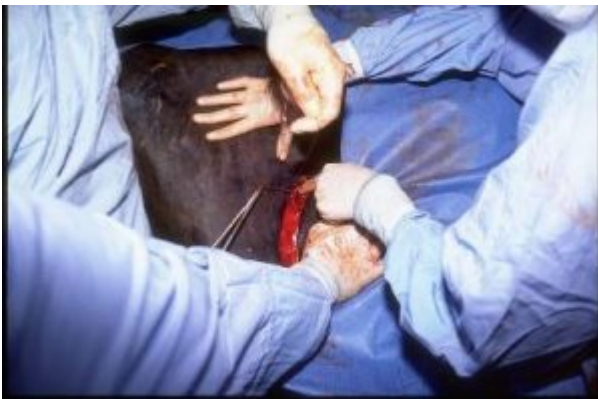Place a sterile sleeve on your left arm (regardless of whether left or right handed). If it is large for your hand, add a sterile glove over the top to improve your palpation skills. Generally this is one size larger than your normal glove size. ****REMOVE ANY HEMOSTATS USED FOR BLEEDERS****. Finding these in the belly is somewhat challenging.

Exploration should be done from clean to potentially (or known) contaminated regions. In cattle, the riskiest areas are by the reticulum (hardware disease), liver (abscesses) and abomasum (perforated ulcers). As all of these are cranioventral, we typically start caudodorsal and to the left, followed by caudo ventral, craniodorsal and finally, cranioventral.

A prophylactic omentopexy is often performed at the conclusion of right flank procedures, even if not for abomasal displacement.

Closure:

The internal abdominal oblique and transversus can be closed as a unit, using 2 chromic gut or similar suture in simple continuous pattern. High levels of air in the abdomen can lead to pain so the cows are often "burped" during closure. Start the closure at the ventral aspect of the muscle layers. As you reach the top, preplace the final sutures and the first throw but do not tighten. Push in on the cow's flank to push the gas out. With the flank still shoved in, tighten the last throw and then tie.



The external abdominal oblique is typically closed by itself in a similar fashion but no burping required.

Some practitioners close all muscles together. As muscles tear, that can be risky if the cow falls during the healing period.

The skin is closed with a Ford Interlocking pattern using nonabsorbable suture in size 3 or 5. This is a great time to finish with an Aberdeen knot. A cruciate or simple interrupted suture is often placed at the ventral aspect. This can be removed to allow drainage if seroma or abscess develops.

Hint: Suturing cow hide is like sewing leather. If you try to insert your needle at an angle to the skin, you make it harder. If the needle is perpendicular to the skin, it goes in easier. The easiest way to do this is the change how you hold the skin. Make the skin perpendicular to the needle. It also helps to “choke up” on the needle – grasp it closer to the tip.



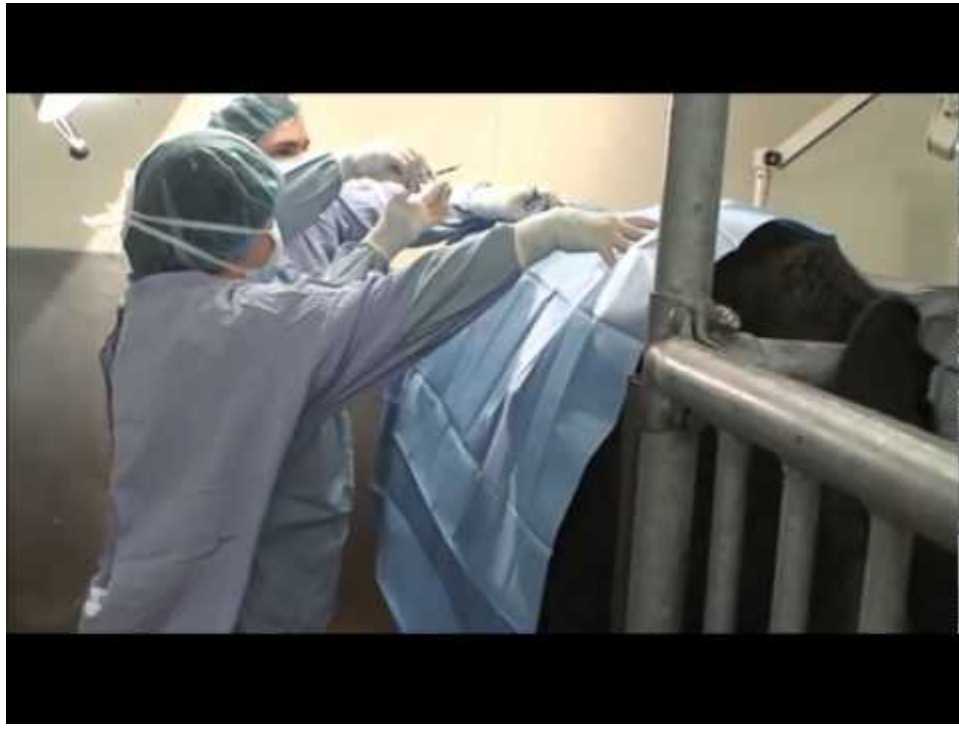Postoperative care

- Suture removal in 10-14 days
- Monitor the cow for any signs of infection or peritonitis
- Consider rumen transfaunation if available

Complications

- Incisional dehiscence (rare)
- Incisional infection (common)
- Peritonitis

Videos



A YouTube element has been excluded from this version of the text. You can view it online here: <https://open.lib.umn.edu/largeanimalsurgery/?p=3025>



A YouTube element has been excluded from this version of the text. You can view it online here: <https://open.lib.umn.edu/largeanimalsurgery/?p=3025>



A YouTube element has been excluded from this version of the text. You can view it online here: <https://open.lib.umn.edu/largeanimalsurgery/?p=3025>

Resources

[PRACTICAL APPROACHES TO ON-FARM BOVINE SURGERY](#), Dr. Gordon Atkins, University of Calgary
Veterinary Medicine

How to - Bovine Abdominal Exploratory- Right

Indications

An abdominal exploratory is a relatively cheap and effective diagnostic tool both in the field and in the hospital. Since most cows will not be shipped to a referral center, many diagnostics are not available. Lab-work typically needs to be run at the clinic or shipped off. Ultrasound is a powerful tool and can be utilized in the field. In most cases with an abnormal ultrasound, exploratory surgery is indicated. If ultrasound is negative, the next useful tool is exploratory laparotomy.

Relevant anatomy

The right flank is the preferred approach to an exploratory. Due to the rumen, ventral incisions are useful only for direct evaluation of structures in the abomasal area. From the right flank, most structures are palpable if not visible.

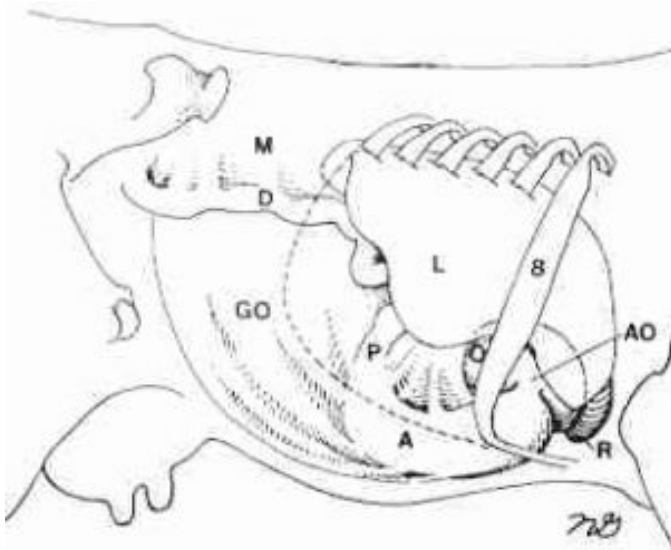
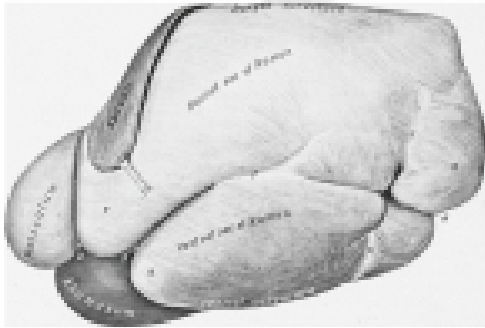
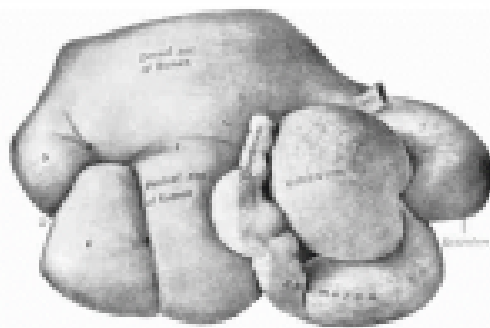


Fig 1. Note the duodenum(D) and greater omentum (GO)



Left side (note reticulum position)



Right side (note reticulum position)

Fig. 2 Reticulum position

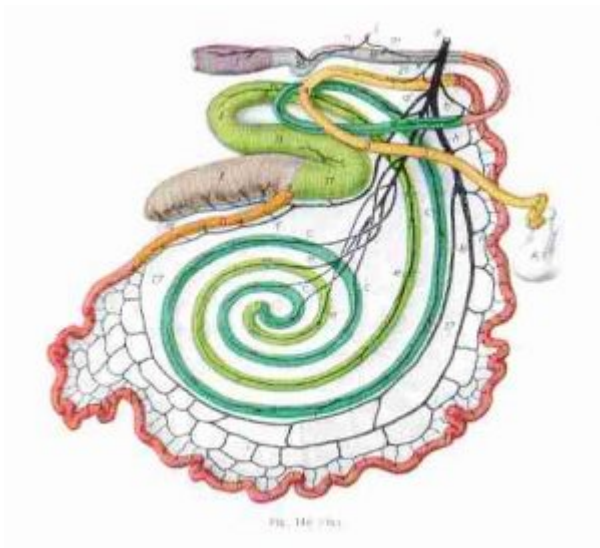

Fig. 3 Note the ileocecal and cecocolic junctions

Preoperative management

Food restrictions: NA

NSAIDs/analgesics: Recommended preoperatively. Flunixin meglumine 1.1-2.2 mg/kg iv is standard.

Antibiotics: Recommended. As cows can wall off infection, there can be surprises inside. If milking, ceftiofur 2.2 mg/kg im is standard. In beef or non-lactating cattle, other options do exist. Remember: the label dose of procaine penicillin is ineffective!

Local blocks: A [line block](#), [inverted L](#) or [paravertebral](#) are all reasonable options.

Position/preparation: See [How to- Standing GI Surgery](#)

Surgery Supplies:

- Standard surgery pack

- Sterile sleeves for internal palpation
- Scalpel blade and handle
- 2 or 3 absorbable suture material for muscle closure
- 3+ nonabsorbable suture material for skin closure
- Biopsy instruments and formalin- optional
- DA simplex – long flexible tubing attached to a 10ga needle for viscus decompression -optional

Surgical procedure

Follow the guidelines for [standing GI surgery](#).

Place a sterile sleeve on your left arm (regardless of whether left or right handed). If it is large for your hand, add a sterile glove over the top to improve your palpation skills. Generally this is one size larger than your normal glove size. ****REMOVE ANY HEMOSTATS USED FOR BLEEDERS****. Finding these in the belly is somewhat challenging.

Exploration should be done from clean to potentially (or known) contaminated regions. In cattle, the riskiest areas are by the reticulum (hardware disease), liver (abscesses) and abomasum (perforated ulcers). As all of these are cranioventral, we typically start caudodorsal and to the left, followed by caudo ventral, craniodorsal and finally, cranioventral.

The omental sling will be in the palpation path unless pulled out of position by a late term pregnancy. In most cases, the duodenum and sling will be the only things visible in the incision (Fig 1). If there is a distended structure, it can be the abomasum (RDA or abomasal torsion) or gas in the omental bursa. Gas in the omental bursa develops after abdominal surgery or with a ruptured abomasal ulcer.

- Reach caudally and curve your left arm so that you can check the rumen and the left side. Palpate forward along the left body wall. Check the rumen gas cap and rumen pack. The rumen should have a small gas cap and be easily indentable.
 - An LDA will palpate as a second rumen gas cap.
- Return to the pelvis. Evaluate the structures in this region:
 - bladder – she will urinate
 - sublumbar lymph nodes
 - uterine – check involution
 - ovaries – evaluate for normal size and structure
- Evaluate the caudal intestines. The intestines should be fairly empty and located in the back 1/3 of the abdomen.
 - The intestines cannot be traced from duodenum to cecum

- If the intestines need to be evaluated, exteriorize the cecum (a blind-ended sac with no bands). The spiral colon is connected on the dorsal surface and the ileum enters on the ventral surface. (Fig 3)
- Evaluate the kidneys. Reach forward on the inner aspect of the sling. The kidneys are both on the right side of midline, lobulated and should be nonpainful.
- Evaluate the ventral abdominal floor. Pass your hand along the ventral abdomen. It should pass easily without obstruction.
- Return to the outer surface of the sling and palpate the cranial abdomen.
- Evaluate the liver
 - Edges should be sharp. Rounded edges indicate likely fatty liver.
 - The gall bladder will be distended in cattle that are anorexic.
- Evaluate the ascending duodenum.
 - It should not be distended. Normal attachments connect it to the liver.
- Evaluate the abomasum
 - The abomasum can be identified by a mucosal slip.
 - The abdomen should be mostly empty and should be located on the right side of midline in the ventral abdomen
 - The pylorus is muscular but should be evenly muscled and a lumen should be palpable.
- Evaluate the omasum
 - This is a round firm basketball medial to the abomasum
- Evaluate the reticulum (Fig 2)
 - To find the reticulum, pass your hand down along the body wall, palm side down. Aim for the ventral midline about 6-12" forward from the incision (NOT up by the tonsils). Turn your hand palm side up. The reticulum will usually be in your palm. The reticulum is a mostly empty sack that should be easily movable. It often contains sand. The honeycomb pattern is variably distinct.
- Evaluate the diaphragm
 - It should be intact with no herniation or defect.

Closure : Follow the guidelines for [standing GI surgery](#).

Postoperative care

- See [standing GI surgery](#).

Complications

- See [standing GI surgery.](#)

Videos

Resources

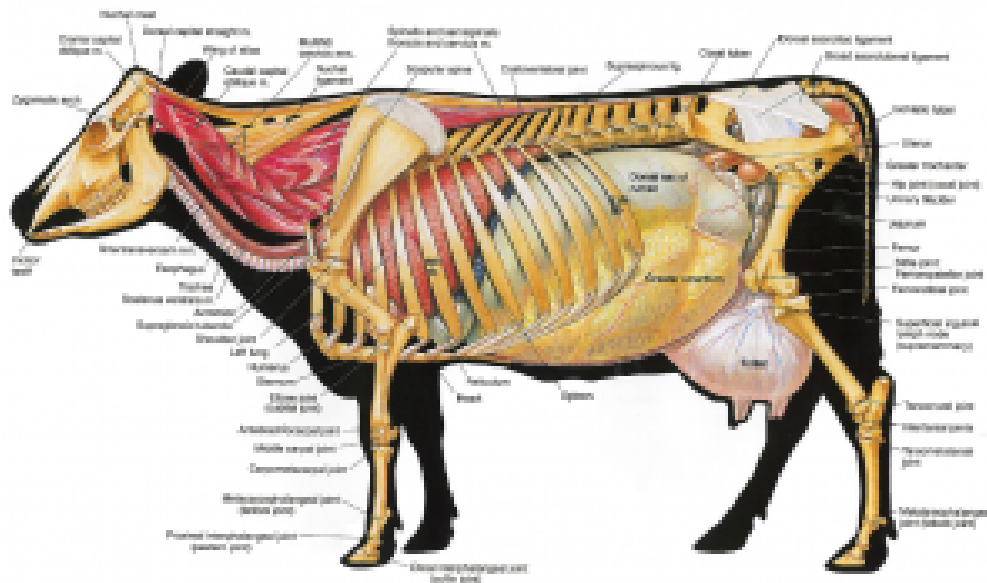
How to - Bovine Abdominal Exploratory- Left

Indications

Left flank exploratories are less common but are useful when the animal is showing signs of vagal indigestion or other left sided abnormalities. Anytime a procedure is performed on the left (Csection, rumenotomy) it should be accompanied by a full exploratory.

Relevant anatomy

The rumen takes up considerable space. How much of the intestinal structures are palpable depends on the size of the cow, arm length of the surgeon and the amount of intestinal fill.



Preoperative management

Food restrictions: NA

NSAIDs/analgesics: Recommended preoperatively. Flunixin meglumine 1.1-2.2 mg/kg iv is standard.

Antibiotics: Recommended. As cows can wall off infection, there can be surprises inside. If milking, ceftiofur 2.2 mg/kg im is standard. In beef or non-lactating cattle, other options do exist. Remember: the label dose of procaine penicillin is ineffective!

Local blocks: A [line block, inverted L or paravertebral](#) are all reasonable options.

Position/preparation: See [How to- Standing GI Surgery](#)

Surgery Supplies:

- Standard surgery pack
- Sterile sleeves for internal palpation
- Scalpel blade and handle
- 2 or 3 absorbable suture material for muscle closure
- 3+ nonabsorbable suture material for skin closure
- Biopsy instruments and formalin- optional
- DA simplex – long flexible tubing attached to a 10ga needle for viscus decompression -optional

Surgical procedure

Follow the guidelines for [standing GI surgery](#).

Place a sterile sleeve on your right arm (regardless of whether left or right handed). If it is large for your hand, add a sterile glove over the top to improve your palpation skills. Generally this is one size larger than your normal glove size. ****REMOVE ANY HEMOSTATS USED FOR BLEEDERS****. Finding these in the belly is somewhat challenging.

Exploration should be done from clean to potentially (or known) contaminated regions. In cattle, the riskiest areas are by the reticulum (hardware disease), liver (abscesses) and abomasum (perforated ulcers). As all of these are cranioventral, we typically start caudodorsal and to the right, followed by caudoventral, craniodorsal and finally, cranioventral.

- Reach caudally and curve your right arm so that you can check the intestinal fill on the right side.
- Return to the pelvis. Evaluate the structures in this region:
 - bladder – she will urinate
 - sublumbar lymph nodes
 - uterine – check involution
 - ovaries – evaluate for normal size and structure
- Evaluate the rumen pack
 - Normal fill and layers?
- Evaluate the ventral abdominal floor. Pass your hand along the ventral abdomen. It should pass easily without obstruction.

- Evaluate the cranial abdomen
 - Palpate the reticulum – is it freely movable? Adhered?
 - If no issues, reach across to the abomasum.
 - Normal fill and position?
- Evaluate the diaphragm and spleen
 - Diaphragm should be intact with no herniation or defect.
 - Spleen should be smooth, not nodular

Adhesions should NOT be broken down. They are usually attempting to wall something off.

Closure : Follow the guidelines for [standing GI surgery.](#)

Postoperative care

- See [standing GI surgery.](#)

Complications

- See [standing GI surgery.](#)

Videos

Resources

FA GI Topics

Quick notes

Hardware disease

Traumatic reticuloperitonitis secondary to hardware is more common in the postpartum period, often related to the straining of parturition.

Clinical presentation

- Distended rumen
- Painful on board or hand pressure test
- Does not scootch with withers pinch

Confirmation is most easily performed with ultrasonography rather than radiographs.

Treatment

- Conservative – treat medically with antibiotics and rest; allow to wall off. Add a magnet if she doesn't have one to stabilize the wire (may not get into the reticulum though). Transfaunate.
- Surgery – Rumenotomy to remove the object and/or drain the abscess. Abscesses must be cranial to be worth draining. Ensure one magnet and transfaunate.
- Cull – not a bad idea for some cows

Rumenotomy

Administer procaine penicillin G (gram positive anaerobes in the rumen). Left flank incision, ideally in the gas cap but the surgeon has to be able to reach the reticulum. Suture the rumen to the skin or use a rumen board to hold it out in order to minimize peritoneal contamination.

Once the rumen is secured, a vertical incision is made in rumen. A path is cleared out to the reticulum by removing ingesta. The reticulum is then searched for any hardware. If you lift up on the reticulum, it should be freely movable. If not, check the adhered area carefully as that is where the hardware exited the rumen.

If an abscess is cranial, it can be drained into the rumen. Otherwise, place one magnet, transfaunate and then close the rumen. Clean well and set it free.



A YouTube element has been excluded from this version of the text. You can view it online here: <https://open.lib.umn.edu/largeanimalsurgery/?p=1583>

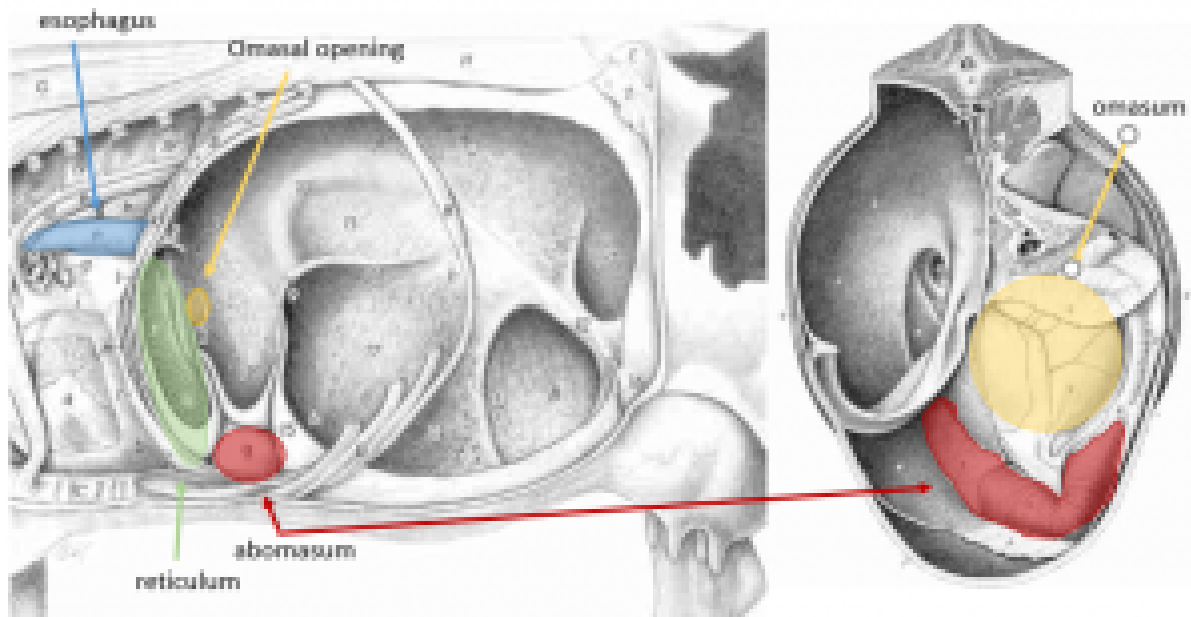
How to - Rumenotomy

Indications

Rumenotomy is indicated for vagal indigestion, hardware disease, rumen acidosis and some forms of choke. Rumenotomy allows exploration of the rumen, reticulum and parts of the omasum.

Relevant anatomy

The rumen is a large fermentation vat. The layers should be gas (dorsal), recent fiber, older fiber and fluid (ventral). The reticulum is sac off the dorsal aspect. The esophagus empties into the rumen from the dorsal cranial wall while the reticulum empties into the omasum on the medial wall just above the pillar separating the rumen and reticulum. The omasum and abomasum are often palpable through the rumen wall.



Preoperative management

Food restrictions: If possible the cow should be held off feed for 24 hours prior to rumenotomy.

NSAIDs/analgesics: Recommended preoperatively. Flunixin meglumine 1.1-2.2 mg/kg iv is standard.

Antibiotics: Recommended. If milking, ceftiofur 2.2 mg/kg im is standard. In beef or non-

lactating cattle, other options do exist. Pencillin is often effective; however, remember that the label dose of procaine penicillin is ineffective!

Other: If possible, plan on rumen transfaunation.

Local blocks: A [line block](#), [inverted L](#) or [paravertebral](#) are all reasonable options.

Position/preparation: See [How to- Standing GI Surgery](#)

Surgery Supplies- Additional

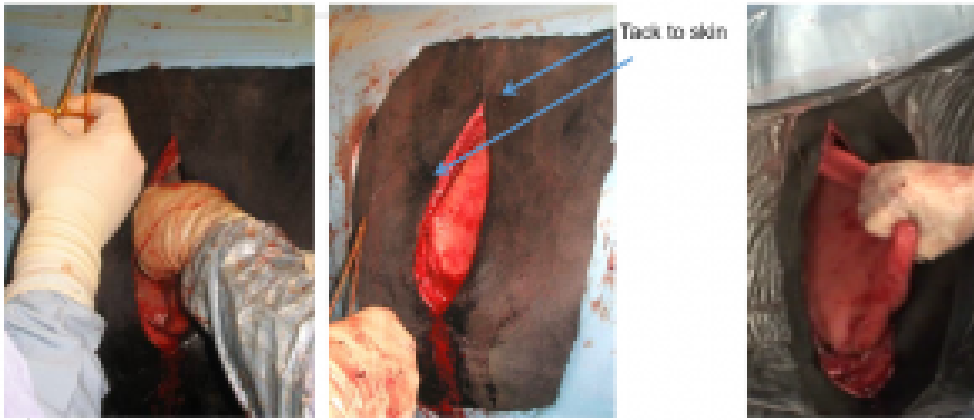
- Extra sleeves and gloves
- Additional laceration or surgery pack is ideal
- Sterile saline for lavage
- Rumen board – optional
- Wound drape – optional
- 2 suture on a cutting needle for securing rumen
- 2-0 or 0 absorbable suture for closing rumenotomy
- Wet-dry vac -optional

Surgery Supplies – Standard

- Standard surgery pack
- Sterile sleeves for internal palpation
- Scalpel blade and handle
- 2 or 3 absorbable suture material for muscle closure
- 3+ nonabsorbable suture material for skin closure

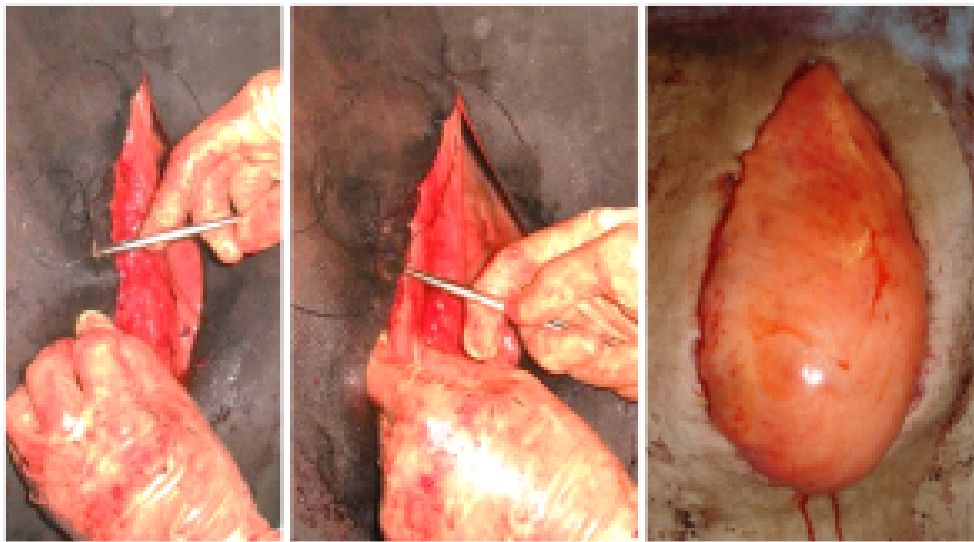
Surgical procedure

After exploratory, the rumen is tacked to the body wall to hold it in position. This will minimize the work needed to hold it up and decrease the risk of peritoneal contamination.



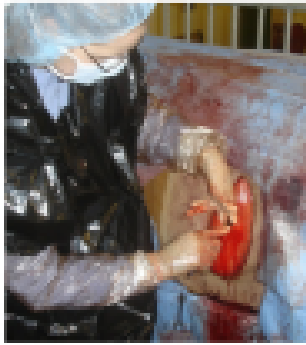
The rumen is secured to the body wall with some extra “poof”

It is important to control contamination. This can be via use of a rumen board, [rumen protector](#) or by creating a water tight seal through inverting suture pattern. The latter is the most effective. Secure the rumen to the skin using a continuous Cushing pattern of 2 suture on a cutting needle. When completed accurately, no suture should be visible. Any gaps should be closed with a mattress suture, especially at the ventral aspect. NOTE that the rumen should be poofed out a bit. However, too much poof leads to a poor match with the skin and more gaps.



Separate rumenotomy instruments (scalpel, saline, gauzes, needle holders, suture, scissors) from closure instruments. Cover closure instruments to keep sterile and move them away from the area. Consider adding protective gear to minimize lingering smells. Garbage bags are good protection. At this stage, the procedure is not a sterile one.

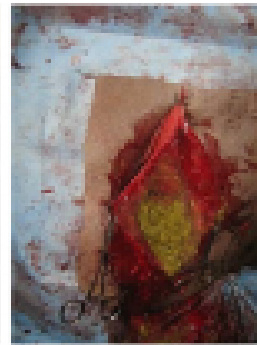Incise the rumen. Remove ingesta along the path to the reticulum for hardware or all of it for rumen acidosis. A wound protector can minimize trauma to the rumen surface. Another option would be to tack the rumen open or temporarily suture it open to minimize exposure to the serosal surface.



Barrier protection for surgeon, isolating rumen



Wound drape: sterile goes in rumen



Rumen lacerated open

Explore the reticulum, esophageal opening and omasal opening. If the reticulum does not move, investigate the adhered area for penetrating foreign bodies. Palpate through the wall for any abscesses that need drainage. Hardware should be removed as should any extra magnets. One magnet should be left or placed. Rumen transfaunation is easiest at this stage.

If an abscess is identified, it can be drained into the rumen through the *area adhered*. Any incision that extends beyond that area will leak ingesta into the peritoneum. Note: Pus does not drain uphill well. And if you lose a scalpel blade, you have to find it. Tie it to your wrist before taking it into the rumen.

If contamination occurs or peritonitis identified, DO NOT lavage the abdomen. Cows can wall off infection if localized.

Rumen closure

The rumen drapes or shields are removed and the rumen surface cleaned. The rumenotomy incision is closed in two layers with an inverting pattern uppermost. After the first layer is closed and the rumen surface cleaned, the garbage bags are removed from the surgeons, gloves changed and the clean instruments used. The rumen is slowly released from the body wall so that it can be cleaned well prior to return to the abdominal cavity.

Body wall closure

Follow the guidelines for [standing GI surgery](#).

Postoperative care

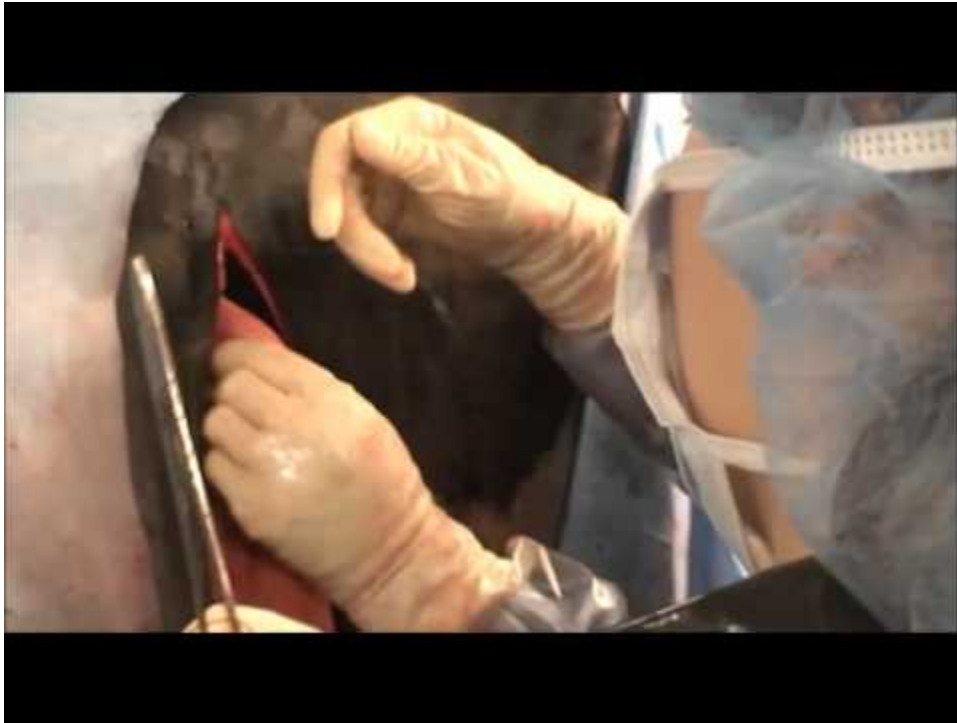- Continue NSAIDs and antibiotics for at least 3 days
- Provide new rumen flora if possible
- Monitor for infection

Complications

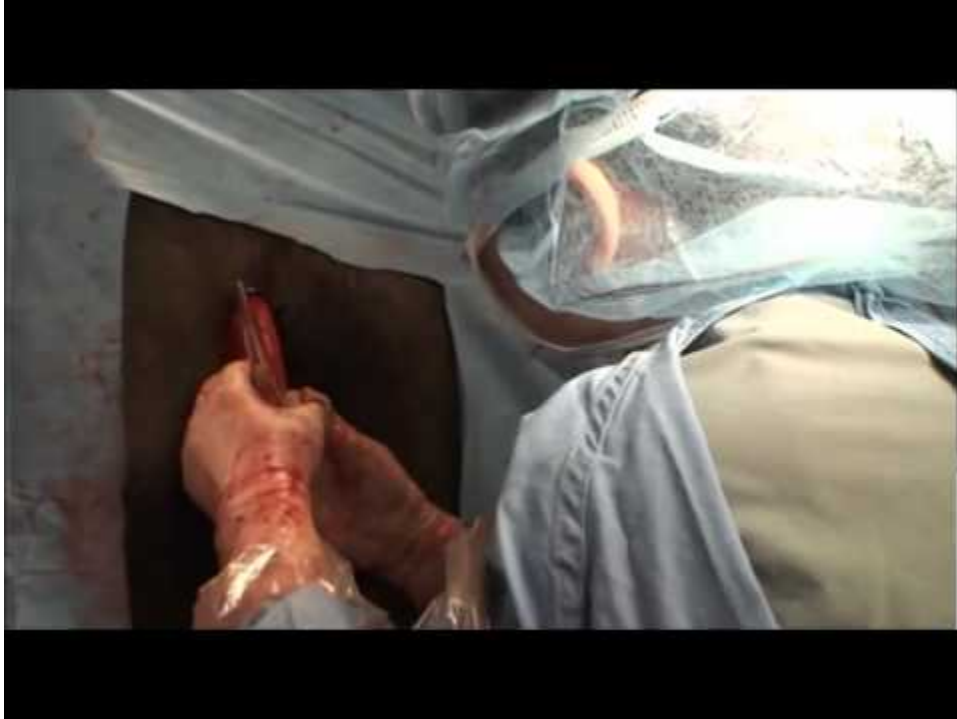- Lack of improvement

- Peritonitis
- Incisional infection

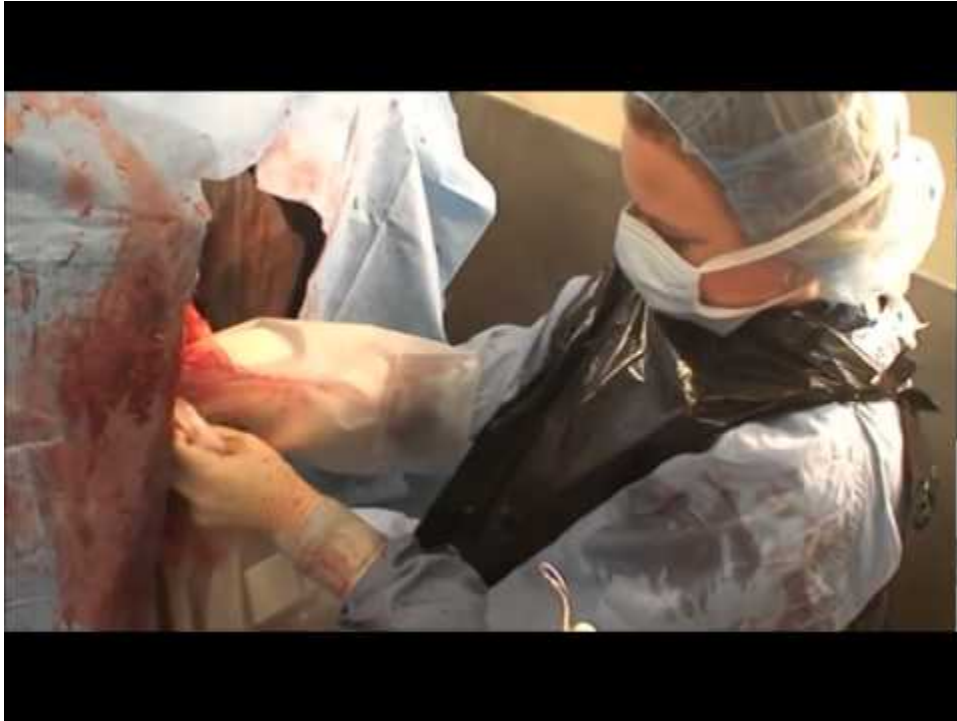Videos



A YouTube element has been excluded from this version of the text. You can view it online here: <https://open.lib.umn.edu/largeanimalsurgery/?p=3260>



A YouTube element has been excluded from this version of the text. You can view it online here: <https://open.lib.umn.edu/largeanimalsurgery/?p=3260>



A YouTube element has been excluded from this version of the text. You can view it online here: <https://open.lib.umn.edu/largeanimalsurgery/?p=3260>

Resources

How to - Rumenostomy

Indications

Rumenostomy is performed in growing calves with chronic bloat and in any age ruminant to provide nutritional support. Rumenostomies can be performed instead of rumen trocarization for improved results. Rumenostomies are also performed for feed trials to enable direct feeding and/or sampling. Finally, a rumenostomy can be placed in an adult cow to provide easy access to microflora (rumen donor). Rumenostomies typically have smaller openings designed to close over time (calves) or are kept open with a rumen cannula sized to fit the need.

Relevant anatomy

The rumen is located on the left side of the abdomen. A rumenostomy is centered in the left paralumbar fossa.

Preoperative management

Food restrictions:

Surgery is harder with a full rumen. Animals should be held off feed for 24 hours if not urgent. Bloating calves are NOT typically held off feed as the procedure may be needed on an emergency basis.

NSAIDs/analgesics:

Animals should be given flunixin meglumine or other NSAID prior to surgery

Antibiotics:

Procaine penicillin G is typically given preoperatively

Local blocks:

Line block, inverted L or paravertebral block with lidocaine

Position/preparation:



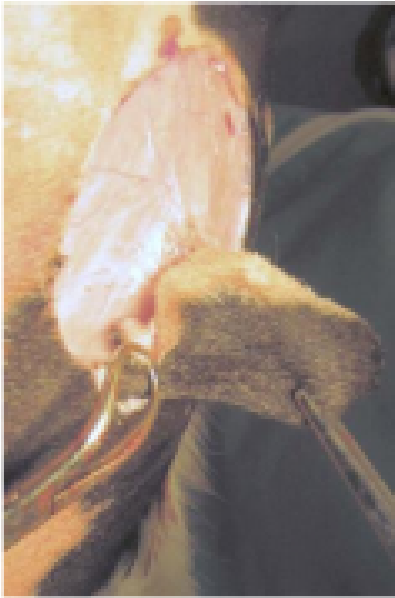Standing and restrained. Larger animals can be restrained in chutes or headgates; younger animals are often restrained by people.

Surgery Supplies:

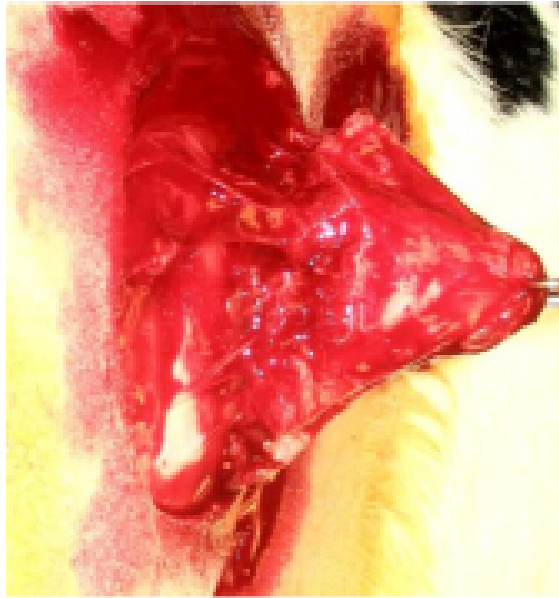- Standard pack
- Scalpel blade and handle
- 2-0 to 0 absorbable, taper needle for the inner layer
- 2-0 to 0 nonabsorbable or absorbable, cutting needle for the outer layer
- Cannula (optional); soaking in hot water
- Syringe case, 0 suture, umbilical tape (optional)

Surgical procedure

After the area is clipped, prepped and blocked, a circular incision is made in the center of the flank through the skin. In a standard rumenostomy, this is the diameter of two ribs. If a cannula is being inserted, this is the inner diameter of the cannula. The circle of skin is removed. A circle of external abdominal oblique muscle is removed.

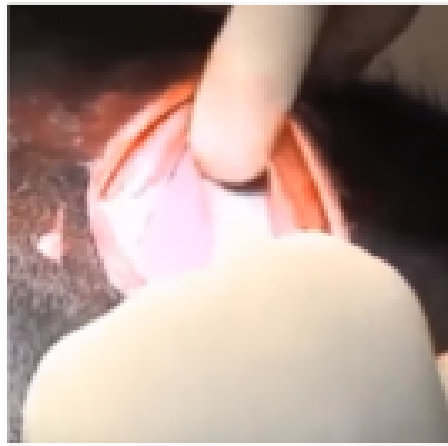
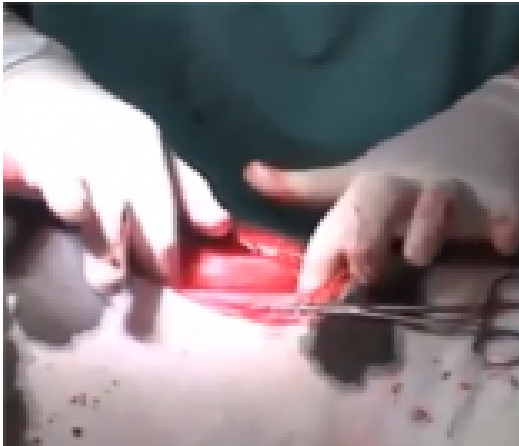
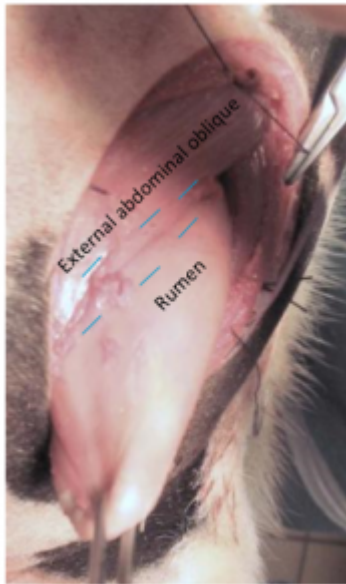Remove circle of skin



and of external abdominal oblique

The internal abdominal oblique and transversus muscles are separated along their fibers to grid the opening. This creates a natural valve effect that minimizes rumen fluid leakage.

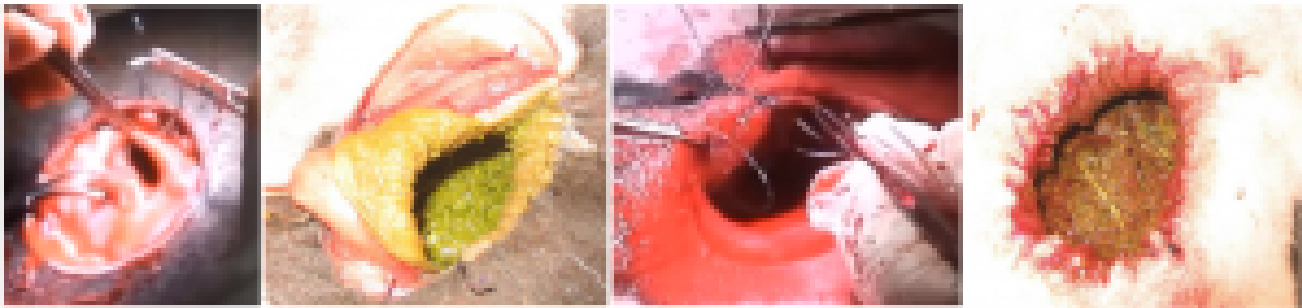




The rumen is grasped with allis tissue forceps and pulled gently out the incision until is “poofed out” and is filling the the hole. Some exteriorization is needed to minimize tension on the suture line. Excessive exteriorization creates folds and areas that can necrose under a cannula.

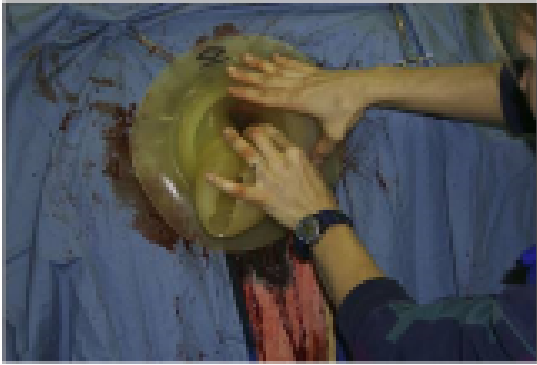The rumen is secured to the external abdominal oblique with an inverting pattern using 2-0 or 0 absorbable suture (taper needle). This pattern (blue lines in image) is placed as far from the center of the circle as possible to avoid interference with the final layer. This pattern creates a water tight seal that protects the abdominal cavity from contamination.

A circle of rumen is removed stepwise. One quarter of the arc is incised. The cut edge of the rumen is sutured to the cut skin edge in a continuous appositional pattern using the 2-0 or 0 suture (cutting needle).

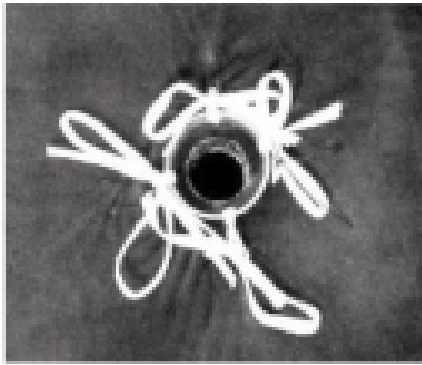


After the first quarter is incised, another quarter is transected and sutured. At this stage, the continuous pattern should be knotted to prevent a pursestring effect. The suture is not cut free but is simply tied in place and then continued in use. The third quarter is transected and sutured. This is continued until a full circle of rumen wall is removed and the remaining rumen secured to the skin.

If a cannula is being placed, it is inserted at this time. Having it soaking in hot water helps the pliability. It should fit snugly. A temporary cannula can be constructed out of a syringe case for cases of bloat. The case is secured to loops of suture using umbilical tape. The cap can be put back on the case to minimize fluid leakage; bloat will blow the cap off and the gas can escape. Both can keep the site open, potentially longer than needed.



Cannula being inserted



Syringe case can be capped

Postoperative care

- NSAIDs are continued for 2-3 days, antibiotics for 5 days
- The flank is coated with vaseline and cleaned as needed to minimize scalding from the rumen juices.
- Nonabsorbable sutures are removed at 10-14 days
- Without a cannula, the rumenostomy site will gradually shrink and eventually close in most situations. If sized appropriately, the bloat should be resolved by the time it closes.

Complications

Peritonitis- animals may have a fever and be off feed. Some cattle can wall off the infection.

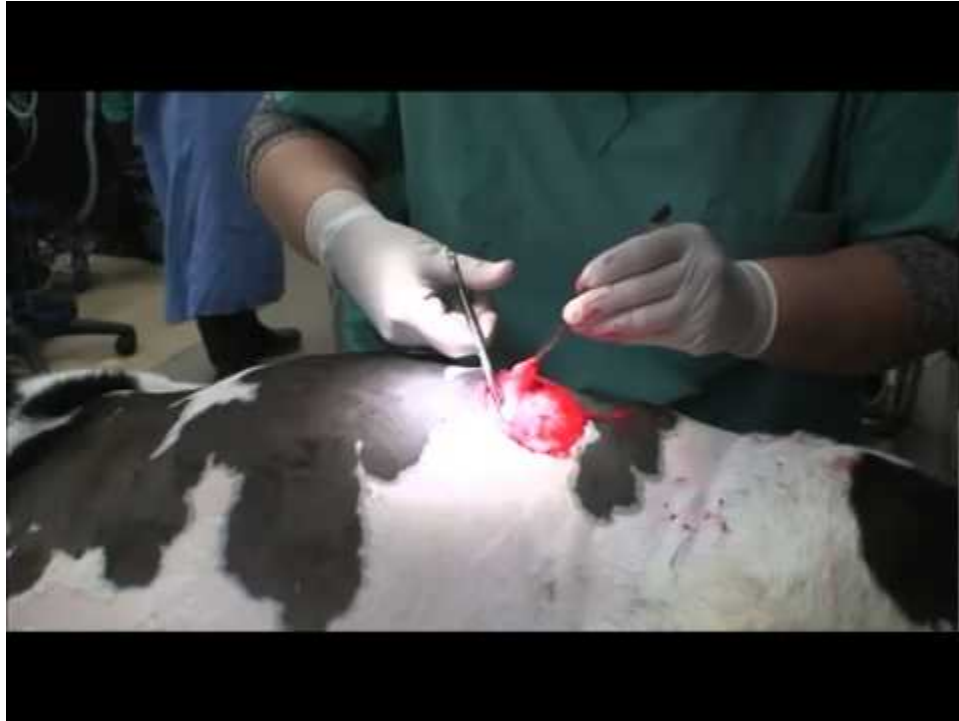Incisional infection- part of the suture line may need to be opened to allow drainage.

Skin scald – can be treated with cleaning, zinc oxide and vaseline

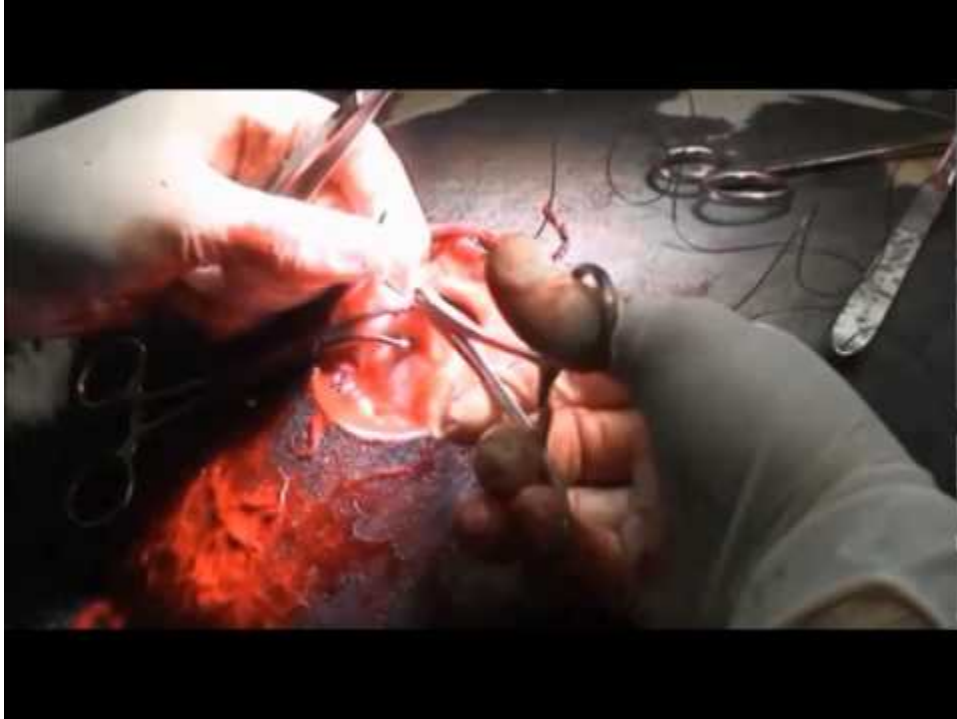Lack of closure – with constant manipulation from cleaning or continued cannulation, the site will stay open. It can be closed if needed. Closure involves resecting the fistula and should be done by an experienced surgeon.

Videos

This videos were taken as part of a teaching laboratory; calves are in lateral recumbency rather than standing.



A YouTube element has been excluded from this version of the text. You can view it online here: <https://open.lib.umn.edu/largeanimalsurgery/?p=3109>



A YouTube element has been excluded from this version of the text. You can view it online here: <https://open.lib.umn.edu/largeanimalsurgery/?p=3109>

Resources

Abomasal displacement

Right displaced abomasum

These can occur in any animal with an abomasum. Rare in small ruminants.

Left displaced abomasum

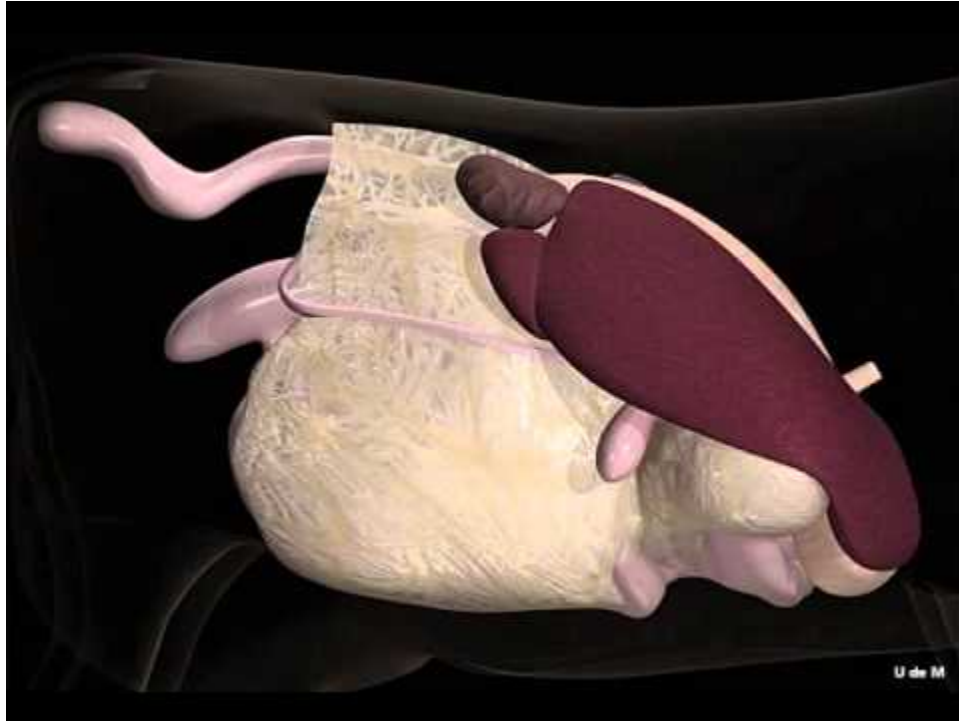
Classically these occur in the early (first 6-8 weeks) postpartum dairy cow.

Clinical findings:

- scant loose feces
- left sided ping on a line from tuber coxae to elbow, centered on 12th ICS
- sunken left PLF
 - rumen usually pushes the left body wall out. With an LDA, the abomasum pushes the rumen toward the center line
- ketosis
- dehydration
- metabolically alkalosis
- hyponatremia, hypochloremia, hypokalemia, hypocalcemia

Treatment options

- Fluid therapy – hypertonic saline and oral water after surgery; avoid LRS
- Surgical options
 - Roll and toggle or tack
 - Right sided omentopexy and/or antropexy (pyloropexy)
 - Left side abomasopexy
 - Right paramedian abomasopexy
 - Laparoscopic abomasopexy



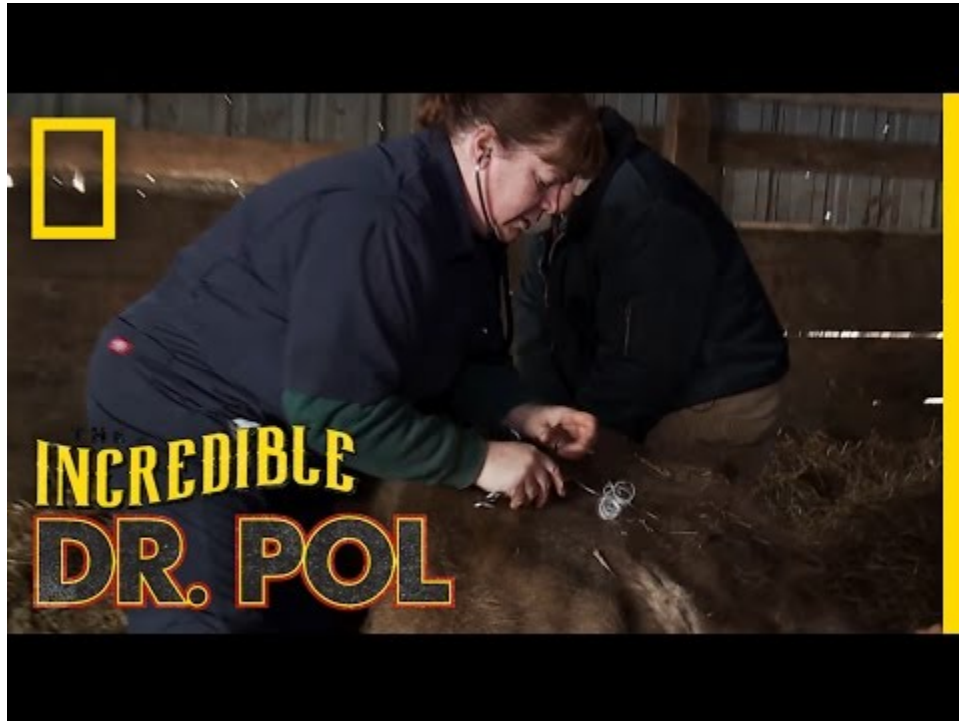A YouTube element has been excluded from this version of the text. You can view it online here: <https://open.lib.umn.edu/largeanimalsurgery/?p=1548>

Roll and toggle

Cow is put on her back with casting ropes and/or sedation (acepromazine, xylazine and/or butorphanol). When she is on her back, the abomasum should float into its normal position. After the abomasum is identified by pinging, two toggles can be placed in the abomasum. Quick work is needed to identify the abomasum before the gas leaves. Potential complications include not being able to find the abomasum and toggling the pylorus. Other risks include tacking other structures, tacking the abomasum in the wrong position and problems associated with dorsal recumbency. If the cow is not doing well 2 days postoperatively, the toggle should be cut loose. If she recovers, the toggle should be cut free in 2-3 weeks to prevent fistula formation.

<https://youtu.be/OLy3oGdwYBo>

This is a tack suture vs a toggle but you can see the general procedure:



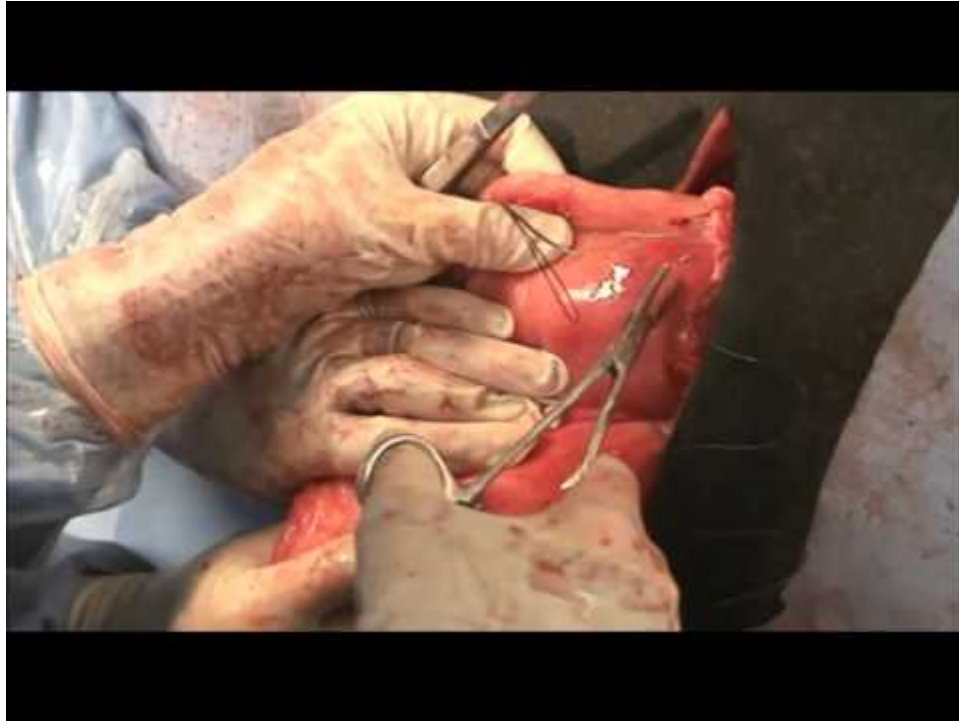A YouTube element has been excluded from this version of the text. You can view it online here: <https://open.lib.umn.edu/largeanimalsurgery/?p=1548>

This one has lots of details : [MSU roll and toggle](#)

Right sided omentopexy

This procedure is done standing with a local block. An incision is made in the right paralumbar fossa and the abomasum identified through palpation of the far side of the abdomen. The abomasum is decompressed using 10 gauge needle attached to tubing. Once it is deflated, the surgeon reaches underneath the viscera and pulls it over to the right side. This can be a scoop after lifting the viscera or a pull on the omentum. Once it is pulled to the right side, the omentum just caudal to the pylorus is used for the pexy. There are many versions of omentopexy. Commonly, horizontal mattress sutures are used to attach the omentum to the muscles on the cranial aspect of the incision. If desired, part of the antrum (slipped mucosa) can also be attached to the cranial incision.

Complications include breakdown of the pexy, particularly in very fat cows or pregnant cows. If adhesions are present, the abomasum often cannot be brought to the right side.



A YouTube element has been excluded from this version of the text. You can view it online here: <https://open.lib.umn.edu/largeanimalsurgery/?p=1548>

Left sided abomasopexy

This procedure is done standing with a local block. An incision is made in the left paralumbar fossa and the abomasum identified as a gas distended structure in the incisional area. A short run of ford interlocking sutures are preplaced in the greater curvature. These will create your pexy through adhesion formation. A needle is placed on each end of the suture and these ends run out the ventral body wall to the right of midline, just behind the xiphoid. An assistant is generally needed to grab the needles as they exit the body wall. The abomasum is deflated and the sutures pulled tight. This will pull the abomasum to its normal position. After checking to make sure no structures are stuck between the abomasum and the body wall, the sutures are tied to each other, creating the pexy.

Complications include entrapment of viscera, breakdown of the adhesion and abomasal fistula formation. Can be useful if adhesions.

Cannot be done for an RDA or abomasal volvulus.



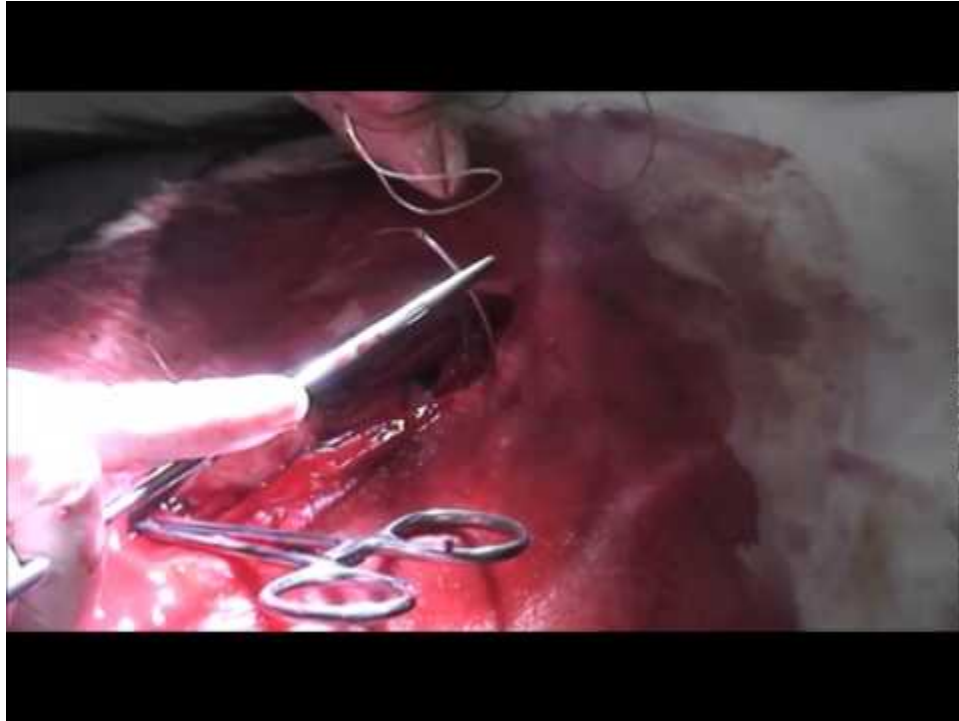A YouTube element has been excluded from this version of the text. You can view it online here: <https://open.lib.umn.edu/largeanimalsurgery/?p=1548>

Right paramedian abomasopexy

This procedure is done with the cow in dorsal recumbency as for the toggle procedure. A 4" incision is made 4" caudal to the xiphoid and 4" to the right of midline, avoiding the milk veins. Once the peritoneal cavity is entered, the abomasum is identified. It should have returned to its normal position and can be identified via the mucosal slip. The pexy is performed by incorporating the abomasum into the closure of the internal rectus sheath using a continuous pattern. The pexy should extend for ~ 6 bites and finish ~4" from the reticuloabomasal fold.

Complications include problems with recumbency (worsening pneumonia) and with standing up. Cows with nervous ketosis, musculoskeletal issues and pneumonia should not be put into dorsal recumbency.

Should not be used with an abomasal volvulus or anything that might be a volvulus.

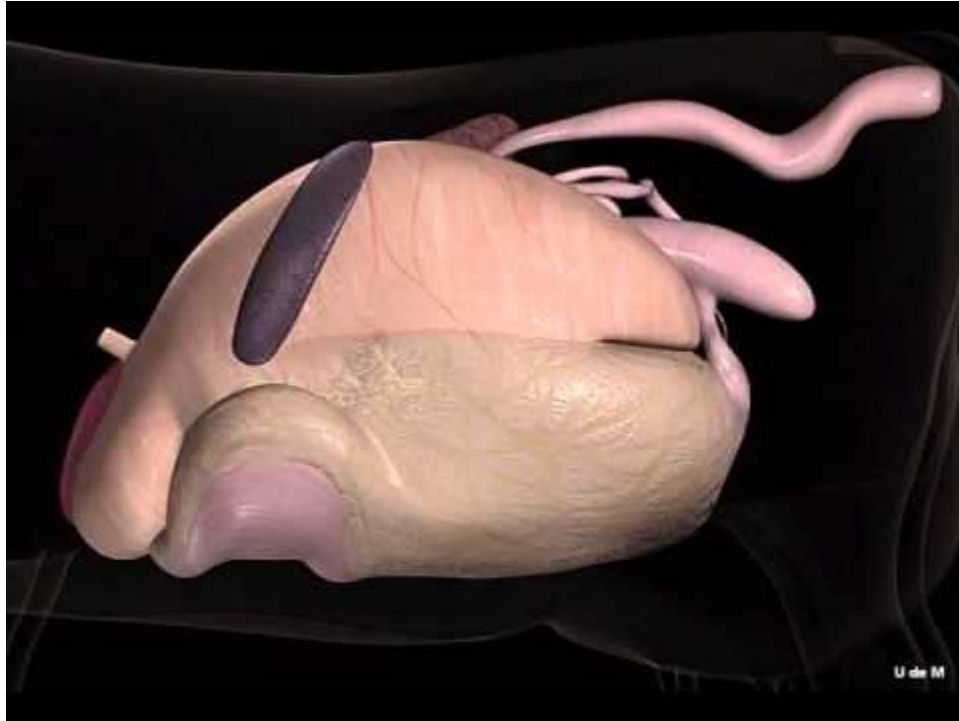


A YouTube element has been excluded from this version of the text. You can view it online here: <https://open.lib.umn.edu/largeanimalsurgery/?p=1548>

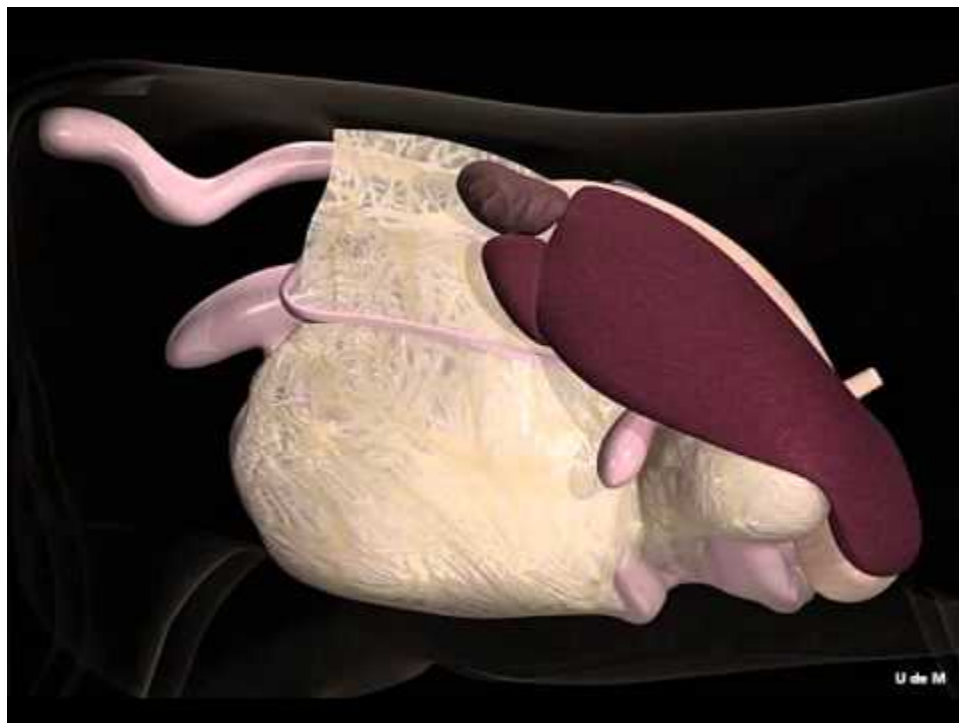
Laparoscopic abomasopexy

This is basically a visualized toggle procedure and generally requires casting the cow.

Resources



A YouTube element has been excluded from this version of the text. You can view it online here: <https://open.lib.umn.edu/largeanimalsurgery/?p=1548>



A YouTube element has been excluded from this version of the text. You can view it online here: <https://open.lib.umn.edu/largeanimalsurgery/?p=1548>

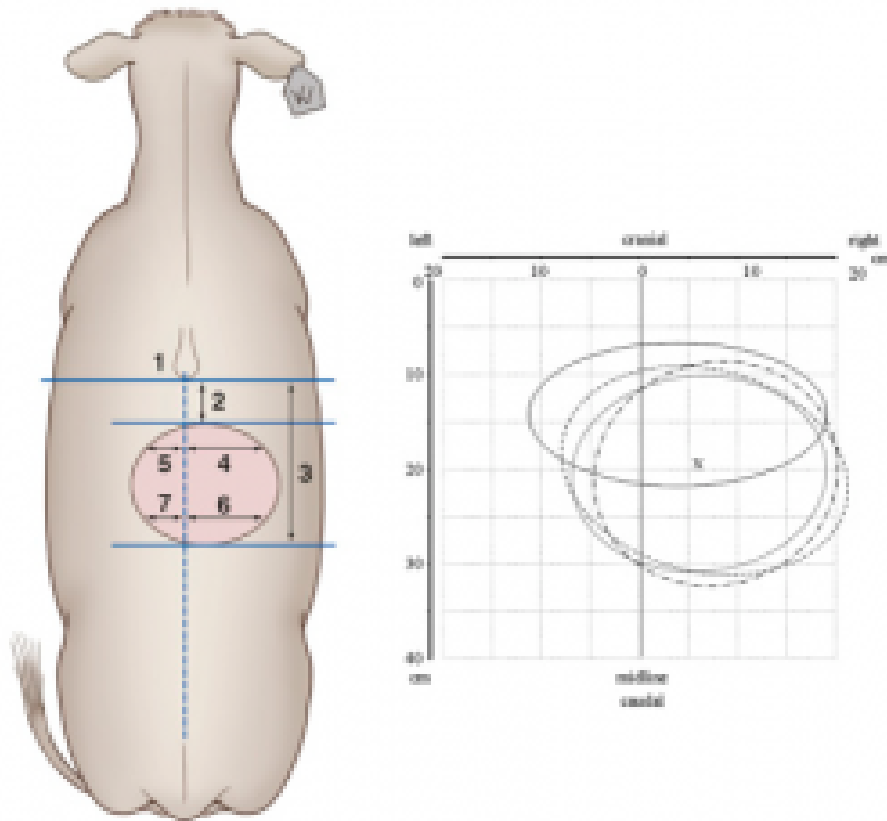
How to - Right flank omentopexy/antropexy

Indications

Stabilization of the abomasum is indicated with any DA surgery and is generally performed any time a right flank exploratory is performed (prophylactic tack). Right flank omentopexy is one option. Omentopexy combined with a tack of the antrum (often called pyloropexy) is a modification that may be stronger.

Relevant anatomy

The abomasum is normally located on the ventral abdomen, typically just to the right of midline. It often shifts horizontally across the midline during late gestation. When gas filled, the abomasum can displace to either the left or the right sides of the abdomen and float up. The pylorus will stay more ventral while the body of the abomasum floats more freely upward.

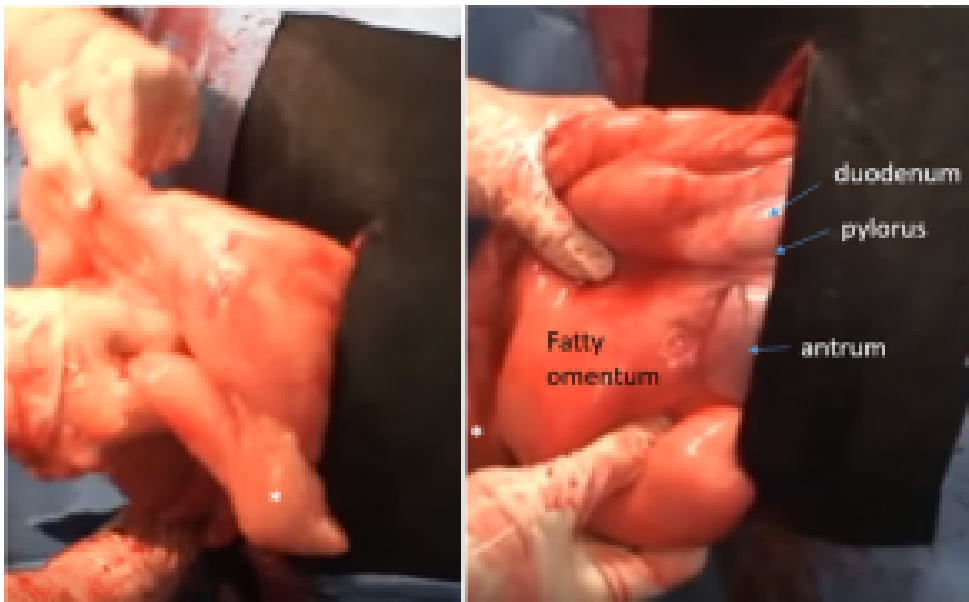

Normal location (left) and changes in abomasal position with stage of gestation.

Wittek T, Constable PD, Morin DE. J Am Vet Med Assoc 2005; 227:1469-1475

Fig 1. Normal position of the abomasum and changes with gestation.

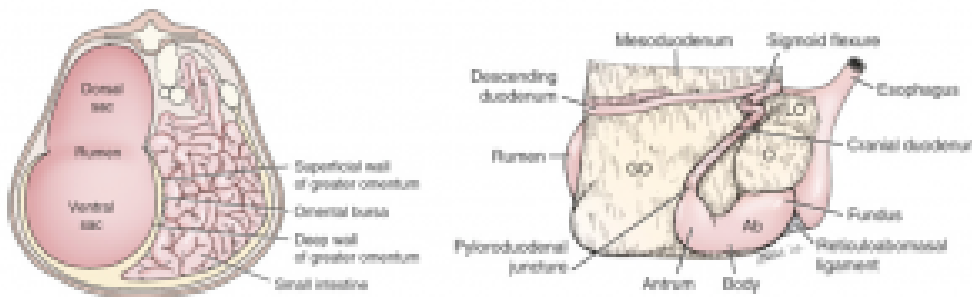
The abomasal antrum is exposed while the pylorus and proximal duodenum are encased in omentum. The “sows ear” is not necessarily close to the antrum.



The "sow's ear" is a fold of omentum (*) at a variable distance from the pylorus

Fig 2. Abomasal antrum and sow's ear

The greater curvature of the abomasum is encased within the omental bursa – a potential space formed by the greater and lesser omentum (omental leaves). The greater omentum has two layers. The superficial layer connects the descending duodenum, abomasum and the left longitudinal groove of the rumen. The deep layer connects the duodenum, abomasum and the right longitudinal groove of the rumen. This creates the “sling” and the omental bursa between the layers. The lesser omentum connects the abomasum, liver and ascending duodenum.



Farm Animal Surgery, 2nd Edition.

Fig 3. Note how the angle between the duodenum and the abomasum is ~ 45 degrees. This is important to remember when pulling up the abomasum

The flank musculature is comprised of the external abdominal oblique, internal abdominal oblique and transversus abdominus muscle.

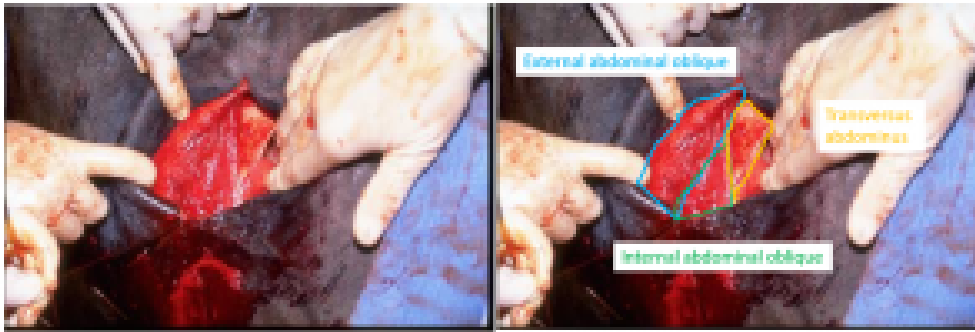

Fig 4. Flank musculature shown as grided

Preoperative management

Food restrictions: NA

NSAIDs/analgesics: Recommended preoperatively. Flunixin meglumine 1.1-2.2 mg/kg iv is standard.

Antibiotics: Recommended. As cows can wall off infection, there can be surprises inside. If milking, ceftiofur 2.2 mg/kg im is standard. In beef or non-lactating cattle, other options do exist. Remember: the label dose of procaine penicillin is ineffective!

Local blocks: A [line block](#), [inverted L](#) or [paravertebral](#) are all reasonable options.

Position/preparation: See [How to- Standing GI Surgery](#)

Surgery Supplies – Additional

- 2 chromic gut, 2 vicryl, 2 nylon or similar for the pexy
- DA simplex – long flexible tubing attached to a 10ga needle for viscus decompression
- 0 vicryl or similar for the abomasotomy with abomasal volvulus
- Large bore stomach tube – for abomasal volvulus

Surgery Supplies- Standard

- Standard surgery pack
- Sterile sleeves for internal palpation
- Scalpel blade and handle
- 2 or 3 absorbable suture material for muscle closure
- 3+ nonabsorbable suture material for skin closure

Surgical procedure

Follow the guidelines for [Standing GI surgery.](#), [How to – Abdominal Exploratory](#)

To replace a left displaced abomasum

Identify the top part of the abomasum or as high as you can reach. Take the DA simplex (tubing with 10 ga needle attached) into the abdomen, protecting the needle by having it in your palm or folded backwards. When you reach the abomasum, tunnel the needle through the wall of the DA for a few mm and then direct it perpendicularly into the lumen. Push down to encourage as much gas as possible to escape. Remove the simplex and drop it on the floor or hand to a nonsterile assistant (contaminated).

Reach under the sling and grab the pylorus OR grab the omentum that is in the cranioventral aspect of the omentum and gradually pull on that at a 45 degree angle (see Fig 3) to pull the abomasum over to the left side. This may take some wiggling or manipulation inside the cow. If the omentum starts to tear (much more likely in very fat cows), stop and try to find the pylorus to pull the abomasum over directly. NOTE: Pulling vertically pulls on the rumen and pulling horizontally pulls on the liver. Neither will help reposition the abomasum. Pull at an angle.

If it is not moving check for

- excessive gas – repalpate craniodorsally and repeat the gas removal if necessary
- adhesions – previous pexy or ulcer – palpate along the ventral body wall. If present, close and move to plan B
- torn omentum – attempt to grab the pylorus itself

To replace a right displaced abomasum

Identify the gas distended viscus and verify displaced vs twisted. Run your hand down the medial aspect. If your hand can follow the medial aspect down to the ventral abdomen, it is just displaced. A twist will stop your hand midway down. A twist is also usually accompanied by displacement of the omental sling. If you have a twist, see below.

Decompress the abomasum using the tunneling technique + direct stab. Once the gas is relieved, dispose of the simplex and grab the pylorus. The abomasum has flipped up in a counterclockwise manner as viewed from the rear. Push down the body of the abomasum while pulling up on the pylorus. If you move too slowly, the gas will redevelop and you will need to repeat the decompression.

To correct an abomasal volvulus

With a volvulus, the abomasum has moved into the RDA position (flipped up) and then twisted counterclockwise as viewed from the right side of the cow. You need to twist it clockwise into RDA position and then flip it down. However, it is usually full of fluid. Untwisting can be challenging until you remove the fluid.

Cover both arms with sterile sleeves and overgloves, set up gastrotomy instruments (needle holders, suture scissors, suture, blade) and move the clean instruments aside. Preplace two pursestring sutures of 0 vicryl in the exposed abomasal body – one with a center diameter of 4 cm and one encircling that with a slightly larger central diameter. Leave the ends of each pursestring long. Create a stab incision in the center, big enough for your large bore stomach tube. Quickly insert the stomach tube, passing it into the ventral aspect of the abomasum. Abomasal fluid will start to siphon off. Adjust the tube as needed to remove as much fluid as possible. Remember, as you

pull the tube out, the tube is contaminated. Remove the tube fully and tighten the pursestring sutures. Clean the surface and remove the overgloves and sleeves. Use the suture in the last pursestring or an additional strand to cover the knots with an inverting pattern.

Reposition the abomasum by pushing it forward and then down (or pull on the pylorus clockwise and then correct the RDA).

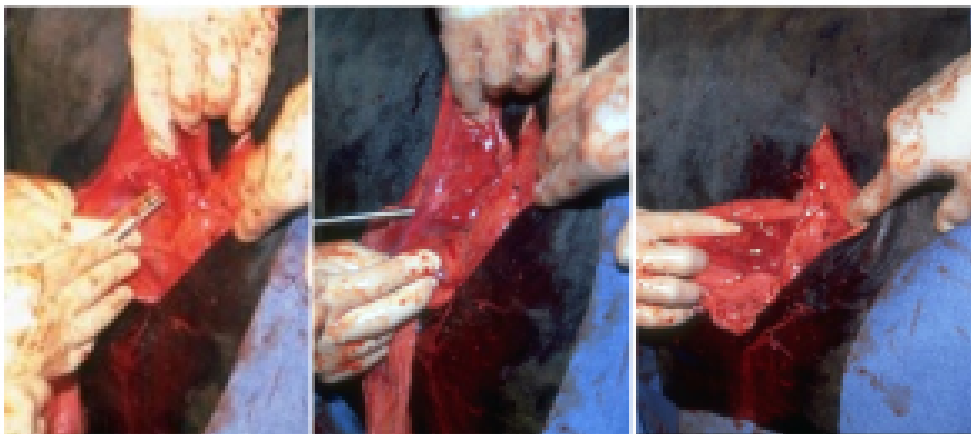Omentopexy

Prior to closure, palpate the abomasal wall for ulcers and perform the omentopexy. There are several viable methods. This is one of them:

Pull the abomasum up (or extend the incision down) so that the abomasal antrum is visible (Fig 1). Clamp the omentum dorsal to the antrum to the dorsal aspect of the incision to hold it in place. The pylorus should not be elevated more than necessary or it puts the cow at risk of duodenal torsion.

Place 2 horizontal mattress sutures across the cranial incisional musculature and the omentum + 1 horizontal mattress across the musculature and the antrum.

- *Omentopexy bites*: Starting on the external abdominal oblique using 2 suture material, insert the needle 1 cm caudal to the cut edge, through the internal abdominal oblique, through the transversus, through the omentum (the part that is just caudal to the pylorus or duodenum) from cranial to caudal, back through the omentum from caudal to cranial, back through the transversus, back through the internal abdominal oblique and back through the external abdominal oblique. Tighten up the suture so the omentum is tightly against the body wall. Tie. Repeat for 1-2 more sutures.



Needle moving cranial to caudal through omentum

Needle moving caudal to cranial back through omentum

Omentopexy completed

- *Antropexy bite*: Using the same process, insert the needle through the musculature, through the slipped wall (mucosa not included) of the abomasal antrum, back through the slipped wall of the abomasal antrum and back through the musculature. With an RDA, you may be able to get 2 horizontal mattress sutures in the antrum instead of just one.

Closure is as described in [How to- Standing GI Surgery](#). If the internal abdominal oblique muscle slid away during

the pexy, you cannot use it for closure. Attach the caudal aspect to whichever layer you prefer. One wound, one scar applies anyway. In 10 days, you can't tell the difference.

Postoperative care

- Suture removal in 10-14 days
- Monitor the cow for any signs of infection or peritonitis
- Consider rumen transfaunation if available
- Continue antibiotics for 5 days and NSAIDs for 3 days if abomasotomy performed

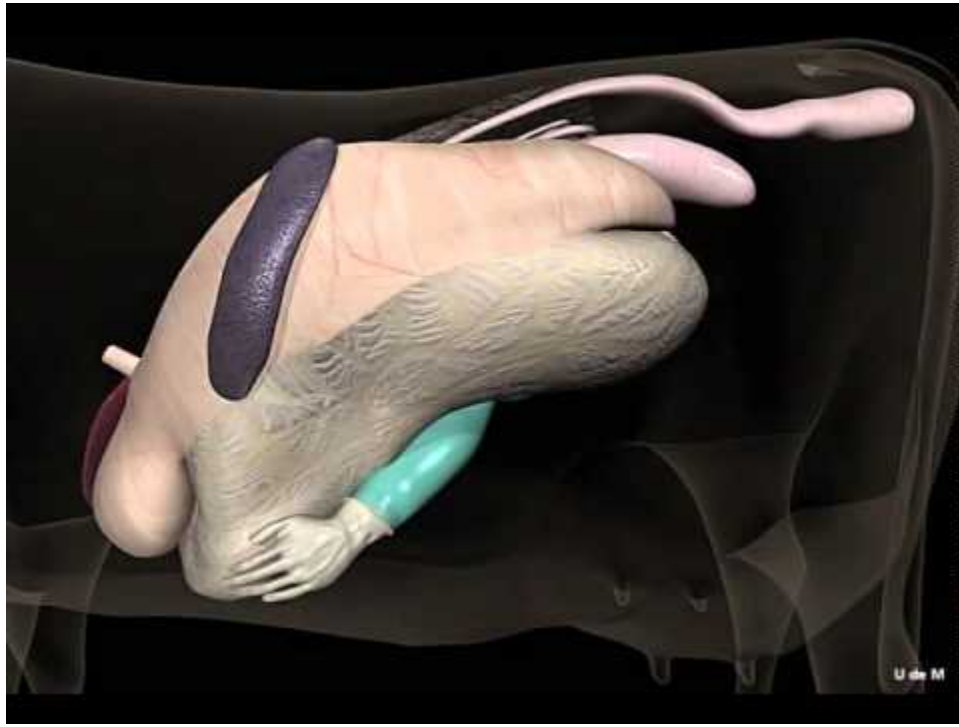
Complications

- Incisional dehiscence (rare)
- Incisional infection (common)
- Peritonitis

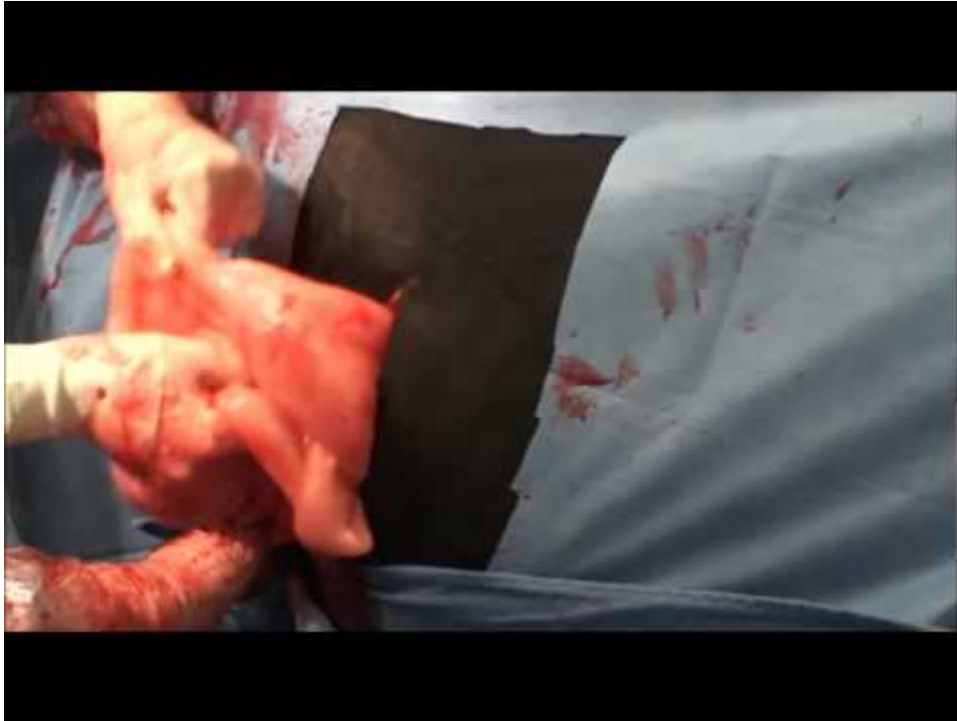Abomasal volvulus

- Abomasal necrosis – if a portion of the abomasum is purple or if the pursestring sutures pull out, the abomasum is devitalized. Quit.
- Abomasal atony – in some cases the abomasal wall is so stretched, it never works again. Cull.
- Unable to detorse – sometimes the omasum and/or reticulum are involved and detorsion is very challenging. Refer or quit.

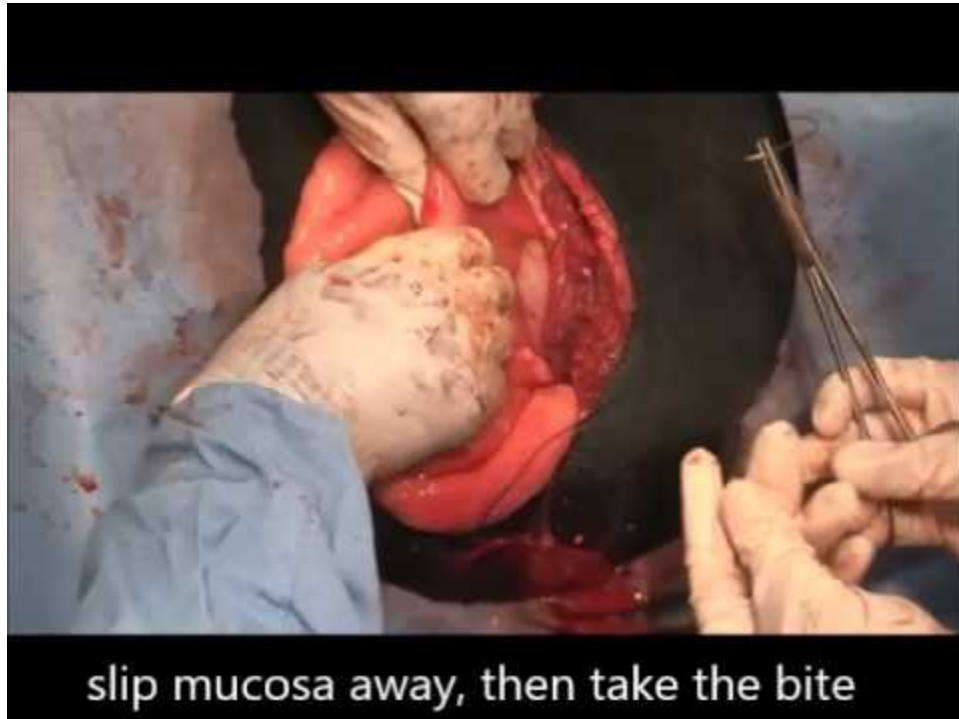Videos



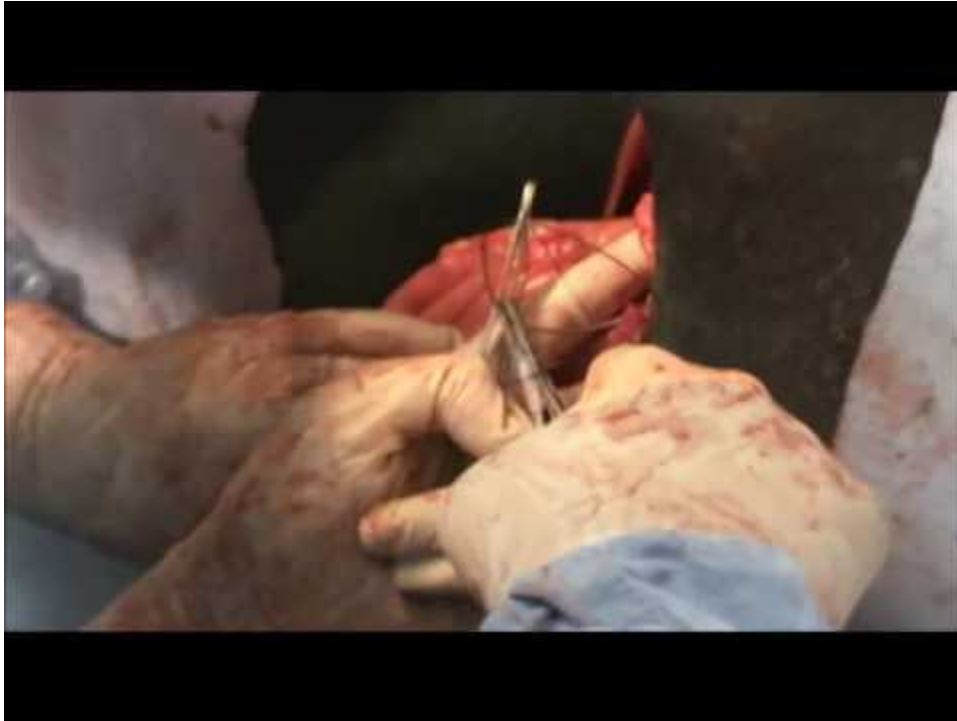A YouTube element has been excluded from this version of the text. You can view it online here: <https://open.lib.umn.edu/largeanimalsurgery/?p=3208>



A YouTube element has been excluded from this version of the text. You can view it online here: <https://open.lib.umn.edu/largeanimalsurgery/?p=3208>



A YouTube element has been excluded from this version of the text. You can view it online here: <https://open.lib.umn.edu/largeanimalsurgery/?p=3208>



A YouTube element has been excluded from this version of the text. You can view it online here: <https://open.lib.umn.edu/largeanimalsurgery/?p=3208>

Resources

[Farm Animal Surgery \(Second Edition\)](#), 2017

Wittek T et al. [Ultrasonographic assessment of change in abomasal position during the last three months of gestation and first three months of lactation in Holstein-Friesian cows](#). *J Am Vet Med Assoc* 2005; 227:1469-1475

Cecal dilatation

RESOURCES

[Surgery of the bovine large intestine](#), VCNA 2008

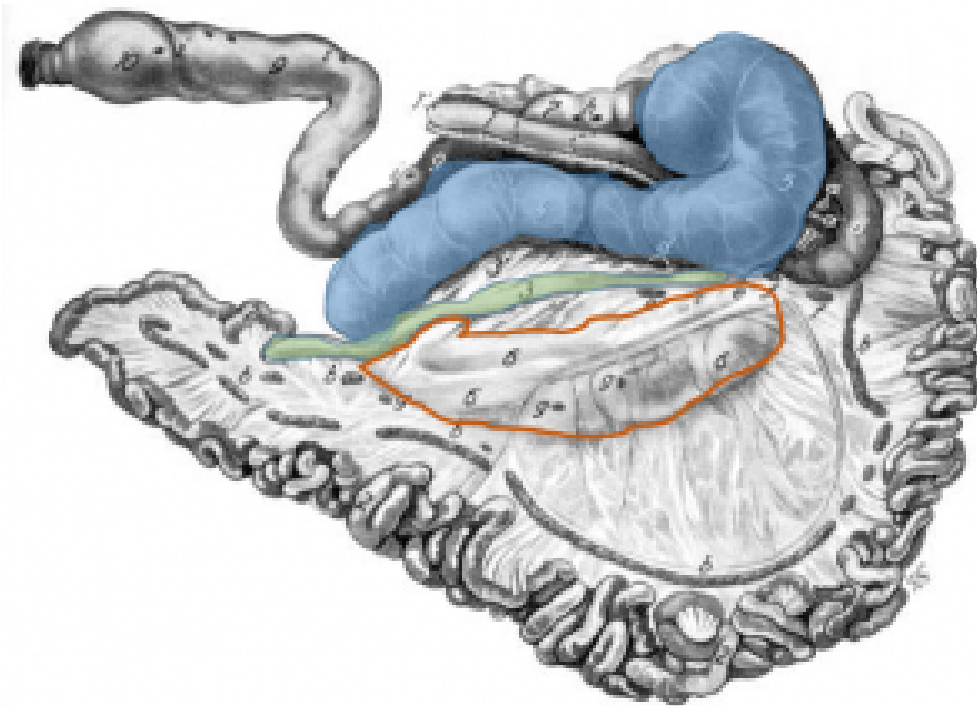
[Clinical findings and treatment in cows with caecal dilatation](#), Vet Record 2012

How to - Typhlotomy

Indications

Typhlotomy is performed to quickly remove fermenting contents in cattle with enlarged ceca due to hypocalcemia and poor motility and with cecal displacements and torsions.

Relevant anatomy



Cecum (blue), and ileum (green) are visible. The spiral colon (orange) is visible through the omental sling

The cecum is a blind ended sac with the tip pointing caudally. It is connected to the spiral colon dorsally and to the ileum ventrally. It has no identifiable features on palpation in the abdomen but is usually found sitting on top of the viscera between the rumen and omental sling. When distended it is easier to find and will usually protrude out the incision. It can distend to up to 3 feet, creating a “ping” that runs the length of the abdomen below the transverse processes. It is not tacked to the body wall so can displace and can twist on its long axis.

Preoperative management

Food restrictions: NA

NSAIDs/analgesics: Recommended preoperatively. Flunixin meglumine 1.1-2.2 mg/kg iv is standard.

Antibiotics: Recommended. As cows can wall off infection, there can be surprises inside. If milking, ceftiofur 2.2 mg/kg im is standard. In beef or non-lactating cattle, other options do exist. Remember: the label dose of procaine penicillin is ineffective!

Other: If the cow has signs of hypocalcemia (cold ear tips, slow PLR), calcium should be started.

Local blocks: A [line block](#), [inverted L](#) or [paravertebral](#) are all reasonable options.

Position/preparation: See [How to- Standing GI Surgery](#)

Surgery Supplies- Additional

- Extra sleeves and gloves
- Additional laceration or surgery pack is ideal
- Sterile saline for lavage
- Sterile assistant
- Lap sponge forceps -optional
- 3-0 absorbable suture (taper needle) for typhlotomy
- DA simplex – long flexible tubing attached to a 10ga needle for viscus decompression -optional
- Biopsy instruments and formalin- optional

Surgery Supplies – Standard

- Standard surgery pack
- Sterile sleeves for internal palpation
- Scalpel blade and handle
- 2 or 3 absorbable suture material for muscle closure
- 3+ nonabsorbable suture material for skin closure

Surgical procedure

See [How to- Standing GI Surgery](#) and [How to – Abdominal Exploratory](#)

It may not be possible to complete the exploratory until after the typhlotomy but it should be attempted to minimize contamination risk.

Instruments should be separated into typhlotomy (will be dirty) and closure sets (should stay clean). The typhlotomy set should include a scalpel blade, sterile saline, gauzes, needle holders, suture, scissors and lap sponge forceps or large hemostats. The closure set (the rest of the instruments) should be covered to minimize the risk of contamination. The surgeon and assistant surgeon should wear sterile sleeves and overgloves to ease clean up after the typhlotomy.

Exteriorize the cecum as much as possible.

The assistant is in charge of making sure the cecal contents and lavage fluid do not go into the abdomen. The assistant should hold the cecum near the tip but not at the tip. This will allow the assistant to direct the contents away from the abdomen and to keep the fluid flow downhill.

Create a 3-5 cm incision at the tip of the cecum. Use the sponge forceps or large clamp to pull out any obstructing chunks so the cecum empties as much as possible. Saline lavage can be provided by the sterile team or by an unsterile assistant.

Once the cecum is emptied, the assistant should elevate the tip of the cecum so that the incision is no longer ventral. This will minimize continued ingesta flow and keep the cecal incision clean for closure. The incision line is flushed gently (be careful of flush wanting to go back into the cow) and cleaned of any gross debris. The incision is closed with a double inverting pattern or a single continuous Lembert. It is important to ensure this line is tight. Midway through the pattern and at the end, hold the working end of the suture in your right hand and use the left to slide down the suture, pushing the sutured cecal tissue toward the suture knot. The cecum will gather slightly but leaks will be minimized. Once the closure is complete, the cecum is again cleaned and returned to the abdomen.

Occasionally the cecum will quickly refill. The incision can be opened and the process repeated.

The typhlotomy pack is covered or removed and the dirty sleeves and gloves removed. The remainder of the procedure can be completed as described in [How to- Standing GI Surgery](#), making sure the cecum is in its normal position with the tip pointing caudally.

Postoperative care

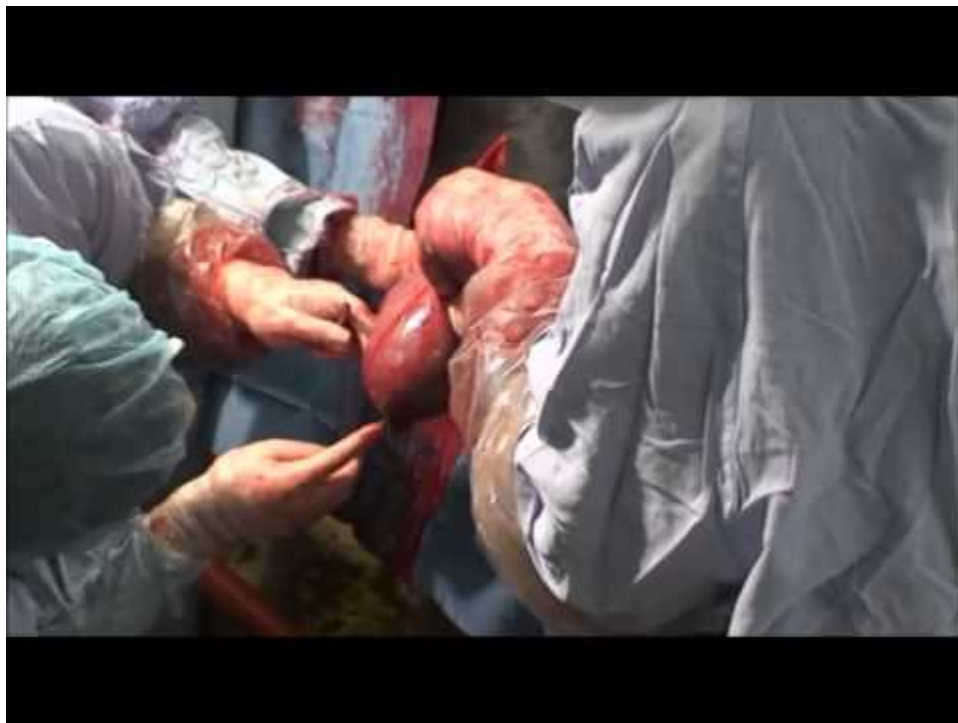- Antibiotics and NSAIDs should be continued for at least 3 days.
- Monitor calcium levels and for signs of peritonitis

Complications

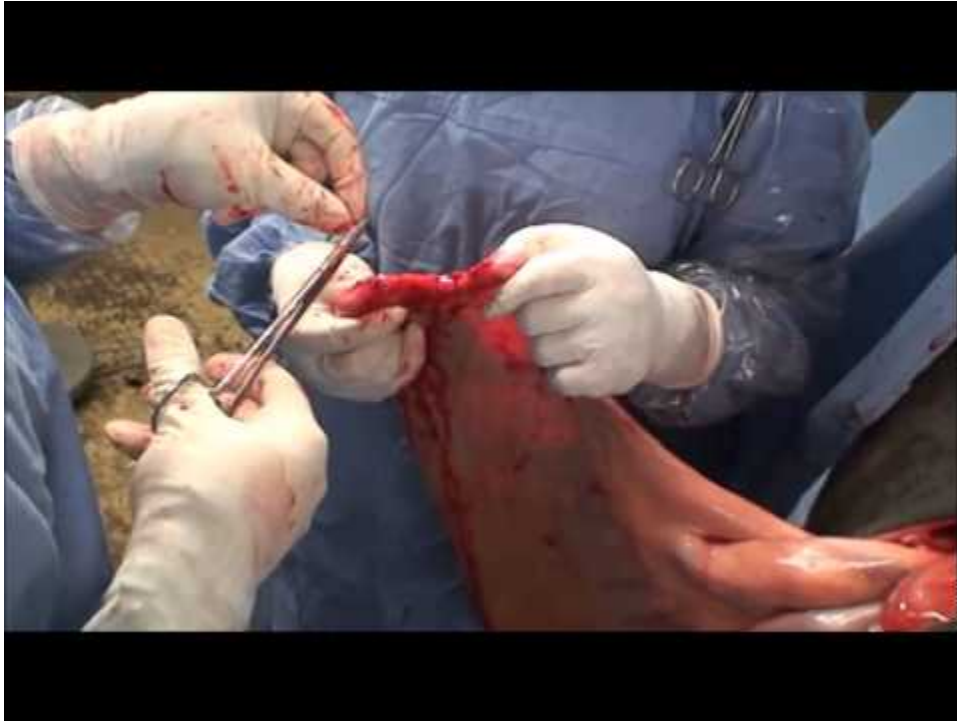- Peritonitis

- Incisional infection
- Continued motility disturbances

Videos



A YouTube element has been excluded from this version of the text. You can view it online here: <https://open.lib.umn.edu/largeanimalsurgery/?p=3197>



A YouTube element has been excluded from this version of the text. You can view it online here: <https://open.lib.umn.edu/largeanimalsurgery/?p=3197>

Resources

Rectal and perirectal disorders



An interactive or media element has been excluded from this version of the text. You can view it online here:
<https://open.lib.umn.edu/largeanimalsurgery/?p=2338>

Practice



An interactive or media element has been excluded from this version of the text. You can view it online here:
<https://open.lib.umn.edu/largeanimalsurgery/?p=2307>



An interactive or media element has been excluded from this version of the text. You can view it online here:
<https://open.lib.umn.edu/largeanimalsurgery/?p=2307>



An interactive or media element has been excluded from this version of the text. You can view it online here:
<https://open.lib.umn.edu/largeanimalsurgery/?p=2307>



An interactive or media element has been excluded from this version of the text. You can view it online here:
<https://open.lib.umn.edu/largeanimalsurgery/?p=2307>



An interactive or media element has been excluded from this version of the text. You can view it online here:
<https://open.lib.umn.edu/largeanimalsurgery/?p=2307>

Female urogenital surgery

Vaginal prolapses, rectovaginal trauma and repair of injured structures

Perineal analgesia

Your choices for regional anesthesia in the perineal area are local infiltration, epidurals, perineal nerve block, and/or splash blocks. General anesthesia would also work but is often more challenging as the anatomy is changed by the change in animal position.

Local infiltration

Line blocks can be quick and easy. We routinely use lidocaine (without epinephrine) and a small gauge needle. Small ruminants are sensitive to lidocaine so monitoring the total dose is important.

Line blocks are very useful for caslicks, lacerations, and other superficial procedures.

Epidurals

Epidurals are relatively easy in dairy cattle and harder but generally doable in the other food animal species. Lidocaine is used routinely. The main side effect of lidocaine is ataxia and that is typically not as problematic in food animals. Lidocaine works quickly so you can tell if it worked. Assume it will wear off in about an hour. If you need longer duration effects, other options include a combination of xylazine + lidocaine or the use of mepivacaine.

[Local anesthesia chapter](#)

Pudendal nerve block

This is a really cool block. It is great for bull penis surgery and for some cow urogenital procedures.



An interactive or media element has been excluded from this version of the text. You can view it online here:

<https://open.lib.umn.edu/largeanimalsurgery/?p=2442>

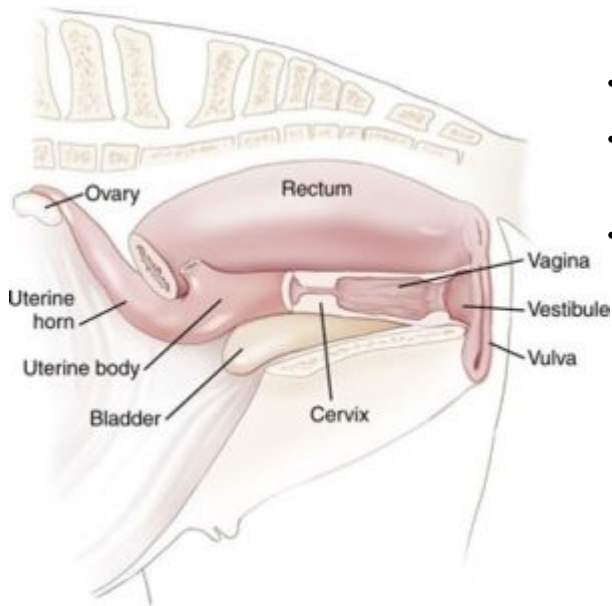


A YouTube element has been excluded from this version of the text. You can view it online here: <https://open.lib.umn.edu/largeanimalsurgery/?p=2442>

Splash blocks

Lidocaine is absorbed through mucous membranes. Spraying or splashing the lidocaine into the vulva will help a little. This is often an added analgesic; rarely is it enough on its own (or your dentist would not actually inject your gums for dental work).

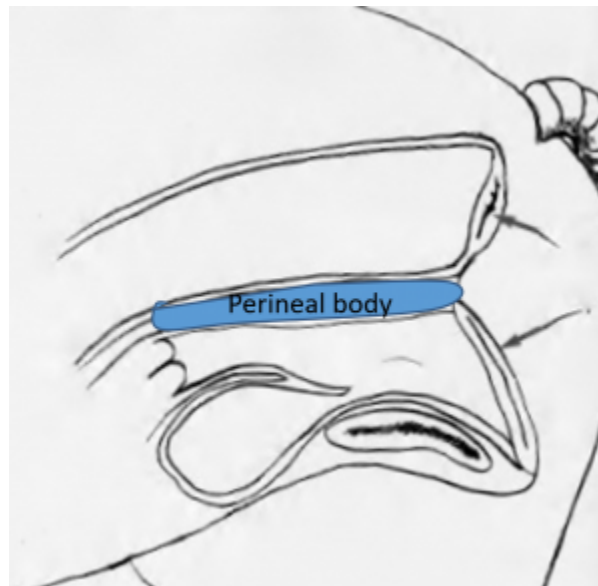
Anatomy

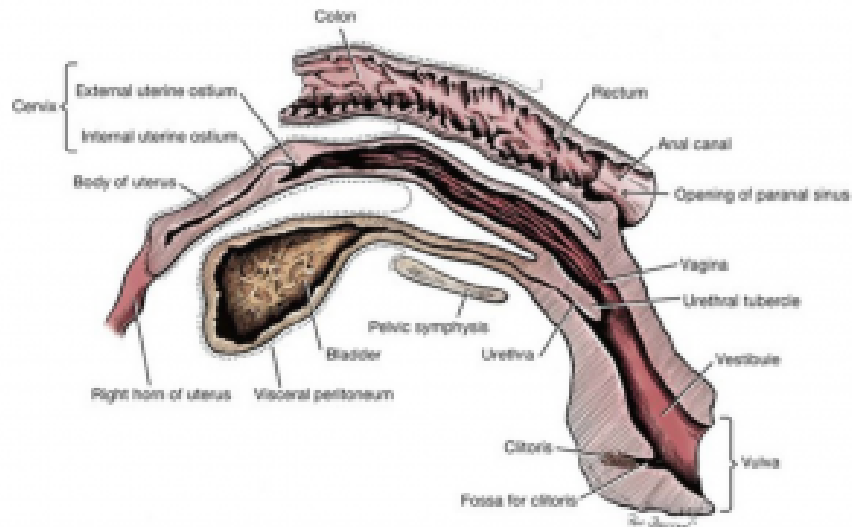


There are 3 main barriers to the uterus:

- vulvar seal due to good anatomic closure of the vulvar lips
- vestibular sphincter (vestibulovaginal ring) due to the perineal body and vaginal tone
- cervix- cervical seal due to good muscle tone

The perineal body is a muscular structure surrounding the vagina. It is composed of the constrictor muscles of the vestibule and vulva.





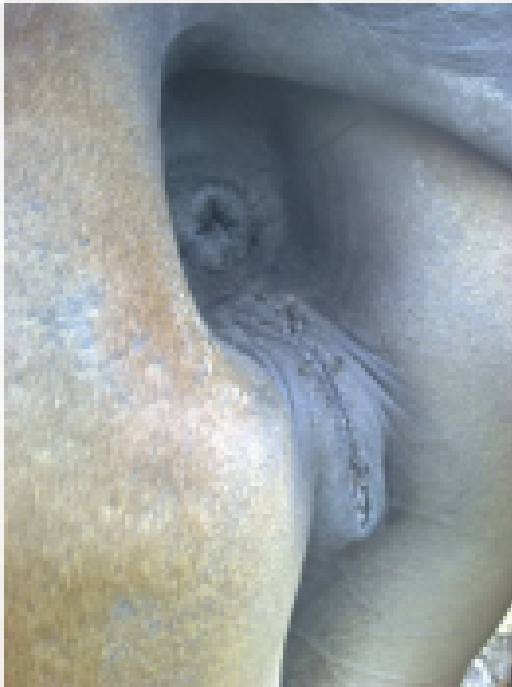
<https://veteriankey.com/vagina-vestibule-and-vulva/> Note muscular tissue surrounding the vulva and vestibule

With trauma and/or normal aging, these can be disrupted.

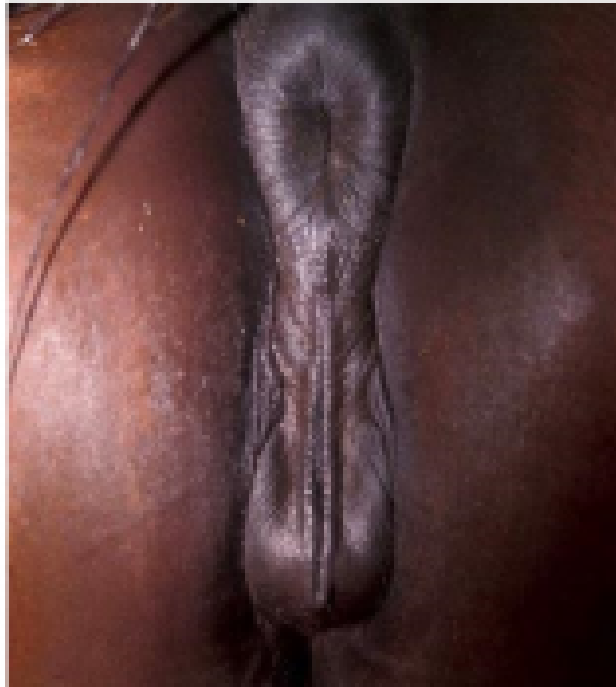Vulvar seal

The vulvar seal can be disrupted by direct trauma (including foaling) or with aging changes. As the mare goes through multiple deliveries and/or weight changes, the vulva can be pulled into a tilt or the constrictor muscles weaken. The vulva should be vertical with 75% of the vulva below the pelvic bone.

Mares can develop “splachnoptosis”, a tilt to the vulva due to forward traction by the viscera.



Splanchnoptosis

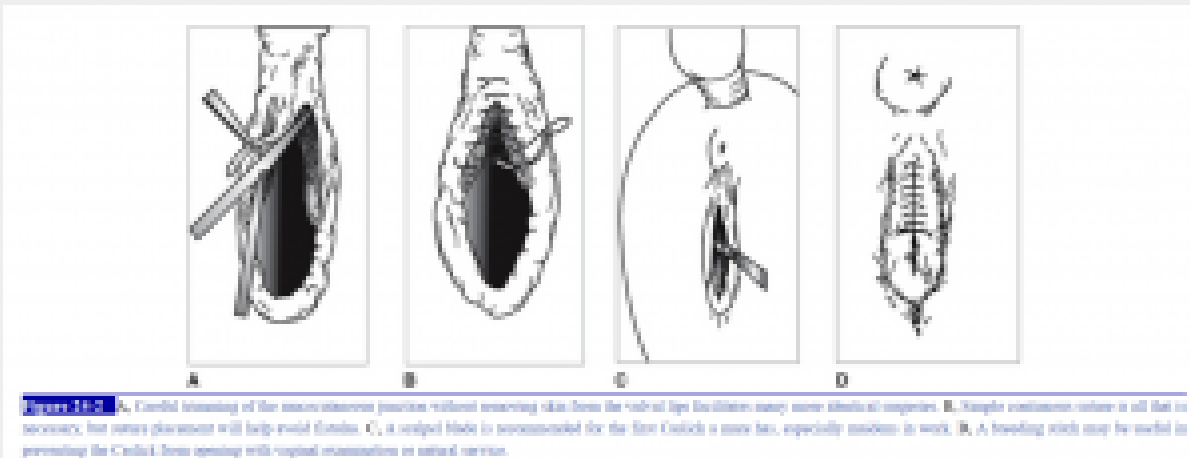


Good conformation

When the vulvar seal is disrupted, mares develop pneumovagina (windsucking) and vaginitis.

Treatment is performance of a Caslick's suture to artificially create vulvar closure. If the mare is bred, the Caslick's does need to be transected prior to foaling!

[Selected Reproductive Surgery of the Broodmare](#)

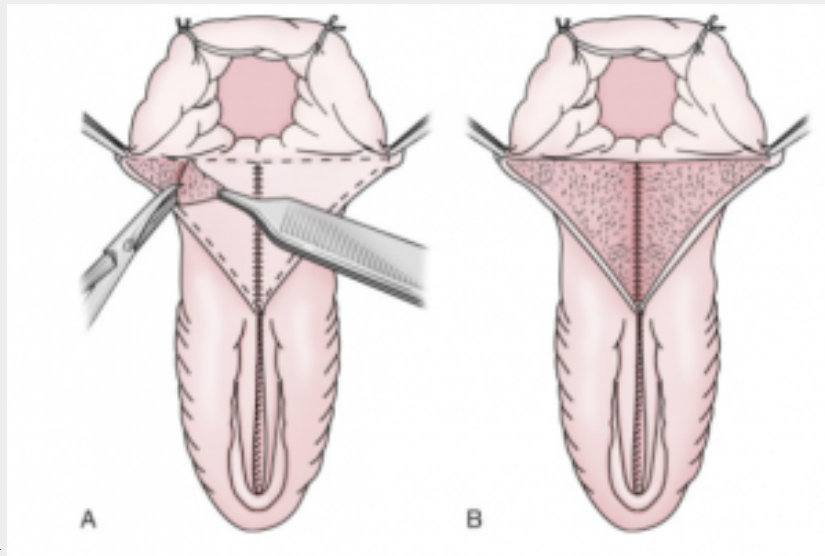


Local anesthesia is generally via a line block on each side of the vulva. This does create temporary swelling.

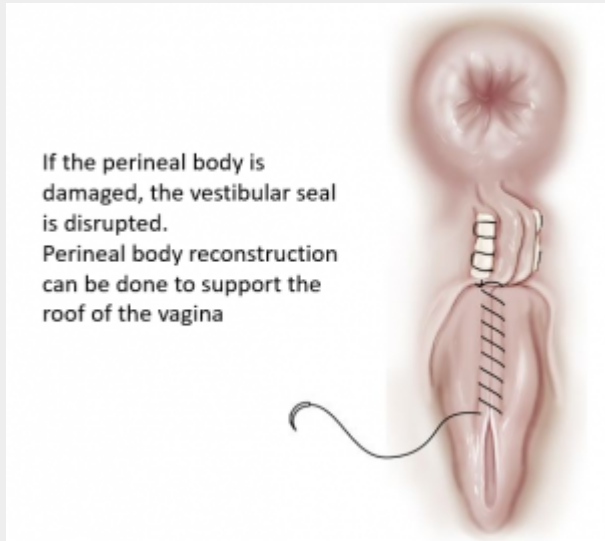
Place sutures more closely together than normal to avoid gaps when the swelling resolves. 2-0 absorbable or non-absorbable suture on a cutting needle works well.

Vestibular seal

Over time or with deliveries, the sphincter muscles can be damaged, resulting in a thinned or ineffective perineal body. The perineal body can be reconstructed using a similar approach as for a Caslick's. This procedure may be useful if a Caslick's does not resolve the windsucking or vaginitis.



[Perineal body](#)



Cervical seal

Generally damage to the cervix is iatrogenic and caused by veterinary manipulation during dystocias. Cervical trauma is identified as a thinned area of the cervix rather than a distinct gap. The cervix is pinched between the thumb and first finger (one of which is in the lumen of the cervix) to identify a thinned area. This is easiest to detect in diestrus. Fixing cervical tears is challenging, requires special instruments and is considered a referral procedure.

Key Takeaways

Caslicks -Recreates the vulvar seal. Useful for pneumovagina and vaginitis occurring due to lack of a vulvar seal. Contraindicated if severe slope (splachnoptosis) and if doing one would make urine hit the Caslicks and bound back into the vagina. Needs to be removed for natural service or parturition

Perineal body transection-. Separates the pull of the viscera from the vagina. Useful for urine pooling due to severe slope and for realigning vulva so a Caslicks can be done without creating more issues. Left to heal by second intention.

Perineal body reconstruction – Creates more support to the vestibule to help reinforce the vestibular sphincter. Useful for pneumovagina and vaginitis that is related to aging changes and/or trauma during parturition. It provides extra strength to a Caslicks at the dorsal aspect.

Cervical reconstruction – Fixes thinned areas of the cervix. Performed for defects in the cervical seal. Referral recommended

Resources

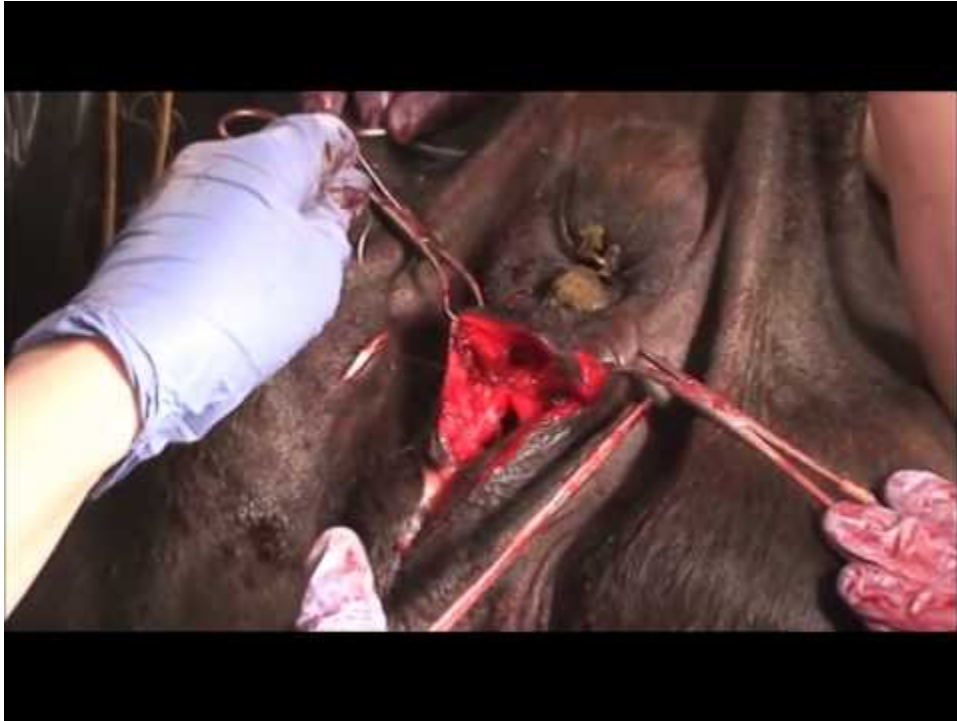[Vulvar conformation, vulvar injuries and the Caslick](#), equine reproduction.com-

- Note: good for caslicks and first degree tears. Not good advice for repair timing on third degree tears!

This video shows a good Caslicks but with poor instrument handling



A YouTube element has been excluded from this version of the text. You can view it online here: <https://open.lib.umn.edu/largeanimalsurgery/?p=1171>



A YouTube element has been excluded from this version of the text. You can view it online here: <https://open.lib.umn.edu/largeanimalsurgery/?p=1171>

How to - Caslick's suture

Indications

A Caslick's suture is used in mares to treat vulvar trauma, pneumovagina, vaginitis and infertility. It should not be used if splanchnoptosis is severe and the Caslicks would impair urine flow.

A deep (thick) Caslick's may be used as a permanent means of preventing vaginal prolapse.

Relevant anatomy

The vulvar lips comprise the first barrier to the uterus. If the vulvar lips do not seal totally, a Caslick's suture is placed to create the seal.

Preoperative management

Food restrictions: NA

NSAIDs/analgesics: NSAIDs are recommended preoperatively.

Antibiotics:NA

Tetanus prophylaxis is recommended.

Local blocks: Typically a line block on each side of the vulva is performed.

Position/preparation: The patient is sedated as needed and restrained in stocks (mares) or headgates (cattle). Sterile gloves are recommended.

Surgery Supplies:

- Scalpel blade and handle
- Metzenbaums
- Suture scissors
- 2-0 suture on a cutting needle

Surgical procedure

A thin strip of tissue is removed from each side of the vulva at the mucocutaneous junction, extending from the dorsal junction to the pelvic brim (approximately 2/3 of the length). The cut edges are sutured together using a split thickness Ford Interlocking or continuous pattern of 2-0 absorbable or nonabsorbable suture material. Due to the local block, bites should be taken closely together (1/2 cm) and pulled snugly to prevent gaps.

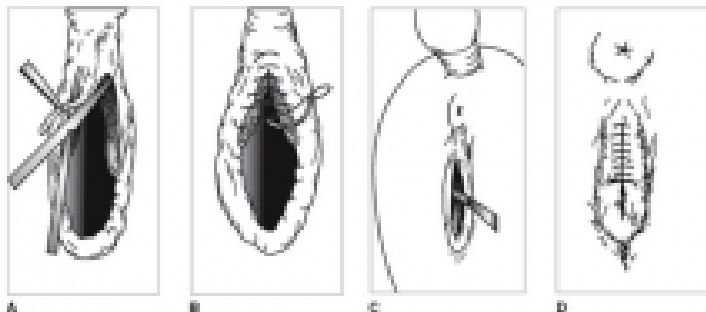
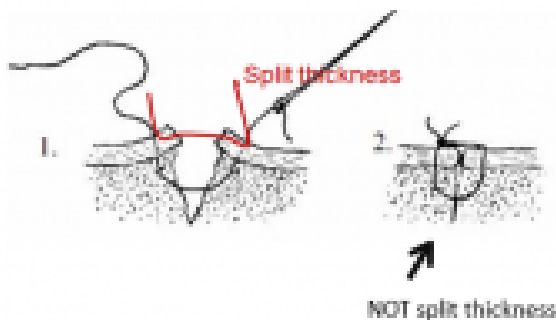
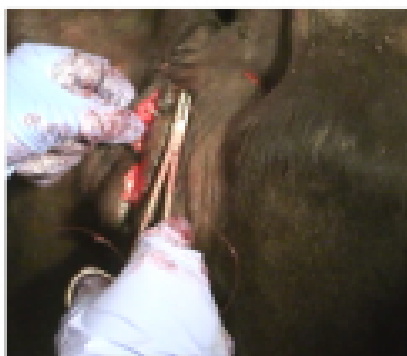

Figure 12-1 A, Careful trimming of the mucocutaneous junction without removing skin from the vulvar lip facilitates easy post-operative inspection. B, Single continuous suture is all that is necessary; two suture placements will help avoid folds. C, A scalpel blade is recommended for the first Caslick's suture line, especially machines in work. D, A locking stitch may be useful in preventing the Caslick from opening with vaginal examination or natural service.



Split thickness suturing

Postoperative care

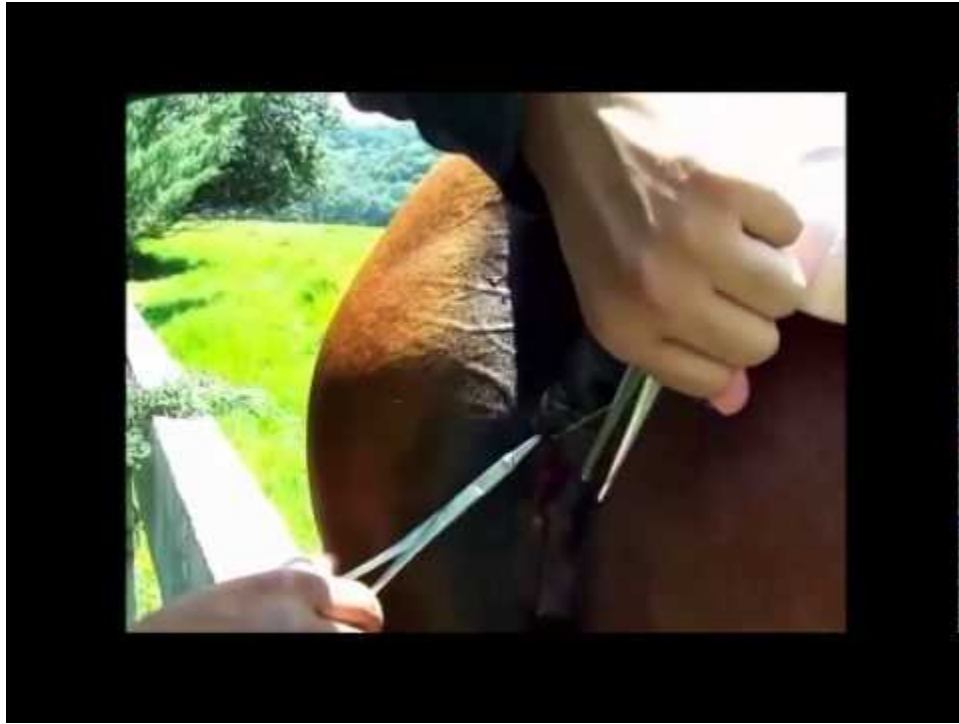- Sutures are removed in 10-14 days.
- Episiotomy is performed to open the Caslick's prior to parturition

Complications

- Gaps may develop between the vulvar lips if the suture pattern is too loose.
- Natural breeding with the vulvar lips closed can lead to trauma to the mare and/or stallion
- Foaling through the closed vulva can lead to trauma to mare and/or foal

- Each time the Caslick's is replaced, it becomes thicker and harder to create a seal.

Videos



A YouTube element has been excluded from this version of the text. You can view it online here: <https://open.lib.umn.edu/largeanimalsurgery/?p=3295>

Resources

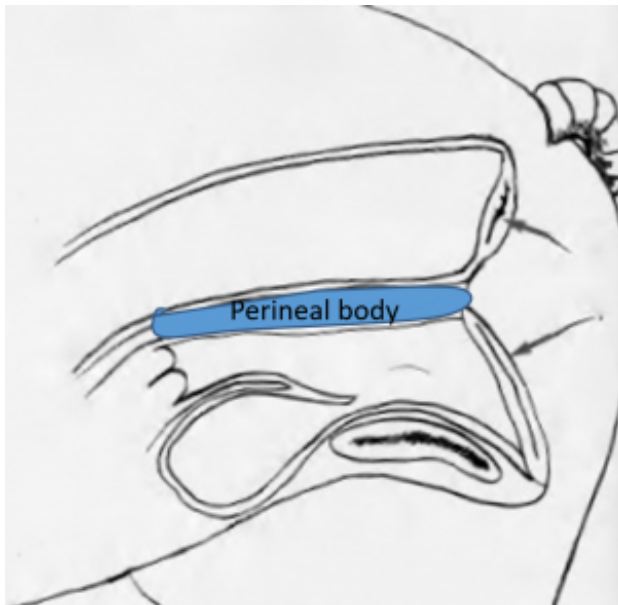
How to - Perineal body reconstruction

Indications

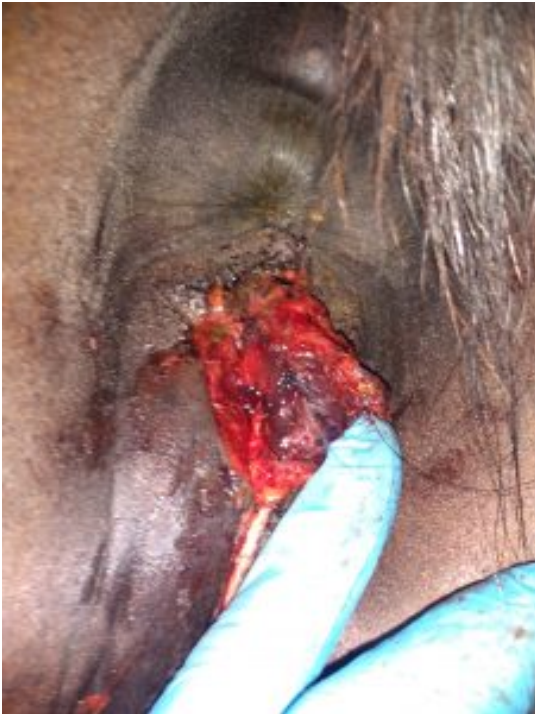The perineal body is reconstructed when it is weakened by trauma or torn with parturition.

Relevant anatomy

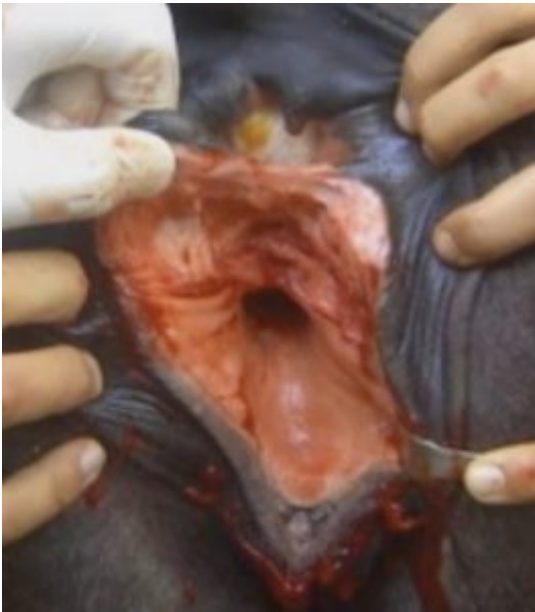The perineal body is a muscular structure dorsal to the vagina and ventral to the rectum. It provides support to the vestibular seal, the second barrier to the uterus as well as to the vulvar lips.



Due to its location, it is easily traumatized during parturition.



At the time of injury, tissues are very friable and undergoing more necrosis. Surgery should be postponed until the area is well healed.



Preoperative management

Food restrictions: NA

NSAIDs/analgesics: Preoperative NSAIDs are recommended

Antibiotics: Preoperative antibiotics are recommended.

Tetanus prophylaxis is recommended.

Local blocks: [Local infiltration or epidural](#)

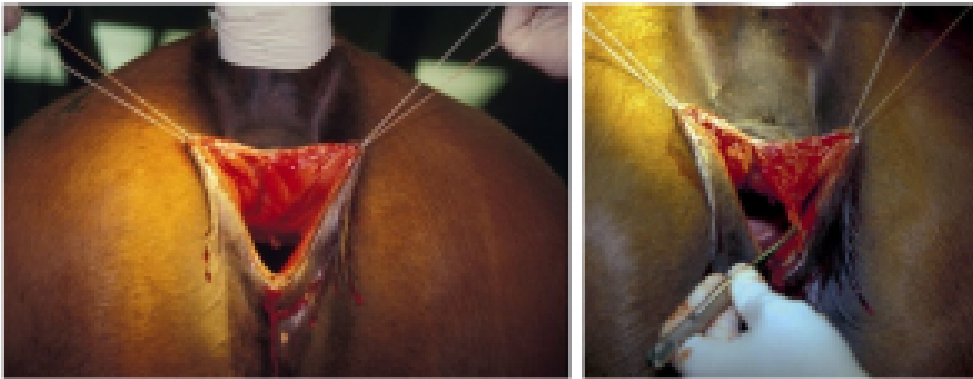
Position/preparation: Repair at the time of injury is unrewarding as most will dehisce. Repair should wait until the area has developed fibrous tissue, at least 3-4 weeks. The procedure is done standing with the patient sedated as needed. Surgeon should be gloved.

Surgery Supplies:

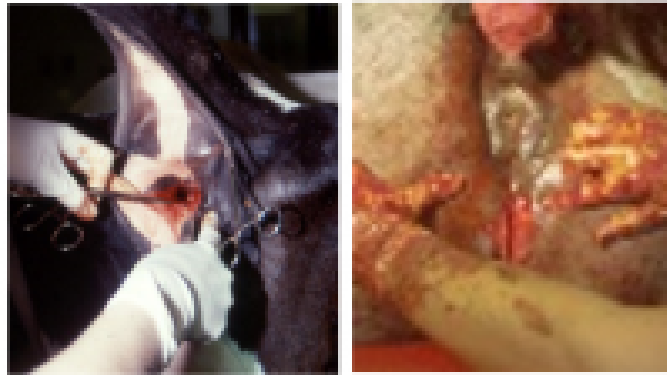
- Scalpel and handle
- Metzenbaum scissors
- Thumb forceps
- Needle holders
- Suture scissors
- 2-0 to 3-0 absorbable suture, taper needle
- 2-0 suture, cutting needle (Caslick's)

Surgical procedure

Stay sutures are held by an assistant or clamped to the perineum to provide exposure. The healed epithelial tissue is dissected off the surface, creating fresh edges in a roughly triangular pattern, extending the depth of the tear.



Once the edges are freshened, the two sides are apposed starting the in deeper tissues and using any pattern. Often cruciates are most useful



The most superficial layer is closed as for a [Caslicks](#) (continuous split thickness pattern) or with an interdermal pattern.

Postoperative care

- Keep the area clean and dry.
- Suture removal if needed in 10-14 days

Complications

The perineal body will not be as strong or as flexible as it was originally; this may lead to tears with parturition.

Videos

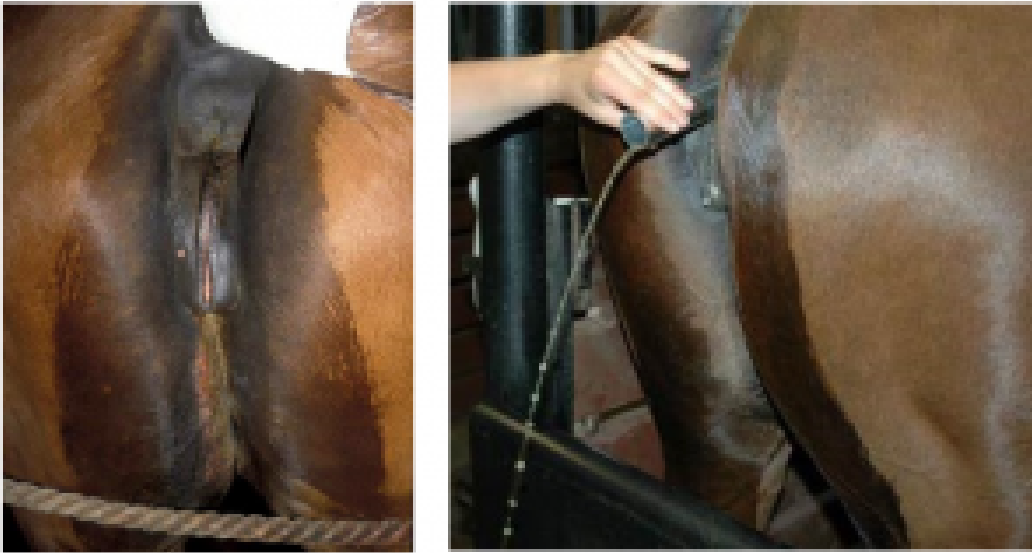
Resources

Vulva, vestibule, vagina and cervix, [Equine Surgery](#)

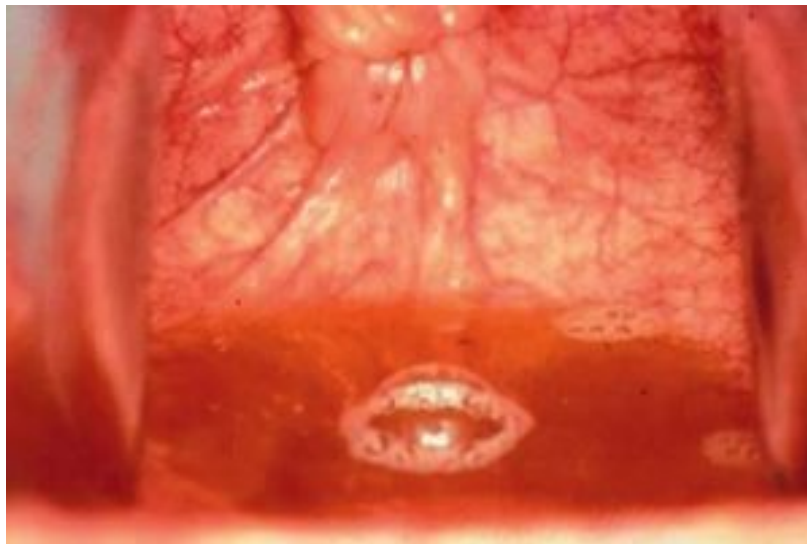[Surgery of the Bovine Reproductive System and Urinary Tract](#), Farm Animal Surgery 2nd edition

Urine pooling, perineal body transection and urethral extension

Mares (or cows) with poor conformation, particularly splanchnoptosis, can develop urine pooling due to a tilt in the vaginal vault



Vulvar tilt and evidence of urine pooling



view of urine inside the vagina (cervix at 12:00)

Urine is highly irritating and can create further vaginitis and/or enter the uterus. Urine in the uterus causes fibrosis and leads to infertility.

Treatment

Since vaginitis can lead to urine pooling, the first treatment is typically a Caslicks. *This is a bad idea if the vulva is severely tilted and mostly above the pelvic brim.*

If problems persist, the **perineal body can be transected** (Pouret's procedure), removing the traction from the viscera. This is a simple procedure performed with an epidural or line block. The tissue is transected until the vulva is again vertical. This is reflected internally as a flatter vaginal vault. While the article below describes closure, these usually do well when left to heal by second intention.

Equine Perineal and Vulvar Conformation Correction Using a Modification of Pouret's Technique




Fig. 1. Note the abnormal vulvar conformation before surgery, with the vulvar **labia** partially opened and the horizontal skin incision of 3-4 cm, which was made half way between the anus and the upper **commissure** of the vulva.

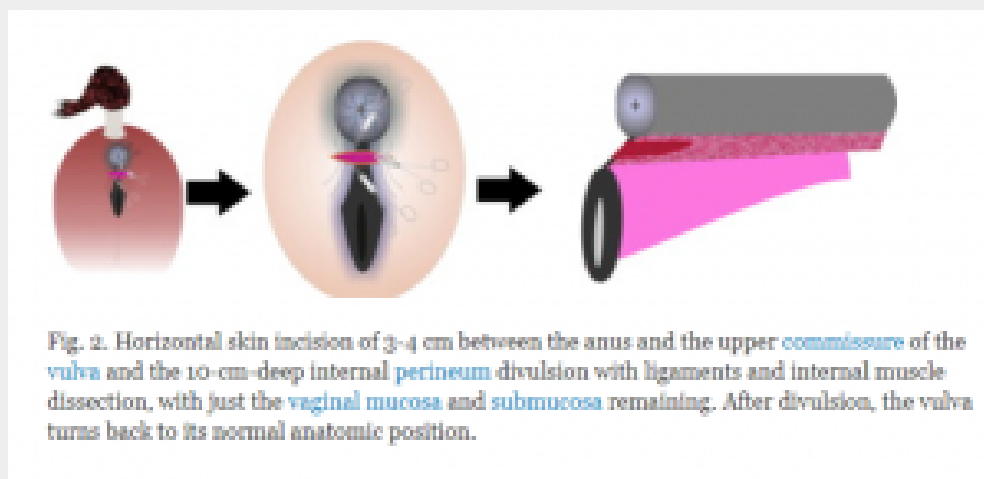
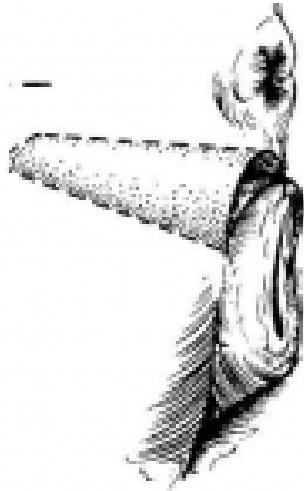
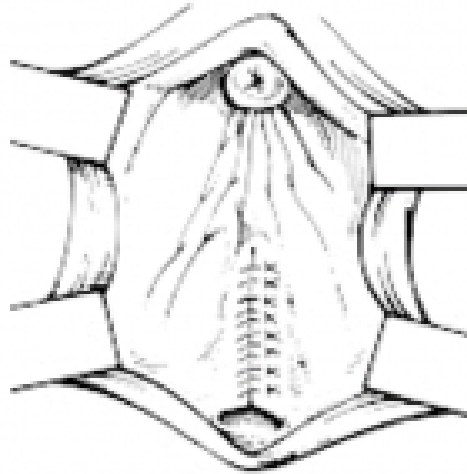


Fig. 2. Horizontal skin incision of 3-4 cm between the anus and the upper **commissure** of the vulva and the 10-cm-deep internal **perineum** division with ligaments and internal muscle dissection, with just the **vaginal mucosa** and **submucosa** remaining. After division, the vulva turns back to its normal anatomic position.

If perineal body transection is not sufficient, the urethra tunnel can be extended so that urine is released close to the vulvar lips, giving minimal opportunity to flow back toward the cervix. Both procedures can also be done at the same time.



Perineal body transection



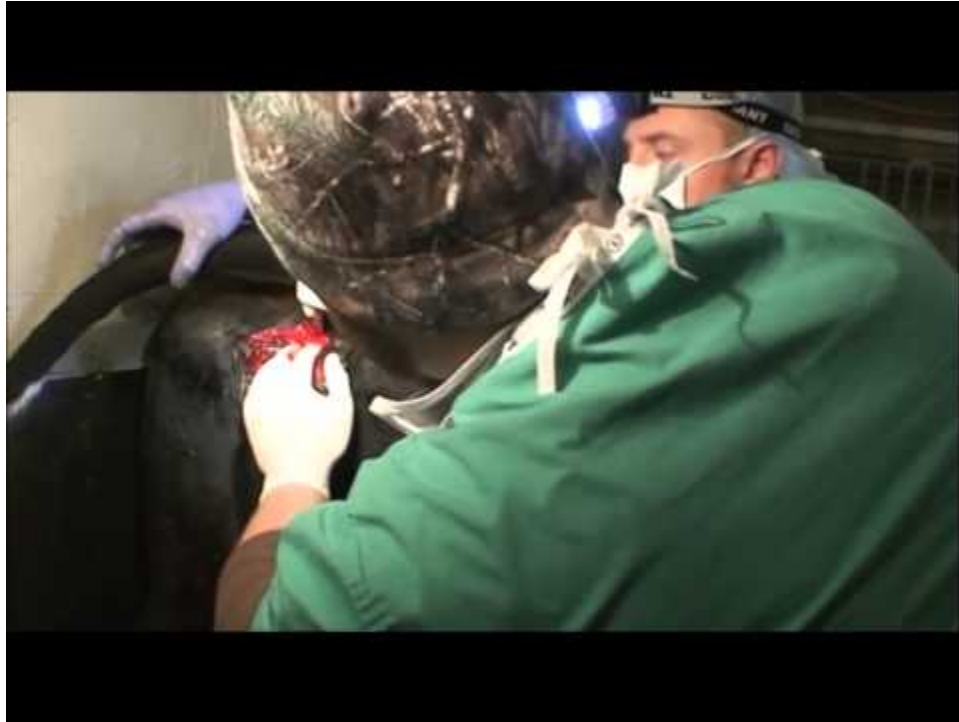Urethral extension

Key Takeaways

To fix urine pooling:

- Perform Caslicks if slope isn't too severe
- Perform perineal body transection if splanchnoptosis
- Perform urethral extension if still not fixed

Resources



A YouTube element has been excluded from this version of the text. You can view it online here: <https://open.lib.umn.edu/largeanimalsurgery/?p=2657>

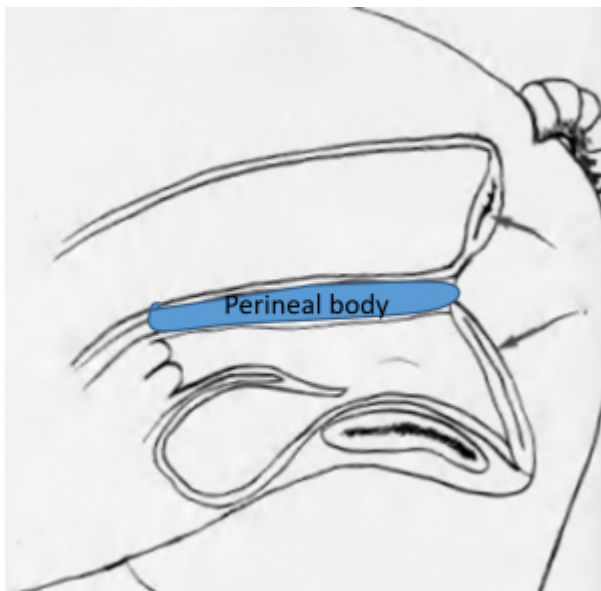
How to - Perineal body transection

Indications

Perineal body transection is performed for severe splanchnoptosis, for pneumovagina unresponsive to Caslicks, and for mild cases of urine pooling.

Relevant anatomy

The perineal body is located between the dorsal vagina and the rectal floor. It is comprised of sphincter muscles that create tone for the vestibule, help maintain the vestibular sphincter, and also connects the vaginal vault to the rectum and viscera (this isn't always helpful).



Preoperative management

Food restrictions: NA

NSAIDs/analgesics: Preoperative NSAID recommended

Antibiotics: NA

Tetanus prophylaxis is recommended.

Local blocks: [Line block or epidural](#)


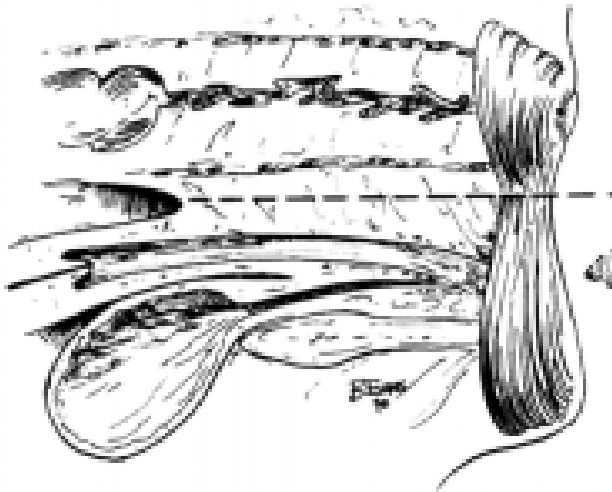
Position/preparation: Standing procedure. The rectum should be emptied prior to surgery. The area is cleaned and blocked. Surgeon should be gloved.

Surgery Supplies:

- Scalpel blade and handle
- Towel clamps

Surgical procedure

A towel clamp is hung on the dorsal aspect of the vulva. A 4-6 cm inverted U incision is made between the rectum and vagina. Sharp scalpel dissection is carried forward until the vulva is vertical. Slight additional dissection may be helpful to minimize changes after healing.



The towel clamp is removed and the area left open for second intention healing.

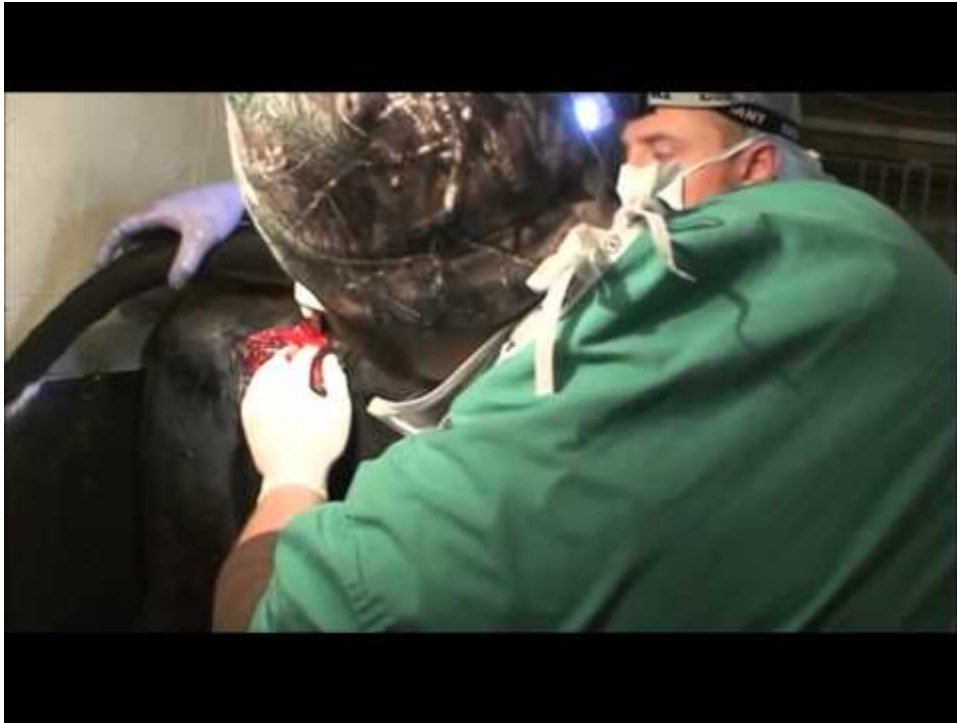Postoperative care

- Clean the wound daily until epithelialized.

Complications

- Very extensive dissection could enter the peritoneal cavity but this would be difficult as the peritoneal reflection is approximately 12" deep

Videos



A YouTube element has been excluded from this version of the text. You can view it online here: <https://open.lib.umn.edu/largeanimalsurgery/?p=3241>

Resources

O’Kinnon and Vasey, [Mare Surgery](#)

How to - Urethral extension

Indications

Urethral extension is indicated for urine pooling that does not respond to Caslicks and/or perineal body transection. There are multiple techniques.

Relevant anatomy

The urethra opens on the floor of the vaginal, approximately 6" from the vulvar lips. The floor of the vagina is used to create a new tunnel.

Preoperative management

Food restrictions:NA

NSAIDs/analgesics:NSAIDs are recommended preoperatively.

Antibiotics: Antibiotics are generally considered optional. If used, trimethoprim sulfa is fine in horses. Ceftiofur or penicillin could be used in cattle.

Tetanus prophylaxis is recommended in horses

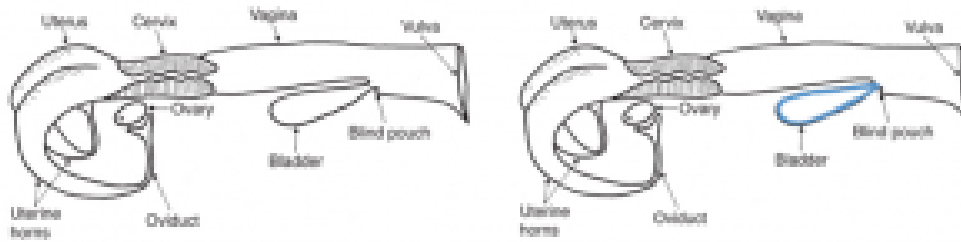
Local blocks: [Epidural +/- splash block](#)

Position/preparation:

The patient is restrained in a standing position and sedated as needed. The surgeon wears sterile gloves and uses sterile gel lubrication to ease manipulation within the vagina.

The tail is tied to the side, the rectum is emptied and the perineal area cleaned.

Pass a urinary catheter or foley into the urethra. The bovine urethral opening is tightly closed unless the cow has just urinated. The opening is approximately wrist deep, just past the blind urethral diverticulum. The tissue just beyond the diverticulum is actually two layers and is the opening of the urethra. Sometimes a urethra papilla can be palpated on the floor. Push forward and down over the papilla.



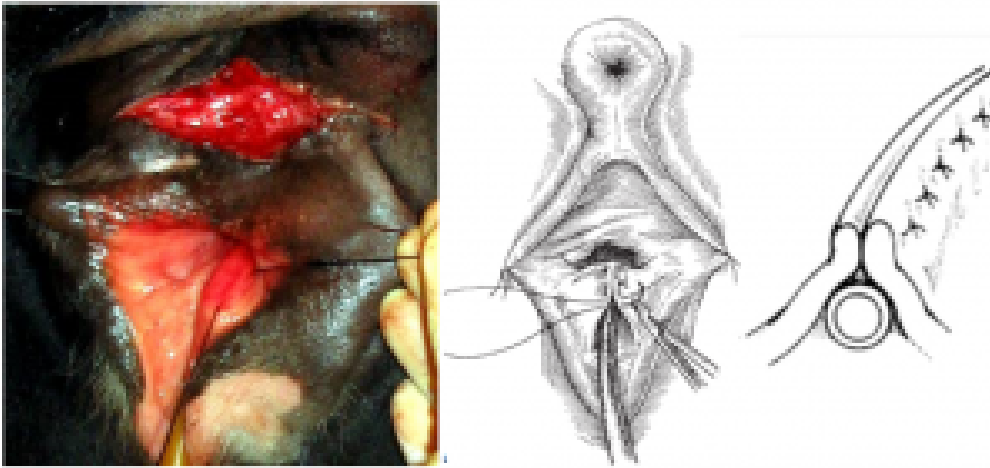
The urethral opening is much less open than it appears in the diagram.

Surgery Supplies:

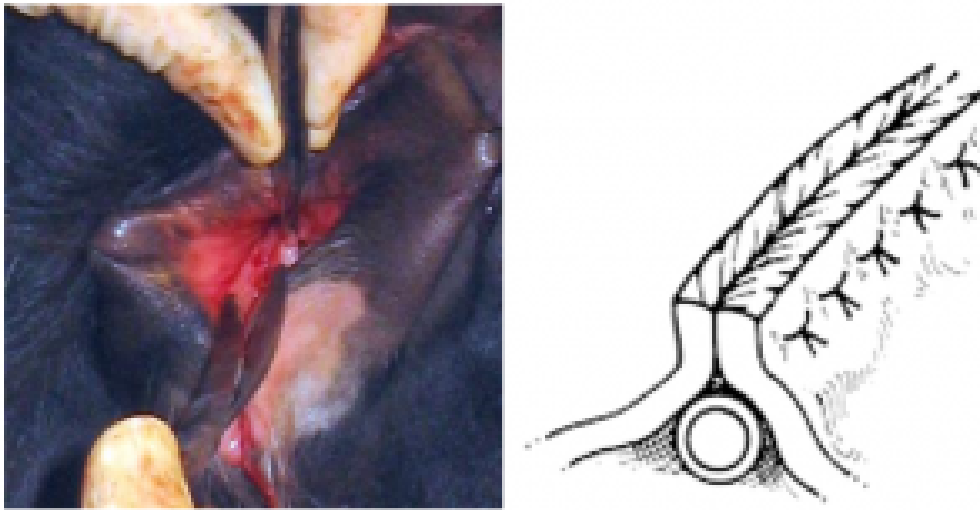
- Urinary catheter
- Scalpel and scalpel handle
- 0 suture, taper needle
- 2-0 suture, taper needle
- Needle holders
- Metzenbaum scissors
- Suture scissors
- Speculum or stay sutures
- Headlamp
- Allis tissue forceps – optional
- New methylene blue -optional

Surgical procedure – Shires & Kaneps

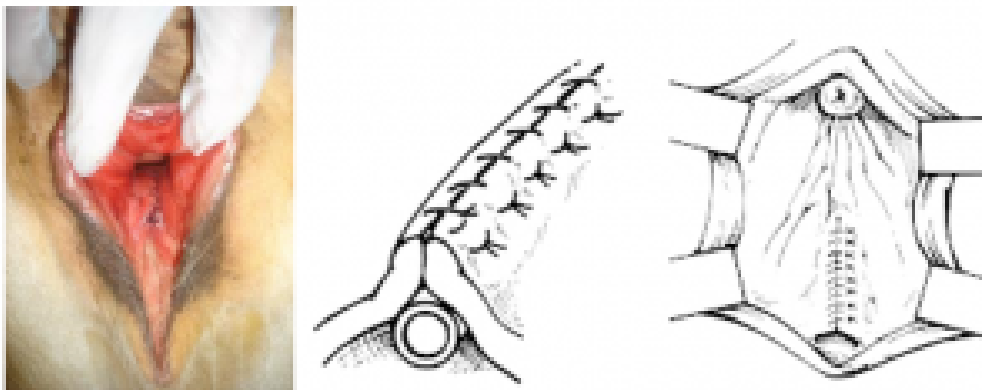
The vaginal vault is held open by stay sutures on the vulvar lips or use of a speculum. The floor of the vagina is loosely tacked up over the catheter using 2-3 horizontal mattress sutures of 0 suture material. The goal of this step is to hold the tissue in place; a water tight seal is not needed. Leave the suture ends long in case removal is needed.



The top edges of the tented tissue is transected using Metzenbaum scissors. This creates a fresh edge.




The fresh edges are apposed using a simple continuous pattern with 2-0 absorbable suture material.



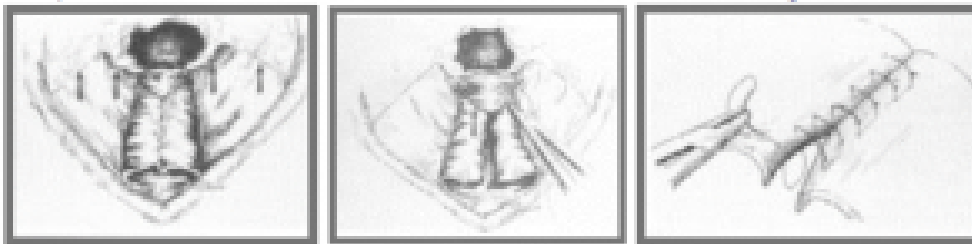
The catheter is removed. If the tunnel is tight, the horizontal mattress sutures can be cut free.

Surgical procedure – McKinnon & Vasey

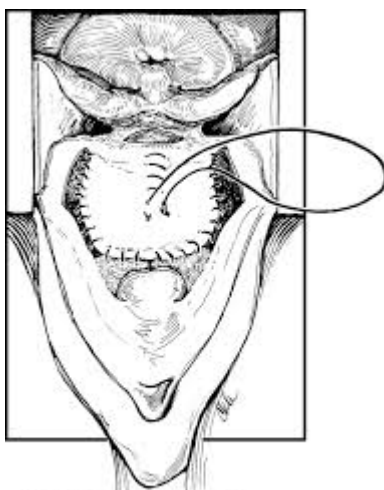
After gaining exposure of the vaginal vault, the transverse fold is grasped with Allis tissue forceps, retracted caudally and split into dorsal and ventral shelves using scalpel dissection horizontally across the fold. The dissection is continued on the vaginal walls, creating a flap of tissue on either side. Each flap should extend to the vulvar labia. The dissection is continued until both flaps can reach past the midline without tension. It can be challenging to determine where the dissection is complete due to the bleeding involved. Sterile new methylene blue dye can be used to aid in visualization of what is already dissected as the dye sticks only to the submucosal tissues.



The three flaps are opposed using a Connell pattern (full thickness Cushing).



Additional variations on this technique exist, including further dissection of the transverse fold so that the top layer can be pulled forward and cover the sutured Y part of the repair.



Postoperative care

- NSAIDs should be continued for 3 days
- The patient should be monitored to ensure she can urinate without difficulty

Complications

- Fistula formation is relatively common. Depending on the size of the fistula, repair may not be necessary

Videos

Resources

Shires and Kaneps, A practical and simple surgical technique for repair of urine pooling in the mare, AAEP circa 1989

McKinnon and Vasey, [Mare Surgery](#)

Rectovaginal lacerations

Rectovaginal tears generally occur with parturition and cause different levels of injury

- injury to the vulva only (type I)
- injury to the vulva and perineal body (type II)
- injury to the roof of the vagina and floor of the rectum (type III)

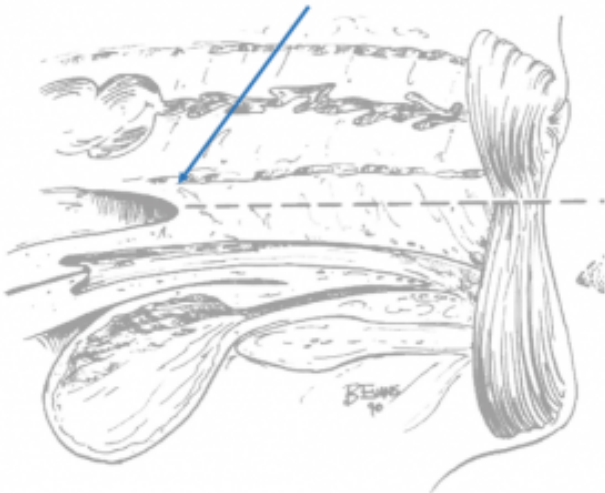
Therapy

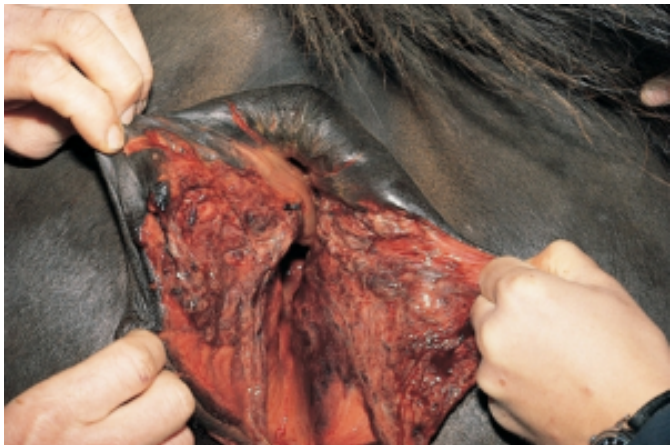
Type I tears are treated by Caslick's procedure.

Type II tears are treated by perineal body reconstruction and Caslick's procedure.

Type III tears are treated by reconstruction of the two tubes (vagina and rectum) plus perineal body reconstruction and Caslicks. This is typically a referral procedure although it can be performed in the field by an experienced surgeon. The laceration does NOT extend into the peritoneal cavity in most situations.

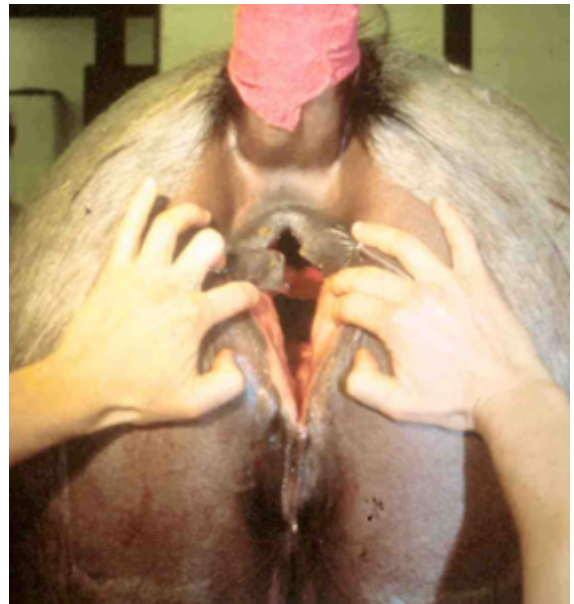Peritoneal reflection usually >12" in from the anus (depends on abdominal fill etc)





acute injury

For



ready for repair

initial care, animals generally require NSAIDs and often antibiotic therapy due to local tissue damage. For cattle, this is typically flunixin meglumine and ceftiofur or similar antibiotic. For horses, this is typically either flunixin meglumine or phenylbutazone and trimethoprim sulfa.

Due to the amount of tissue trauma, it is pointless to repair these at the time they occur. The amount of blunt trauma results in continued tissue deterioration and any sutures placed will dehiscence in 2-3 days. Granulation tissue develops in 5 days and is mostly vessels. It does not hold suture. While the vulva and perineal body can often be repaired at 2-4 weeks, type III tear repair requires fibrous tissue formation and should be delayed until 4-6 weeks after injury.

Type III tears are challenging to repair due to the high flora content, presence of collagenase producing bacteria and, in horses, firm fecal balls. Mares should be on a laxative diet and have soft feces prior to repair. If the foal is alive and nursing, repair should be delayed until after the foal is weaned. It is unreasonable a mare to produce enough milk on the adjusted diet.

Prognosis is actually very good with appropriate repair. While the vagina does get contaminated until the tear is fixed, it can rapidly clear the inflammation during the next heat cycle. The rectum and vagina typically heal quickly. The biggest issue is fistula formation due to tension on the repair. Second attempts are common.

Resources

[Urogenital surgery with the mare standing](#), VCNA 2014 -details at the end of the article; just if interested


How to - 3rd degree rectovaginal tear repair

Indications

3rd degree tears are the result of dystocia. The baby splits the roof the vagina, the perineal body and the floor of the rectum. This creates two tubes that do not extend the normal distance.

Relevant anatomy

The trauma creates two tubes that do not extend the normal distance. Neither tube has a sphincter (no anal sphincter, no vulvar lips).



Preoperative management

Food restrictions: Mares should be on a low bulk diet – mostly grass and easily digestible feedstuffs. No hay. No dietary change is needed for most cattle due to the softer feces.

NSAIDs/analgesics: Perioperative NSAIDs are recommended.

Antibiotics: Perioperative antibiotics are needed.

Tetanus prophylaxis is recommended for horses

Local blocks: [Epidural](#)

Position/preparation: This is an advanced procedure; the surgeon should have advanced skills and a hospital environment is best. The procedure is done at least 3-4 weeks after the injury to allow fibrous tissue formation. The patient is standing and the surgeon is gloved.

Surgery Supplies:

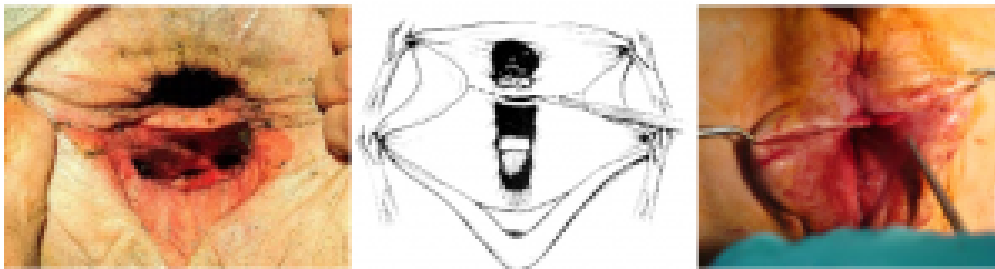
- Standard surgery pack
- Headlamp
- Retractor suture or speculum
- 3-0 absorbable suture, taper needle
- 2-0 absorbable suture, taper needle
- 2-0 suture, cutting needle (Caslicks)
- headlamp

Surgical procedure

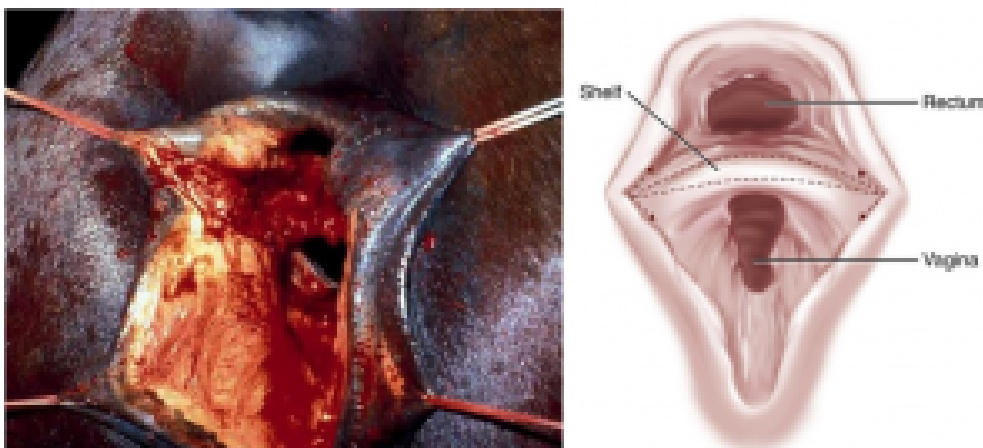
The goal of the surgery is to recreate the anal tube, the vaginal tube, the perineal body and some version of sphincter for each.

Create anal tube and vaginal tube

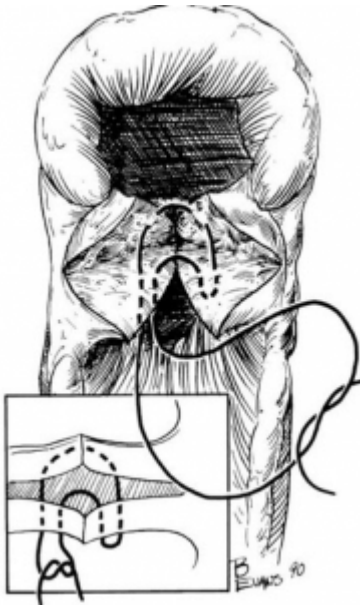
The shelf between the rectum and vagina is split horizontally, keeping the rectal side thicker than the vaginal side.



The incision is continued along both walls to the external mucocutaneous junction. The wall dissections are undermined up the wall of the rectum and down the wall of the vagina to create two shelves that easily pass the midline.

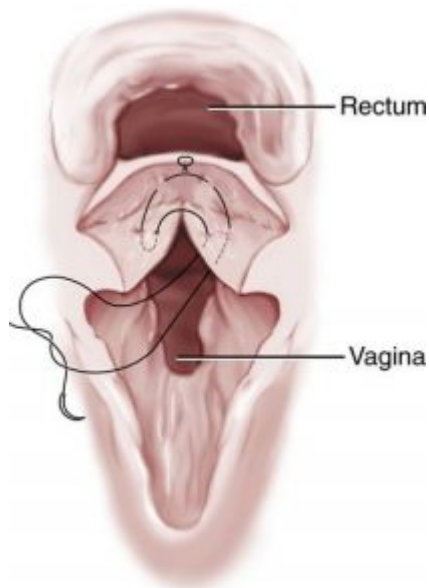


Once the shelves are created, they are apposed in three layers – the floor of the rectum, the perineal body, and the roof of the vagina. This can be done in a 6 bite technique all at once or in steps individually.



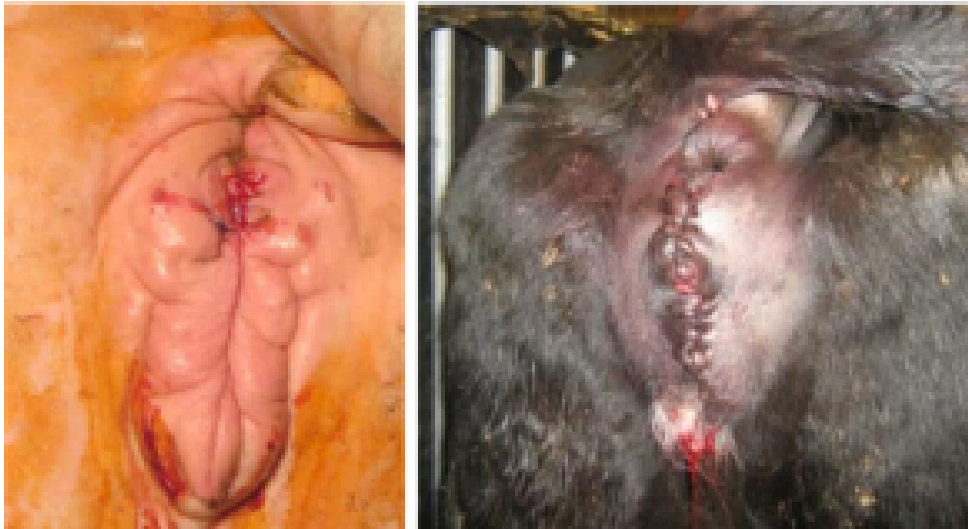Auer, Equine Surgery

For the individual layers, 2 or 3 suture lines are run in tandem. One line closes the rectal floor using a simple continuous pattern. The perineal body and vaginal roof can be closed individually or in combination. A few bites are taken with one strand of suture, then a few bites with the other. The strands are alternated until the tube reach the level of the perineal body, approximately 1-2" from the skin.



Auer, Equine Surgery

Once that level is reached, it is followed by [perineal body reconstruction](#) and a [Caslicks](#).



Postoperative care

- Soft feces are maintained until recheck. The incision lines can be checked in 7-10 days for any fistulas needing further repair.

Complications

Fistula formation is common, particularly with insufficient undermining of shelves and firmer feces.

Videos

Resources

Vulva, vestibule, vagina and cervix, [Equine Surgery](#)

Vaginal prolapses

Vaginal prolapses are not uncommon in food and fiber species, being most predominant in heavily pregnant cattle, sheep and pigs. Older animals are more commonly affected. Prolapses are occasionally seen in beef heifers and at other stages of gestation.

Besides pregnancy, other risk factors include coughing, obesity, hormonal changes (including estrogenic feeds), trauma, short tail docks and previous vaginal prolapses. Poor quality roughage and severe cold weather have been implicated. Breed predispositions occur with Herefords, Shorthorn cattle and llamas more prone to vaginal prolapses. Bos indicus breeds are more prone to a variant involving cervical prolapse.

Differentials include rectal and uterine prolapses. Uterine prolapses are covered with caruncles (“bread loaf” appearance). Animals may develop secondary prolapses (eg rectal prolapse from straining due to a vaginal prolapse).

Recurrence is common.

Therapy

The 3 R’s apply to fixing vaginal prolapses:

- Replace
- Retain
- [Prevent] recurrence

In the middle of that we try to deliver a live neonate.

Epidural anesthesia is indicated. Pudendal nerve block may help.

If prolapsed tissue isn’t damaged, osmotic agents (hypertonic saline, dextrose*) are used to reduce swelling and return it to its normal position. The bladder is sometimes involved; emptying it can help with replacement (lift prolapse toward anus). *some concern that sugar and salt granules can directly damage the mucosa.

If the tissue is damaged or the swelling just won’t go back in, we can perform surgery to remove the damaged area, using either mucosal resection/anastomosis or a complete amputation and anastomosis.

Retention can be via:

- closing the vulva lips and preventing anything from extruding
- creating scar tissue to hold the vagina in position (pexy)

- removing the vaginal tissue to minimize the amount that can prolapse

As the animals are often pregnant, it is necessary to choose a technique that will not cause delivery issues. This can vary depending upon accuracy of due dates and level of calving supervision. However, sometimes you need more than one technique initially. If you can get the prolapse back where it belongs, the swelling goes down. It may be 24 hours with a Buhner stitch before a Minchev pexy is feasible.

Standing sedation (if needed) and local anesthetic blocks are effective for these procedures. A [pudendal nerve block](#) can help with relaxing the vagina as well as providing analgesia if pexy techniques are performed (see page 22 in the linked reference).

Sheep are often treated with a [commercial retention device](#), rather than surgery.

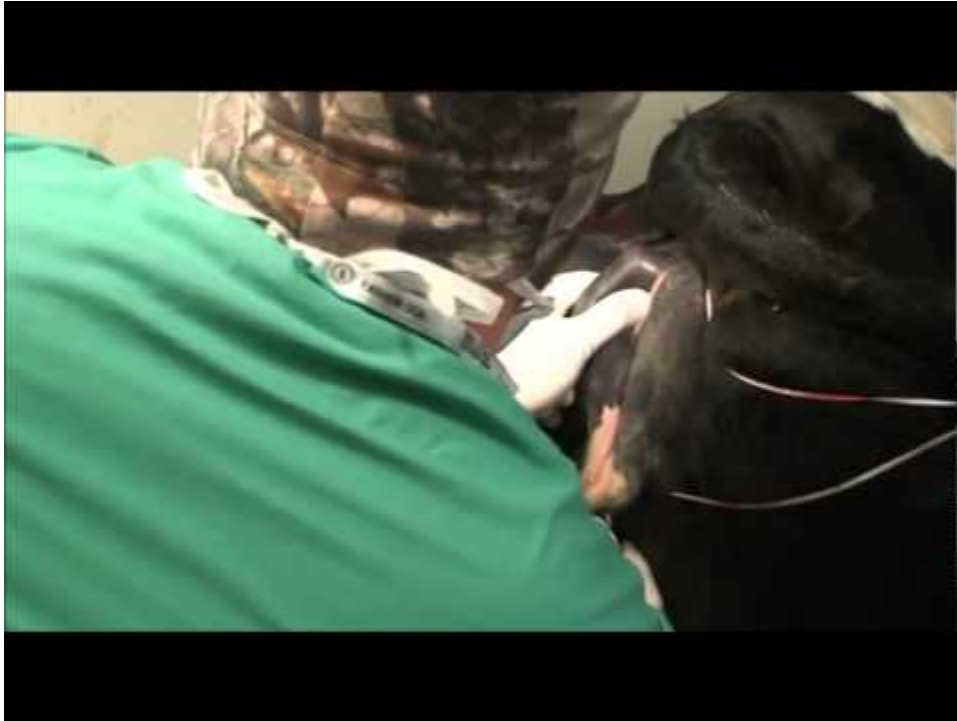Buhner stitch

The Buhner stitch is basically a pursestring around the vulva, designed to hold everything in place. It must be removed prior to parturition or delivery will result in trauma to mom and baby. A large Buhner needle is used to place umbilical tape deeply around the vulva. This is tightened until only 1-2 fingers can fit into the vulva.

Ideal : two small incisions ventrally (to keep the knot from disappearing) and one at the top (so the suture material sinks SQ)

Cattle do develop signs of impending parturition that can be used as markers (milk in the udder, relaxed tail head, etc).

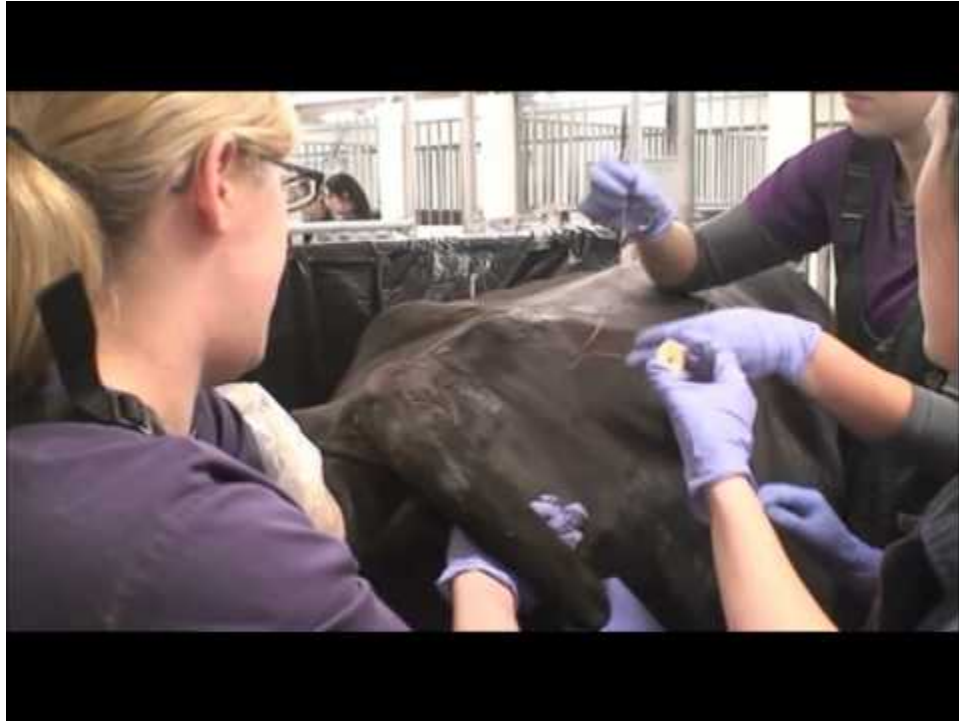Variations of the Buhner include horizontal mattress sutures (easier to put in but less physiological) and bootlace patterns (suture loops on each side of the vulva are placed for umbilical tape to be threaded through; this variant can be opened and reclosed without surgery but is not as strong).



A YouTube element has been excluded from this version of the text. You can view it online here: <https://open.lib.umn.edu/largeanimalsurgery/?p=1175>

Minchev Pexy

The Minchev procedure creates an adhesion between the vagina and the sacrosciatic ligament (in the pelvis) to prevent prolapse. This technique keeps the vagina open and does not need to be removed for delivery. It is important to avoid the rectum when performing the pexy. Typically we place two sutures to distribute forces. The sutures should be on the same side to avoid squeezing the rectum between them. “Buttons” are used to distribute pressure; without such stents the suture tends to cut through the tissue. Sutures are left in place until after calving.



A YouTube element has been excluded from this version of the text. You can view it online here: <https://open.lib.umn.edu/largeanimalsurgery/?p=1175>



A YouTube element has been excluded from this version of the text. You can view it online here: <https://open.lib.umn.edu/largeanimalsurgery/?p=1175>

Cervicopexy

Since the prolapse typically originates from the floor of the vagina just in front of the cervix, that would be an ideal location for a pexy. However, there is a large artery in the area. The ideal procedure actually involves a flank approach as well as a vaginal approach. One surgeon inserts the needle vaginally, pushing it into the abdomen. The second surgeon grabs the needle, passes it through the prepubic tendon and then back vaginally to the first surgeon.

The procedure is easier if the cow is off feed and with pneumovagina.

Primary Resources

Malone ppt on [Vaginal prolapse repair](#) options

[Cervical and vaginal prolapses](#), Merck manual

[Prolapse section](#), Veterinary Care of Sheep and Goats textbook

Secondary Resources

[Management of uterine and vaginal prolapse in the bovine](#), VCNA 2008 – pp 214-end. Note : While this article says vaginal prolapses can be either pre or postpartum, the majority are prepartum unless the cow is on hormones for superovulation. More useful for uterine prolapses

[cervicopexy notes](#) from ACVS, 2016

Bovine Prolapse surgeries



A YouTube element has been excluded from this version of the text. You can view it online here: <https://open.lib.umn.edu/largeanimalsurgery/?p=1175>



A YouTube element has been excluded from this version of the text. You can view it online here: <https://open.lib.umn.edu/largeanimalsurgery/?p=1175>

How to - Buhner stitch

Indications

A Buhner stitch is used for vaginal prolapse retention. It can be used short term until a more permanent procedure can be performed in beef cattle and embryo flush cows or can be used as the primary control method in dairy cattle with monitored calving.

Relevant anatomy

The Buhner stitch is placed deeply around the vulva, exiting the perineal body dorsally and the subcutaneous tissues ventrally.

Preoperative management

Food restrictions: NA

NSAIDs/analgesics: NSAIDs are recommended.

Antibiotics:NA

Local blocks: [Epidural or pudendal nerve block](#)

Position/preparation: The cow is restrained in a standing position. Sedation is not usually required

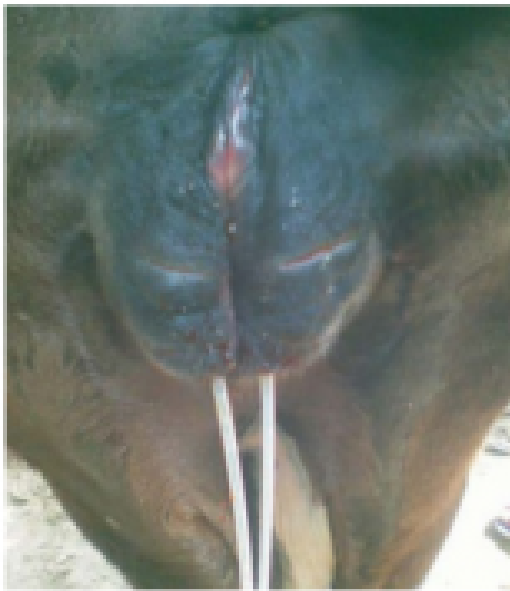Surgery Supplies:

- Buhner needle
- Scalpel blade
- Umbilical tape

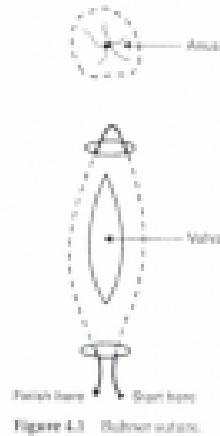
Surgical procedure

A 1cm full thickness skin incision is made just below the vulva at the 5:00 position. The Buhner needle is inserted in this incision and directed upwards. The vulvar skin is manipulated on the Buhner needle until the needle exits dorsally above the vulva and below the anus. A 1 cm skin incision can be made horizontally above the vulva to

make it easier to exit the needle. Once the needle is exteriorized, umbilical tape is threaded through the opening in the needle. The needle and tape are pulled ventrally so that one end of the tape exits the original incision. A long strand is left exiting from the dorsal incision.



DEEP path
Starts and ends *under* vulva
Minimize exposed suture



The procedure is repeated on the opposite site starting with a 1cm incision at 7:00 and exiting out the same dorsal incision. The dorsal free end of the umbilical tape is threaded through the needle and pulled down through the ventral incision.

The two strands of umbilical tape are tied in a bow, tightly enough to keep the prolapse inside the vagina but loosely enough to allow urination.

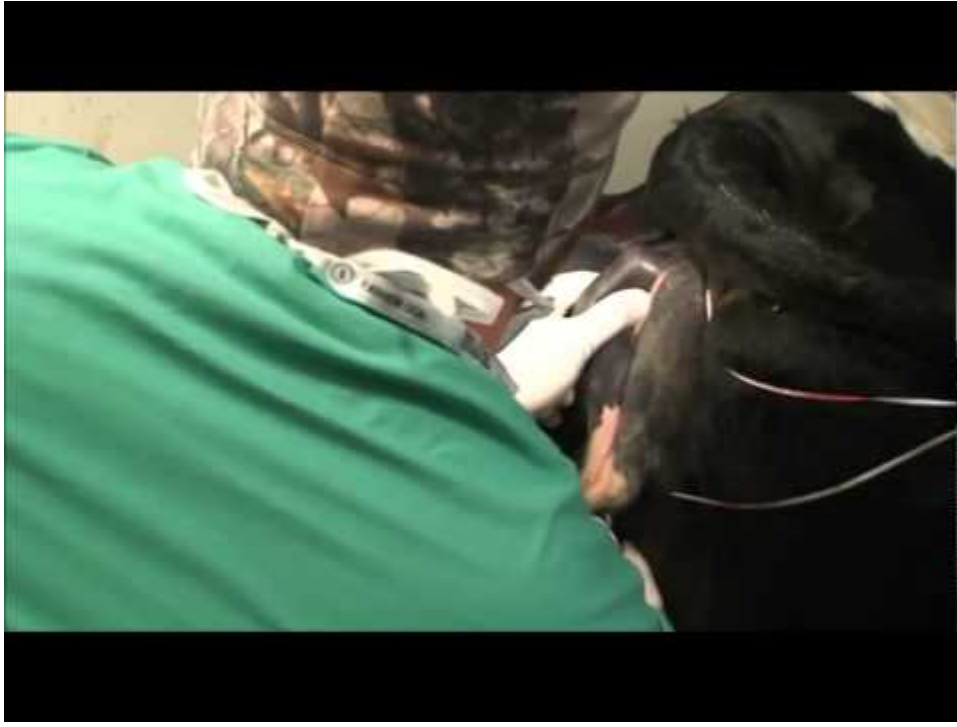Postoperative care

- The tape must be removed prior to parturition.

Complications

- Localized infection (and odor) will develop
- Trauma to dam and baby if the tape is in place during parturition

Videos



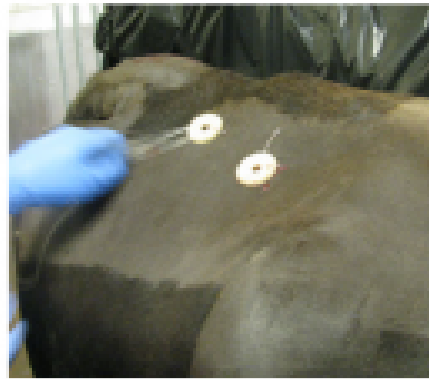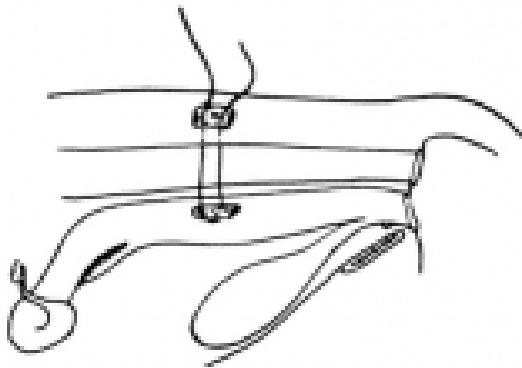
A YouTube element has been excluded from this version of the text. You can view it online here: <https://open.lib.umn.edu/largeanimalsurgery/?p=3297>

Resources

How to - Minchev pexy

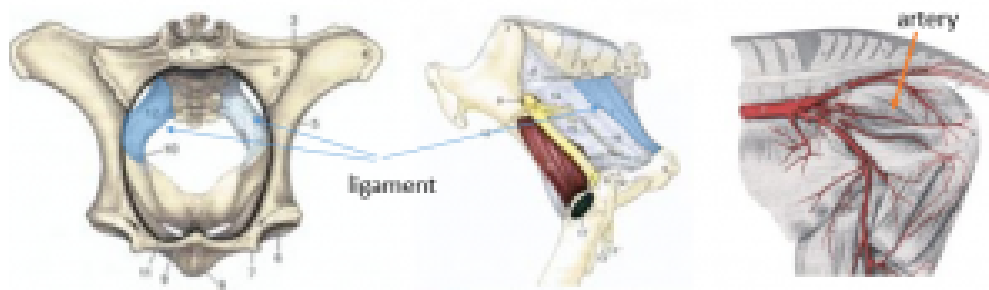
Indications

The Minchev technique is used for retention of vaginal prolapses particularly when animals will not be observed for parturition and when continued retention is likely (eg embryo flush cows).



Relevant anatomy

The suture is passed from the vaginal vault through the sacrosacral ligament. The rectum and internal iliac artery should be avoided. The artery runs horizontally across the pelvis and the pulse is palpable.



Preoperative management

Food restrictions: NA

NSAIDs/analgesics: Perioperative NSAIDs are recommended.

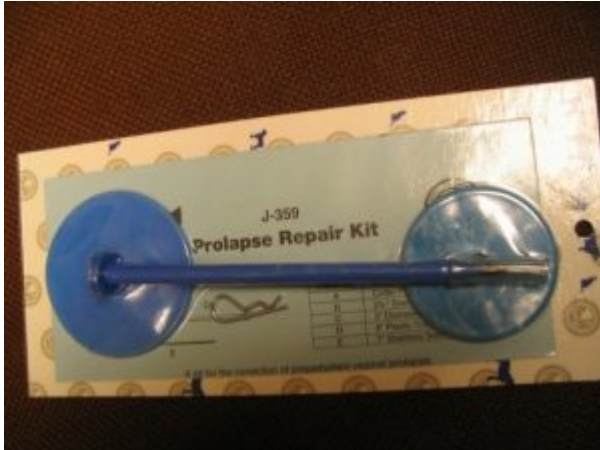Antibiotics: Preoperative antibiotics are recommended.

Local blocks: [Epidural, pudendal and/or line block](#)

Position/preparation: The patient is restrained standing. The surgeon is gloved. The vagina is cleaned as is the skin over the gluteal muscles. An assistant with a rectal sleeve can be used to move the rectum out of the line of fire.

Surgery Supplies:

- Straight needle (strong, at least 3" long), Buhner needle or Minchev kit



- Umbilical tape or large nonabsorbable suture
- Buttons, inserts from ligapak, gauze rolls or stents
- Gauze (padding for glove) or thimble- optional

Surgical procedure

The surgeon palpates vaginally to find the internal iliac artery and determine placement of two buttons. These should be placed as close to the cervix as possible. The surgeon can push on the vaginal wall and see the exit site on the outside of the cow.

The prolapse device or Buhner needle are inserted vaginally and exited out the vaginal wall at 1-2:00, avoiding the artery. Manipulation is minimal due to the size of the instruments. The prolapse device has a locking pin and buttons. It is self-retaining after the stylet is removed and the pin inserted.

Buhner needle

Once the Buhner needle is exited, umbilical tape is threaded through it and it pulled back into the vagina, bringing the tape through. The procedure is repeated to create a horizontal mattress. The tape is threaded through a stent, button or around gauze both externally and internally to prevent suture pull through.

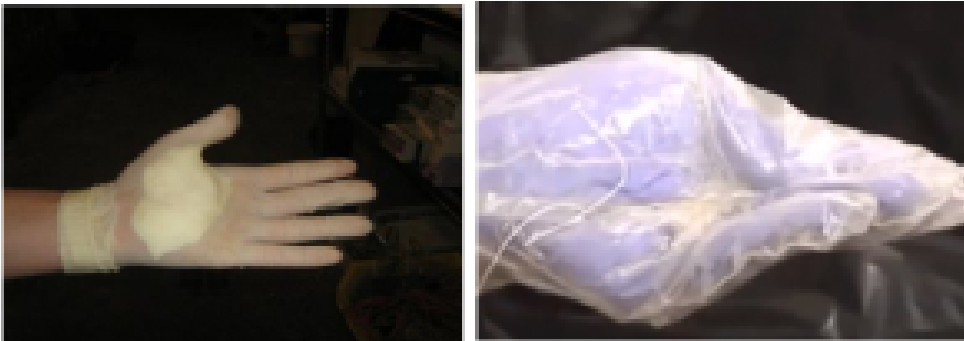A second pexy is repeated on the same side to strengthen the adhesion without constricting the rectum.

Straight needle

With the straight needle, a long piece of suture is threaded on the needle. The needle is inserted into the vaginal wall at the desired location.



Minchev exit points

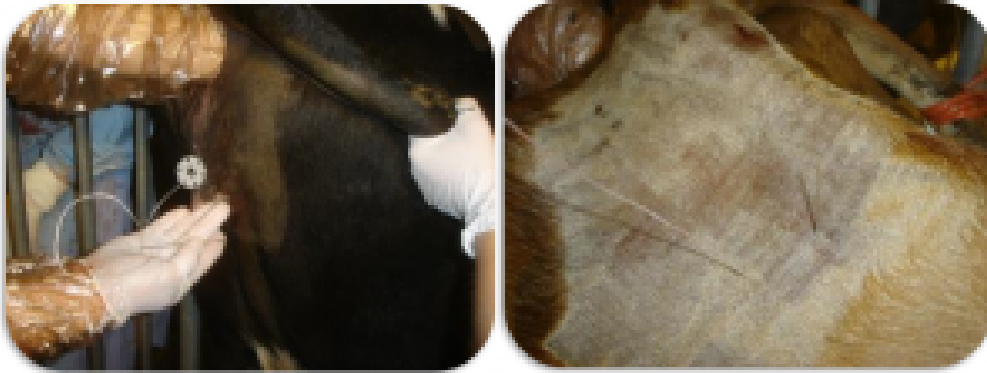

Padded glove and glove+ sterile sleeve+ lube holding needling


The surgeon pushes the needle through (a thimble inside the glove or a gauze padded palm make this less painful) and an assistant grabs it as it exits.



One strand of the suture is pulled to the outside and held. The internal strand is threaded through a button or stent and the needle replaced on that strand. The procedure is repeated close to the first puncture.



Both ends are tied over a second button externally.



A second pexy is repeated on the same side to strengthen the adhesion without constricting the rectum.

Rectal palpation should be used to verify no suture has entered the lumen.

Postoperative care

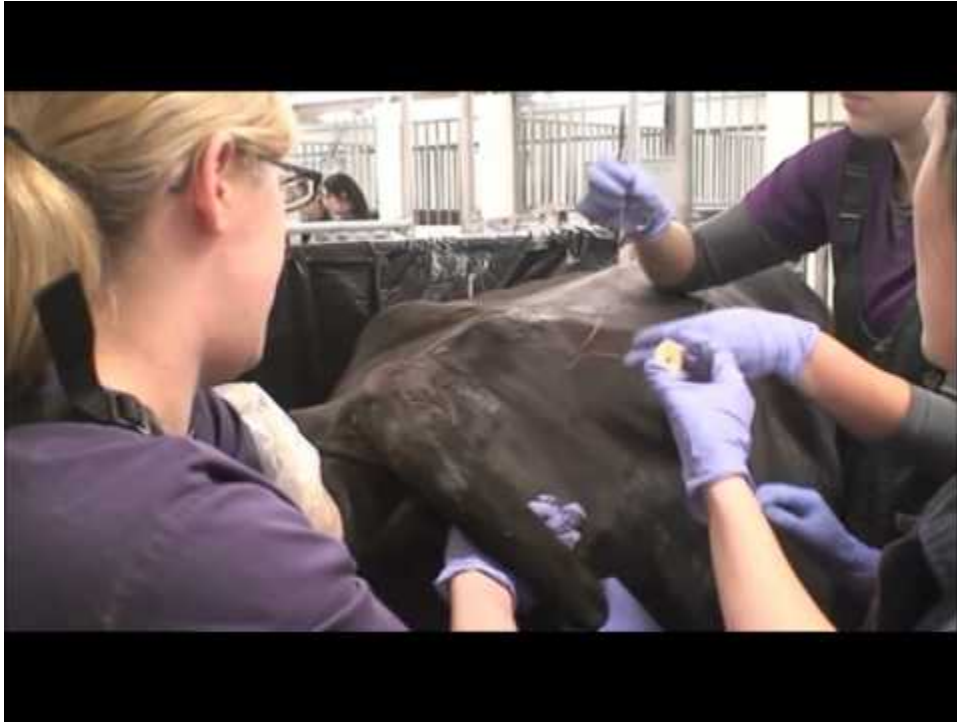- Sutures should be left in place through parturition or at least for 3 weeks if the animal is not pregnant.

Complications

Infection is common but rarely leads to an abscess. Suture that enters the lumen of the rectum should be removed.

Prolapse is still possible, particularly if the pexy isn't far enough cranial, if the sutures tear out or if just bad luck.

Videos



A YouTube element has been excluded from this version of the text. You can view it online here: <https://open.lib.umn.edu/largeanimalsurgery/?p=3300>



A YouTube element has been excluded from this version of the text. You can view it online here: <https://open.lib.umn.edu/largeanimalsurgery/?p=3300>

Resources

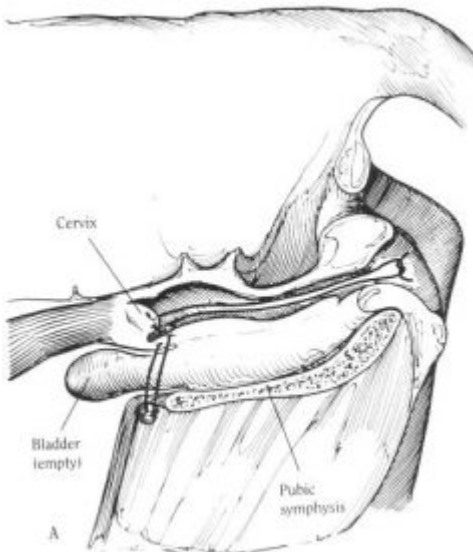
How to - Cervicopexy

Indications

Cervicopexy is indicated for valuable cattle with recurrent vaginal prolapses. It is fairly complex so is generally used for prolapses not responding to other therapies.

Relevant anatomy

The floor of the vagina is sutured to the prepubic tendon, avoiding the artery and the bladder.



Preoperative management

Food restrictions: Animals should be held off feed for at least 24 hours to decrease abdominal fill.

NSAIDs/analgesics: Perioperative NSAIDs are recommended

Antibiotics: Preoperative antibiotics are recommended.

Local blocks: [Epidural and local blocks](#)

Position/preparation: The animal is restrained in a standing position. The surgeon working vaginally is gloved. A second surgeon should be ready for abdominal surgery. Place a rigid catheter into the bladder.

Surgery Supplies:

- Standard surgery pack
- Bent needle – S needle bent into backwards C with the lower leg shorter than the upper bit
- 3 Vetafil approximately 12 feet long

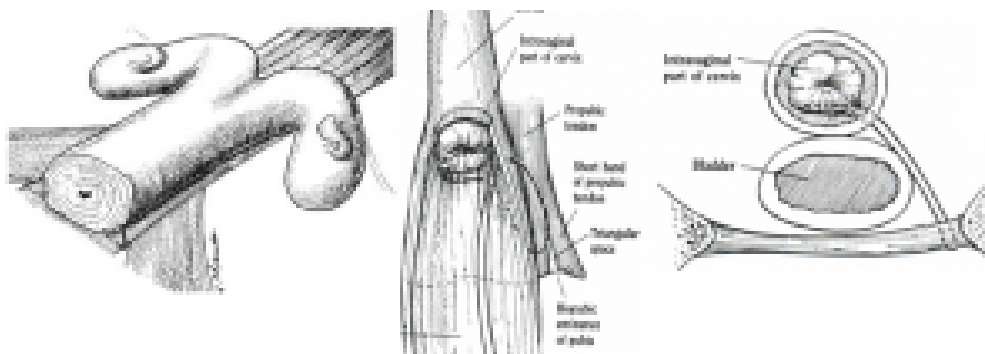
Surgical procedure

This procedure uses one surgeon in the vagina and one working through the right flank.

The surgeon in the vagina introduces the curved needle through the vaginal floor, just off midline in the fornix. The needle is pushed into the peritoneal cavity.

The surgeon in the peritoneal cavity takes the needle, passes it through the prepubic tendon and pushes it back into the vagina on the opposite of midline.

The first surgeon passes the needle through the ventral aspect of the cervix (not into the lumen) and ties the ends. The cervix is pulled down as tightly as possible.



The surgeon in the flank incision verifies nothing is caught on the abdominal side and then closes the incision.

Colpotomy version

The procedure can be performed by one surgeon if a colpotomy incision is made in the vagina to allow access to the peritoneal cavity. Risk of contamination is greater as is the risk of evisceration if the animal continues straining.

Postoperative care

- Antibiotics and NSAIDs are continued for 3 days.
- Monitor for vaginal discharge
- The suture should be considered permanent.

Complications

Contamination of the procedure may lead to persistent drainage and/or peritonitis and require suture removal.

The procedure can be challenging in obese cattle.

Videos

Resources

Ovariectomy

Ovariectomy is performed to remove abnormal ovaries, for uterus unicornus (stop ovulation on the side with the missing horn), to improve production in feedlots and to allow shipment of cattle from TB regions.

Ovariectomy can be done transvaginally through a colpotomy incision or via the flank.

Special instruments exist to assist heifer spaying. An ecraseur is effective in older animals but requires a flank incision or larger colpotomy.

How to : Colpotomy

Indications

Colpotomy is useful for access to the peritoneal cavity for ovariectomy, mummy removal and cervicopexy.

Relevant anatomy

The peritoneal cavity is entered at 2:00 or 10:00 from the vaginal fornix. This avoids the rectum (12:00), bladder (6:00) and iliac arteries (3:00 and 9:00). The upper incisions also decrease the risk of evisceration.

Preoperative management

Food restrictions: Hold patients off feed for 24 hours to minimize abdominal fill.

NSAIDs/analgesics: Perioperative NSAIDs are recommended.

Antibiotics: Perioperative antibiotics are recommended as it is a contaminated procedure.

Local blocks: [Epidural and splash block](#)

Position/preparation: The patient is restrained standing. Sedation is recommended.

Surgery Supplies:

- Colpotomy spear – scissors, ovariectomy device, ring blade or scalpel

Surgical procedure

After the vaginal is cleansed, the surgeon punctures the wall of the vagina and the peritoneum. This should be done quickly and relatively forcefully or the peritoneum will be pushed away rather than punctured. As the peritoneum is hard to block, this portion of the procedure can be painful.

The incision is made at 2:00 or 10:00, above the cervix.

The incision is left open in most cases. Closure would require laparoscopic type instruments.

Postoperative care

- Stall or pen rest for 3 days
- Horses may be restrained in a standing position to minimize the risk of evisceration.

Complications

- Peritonitis
- Intestinal evisceration
- Trauma to internal organs
- Inability to puncture the peritoneum

Videos

Resources

Teat and udder diagnostics

Common teat issues include lacerations, congenital anomalies and blunt force trauma. Many are fixable but with a poor long term prognosis. Determining which are reasonable to fix is important.

Palpation and ultrasound are key.

Palpation

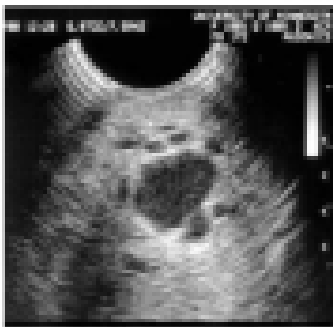Palpation of the teat can identify if it is filled with milk, identify fibrosis and signs of inflammation. A sterile teat cannula can be inserted into the teat and used to palpate the lining. The cannula should be easy to insert and the lining should be smooth. Milk should flow from the cannula in a normal lactating animal.

Ultrasound

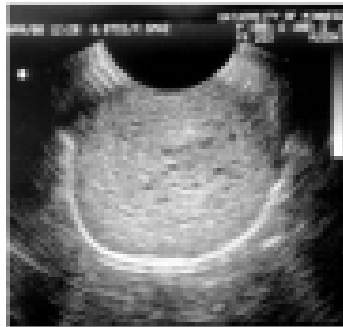Ultrasound can be used to

- 1) determine the location of the obstruction

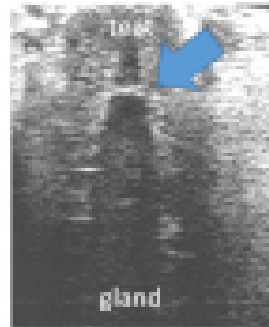
Milk can be identified in a normally functioning teat and gland. With stimulation, milk should enter the teat canal. A teat may be normal and be devoid of milk if the milk is not being produced or if milk cannot enter the teat. A common obstruction is a membrane at the junction of the teat and gland. With careful positioning, this membrane can be observed ultrasonographically in some cows.



Normal teat with milk

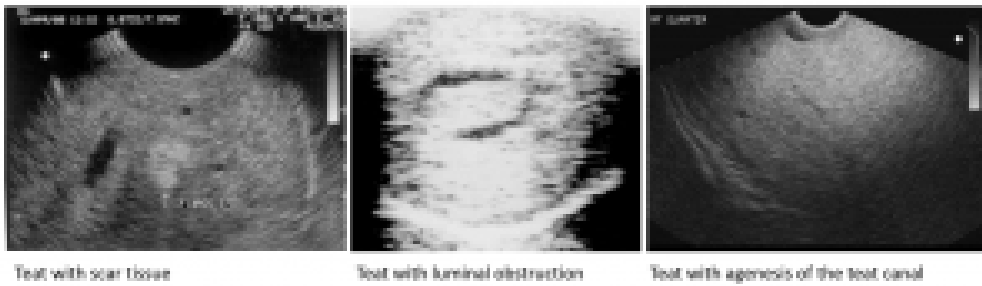


Normal teat without milk



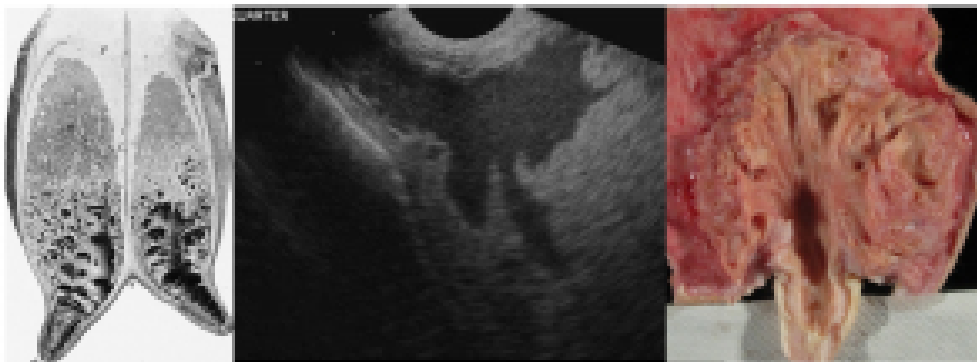Membrane between teat and gland

Ultrasound can often detect fibrosis and intraluminal obstructions. However, agenesis of the teat lumen (lack of formation) appears the same as a normal teat without milk flow.

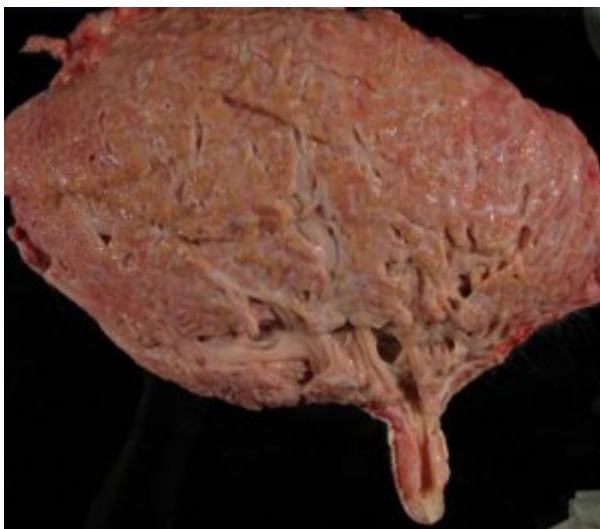

2) determine if the gland is normal and active

Two issues can arise with the gland. Congenital anomalies often come with other congenital anomalies. A malformed teat may coexist with malformed gland. And, if the teat has been obstructed for >5 days, the gland will start to dry off, even if normally structured. The quarter should be compared to the contralateral quarter to assess structure. A common abnormality is lack of gland cisterns (collection sites). This will significantly impact milk quantity.

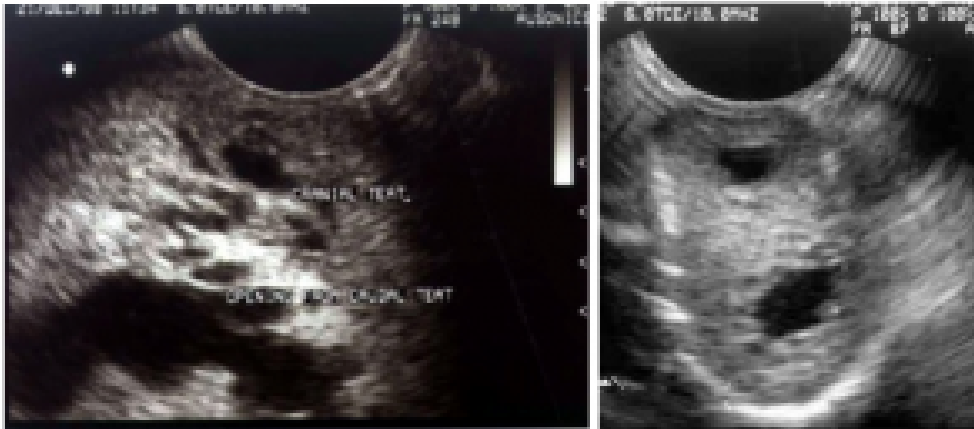


Normal gland anatomy and sonographic appearance



3) identify abnormal milk flow

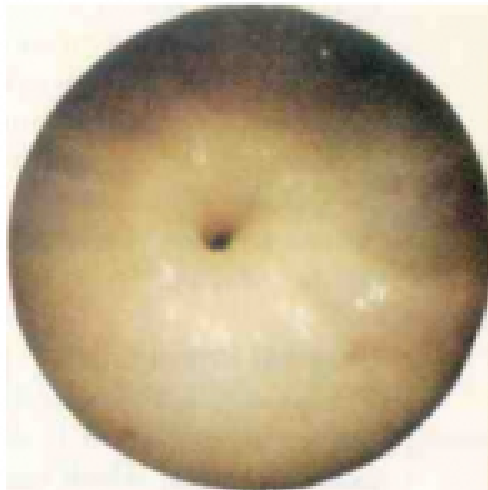Supernumerary teats come in many forms. Conjoined teats are one version. Ultrasound can show the two teat lumens.



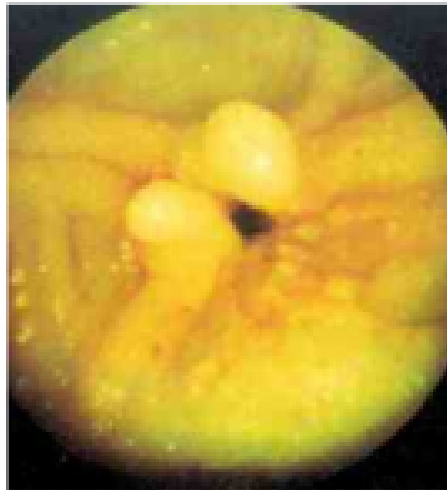Thelescopy

Evaluation of the internal structure of the teat can be performed by thelotomy (incision) or by scoping the teat with a needle scope. This is a referral procedure.

This teat has been stepped on and the teat sphincter damaged. The damaged portion has everted into the teat lumen. This causes intermittent obstruction of milk flow.



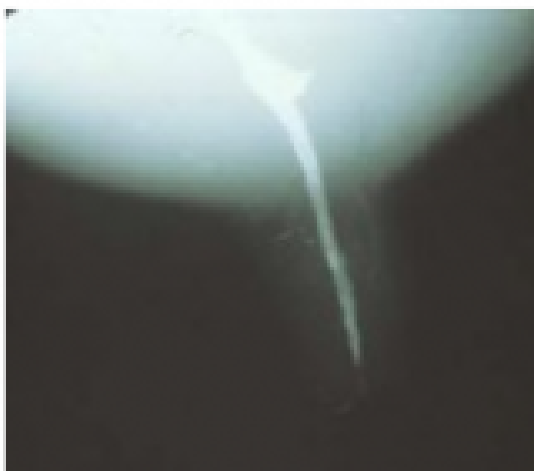Theloscopic view of normal sphincter.



View of traumatized sphincter

Contrast Radiography

Occasionally, contrast studies are used to identify anomalies and structural changes.



Narrowed gland and teat cistern.



Conjoined teat

Udder disorders and surgery

How to - Surgical Mastectomy

Indications

Relevant anatomy

Preoperative management

Food restrictions:

NSAIDs/analgesics:

Antibiotics:

Tetanus prophylaxis is recommended.

Local blocks:

Position/preparation:

Surgery Supplies:

.

Surgical procedure

Postoperative care

.

Complications

Videos

Resources

Other stuff

Occasionally a prolapsed uterus is too damaged to replace or just won't go back in. These can be amputated. Be aware that other tissues can prolapse into with the uterus- intestines or bladder may be within the prolapse prior to amputation. Per a UMN graduate – two Callicrate banders work well and are more efficient than suturing!

Practice

[Crossword puzzle](#)



An interactive or media element has been excluded from this version of the text. You can view it online here:
<https://open.lib.umn.edu/largeanimalsurgery/?p=2325>



An interactive or media element has been excluded from this version of the text. You can view it online here:
<https://open.lib.umn.edu/largeanimalsurgery/?p=2325>



An interactive or media element has been excluded from this version of the text. You can view it online here:
<https://open.lib.umn.edu/largeanimalsurgery/?p=2325>

Food/Fiber Cesarean Sections

This section will cover C-sections in cows, small ruminants and camelids. Additional resources are found in the anesthesia section.

Left flank Cesarean section

Overview

[Csections in cattle](#), ACVS

Csections can be performed from many different approaches. Left flank standing Csection is standard for large ruminants.

A left flank approach is easier than the right because the rumen functions to keep everything else inside the cow so you don't have to worry about intestines getting contaminated or traumatized, etc. An oblique incision provides more direct exposure to the uterus. This can be beneficial for smaller surgeons.

Complications

Almost all cattle will develop retained placentas. There is recent evidence that flunixin meglumine increases this risk. However, NSAIDs do a lot of good things and retained placenta is readily treated in cattle. These are not as life threatening as in horses and are left to resolve on their own.

Incisional infections may develop and are treated by removal of a distal suture to allow drainage

Prognosis is good for fertility if the uterus was healthy at the time of surgery.

PRIMARY RESOURCES

[Surgical approaches for Csection in cattle](#), 2008 CVJ- Nice review of approach options (with pictures) and general dos/don'ts. While he says monofilament suture for the uterine closure, I do like braided absorbable suture to close the uterus; the uterus doesn't tear as easily if you take decent bites.

[Field Csections](#), 2008 VCNA – Very detailed, step-by-step approach. Lots of hints so good for future reference. I would not give 2.2 mg/kg banamine BID to a fresh cow; too ulcerogenic. Either 2.2 mg/kg SID or 1.1 mg/kg BID and always iv. His PPG dose is what I recommend (22000 IU/kg) but needs to be BID. And not my first choice of antibiotics for a lactating animal due to milk withholding times. Please don't do abdominal lavage– with or without antibiotics! Cattle try to wall things off. If you spread it around, you are making it harder.

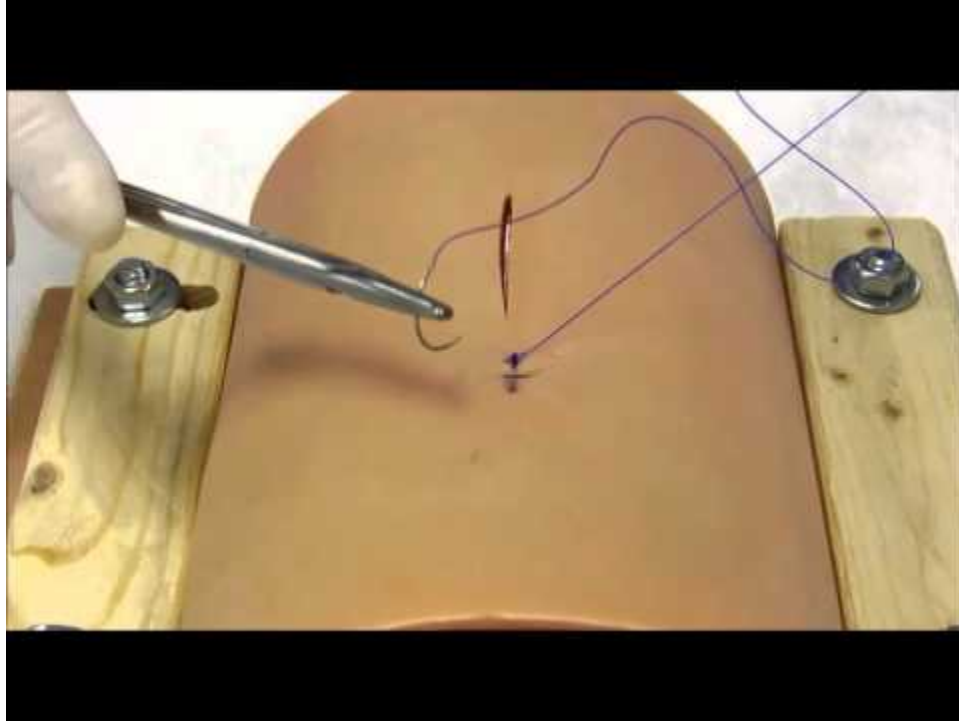
[Perioperative antibiotics](#) chapter

SECONDARY RESOURCES

Malone [Csection ppt](#) -bovine- see first slide for rope placement; more pictures

Trent [Csection notes](#)-covers a variety of species

Utrecht suture pattern



A YouTube element has been excluded from this version of the text. You can view it online here: <https://open.lib.umn.edu/largeanimalsurgery/?p=960>



A YouTube element has been excluded from this version of the text. You can view it online here: <https://open.lib.umn.edu/largeanimalsurgery/?p=960>

How to - Left Flank Csection

Indications

Cesarean section is indicated for many causes of dystocia, as a preventive measure for animals with anticipated dystocia and for gnotobiotic calves.

Relevant anatomy

The uterus can be accessed from either side. The rumen holds in the intestines on the left, making that the preferred approach. The uterus can be challenging to exteriorize via the left flank if the pregnancy is in the right horn or with uterine torsions. A ventrolateral approach is preferred for weak cows, damaged or emphysematous uteri.

The body of the calf will be in the pregnant horn, forcing limbs into the nonpregnant horn. That makes the nonpregnant horn easier to manipulate.

Preoperative management

Food restrictions: NA

NSAIDs/analgesics: Recommended preoperatively. Flunixin meglumine 1.1-2.2 mg/kg iv is standard.

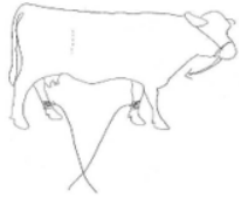
Antibiotics: Recommended if any vaginal manipulation or prolonged dystocia. In general, the cervix is open and preoperative manipulations ensure the uterine fluids are contaminated. Timing is important to ensure the drugs are at high concentrations at the time of surgery (see earlier [chapter](#)). If milking, ceftiofur 2.2 mg/kg im is standard. In beef or non-lactating cattle, other options do exist. Remember: the label dose of procaine penicillin is ineffective!

Local blocks: A [line block](#), [inverted L](#) or [paravertebral](#) are all reasonable options. A line or inverted L is required for an oblique incision as the paravertebral will not cover the ventral aspect. An [epidural](#) can help minimize straining if the cow is actively in labor.

Position/preparation: See [How to- Standing GI Surgery](#)

Position/preparation: Standing. Healthy cows tolerate standing surgery very well. Many do not need sedation but will do fine with just a local block. However, if they are heavily pregnant, (and particularly if they are Jerseys) they may just decide to lie down in the middle of the procedure. If this is a concern, we try to make it more likely that she will land incision side up.

Head toward incision; ropes
between outside legs



Place ropes on the far legs and tie her head toward the incision. If she starts to lie down, nonsurgical personnel pull on the ropes and pull her legs out from under her. With the head tied in this direction, she is also more likely to fold that way and stay incision side up.

An assistant is almost always necessary. This can be an untrained assistant that is garbed in sterile gloves (rectal sleeves are fine) and told what to touch and not touch. If the calf is alive, another person is needed for calf care and should be asked to set up an area for drying and warming the calf. This person can act as a nonsterile assistant and help with calf removal etc.

Surgery Supplies – Supplemental

- 2 absorbable suture material for uterine closure
- Calf hooks and chains
- Oxytocin
- Uterine forceps – optional
- [Sterile envelope cutter](#) – optional for incising the uterus
- Gigli wire and handles – optional


Surgery Supplies – Standard

- Standard surgery pack
- Sterile sleeves for internal palpation
- Scalpel blade and handle
- 2 or 3 absorbable suture material for muscle closure
- 3+ nonabsorbable suture material for skin closure

Surgical procedure

After the cow is clipped and prepped, a 40 cm vertical or 40-50 cm oblique incision is made starting in the caudal third of the paralumbar fossa and continued through all muscle layers and the peritoneal cavity. The flank incision

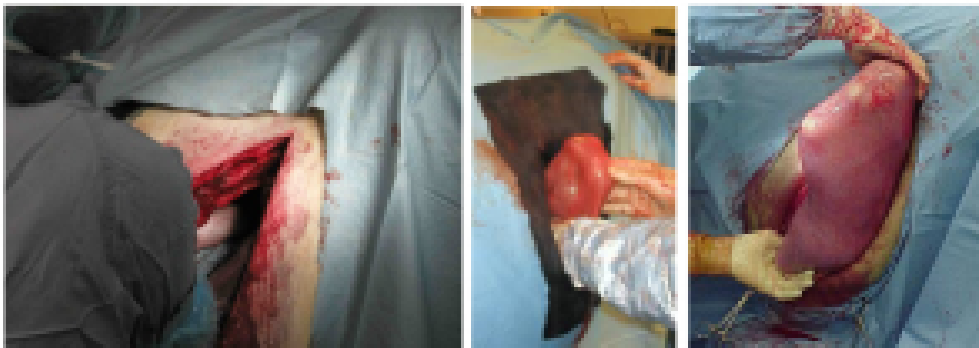should be just long enough to exteriorize the calf's hindlimb from toe to point of hock. An incision smaller than this will prevent calf removal; a larger incision much longer will make it hard to hold the calf out during the Csection.



Once the cavity is open, sterile sleeves and overgloves are placed on both arms. Instruments for closure should be separated and covered to keep them clean.

The uterus and any torsions are identified. If the calf is in typical position, a hindlimb is grasped and brought to the incision (forelimb if the calf is breech). With careful rocking and manipulation, the nonpregnant horn containing the hindlimbs is brought to the incision. The healthy uterus can tolerate a fair bit of force but whole hand manipulation should be used rather than fingers which can cause more damage. If the pregnancy is in the far (right) horn, the surgeon reaches underneath, grasps the top of the uterus and pushes it down and pulls it over to the left side, creating a 180 degree torsion.

Once the hindlimb is identified, it is grasped and brought out the incision. If the limb can be hooked out the incision, that helps prevent the calf from moving away again.



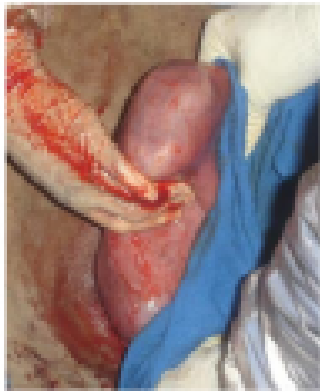At this stage it is important to ensure everyone knows the plan.

1. Someone must keep the uterus held out so that the uterine contents drain outside of the cow. The sterile assistant is generally given this job. A moist hand towel or padded uterine forceps can be used to maintain a grip on the uterus at the top and bottom. Holding in the middle means being in the way of the scalpel blade during the Csection. It is tempting to let go once the calf is out; it is important that this person stay holding the uterus. The job is hard until the calf is removed.
2. Someone will take the chains and pull the calf out. This person can be nonsterile. The calf will need to

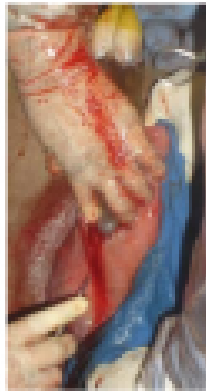
be pulled upwards first and then horizontally. A taller person can be helpful (or a stepstool). This person must follow the surgeon's direction on when to pull.

3. Someone to create the incision in the uterus; typically the surgeon. The surgeon will also manage the rest of the team, directing when to start and stop pulling.

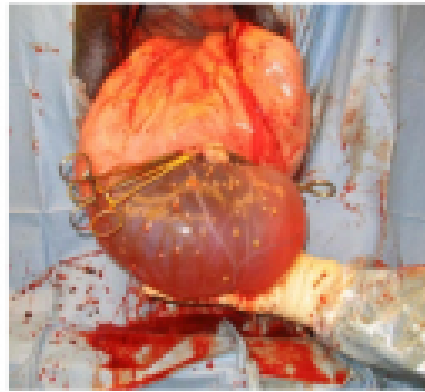
The incision is made between caruncles (to avoid bleeding) starting at the tip of the toes. The eponychium will protect the calf from damage if the scalpel goes a little too deep. Either a scalpel or envelope cutter can be used. The amnion is incised.



Grasping uterus with towel

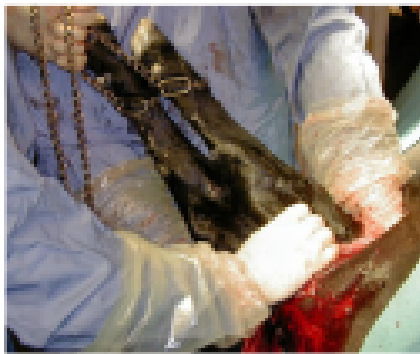
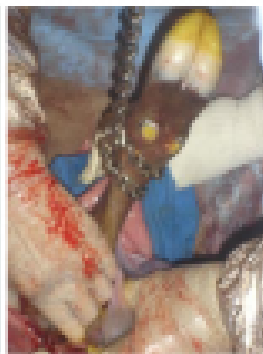
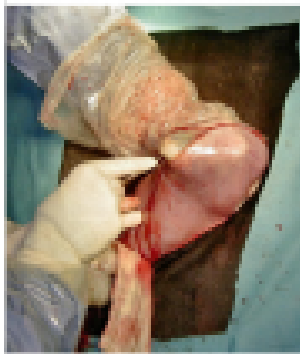Incising wall

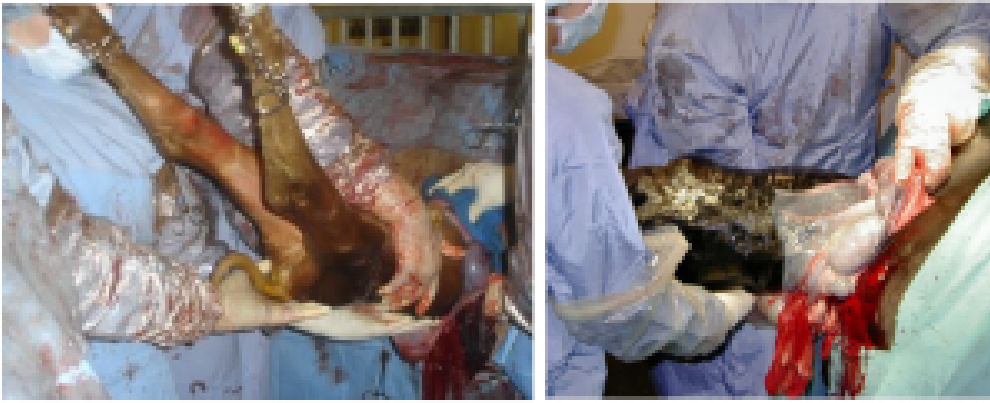

Amnion exposed

Once the foot is accessible, chains can be put on the limb to prevent the calf from moving away. A double loop is recommended to avoid too much pressure in one site. The chain is passed off to the nonsterile assistant to grab with a hook. No pulling is needed yet, just holding. The incision can then be lengthened sufficiently to find the other matching foot. Another chain (or other end of a long chain) is placed on this foot and handed off as before.

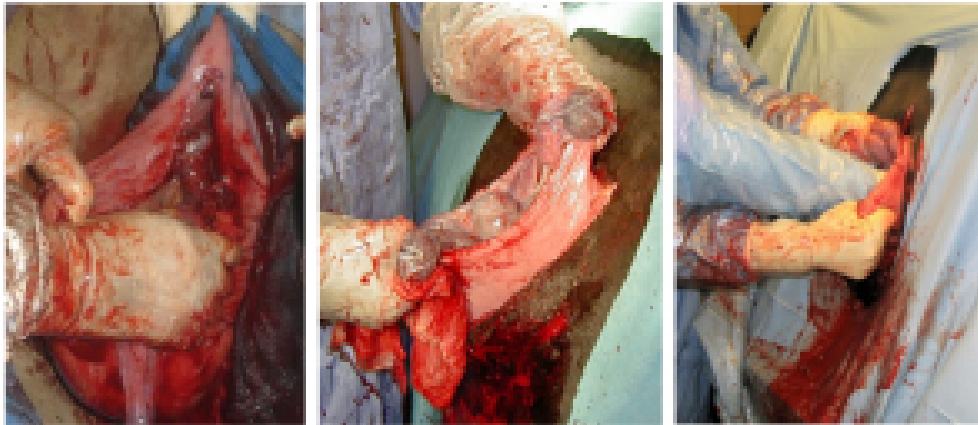


At this stage the uterus is firmly grasped by the sterile assistant and the incision in the uterus lengthened to the point of the hock. If the incision is not long enough, the uterus will tear. The surgeon can and should stop the action at any point if it is deemed a longer incision is needed. The calf is pulled out (upwards and then horizontally) as it is supported by the surgeon. The umbilicus should tear naturally. If not, the cord is held at each end and torn by pulling the ends apart. The calf can be taken to the prepared area.

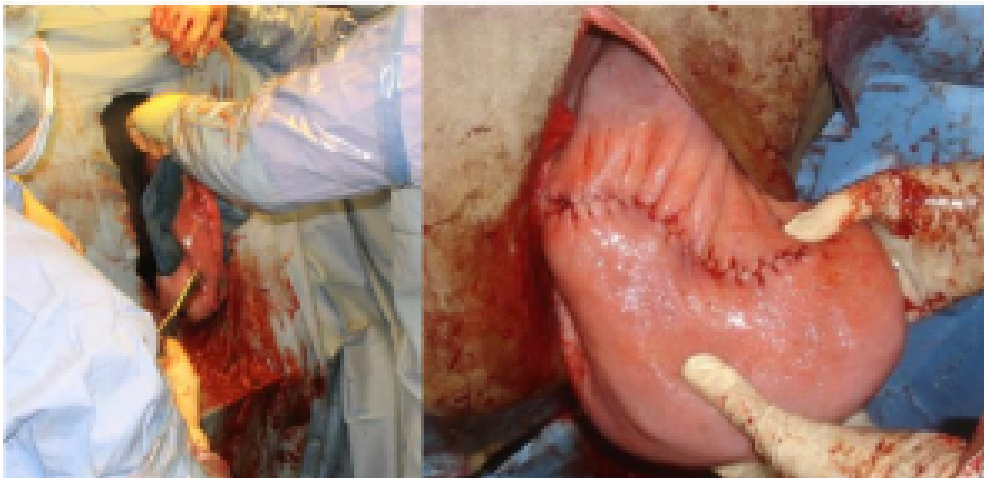

Note how the uterus is still held!

The amnion can be pulled off or pushed into the uterus. Any fluid can be dumped on the ground outside of the cow. The surgeon should check for any other calves or uterine tears.



The uterus is closed in two layers. One layer is often described in the literature but that suture line becomes loose as the uterus contracts, making a second advisable. Any inverting pattern can be used (Lembert, Utrecht, Cushing). Absorbable #2 with a swedged on needle is advised. Full thickness patterns are not recommended and appositional and everting patterns can lead to adhesions. The placenta is not usually ready to be removed so should be pushed into the uterus. Care should be taken to avoid suturing the placenta into the incision line.



Once the first layer is completed, the sterile assistant can relax. Blood clots are removed from the uterine surface and a second layer of closure performed. The cow should be given oxytocin after the first layer is closed to ensure good involution (and a tighter suture line) during the second. The uterus is returned to the abdominal cavity and checked once again to ensure normal position, no other calf and no tears.

Closure : Follow the guidelines for [standing GI surgery](#).

Postoperative care

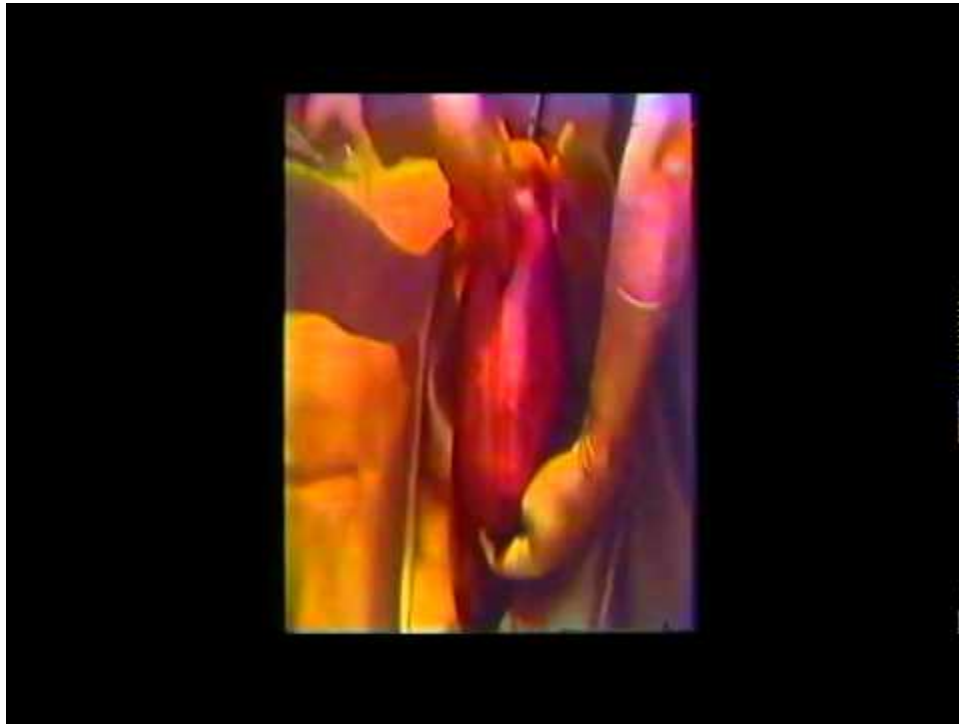- NSAIDs and antibiotics should be continued for at least three days if any risk of uterus contamination
- Oxytocin helps with uterine contraction but does not help with retained placentas.
- The placenta is tied in a knot to add traction but is left to pass on its own

Complications

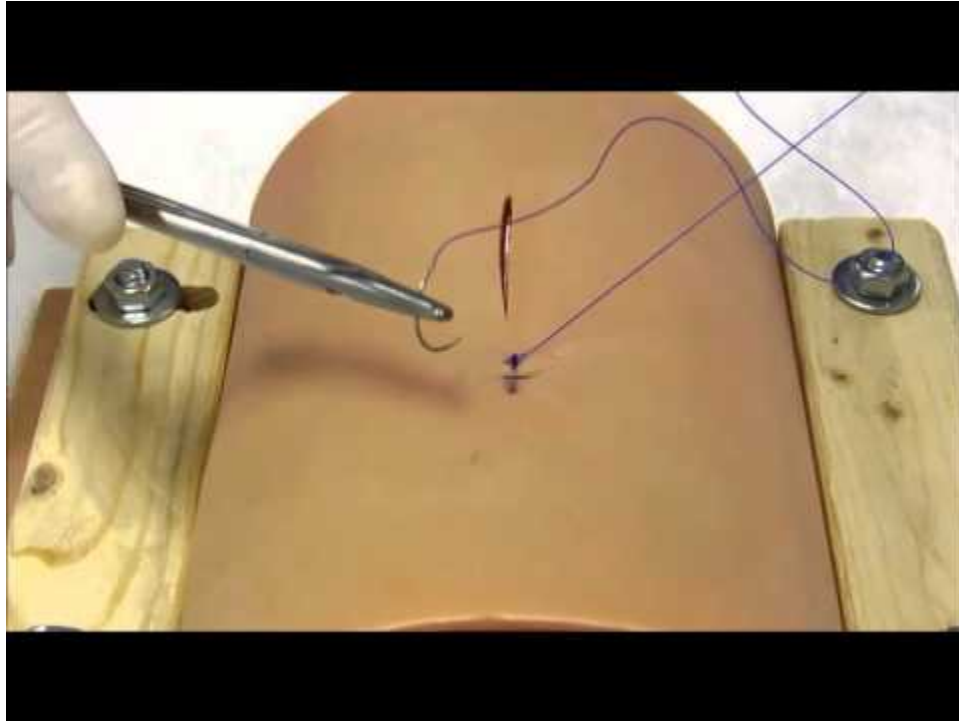
Almost all cattle will develop retained placentas. There is recent evidence that flunixin meglumine increases this risk. However, NSAIDs do a lot of good things and retained placenta is readily treated in cattle. These are not as life threatening as in horses and managed with oxytocin and time.

Incisional infections may develop and are treated by removal of a distal suture to allow drainage

Videos



A YouTube element has been excluded from this version of the text. You can view it online here: <https://open.lib.umn.edu/largeanimalsurgery/?p=3276>



A YouTube element has been excluded from this version of the text. You can view it online here: <https://open.lib.umn.edu/largeanimalsurgery/?p=3276>

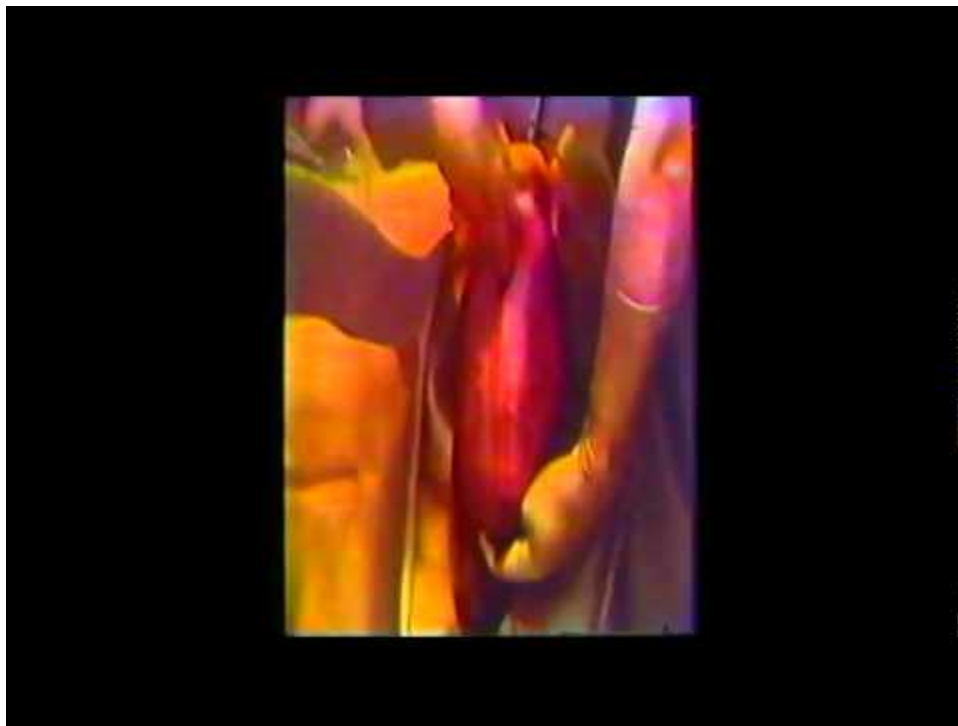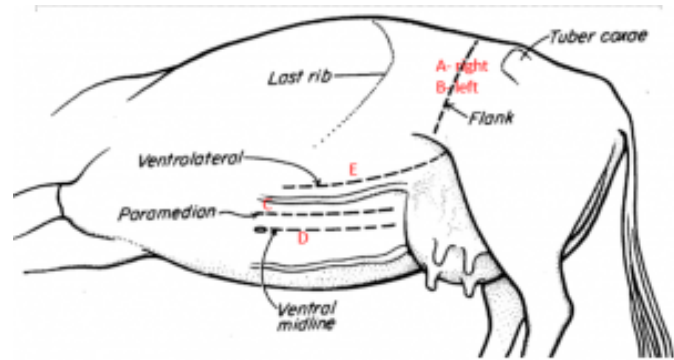
<http://mediamill.cla.umn.edu/mediamill/embedqt/154851>

Resources

Other approaches and species

Other situations

If the cow has been in dystocia for a prolonged period of time (definition of prolonged varies by parity and by environmental temperature), recumbent csection is likely and you should just plan to perform the csection with the cow down. Many times the uterus is not healthy and pulling it to a flank incision can rupture it. A paramammary (ventrolateral, marcenac) approach in the recumbent cow is most useful as the incision is directly over the uterus and manipulation is minimal. See E in the picture:



A YouTube element has been excluded from this version of the text. You can view it online here: <https://open.lib.umn.edu/largeanimalsurgery/?p=2734>

If the calf is a fetal monster, fetotomy can be performed via the Csection incision. This will make it easier to fit it through the incision.

Double muscled breeds (Belgian Blue, Charolais, etc) have higher levels of dystocia due to the larger hindquarters of the calf. Veterinarians may be asked to perform elective Csection.

Elective Csection

The best indicator of readiness is cervical dilation. However, calves within 2 weeks of their due date will usually survive. To ensure maturity of the calf, dexamethasone (20-30 mg im) should be given to the cow 24 hours prior to anticipated calving or Csection. A combination of prostaglandin and dexamethasone is often used to induce calving while improving lung maturation. Labor usually starts in 24-72 hours.

Other species

A flank incision in the recumbent animal is typically used in small ruminants. Heavy sedation is preferred over general anesthesia and intubation due to the risk to the babies. Goat babies can hide very well; extra attention needs to be taken with checking to make sure all are removed.

Camelid csections can be either flank or ventral midline, depending upon your anesthesia options and personnel availability. No need to grab a hindlimb, any body part will do.

Csections are rarely performed in production swine but can be needed in pet pigs. Flank incision, paramammary or ventral midline incisions are all potential options. Pull the uterus containing one piglet out the incision. Incise over the piglet and remove. The next pig on either side can typically be milked toward the incision. Create another incision for the next set of pigs. [See images](#)

Resources

Goplen [Csection ppt](#)– sm ruminant

[Difficult Csections](#), 2014 In Practice

Trent [Csection notes](#)-covers a variety of species

[Detailed Csection hints and techniques](#), 2008 IJVS – nice details for breech, torsions etc. Good reference

[Induction of parturition in cattle](#), 2006 www.canadianveterinarians.net/ laround

A variety of Csections:



A YouTube element has been excluded from this version of the text. You can view it online here: <https://open.lib.umn.edu/largeanimalsurgery/?p=2734>

Uterine torsions

Uterine torsions are not uncommon in cattle and are relatively common in camelids. Horses are rarely affected, with uterine torsions causing colic early in the last trimester.

Camelids are theorized to develop torsions due to the uneven distribution of weight in the uterus and their tendency to roll when in a new environment. However, everything is just a theory.

Diagnosis

Uterine torsions are identified in cattle at the time of parturition. Labor does not progress. On examination, the vagina has a noticeable twist and the cervix is usually closed.

Uterine torsions in camelids are identified anytime (or multiple times) in the last few weeks of gestation. The vagina may or may not twist.

Uterine torsions in horses are identified early in the trimester and are associated with abnormal rectal findings (and normal vaginal findings). The broad ligaments of the uterus may be palpably abnormal, with one extending over the top of the uterus and the other diving below. The rectum may be tighter than usual and may twist.

Treatment

Ideal treatment is nonsurgical and early in the process. Delayed therapy means constricted blood supply to the fetus and to the uterus. This can lead to death of the fetus or hypoxic babies. The uterus may rupture or necrose.

Detorsion rods

If the cervix is open, detorsion rods or manipulation of the fetus can be used to untwist the uterus. These methods can damage a compromised uterus.

Rolling

The dam is rolled to catch up to the baby (in the twisted uterus) while holding baby still. In camelids, the uterus is held in place with gentle hand pressure while the dam is rolled in the direction of the torsion. In larger animals, a “plank in the flank” is used to hold the uterus still. For this option, a long flat board is placed across the flank of the laterally recumbent animal. A person stands on the flank to hold the uterus in position while the dam is rolled in the direction of the torsion. This method is not advised in a compromised uterus.

Csection

If rolling doesn't work or isn't an option, Csection can be performed. Ideally the uterus would be detorsed prior to removal of the fetus; however, this can be challenging and works best early in the disorder. The uterus is rocked back and forth until enough momentum develops to carry it through the loop (like taking the swing over the top of the swing set). This works better if fluid is still present within the uterus.

If the uterus cannot be detorsed, it can be very challenging to bring the uterus outside of the flank incision (to enable the fluids to drain out). If the cervix is still closed and the calf isn't too deteriorated, this is less of a concern as the uterine fluid should be sterile. In this situation, it is generally okay if some uterine fluid is spilled while getting the calf out. Once the calf is out, it is relatively easy to hold the uterus in place for it to be sutured. After it is closed, detorsion is easy.

Resources

[Uterine torsions in the bovine, a review](#), 2008 IP- lots of good details on potential causes, diagnosis, and treatment

[A study of 55 field cases of uterine torsion in dairy cattle](#), 2008 CVJ – epidemiologic analysis of risk factors and intervention successes

[Comparative study 2 detorsion methods](#), 2016 VA- a variant of the plank method (no plan); and camelids can act like cattle (torsion palpable vaginally) or like horses (not).

[Vet student explanation](#)– lots of images and literature review

[Dystocia in camelids](#) 2012 OJAS – mostly about camels

[Uterine torsion and Csection in llamas and alpacas](#), 2009 Sm Rum Research – nice review of pathophysiology and prognosis



A YouTube element has been excluded from this version of the text. You can view it online here: <https://open.lib.umn.edu/largeanimalsurgery/?p=1022>

Pregnant anesthesia animal sedation and anesthesia

Anesthesia is tricky during pregnancy, particularly in large animals.

The first trimester is risky due to the teratogenic effects of many drugs. Anesthesia is avoided in this trimester whenever possible.

The third trimester is risky as the large fetus can impair venous return to the heart by pressure on the vena cava and diaphragm. Avoid dorsal recumbency whenever possible.

Generally elective procedures are scheduled during the second trimester or after the birth.

During Csections, avoid agents that increase tone to the uterus (for the surgeon) or compromise the cardiovascular or respiratory system of the fetus/baby. Drugs that can be reversed or have minimal depressive effects are ideal. Multimodal anesthesia helps to minimize the amount (and side effects) of each drug.

PRIMARY RESOURCES

[FA Sedation chapter](#) – xylazine increases uterine tone and is considered abortigenic for cattle in the last trimester

[FA Anesthesia chapter](#)

[Local blocks chapter](#) – for epidurals

[Drugs and the placenta](#), Open Anesthesia (human)- good resource for what drugs cross the placenta



A YouTube element has been excluded from this version of the text. You can view it online here: <https://open.lib.umn.edu/largeanimalsurgery/?p=1053>

SECONDARY RESOURCES

[the daily moos](#)

[Anesthesia for pregnancy and reproductive disorders](#), Wendt-Hornickle

[Anesthesia for reproductive disorders](#), Graham

Two methods for casting:



A YouTube element has been excluded from this version of the text. You can view it online here: <https://open.lib.umn.edu/largeanimalsurgery/?p=1053>

Exercises - Bovine standing Csection

Exercises

Make a [comparison chart](#) for the various Csection approaches

Try your hand at these questions. The video moves at warp speed but you can replay as needed!



An interactive or media element has been excluded from this version of the text. You can view it online here:
<https://open.lib.umn.edu/largeanimalsurgery/?p=1028>

Halloween reading : [Of psychopaths and presidential candidates](#)

FA male urogenital surgery

Teaser animals

Scrotal, testicular preputial and penile abnormalities

Also see [Preputial injuries](#) and [Penile injuries](#)

Teaser animals

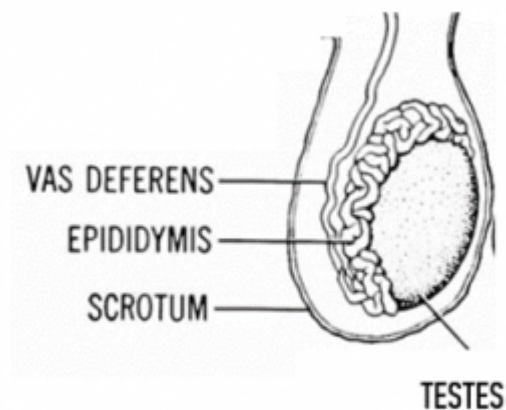
Teaser animals are useful to improve herd reproduction (see [the ram effect](#)). Having males with testosterone around improves cycling, fertility and heat detection. Teaser animals should be amenable to handling, not so large that they injure the females, and must be interested in their jobs.

In bulls, we typically recommend two procedures.

- Prevent pregnancy
 - Teaser animals are not destined to sire offspring
 - If offspring are needed, no need to create a teaser animal
- Prevent intromission
 - This is to minimize disease transmission

Pregnancy prevention

We have two main options. For both, the goal is removal of a portion of the sperm pathway. Both affect the same path, just different parts.



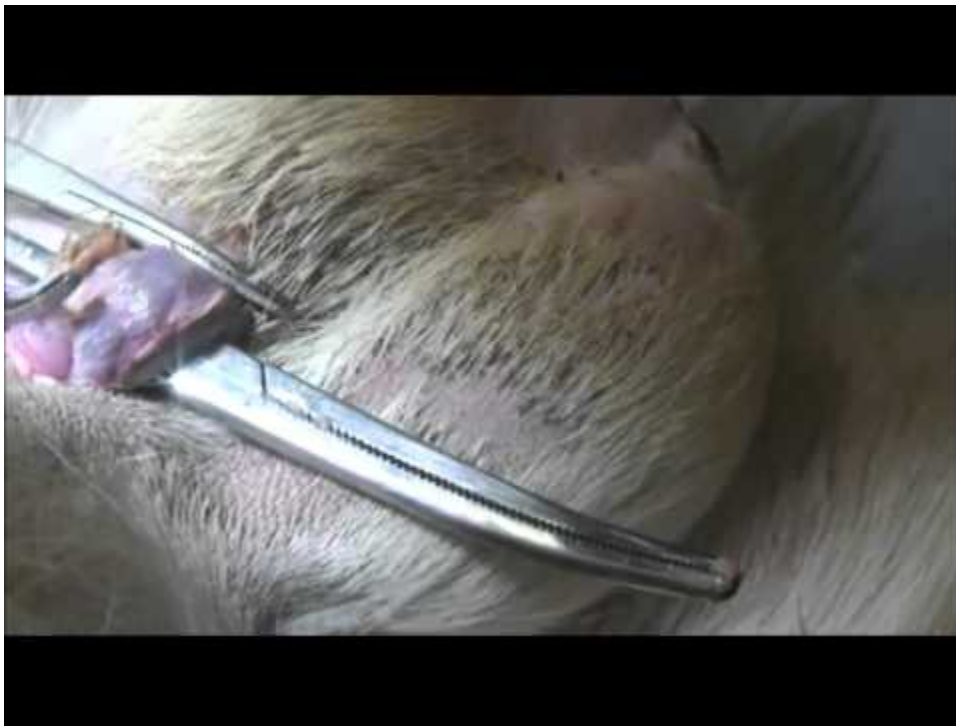- Vasectomy
 - Vasectomy can be more challenging. Depending upon the age of the animal, the vas can be very thin, hard to find and can resemble the nerve. Transecting the nerve does not prevent pregnancy. However, access to the vas deferens is easier if the procedure is performed laparoscopically (camelids) or in adult sheep (due to the restraint position of cradling them on their hindquarters). A centimeter or longer chunk of the vas deferens should be removed to minimize the risk of recanalization.
- Epididymectomy
 - Epididymectomy is typically easier once the surgeon has performed the first one. The epididymis is hard to miss. The only challenge to the surgery is figuring out where to ligate since there isn't a discrete structure. However, due to the larger tissue volume being removed, hemorrhage is more likely. If uncontrolled, hemorrhage can lead to healing complications. Most of the tail of the epididymis should be removed. Recanalization is possible but not common.

Prevent intromission

Particularly in open herds (new animals coming in), teaser animals should not actually breed the females as this can increase the risk of venereal disease transmission. In order to prevent this, several options exist with varying success rates and healing times.

- Penile translocation – aka Sidewinders
 - The preputial opening is moved to the flank of the bull. The penis is left untouched. When the bull gets an erection, the penis is extruded out his flank and he usually misses the target. Since there is no pain involved, most of these bulls maintain their libido.
 - This procedure requires general anesthesia. It is typically performed in hospitals rather than in the field.
 - Healing time is 2 months (plan ahead).
- Preputial pouch
 - The preputial opening is sutured closed and another opening created ventrally for urine flow. The penis is left untouched. As long as the urine hole is small enough, the penis cannot be extruded. Since there is no pain involved, most of these bulls maintain their libido.
 - This procedure requires general anesthesia; however, it is simpler to perform than the penile translocation.
 - Urine collects in the sheath requiring periodic flushing (higher maintenance).
 - Healing time is 2 months (plan ahead)
- Penectomy
 - The penis is shortened to prevent intromission.
 - Hemorrhage is a risk with this procedure. Careful closure of the corpus cavernosum is required.
 - Bulls do not maintain their libido due to apparent discomfort.
 - Healing time is 2 months.
- Artificial thrombus model
 - Methylmethacrylate (mixture of powder and liquid cures into a solid form) is injected into the corpus cavernosum to prevent erection due to blockage of blood flow.
 - The procedure can be performed in the standing animal and is relatively straight forward
 - If the urethra is injected instead, the resultant urinary obstruction can be fatal.
 - Healing time is 2 weeks.
- Penis tie-down
 - Adhesions are created between the penis and the internal sheath, preventing exteriorization of the penis.

- The procedure is relatively quick and straight forward
- Adhesions may break down if the bull gets an erection prior to strong scar tissue formation
- Healing time is 2 months.
- Iatrogenic preputial stenosis
 - The internal prepuce is wrapped with a K wire (Kirschner wire) to prevent exteriorization of the penis while still permitting urine flow
 - Creating the appropriate diameter is a bit of an art
 - The procedure is quick and straight forward
 - Healing time is 2 weeks



A YouTube element has been excluded from this version of the text. You can view it online here: <https://open.lib.umn.edu/largeanimalsurgery/?p=2610>

Primary Resources

[Malone ppt](#) (images and tips) teaser bulls

[Surgical techniques for the preparation of teaser bulls](#), 1995 VCNA – older but one of my favs for images and descriptions

Secondary Resources

[Teaser preparations in small ruminants](#), OSU- explains options for goats and sheep

[Development of Teaser Bulls Under Field Conditions](#), 2008 VCNA- useful images and explanations

[Preparation of teaser bulls](#) 2014 Bovine Reproduction- I have not read yet

[Occlusion of the corpus cavernosum penis in bulls intended for estrus detection: 18 cases \(2002–2016\)](#), 2019 JAVMA- latest and greatest on this technique; includes challenges and success rates

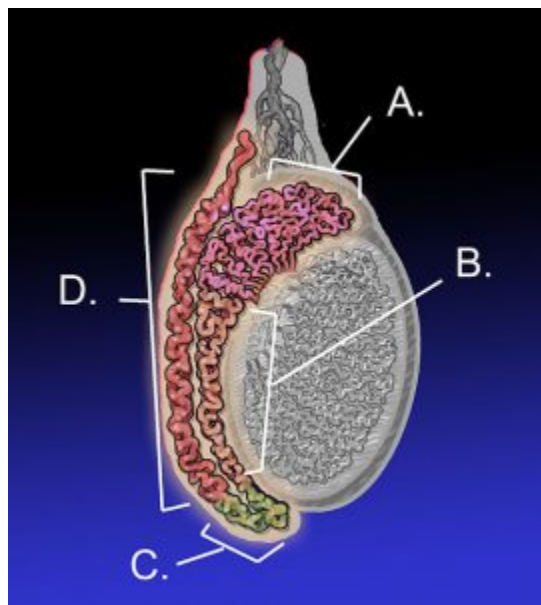
How to - Epididymectomy

Indications

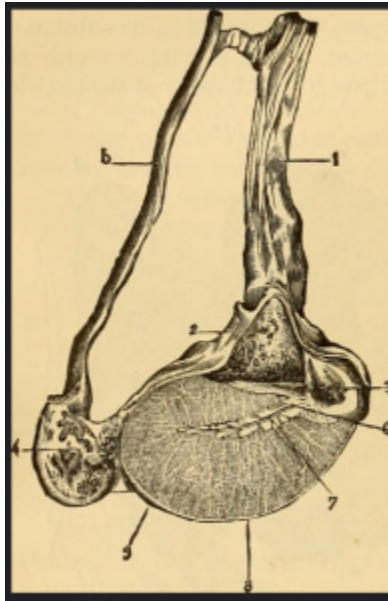
Bilateral epididymectomy is performed to create a non-fertile male that can still identify animals in heat and/or retain male secondary sex characteristics (lion mane, etc). Unilateral castration is performed for unilateral disorders of the epididymis that require removal.

Animals selected as teasers should be manageable, of a size to not cause injury during mounting behavior and have good libido.

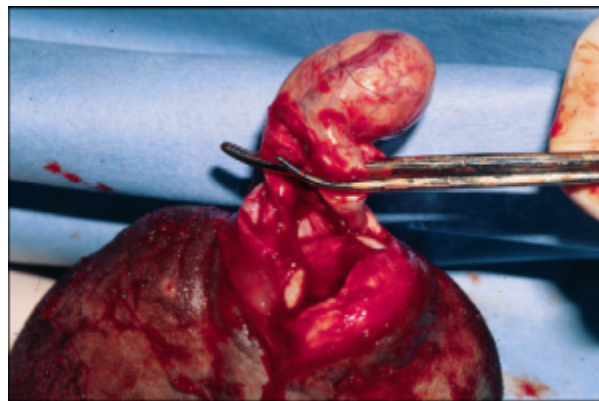
Relevant anatomy



C – tail of epididymis. D- ductus deferens



*epididymis (4) and ductus (b)
separated from testicle to show
anatomy*



Preoperative management

Food restrictions: In bulls, the procedure can be done standing in a chute with no sedation. In most other cases, the animal is only lightly sedated for the procedure and no food withholding is required. If needed for exotic ruminants or other cases, food should be withheld for 48 hours to minimize bloat.

NSAIDs/analgesics: Preoperative NSAID administration is recommended to minimize pain and inflammation. Postoperative NSAID administration is not usually required unless inflammation or pain is evident.

Antibiotics: Preoperative antibiotics are not indicated for routine cases.

Tetanus prophylaxis is recommended.

Local blocks: Lidocaine is used to block the cord and/or the surgical site. A cord block avoids distortion of the

surgical site. A ring block around the cord can help with analgesia. Injection along the proposed incision line and



into the epididymis is quick and effective but does alter the anatomy.

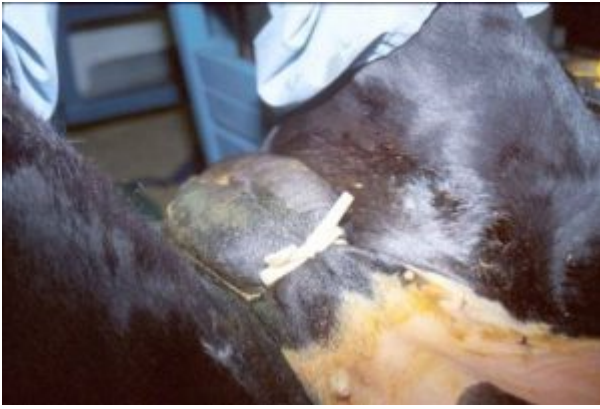Position/preparation: Bulls can be restrained a chute with a butt bar in place. Sheep are held in a sitting position. Other animals are cast or sedated until in lateral recumbency. The upper leg should be pulled forward to expose the scrotum. The scrotum is clipped (if needed) and scrubbed prior to and after the local block. Surgeons should glove. A headlamp is recommended.

Surgery Supplies:

- Scalpel blade + handle
- Allis tissue forceps or towel clamps
- Needle holders
- Suture scissors
- 3-0 to 0 absorbable suture depending upon patient size

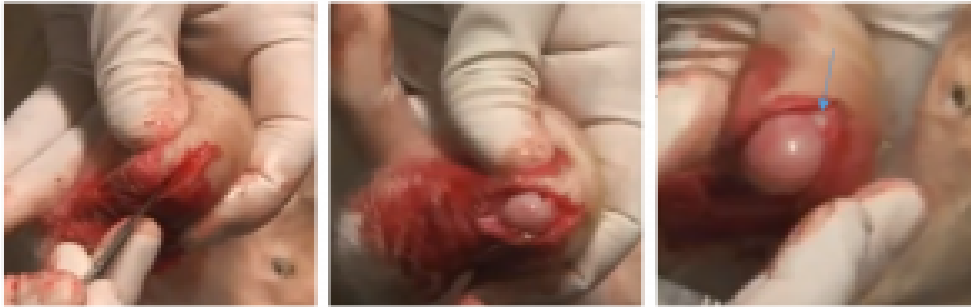Surgical procedure

A clean towel or sterile drape can be placed under the scrotum and/or over the animal's abdomen for suture management. Stabilize the testicles in the scrotum with your nondominant hand or with a penrose drain wrapped around the scrotum to hold the testicles in place. The tail of the epididymis should be clearly visible and the testicle should not be able to move in the scrotum.



This bull is also getting a penile translocation. Dorsal recumbency makes both procedures possible.

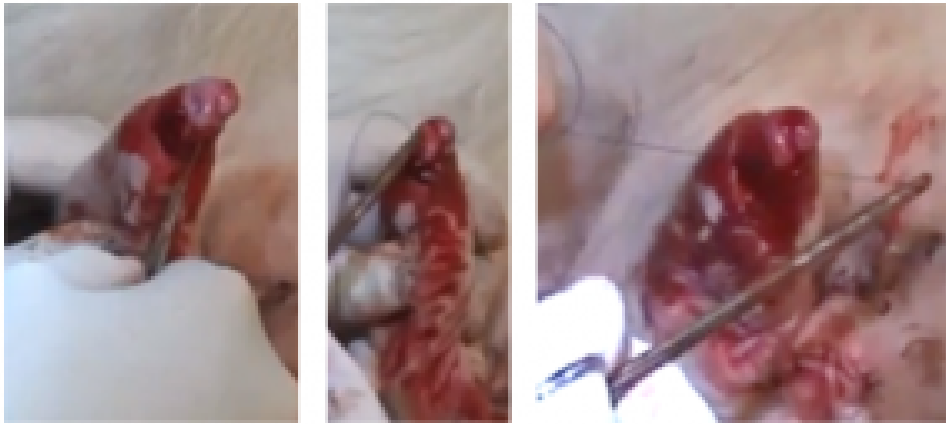Incise over the tail of the epididymis, exposing both the site at which it is connected to the testicle and the connection to the narrower ductus deferens. Dissect through the skin until you can see the epididymal bulge. Expand the incision so you can see where the epididymis ends and the testicle is visible.



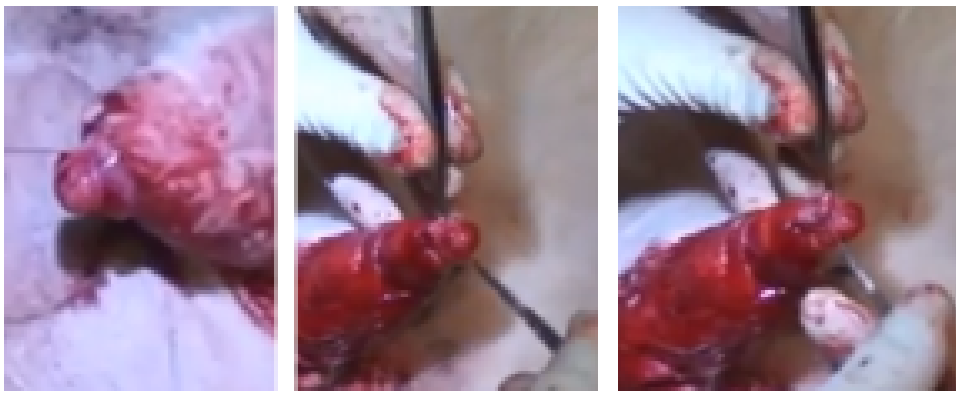Incision over epididymis. Epididymal bulge. Area of attachment to testicle (blue arrow)

Option 1. Ligate and then dissect

Continue your incision through the vaginal tunic, exposing the epididymis. One side will connect to the ductus and has a relatively narrow area to ligate. The other side connects to the testicle and is going to be harder to define where best to place your suture. It doesn't matter. The discontinuity you are creating is the important part. Find one side and ligate it. Repeat on the other side. Dissect the epididymis free from the testicle. Close either the tunic or the skin using 3-0 or smaller absorbable suture in a continuous pattern.



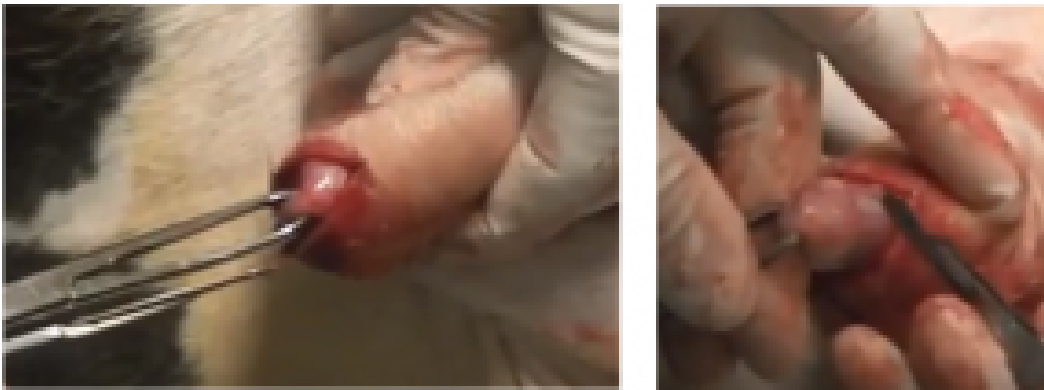Ligating the ductus side. Sliding the needle in hub first is easy and minimizes accidental trauma



Dissecting off the other side means much thicker tissue in the ligature and dissection

Option 2. Dissect and then ligate

Grasp the epididymis (still covered by the vaginal tunic) with the Allis tissue forceps. Dissect the epididymis off at the junction with the testicle. Continue until you have the epididymis only connected to the other structures by the ductus deferens. Ligate the ductus with 3-0 absorbable suture. Close the tunic in a simple continuous pattern using the 3-0 absorbable suture. Leave the skin open.



“Closed approach”. Dissecting the epididymis off of the testicle.

Postoperative care

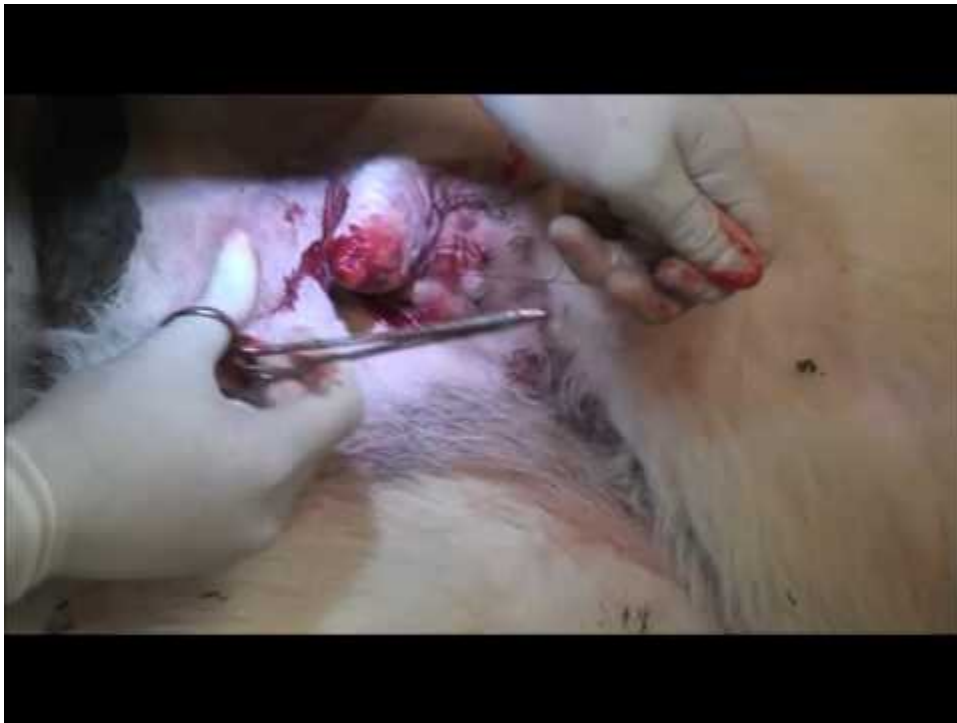- Monitor for signs of infection. Open for drainage if necessary.
- Avoid breeding or access to females for 8 weeks.
- Communicate meat withholding restrictions

Complications

There is a risk of hemorrhage and damage to the testicle; resulting testicular atrophy could alter secondary sex characteristics. There is a risk of continued fertility, primarily due to recanalization of the ductus. Sperm granulomas likely occur but have minimal impact on health of the teaser animal.

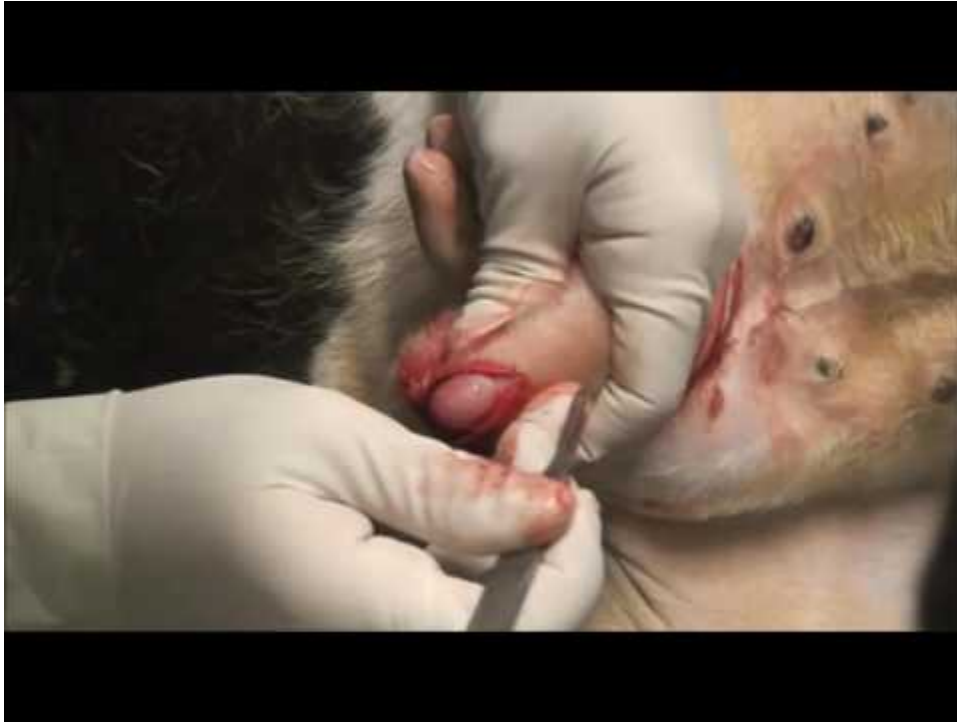Videos

Dissect first approach



A YouTube element has been excluded from this version of the text. You can view it online here: <https://open.lib.umn.edu/largeanimalsurgery/?p=2812>

Closed approach



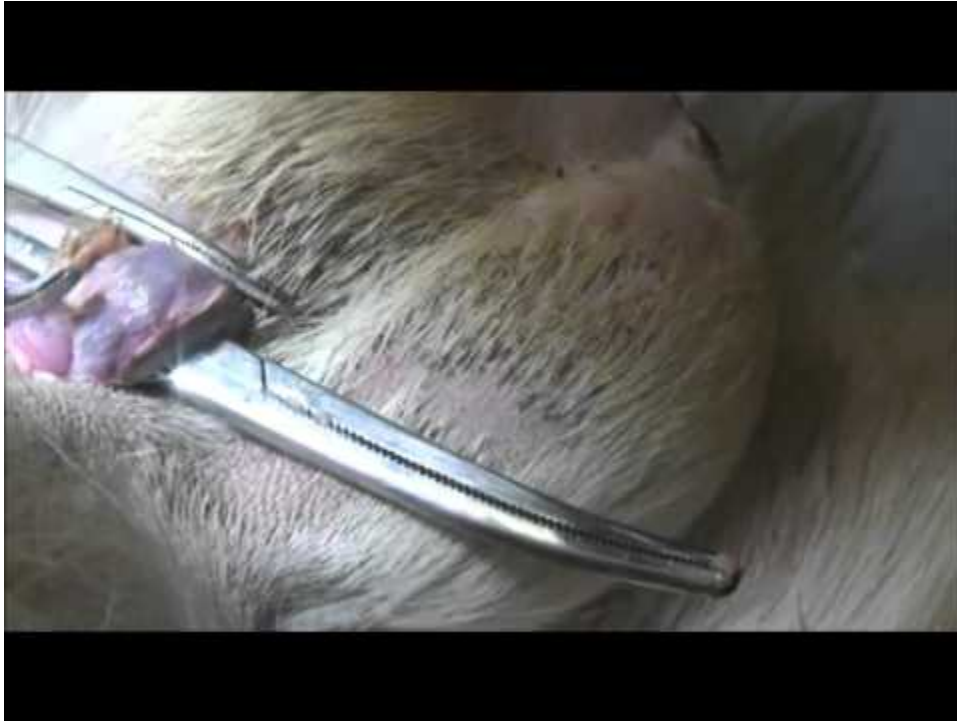A YouTube element has been excluded from this version of the text. You can view it online here: <https://open.lib.umn.edu/largeanimalsurgery/?p=2812>

Resources

[Preparation of teaser bulls](#) – Veteriankey

[Teaser preparation in small ruminants](#), Niehaus, OSU

Epididymectomy on a cadaver (starts at 5:50)- good view of anatomy



A YouTube element has been excluded from this version of the text. You can view it online here: <https://open.lib.umn.edu/largeanimalsurgery/?p=2812>

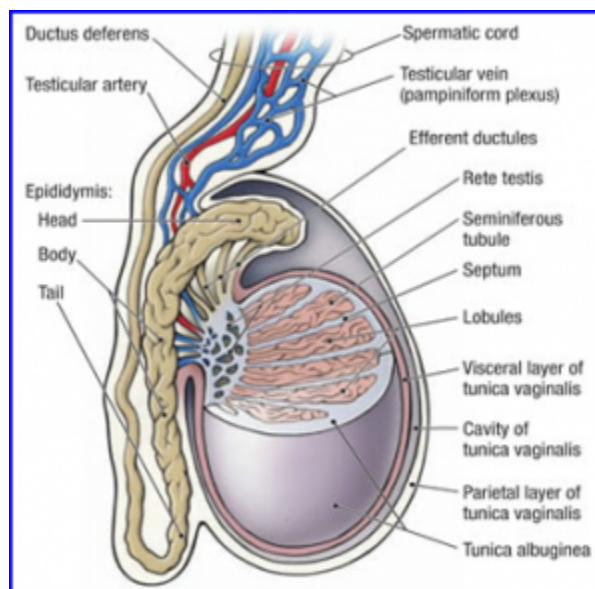
How to - Vasectomy

Indications

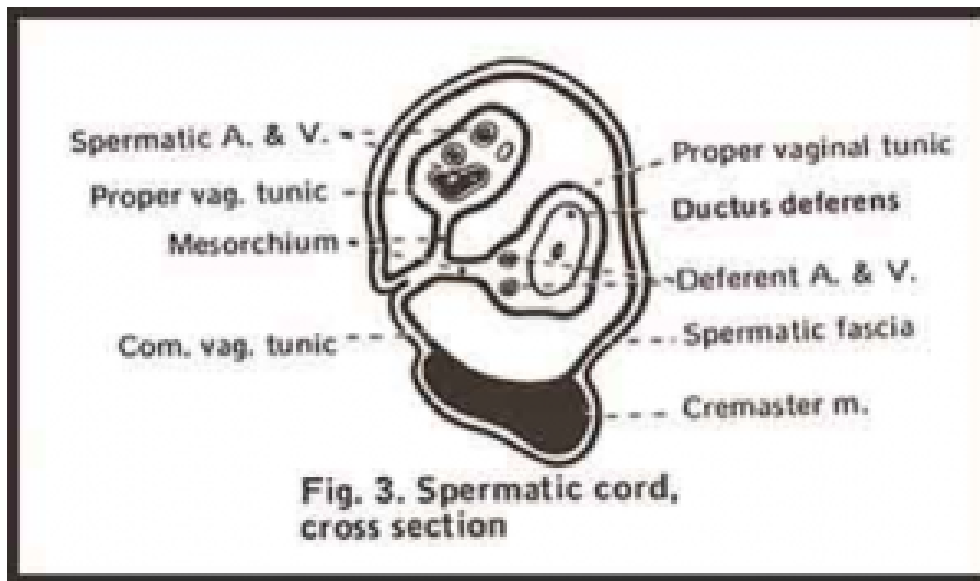
Bilateral vasectomy is performed to create a non-fertile male that can still identify animals in heat and/or retain male secondary sex characteristics (lion mane, etc).

Animals selected as teasers should be manageable, of a size to not cause injury during mounting behavior and have good libido.

Relevant anatomy



Note relationship of vessels and ductus in cord



Note how ductus deferens is in a separate tunic within the vaginal tunic

Preoperative management

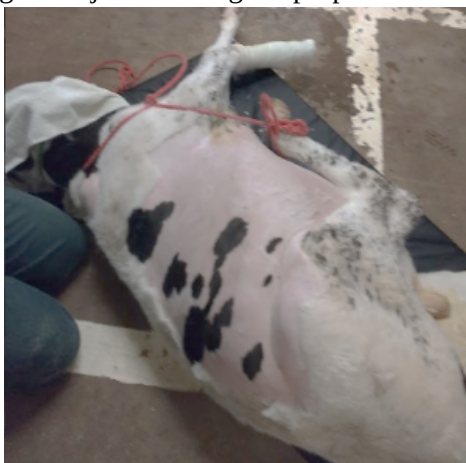Food restrictions: In bulls, the procedure can be done standing in a chute with no sedation. In most other cases, the animal is only lightly sedated for the procedure and no food withholding is required. If needed for exotic ruminants or other cases, food should be withheld for 48 hours to minimize bloat.

NSAIDs/analgesics: Preoperative NSAID administration is recommended to minimize pain and inflammation. Postoperative NSAID administration is not usually required unless inflammation or pain is evident.

Antibiotics: Preoperative antibiotics are not indicated for routine cases.

Tetanus prophylaxis is recommended.

Local blocks: Lidocaine is used to block the cord and/or the surgical site. A ring block around the cord can help with analgesia. Injection along the proposed incision line and into the cord is quick and effective but does alter the



anatomy.

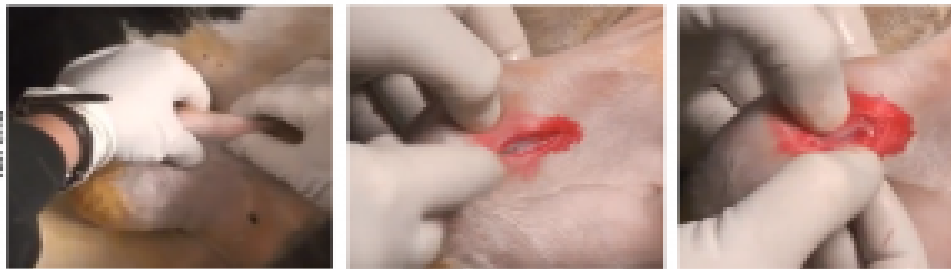Position/preparation: Bulls can be restrained a chute with a butt bar in place. Sheep are held in a sitting position. Other animals are cast or sedated until in lateral recumbency. The upper leg should be pulled forward to expose the scrotum. The scrotum is clipped (if needed) and scrubbed prior to and after the local block. Surgeons should glove. A headlamp is recommended.

Surgery Supplies:


- Scalpel blade + handle
- Allis tissue forceps or towel clamps
- Mosquito hemostat x 2-3
- Kelly hemostat, curved
- Needle holders
- Suture scissors
- 3-0 to 2-0 absorbable suture

Surgical procedure

A clean towel or sterile drape can be placed under the scrotum and/or over the animal's abdomen for suture management. Identify the spermatic cord in the neck of the scrotum. The vas deferens is located on the axial side. Make a longitudinal incision over the axial side of the cord through the skin and subcutaneous tissues. Identify the cord. The vas deferens can be palpated on the axial aspect in some cases, separate from the pampiniform plexus.

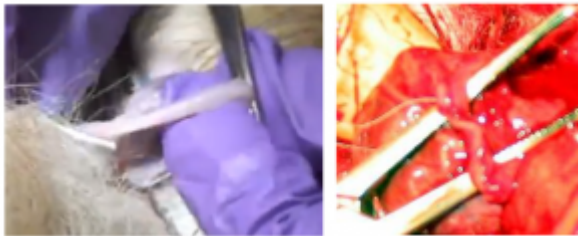

Elevate the cord onto the Kelly forceps to keep it stable. You may be able to see the white vas deferens on the side, through the wall of the tunic. Incise the tunic that covers the structures within. *This step is commonly missed. If the pampiniform plexus is not readily visible, you haven't gone through the tunic.* Once the tunic is open, find the firmer structure that is somewhat isolated. Elevate this on the mosquito hemostat. When relaxed, the vas deferens has a slightly coiled appearance to it.



elevating the cord and then separating the vas deferens

Clamp the ends of the section of vas deferens to be removed. In older animals, ligate each end to prevent sperm granuloma formation and remove at least 1 cm section. In a mature animal, the contents can be squeezed onto a slide and checked for sperm to verify it is the vas deferens. In younger animals, the section can be removed without ligation (piglets). The skin is closed routinely.



Postoperative care

- Monitor for signs of infection. Open for drainage if necessary.
- Avoid breeding or access to females for 8 weeks.
- Communicate meat withholding restrictions

Complications

There is a risk of removing the wrong structure, particularly in younger animals. Accidental damage to the pampiniform plexus could cause significant hemorrhage. There is a risk of continued fertility, primarily due to recanalization of the ductus. Sperm granulomas may occur.

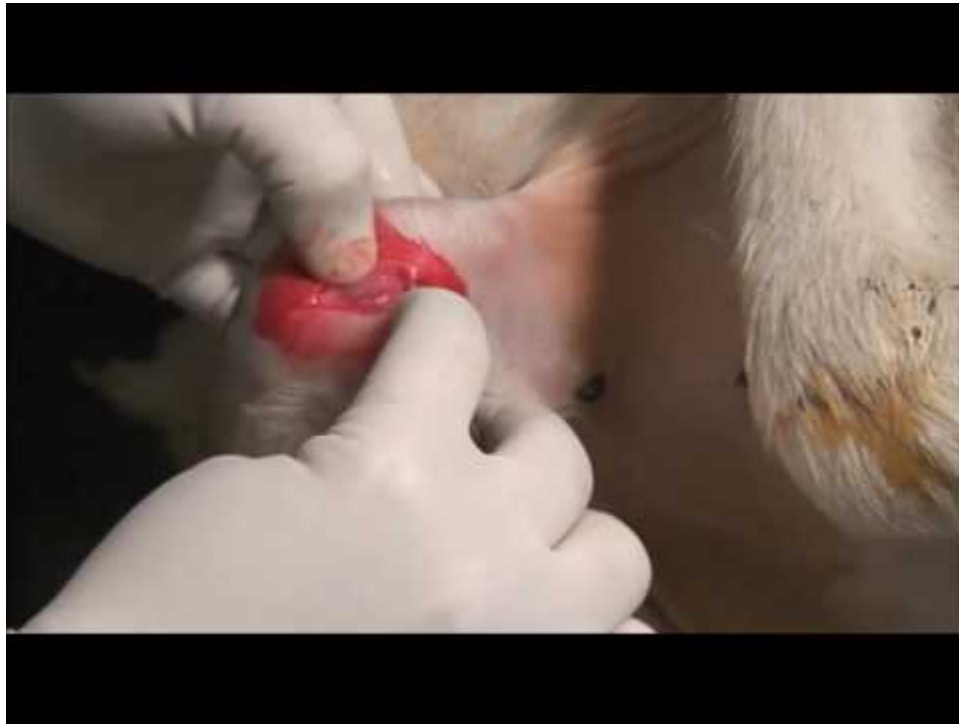Videos

Cadaver demo



A YouTube element has been excluded from this version of the text. You can view it online here: <https://open.lib.umn.edu/largeanimalsurgery/?p=2808>

Vasectomy (on a calf but doing it the piglet way)



A YouTube element has been excluded from this version of the text. You can view it online here: <https://open.lib.umn.edu/largeanimalsurgery/?p=2808>

Resources

[Preparation of teaser bulls](#) – Veteriankey

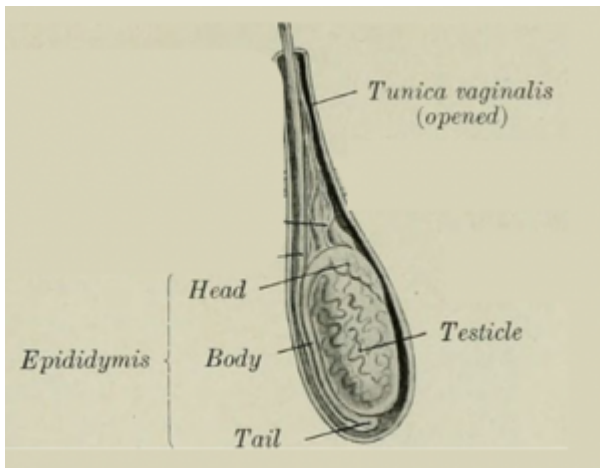
[Teaser preparation in small ruminants](#), Niehaus, OSU

How to - Unilateral castration

Indications

Unilateral castration is most commonly performed to maintain fertility in a male animal despite trauma, tumors or temperature changes in the single testicle. Inguinal hernias are treated most effectively by unilateral (if not bilateral) castration. Removing the testicle means being able to fully close the inguinal ring. Leaving space for the testicular artery means leaving space for the guts to come through, as well.

Relevant anatomy



Preoperative management

Food restrictions: In bulls, the procedure can be done standing in a chute with no sedation. In most other cases, the animal is only lightly sedated for the procedure and no food withholding is required. If needed for exotic ruminants or other cases, food should be withheld for 48 hours to minimize bloat.

NSAIDs/analgesics: Preoperative NSAID administration is recommended to minimize pain and inflammation. Postoperative NSAID administration is indicated. Excessive inflammation can lead to fibrous tissue formation and inability to thermoregulate.

Antibiotics: Antibiotics are not usually indicated unless the reason for castration involves infection. Results of culture and sensitivity can guide antibiotic selection if available. If not, the most common organism in cattle will be *Trueperella pyogenes*. Antibiotics tend not to work well in pus despite sensitivity *in vitro*. Drainage is important.

Tetanus prophylaxis is recommended.

Local blocks: Lidocaine is used to block the cord and/or the surgical site. A cord block avoids distortion of the surgical site. A ring block around the cord can help with analgesia. Injection along the proposed incision line and into the testicle is quick and effective but does alter the anatomy.

Position/preparation: Bulls can be restrained a chute with a butt bar in place. Sheep are held in a sitting position. Other animals are cast or sedated until in lateral recumbency. The upper leg should be pulled forward to expose the scrotum. The scrotum is clipped (if needed) and scrubbed prior to and after the local block. Surgeons should glove.

Surgery Supplies:

- Scalpel blade + handle
- Needle holders
- Suture scissors
- 0-1 absorbable suture depending upon patient size
- Emasculators

Surgical procedure

An incision is made vertically in the scrotum, following the length of the affected testicle along its abaxial border (minimizing trauma to the unaffected testicle). The testicle is exteriorized. The cord is ligated with 0 absorbable suture (avoid chromic gut). The testicle is emasculated distal to the ligature or another ligature placed.

The scrotum can be left open for second intention healing if infection is a concern. Betadine soaked gauze can be inserted into the space to keep the wound open until the space is closed by granulation tissue. Animal comfort is increased if the scrotum can be closed. Extra skin can be removed to minimize deadspace but will cause bleeding. The scrotal skin is closed with simple continuous, cruciates or a Ford-Interlocking pattern. Two -three interrupteds placed ventrally will make drainage easier if infection develops. Absorbable suture may be used if removal will be difficult.

Postoperative care

- Continue NSAID therapy for 3 -5 days
- Cold hydrotherapy can be used if the skin was closed and if swelling is present.
- If packing was used, pull out and trim off a small amount each day until fully removed.
- Keep the area clean and dry for 10 days postoperatively
- Minimize exercise for the first day to minimize the risk of bleeding

- Monitor for signs of infection, herniation or dehiscence.
- Evaluate semen quality in 60 days (allow recovery).
- Communicate meat withholding restrictions

Complications

Inflammation can cause scarring. Scarring can lead to inability to thermoregulate and subsequent infertility.

Videos

Resources

[Surgery of the scrotum](#), Vet Clin Food Anim 24 (2008) 253–266

Preputial issues

Pot bellied pigs can develop penile prolapse.

Treat with phallopey

L Reig et al. [Surgical treatment of chronic penile prolapse in Vietnamese pot-bellied pigs: 5 cases \(2016–2017\)](#). 2019 Vet Surg 48:890-896.

Practice



An interactive or media element has been excluded from this version of the text. You can view it online here:
<https://open.lib.umn.edu/largeanimalsurgery/?p=2622>

Urogenital wounds

Wounds in large animal species follow the same healing process as wounds in small animal species. However, wounds in cattle and other ruminants tend to be contaminated and chronic. They also tend to heal fast, sometimes too fast.

This section will deal with wounds in areas that tend to be somewhat unique.

Teat trauma

Teats wounds are managed similarly to wounds in other species with the exception of milk flow.

As with other wounds, it is important to determine the level of healing potential.

- Is the wound acute or chronic?
- Is the wound clean or contaminated?
- Was the type of trauma blunt or sharp?
- How deep does the wound go? Any other structures involved?
- Does the wound have good blood supply?
- Is any skin missing?
- Are there any other factors that can interfere with healing?
- Has the wound been treated already? If so, with what? Response?
- Is the cost of treatment reasonable for the client?

Due to the generally good supply, superficial wounds heal well even with skin loss. Full thickness wounds in nonlactating animals are a risk primarily due to the need for sedation and recumbency in pregnant animals. Avoid dorsal recumbency and avoid xylazine sedation in the third trimester.

For lactating animals, wounds that extend into the teat lumen or that damage the sphincter require special consideration. Adulteration of the milk with antibiotics and antiseptics must be avoided.

Full thickness wounds

Wounds into the teat lumen significantly increase the risk of mastitis from environmental contaminants. Lactating animals will also be losing milk as long as the wound remains open. This can be a significant financial loss.

It is also important to consider the process of milking during the healing process. Machine milking is a vacuum process and is much less traumatic than hand milking. Machine milking can start as soon as fibrin seal forms across the suture line (approximately 6 hours in a healthy animal).

Milk flow and milking will tend to keep the wound open. Fistula formation is more likely. With fistulas, the laceration heals but leaves an opening that permits milk to leak out the wound. This fistula also continues to increase the risk of bacterial contamination and mastitis.

Sphincter wounds

At this time, we do not have any way to recreate the teat sphincter. The sphincter can be damaged by lacerations or blunt trauma. Cows with a laceration involving the sphincter should be treated by teat or udder amputation or culling. Cows with blunt trauma to the teat end (eg from a foot) may rupture the sphincter. Parts will prolapse into the teat and interfere with milk flow due to a ball-valve type action.

Milk safety

The milking process helps ensure the teats stay clean and protected. Teat bandaging is difficult and unnecessary. However, it is important to avoid topical agents that are prohibited in milk. Salves may help keep the wound moist and healthy but need to be food safe, as well.

Teat laceration repair

Teat wounds are managed similarly to other wounds. The wound should be gently cleaned and debrided if needed. Sharp debridement is preferred but minimize the amount of tissue removed to avoid constricting milk flow.

Full thickness teat wounds should be closed in 3 layers to minimize fistula formation. The smallest diameter suture material reasonable should be used; 3-0 is typical. Monocryl should not be used as it dissolves rapidly in normal milk. Dexon dissolves rapidly in mastitic milk. Teat tissue heals rapidly; a short duration suture material could be used. However, monofilaments are less traumatic in the delicate mucosa. The final layer can be closed in a subcuticular (intradermal) pattern, standard skin appositional pattern or with wound glue.

Typical teat laceration repair

Mucosa closure – 3-0 absorbable suture in a simple continuous pattern

options include polydioxanone, polyglactin 910

Submucosa closure – 3-0 absorbable suture in a simple continuous pattern

options include polydioxanone, polyglactin 910 and poliglecaprone 25

Skin closure – 3-0 absorbable or nonabsorbable suture in a subcuticular or appositional pattern

Teats should not be milked until a fibrin seal forms, typically in 6 hours. After that, frequent milking is useful to minimize swelling. Avoid hand stripping and hand milking for at least 24 hours.

Resources

[Local blocks of the teat](#), slide #47

Cases

[Repair of teat laceration in a cow](#), case report

[Traumatic teat laceration in a Jersey cow](#), case report

[Teat fistula in a Jamunapari goat](#), case report

Preputial wounds

Preputial wounds are relatively common in breeding bulls. Due to their location, these wounds do have more associated complications, particularly swelling, infection and adhesions.

Most preputial wounds should be treated by second intention healing or delayed primary closure due to contamination. The exception is preputial avulsions. These wounds are 360° avulsions of the prepuce from the free portion of the penis at the preputial ring. Generally these are seen in bulls being collected for AI. These wounds heal poorly if left unsutured; however, since the bull was generally cleaned prior to collection, the area is only minimally contaminated and the wounds can be closed primarily.

With second intention or delayed closure, the wound must be managed to minimize swelling, contamination and adhesions.

Contamination

It is very difficult to clean the sheath to minimize contamination. Wound identification may also be delayed, letting bacteria adhere and form a protective glycocalyx. Assume the wound needs sharp debridement. Soaking in an antiseptic solution may also help remove surface bacteria.

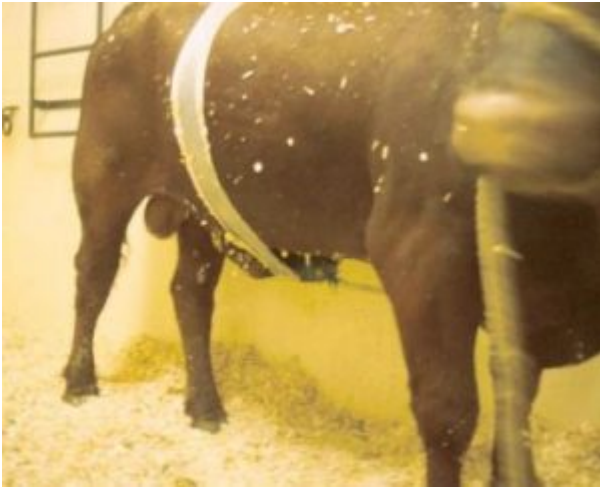

Swelling

Trauma leads to swelling and this is particularly significant in ventral tissues. If the prepuce can be returned to the sheath, the swelling is minimized. A purse string may be necessary to retain the tissues in the sheath.

However, if the prepuce is not reducible, the area needs to be elevated as much as possible. The prepuce can be slung or held next to the ventral abdomen with old sheets or with sticky tape applied over a soft wrap.

Swelling and bandaging can lead to urethral obstruction; a penrose drain or silicon tube can be used to wick urine out of the sheath.



Adhesions

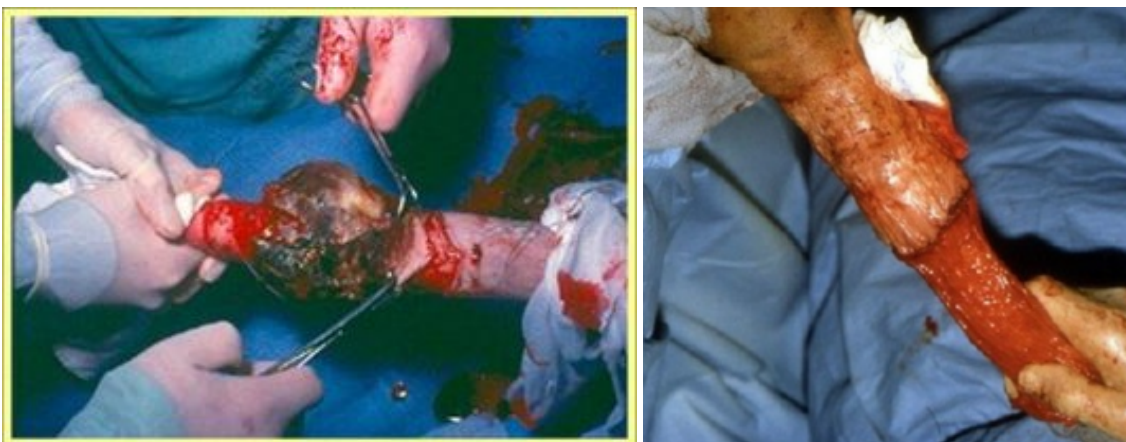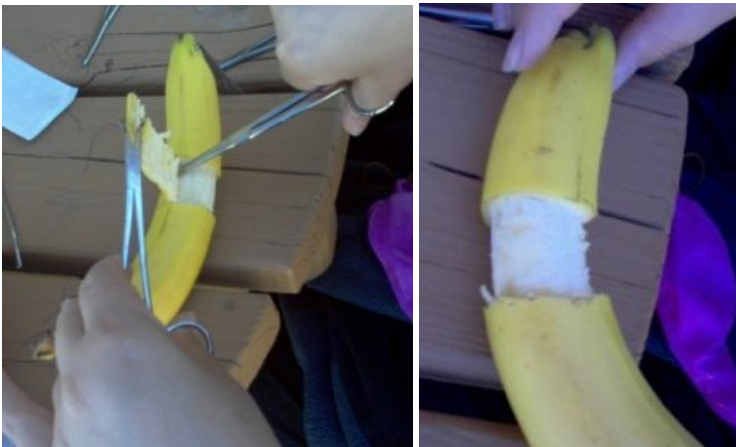
A lanolin based ointment can be coated on the damaged tissue to minimize adhesions within the sheath that would prevent intromission or semen collection. As healing progresses, slight stimulation of a cow in heat will also encourage movement of the prepuce.

Preputial surgery

Many preputial wounds will need eventual surgery. This may be sharp debridement and primary closure but more often this is reconstructive surgery. There are two main options for preputial reconstruction : reefing (circumcision) and amputation. These surgeries are essentially the same as rectal prolapse surgery; reefing is essentially submucosal resection while amputation is similar in both. Vaginoplasty would also equate to reefing.

Preputial resection

Preputial resection is preferred over preputial amputation when possible. It is only possible when the penis can be extended and exteriorized. With the penis extended, the damaged area of prepuce is removed by making a circumferential incision around each side of the damage. These are connected by a longitudinal incision and then peeled off the underlying layers. The two circumferential incisions are then reanastomosed, taking care to not twist the penis and prepuce while doing so.



Preputial amputation

Preputial amputation is performed when the penis cannot be exteriorized. After placement of overlapping sutures 360° around the healthy prepuce to control bleeding, the distal prepuce is transected and the cut edges

anastomosed. It may be helpful to cut a “v” incision in to the circle to avoid cicatrix formation. These do tend to stricture, regardless. For breeding purposes, a prepuce length of at least 1.5-2x as long as the free portion of the penis.

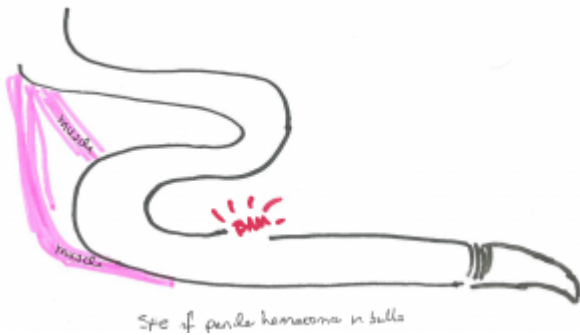Resources (google at your own risk)

[Penile and preputial problems in the bull](#), MS Gill

[Surgical procedures in the bovine](#), start at page 13

Penile injury

The most common penile injury in breeding bulls is penile hematoma (broken penis). Rather than just a small vessel rupture, these are generally tunica albuginea ruptures. The amount of pressure in the bull's erect penis is very high. If the bull bumps the cows flank, something has to give. The penis almost always ruptures at the base of the sigmoid flexure at the level of the retractor penis muscle attachments. It ruptures on the dorsal surface. This area is weaker due to the bending required. This results in a bleed on the dorsum of the penis with the size of the hematoma related to the amount of breeding attempted by the bull after the injury.



Multiple complications can occur :

The dorsal nerve can be damaged either during the rupture or be entrapped by scar tissue during the healing. Some of these bulls will develop nerve damage with further breeding attempts as the tissue tears rather than stretches.

The tunic can fail to heal, leading to loss of pressure in the corpus cavernosum and the inability to gain an erection.

The hematoma can become infected, turning into an abscess.

Adhesions can develop between the penis and sheath, creating phimosis or inability to extrude the penis.

The prepuce is often prolapsed due to limited space in the sheath and can get damaged.

Resources

[Penile and preputial problems in the bull](#), MS Gill

[Urogenital pictures library](#), The Drost project (site is temporarily unavailable)

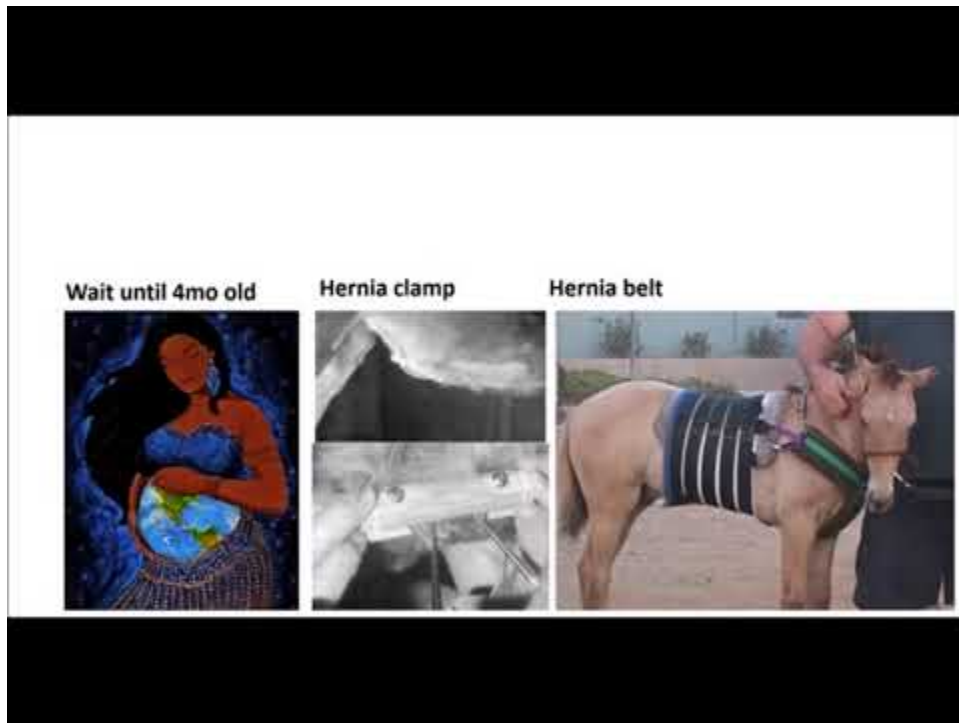
[Penile amputation after trauma](#), case report

Bladder, Urethra and Umbilicus

This unit focuses on umbilical disorders (hernias, infections), urolithiasis, urethral ruptures and bladder ruptures.

Umbilical hernias

Equine umbilical hernias- overview



A YouTube element has been excluded from this version of the text. You can view it online here: <https://open.lib.umn.edu/largeanimalsurgery/?p=878>

Umbilical hernias are typically seen in young animals and are typically are either (1) inherited or (2) develop due to umbilical infections. A few develop due to traumatic separation of the umbilical cord. Ventral hernias can also develop as incisional complications or direct trauma. Congenital hernias are likely inherited if there is no sign of infection. Quarterhorse fillies, Holstein calves and pigs are predisposed.

Small congenital hernias may resolve on their own, often by 4 months of age. Surgery is usually delayed until the foal is weaned and is 4-6 mo of age.

Small hernias are most dangerous as intestines can slip into the hernia and get stuck. Large hernias may not need fixing as intestines slide in and out. The hernia needs to have a firm ring before surgical repair is attempted. This can take 30+ days after trauma or incisional dehiscence.

Surgical repair can be done either closed (keep the hernia sac and peritoneum closed) or open (open the hernia sac and open the peritoneal cavity). Closed repair is frequently performed in horses. A [fusiform incision](#) is made

around the hernia and the hernial sac dissected free of the skin (which is removed). The sac is pushed into the abdomen and the hernia sides closed over it.

Open repair is advised for bovine hernias since infection is often the cause of the hernia. After dissection to the abdominal wall, a stab incision is made into the abdominal cavity and then the hernia sac opened carefully, following the hernial ring. The stab incision should be made to one side to avoid the umbilical vessels that traverse cranially and caudally. These vessels should not be patent at this stage but may contain pus!

Body wall closure should be done with relatively large, long lasting suture in a simple continuous pattern. We use #2 PDS for most weanlings. Babies like to bounce. Bouncing is hard on the incision. PDS is the longest lasting absorbable suture we have. It maintains strength for about 45 days. Continuous patterns have been shown to be more secure under tension than interrupted patterns:

Many of us were taught to close hernias with a vest-over-pants suture or a bunch of cruciates. That was bad advice. The goal was to strengthen the closure or minimize the risk of it falling apart. A vest-over-pants (or Mayo mattress suture) creates an overlapping body wall. The problem is that the body wall doesn't heal that way. The multiple cruciates were done in the hopes that, if one failed, the others would hold. That isn't true either. Once one pops, all of them pop. Simple continuous suture redistributes pressure as needed. Yes, you need to tie good knots but that is true for all of them.

Many postoperative complications are similar across species for abdominal surgery and include infection, peritonitis and hernia recurrence. The body wall is fascia and is poorly vascular. In the adult horse, it takes approximately 60 days for the hernia repair to have moderate strength. No absorbable suture lasts that long so restricted exercise is important.

Key Takeaways

- Umbilical hernias are often associated with umbilical infections in calves.
- Pigs and foals just get hernias (not always infections) and these are likely hereditary. We still do surgery on foals but owners should be advised about inheritance risk. We try to avoid surgery in show pigs.
- Use fusiform incisions, enter abdominal cavity to the side (not cranial or caudal).
- Foals with umbilical infections are sick. Since the diagnosis occurs fairly early, these animals do respond to antibiotic therapy.
- The body wall heals really slowly. Early exercise will increase the risk of hernia recurrence.

Supplemental Resources

[Management of umbilical disorders in the foal](#), In Practice, 2008- more details; nice reference for your files

[Tissue Strength and Wound Morphology of the Equine Linea Alba After Ventral Median Celiotomy](#), Vet Surg 2000- evidence regarding how long the body wall takes to heal after surgery

Video: field anesthesia for hernia repair – designed to give you an mental image of the procedure



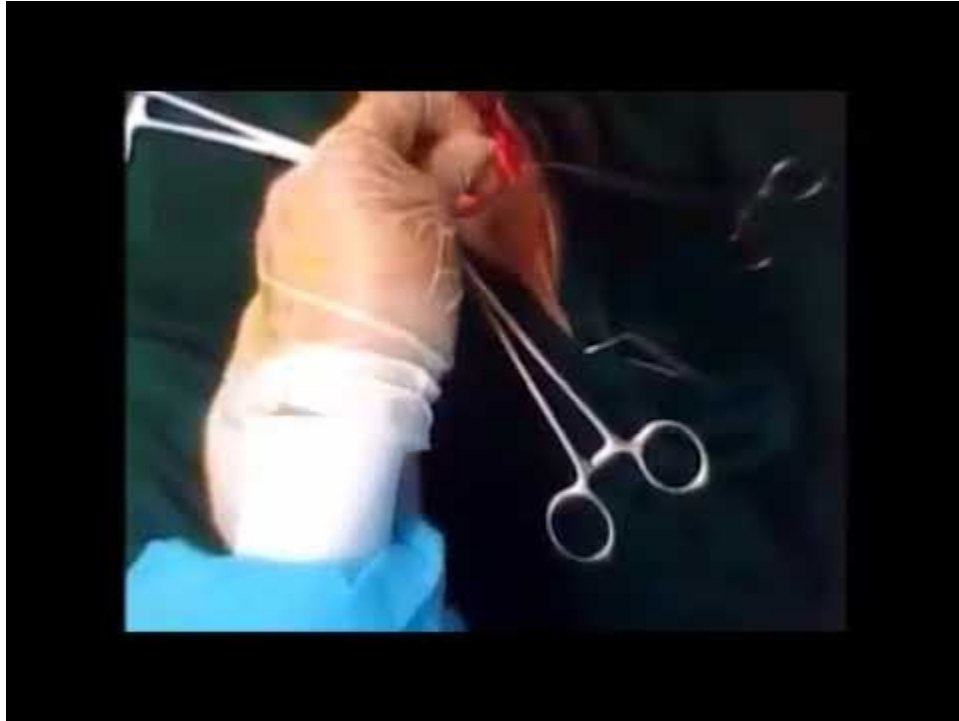A YouTube element has been excluded from this version of the text. You can view it online here: <https://open.lib.umn.edu/largeanimalsurgery/?p=878>

Video : Simple hernia repair in a horse (or dog, pig, calf, etc)- more specifics for those that want them



A YouTube element has been excluded from this version of the text. You can view it online here: <https://open.lib.umn.edu/largeanimalsurgery/?p=878>

Video: protecting the intestines during body wall closure – cool technique that applies to all species



A YouTube element has been excluded from this version of the text. You can view it online here: <https://open.lib.umn.edu/largeanimalsurgery/?p=878>

Exercise I

Challenge yourself!

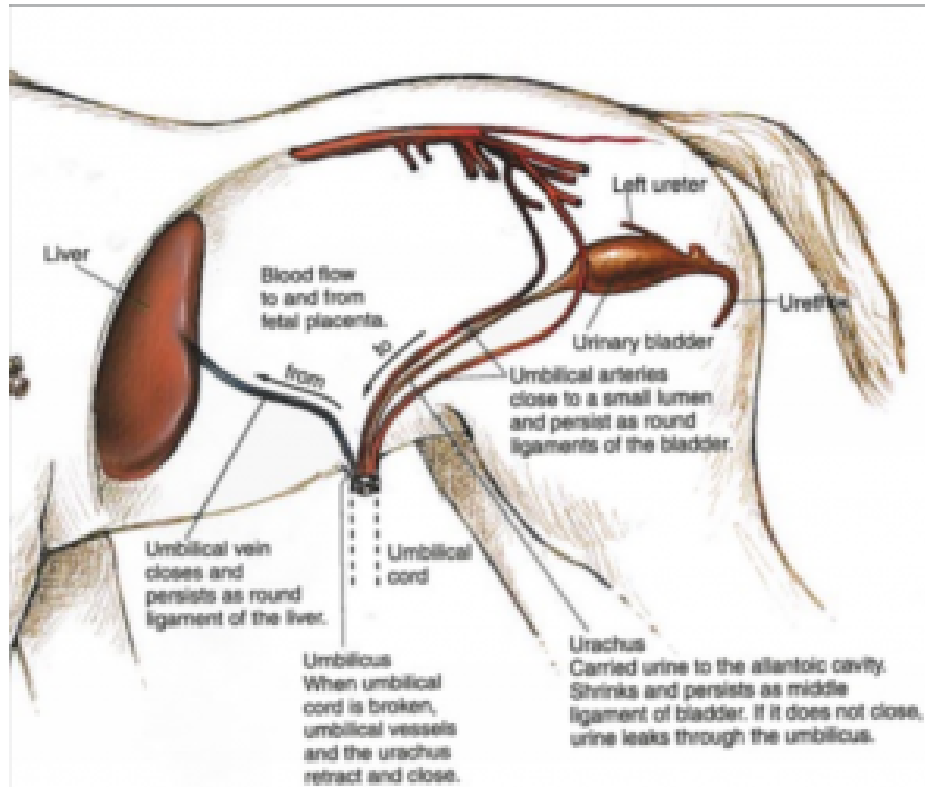


An interactive or media element has been excluded from this version of the text. You can view it online here:

<https://open.lib.umn.edu/largeanimalsurgery/?p=908>

Umbilical infections

Umbilical infections are most commonly seen in calves. Camelids and foals can also present with umbilical infections; these animals tend to be much sicker and present at a younger age.



Umbilical structures. The “round ligament of the liver” is also known as the “falciform ligament”.

Normally the urachus dissolves and is not present at birth. The umbilical arteries turn into the round ligaments of the bladder. The umbilical vein becomes the falciform ligament (aka the round ligament of the liver).

Any of the umbilical structures can become infected (and not follow the normal patterns). Urachal infections are the most common; umbilical vein infections the least common.

Diagnostics



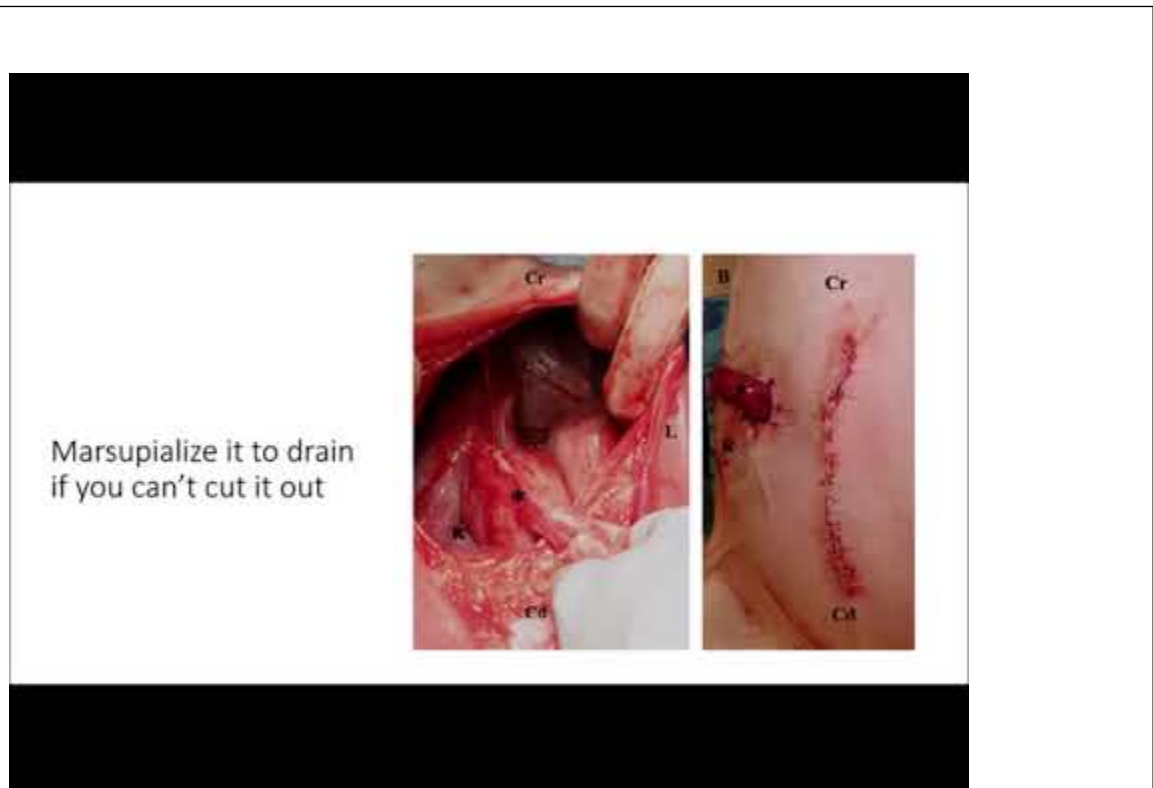An interactive or media element has been excluded from this version of the text. You can view it online here: <https://open.lib.umn.edu/largeanimalsurgery/?p=862>

Camelids and foals get very sick if the umbilicus is infected and are generally treated with systemic antimicrobial therapy.

Calves tend to have more chronic infections and are treated by removal or drainage of the infected structure. If possible, we remove the infected stalk without opening it or rupturing it. In calves, open hernia repair is preferred over closed repair to evaluate for any signs of infected umbilical structures or adhesions that might be hiding in there. After fusiform incision and dissection down to the hernial ring, the peritoneal cavity is entered at the edge of the hernial ring on one side and the sac dissected open carefully to avoid opening any infected umbilical structures. Since the initial incision is blind, the incision is made to the side versus along the cranial path of the umbilical vein or the caudal path of the urachus or umbilical arteries. The infected stalk is identified and, ideally, removed.

Calves with umbilical vein infections often have liver involvement. This makes them higher anesthetic risks and poor doers.

Calf hernias intro (consider this required viewing)



A YouTube element has been excluded from this version of the text. You can view it online here: <https://open.lib.umn.edu/largeanimalsurgery/?p=862>

- Urachal infections are the most common form of umbilical infection in calves. Surgery to remove the stalk includes amputating the end of the bladder.
- Close the bladder in 2 layers with inverting suture patterns. Avoid suture in the lumen of the bladder (nidus for stone formation). 3-0 monocryl works well in foals, goats and other smaller patients.
- Umbilical artery infections can usually be removed en bloc (cut after the mushroom cap and where the “artery” is thin. No blood flow to worry about.
- Umbilical vein infections -> liver and have a poor prognosis. Surgery involves marsupialization.
- Keep these animals on restricted exercise for 6-8 weeks to avoid recurrence of the hernia.
- No matter what you read, don't do a vest over pants or a Mayo mattress suture for these. Appositional continuous pattern is best!
- Use suture material that will last the 6-8 weeks and use large enough (#1 or #2 PDS or nylon usually) suture

Supplemental Resources

[Umbilical masses in calves](#), ACVS- nice review

[Calf umbilical surgery](#), -nice details if you will be doing these in the future – save for your files

We do recommend continuous patterns for all 3 layers of the body wall closure. I also agree with her suture removal time (14 days) but really keep calves and foals restricted for much longer than 14 days. Think about it. How long does your suture last (PDS? Vicryl?) and how long does it take the body wall to heal (60 days for adult horse)? What can happen if they bounce in the time frame between when the suture is no longer strong and body wall is still weak?

This study is one of my favorites:

[Vet Surg.](#) 1999 Nov-Dec;28(6):442-7.

Comparison of incisional bursting strength of simple continuous and inverted cruciate suture patterns in the equine linea alba. [Magee AA](#)¹, [Galuppo LD](#).

OBJECTIVE:To determine the bursting strength of ventral median abdominal incisions closed by either simple continuous or inverted cruciate suture patterns.

METHODS:A 25 cm ventral median incision was made through the linea alba and a 200 L polyurethane bladder was placed within the abdomen. Either a simple continuous or an inverted cruciate pattern using 3 polyglactin 910 with a bite size and suture interval of 1.5 cm was used to close linea incisions. Closure time was recorded

for each pattern. The bladder was inflated with air at 40 L/min, and the pressure at body wall failure recorded. The length of suture used for wound closure and the wound failure modes were recorded. Deviation from the linea (cm), total suture length (cm), suture length to wound length ratio (SL:WL), closure time (min), bursting pressure (mm Hg), and failure modes were compared between groups using Welch-Aspin t-tests. The effects of independent subject variables were assessed for possible effects on bursting strength using analysis of covariance.

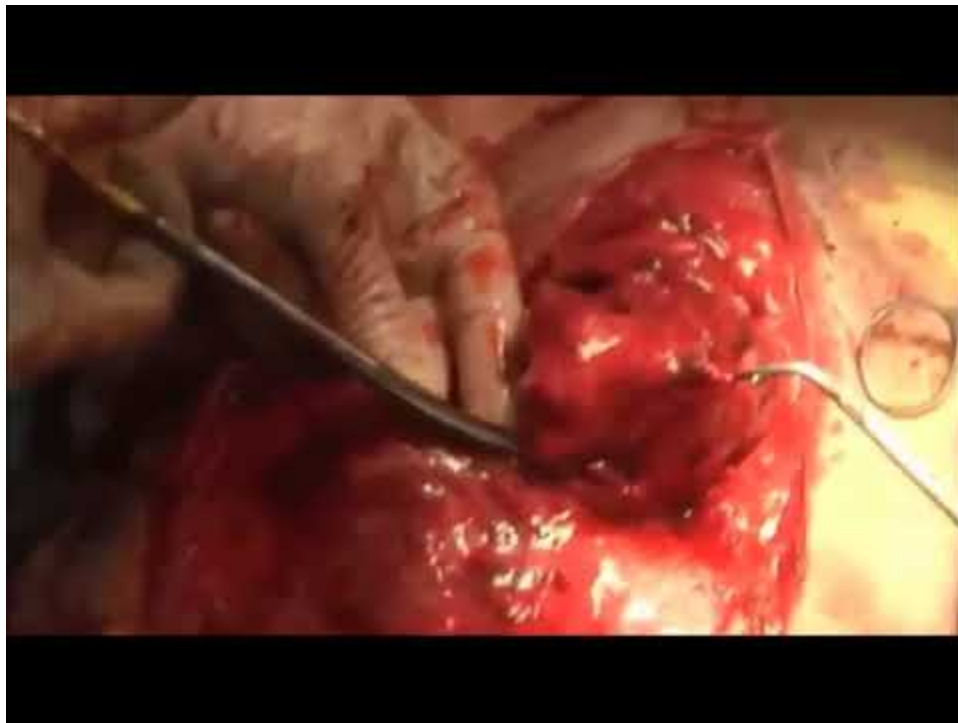
RESULTS: Mean bursting pressure was significantly greater for the simple continuous pattern than for the inverted cruciate pattern ($P = .01$). Significantly less suture material ($P = .0002$) was required with the continuous pattern than with the inverted cruciate pattern. Mean closure time, SL:WL, deviation from the linea, and failure modes were not significantly different between groups. No significant effects were noted for independent variables in both groups on bursting strength.

CONCLUSIONS: In this model, a simple continuous closure pattern for ventral median abdominal incisions was stronger than an inverted cruciate pattern. A simple continuous pattern leaves less foreign material in the wound, which may be of benefit in reducing incisional complications.

CLINICAL RELEVANCE: Use of a continuous closure pattern for the linea alba may offer greater wound security during episodes of increased intra-abdominal pressure in horses.

[Comparison anesthesia techniques in calves undergoing umbilical surgery.](#) Vet Anes Anal 2012 – for future reference

More visual details for those of you interested:



A YouTube element has been excluded from this version of the text. You can view it online here: <https://open.lib.umn.edu/largeanimalsurgery/?p=862>

Exercise 2

Challenge yourself!



An interactive or media element has been excluded from this version of the text. You can view it online here:

<https://open.lib.umn.edu/largeanimalsurgery/?p=911>

Patent urachus

Generally a patent urachus in 1-2 week old foal means the foal is systemically ill. Treat the systemic illness, not the urachus (broad spectrum antibiotics). Once the foal is improved, the urachus will close over. Occasionally the urachus becomes infected and needs to be removed. This is the common scenario in calves but is rare in foals. Treatment with silver nitrate or other cauterizing agents does not help and may lead to infection.

Other reasons the urachus fails to close may be due to congenital anomaly, abnormal tension on the cord at parturition or partial urethral obstruction at parturition.



A YouTube element has been excluded from this version of the text. You can view it online here: <https://open.lib.umn.edu/largeanimalsurgery/?p=919>

Supplemental Resources

[Navel ill in foals](#), ACVS- good resource to bookmark

Study Break

<http://www.smosh.com/articles/20-ridiculously-stupid-warning-labels>

<http://rinkworks.com/said/warnings.shtml>

Ruminant urolithiasis

[Urolithiasis podcast](#)

Urolithiasis is a common problem in goats and feedlot cattle. It is not uncommon in pigs, camelids and horses. The type, number and location of stones varies by species. Pigs and camelids can also develop urethral polyps which present in very similar manner to stones but are much harder to treat (can't readily remove them). Camelids tend to die due to related metabolic complications.

Horses present for hematuria. The other species present for partial or complete urinary obstruction. Animals may be seen straining to urinate or defecate. Feedlot steers may be found dead (often with calculi on the preputial hairs). A vocalizing buck or wether should be assumed blocked by a urolith until proven otherwise.

Diagnosics

Passing a urinary catheter is generally not possible in ruminants due to the urethral diverticulum. This means you cannot diagnose stones just because you can't pass a urinary catheter. The most effective diagnostic test is a rectal exam (digital rectal exam in small ruminants). In an obstructed animal, the urethra is often pulsing. Imaging can be used to confirm or assess the number and location of stones. Most (but not all) stones are radio-opaque. Ultrasound can be used to identify full bladders, urine leakage and occasionally urethral stones. Stones will often lodge in the vermiform appendage of goats and in the sigmoid flexure of all ruminants (and generally in both).

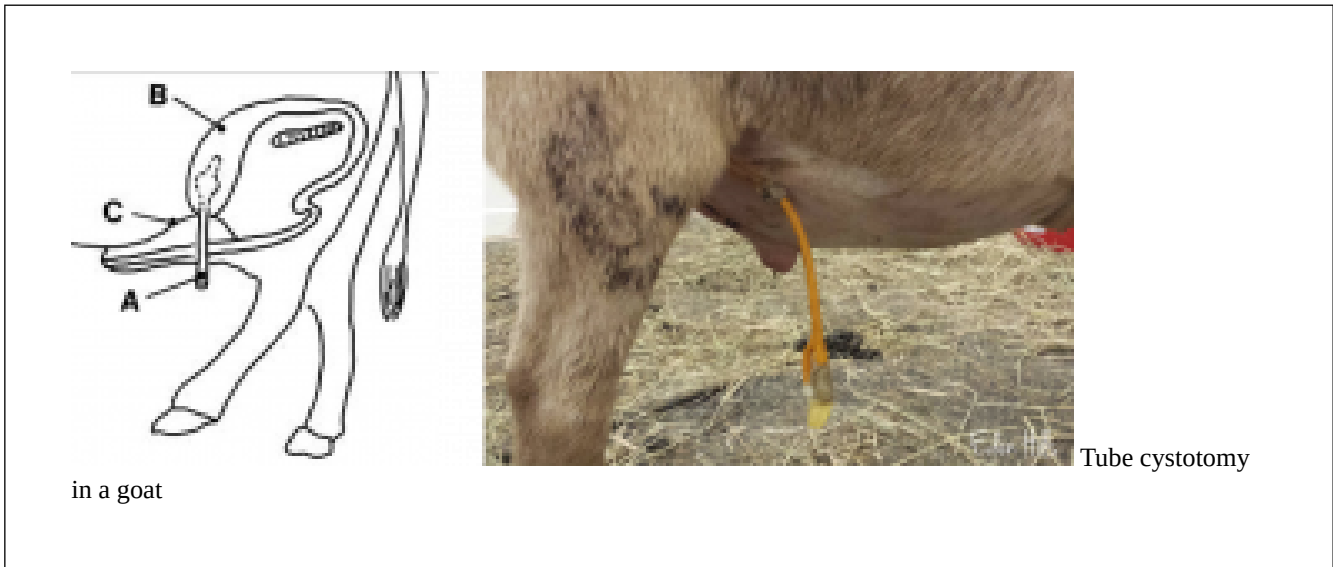
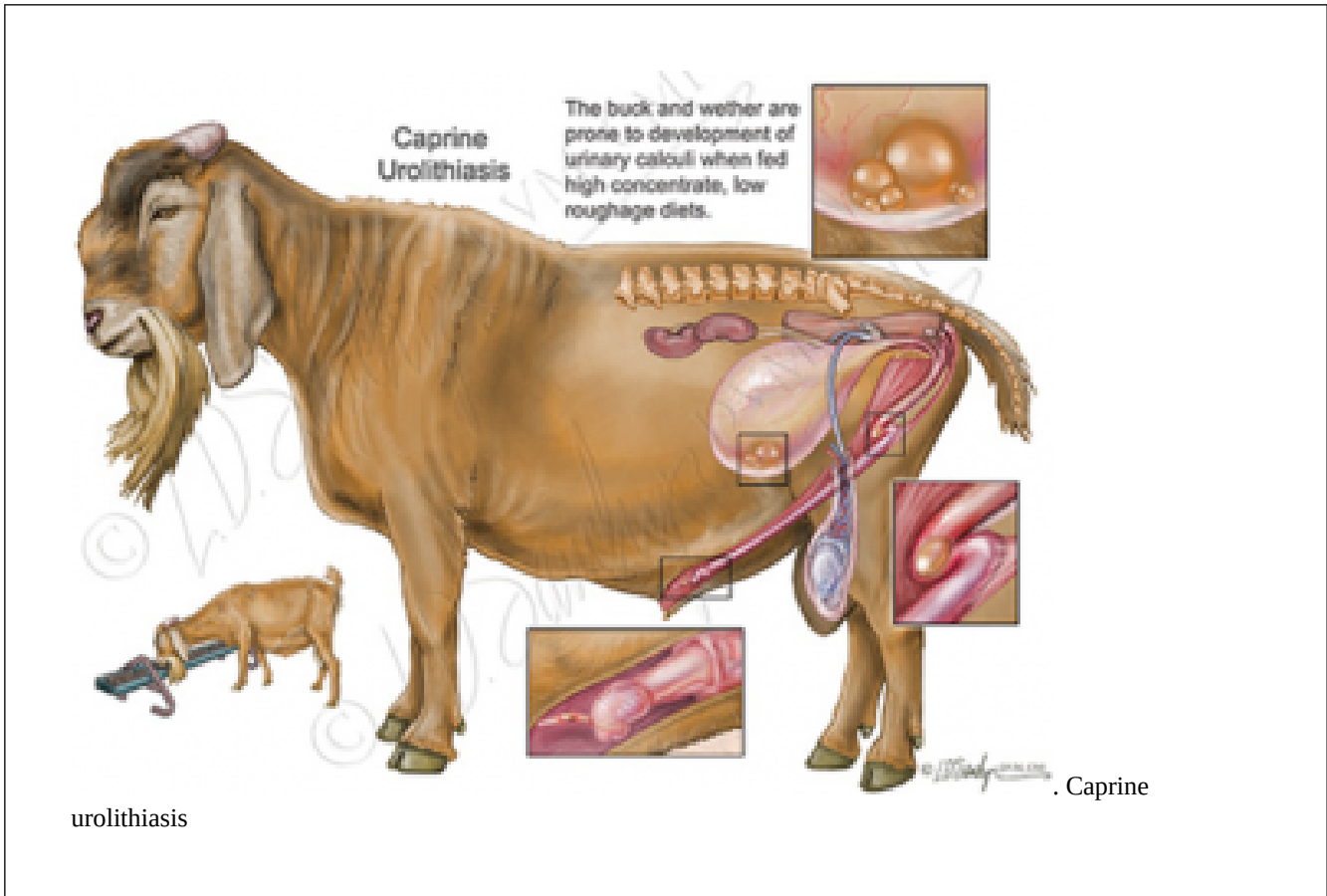
Treatment

- Enable urination (amputation of the vermiform appendage, tube cystotomy or other procedure) or relieve the bladder via cystocentesis
 - amputation of the vermiform appendage can help temporarily. The offending stone is removed but more come down the urethra later.
 - perineal urethrostomy is not a great choice in ruminants due to their propensity to stricture; it works fine in feedlot steers as their lifespan is limited
 - penile amputation is performed in feedlot steers (instead of perineal urethrostomy) as it is easier
 - bladder marsupialization leads to severe urine scald and ascending pyelonephritis
 - most pet goats will do best with a tube cystotomy
- Remove, dissolve and/or encourage passage of the stones
 - once the pressure to urinate is relieved (tube placed into bladder), the stones may pass on

their own as the urethral relaxes

- retrograde or anterograde (at surgery) flushing of the urethra tends to cause urethral rupture
- Minimize the risk of recurrence
 - once a stone former, always a stone former
 - dietary adjustments are needed
 - soychlor or pasturechlor is the most effective dietary adjustment we have currently
 - many people incorrectly believe ammonium chloride in the feed is effective
 - it works but goats don't like it. For effective use, it needs to be given orally as a medication.
 - it should also be given in a pulsatile fashion – it stops working if given continuously
- Manage any related complications (uremia, urinary tract infections, ruptured bladder, ruptured urethra)
- Analgesics are needed, especially for goats
 - consider phenazopyridine (relieves bladder irritation), narcotics and NSAIDs
 - goats are pretty sensitive to pain and will tend to be in rough shape for a day or two post-operatively
- Remove the tube once the goat can urinate on his own through the penis
 - this happens when the stone is passed, even with the tube still in place
 - antibiotic coverage is maintained while the tube is in place due to the risk of ascending infection
 - generally we leave the tube in for at least 8 days to create an adhesion to the body wall (this number is pulled out of thin air as far as I can tell)

Uremic animals are not edible. All uremia needs to resolve before an animal is shipped for meat. This can take several weeks.



Key Takeaways

- If you have an animal with renal compromise, be very cautious with NSAIDs, steroids, tetracyclines and aminoglycosides. Penicillins are generally pretty safe. Consider drugs excreted by liver if no other

restrictions apply (eg fluorquinolones).

- Goats get stones because of diet issues. Urethral pulsation = obstruction. Tube cystotomies rule. Do not flush the urethra – goat urethras easily rupture.
- Feedlot steers get stones due to diet issues. Penile amputation is recommended and the site will still stricture. Slaughter when no longer uremic. Uremic animals are not edible.
- Camelids die
- Pigs can have stones (removable) or polyps (not removable)
- DCAD diets are most effective. Do not give soychlor to the breeding does as it also pulls calcium from the goat and leads to jelly babies (no calcium).
If clients use ammonium chloride (most goats won't eat enough to help), they need to stop it intermittently or it stops working

Primary Resources

[urolithiasis anes and tube cystotomy Sheep and Goat Medicine-](#) works through all the diagnostics and options for treatment in more detail

[Prevention of urolithiasis in livestock](#)– CSU Van Metre- great practical hints for preventing stone formation

Secondary Resources

[General anesthesia for patients with liver or renal disease](#), DVM 360 2011 – SA perspective but nice review of what drugs are good or bad when your patient has other issues

[1990 antibiotic associated complications with renal disease](#) 1990 Reviews of Infectious Diseases- also for your files. hard to find this info.

[Obstructive urolithiasis in ruminants](#) – a review – 2013 VetWorld – starts at square 1 and covers physiology, lab changes etc

[urolithiasis in small ruminants](#), ACVS – succinct general overview describing options; doesn't give relative pros/cons

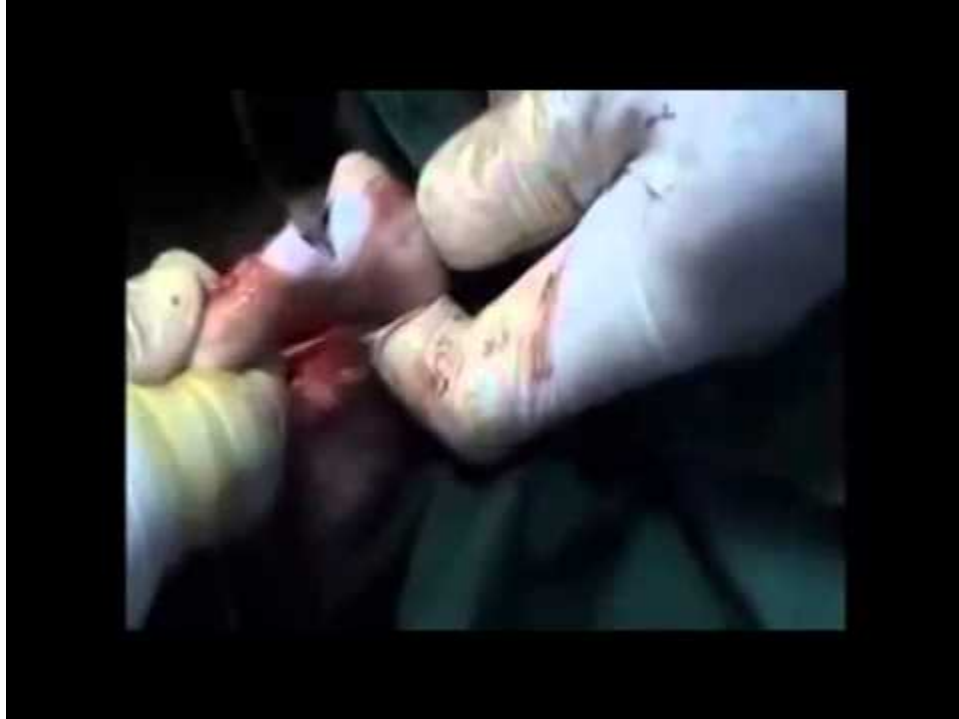[Urolithiasis in small ruminants](#), AASRP- more details than you ever wanted to know; good reference for future as he goes through more complex situations; please don't do the hydropulsion though.

[Surgery of obstructive urolithiasis in ruminants](#), VCNA 2008 -good overview with nice references; good for your files

[Summer 2005 newsletter](#) case of the month (page 3-4)- I use this for soychlor dosing; for your files. Also totally agree with filling the foley balloon with saline vs air. They last longer

[Effects of castration on penile and urethral development in Awassi lambs](#), 2007 Bulgarian J of Vet Med -finally some EBM on this topic

penile amputation -for those of you struggling to visualize or just wanting more



A YouTube element has been excluded from this version of the text. You can view it online here: <https://open.lib.umn.edu/largeanimalsurgery/?p=853>



A YouTube element has been excluded from this version of the text. You can view it online here: <https://open.lib.umn.edu/largeanimalsurgery/?p=853>

STUDY BREAK

otter urolithiasis



A YouTube element has been excluded from this version of the text. You can view it online here: <https://open.lib.umn.edu/largeanimalsurgery/?p=853>

dolphin urolithiasis



A YouTube element has been excluded from this version of the text. You can view it online here: <https://open.lib.umn.edu/largeanimalsurgery/?p=853>

How to - Tube cystotomy

Indications

Tube cystotomy is typically performed in small ruminants for treatment of obstructive urolithiasis. Tube cystotomy can be performed in other species. It is generally temporary but can be a permanent option if the obstruction does not resolve or is due to polyps or tumors.

Relevant anatomy

A tube is placed in the bladder and exited from the body wall in a location that allows the bladder to sit in a normal position and in direct apposition to the body wall.



Preoperative management

Fluid deficits and severe electrolyte abnormalities should be corrected preoperatively. Hyperkalemia is rare in goats and dehydration is not often severe so therapy does not often need to be completed prior to anesthesia.

Food restrictions: NA

NSAIDs/analgesics: Preoperative NSAIDs and analgesics are recommended as goats are very sensitive to pain. Flunixin meglumine is often combined with a narcotic.

Antibiotics: Preoperative antibiotics are indicated. Common choices are ceftiofur, amoxicillin or ampicillin.

Tetanus prophylaxis is recommended.

Local blocks: The skin incision can be blocked using a U shaped line block

Position/preparation: Dorsal recumbency

Surgery Supplies:

- Standard surgery pack
- 3-0 absorbable suture (bladder)
- 0-1 absorbable suture (PDS) or nonabsorbable suture (body wall)
- 2-0 absorbable suture (musculature, SQ tissue)
- 2-0 to 0 nonabsorbable suture (skin)
- 2-0 to 0 suture for fingertrap knot (braided works well to hold it but is often absorbable so can be a problem in long term cases)
- Pezzar (foley if pezzar is not available) sized to match the patient (no more than 1/8 size of bladder when not distended). Pezzars are preferred as the foley balloon can rupture. If used, the balloon should



be distended with saline rather than air.

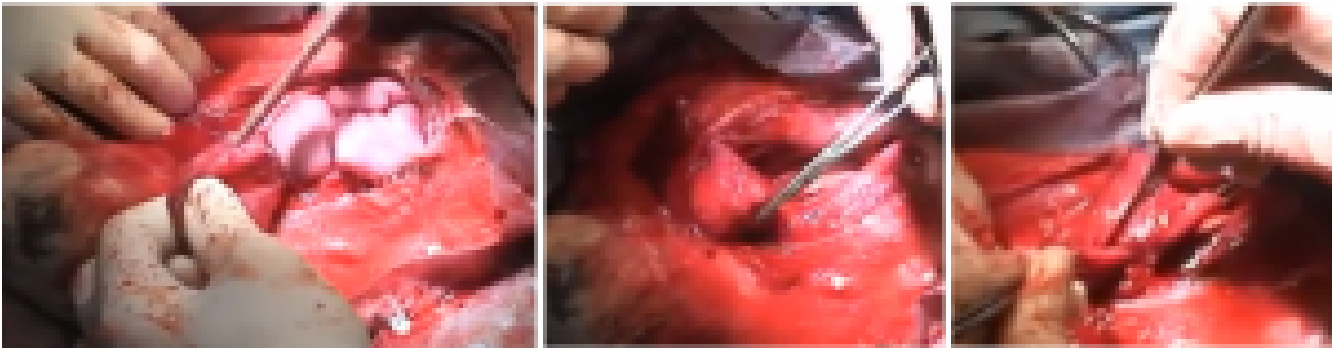
Surgical procedure

The patient is placed in dorsal recumbency under general anesthesia, prepped and draped.

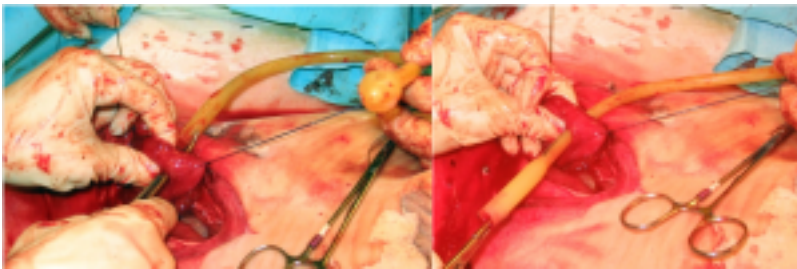
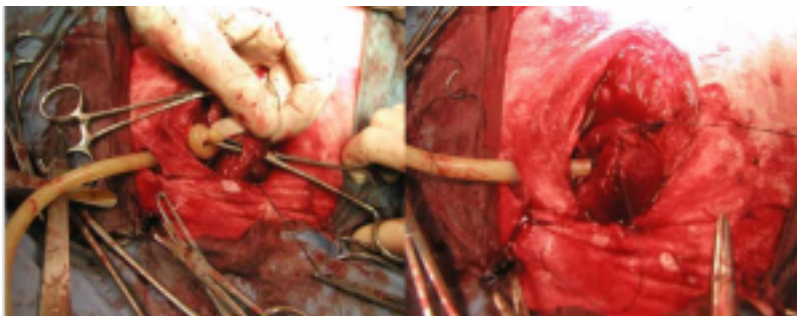
A paramedian skin incision is made in the caudal abdomen, adjacent to the prepuce. The incision should extend ~10 cm and finish between the nipples. The skin and prepuce are shoved to the side and the abdomen opened through the linea alba.



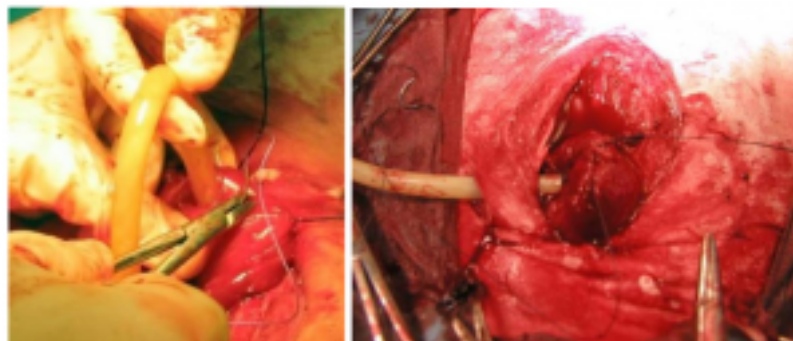
The bladder is identified. Two 3-0 stay sutures are placed in the bladder at the dorsal aspects on either side. The bladder is incised close to the trigone and the bladder flushed to remove as many stones as possible. A red rubber catheter can be placed into the urethra and the urethra flushed (low pressure only) to remove additional stones. Forceful flushing can easily rupture the urethra and should be avoided.



A second incision is made on the same side of the bladder as the tube will exit the body wall. A small nick is made and the tube passed through the nick. This can be done by pushing the pezzar end into the bladder or the tube end out of the bladder. A pursestring suture is placed around the tube.



The bladder is closed in 2 layers using 3-0 absorbable suture in inverting patterns. The stay sutures can be tied in place in trimmed short to prevent leaks. The bladder should be checked for leaks by adding fluid through the pezzar.



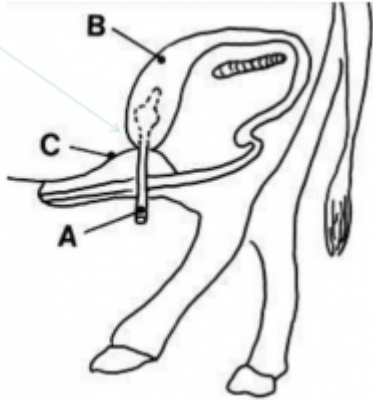
Purse string

Bladder closed

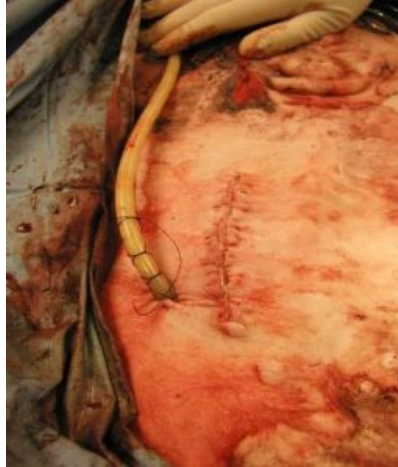
The tube is exited through all layers of the body wall, generally at a slight angle so that there isn't a direct path from body wall to outside but that each opening is a little off from the others. Be careful to make sure the tube

goes through the wall, not through the incision (or you can't close the incision). **The bladder needs to reach the body wall- the incision through the skin cannot be too far forward.**

Direct apposition

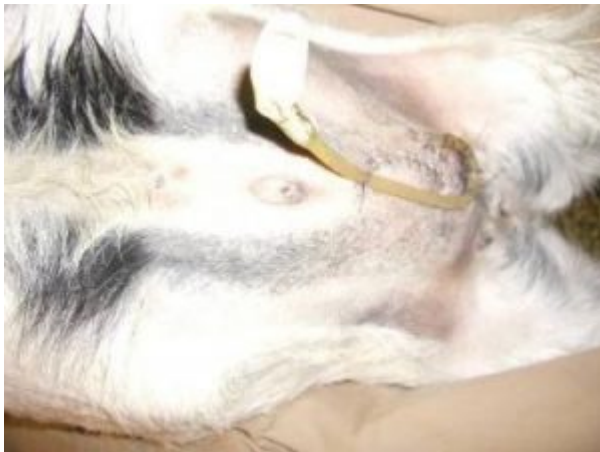

The pezzar is pulled up so the bladder is snug against the body wall. The pezzar is secured in place using a fingertrap knot of 2-0 suture material.



The body wall is closed routinely. The linea is closed using a simple continuous pattern with slowly absorbing 0 suture material. If the incision was off midline, the ventral sheath of the rectus abdominis is closed similarly. Subcutaneous tissues are closed in a simple continuous pattern using 2-0 absorbable suture. The skin is closed using nonabsorbable suture in a Ford interlocking or simple continuous pattern.

The pezzar is tacked to the body wall in 2-3 spots so that the opening of the pezzar is lined up with the preputial opening.



Postoperative care

- A glove fingerip is placed over the end of the tube; a nick is made in the end of the glove finger to allow urine drainage. This is to minimize the risk of ascending infection.

- Postoperative analgesics are usually required in the first 24 hours. Buprenorphine is commonly used; morphine is also an option.
- The patient is left on antibiotics until after the tube is removed.
- NSAIDs are maintained for at least 3 days, typically until normal urine flow is resumed.
- The tube is checked frequently to ensure the tip is dripping. If dripping stops, the tube may be blocked by a stone or blood clot. The obstruction should be flushed free using sterile technique.

Most patients will start urinating out of the prepuce within a few days. Once the obstruction is relieved with the tube placement, the urethra relaxes and the stone(s) pass.

The tube should be left in place for at least 8 days. The goal of this time frame is to permit an adhesion to form between the bladder and the body wall so urine does not leak into the peritoneal cavity with tube removal.

Once the patient is urinating and it has been at least 8 days, the tube can be removed. The fingertrap knot is removed, the body wall is held in place with one hand while the tube is pulled forcefully with the other. The owner should monitor for uroabdomen (distension, off feed) but this is rare.

Complications

Lack of urination

Occasionally the stones do not pass. Lidocaine can be infused up the catheter using sterile technique. A lidocaine epidural may be administered. Muscle relaxants and alpha blockers (acepromazine, bethanechol, phenoxybenzamine) can be tried. The tube should be kept in place. Occasionally other therapy (laser lithotripsy etc) may be necessary.

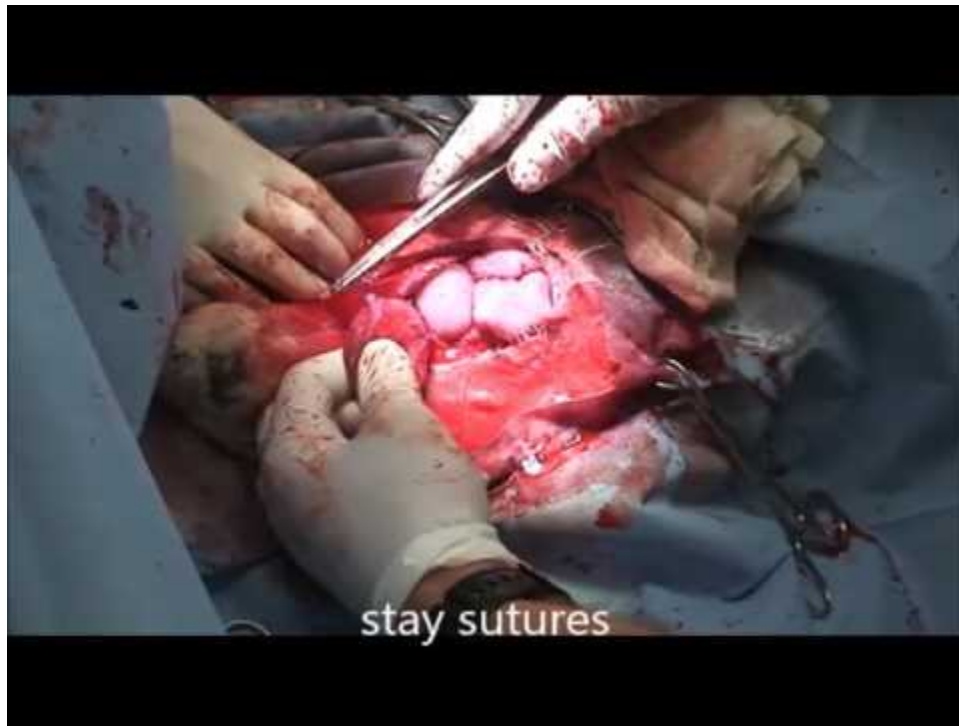Urethral rupture

If flushing is too vigorous, the urethra may rupture. The skin ventral to the area should be lanced and the tissues flushed. The tube will help with healing.

Infection

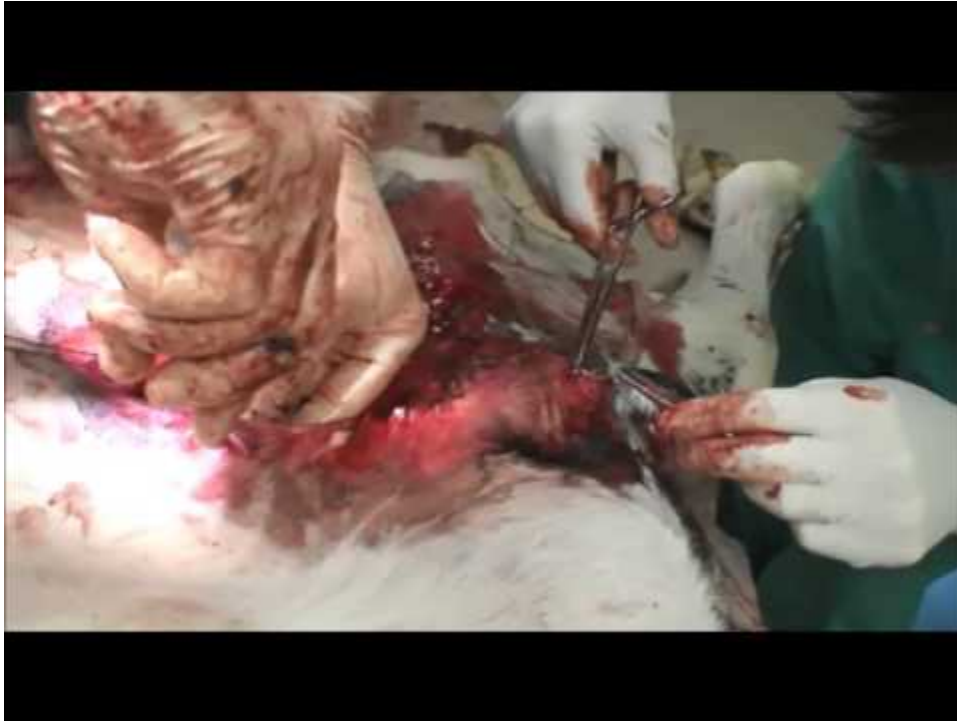As with any surgery, incisional infections and peritonitis are a risk. Animals will be off feed, tender on palpation of the incision (incisional infections), and may be febrile.

Videos

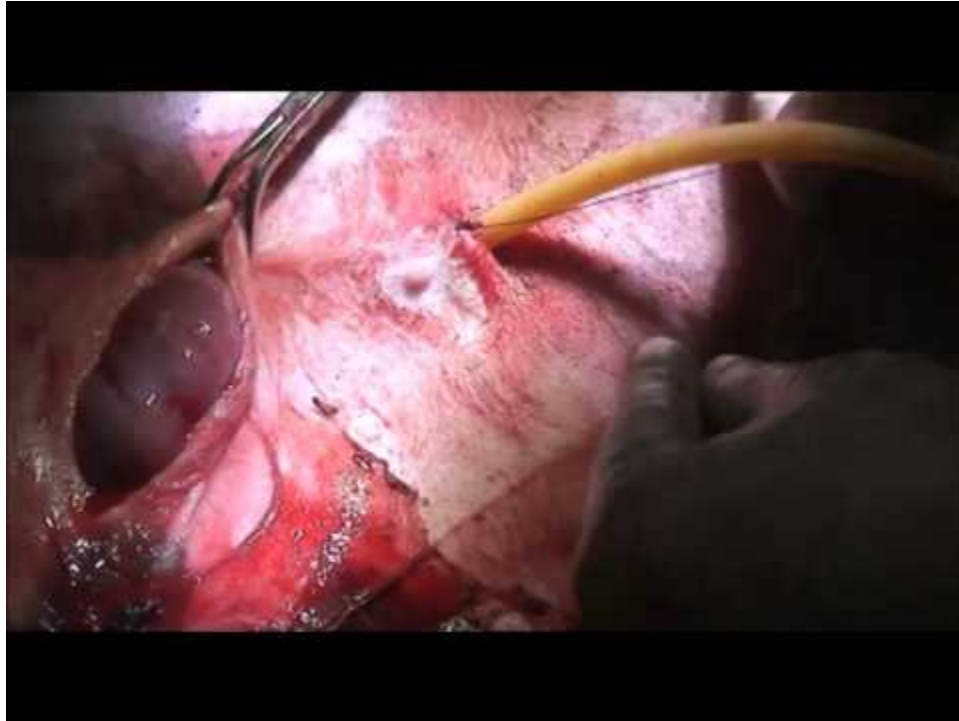


A YouTube element has been excluded from this version of the text. You can view it online here: <https://open.lib.umn.edu/largeanimalsurgery/?p=2978>

pulling pezzar through body wall



A YouTube element has been excluded from this version of the text. You can view it online here: <https://open.lib.umn.edu/largeanimalsurgery/?p=2978>



A YouTube element has been excluded from this version of the text. You can view it online here: <https://open.lib.umn.edu/largeanimalsurgery/?p=2978>

Resources

[Urolithiasis in small ruminants](#), AASRP- more details than you ever wanted to know; good reference for future as he goes through more complex situations; please don't do the hydropulsion though.

[Surgery of obstructive urolithiasis in ruminants](#), VCNA 2008 -good overview with nice references; good for your files

Ruptured bladders

[Ruptured bladders podcast](#)

Ruptured bladders are most common in neonatal colts and in ruminants with urolithiasis. Ruptured bladders are unusual in camelids and swine. In adult horses, ruptured bladders are generally associated with parturition and are not common.

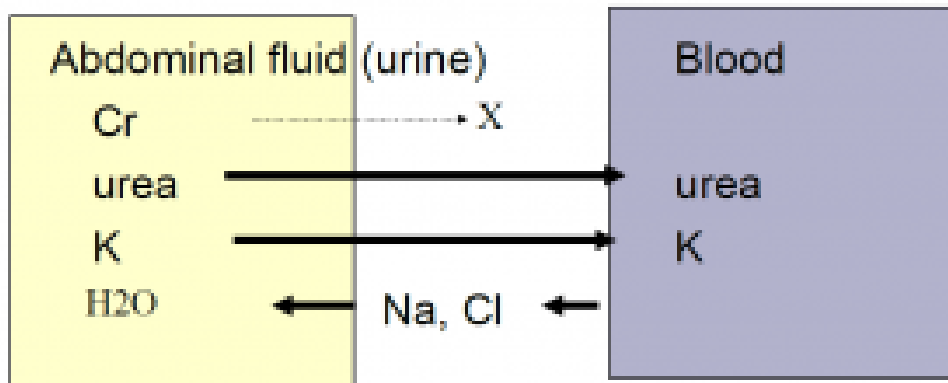
Colts are more likely than fillies to develop ruptured bladders during parturition. The longer urethra means the squeeze of parturition is more likely to rupture the bladder than to express the bladder. The bladder generally ruptures on the dorsal surface. Foals are often normal for the first day but then develop signs of uroabdomen.

Ruminants with obstructed urethras may rupture either the bladder or the urethra. When the bladder ruptures, the fluid leaks into the peritoneal cavity. When the urethra ruptures, the fluid leaks subcutaneously along the ventral abdomen.

Diagnostics

Due to the size of the molecule, we use creatinine to determine if the fluid in the belly is urine or not. Creatinine doesn't equilibrate so we can compare the abdominal fluid creatinine to the serum creatinine. If the concentration in the abdominal fluid is at least 2x the concentration in the blood, it is urine. Heating the fluid is often a quick and dirty way to tell, too.

Alterations with urinary track disruption



■ $\text{Cr (abd) : Cr(blood) > 2:1}$

When urine is released into the peritoneal cavity, it is full of water, urea and potassium. The urea and potassium equilibrate with the blood, leading to abnormally higher levels of urea and potassium in the blood. The free water pulls sodium and chloride after it, leading to low levels of sodium and chloride in the blood. Creatinine cannot equilibrate so is useful to measure.

Treatment

1. drain the urine out of the peritoneal cavity
2. repair the bladder surgically or keep the bladder decompressed so it can heal via second intention (this may require a PU)
3. manage the inflammation, uremia and electrolyte disturbances

Because these are neonatal and/or sick animals, anesthesia can be tricky. If the animal has high potassium when it is anesthetized, it can lead to fatal arrhythmias. Oxygenation can be impaired if the thoracic or abdominal cavities contain fluid that restricts diaphragmatic function. Dehydration needs to be managed without causing more fluid accumulation and with careful attention to the electrolyte imbalances. Remember, many fluids contain potassium and/or lactate.

For neonate sedation concerns, go back to the earlier [drug chapters](#) for more resources.

To avoid adhesions and future stone formation, bladders are closed with two layer inverting patterns that don't enter the lumen (eg two layer Cushing pattern). By using an inverting pattern, we minimize suture exposure and adhesions. Avoiding the lumen decreases the risk of additional stone formation on the suture nidus. Bladders heal quickly so short duration absorbable suture works well.

Prognosis

Prognosis is surprisingly good. Anesthesia is the risky part. Foals recover well and seem to have no related problems. Goats need to have the cause of the obstruction fixed as well as the ruptured bladder. Large ruminants are generally managed conservatively until slaughter is possible.

Key Takeaways

- Ruptured bladders occur most commonly in male foals (~ 2 days of age) and in ruminants with urolithiasis.
- Peritoneal creatinine 2x serum creatinine = urine. A quick test is to heat the sample and sniff.
- Foals should be referred to a hospital equipped to manage the hyperkalemia and anesthetic risk. These animals must be stabilized – eg get K < 5.5 prior to anesthesia. Medical emergency, not surgical emergency.
- Prognosis is good for foals. Prognosis is not as good for animals with urolithiasis.
- Keep suture out of bladder (use cushing or lembert); otherwise it becomes a nidus for stone formation

PRIMARY RESOURCES

[Uroperitoneum in foals](#), Merck online- nice overview of how these babies look

[Ebook Anesthesia chapter](#) – see Foal resources section at bottom of page

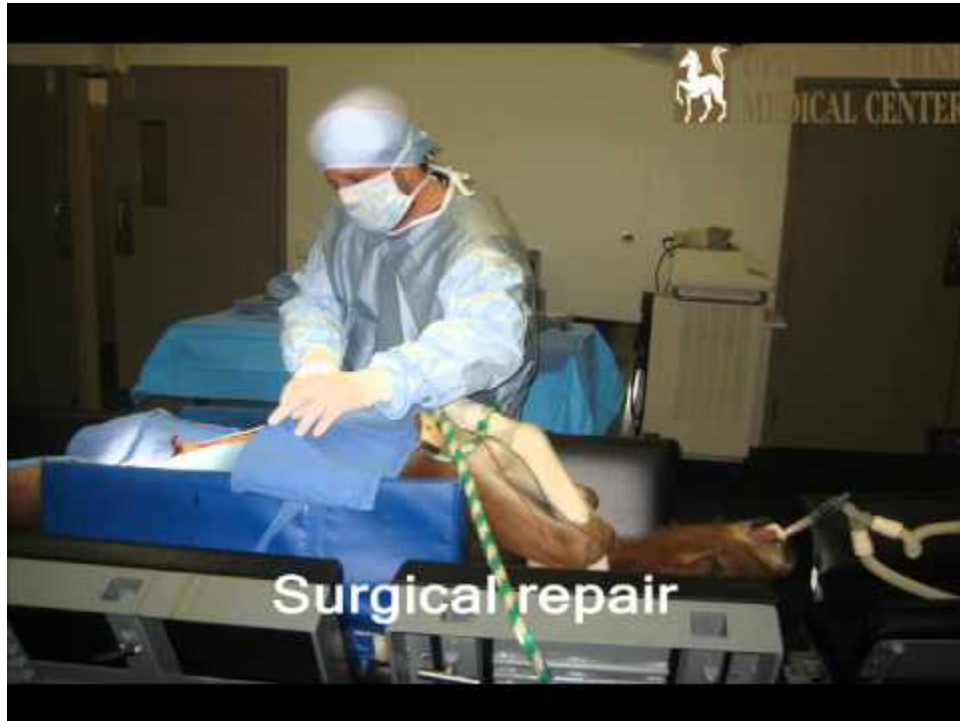
[Common fluid types in vet med](#) -note: we carry saline, LRS and sterile water/dextrose.

SECONDARY RESOURCES

[Bladder ruptures](#), AAEP- client friendly version

[Malone Notes ruptured bladder](#) _what more is there to say. more of a surgeon perspective

[Conservative management of a ruptured bladder in a gelding](#), 2019 EVE – good review of principles that can apply across species



A YouTube element has been excluded from this version of the text. You can view it online here: <https://open.lib.umn.edu/largeanimalsurgery/?p=860>

Study break- be proud!



A YouTube element has been excluded from this version of the text. You can view it online here: <https://open.lib.umn.edu/largeanimalsurgery/?p=860>

Ruptured urethras

The most common cause of ruptured urethra in a ruminant is urolithiasis. In horses, the most common cause is trauma. Ruptured urethras are rare in camelids and swine.

Ruminants

As the stones lodge in the urethra, they can cause local damage (pressure necrosis). The force of urination can lead to rupture at the damaged site. The early signs of urethral obstruction can easily be missed in feedlot cattle; often the animals present with urethral rupture. Urethral flushing or forceful bladder compression can also rupture the urethra. This is much easier to do in small ruminants than in small animals. It may be a combination of weaker urethral wall due to the sigmoid flexure and chronicity of the stones. **AVOID** flushing the urethra in goats!

Subcutaneous urine is very irritating. Animals often develop a fever and skin necrosis from the urine. As urine gravitates ventrally, a plaque of edema will develop around the prepuce. This eventually leads to cold, leathery skin in the area.

Treatment


1. avoid more urine leakage – divert urine via a tube cystotomy or perineal urethrotomy
2. release the urine that is collecting subcutaneously – incise the skin to allow drainage
3. reduce the inflammation – NSAID therapy

Animals cannot be shipped for meat until the uremia resolves. Pet animals can recover with proper treatment. The urethral rupture will usually heal via second intention closure.

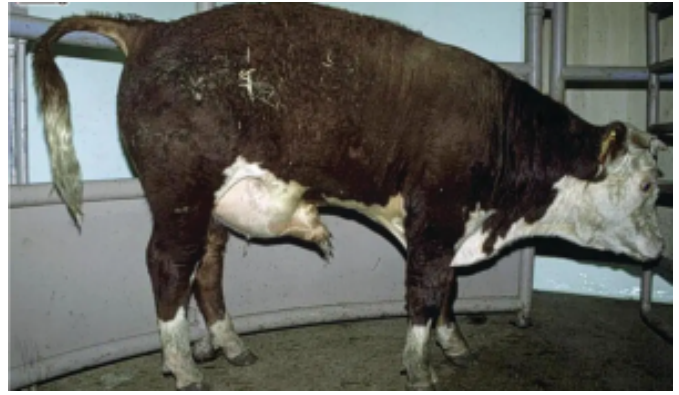Horses

Urethral rupture is rare in horses and is usually related to a kick in the perineal region or to accidental trauma during castration. Treatment goals are the same as for cattle. Diagnosis can be more challenging as the kick injury may not have been witnessed and signs are often not evident for several days. See [equine hematuria](#)

Ruptured bladder (left) vs ruptured urethra (right)



<https://actavetscand.biomedcentral.com/articles/10.1186/s13028-015-0126-y>



<https://veteriankey.com/bovine-urolithiasis/>

Exercise 3

Exercises

Try out your knowledge on this case



An interactive or media element has been excluded from this version of the text. You can view it online here:
<https://open.lib.umn.edu/largeanimalsurgery/?p=945>

Exercise 4

Exercise



An interactive or media element has been excluded from this version of the text. You can view it online here:

<https://open.lib.umn.edu/largeanimalsurgery/?p=28>

Equine hematuria

The most common causes of hematuria in horses are penile SCC and urolithiasis.

Renal hemorrhage

Kidney disorders are rarely treatable in the horse. Luckily, renal failure progresses slowly in the equine and diagnosis of renal disorders may not be imminently fatal. However, diagnosis of kidney disease is often delayed due to the lack of clinical signs prior to the onset of renal failure. Renal hemorrhage is considered idiopathic and usually becomes bilateral time. It may be due to toxins causing medullary crest necrosis. Surgery on the kidneys is rarely performed.

Bladder neoplasia

Solitary lesions of the bladder apex can be treated by resection cystoplasty (cut off end of bladder and close). However, neoplasia is usually advanced by the time of diagnosis.

Urethral hemorrhage

Stallions are presented for hemospermia associated with pain on ejaculation. Geldings are presented for hematuria with minimal other clinical signs. On endoscopy, linear urethral defects are found at the level of the ischial arch (near openings for accessory glands). It is theorized that the bleeding is due to “blow out” of the corpus spongiosum penis. Blood is seen at end urination when the bulbospongiosus muscle contracts to expel urine (and there is an increase in pressure in the corpus spongiosum).

Treatment involves prolonged sexual rest and/or temporary perineal urethrostomy. By opening the corpus spongiosum penis, pressure cannot build up and bleeding is minimized. Because the CSP is the suspected culprit, the PU may not need to enter the urethral lumen but may just extend through the CSP.

Urethrorrhexis (urethral laceration)

The urethra is relatively exposed in the perineal and inguinal region. Trauma from kicks, barbed wire, and jumping fences can lead to laceration. The penis has also been lacerated accidentally in castration procedures. Following trauma, urine leakage leads to a pronounced soft tissue inflammatory reaction with secondary edema of the prepuce, inguinal region and hindlimbs.

Diagnosis may be difficult. Ultrasound and endoscopy can be useful. Fluid aspirated from the tissues will have an ammonia smell, particularly if heated. Dyes and positive contrast radiographs may be needed.

Treatment goals :

- control regional inflammation with NSAIDs, hydrotherapy, antibiotics
- surgical resection of damaged tissue
- divert urine flow

Equine urolithiasis

Urolithiasis

Horses tend to have a single stone in the bladder. The presenting complaint is hematuria, generally associated with exercise. It is rare for the stone to move more distally than the pelvic urethra. However, those cases can develop ruptured bladders. Many horses with bladder stones do have nephroliths as well.

Bladder stone removal may be accomplished through the urethra (standing) or via cystotomy (general anesthesia). Gradual urethral sphincter dilation and/or sphincterotomy can allow stone removal in mares. Stones in males are often removed via perineal urethrotomy or, less commonly, via a perirectal incision. In both cases, stones may need to be broken up prior to standing removal. Other options include stone buster lasers, laparoscopy and lithotripsy. Standing removal is most common and can be done in the field with proper facilities (stocks advisable).

Laparocystotomy

Removal of stones via cystotomy under general anesthesia is considered by many to be the procedure of choice. This method allows intact stone removal, culture of the bladder wall, and removal of all stone debris. Leaving stone debris can lead to future obstruction and/or stone formation. However, bladder access is difficult in adult horses and is occasionally impossible. General anesthesia and laparotomy is also the most expensive option with the longest associated recovery period.

Laparoscopic cystotomy

This method of removal has been reported. It does require experience with laparoscopy and specialized instrumentation. The stone needs to be caught in a bag and it is difficult to close the bladder with inverting sutures that don't penetrate the lumen. Can remove stones up to 6-8cm in diameter.

Perineal urethrostomy (males)

Stone removal is performed in the standing animal under epidural anesthesia. Access to the stone is obtained through the PU. The stone is manipulated per rectum and removed via the PU using a grabbing forceps (lithotrite or other). In some instances the stone must be broken up to allow removal. Fragments of stone are often left behind and need to be flushed out to minimize the risk of stone recurrence. Trauma to the rectum, urethra, and testicles (if present) is possible.

Pararectal cystotomy (Gokel's operation)

This procedure is not often used but may be an economical approach for removing large cystic calculi. It has been recently suggested to be a useful method with lower risks than PU's. *Vet Surg 39:654-659, 2010*

Electrohydraulic lithotripsy

Lithotripsy is performed via a PU. The bladder is emptied and the calculus identified via cystoscopy. The lithotripsy probe or lithotrite is passed into the bladder via the urethrostomy and electrical current applied to fragment calculus. The pieces of calculus are removed manually or by lavage. Regular shockwave machines have also been used to do lithotripsy (special handpiece) *Laser treatment*

Pulsed dye or "stone-buster" lasers are used to vaporize stones and allow them to be flushed out. The laser is inserted via a PU. The laser creates a plasma layer at the surface of the stone and the stone disintegrates. These lasers require a fluid medium to work and this can be tiresome in the standing horse (takes a lot of time just to maintain a fluid bath). Lasers can be rented from human hospitals or laser supply organizations. Not much advantage over standing procedures. (Holmium : YAG lasers are cheaper— \$500/day vs \$1500/day—and work in people but don't work on many equine stones. These work via a photothermal mechanism.)

Manual removal ± sphincterotomy (females)

Mares aren't as prone to stones but they do occur. Most can be removed standing.

Method :

- gradually dilate sphincter by inserting one finger, then two, etc
- if need more room, incise sphincter on dorsal and cranial aspect by inserting a blade into the urethra and cutting from inside the urethra out into the vestibule/vagina

- grab stone with lithotrite, using hand in rectum to manipulate stone
- may need to crush large calculi prior to removal
- follow with copious lavage (can use endoscope to see if all debris removed)
- close sphincter (if cut) with monofilament absorbable suture material

Sabulous urolithiasis

These are poorly responsive to medical or surgical treatment; usually due to abnormal bladder emptying

Urethral calculi

Urethral calculi are frequently associated with bladder rupture unless a PU is performed. Frequently stones are in the proximal urethra and removal is as for a bladder stone. Distal stones may be removed with a similar incision over the stone or just proximal to it. The procedure is performed under GA in dorsal recumbency. A tourniquet may be applied to assist with hemostasis with penile stones. The incision is made in through the CSP into the urethra (identified by a urinary catheter). Grasping forceps are used to remove the stone. The surgery site is closed with 3-0 absorbable suture if in the sheath due to the risk of adhesion formation. Other sites may be best left open due to tissue trauma and contamination.

Nephroliths

Removal of nephroliths can be performed via nephrectomy or nephrotomy but is uncommon (not usually clinical problem until hydronephrosis and renal failure). Percutaneous removal has been reported in people. Using fluoroscopy or ultrasonography, a needle is placed through the flank into the kidney. A small guidewire is placed through the needle. The tract is progressively dilated to 24Fr to accommodate a nephroscope. Smaller calculi are removed using forceps or a basket. Larger calculi are fragmented using lithotripsy. The nephrostomy tube is left in place for 3 days.

Ureteral calculi

Ureteral calculi are rare and can cause intensive pain. They may be palpable per rectum just cranial to the brim of the pelvis. Most horses will have renal failure at the time of diagnosis. Pyelography, ultrasound, endoscopy (go up the ureter) or scintigraphy can be useful in the diagnosis. Surgical removal can be performed via a paralumbar incision. An alternative is to pass a Dormia basket stone dislodger retrograde from the ureteral orifice. The dislodger is guided by digital palpation into the ureteral orifice and then guided beyond the calculus by a second person palpating per rectum. The basket is opened and retracted to snare the stone. Slow gentle traction is used for removal.

Management for recurrence

Once a stone former, always a stone former”

- recommend biannual examinations to check for stones
- stones are much easier to remove if small and “immature” (not fully calcified)
- it is easiest to detect stones with an empty bladder (catheterize bladder if necessary)
- combine rectal palpation/ ultrasound
- should ultrasound kidneys if cystic calculi found (may not treat nephroliths but can detect hydronephrosis)
- increase water consumption and urine output
- feed salt (cattle fed salt at 1-2% of ration decreases incidence of stones)
- decrease calcium in diet
- acidifying diets may help dissolve or prevent stones
 - it has been extremely difficult to acidify urine in herbivores
 - acidic urine may not affect formation of stones in horses (unknown)
 - ascorbic acid = oral Vit C; 4000 mg po q12h
 - potassium magnesium aspartate 2500 mg po q 12h
 - latest : DCAB diets may help – SoyChlor is a ruminant feed additive that does acidify urine in horses
 - *we don't know the effects of this diet on equine bone yet but the diet is used to stimulate osteoporosis in sheep*
 - *appears to increase excretion of calcium so probably NOT a good idea in horses*

Exercise 5



An interactive or media element has been excluded from this version of the text. You can view it online here:
<https://open.lib.umn.edu/largeanimalsurgery/?p=2404>

FA youngstock processing

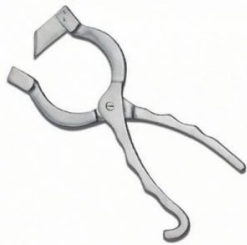This section discusses the surgical components involved with youngstock processing in food animal species.

Bovine castration

Overview

Calves can be castrated at any age but are typically castrated within the first week to first few months of life. Newborn calves are easier to restrain and handle and experience less bleeding and infection. Production parameters (weight gain) are also minimally affected in the younger calves.

Generally producers and owners castrate their calves. Rarely would a vet be called to perform routine castration but vets may be asked to train new owners or to work with rescue groups. General types of castrations and tools are bloodless (burdizzos, banding) or open (blades).



Newbury knife

Open castration is more common in northern climates and in colder weather. Fly control is necessary. A scalpel blade may be used to remove the bottom third of the scrotum (after pushing the testicles up) or a special knife (Newbury knife; left) can be used to open the scrotum down both sides using a guarded blade for extra safety.

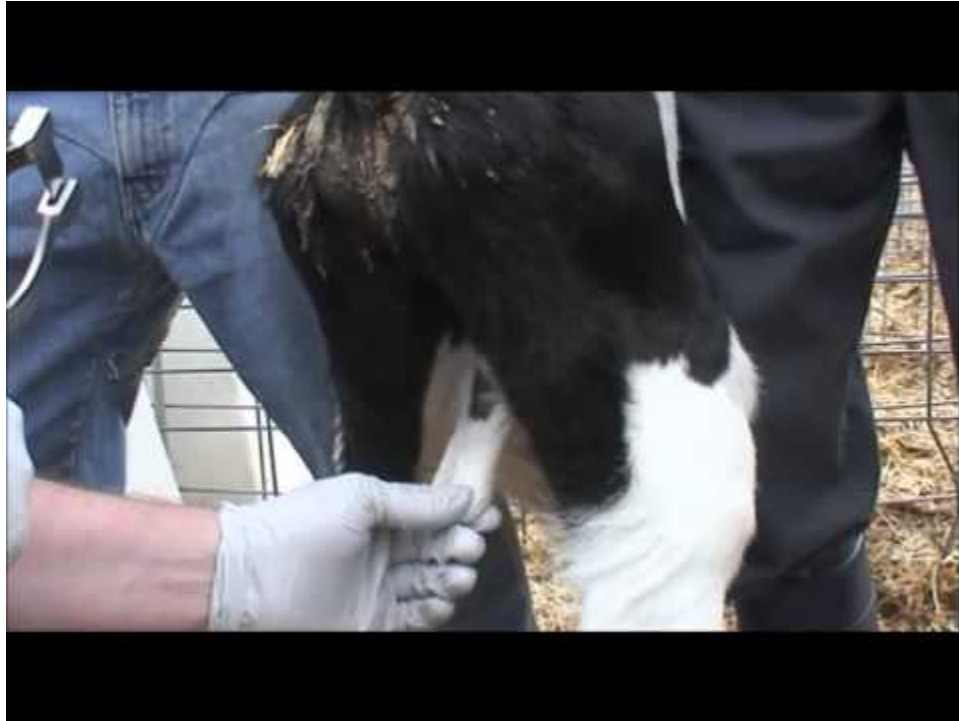Once the testicles are exposed, they may be removed by pulling the cord apart (hold the proximal end well) or by using tools. With the pull method, the trauma causes vascular spasm and vessel clotting. This works best in young animals (<3 mo old) with smaller cords (and arteries). Twisting or tearing of vessels stimulates the clotting cascade; cutting doesn't.

The Henderson tool was developed in cattle and twists the cord to create trauma (releases clotting factors) and hemostasis.

Emasculators or ligatures can also be used in large animals.



Henderson tool



A YouTube element has been excluded from this version of the text. You can view it online here: <https://open.lib.umn.edu/largeanimalsurgery/?p=1160>

Castration with Henderson tool



A YouTube element has been excluded from this version of the text. You can view it online here: <https://open.lib.umn.edu/largeanimalsurgery/?p=1160>



A YouTube element has been excluded from this version of the text. You can view it online here: <https://open.lib.umn.edu/largeanimalsurgery/?p=1160>

Bloodless castration is created by crushing the cord vessels, leading to ischemic necrosis of the testicle and skin.

Banding. An elastrator tool is used to stretch the rubber rings so they can be passed over the scrotum and released on the cord. The scrotum and testicles fall off in 30-40 days. Elastrator bands can lead to tetanus and seem to have the most significant effects on the calves (pain or discomfort). They should not be used on older calves as the crush may not be sufficient. It is also easy to miss a testicle that slides up and out of the way, leading to incomplete castration. The Callicrate bander operates on similar principles to the elastrator tool but can be used on adult bulls.



Jeffers Band Castration Tool



A YouTube element has been excluded from this version of the text. You can view it online here: <https://open.lib.umn.edu/largeanimalsurgery/?p=1160>



Callicrate bander kit

Burdizzo. The Burdizzo emasculatome also crushes the cord without cutting the skin. With this technique, the testicles atrophy but the scrotum does not slough. The clamp is placed on each cord individually and at different levels. The crush should be held for ~10 seconds. The staggered crush saves blood supply to the skin while still damaging the cord to each testicle. The Burdizzo is used on calves with slightly larger cords that can be readily palpated.



Burdizzo

[Cowsmopolitan ad](#)

Analgesia and anesthesia

Local anesthesia using lidocaine (testicular, cord blocks or epidurals) mitigates the distress of the procedure but does not prevent the cortisol response or postoperative behavior changes. Preoperative NSAIDs improve the cortisol response but are not sufficient pain control for the procedure. The combination is ideal. Meloxicam added to the milk ration at least 3 hours prior to castration makes a noticeable difference. If the procedures are to be done early in the morning, the drug can be given the night before. Cattle are not super sensitive to lidocaine (high dose 8 mg/kg) but younger animals are less able to metabolize it so some caution with larger volumes is warranted.

Testicular block



A YouTube element has been excluded from this version of the text. You can view it online here: <https://open.lib.umn.edu/largeanimalsurgery/?p=1160>

Key Takeaways

Bovine castration is best done in young animals with preoperative analgesia (NSAID) and local blocks
Open (surgical) or closed (crushing) methods may be used, with the recommended techniques varying by age.

Resources

Miesner and Anderson. [Surgical Management of Common Disorders of Feedlot Calves](#). Vet Clin Food Anim 31 (2015) 407–424

JF Coetzee. [Assessment and Management of Pain Associated with Castration in Cattle](#). Vet Clin Food Anim 29 (2013) 75–101

JM Ewoldt. [Surgery of the scrotum](#), Vet Clin Food Anim 24 (2008):253–266

[Castration of calves fact sheet](#), Ontario 2007 and [Castrating beef calves](#), UTenn – useful for age ranges and complications

390 Large Animal Surgery

Barrell/Knauer [Yak intratesticular block](#)

Small ruminant castration

For castration, small ruminants are essentially small calves. The same techniques apply

- surgical
 - blade to open the scrotum with testicle removal by traction, emasculator, or ligature
- bloodless
 - Bander/rubber bands – considered the most painful and may be inhumane in older goat kids
 - Burdizzos- stagger crushes to avoid the same issues seen with banders
 - Callicrate bander – for older goats
 - Short scrotum method – the scrotum is banded, leaving the testicles in place but pushed close to the body

Goats are very sensitive to pain so it is essential to provide sedation and analgesia. Goats are also very sensitive to lidocaine. A maximum dose of 4 mg/kg is recommended. The lidocaine can be diluted to make the small volume go further; this does result in a shorter duration of action. Hint : Lidocaine is 2% or 20 mg/ml. Preoperative NSAID options include flunixin meglumine iv or meloxicam orally. Sedative options include xylazine or detomidine (careful with xylazine dosing and avoid these drugs in sheep) or diazepam/ketamine.

Goats are also prone to tetanus so should receive tetanus vaccination.

Many goats are disbudded and castrated in the first week of life. Pet goats might benefit from more growth prior to castration, particularly in case it helps urethral diameter.

How to castrate a goat



A YouTube element has been excluded from this version of the text. You can view it online here: <https://open.lib.umn.edu/largeanimalsurgery/?p=2147>

Key Takeaways

Small ruminants may be castrated by surgical or crushing techniques; banding is not ideal and is being gradually replaced by the short scrotum method in other countries.

Goats need preop analgesia and local blocks; sedatives can be helpful. Be careful with xylazine in sheep.

Small ruminants are sensitive to lidocaine; careful dosing is essential.

All small ruminants need tetanus vaccination.

[Small Ruminant Castration Guide](#) – includes other resources

[The short scrotum method of castration in lambs: a review](#)

Piglet castration

In the USA, pigs are castrated at a young age to avoid boar taint, a slight odor/taste to meat. In Europe, many food buyers will not buy castrated pigs but they sell pigs at a younger age/lighter weight and are more used to the flavor difference.

Piglets are almost always castrated using an open technique and using traction to remove the testicle.

The same reasons for early castration of calves also apply to pigs: castrate young animals for easier restraint and handling, fewer complications and minimal impact on pig weight gain, etc. Piglets are generally castrated 4-14 days of age. This avoids the first few days when they are absorbing colostrum, makes it easier to identify inguinal hernias, and is still well before weaning. Piglets should be castrated at least 5 days prior to weaning to minimize the risk of combined stressors.

The industry standard is changing to encourage local anesthesia as part of pig castration. Lidocaine can be administered intra-testicularly. Adult pigs are NOT very sensitive to lidocaine with a high dose of 8 mg/kg but neonates will be more sensitive. Meloxicam is secreted through the sows milk so feeding meloxicam to the sow at least 3 hours prior to castration would add analgesia and prevent windup.

[Piglet castration steps](#). VA Cooperative Extension:

Castration Method for One Person Using a Surgical Knife (adapted from PIH 01-01-07)

1.	Hold the piglet by both hind legs with its head down.
2.	Using the thumb, push up on both testicles.
3.	Make an incision through the skin of the scrotum over each testicle in the direction of the tail.
4.	Be sure the incisions are made low on the scrotal sac to allow for fluid drainage.
5.	It does not matter if you cut through the white membrane of each testicle or not.
6.	Pop the testicles through each incision and pull on them slightly.
7.	Pull each testicle out while pressing your thumb against the piglet's pelvis.
8.	Thumb pressure on the pelvis is important to ensure that the testicular cords break off at the point of your thumb rather than deep inside the body, which may promote development of a hernia.
9.	If necessary the testicle may be cut free of the cord using a scraping motion.
10.	Cut away any cord or connective tissue protruding from the incision and spray the wound with antiseptic.



A YouTube element has been excluded from this version of the text. You can view it online here: <https://open.lib.umn.edu/largeanimalsurgery/?p=2149>

Key Takeaways

Piglets should be castrated at a young age, using analgesics and local anesthesia

Pigs are prone to inguinal hernias; waiting until at least 4 days of age enhances identification of problem pigs.

Resources

Bates et al. [Impact of Transmammary-Delivered Meloxicam on Biomarkers of Pain and Distress in Piglets after Castration and Tail Docking](#)-2014, PLoS One

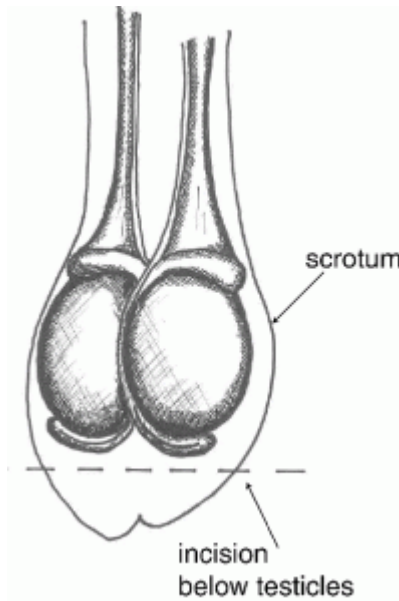
JF Coetzee et al. [Transmammary delivery of firocoxib to piglets reduces stress and improves average daily gain after castration, tail docking, and teeth clipping](#). *Journal of Animal Science*, Volume 97, Issue 7, July 2019, Pages 2750–2768,

How to - Open castration

Indications

Calf, lamb and piglet castration is typically performed on farm by the producer or an employee. However, many goat owners would prefer a veterinarian castrate their pets and more farm animal rescues are in need of assistance.

Relevant anatomy



Preoperative management

Food restrictions: NA

NSAIDs/analgesics: NSAIDs should be given preoperatively. For young calves, meloxicam added to the milk ration 3 hours prior to the procedure provides analgesia.

Antibiotics: NA

Tetanus prophylaxis is recommended.

Local blocks: Cord block, testicular block or epidural.

Position/preparation: Standing or recumbent. Goats should be sedated for the procedure.

Surgery Supplies:

- Scalpel blade or Newbury knife
- Emasculators (depending on age)
- Suture 0 absorbable (depending on age)

Surgical procedure

The testicles are pushed toward the body and the distal third of the scrotum removed with a sharp incision. The testicles should drop out of the scrotum. Depending on the age of the animal, the cords can be pulled (creating hemostasis by traumatizing the vessel), emasculated or ligated and transected

Postoperative care

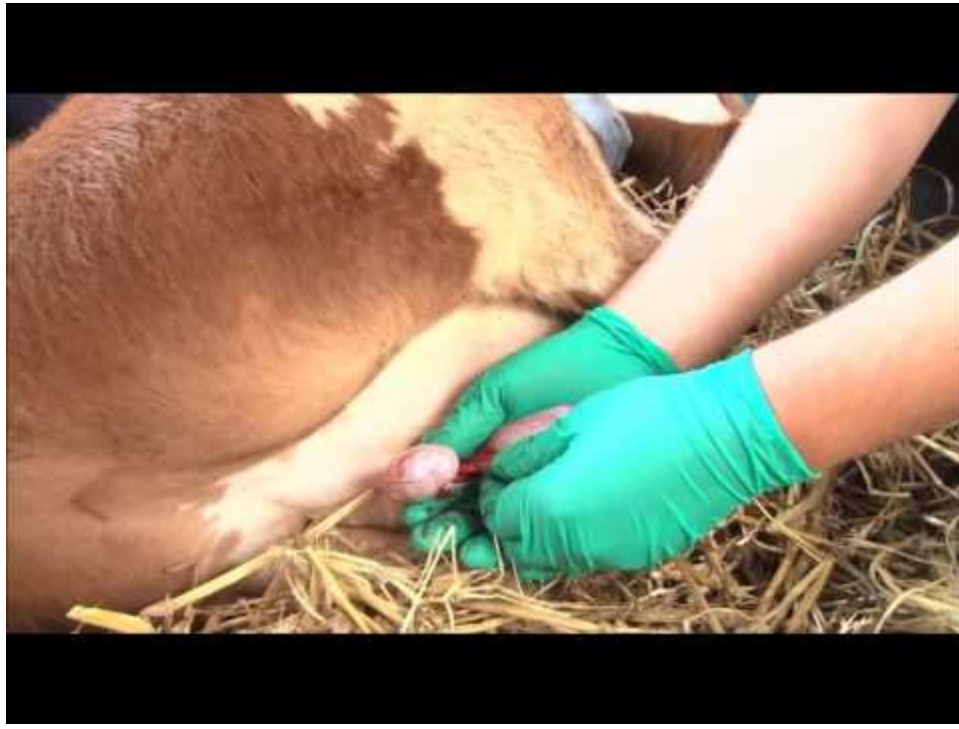- NSAIDs should be continued for 1-3 days to optimize recovery
- Monitor for incisional issues (infection, evisceration) and animals going off feed

Complications

Evisceration (rare)

Infection (rare)

Videos



A YouTube element has been excluded from this version of the text. You can view it online here: <https://open.lib.umn.edu/largeanimalsurgery/?p=3125>



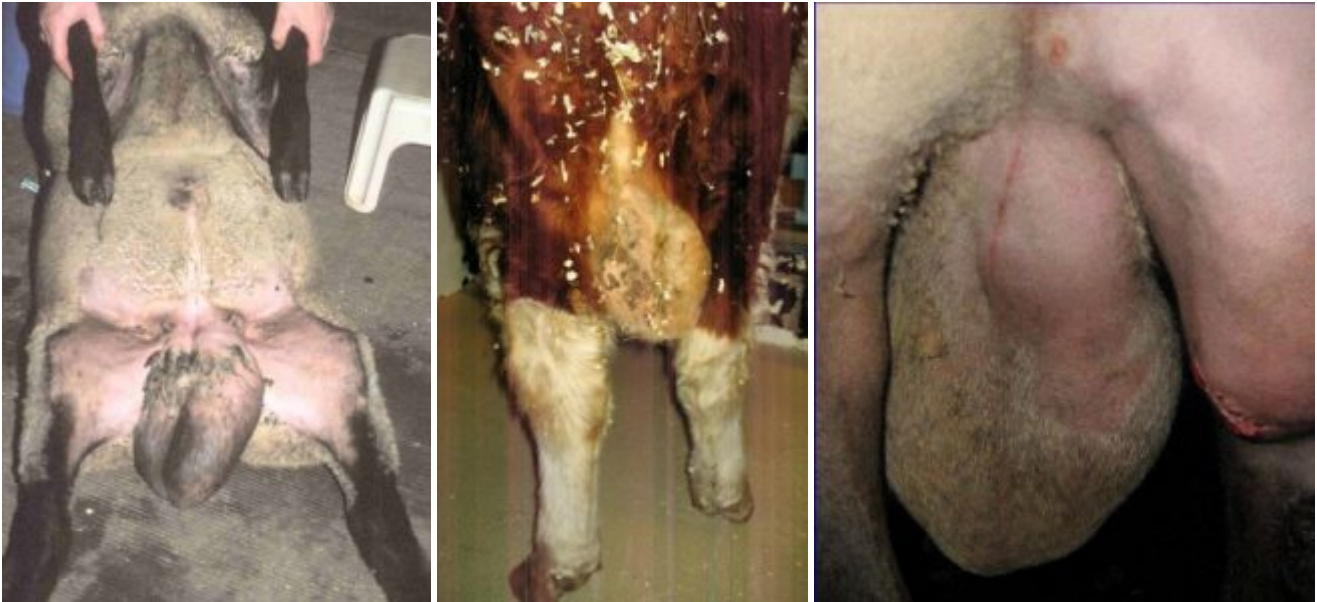A YouTube element has been excluded from this version of the text. You can view it online here: <https://open.lib.umn.edu/largeanimalsurgery/?p=3125>

Resources

[Castration of calves](#)

FA Inguinal Hernias

Unlike in adult stallions, inguinal hernias tend to be an incidental finding in ruminants and swine (including pot bellied pigs) of all ages. Most cases do not cause strangulation of the intestines and are not emergencies. If you see an enlarged scrotal neck, you should immediately put inguinal hernia at the top of the differential list. Other findings would include a soft, reducible, non painful swelling and intestines entering the inguinal ring on rectal examination. Ultrasound can be used to confirm if needed.

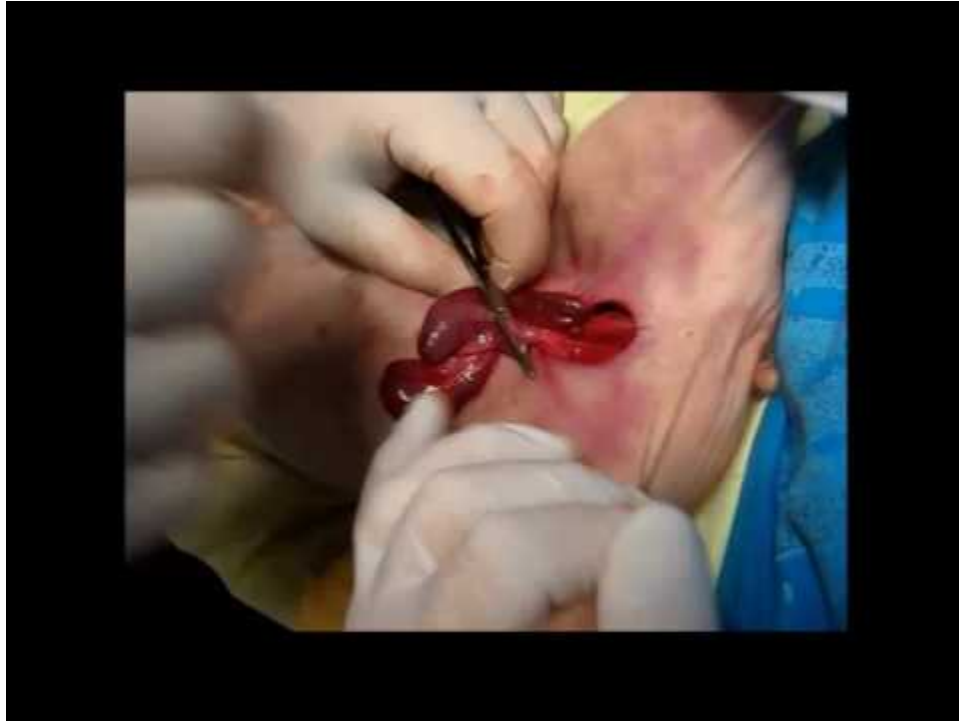

Inguinal hernias in youngstock are considered heritable in most species. Herefords and pigs are particularly prone. Animals should be castrated or not used for breeding. Inguinal hernias in bulls and rams are potentially acquired. While some consider these hernias a delayed manifestation of an inherited issue, others claim the inguinal ring is “stretched” by right lateral recumbency and the growth of a fat pad in the region. Inguinal hernias can be found in females and castrated males but uncommonly.

The biggest concern is for evisceration at the time of castration.

Castration and hernia repair

In young animals, castration is performed with the animal in dorsal recumbency and the intestines returned to the peritoneal cavity by twisting. The tunic is ligated and/or the external inguinal ring closed to minimize the risk of evisceration:



A YouTube element has been excluded from this version of the text. You can view it online here: <https://open.lib.umn.edu/largeanimalsurgery/?p=1162>

Inguinal hernia repair in adult animals is best done under heavy sedation and/or general anesthesia in a hospital setting. Hemicastration should be performed to enable tight closure of the inguinal ring. Leaving room for the testicular artery to pass through the ring also means leaving room for re-herniation.



An interactive or media element has been excluded from this version of the text. You can view it online here: <https://open.lib.umn.edu/largeanimalsurgery/?p=1162>

Key Takeaways

Inguinal hernias are considered heritable in most groups.

FA inguinal hernias are rarely emergencies.

Castration of affected animals should be performed carefully to minimize the risk of evisceration.

Resources

[Inguinal hernias in calves and bulls](#)

J Rush et al. [Theriogenology question of the month](#), 2017 JAVMA 250(4) – inguinal hernia in bull

[Surgical treatment for different hernias in sheep and goats](#), JVetSci 2007

[Bull examination and testing](#) – includes a classic image

JM Ewoldt. [Surgery of the scrotum](#), Vet Clin Food Anim 24 (2008):253–266

FA cryptorchidism

Cryptorchidism is considered an inherited tendency.

In ruminants, cryptorchidism is supposedly generally due to an ectopic testicle. See pgs 260-261 in [Surgery of the Scrotum](#), VCNA 2008. However, more reports are finding the testicles abdominally.

Cryptorchid testicles are commonly found abdominally in swine. Pigs can also have ectopic testicular tissue. To remove the cryptorchid testicle in pigs, an incision is made in the paralumbar fossa with the pig in lateral recumbency with the affected side up. The testicle is usually large and will be on a path between the kidney and the inguinal ring (the descent path).

ABSTRACT

This paper describes features of a study of different aspects of cryptorchidism in sheep in different parts of England. A total of 83 cryptorchid testes (57 unilateral and 13 bilateral) were recognised in 70 animals post-slaughter at three abattoirs in the south west of England between June 2000-January 2004. Abdominal cryptorchids (60) were common than inguinal (23); 69% percent of cases were unilateral. External examination for cryptorchidism was carried out on 5134 young male lambs carried out in 2001 at Foot and Mouth Disease disposal sites, and on farms, during the UK outbreak of the disease. A total of 29 cases of cryptorchism [0.56%] were detected; 86% of cases were unilateral. In both situations the right testis was more commonly affected than the left.

(10) (PDF) *Cryptorchidism in Sheep: A Clinical and Abattoir Survey in the United Kingdom*. Available from: https://www.researchgate.net/publication/276491292_Cryptorchidism_in_Sheep_A_Clinical_and_Abattoir_Survey_in_the_United_Kingdom [accessed Jul 15 2019].e.

Location of undescended testes differs greatly among species. For cats, dogs and horses, 50, 92 and 47-60% of retained testes were in the abdominal cavity, although 1 report for horses gave 33% abdominal (see Table 1 in Amann and Veeramachaneni, 2007). There are no reliable data for pigs, but subcutaneous locations might predominate. From [Cryptorchidism and associated problems in animals](#) R. P. Amann and D. N. R. Veeramachaneni A, Anim Reprod 20

Resources

JM Ewoldt. [Surgery of the scrotum](#), Vet Clin Food Anim 24 (2008):253–266

Scolo et al. [Pig surgery: cryptorchidectomy using an inguinal approach](#). Vet Rec 2016

SS Nair. [Ultrasound Diagnosis of Cryptorchidism in Sheep](#). Frontier J. Vet. Anim. Sci. Vol.4, No.1(Jan-June) 2015

406 Large Animal Surgery

R P Amann and D N R Veeramachaneni. [Cryptorchidism in common eutherian mammals](#). Reproduction 133(3), 2007- very thorough coverage!

[Testicular descent animation](#)

Disbudding and dehorning

Overview

AVMA's position on analgesics during dehorning



A YouTube element has been excluded from this version of the text. You can view it online here: <https://open.lib.umn.edu/largeanimalsurgery/?p=734>

Learning Objectives

Study Questions

Dehorning methods include paste, Barnes, gigli wire, and thermocautery. Are there age restrictions for any of these? If so, what is the recommended/maximum age?

How do you know if the thermocautery has damaged the tissue sufficiently?

What happens if you don't kill off all the germinal tissue when disbudding?

Why do we want to dehorn/disbud calves at a young age?
What nerves do you need to block?
You should be able to find the related local block how tos (reference for future).
What sedation could you use if needed?

Primary sources – use Ctrl F in a document below to find the answers you still need for the study guide

[Calf dehorning](#), Ontario

[Technique comparison page](#), MSU page 6

See images for [dehorning vs disbudding](#), ABBA




Figure 2. Dehorning Tools

Other notes

Sandra Baxendell (6/30/19) – uses “Buccalgesic” – a form of meloxicam designed to be absorbed through the oral mucous membranes. Lets it work for 5 min (while clipping and weighing). Then she gives 4.5 mg/kg alphaxalone slowly iv (usually 2-3 mls). That gives just enough time to disbud if the iron is already hot.

OVC has developed an easier method of local anesthesia – they inject lidocaine subcutaneously under the horn bud vs trying to find the nerves. The same effect could be obtained with a ring block around the horn.

Key Takeaways

- Disbudding should be done at a young age, using perioperative meloxicam, local blocks and/or sedation.
- Hot iron disbudding is most popular. Burn until a copper ring is achieved. Burn again if necessary.
- Scurs form if the bud is incompletely cauterized.
- Dehorning opens up the sinus and can lead to serious infections.
- Horn tipping is an option in adult cattle that are dangerous due to their horns.

Additional resources-

Miesner and Anderson. [Surgical Management of Common Disorders of Feedlot Calves](#). Vet Clin Food Anim 31 (2015) 407–424

P Aubry. [Routine Surgical Procedures in Dairy Cattle Under Field Conditions: Abomasal Surgery, Dehorning, and Tail Docking](#). Vet Clin Food Anim 21 (2005) 55–72

MN Hempstead et al. [Pain sensitivity and injury associated with three methods of disbudding goat kids: Cautery, cryosurgical and caustic paste](#). The Veterinary Journal 239 (2018) 42–47

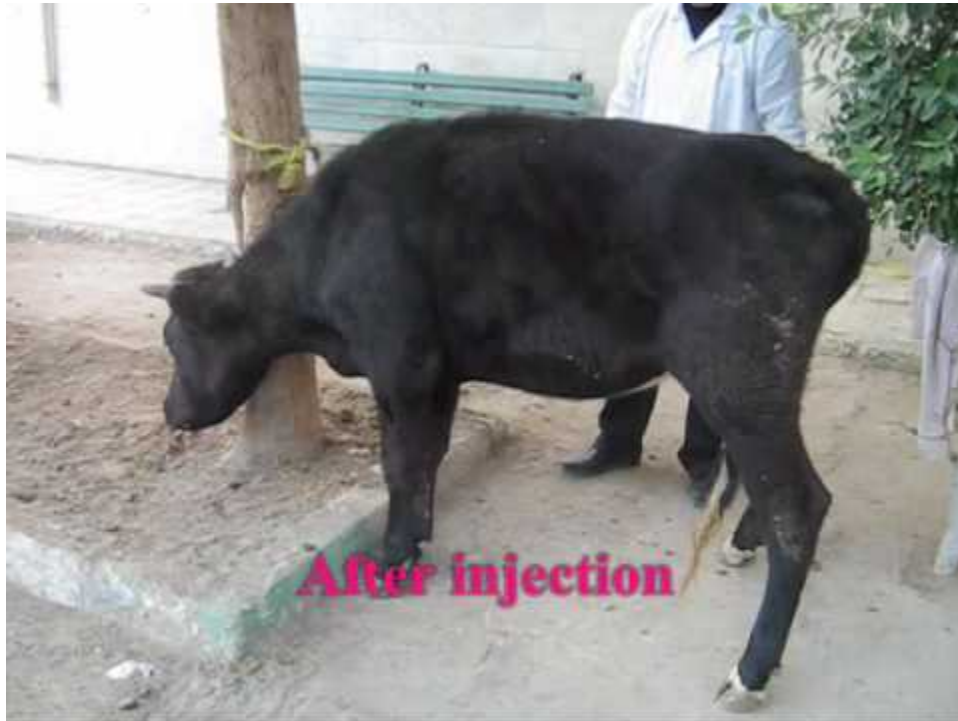CD Neely et al. [Effects of three dehorning techniques on behavior and wound healing in feedlot cattle](#). J. Anim. Sci. 2014.92:2225–2229

Dehorning on CCHP rotation



A YouTube element has been excluded from this version of the text. You can view it online here: <https://open.lib.umn.edu/largeanimalsurgery/?p=734>

Xylazine sedation



A YouTube element has been excluded from this version of the text. You can view it online here: <https://open.lib.umn.edu/largeanimalsurgery/?p=734>

Barrell/Knauer [dehorning block](#) and bovine sx [dehorning block](#)

Dehorning block using lidocaine + xylazine



A YouTube element has been excluded from this version of the text. You can view it online here: <https://open.lib.umn.edu/largeanimalsurgery/?p=734>

Tail docks

Tail docking is routinely done in lambs (to avoid painful fly strike), piglets (to avoid tail biting by other pigs) and less commonly in cattle (for cleanliness to cow, milk and producer). Tail docking may also be performed to treat tail trauma.

Cow tail docking is usually performed by the producer using castration rings. The tail is banded 7-8 cm below the vulva in calves, usually at the time of dehorning. The practice is going out of favor due to lack of evidence that it improves cleanliness and due to concerns of pain, altered social communication and impact on fly control. When the tail is traumatized, tail docking can be performed surgically in a similar manner to small animal tail docks.

Sheep tail docking can be performed by rubber ring banding, banding combined with crushing (emasculatome), or hot blade. Most lambs are docked between 1-3 weeks of age. Local anesthesia does help and oral meloxicam would be reasonable. The AVMA has reviewed the practice and recommends:

“The Farm Animal Welfare Council (FAWC) recommends that docking should be avoided whenever possible.²² The FAWC also concluded that tail docking of lambs up to 7 days old is best done with a rubber ring; that lambs between the ages of 1 and 8 weeks old should be docked with a docking iron (hot blade) or a clamp; and that acute pain of tail docking can be alleviated using locally applied anesthetics.¹⁸ “

<https://www.avma.org/KB/Resources/LiteratureReviews/Pages/Welfare-Implications-of-Tail-Docking-of-Lambs.aspx>



The band is well distal to the caudal aspect of the tail folds

If tails are docked too short, lambs are at increased risk of rectal prolapse. The tail should be long enough to maintain the full length of the caudal tail folds. These folds help move feces away from the perineal region. Other reasonable measures include 3 vertebrae and/or long enough to cover the vulva.

Pigs tend to bite each others tails. Once tail biting begins it continues and can even escalate. This can be minimized by shortening the tails. Tail docking is usually done by [hot iron](#) in pigs less than 7 days old. It is commonly combined with teeth clipping. The AVMA is reviewing this practice as well:

“Tail docking is performed to reduce tail biting and cannibalism among pigs. Tail docking should be performed early and sufficiently prior to weaning such that no open wounds remain at the time of weaning. Clean, sharp equipment must be used to minimize pain and risk of infection. “

<https://www.avma.org/KB/Policies/Pages/Tail-Docking-and-Teeth-Clipping-of-Swine.aspx>

Resources

P Aubry. [Routine Surgical Procedures in Dairy Cattle Under Field Conditions: Abomasal Surgery, Dehorning, and Tail Docking](#). Vet Clin Food Anim 21 (2005) 55–72

C Stull. [Welfare concerns: Tail docking of sheep](#). UCDavis- also goes through techniques

Li and Johnston UMN Extension –[Research reaffirms the need for tail docking for pigs](#). 2016

How to - Tail Dock - Adult

Indications

Tail docking in adult animals should be restricted to cases of trauma or infection.

Relevant anatomy

The tail is comprised of vertebrae, vertebral spaces, coccygeal muscles and vessels on either side. Disarticulation should be between vertebrae.

Preoperative management

Food restrictions:NA

NSAIDs/analgesics: Perioperative NSAIDs are recommended

Antibiotics: NA

Tetanus prophylaxis is recommended in horses

Local blocks: [Epidural or ring block](#)

Position/preparation: The patient is kept standing. Surgeon wears gloves. The area is clipped and prepped.

Surgery Supplies:

- Scalpel and handle
- Mosquito hemostats
- Mayo scissors
- Needle holders
- Suture scissors
- 3-0 absorbable (vessels)
- 2-0 or 0 suture, cutting needle (skin)
- Tourniquet – optional

Surgical procedure

A tourniquet may be applied proximally but usually isn't necessary.

The appropriate vertebral space is identified. Semilunar skin incisions are made dorsally and ventrally with both flaps extending beyond the point of disarticulation. The dorsal flap should extend further than the ventral flap. The flaps are undermined and retracted cranially. The vessels are ligated with 3-0 suture and muscles transected. The coccygeal vertebrae are disarticulated. The dorsal flap is folded over the end and sutured to the ventral flap.



Postoperative care

- Keep area clean and dry.
- Suture removal in 10-14 days

Complications

Dehiscence and infection are possible. Second intention healing is recommended if either occur.

Videos

Resources

[Ch 48 Amputation](#), Cal Vet Upenn Project

Challenge yourself!



An interactive or media element has been excluded from this version of the text. You can view it online here:
<https://open.lib.umn.edu/largeanimalsurgery/?p=2198>



An interactive or media element has been excluded from this version of the text. You can view it online here:
<https://open.lib.umn.edu/largeanimalsurgery/?p=2198>



An interactive or media element has been excluded from this version of the text. You can view it online here:
<https://open.lib.umn.edu/largeanimalsurgery/?p=2198>



An interactive or media element has been excluded from this version of the text. You can view it online here:
<https://open.lib.umn.edu/largeanimalsurgery/?p=2198>



An interactive or media element has been excluded from this version of the text. You can view it online here:
<https://open.lib.umn.edu/largeanimalsurgery/?p=2198>

Eye surgery

This section provides resources on enucleations, eyelid lacerations and other eye issues in all LA species.

Ocular blocks

Local anesthesia is required, not only for standing procedures, but for any enucleation (even those performed under general anesthesia). This is due to the [oculocardiac reflex](#).

The auriculopalpebral nerve block helps with the eye examination as it numbs the eyelid muscles. It does not provide analgesia.

For upper eyelid surgery, the supraorbital nerve is blocked to provide local anesthesia. For lower eyelid surgery, it is generally easiest to perform a line or regional block.

Several options exist for local anesthesia for enucleations. I prefer a retrobulbar block using a curved needle (epidural needle works well) and ~10 cc lidocaine. The needle is inserted between the globe and the bony orbit. As it is advanced, the needle follows the curve of the orbit to the back of the eye and ocular nerve. Lidocaine is injected at the back of the eye and as the needle is withdrawn.

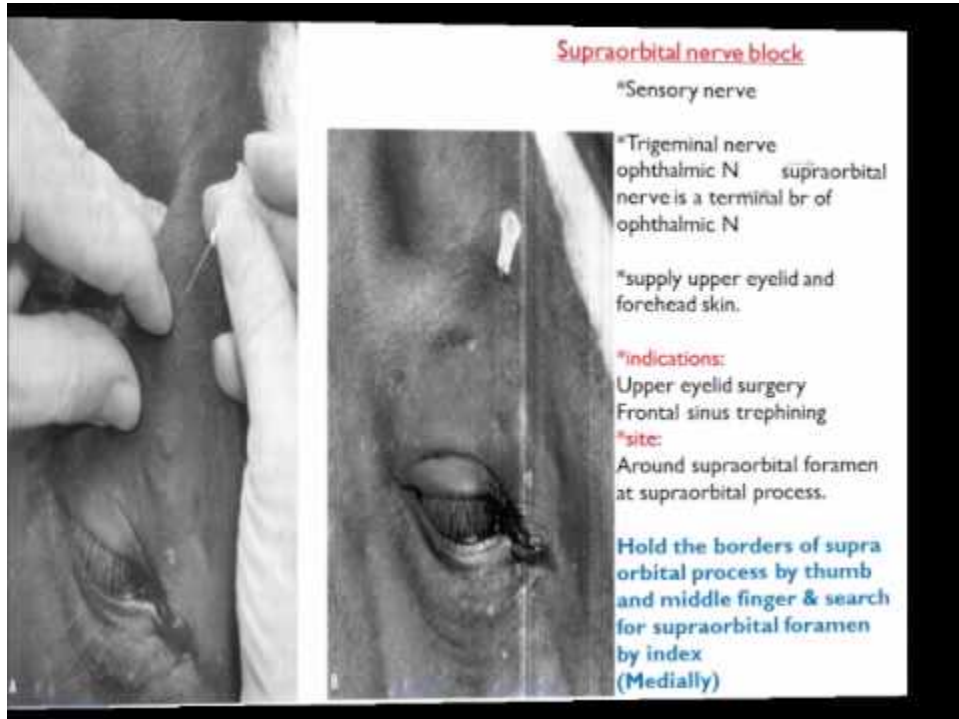
Key Takeaways

Use local blocks for all enucleations.

- Block the optic nerve to prevent the heart from stopping
- For standing procedures, block the motor function (muscles) as well as sensation

RESOURCES

Head blocks video: spelling issues but good content



A YouTube element has been excluded from this version of the text. You can view it online here: <https://open.lib.umn.edu/largeanimalsurgery/?p=750>

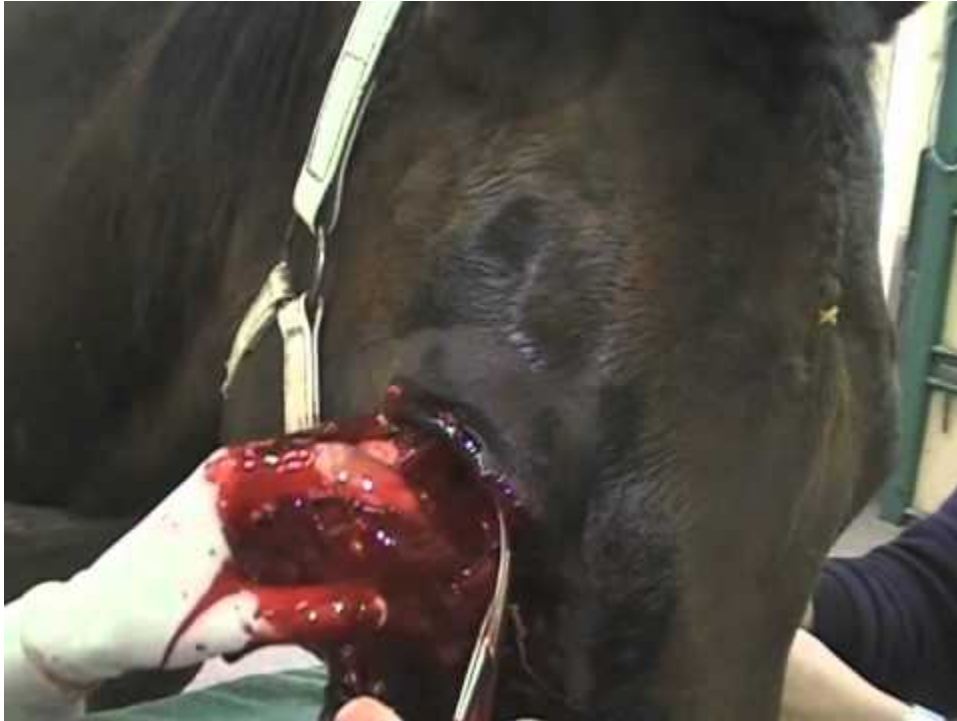[Ocular blocks](#) (and more)

[How to prepare for ocular surgery in the standing horse](#), AAEP, 2002- has pictures

[Field surgery of the eye and periorbital tissues](#), VCNA, 2008 – good for blocks and sedation

[Anesthesia Rotation moodle site](#) (enrollment key = sleepy)

These videos also show nerve blocks:



A YouTube element has been excluded from this version of the text. You can view it online here: <https://open.lib.umn.edu/largeanimalsurgery/?p=750>

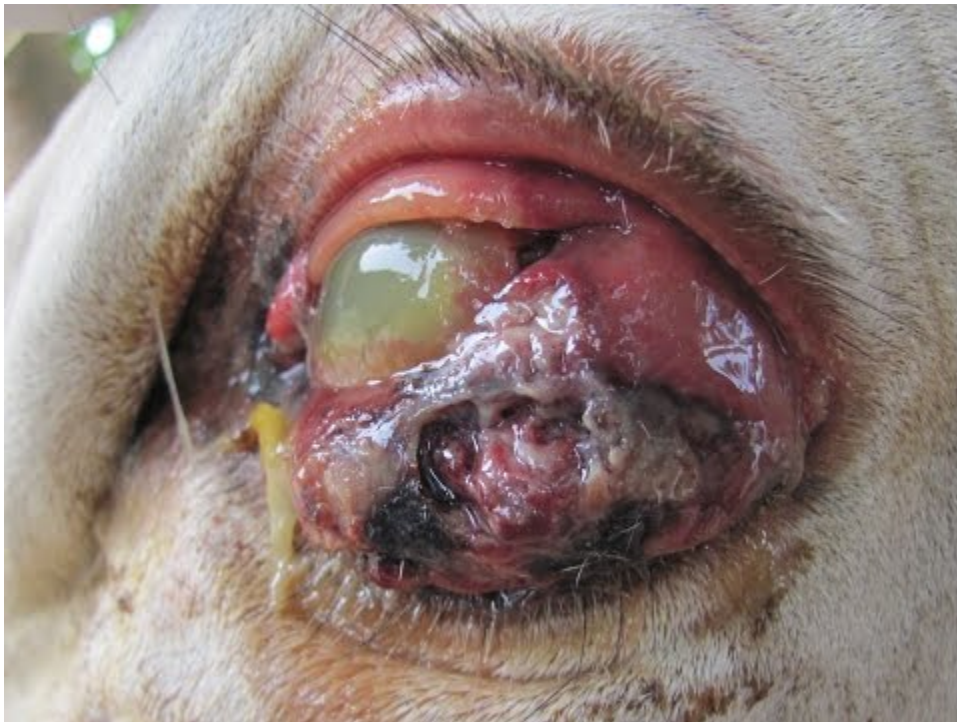Enucleations

OVERVIEW

Much of what you know about SCC in other species translates to cattle, particularly in terms of risk factors and metastatic activity. The same terms apply for eye removal surgery, as well, but we don't use them appropriately or consistently in most situations. When we talk about cattle enucleations, we generally mean exenterations.

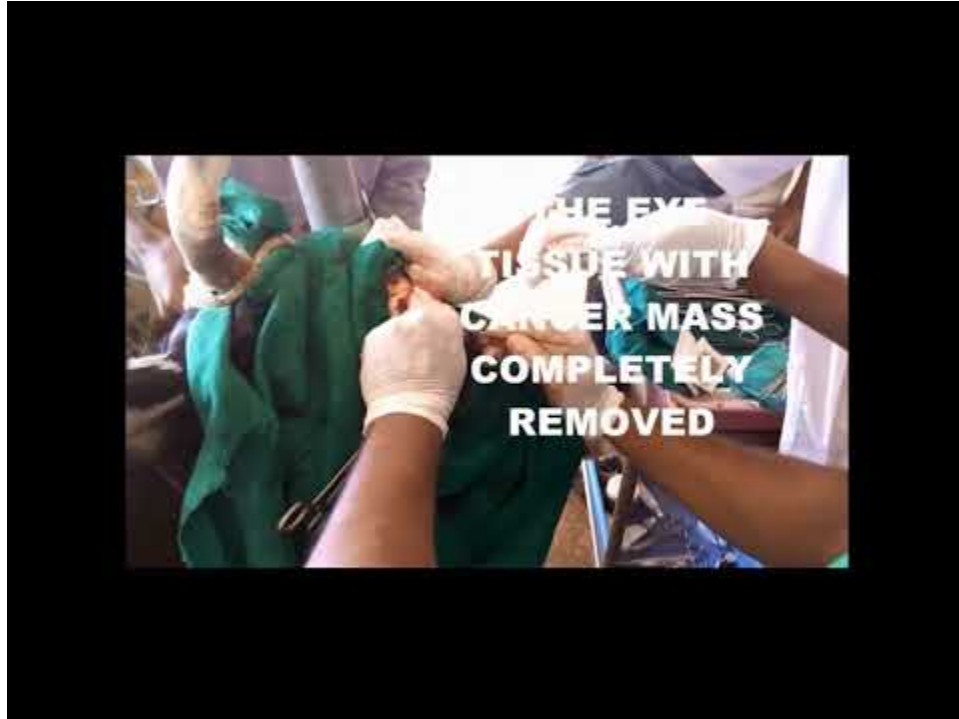One potential difference is we don't ligate the artery (with a complete bony orbit, this is hard). That means we have to control hemostasis in other ways. Cows like to clot but this is an artery. Suturing the lids closed creates a closed space. With enough bleeding, the pressure builds up and stops the arterial flow. Nice bulging eye for a bit.

Watch this video as is first to get a general idea of how ocular SCC is handled surgically in cattle:



A YouTube element has been excluded from this version of the text. You can view it online here: <https://open.lib.umn.edu/largeanimalsurgery/?p=736>

Then watch again with my comments:



A YouTube element has been excluded from this version of the text. You can view it online here: <https://open.lib.umn.edu/largeanimalsurgery/?p=736>

Learning Objectives

What breeds are prone to SCC?

Where does ocular SCC commonly start? (specific sites of the eye)

Does SCC tend to be benign, invade locally or metastasize?

What treatment options exist in cattle? Eg can you use radiation, lasers, chemotherapy, cryo?

What are the differences between enucleation, evisceration and exenteration? Note we use the terms incorrectly.

When would you recommend an exenteration over an enucleation?

What layers do you close after exenteration? What do you do if it won't close all the way?

What are the aftercare requirements for animals having an eye removed?

What are common complications of these surgeries?

What drugs would you recommend for standing sedation in cattle?

Why are local blocks considered a necessity in enucleations/exenterations, even those under GA?

What are the ramifications of ocular SCC in cattle for slaughter a) if visible at the time of slaughter b) if the eye is removed prior to slaughter?

Primary Sources- Now use these to find answers, using ctrl F. Only read the entire thing if you want to or if you need an overview again

[Bovine ocular SCC in Italy](#)– VETERINARSKI ARHIV 84 (5), 449-457, 2014- same pathogenesis applies in the US

[Eye extirpation in cattle](#), the Australian way, U Queensland, 2013

[Field surgery of the eye and periorbital tissues](#), VCNA, 2008

[Bovine enucleations : case info and complications](#) – CVJ, 2010- especially useful for finding out what complications are common

[slaughter info](#)-compilation of notes

[when to exenterate vs enucleate](#)– human version

Malone’s extra tidbit : if you see ocular SCC lesions in a gelding, check the penis for other lesions and visa versa.

Key Takeaways

- White animals are prone to SCC
- SCC tends to start on the lids or the limbus and is locally invasive but slow to metastasize
- Exenteration is what we really perform in LA; we call it enucleation
- Eye removal doesn’t usually affect slaughter options unless the lymph nodes are enlarged; a nasty eye creates more issues
- Rarely do we try to ligate the ocular artery; we close the skin fast to create pressure for hemostasis
- Complications include infection and dehiscence. Occasionally too much skin is removed and closure can be challenging.

RESOURCES

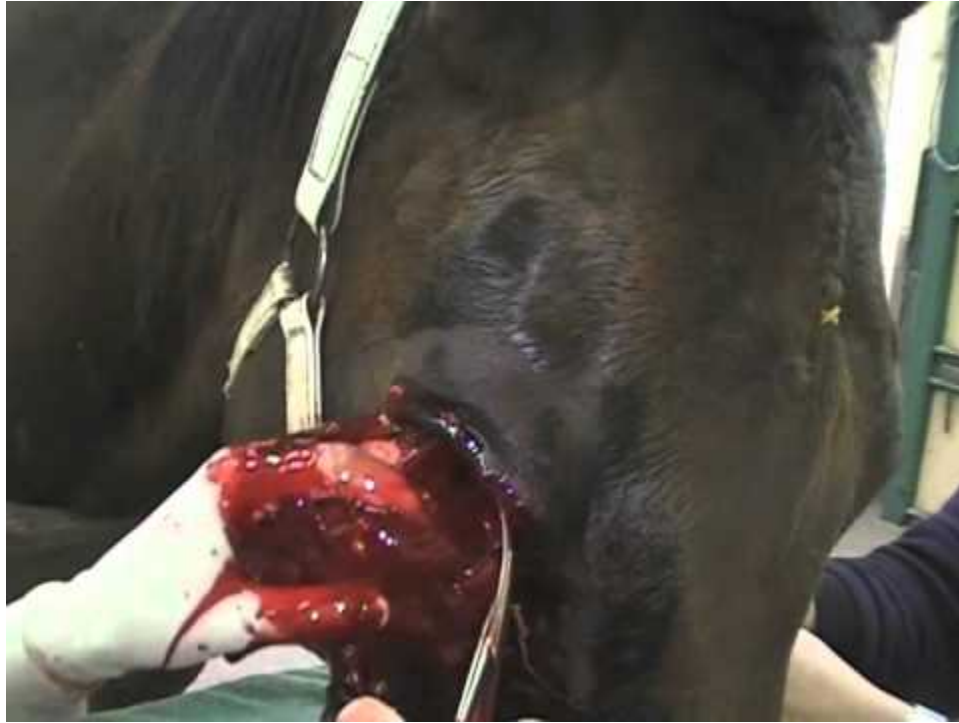[Bovine Ocular SCC](#) – VCNA,2010- skim the headings to see which parts might help you answer questions

[Ocular field surgery in ruminants](#), Intl J Vet Med, 2015- see enucleation surgery blocks and techniques;. also discusses SCC risks

[Bovine welfare issues – eye disorders](#), 2010 VCNA

[Surgical treatment of the eye in farm animals](#), 2010 VCNA pgs 460-462, 471-end- has a bit more about exenteration vs enucleation how to

More videos



A YouTube element has been excluded from this version of the text. You can view it online here: <https://open.lib.umn.edu/largeanimalsurgery/?p=736>

How to - Exenteration

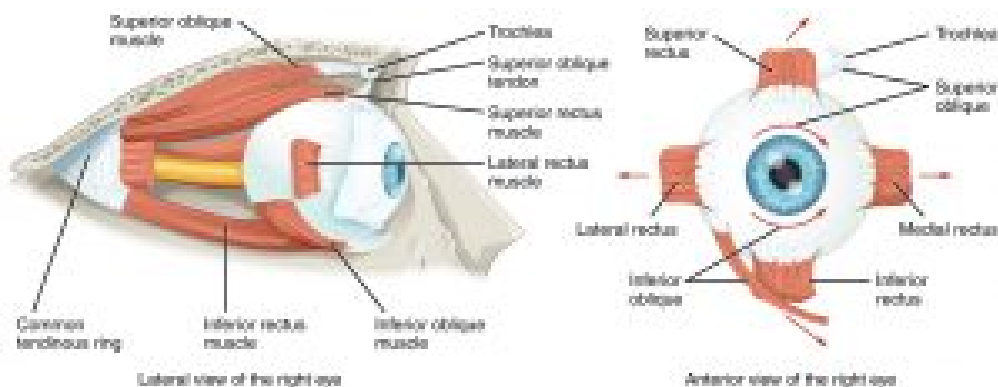
Indications

Eyes may be removed due to trauma, infection, neoplasia or pain (ulcers, glaucoma, uveitis). Enucleation may be the quickest way to a comfortable animal and can decrease the risk of spread of tumors or aggressive infections.

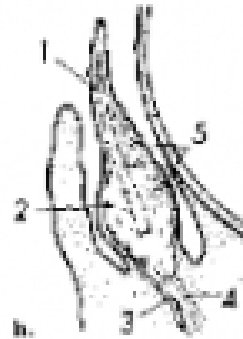
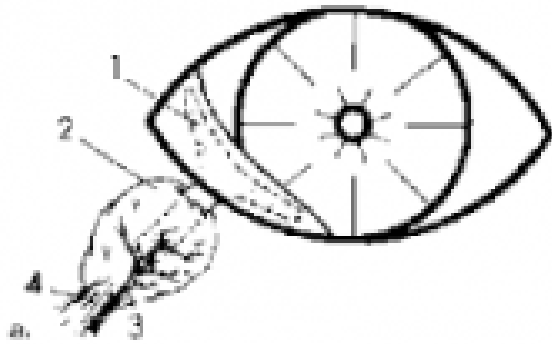
Relevant anatomy

The optic nerve should be blocked with local anesthetic prior to surgery, even with animals under general anesthesia. The optic nerve can be accessed in a variety of methods. See [Ocular blocks](#).

Cattle have a deep bony orbit; horses have a complete bony orbit as well but it is wider so easier to access caudal structures. The ocular artery and optic nerve are at the back of the globe in the center of the orbit. The remainder consists primarily of extraocular muscles and the third eyelid.



The third eyelid and its gland should be removed or the animal will continue to produce tears.



Preoperative management

Enucleation can be performed standing in many horses and cattle. This increases the safety by decreasing the likelihood of extensive hemorrhage and the risks of anesthesia and recovery. In small ruminants, sedation is typically needed. General anesthesia may be needed in some horses with extensive SCC to enable more cosmetic reconstruction.

Food restrictions:

NA unless general anesthesia is indicated.

NSAIDs/analgesics:

Preoperative and postoperative analgesics are required.

Antibiotics:

As the eye is not a sterile environment, preoperative and postoperative antibiotics are indicated. Broad spectrum coverage is indicated but first line drugs are fine (penicillin + gentamicin (equine), cephalosporin, ampicillin).

Tetanus prophylaxis is recommended.

Local blocks:

Options to block the ocular nerve include various forms of retrobulbar block including the Peterson nerve block. All are effective if performed correctly. If blocked, the pupil should dilate.

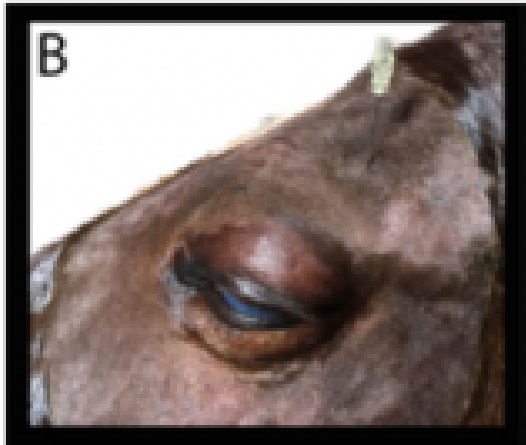

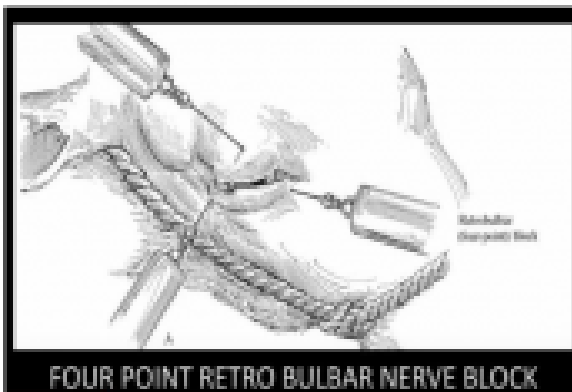
Figure 76. The location of the retrobulbar nerve block using a thin spinal needle placed against the rim of the appagmatic bone in the supraorbital pouch and advanced until a "pop" is felt as the needle penetrates through the fascia of the optic cone.

<http://veterinarynews.dvm360.com/guide-regional-analgesia-head-equine-patients?pageID=5>



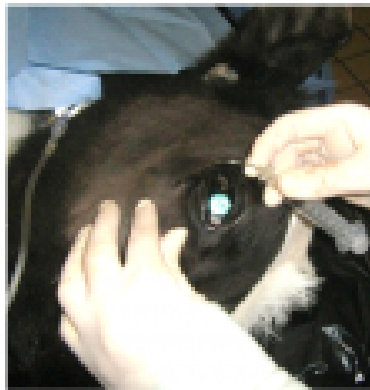
Peterson nerve block

<https://www.vetstream.com/treat/bovis/technique/peterson-block>



FOUR POINT RETRO BULBAR NERVE BLOCK

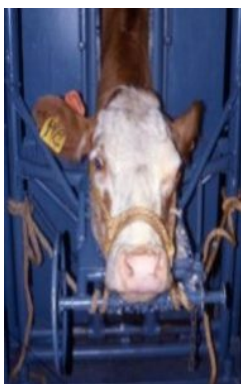20 ga needle, straight in, 5-10cc/site



Curved needle, retrobulbar block

Curve a catheter or spinal needle, insert until it reaches the other side of the orbit, flush 20 cc in adult animal

Position/preparation:



The animal is positioned in stocks or head gate (standing sedation) or in lateral recumbency with the affected eye uppermost. A head tray or dental halter can help hold the head still and at a reasonable level. The eye is clipped and prepped.

Surgery Supplies:

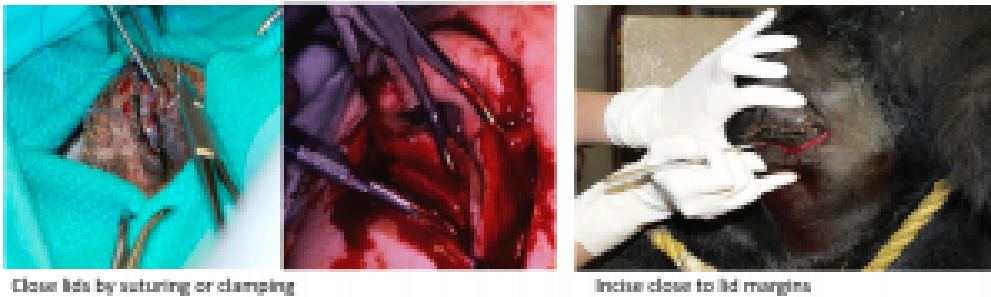- Surgery pack
- Scalpel and handle
- Right angle hemostats (optional)

- Ecraseur (equine only)
- 2-0 or 0 suture on a cutting needle to close the lids
- 0 monofilament absorbable for the artery
- 0 suture on a cutting needle for the skin closure

Surgical procedure


The eyelids are sutured closed. The ends of the suture tags are left long as handles. Alternatively, towel clamps can be placed at each canthus. Towel clamps or allis tissue forceps are useful as they hold themselves closed; this is much easier on the surgeon as compared to holding tissue forceps closed.

A fusiform incision is made around the eyelids, pointy ends at the canthi, staying close to the lid margin. ** Incisions too far away from the lid margin can be challenging to close.**



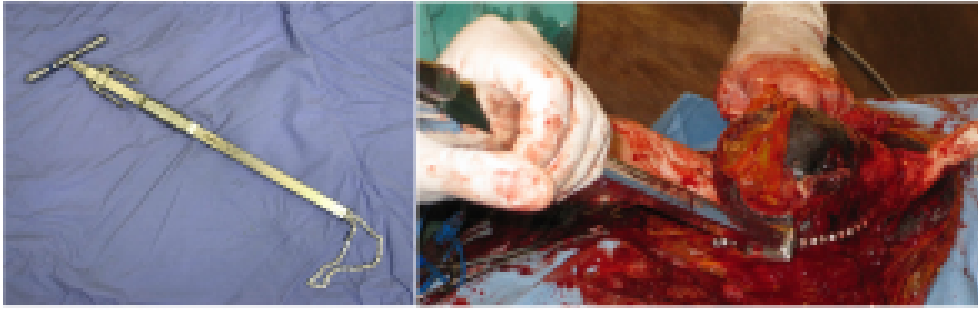Continue dissection through the retrobulbar tissues using mayo scissors (scalpel dissection may be needed at the canthi). Whenever possible, use scissors instead of a scalpel. The tissue trauma associated with scissors activates the clotting cascade and bleeding is lessened.

Work around the full circumference, moving deeper with each pass. Cut anything in your way. Digital palpation helps identify what needs to be cut.



If the dissection exposes the globe, ensure you also remove the third eyelid and gland. This will come out naturally if the globe is not exposed.

Once the only structures left are at the caudal aspect of the eye, prepare your suture for closure. Typically we do not clamp the artery in large animal species. In horses, an ecraseur can be used to crush and sever the artery. This does not work in cattle due to the anatomy of the orbit. In cattle, cut the artery with scissors.



Closure: Trim the eyelid margins and close the lids in a simple continuous pattern with 0 suture material. The needle on 2-0 suture material makes it difficult to be efficient.

Postoperative care

- Antibiotics are often continued for 5 days; NSAIDs are continued for 3 days.
- Monitor the incision for any signs of inflammation or infection. Sutures can be removed to allow drainage if necessary
- Prevent the animal from rubbing the area. Fly masks work well.
- Suture removal in 10-14 days

Complications

Contamination

If the skin should not be closed due to contamination and risk of infection, the socket can be packed with betadine soaked gauze and closed partially. The partial closure and packing will put enough pressure on the artery to create hemostasis. The packing can be removed gradually over the next few days.

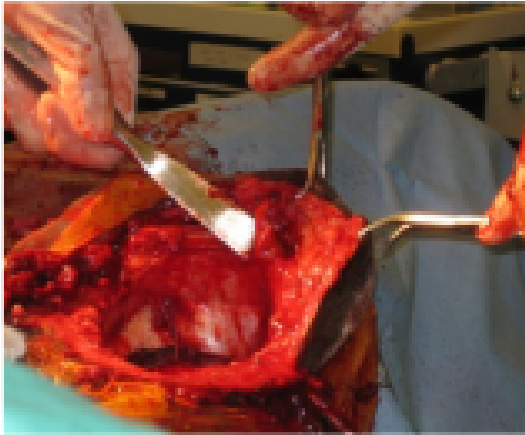
Infection

Open the suture line partially or completely to allow drainage.

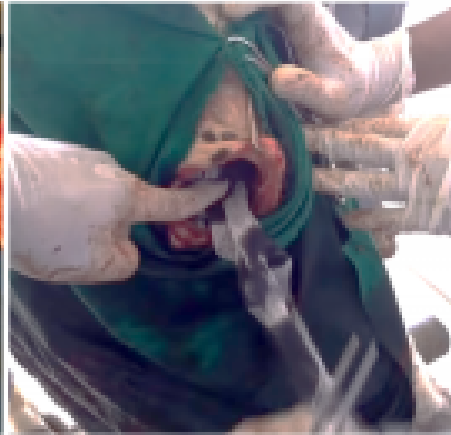
Incomplete closure

If the lids cannot be closed due to excess skin removal, the following options may help

- undermine and mesh the skin – make sure this area is over bone, not over the socket if hemorrhage is present
- remove brow bone – using an osteotome and mallet, this bone can be removed to create less of a bump
- leave it open – pack and cover with a stent bandage



Removing bone to enable closure




Packing with (incompletely) soaked betadine gauze

Tumor recurrence

Owners should be counseled to watch for growths or ulceration that could indicate tumor recurrence.

Videos



A YouTube element has been excluded from this version of the text. You can view it online here: <https://open.lib.umn.edu/largeanimalsurgery/?p=3081>



A YouTube element has been excluded from this version of the text. You can view it online here: <https://open.lib.umn.edu/largeanimalsurgery/?p=3081>



A YouTube element has been excluded from this version of the text. You can view it online here: <https://open.lib.umn.edu/largeanimalsurgery/?p=3081>

Resources

Eyelid lacerations

Eyelid lacerations require special care but not specialists. Horses like to injure their eyelids quite frequently. Horse eyelid lacerations are often referred to as “bucket handle tears” as they injure them on their water or feed buckets when they jerk their heads up too quickly. The exposed eyes of camelids make eyelid lacerations prone in those species too.

Eyelid lacerations may be repaired using standing sedation or under general anesthesia. For standing sedation, personal preference often plays a role with many options. Go light on the butorphanol as some horses will develop twitches with narcotics. These can be very annoying.

When prepping the eye, use betadine solution (not soapy) rather than betadine scrub (soapy) and avoid alcohol. The eyelashes may be trimmed if needed but rarely is further clipping required. Eyelube is used to protect the eye during surgery. Local blocks can help with both standing sedation or GA. Preoperative antibiotics and NSAIDs are recommended.

DO NOT TRIM off flaps unless obviously dead (cold, leathery). The head has excellent blood supply and most lacerations will heal fine. However, defects at the lid margin lead to exposure keratitis due to inability of the eye to fully close. The laceration margins may be scraped or trimmed very lightly to bleeding tissue.

Closure is typically in two layers but one may be sufficient. Closing the palpebral conjunctiva may provide some pain relief but isn't required. This layer will touch the cornea so should be small gauge soft suture (eg 4-0 vicryl, simple continuous with knots in the SQ layer.) Skin is also closed with small gauge soft suture; absorbable suture may be used. When closing the skin, close the eyelid margin first to ensure optimum alignment. A [figure 8 pattern](#) minimizes the suture poking into the cornea by moving the knots back from the eyelid margin. This pattern needs to be symmetric to create a even lid margin. It may take 2-3 attempts but the time spent is worthwhile. After the margin is apposed, the remainder of the laceration can be closed with simple interrupted or cruciate sutures.

Postoperative antibiotics are usually not required. NSAIDs can help minimize swelling and decrease the risk of dehiscence. If animals start to rub at the eye, an eye cup or head bandage should be used to protect the wound. Sutures should be removed in 10-14 days even if absorbable. As the sutures dissolve, parts may start to rub the cornea. Unless the cornea has been damaged, we don't try to treat the eye topically. The difficulty in getting medications into the eye outweighs any benefit and may well cause damage to the eyelid repair.

Examples



An interactive or media element has been excluded from this version of the text. You can view it online here:
<https://open.lib.umn.edu/largeanimalsurgery/?p=738>



An interactive or media element has been excluded from this version of the text. You can view it online here:
<https://open.lib.umn.edu/largeanimalsurgery/?p=738>

Key Takeaways

Eyelid lacerations should be repaired primarily. They do poorly if left for second intention healing.

Don't debride or cut off pieces of eyelids.

Use soft small gauge suture material on a cutting needle. If nonabsorbable, remove in 10-14 days.

Use a pattern that keeps suture away from the cornea.

Don't use betadine scrub or chlorhexidine scrub near the eye, unless the eye is being removed.

RESOURCES

[Equine eyelid disease](#), 2005 CTEP pg 96-97 – good resource for other eyelid surgeries (all species) and periocular sarcoids

Bonus : lion eye surgery

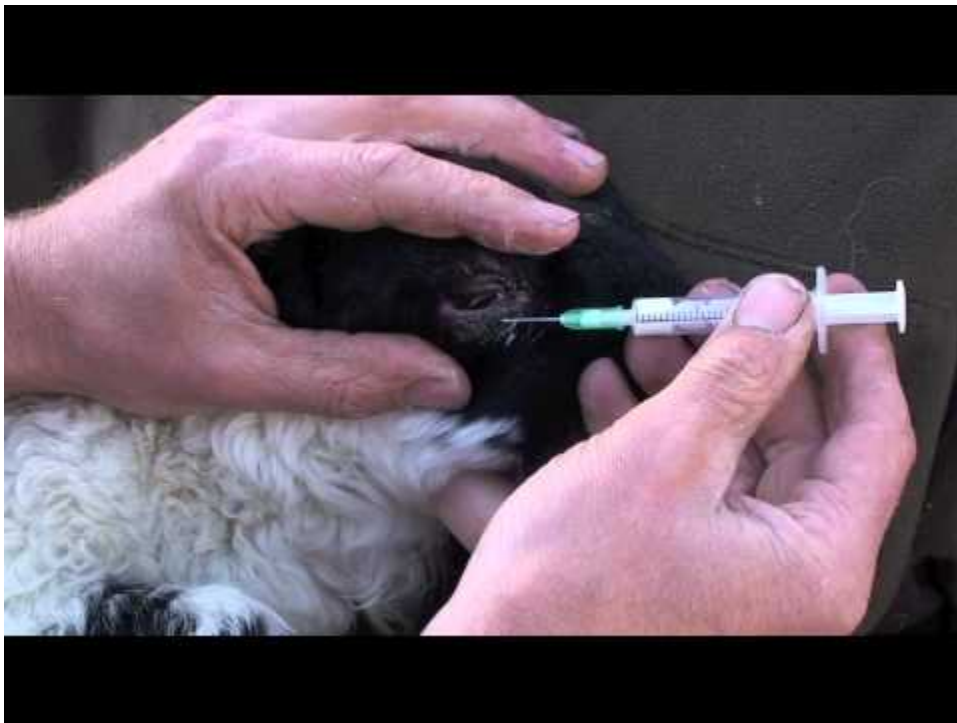

A YouTube element has been excluded from this version of the text. You can view it online here: <https://open.lib.umn.edu/largeanimalsurgery/?p=738>

Entropion

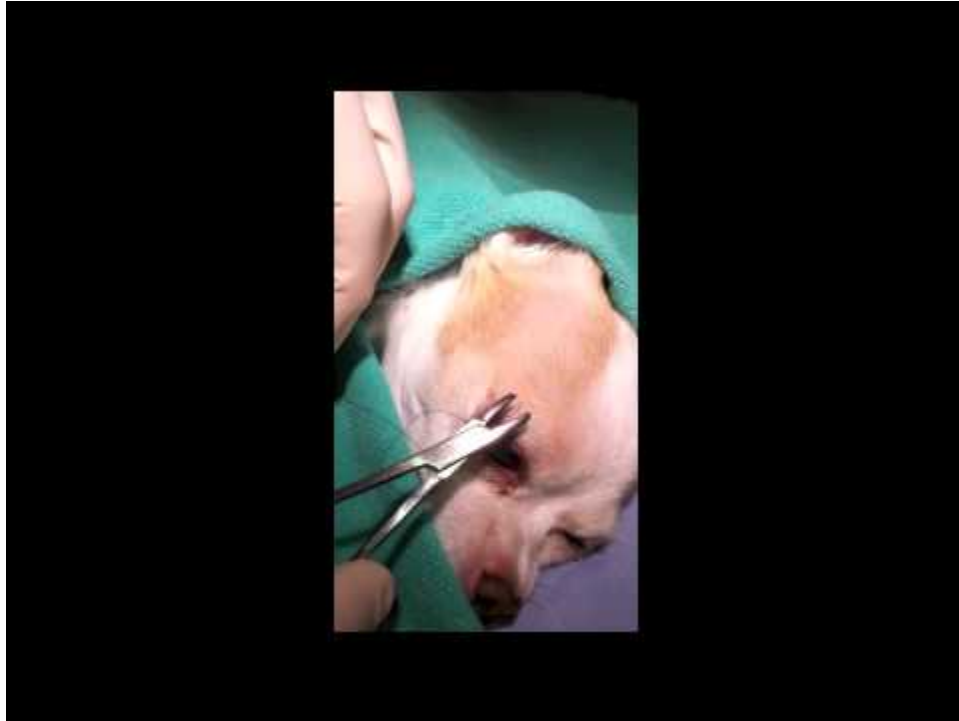Entropion is identified in some neonatal foals and often in lambs. The eyelids fold inward and the eyelashes rub on the cornea. Affected animals present with epiphora.

Most animals will outgrow the issue; treatment is just to prevent problems until the deformity resolves. Long acting penicillin may be injected subcutaneously to create swelling in the lower lid. This will roll out the eyelid and the drug will be absorbed over time. However, this isn't ideal use of antibiotics.



A YouTube element has been excluded from this version of the text. You can view it online here: <https://open.lib.umn.edu/largeanimalsurgery/?p=2346>

In lambs, tacking sutures are often used to roll out the lower lid temporarily. Yes, this is not a lamb.



A YouTube element has been excluded from this version of the text. You can view it online here: <https://open.lib.umn.edu/largeanimalsurgery/?p=2346>

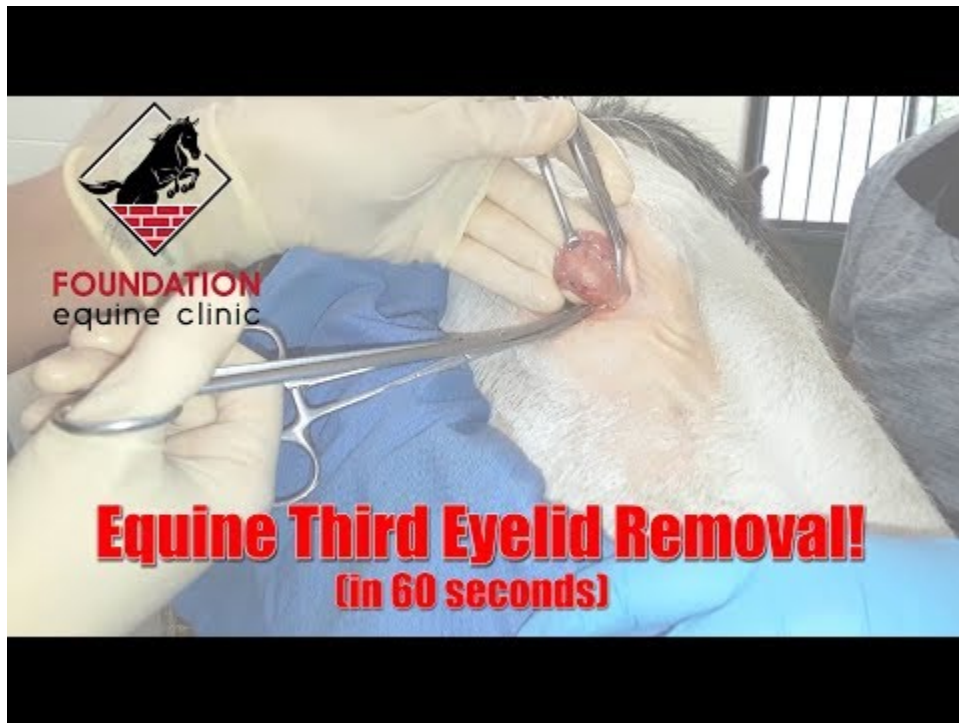RESOURCES

<http://www.infovets.com/books/srm/C/C202.htm>

<https://www.nadis.org.uk/disease-a-z/sheep/eye-diseases-in-sheep/>

Eyelid mass removal

Third eyelids are most often removed due to tumor involvement (usually SCC).



A YouTube element has been excluded from this version of the text. You can view it online here: <https://open.lib.umn.edu/largeanimalsurgery/?p=2350>

Eyelid masses (generally SCC) may be removed using H plasty. It is important to maintain or recreate the eyelid margin. This surgery pulls up skin from lower on the face to create the margin. Really cool and works in all species.

Equine periocular sarcoids are generally not removable (removing them would leave a huge gap and cause exposure keratitis). We treat these with imiquimod (safe near the eye), cisplatin beads and/or other chemotherapeutic injections. Combination therapy can be useful.

RESOURCES

JS Harper. [How to Surgically Remove the Third Eyelid in the Standing Horse](#). 2009 Vol. 55 AAEP PROCEEDINGS

444 Large Animal Surgery

B Welker et al. [Excision of Neoplasms of the Bovine Lower Eyelid by H-Blepharoplasty](#). *Veterinary Surgery*, 20, 2, 133-139, 1991

Practice



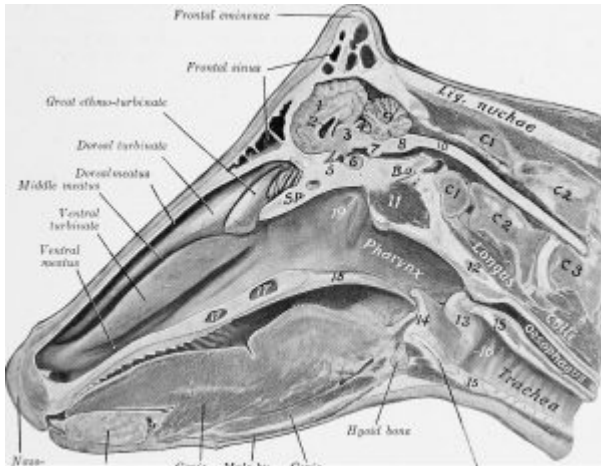
An interactive or media element has been excluded from this version of the text. You can view it online here:
<https://open.lib.umn.edu/largeanimalsurgery/?p=2314>

LA Respiratory Issues

This chapter focuses on upper and lower respiratory disorders with a surgical emphasis. The conditions described are predominantly an issue in horses.

Anatomy Review - Nasal Discharge

Anatomy Review:



[Nasal discharge anatomy powerpoint](#)

Challenge Yourself



An interactive or media element has been excluded from this version of the text. You can view it online here:
<https://open.lib.umn.edu/largeanimalsurgery/?p=805>

Nostrils and nasal conchae

Horses are obligate nasal breathers. They don't have the option to breathe through their mouths unless other abnormalities are present. Nasal abnormalities can cause significant airway compromise. Alpacas and llamas are semi-obligate nasal breathers and can breathe for a bit through their mouths. However, they can't breathe and eat or drink at the same time. Camels are bit more [unique](#). Cattle can breathe through their mouths but do not do so unless very hot, very distressed or have significant pathology in the nasal region.

Common nasal and nasal conchae abnormalities with surgical therapies:

Choanal atresia

[Choanal atresia](#) occurs when the nasal passage fails to develop properly. Embryonically, the passage opens from both directions. With atresia, the passages fail to meet in the middle, leaving an obstruction. This means airflow does not reach the trachea from the nostril. If unilateral, symptoms are mild until the animal is older and/or exercising. If bilateral, it means a quick death for foals and respiratory distress for camelids. A candidate gene has been identified in camelids. Treatment is not recommended, affected animals should not be bred and the breeding that led to the cria should not be repeated.

Resources: [Conditions of the respiratory tract](#)

[Diseases of the respiratory tract](#)

Nasal epidermal inclusion cyst

Nasal epidermal inclusion cysts occur in the [false nostril](#) (nasal diverticulum) of horses. These were previously identified as atheromas. While surgery was recommended in the past, the best treatment at this time is to [inject the cyst with formalin](#). Formalin dries up the secretions and the dried out sack can be removed digitally but usually falls out of the nostril on its own.

Resources: [Conditions of the respiratory tract](#)

Conchal cyst

[Conchal cysts](#) are congenital anomalies that develop in the nasal conchae (scrollwork). These cysts can be very slow to develop and may not be identified until animals are adults. Clinical signs are associated with blockage of the nasal passage (lack of airflow, drainage issues) and deformation of the skull. Treatment involves surgical removal of the cyst, generally with a nasal flap procedure performed standing.

Wry nose

[Wry nose](#) is observed in newborn foals, calves and crias and is a severe malformation of the head. The nasal septum is deviated with malalignment of the jaws and teeth. While surgery is possible to improve the condition, affected animals continue to have restricted airflow and problems with dentition. Nasal septum changes can also occur with trauma to the nose.

Resources: [Conditions of the respiratory tract](#)

Nasal tumors

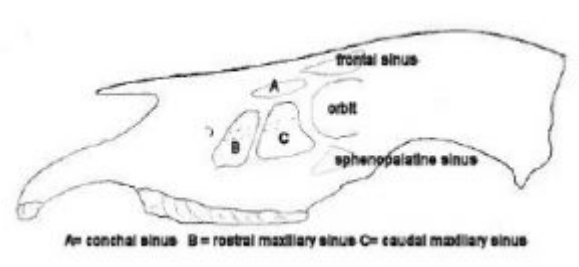
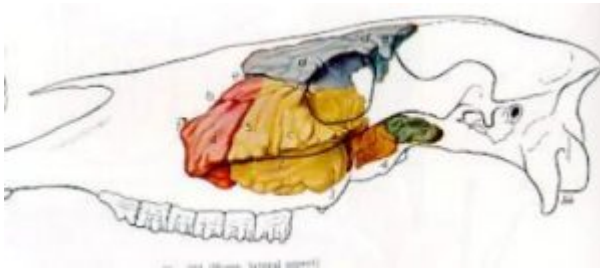
The most common nasal tumor in horses is a [polyp](#), generally believed to develop from chronic irritation. Other tumor types can develop from the various tissues in the nose, including adenocarcinomas, adenomas, chondromas, lymphosarcomas, osteosarcomas, and others. [Enzootic nasal adenocarcinomas](#) is a transmissible tumor of sheep and goats caused by a retrovirus. This tumor can occur in very young animals. Clinical signs include poor airflow/exercise intolerance, nasal discharge, nasal bone deformity and odor. Differentials for nasal tumors include granulomas and amyloidosis.

Resources: [Disorders of the paranasal sinuses](#)

[Diseases of the respiratory tract](#)

Paranasal sinus disease

Large animal species have [complex sinus anatomy](#), supposedly related to decreasing the weight of the head but mostly serving to create pockets of infection. The equine frontal and maxillary sinuses drain through the nasomaxillary opening in the rostral maxillary sinus.



Viscera of domestic animals.

Common paranasal sinus disorders with surgical therapies:

Primary sinusitis

[Sinusitis](#) results from infections and when the nasomaxillary opening is obstructed and drainage is impaired. Radiographs are useful to identify fluid in the sinus(es). Surgical treatment involves flushing the sinus and/or creating drainage into the middle nasal meatus. Warning: *Streptococcus equi* should be considered as a possible cause.

Traumatic sinusitis

Sinus trauma, including dehorning trauma, can lead to sinusitis. Drainage can be problematic if the trauma affects the frontal sinus. The frontal sinus needs to drain into the maxillary sinus before it can drain out the nasal passages. Blockage along the way can occur due to other consequences of trauma or to inspissated pus. Drainage may be through sinus trephination, through enlargement of the nasomaxillary openings or creation of new openings into the nasal passageway.

Resources: [Frontal sinusitis in adult beef bulls](#), JAVMA 2019

Tooth root infections

The maxillary sinuses of adult horses contain roots of 108-111, 208-211. These [teeth can become infected](#) and lead to secondary infection of the maxillary sinus. Tooth root infection should be suspected with unilateral sinusitis. While

radiographs are useful to identify sinusitis. [CT \(computed tomography\) is the gold standard](#) for determining if a tooth (teeth) are infected.

Resources : [Focus on Dentistry](#), 2011 pg 4

Sinus cysts

[Sinus cysts](#) are similar to [conchal cysts](#) in development, clinical signs, and therapy. Radiographs and CT examinations are useful for diagnosis.

Ethmoid hematomas

[Ethmoid hematomas](#) develop off the ethmoid turbinates and may or may not end up in a sinus. Potentially related to trauma, ethmoid hematomas often lead to a foul smelling discharge due to pressure necrosis on nearby tissue. The discharge is intermittently hemorrhagic and purulent in many cases. Airflow is often reduced. Despite the location caudal to the septum, unilateral discharge is common with unilateral lesions. Horses can have bilateral hematomas. [Endoscopy](#) combined with radiographs or CT is useful for diagnosis and evaluation of size and location. Treatment options include [laser therapy](#), [formalin injections](#) and/or [surgery](#). Recurrence is common.

Resource: [Conditions of the respiratory tract](#)

[Disorders of the paranasal sinuses](#)

Sinus tumors

[Sinus tumors](#) are uncommon but include squamous cell carcinoma and tumors of dental origin. Clinical signs are related to bony remodeling, tissue necrosis and impairment of nasal discharge. Sinus flaps may be needed for diagnosis and therapy. Tumors are often advanced by the time of diagnosis.

Resources : [Disorders of the paranasal sinuses](#)

Challenge Yourself

Dental disorders are common. Work your way through the following exercise to review the topic.



An interactive or media element has been excluded from this version of the text. You can view it online here:

<https://open.lib.umn.edu/largeanimalsurgery/?p=626>

PRIMARY RESOURCES

[Disorders of the paranasal sinuses](#), Tremaine and Freeman – great pictures and explanations

[Paranasal sinus disease](#), 2011 Compendium- another great resource for common diseases

SECONDARY RESOURCES

[How to perform a minimally invasive sinus flush](#), 2008 AAEP – very handy skill if doing equine

[Sinusitis in horses](#), ACVS -short and sweet with a surgery perspective

[Review of paranasal sinusitis](#), 2012 EVE -diagnosis and treatment

[Cheek teeth diastemata](#), 2015 EVE -more than I ever wanted to know

Pharyngeal disorders

The [pharyngeal region](#) includes the soft palate, extensions of the palate into the walls and roof of the pharynx, openings into the guttural pouches and to the larynx. [Pharyngeal dysfunction](#) is an important cause of poor performance and noise associated with exercise. The muscles of the pharynx are essential to maintaining an open airway despite high negative pressures during inspiration.

Common disorders:

Cleft palate

[Cleft palates](#) occur as [congenital anomalies](#) in most species. The earliest clinical sign is usually milk drainage from the nostrils. Careful digital evaluation of the palate should be performed in all neonates to ensure the palate is complete. Surgical repair is challenging and success depends on how much of a defect is present and whether or not aspiration pneumonia develops. If treatment is an option, affected animals should be hospitalized to minimize the risk of aspiration through feeding tube placement and antibiotic therapy.

Pharyngeal lymphoid hyperplasia

The lymphoid tissue in the pharynx can become inflamed in young horses leading to numerous bumps visible endoscopically. [Pharyngeal lymphoid hyperplasia](#) (PLH) may lead to symptoms of a sore throat but is often identified incidentally. Treatment is not usually required but throat sprays containing an anti-inflammatory agent may help.

Dorsal displacement of the soft palate

In the horse, the [soft palate merges into the walls of the pharynx](#), totally separating the oral cavity from the nasal cavity. The larynx connects with the nasal passage through an opening in the soft palate. When the horse [swallows](#), the palate moves up to allow food to access the esophagus (lives dorsal to the larynx). With DDSP, the palate moves up during exercise, blocking part of the airflow. Diagnosis is through [exercise endoscopy](#). Multiple causes of DDSP exist, leading to various treatment options. If anti-inflammatory treatment does not help, the preferred surgery is a [“tie-forward”](#) procedure to keep the larynx positioned within the ostium. [Tongue-ties](#), while not supported by clinical trials, are common in racing horses and are designed to prevent DDSP by preventing swallowing.

Resources: [Disease of the respiratory tract](#)

[Surgery of the URT](#)

Pharyngeal collapse

[Pharyngeal collapse](#) results from the large negative airway pressures and is a common cause of poor performance. Treatment is nonspecific. Diagnosis is through [endoscopy](#) during exercise. Any inflammation and other disorders should be treated. The [prognosis is poor](#) for most performance horses.

Resources: [Disease of the respiratory tract](#)

Rostral displacement of the palatopharyngeal arch

The palatopharyngeal arch borders the opening to the larynx. When [rostral displacement](#) occurs, the opening the larynx is partially obstructed. This is a congenital lesion leading to impaired laryngeal function (required for performance) and swallowing. Treatment is often unrewarding.

Resources: [Conditions of the respiratory tract](#)

Pharyngeal trauma

Pharyngeal trauma is relatively common in cattle, often due to medication administration with [bolus guns](#). The bolus can be pushed through the oropharynx, causing cellulitis. Cellulitis in this area can lead to dysphagia, dyspnea and mediastinitis. [Diagnosis often requires radiographs](#) and endoscopy; oral palpation can be useful in larger patients. To treat, the foreign body is removed, any abscesses are drained surgically and the cellulitis treated with systemic antibiotics. A rumen fistula may be needed for feeding and a tracheotomy needed for breathing in more severe cases. Due to the location, drainage of the abscesses can be tricky and is best done at a referral hospital if possible.

[Balling gun-induced trauma in cattle: clinical presentation, diagnosis and prevention](#), Veterinary Record, 29 June 2013, Vol. 172(26), p. 685

[Respiratory Surgery](#), Vet Clin Food Anim 32 (2016) 593-615

RESOURCES

[Upper airway conditions affecting the equine athlete](#), VCNA: Equine Practice, August 2018, Vol.34(2), pp.427-441

[Update on diseases and treatment of the pharynx](#), VCNA: Equine Practice, April 2015, Vol.31(1), pp.1-1

Guttural pouch disorders

The guttural pouches are unique to a small number of species, including the horse. The guttural pouches are expansions of the eustachian tube and are theorized to help with brain cooling. Diagnosis of guttural pouch disorders often includes [endoscopy](#) of one or both pouches.

Even though the openings are caudal to the nasal septum, discharge tends to remain unilateral unless severe or chronic. Why they don't cause bilateral drainage isn't entirely clear. Perhaps related to normal head position or the dorsal position of the openings?

Guttural pouch disorders with surgical options:

Guttural pouch empyema

[Guttural pouch empyema](#), or pus in the guttural pouch, is frequently related to strangles (*Streptococcus equi* infection). Affected horses are often infectious. Drainage from the [guttural pouch openings](#) may be seen on endoscopy. Treatment generally involves lavage of the guttural pouch combined with systemic and/or local antimicrobials.

Guttural pouch chondroids

[Chondroids](#) develop when the purulent material from guttural pouch empyema dessicates. These “stones” of pus may need surgery for removal. NO agents have been found to dissolve the stones and many compounds lead to severe trauma to the guttural pouch.

Guttural pouch mycoses

[Guttural pouch mycoses](#) are fungal infections, generally involving *Aspergillus fumigatus*. The fungus attaches to an artery in the guttural pouch for nutrition. If the fungus is on an artery, [surgical occlusion](#) of the artery is the preferred therapy. This requires both proximal and distal occlusion due to the [Circle of Willis](#) (leads to the potential for blood flow from both ends of the artery). Due to access issues, a balloon or coils are used to block off the far end while a ligature is used on the artery outside of the pouch. If the fungus is on a bone or non-arterial structure, it can be scraped off or treated with topical antifungals. Due to the risk of fatal hemorrhage, those options are not recommended for fungal infections involving an artery. Antifungal agents are not required if surgery is used as the fungus cannot live without the arterial oxygen supply.

Guttural pouch tympany

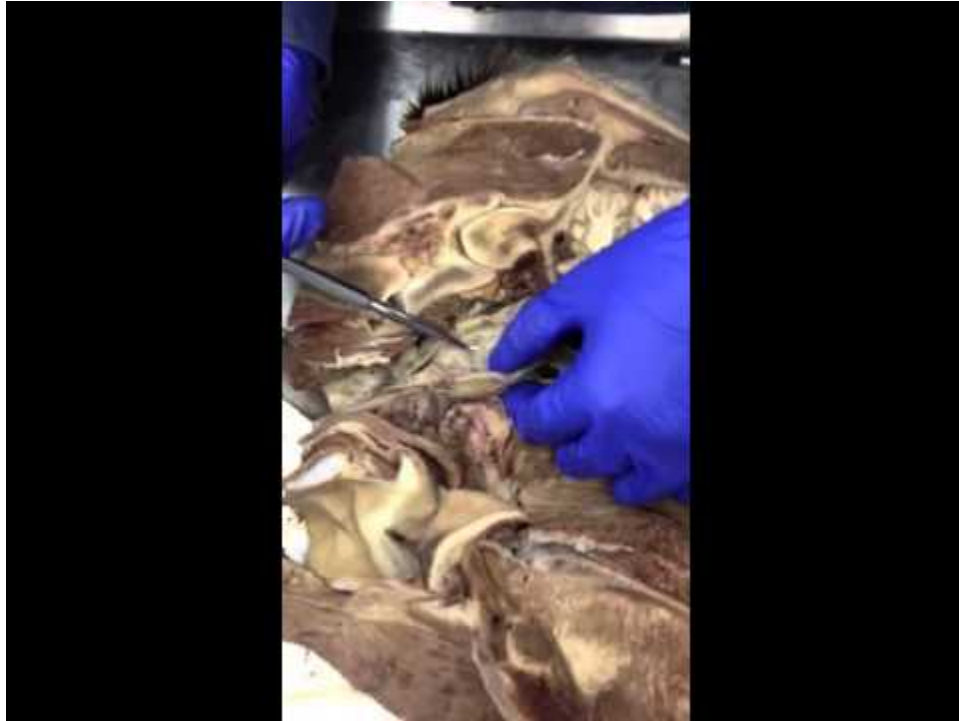[Guttural pouch tympany](#) is a nonpainful fluctuant swelling of one or both guttural pouches, particularly in Arab fillies. Air collects in the pouch as the opening operates as a one way valve rather than allowing bidirectional airflow. Diagnosis is not difficult but it can be more challenging to determine if the disorder is unilateral or bilateral. On endoscopy, an [abnormal guttural pouch opening](#) is often evident. Surgery involves [using a laser](#) to create an opening either into the normal guttural pouch to allow air to exit the normal side or creating an opening into the pharynx. Prognosis is good if treated prior to the development of infection inside the pouch.

Resources: [Conditions of the respiratory tract](#)

Temporohyoid osteopathy

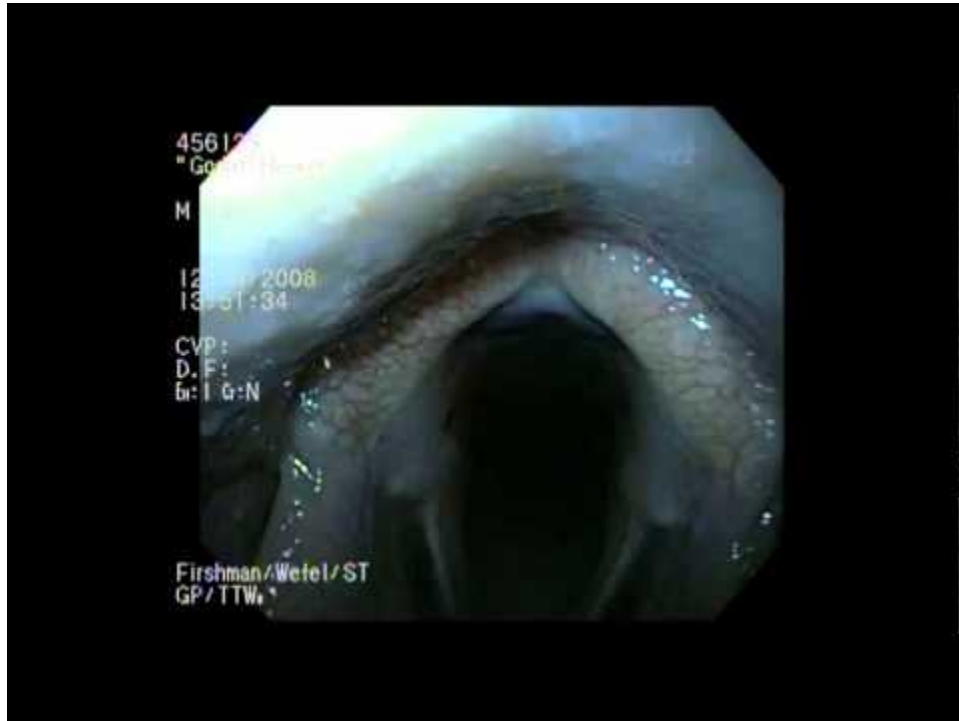[Temporohyoid osteopathy](#) (THO) is incompletely understood but involves proliferation of bone around the temporohyoid joint and can result in fusion of the joint. With movement of the head or tongue, pain results and the stylohyoid bone can fracture. Remodeling of the joint and/or bone can be seen radiographically and endoscopically. The remodeling is suspected to result from local (inner ear) infection. Damage to local nerves can also result in poor tear production, dry eye and corneal ulcers. Surgical treatment involves cutting the ceratohyoid bone in the hyoid apparatus to relieve pressure on the joint and stylohyoid bone. Horses can be affected bilaterally. Prognosis depends upon the degree of dysfunction identified prior to surgery.

Guttural pouch anatomy



A YouTube element has been excluded from this version of the text. You can view it online here: <https://open.lib.umn.edu/largeanimalsurgery/?p=636>

Normal guttural pouch anatomy



A YouTube element has been excluded from this version of the text. You can view it online here: <https://open.lib.umn.edu/largeanimalsurgery/?p=636>

-  An interactive or media element has been excluded from this version of the text. You can view it online here: <https://open.lib.umn.edu/largeanimalsurgery/?p=636>

PRIMARY RESOURCES

[Guttural pouch diseases in horses](#), Merck Manual – a little too short and sweet

[Guttural pouch disease causing neurological dysfunction](#), 2011 VCNA – table with really excellent explanation of nerves and side effects of guttural pouch disease

[Update on disorders and treatment of the guttural pouch](#), VCNA: Equine Practice, April 2015, Vol.31(1), pp.63-89- explains how to drain chondroids surgically and goes into more detail about other procedures.

SECONDARY RESOURCES

[Respiratory Disease Diagnostics in the Horse](#), VCNA: Equine Practice, August 2015, Vol.31(2), pp.307-336-
medical and surgical diagnostics

[Diagnosing guttural pouch disorders and managing guttural pouch empyema in horses](#), Vet Folio 2003 – need to
register for student access

[Guttural pouch diseases](#), UFL- client perspective

Laryngeal disorders

The [larynx](#) includes the epiglottis, paired arytenoids and other laryngeal structures. The larynx connects the pharynx to the trachea. Dysfunction of the larynx leads to swallowing disorders and impaired performance due to decreased airway diameter. Exercise endoscopy is required to accurately evaluate these disorders in horses. These disorder, while sometimes present, are generally not an issue in other species. Calves and young feedlot cattle do get [necrotic laryngitis](#); temporary tracheotomy may assist in treatment.

Laryngeal disorders:

Epiglottic entrapment

The epiglottis moves up during [swallowing](#) to protect the airway. The extra tissue below the epiglottis that permits this movement can also “[entrap](#)” the epiglottis in a pillowcase type sheath. The entrapping tissue catches air on exhalating and billows, creating turbulence and noise. The entrapment also prevents normal movement of the epiglottis. Horses often present with exercise intolerance and cough. Diagnosis is made on [endoscopy and/or radiographs](#). A [laser is used to split](#) the membrane, releasing the epiglottis as the preferred treatment.

Resources : [Performance limiting laryngeal disorders](#)

[Surgery of the URT](#)

Laryngeal hemiplegia

Both arytenoids should adduct during exercise to open the airway for maximal airflow. With [laryngeal hemiplegia](#), generally the left arytenoid doesn't work at all or doesn't work well. The laryngeal branch of the vagus nerve is the longest nerve in the body and appears to degenerate fairly often. This degeneration leads to neurogenic atrophy of the CAD (cricothyroarytenoideus dorsalis) muscle. The CAD muscle is responsible for adduction of the arytenoid during exertion. When the arytenoid doesn't adduct properly, it [vibrates during exercise and impairs airflow](#), leading to poor performance. Diagnosis is via exercise [endoscopy](#). Surgery involves replacing the CAD muscle with a suture to adduct the muscle, removing the arytenoid or transposing a nerve to reinnervate the muscle.

Resources : [Performance limiting laryngeal disorders](#)

[Conditions of the respiratory tract](#)

[Roaring down the stretch](#)

[Surgery of the URT](#)

Arytenoid chondritis

Inflammation of the arytenoid leads to malformation and dysfunction of the arytenoid. Medical treatment is sometimes

effective but often the arytenoid must be removed to open the airway. When the arytenoid is removed, horses are at risk of food aspiration and persistent coughing.

In calves, arytenoid chondritis can develop with [oral necrobacillosis](#) due to *Fusobacterium necrophorum*.

Resources :

[Performance limiting laryngeal disorders](#)

[Conditions of the respiratory tract](#)

[Respiratory Surgery](#), Vet Clin Food Anim 32 (2016) 593-615

Aryepiglottic fold collapse

The negative pressures in the upper airway of the horse can lead to collapse of soft tissue structures. The tissue between the epiglottis and larynx can be pulled into the airway. Horses present with exercise intolerance and noise. Laser surgery may help.

Resources : [Performance limiting laryngeal disorders](#)

[Surgery of the URT](#)

Subepiglottic cysts

[Cysts](#) can develop in the larynx and interfere with function of the epiglottis. Problems with the epiglottis lead to swallowing disorders and feed aspiration. Cysts can be treated by laser or [formalin injections](#).

Resources : [Performance limiting laryngeal disorders](#)

[Conditions of the respiratory tract](#)

RESOURCES

[Update on laryngeal disorders and treatment](#), VCNA: Equine Practice, April 2015, Vol.31(1), pp.13-26

[Upper airway conditions affecting the equine athlete](#), VCNA: Equine Practice, August 2018, Vol.34(2), pp.427-441

Tracheal disorders

Tracheal disorders are rare in horses with the exception of [tracheal collapse](#) in miniature horses. Tracheal collapse leads to respiratory noise and exercise intolerance. [Surgical stenting](#) has been performed as in small animals, with limited success. Tracheal perforation can occur with trauma and is treated [conservatively](#) and/or with a [temporary tracheotomy](#).

Resources

[Disorders of the trachea in horses](#)

Pleural space disorders

In cattle, pleural abscesses and pericarditis occur secondary to [hardware disease](#). Prognosis is grave and treatment is not recommended. The surgery is cool, though, and is aided by the bovine [complete mediastinum](#) which generally prevents bilateral pneumothorax.

Pleural abscesses in horses are generally secondary to [pleuritis](#) and can be treated through drainage once consolidated. Generally pleural surgery is best performed in a referral hospital due to the risk of bilateral pneumothorax and collapse.

Thoracic wounds

Thoracic wounds are the most common cause of pleural space disease in horses. Pneumothorax and pleuritis can develop with significant consequences. Axillary wounds can lead to pneumomediastinum and subsequently to pneumothorax:

Axillary wounds in horses and the development of subcutaneous emphysema, pneumomediastinum and pneumothorax

A. Joswig J. Hardy

[EVE Vol 25 \(3\): 139-143, 2013](#)

Summary

Equine axillary wounds are common in horses. Severe and potentially life-threatening complications that can result from axillary wounds include subcutaneous emphysema, pneumomediastinum and pneumothorax. This report describes the occurrence of these complications and appropriate treatment. Case records of 7 horses after sustaining an axillary wound are reviewed. Of these cases, all 7 developed subcutaneous emphysema, 5 developed a pneumomediastinum and 4 developed a pneumothorax. The time between the wound occurrence and the development of subcutaneous emphysema was able to be determined in 5 of the 7 cases. The mean \pm s.d. time for the development of subcutaneous emphysema following initial injury was 3.2 ± 0.84 days (range 2–4 days). Resolution of subcutaneous emphysema was not achieved until the treatment included packing the wound to stop it from acting as a one-way valve. Horses with a pneumothorax in respiratory distress were managed with thoracocentesis or placement of thoracic drains. Horses with a pneumothorax but without respiratory distress were treated with conservative management. All horses survived to discharge.

PRIMARY RESOURCES

[Axillary wounds in horses](#), EVE Vol 25 (3): 139-143, 2013

470 Large Animal Surgery

[How to manage penetrating wounds in the field](#), AAEP 2012

[Thoracic trauma in horses](#), Volume 31, Issue 1, April 2015, Pages 199-219- denser and more thorough

SECONDARY RESOURCES

[Treating thoracic injuries](#), Vet Folio 2009 -worth subscribing

[Hardware disease in the bovine](#), 2015 Acad J of Animal Diseases (we don't treat as many as they do)

[Diagnosis and treatment of hardware disease](#), 2017 VCNA

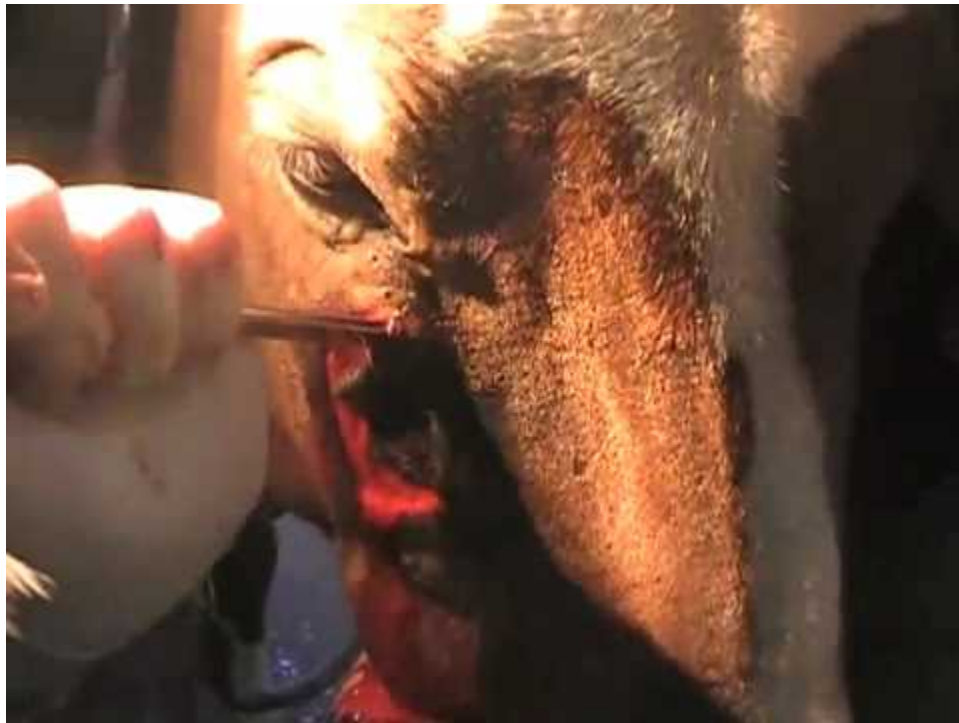STUDY BREAK

[Study break](#): This is what goes on at our house

Diagnostics

Respiratory disorders should first be localized using history and physical examination findings. Definitive diagnosis may require additional evaluation using cultures, radiography (plain and/or contrast), endoscopy, CT scans, ultrasound, and occasionally MRI or scintigraphy. Skull radiographs are challenging to interpret, making CT scans the gold standard for many lesions in the head, particularly tooth and sinus disease. Endoscopy can be performed standing or in the moving horse. Standing examinations are much easier to perform; however, abnormalities seen on standing examinations may disappear during exercise while different lesions appear. In general practice, the primary goal is generally to determine if advanced diagnostics are indicated and provide options to the client.

A sinus flap can be useful for both diagnostics and therapy:



A YouTube element has been excluded from this version of the text. You can view it online here: <https://open.lib.umn.edu/largeanimalsurgery/?p=657>

Challenge Questions

Find a skull or images of a horse, cow or camelid skull and review the disorders below. Try to answer the following questions:

- Why would you get unilateral discharge with some conditions and bilateral with others?
- Classify the following disorders into unilateral or bilateral, purulent or hemorrhagic or other discharge:
 - ethmoid hematoma
 - choanal atresia
 - cleft palate
 - conchal or sinus cyst
 - guttural pouch chondroids
 - guttural pouch mycosis
 - guttural pouch tympany
 - nasal tumor
 - nasal epidermal inclusion cyst
 - sinusitis secondary to dental disorders
- For each of the above, what would be the preferred diagnostic tool to confirm your diagnosis? Consider radiographs, endoscopy, CT and ultrasound.

Exercises

Organize the steps needed to sample a sinus:



An interactive or media element has been excluded from this version of the text. You can view it online here:
<https://open.lib.umn.edu/largeanimalsurgery/?p=657>

RESOURCES

[Respiratory Disease Diagnostics in the Horse](#), VCNA: Equine Practice, August 2015, Vol.31(2), pp.307-336

[Field Examination of the Equine Patient with Nasal Discharge](#), VCNA: Equine Practice, Volume 13, Issue 3, December 1997, Pages 561-588- don't laugh too hard

Exercise 1

Fill in this chart:

Disorder	Presenting complaint	Most useful diagnostic test (including PE)	Treatment options	Prognosis if treated (for life, for performance)	Prognosis if not treated
Ethmoid hematoma					
Nasal epidermal inclusion cyst					
Conchal or sinus cyst					
Guttural pouch chondroids					
Guttural pouch mycosis					
Guttural pouch tympany					
Cleft palate					

RESOURCES

[Malone notes and ppts](#)

<https://www.vetstream.com/treat/equis/diseases/nose-nasal-discharge>

Exercise 2

Advanced Topics

Fill in the chart for these topics:

Disorder	Presenting complaint	Most useful diagnostic test	Treatment options	Prognosis if treated (for life, for performance)	Prognosis if not treated
Choanal atresia					
Deviated septum					
Wry nose					
Temporohyoid osteopathy					

Horses typically don't do well under anesthesia. Use V/Q inequalities and explain why.

RESOURCES

[Respiratory adaptations in health and disease](#)

[Ventilation/perfusion ratio](#)

[Respiratory Surgery](#), Vet Clin Food Anim 32 (2016) 593-615

[Respiratory Disease Diagnostics in the Horse](#), VCNA: Equine Practice, August 2015, Vol.31(2), pp.307-336

[Update on disorders and treatment of the guttural pouch](#), VCNA: Equine Practice, April 2015, Vol.31(1), pp.63-89

[Update on diseases and treatment of the pharynx](#), VCNA: Equine Practice, April 2015, Vol.31(1), pp.1-1

Exercise 3

Use the following exercises to review the material presented in this section.

Challenge Exercises



An interactive or media element has been excluded from this version of the text. You can view it online here:

<https://open.lib.umn.edu/largeanimalsurgery/?p=681>



An interactive or media element has been excluded from this version of the text. You can view it online here:

<https://open.lib.umn.edu/largeanimalsurgery/?p=681>



An interactive or media element has been excluded from this version of the text. You can view it online here:

<https://open.lib.umn.edu/largeanimalsurgery/?p=681>

Video quizzes



An interactive or media element has been excluded from this version of the text. You can view it online here:

<https://open.lib.umn.edu/largeanimalsurgery/?p=681>



An interactive or media element has been excluded from this version of the text. You can view it online here:

<https://open.lib.umn.edu/largeanimalsurgery/?p=681>



An interactive or media element has been excluded from this version of the text. You can view it online here:

<https://open.lib.umn.edu/largeanimalsurgery/?p=681>



An interactive or media element has been excluded from this version of the text. You can view it online here:
<https://open.lib.umn.edu/largeanimalsurgery/?p=681>



An interactive or media element has been excluded from this version of the text. You can view it online here:
<https://open.lib.umn.edu/largeanimalsurgery/?p=681>

Dental disorders supplement

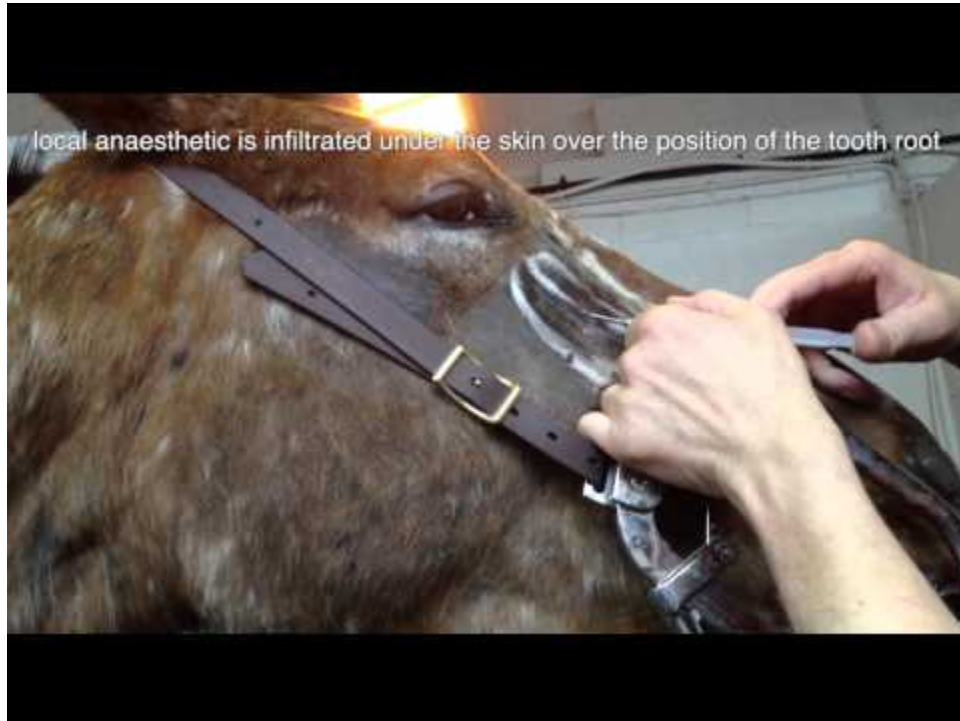Equine teeth are firmly packed together and develop issues readily. Miniature horses have regular sized teeth. Horses develop habits of chewing on things. In other countries, horses are fed silage and don't brush afterwards. Diseases lead to extra calcification and pain or to tooth loss. Dental extraction is challenging and, in the past, involved an osteotome and mallet (basically a hammer and chisel) with the tooth pushed out via force. These days, most teeth are removed through intraoral extraction in the standing horse. Due to the tightly compacted anatomy, this takes time and patience. Occasionally repulsion is still needed. The following videos may help you further understand the process.

Intraoral tooth removal



A YouTube element has been excluded from this version of the text. You can view it online here: <https://open.lib.umn.edu/largeanimalsurgery/?p=703>

Intraoral tooth removal + repulsion



A YouTube element has been excluded from this version of the text. You can view it online here: <https://open.lib.umn.edu/largeanimalsurgery/?p=703>

How to - Temporary tracheotomy

Indications

Temporary tracheotomies are performed when airflow is significantly impaired through the upper airway. The obstruction **MUST** be proximal to the tracheotomy for it to help. Indications of airflow obstruction include nostril flaring, open mouthed breathing, no flow through nostrils, audible respiratory noise and inability to eat and breathe at the same time.

Temporary tracheotomies are also used for intubation for upper airway or dental surgery and when airway access need is immediate (eg animal acutely needs to be intubated).

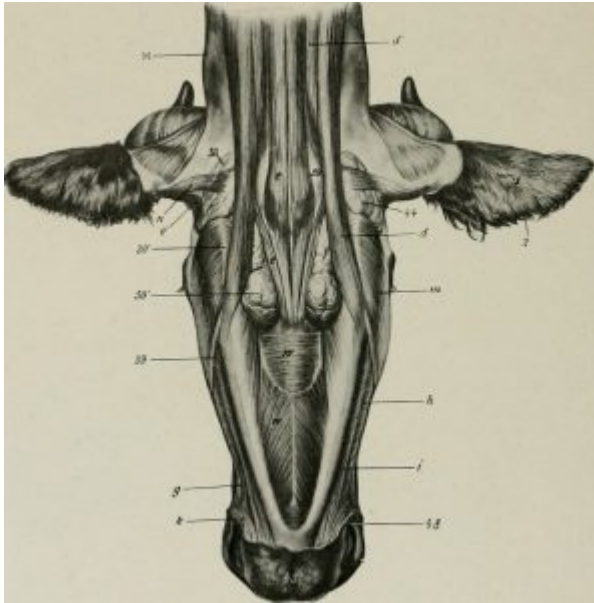
Tracheotomies can also be useful for diagnostics. The diagnostics may further impair the airway and/or an endoscope can be inserted via the tracheotomy to visualize the inner aspect of the larynx.

Relevant anatomy

The proximal aspect of the trachea is the larynx. Cut distal to this unless you are performing a laryngotomy.

The tracheal rings are cartilaginous. If cut, they tend to form chondromas. Chondromas can obstruct airflow. In LA species, we try really hard to **NOT CUT** the cartilage. Cut between the rings, not through them. Yes, the jugulars are in the same ballpark but not really that close. The closest important structure is the esophagus.

The neck strap muscles cover the surface of the trachea. The muscles do not cross midline. If your incision is centered, you can (and should) separate the muscle bellies and avoid cutting any muscle.



Preoperative management

Food restrictions: Not required

NSAIDs/analgesics: Preoperative NSAID is recommended

Antibiotics: Not required

Tetanus prophylaxis is recommended.

Local blocks: Lidocaine line block if the animal is conscious

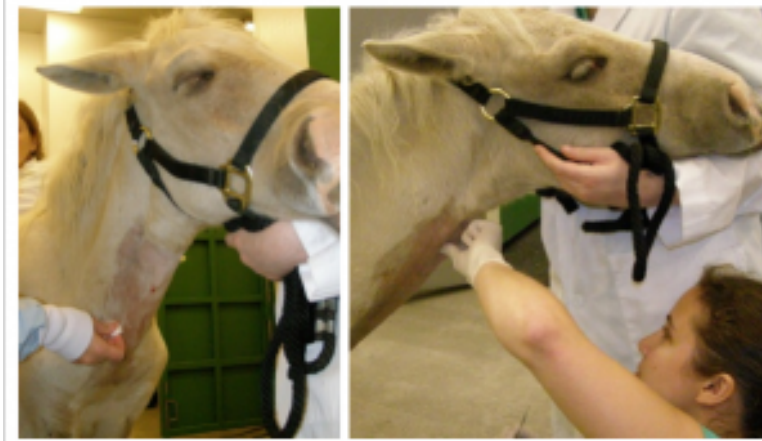Position/preparation: Standing is easiest. The head can be elevated in a dental harness. Standing isn't always an option. Having the animal's neck as straight as possible helps keep the incision midline. If the animal is conscious, the area is clipped and prepped routinely. If the animal has collapsed, just make an incision.

Surgery Supplies:

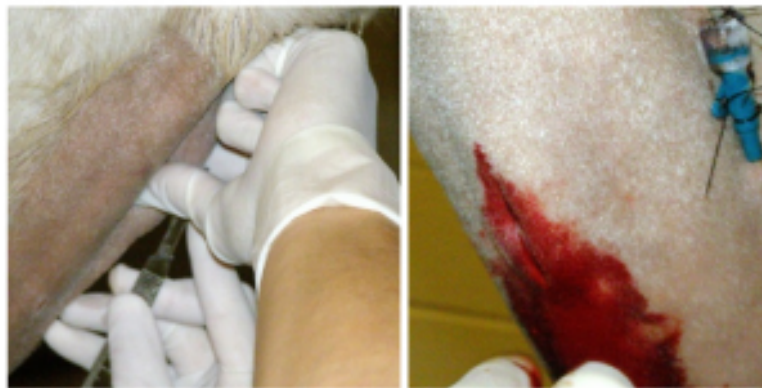- Scalpel blade
- Hemostats (mosquitos or kellys)
- Tracheotomy tube or endotracheal tube

Surgical procedure

- Make a 10 cm vertical incision centered at the junction of the proximal and middle thirds of the palpable trachea (ignore the thoracic component). Incise through skin to the muscles.



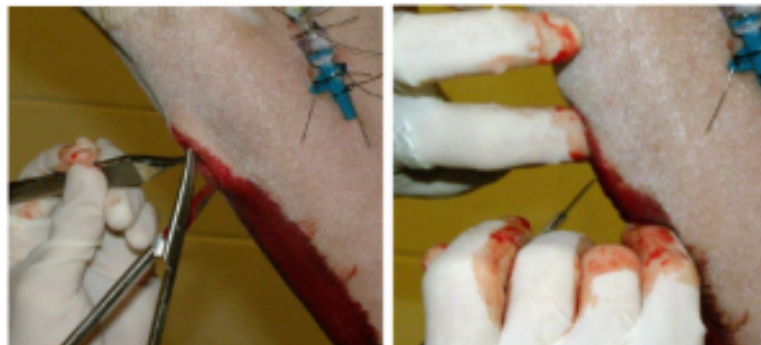Local block and Dr. Nicholson finding the right center spot



Vertical skin incision

Dissect bluntly between the muscle bellies until the tracheal is directly palpable and visible

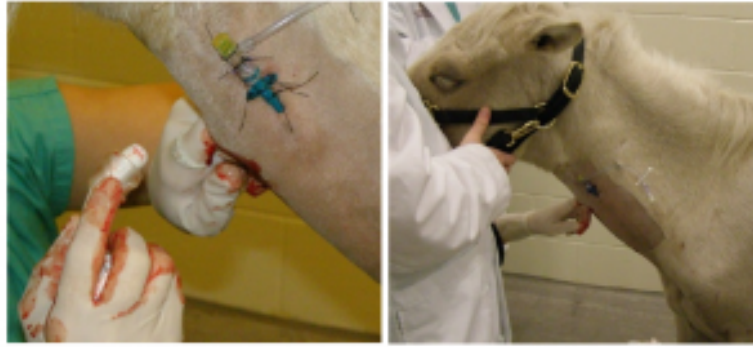- Insert a scalpel blade between the cartilage rings and incise 180 degrees horizontally between the rings.
- Repeat if you didn't actually do that



Dissecting between the muscles; incising the tracheal membrane horizontally

- Push the tracheotomy tube or endotracheal tube into the area. The hemostat can be used to open the

site first, providing a guide. Make sure the tube has gone into the trachea rather than subcutaneously.



Inserting the tracheotomy tube and verifying it is in the trachea, not just SQ

- Secure the tube in place.

Postoperative care

- The tube should be cleaned twice daily for the duration or at least the first two weeks. It is safe to remove the tube and clean it.
- Many clinician perform to trade out 2 tubes so that one can soak while the other is in use. Soaking helps clean off the cement-like exudate.
- Avoid ponds and baths – no water into the tracheotomy site.
- When the animal has recovered, the tracheotomy tube is removed and the wound left to heal by second intention. No closure.

Complications

If the skin incision is made off midline, the animal may suck the muscles/skin over the tracheotomy opening when the tube is removed. This may make changing the tube more challenging. A second set of gear is helpful so that the airway can be maintained open even during cleaning.

The airway is compromised. Larger particles can make it into the lungs and cause respiratory illness. Water could get into the airway and cause drowning.

Videos

Narrated tracheotomy



A YouTube element has been excluded from this version of the text. You can view it online here: <https://open.lib.umn.edu/largeanimalsurgery/?p=720>

Key Takeaways

- If the animal is dying, skip the clip and prep
- Make a vertical incision in the skin, staying on midline
- Make a horizontal incision between the rings, extending about 1/2 way around.
- Do NOT cut cartilage.
- Leave to heal by second intention.

Resources

[Tracheostomy](#), Merck- PS Chondritis is usually unilateral and doesn't often require a tracheotomy unless severe or surgical treatment

[Tracheotomy and tracheostomy tube placement in cattle](#), 2008 VCNA

486 Large Animal Surgery

[More tracheotomy videos](#)

Study break :[sloths](#)

Exercise 4

Challenge Quiz

Take the following quiz until you are comfortable with tracheotomies. You don't always have time to look this one up.



An interactive or media element has been excluded from this version of the text. You can view it online here:
<https://open.lib.umn.edu/largeanimalsurgery/?p=728>

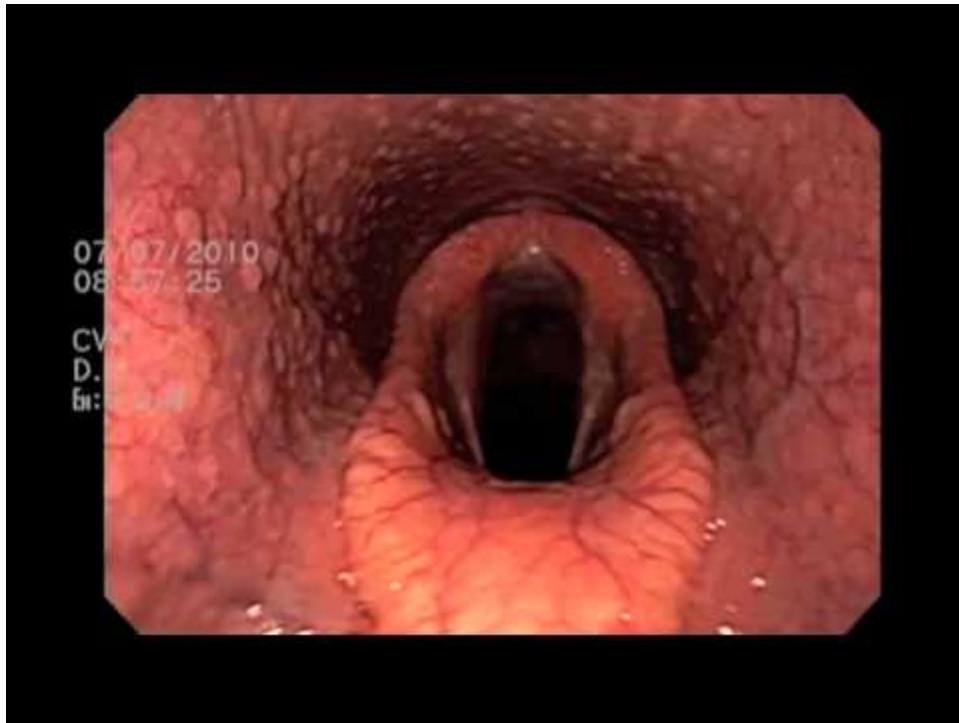
And then try:



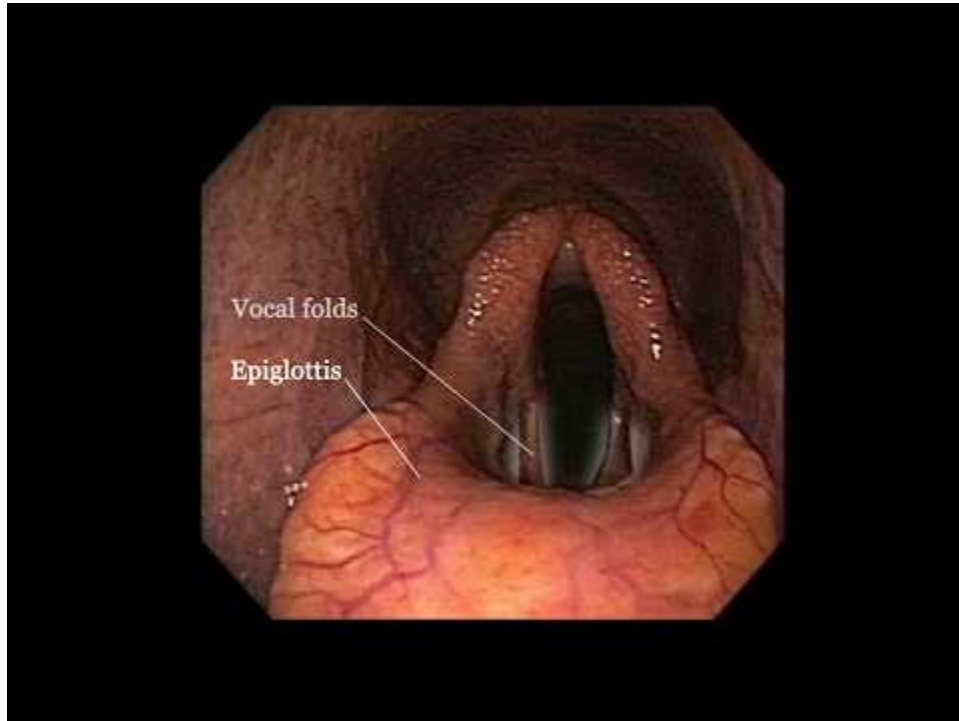
An interactive or media element has been excluded from this version of the text. You can view it online here:
<https://open.lib.umn.edu/largeanimalsurgery/?p=728>

Upper respiratory endoscopy supplement

These videos give you a bit of an overview on normal endoscopy



A YouTube element has been excluded from this version of the text. You can view it online here: <https://open.lib.umn.edu/largeanimalsurgery/?p=815>



A YouTube element has been excluded from this version of the text. You can view it online here: <https://open.lib.umn.edu/largeanimalsurgery/?p=815>

Malone's ppt: [ABNORMALNOISE anatomy](#)



An interactive or media element has been excluded from this version of the text. You can view it online here: <https://open.lib.umn.edu/largeanimalsurgery/?p=815>

RESOURCES

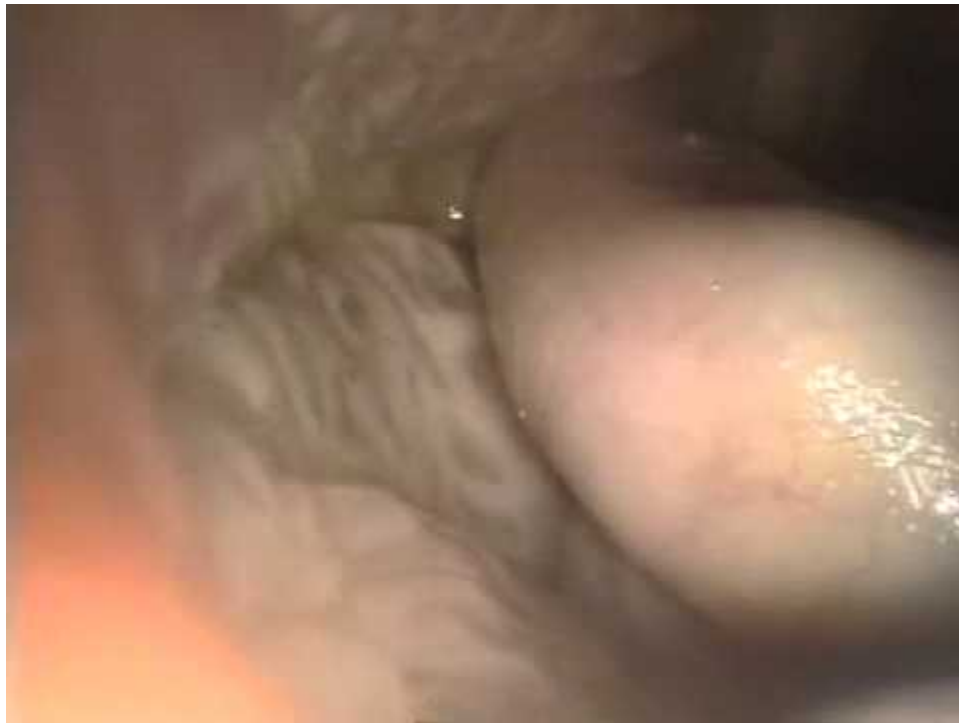[Upper Airway Conditions affecting the Equine Athlete](#), VCNA: Equine Practice, August 2018, Vol.34(2), pp.427-441

Exercise 5

Bugsy 1

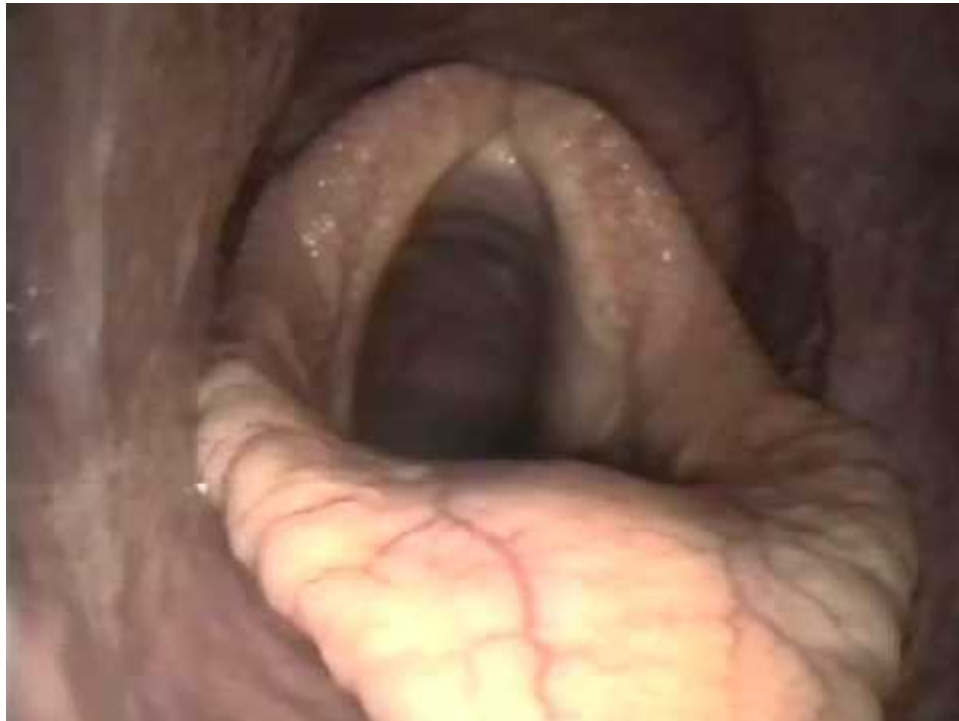“Bugsy” is a 2 yo Thoroughbred racehorse. He is not living up to this potential and is making noise when racing. You are asked to evaluate him and identify treatment options.

Your boss just bought a scope so you pull it out and scope the horse:

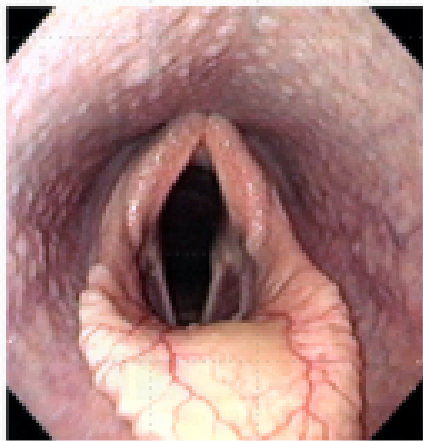


A YouTube element has been excluded from this version of the text. You can view it online here: <https://open.lib.umn.edu/largeanimalsurgery/?p=2575>

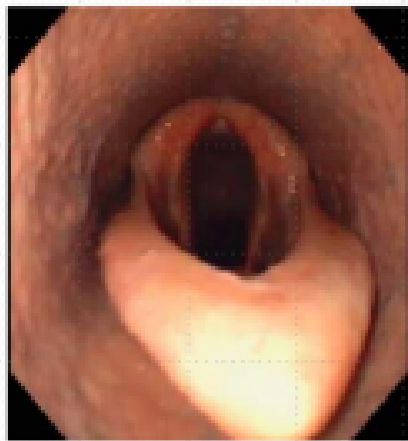For comparison, this one is normal:



A YouTube element has been excluded from this version of the text. You can view it online here: <https://open.lib.umn.edu/largeanimalsurgery/?p=2575>



Normal



Bugsy

What does the epiglottis do? How and when does it move?

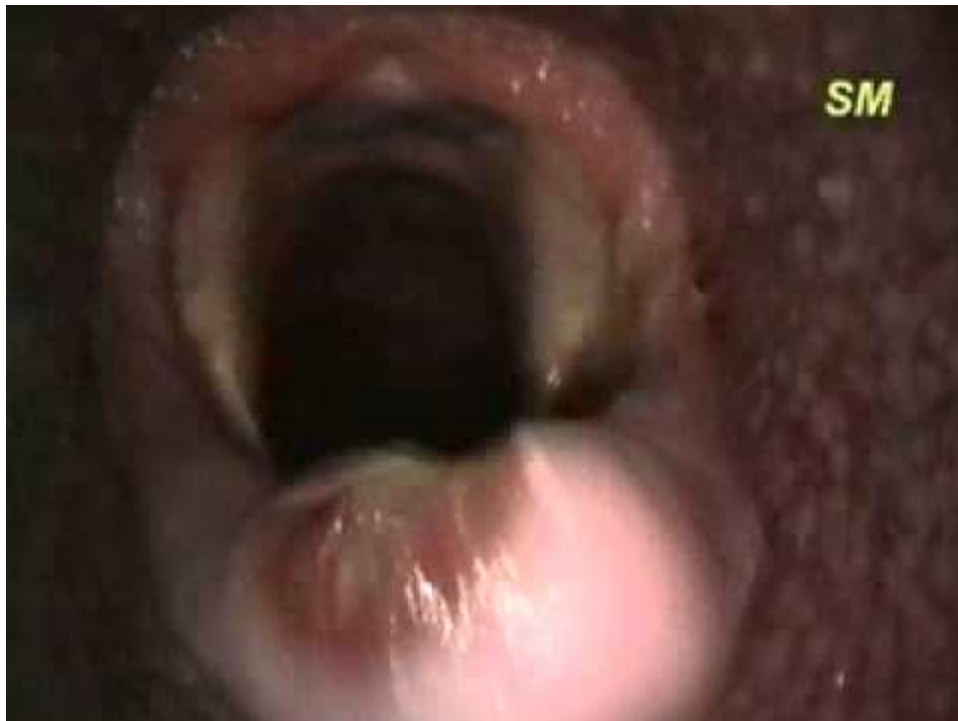Noise is caused by narrowed airways or vibrating structures (think heart murmurs).

What type of noise would you expect from this lesion?

1. No noise
2. Vibration – > noise
3. Narrowed airway -> noise

How would you confirm your hypothesis?

You find :



A YouTube element has been excluded from this version of the text. You can view it online here: <https://open.lib.umn.edu/largeanimalsurgery/?p=2575>

What treatment would you recommend to the owner? Use lay terminology as if you were speaking to the client.

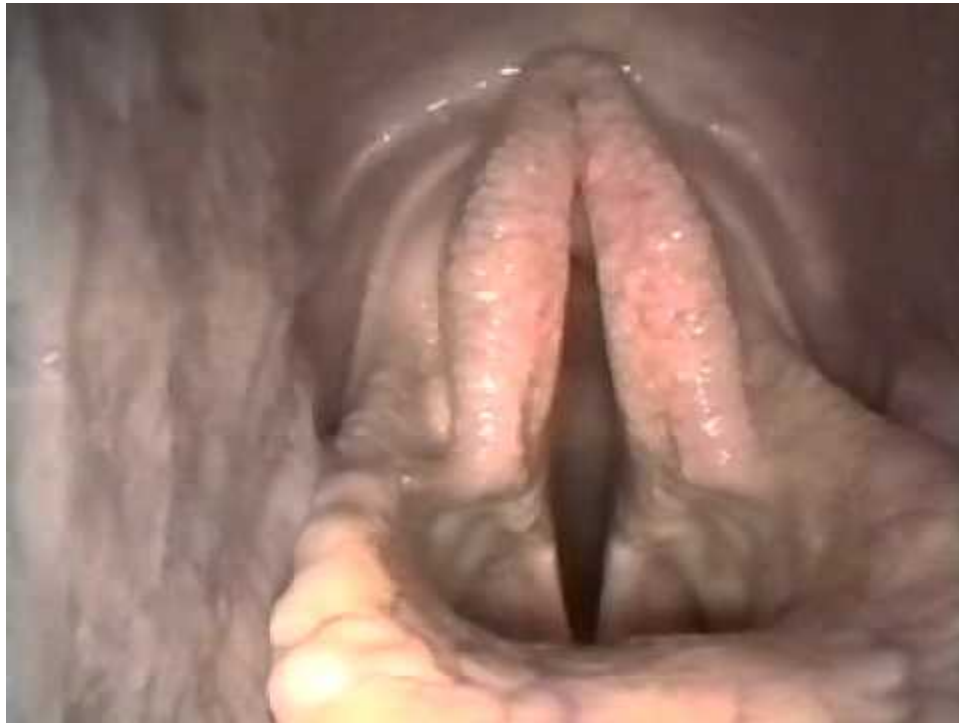What treatment did you **not** recommend to the owner? Why did you skip that one?

What resource did you use for this question?

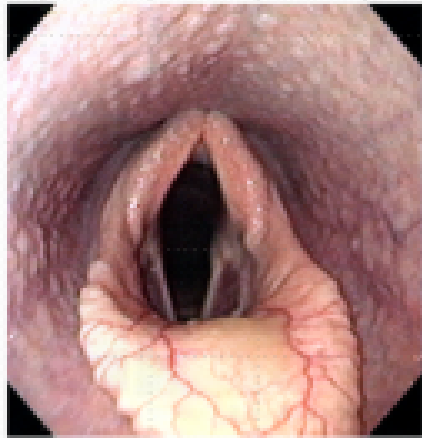
Exercise 6

Bugsy 2

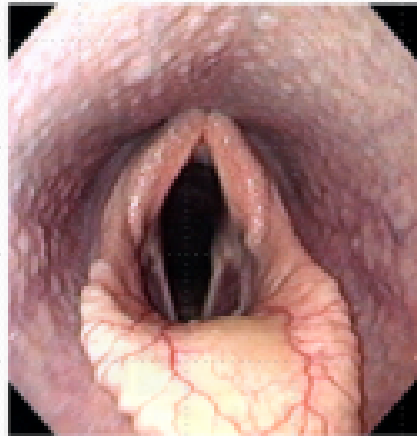
You scope Bugsy and see this instead:



A YouTube element has been excluded from this version of the text. You can view it online here: <https://open.lib.umn.edu/largeanimalsurgery/?p=2582>



Normal



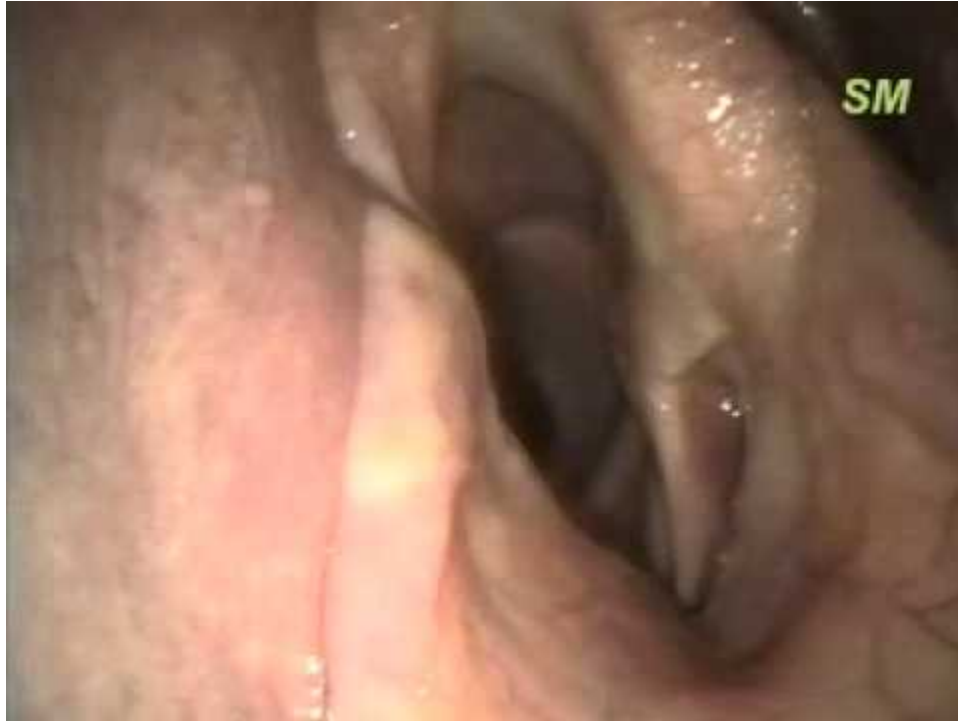Bugsy2

He is still making noise. You tell the client you need to put him on the treadmill and you see

What are your odds of seeing something different at exercise vs standing?

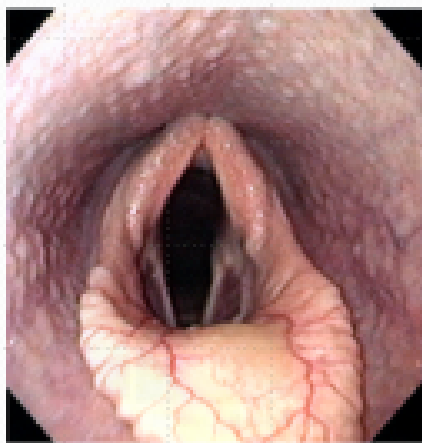
What resource did you use to answer that?

You see

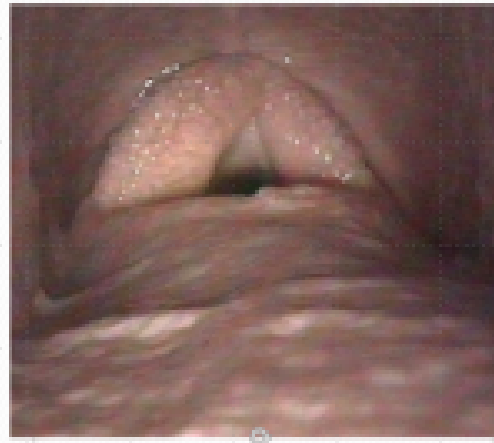


A YouTube element has been excluded from this version of the text. You can view it online here: <https://open.lib.umn.edu/largeanimalsurgery/?p=2582>

Next time you scope him standing you see :



Normal



Bugsy

What is your diagnosis?

What treatment do you recommend? Use lay terminology as if you were speaking to the client.

498 Large Animal Surgery

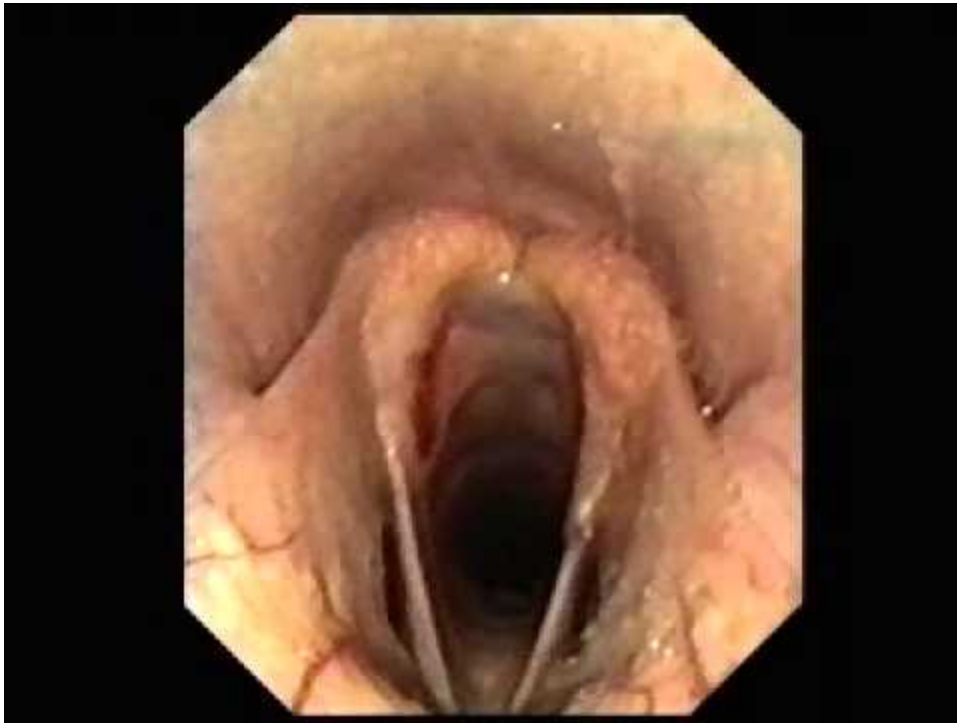What treatment do you not recommend and why?

Resource used:

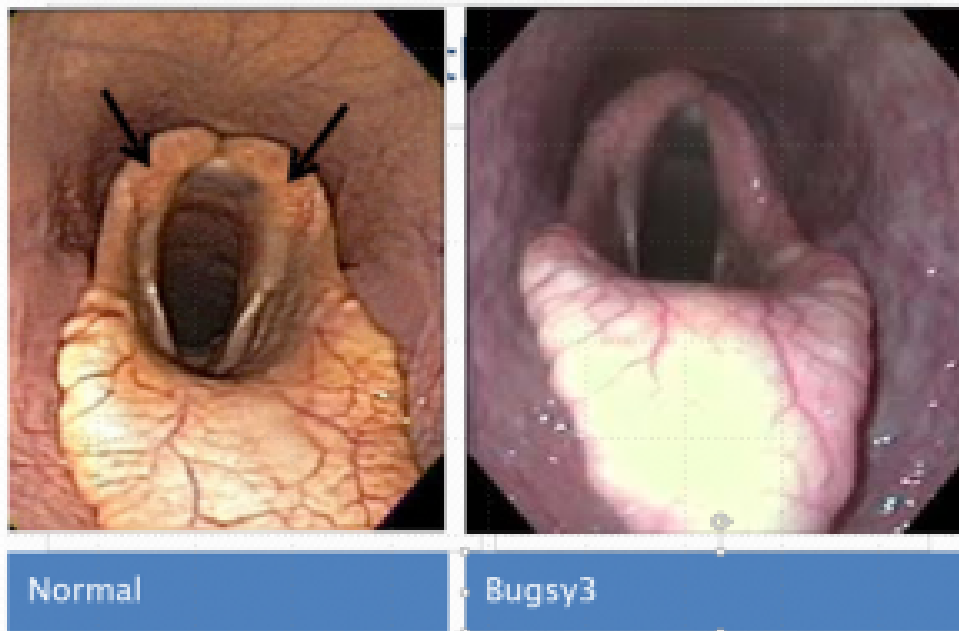
Exercise 7

Bugsy 3

When you scope Bugsy3 you see



A YouTube element has been excluded from this version of the text. You can view it online here: <https://open.lib.umn.edu/largeanimalsurgery/?p=2584>



What is your diagnosis?

What is your treatment recommendation? Use lay terminology as if you were speaking to the client.

What did you not recommend and why?

Resource:

[Bugsy answer key](#)

Exercise 8

Challenge questions

Find a picture of each of the following

- Arytenoid chondritis
- Aryepiglottic fold collapse
- 4-BAD/ rostral displacement palatopharyngeal arch
- Pharyngeal collapse
- Pharyngeal lymphoid hyperplasia

Which of these disorders would be life-threatening if any?

- Arytenoid chondritis
- Aryepiglottic fold collapse
- 4-BAD/ rostral displacement palatopharyngeal arch
- DDSP
- Epiglottic entrapment
- Laryngeal hemiplegia
- Pharyngeal collapse
- Pharyngeal lymphoid hyperplasia

What if either of these were bilateral?

- Arytenoid chondritis
- Laryngeal hemiplegia

For each that are life-threatening, what would be the first step?

Bovine Lameness

Bovine Lameness

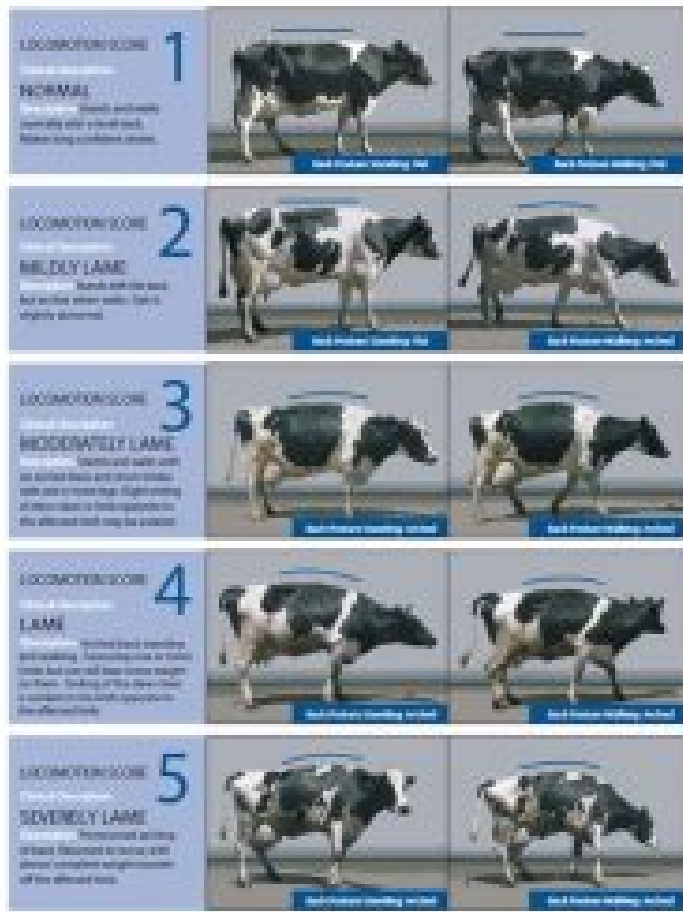Bovine lameness is heavily underdiagnosed. In the midwest, the level of lameness in cattle is 13-16%. Herdsmen recognize less than 1/2 of the cases. Lameness is a big cause of economic loss and is often a herd problem.

Indications of lameness

- posture/loading- where are they moving weight too? is the back arched?
- ability to rise- typically get to knees first, then butt up
- willingness to ambulate
- symmetry -lameness site may be bilateral
- ease of gait
- joint mobility- sinking in fetlock = good leg
- pressure sores – look to the opposite side

[Locomotion scoring of dairy cattle](#)

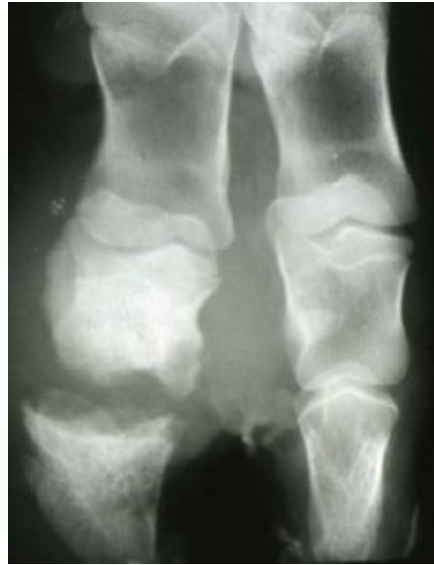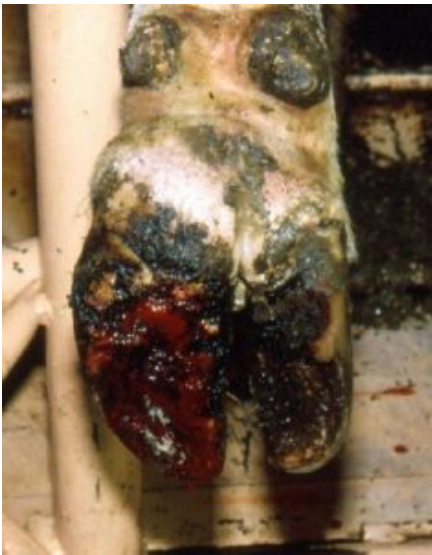Locomotion Scoring of Dairy Cattle*



70-80% of lameness in foot with lateral hind digit most common.

To localize –

- PE
- Lesions
- regional or IA blocks – can use regional perfusion with lidocaine
- radiographs



Septic synovitis (joints, tendon sheaths and bursas)

Infections can enter via direct inoculation (wound or injection), local infection (eg via hoof ulcer or foot rot) or via blood supply (infection elsewhere). Hematogenous is most common in neonates, especially for the larger joints, but can be seen in all ages and can affect multiple joints. Adults can get hematogenous spread, especially to sites of injury even with no direct penetration.

Animals are nonweight bearing and the area is often swollen and painful. Cytology can be useful but cows produce lots of neutrophils. Infected if $>40K$ cells/ul. Evaluate colostral absorption in neonates.

Treatment is high volume lavage (generally need arthrotomy per Malone*; don't do that per Trent), potentially regional perfusion (but not many drugs available anymore), NSAIDs and ideally 4 weeks systemic antibiotics. Animals will generally need restricted exercise for pain control. Physical therapy may be required to minimize limb contracture, especially in young animals.

*In cattle, you just end up flushing the tract. The fibrin is so thick that you can't flush it. Arthrotomies are often necessary to actually flush the junk out – at least in my hands. EDM.

With chronic infection in the distal limb (pastern or coffin joint), you can amputate the distal limb or arthrodese the joint. Amputation works best in unilateral lesions in smaller stature animals that are not housed on slatted floors. Expect 18 months in the herd. Arthrodesis is generally needed for bulls, heavy animals, uneven flooring, and valuable animals. Referral is recommended.

Prognosis depends on rapidity and effectiveness of early treatment.

Bony changes develop fast in cattle but still take 4-5 days. If there is infection near bone, it will develop extensive periosteal reaction. Bones will also lyse when infected. Cow pus is also so thick that it will physically push the bones apart, widening the joint space.

Bovine Foot Conditions



A YouTube element has been excluded from this version of the text. You can view it online here: <https://open.lib.umn.edu/largeanimalsurgery/?p=1869>



A YouTube element has been excluded from this version of the text. You can view it online here: <https://open.lib.umn.edu/largeanimalsurgery/?p=1869>



A YouTube element has been excluded from this version of the text. You can view it online here: <https://open.lib.umn.edu/largeanimalsurgery/?p=1869>



A YouTube element has been excluded from this version of the text. You can view it online here: <https://open.lib.umn.edu/largeanimalsurgery/?p=1869>

Important foot anatomy

Deep flexor tendon attaches on the bottom of P3 at the flexor tuberosity. The pressure of this tuberosity creates sole ulcers.

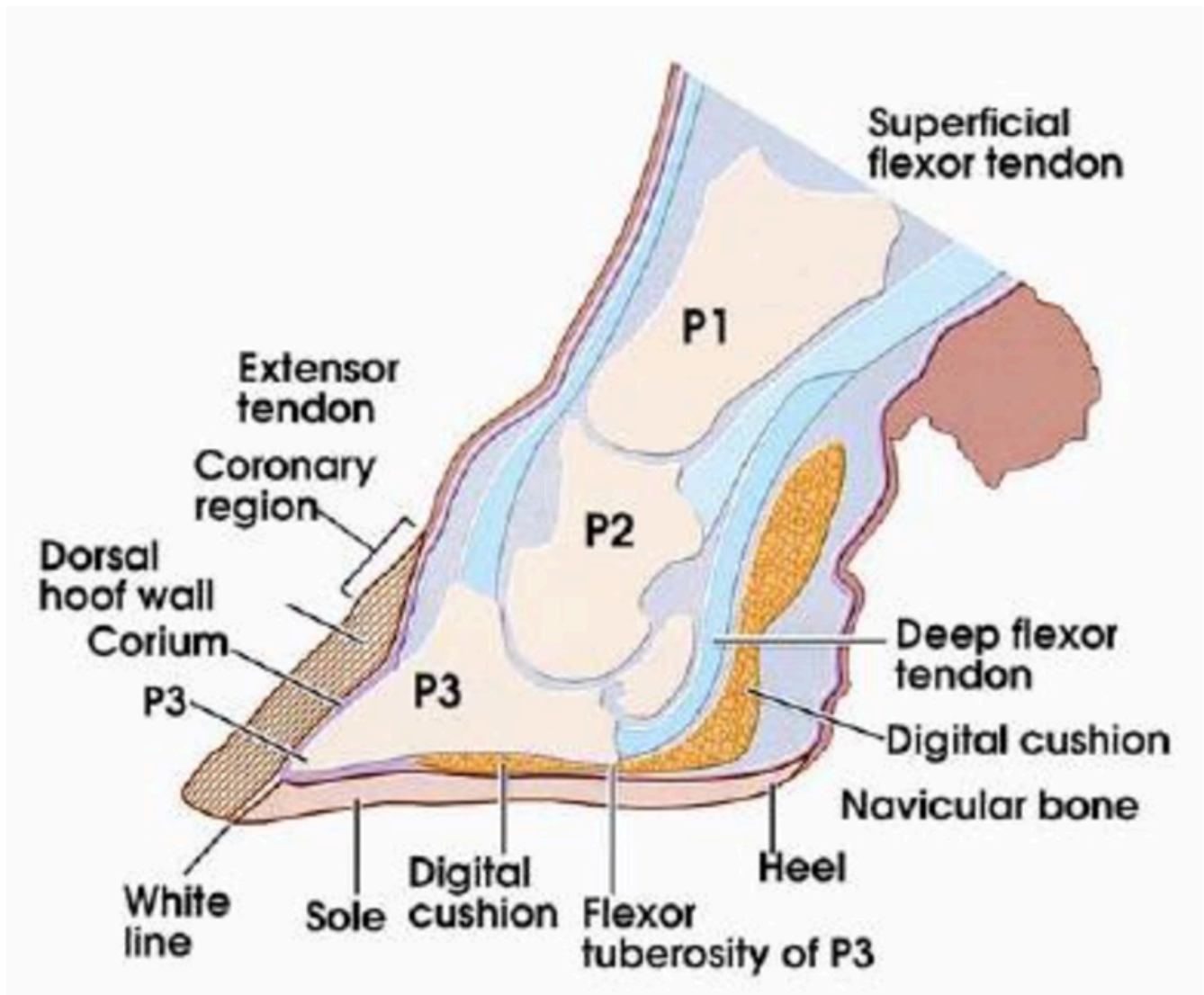
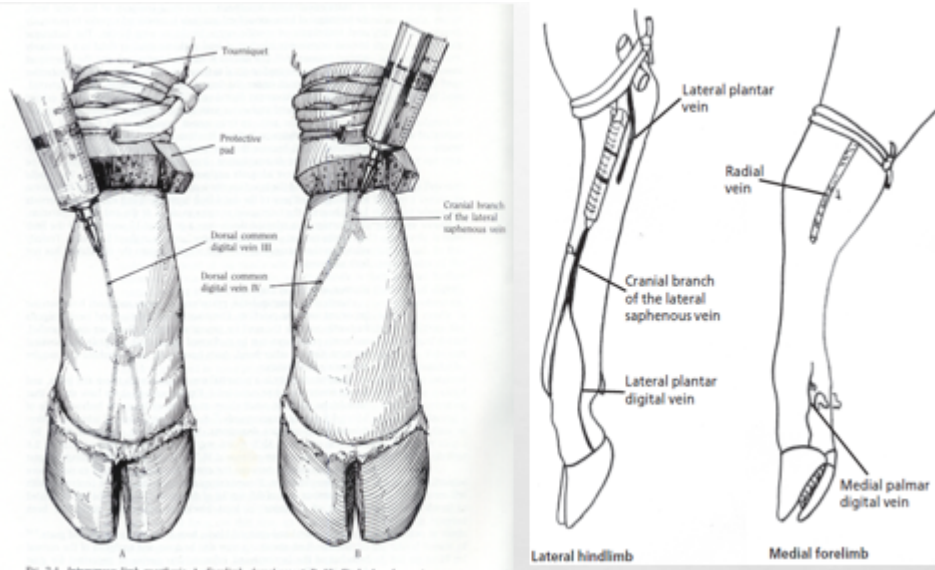
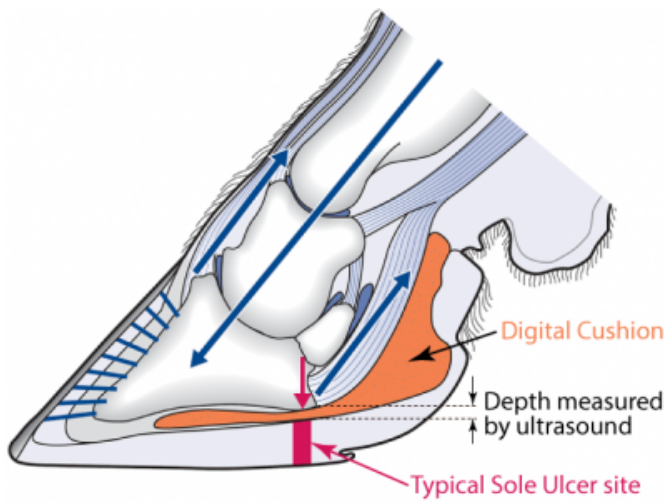


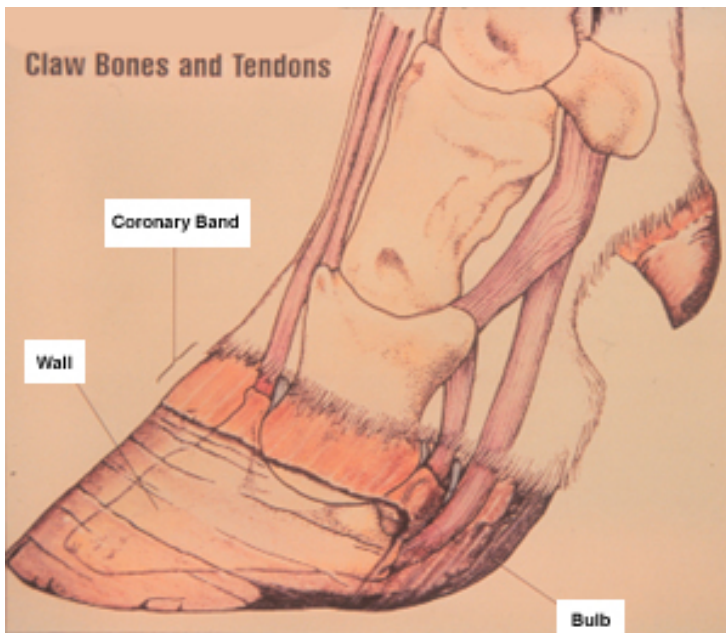
Figure 2: Anatomy of a cow claw (Gooch 2003)

Need to know the location of the veins so you can perform regional anesthesia (these are really hard to see on a live animal with a swollen limb). The best ones are dorsal and just in front of the dewclaws.



The digital cushion gets thinner as the cow goes through each lactation. This is supposed to dissipate her weight (and keep the flexor tuberosity padded).





Foot is suspended by ligaments, rather than by laminae. So not laminitis but stretching of ligaments.



An interactive or media element has been excluded from this version of the text. You can view it online here:
<https://open.lib.umn.edu/largeanimalsurgery/?p=1869>

Joint issues

Osteochondrosis

Osteochondrosis is much less common in cattle. It is seen in bulls and fattening steers. Generally not treated.

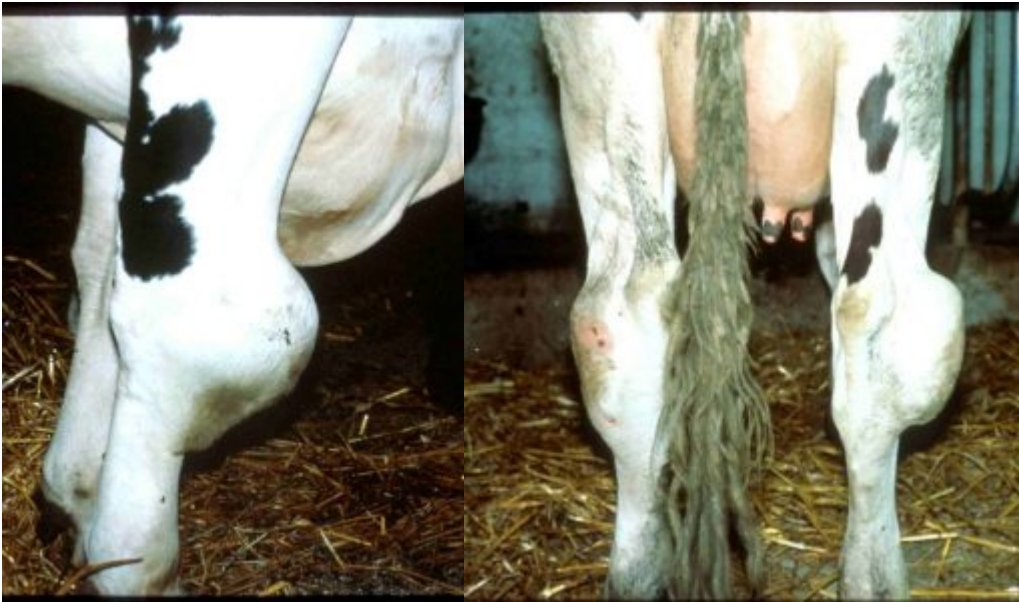Hygromas

Hygromas are extra-articular swellings that occur on the lateral aspects of the hocks or the dorsum of the carpus.

These may reflect poor bedding or housing.

They are not an issue unless they become infected.

Removal is difficult. Drain abscesses.

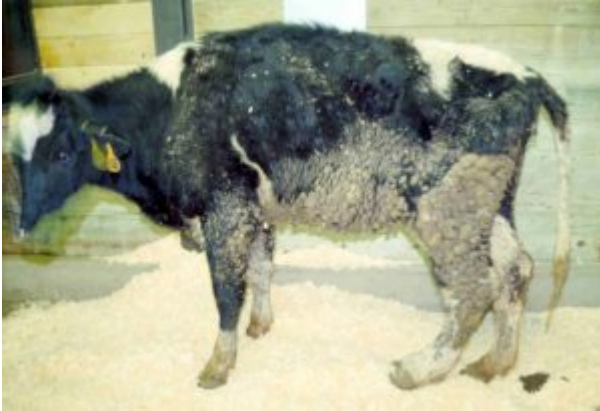

Cruciates

See ligament chapter

Tendon and ligament issues

Flexor tendon lacerations are common. If the toe is tipped up = deep digital flexor laceration. If the fetlock is dropped = superficial digital flexor lacerations.



Damage to both superficial and deep flexor tendons

Treatment : Debride and cast or debride and splint. Suturing doesn't really help. Can be quite functional but takes 10-12 weeks for stable fibrous union.

Prognosis can be okay if flexor tendons and not in the tendon sheath.

Gastrocnemius tendon lacerations are bad. Hock will be dropped. Treatment is Schroeder-Thomas



Dr. Trent with goat with dropped hock

Extensor tendon lacerations have a good prognosis. Initially the animal cannot advance the leg well but they come around.

Cruciate injuries are bad. These are most commonly seen in heavy postparturient cattle with milk fever-difficulty standing and fall. Mild to moderate lameness with joint effusion. Can do a drawer sign but tricky and can only try once. Cow has to be weight standing and you stand behind, shoulder into stifle and pull. Surgery required; referral procedure.

Tendon contractures

Treatment involves physical therapy, pain relief, and progressive splinting. Oxytetracycline can be useful in neonates (relaxes the muscle-tendon unit). Surgery may be needed. Often the joint capsule is involved in congenital lesions making surgery ineffective.

Neuromuscular conditions

Spastic paresis (Elsso Heel)



Genetic, multifactorial condition seen in Angus and Holsteins. Primarily contraction of the gastrocnemius muscle. Starts with very straight leg, then can't bring leg forward, then leg held behind. Accompanied by raised tail head (looks like tetanus and shivers).

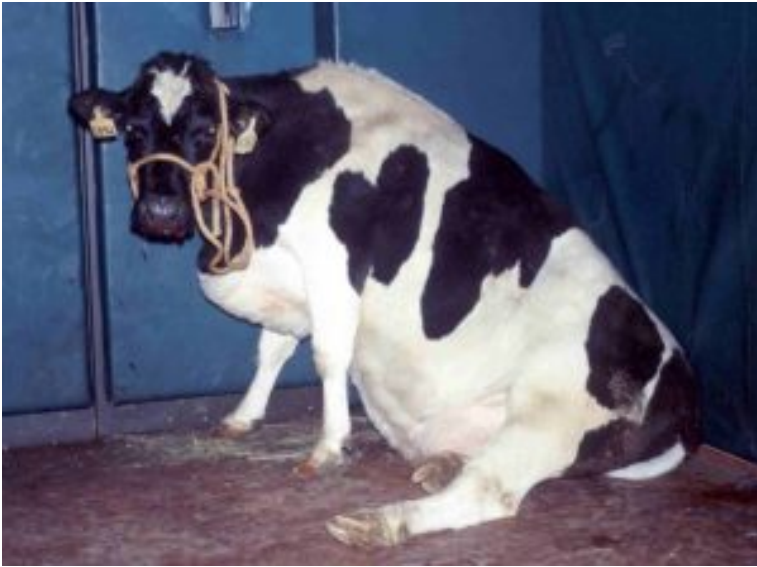Goal of therapy (tenectomy and/or neurectomy) is to get to slaughter rather than to maintain in herd.

Spastic syndrome (Stable Cramps)

Spastic nerve paresis

Femoral/obturator paresis – often related to parturition or falling with legs back . Treat with floating, NSAIDs, lifting

Calves can get this with hip lock dystocias.



Radial/brachial plexus – humeral fractures, rapid abduction (fall on ice), recumbent without padding. Treat with supportive care, splinting, NSAIDs, padding and floating. Splint down the back of the limb to help fix the triceps.

Calving injuries

Cannon bone fractures -Most common injury

Tends to be distal physis of cannon bone. Usually closed, simple and relatively stable if can get aligned. It is sometimes accompanied by vascular damage – this will show up later and can delay or prevent healing. Calves may not have stood to nurse or absorbed colostrum well, so may need colostrum.

Treat with cast or Schroeder-Thomas splint. Full limb is ideal to stabilize joint above and below the fracture (but can sometimes get by with a half limb cast if distal enough.)

Prognosis is guarded due to potential for blood supply damage. Will find out at cast change at 2-3 weeks.

Cast cutters can cut skin! Especially in LA with minimal soft tissue coverage. If you create a wound, do not close it (fiberglass particles in the wound).

Rib fractures

Related to posterior/breech presentation. Need careful palpation to diagnose. Can rupture thoracic vessels. Treatment involves restricted exercise and/or stabilization. Flail chests require stabilization

Jaw fractures

Related to jaw pullers and dystocia. Check for colostrum absorption. These have a variety of stabilization options but need something.

Slipped capital femoral epiphysis

The physis is weaker than the round ligament of the femur. Instead of hip luxation, the physis breaks. Hip stays in, femur gets loose. See with hip lock dystocia – often double muscled breeds. May not notice for awhile. Radiographs useful for diagnosis. Prognosis is fair with surgery, poor otherwise. FHOs are not a good option in cattle.

Femoral nerve paresis “patellar luxation”

Not truly patellar luxation but quadriceps not working. Usually congenital. Lateral luxation, bilaterally. The problem is with the femoral nerve – as the patellar doesn't move correctly the groove doesn't form properly. Calves will have a crouched stance. Poor prognosis if no return of nerve function.

Adult fractures and luxations

Cannon bone fractures

These are high energy fractures and are often comminuted and open. Fixation requires full limb cast or transfixation cast. Prognosis is better in cattle than in horses but poor if open and articular.

Radial and tibial fractures

Better in cattle than horses but need transfixation cast or external fixateur apparatus. A regular cast does not usually work unless really distal radial fracture. Internal fixation is great but often too costly. Internal fixation does not work in calves as their bone is too soft.

Femoral fractures

We cannot fix these but they will often heal on their own as the musculature will stabilize it. Need good bedding and nursing care. The limb may end up with abnormal conformation.

Coxofemoral luxation

Caused by sudden hyperextension. Generally poor prognosis but need referral.

Patellar luxation

Can be treated with imbrication but challenging in larger animals.

Calf injuries



An interactive or media element has been excluded from this version of the text. You can view it online here:
<https://open.lib.umn.edu/largeanimalsurgery/?p=2356>

Food Animal Drug Regulations

Keeping our food supply safe is crucial for all of us. It is also likely that our food sources will change and we will need to understand the basic principles regardless of species interests.

Regulatory Concerns

Ensuring we don't have unwanted drugs in our food supply is an important component of working with food producing species. In the USA, these species are primarily cattle, swine and chickens. Since we generally don't do surgery on chickens, those aren't discussed here. Sheep, goats and camelids are food producing animals but are considered as minor species and have different guidelines. While most pot bellied pigs are not considered food animals, they are still swine and must meet federal guidelines.

FARAD, the food animal residue avoidance databank, should be your first step for determining whether or not a drug can be used in your patient. FARAD is highly useful but can be confusing as it serves many different groups. And not everything you will want to know is on there. This section will help you navigate FARAD, let you practice applying drug withholding information to cases, and expand your ability to find information elsewhere.

RESOURCES

[Milk and dairy beef residue manual](#), 2019

[Drug residues in poultry – a review](#); 2018 JVPT


[More resources](#) including Veterinary Feed Directive

[Extralabel drug use for mixed and small animal practitioners](#), NCSU CVM 2019 Forum

[Honeybees 101: a guide for veterinarians](#), 2017 AVMA

Navigating FARAD

Open up a browser window and go to FARAD.org. Scan through the four orange boxes below the image to explore the site.



Prohibited and Restricted Food Animal Drugs

Under AMDUCA the FDA can prohibit use of an entire class of drugs in selected animal species.

[Learn more...](#)

Request Advice For Extra-Label Drug Use (ELDU)	Search VetGRAM For FDA Approved Food Animal Drugs	WDI Lookup For FARAD Withdrawal Recommendations	Search Citations From our Bibliographic Database
---	--	--	---

There are more links below those too – this seems to be the new version of the boxes.

Request Advice For Extra-Label Drug Use (ELDU)	Search VetGRAM For FDA Approved Food Animal Drugs	WDI Lookup For FARAD Withdrawal Recommendations	Search Citations From our Bibliographic Database
---	--	--	---

Species Specific resource for poultry, cattle, bees and more... [Visit this website!](#) [¡Ahora en español!](#)

Feature Pages Animal Use Classes GRAS PMO VFD Information Combination Drugs	Quick Links Request ELDU Advice Species Specific Prohibited Drugs Search VetGRAM WDI Lookup	References US Food Animals AMDUCA Food Animal News FARAD History FARAD Digests	Help Pages Acronyms Common Terms VetGRAM-HELP Search FARAD Website Info
---	---	--	---

Use the following exercises to help you get more comfortable with the site.

As you work through these, also try to differentiate between

534 Large Animal Surgery

- FDA approved drugs
- non-FDA approved drugs with recommended withholding times
- drugs that can be used under AMDUCA guidelines, with or without recommended withholding times
- drugs that cannot be used in food animals or certain food animal groups regardless

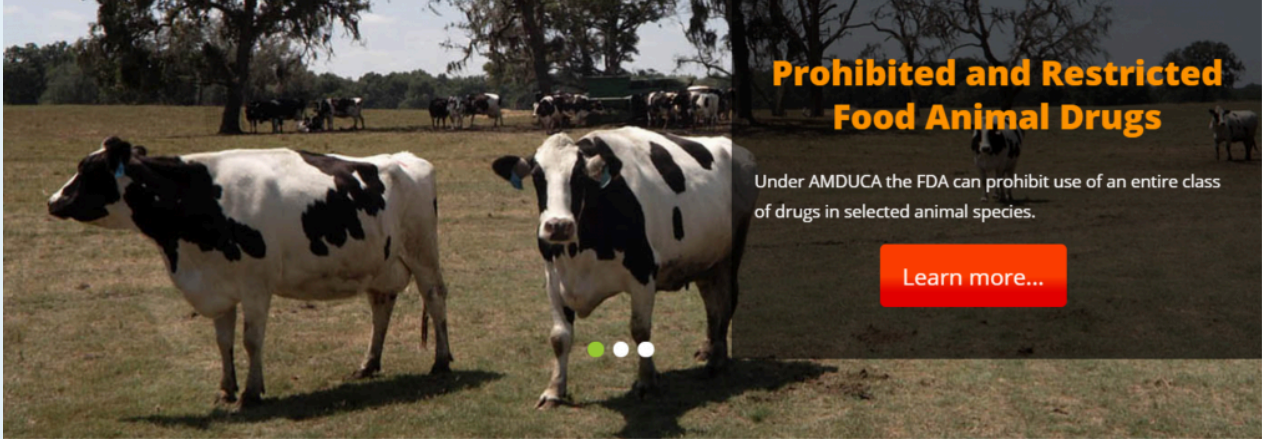
[FARAD tour](#) (the links and how to use them are similar, just not the front page)

[Guide to FARAD Resources](#), JAVMA 2017

Exercise 1 Finding approved drugs

Exercises

Use the approved drug search function <http://www.farad.org/vetgram/search.asp> to answer the questions below.



Prohibited and Restricted Food Animal Drugs

Under AMDUCA the FDA can prohibit use of an entire class of drugs in selected animal species.

[Learn more...](#)

Request Advice
For Extra-Label Drug Use (ELDU)

Search VetGRAM
For FDA Approved Food Animal Drugs

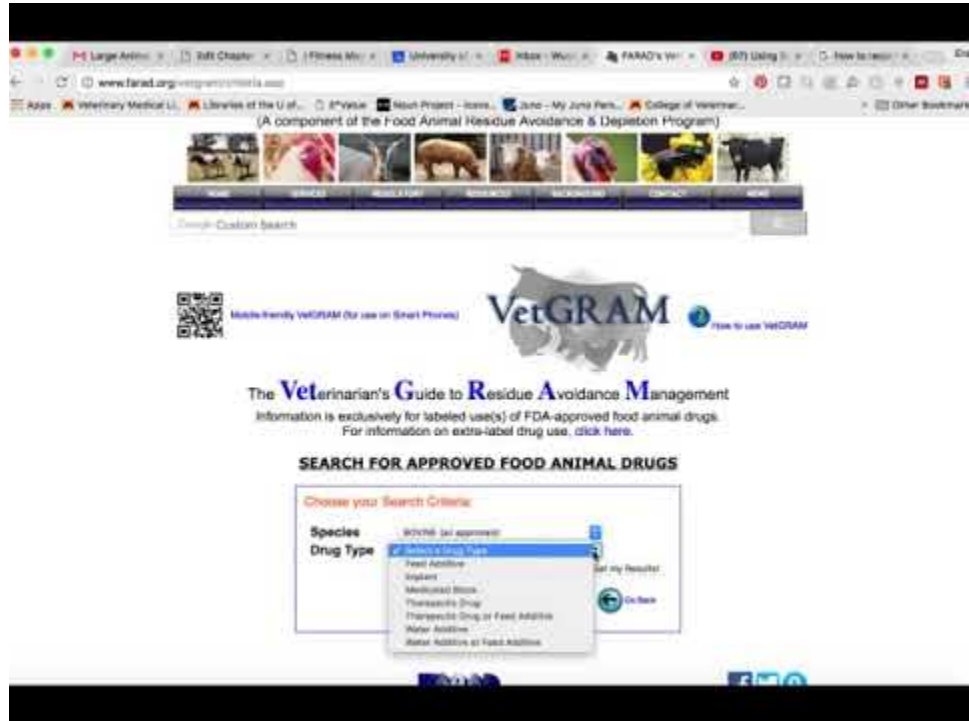
WDI Lookup
For FARAD Withdrawal Recommendations

Search Citations
From our Bibliographic Database



An interactive or media element has been excluded from this version of the text. You can view it online here:
<https://open.lib.umn.edu/largeanimalsurgery/?p=65>

Try it on your own first. After you are familiar with the tab, this video may help make the process more efficient:



A YouTube element has been excluded from this version of the text. You can view it online here: <https://open.lib.umn.edu/largeanimalsurgery/?p=65>

Exercises

Try your new skills again:



An interactive or media element has been excluded from this version of the text. You can view it online here: <https://open.lib.umn.edu/largeanimalsurgery/?p=65>

Exercise 2 AMDUCA

Exercises

[AMDUCA guidelines](#) are also on the FARAD site. See if you can find them to answer the following:



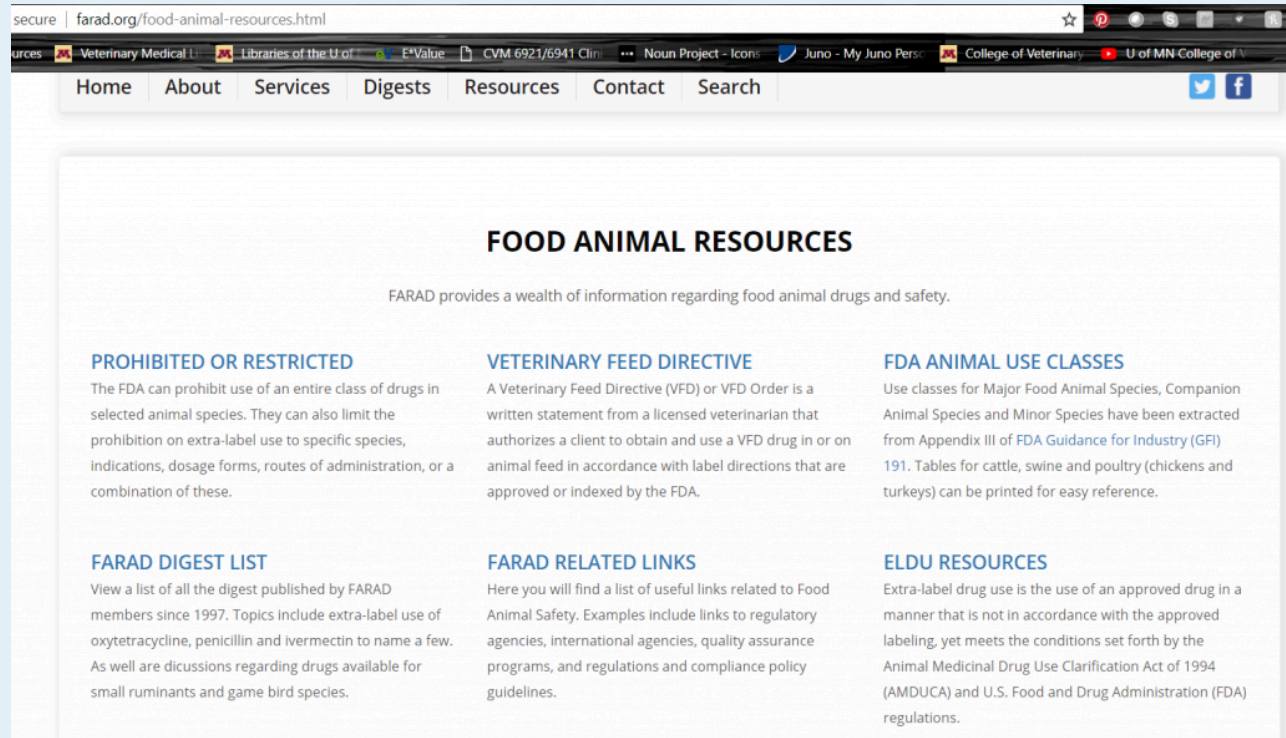
An interactive or media element has been excluded from this version of the text. You can view it online here:
<https://open.lib.umn.edu/largeanimalsurgery/?p=84>

Struggling? Read more about [what is considered Extra-label Drug Use](#).

Exercise 3 Illegal and restricted use drugs

Exercises

Use the FARAD site to find those [drugs that you can't use in food animals](#).



The screenshot shows a web browser window with the URL farad.org/food-animal-resources.html. The page has a navigation menu with links for Home, About, Services, Digests, Resources, Contact, and Search. The main content area is titled "FOOD ANIMAL RESOURCES" and includes a sub-header "FARAD provides a wealth of information regarding food animal drugs and safety." Below this, there are six columns of text, each with a heading and a brief description:

- PROHIBITED OR RESTRICTED**: The FDA can prohibit use of an entire class of drugs in selected animal species. They can also limit the prohibition on extra-label use to specific species, indications, dosage forms, routes of administration, or a combination of these.
- VETERINARY FEED DIRECTIVE**: A Veterinary Feed Directive (VFD) or VFD Order is a written statement from a licensed veterinarian that authorizes a client to obtain and use a VFD drug in or on animal feed in accordance with label directions that are approved or indexed by the FDA.
- FDA ANIMAL USE CLASSES**: Use classes for Major Food Animal Species, Companion Animal Species and Minor Species have been extracted from Appendix III of FDA Guidance for Industry (GFI) 191. Tables for cattle, swine and poultry (chickens and turkeys) can be printed for easy reference.
- FARAD DIGEST LIST**: View a list of all the digest published by FARAD members since 1997. Topics include extra-label use of oxytetracycline, penicillin and ivermectin to name a few. As well are discussions regarding drugs available for small ruminants and game bird species.
- FARAD RELATED LINKS**: Here you will find a list of useful links related to Food Animal Safety. Examples include links to regulatory agencies, international agencies, quality assurance programs, and regulations and compliance policy guidelines.
- ELDU RESOURCES**: Extra-label drug use is the use of an approved drug in a manner that is not in accordance with the approved labeling, yet meets the conditions set forth by the Animal Medicinal Drug Use Clarification Act of 1994 (AMDUCA) and U.S. Food and Drug Administration (FDA) regulations.



An interactive or media element has been excluded from this version of the text. You can view it online here:
<https://open.lib.umn.edu/largeanimalsurgery/?p=98>

Exercises

The terminology can be tricky. Use the [terminology page](#) to answer the following:



An interactive or media element has been excluded from this version of the text. You can view it online here: <https://open.lib.umn.edu/largeanimalsurgery/?p=98>

Exercises

Potbellied pigs are also a challenge:



An interactive or media element has been excluded from this version of the text. You can view it online here: <https://open.lib.umn.edu/largeanimalsurgery/?p=98>

How I would go about figuring this out:

ABOUT FARAD:

The Food Animal Residue Avoidance Databank (FARAD) is part of the Food Animal Residue Avoidance & Depletion Program, which has served the veterinary profession for more than 35 years. FARAD is supported by the USDA National Institute of Food and Agriculture (NIFA) and is staffed by highly-trained veterinary pharmacologists, toxicologists and food animal specialists at five colleges of veterinary medicine at the University of California-Davis, University of Florida, North Carolina State University, Virginia-Maryland and Kansas State University. The overarching goal of FARAD is to provide current and accurate scientific information to veterinary practitioners and thereby foster production of animal-derived human foods that are devoid of unsafe chemical residues, including drugs, pesticides, natural toxins and environmental contaminants. To fulfill this goal, FARAD provides open access to comprehensive up-to-date information and data resources for food animal drugs and, through research and outreach activities, FARAD provides science-based estimates of safe withdrawal intervals for food-producing animal species that have been treated with or exposed to drugs or other chemicals.

Learn more. >

A YouTube element has been excluded from this version of the text. You can view it online here: <https://open.lib.umn.edu/largeanimalsurgery/?p=98>

And just in case you need a reminder of food animal potential:

[Molly gets rescued and eaten](#)

Exercise 4 Identifying withholding times

Exercises

Use the withdrawal recommendation look up <http://www.farad.org/wdilookup/> to find the withholding on lidocaine used for a local block in a dairy cow.



An interactive or media element has been excluded from this version of the text. You can view it online here:

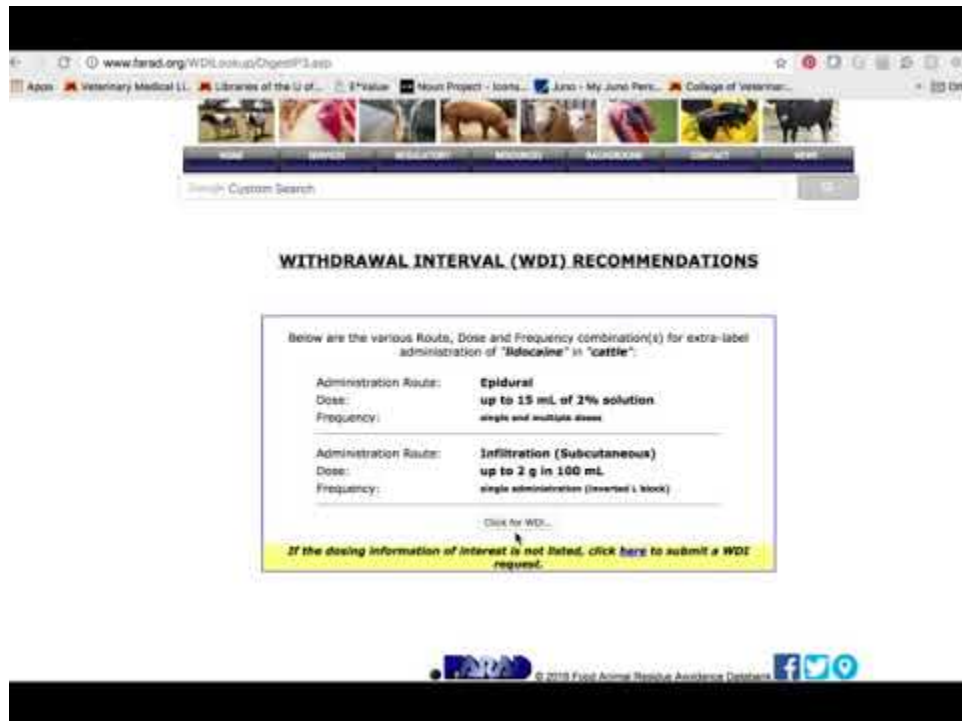
<https://open.lib.umn.edu/largeanimalsurgery/?p=70>

Exercises

What about xylazine? Is it FDA approved? Can you find withholding information?

Obviously we often use drugs that are not FDA-approved but that does mean we have to carefully follow AMDUCA guidelines (and are not uniformly good at doing so). While we tend to consider FARAD calculated withholding times as “approved” this does not equate to FDA approved drugs and label withholding.

RESOURCES



The screenshot shows a web browser window with the URL www.farsd.org/WDLookup/CgrefP3.asp. The browser's address bar and tabs are visible. Below the browser window, the page content is displayed. The main heading is "WITHDRAWAL INTERVAL (WDI) RECOMMENDATIONS". Below this heading, a text box contains the following information:

Below are the various Routes, Dose and Frequency combination(s) for extra-label administration of "lidocaine" in "cattle":

Administration Route:	Epidural
Dose:	up to 15 mL of 2% solution
Frequency:	single and multiple doses
Administration Route:	Infiltration (Subcutaneous)
Dose:	up to 2 g in 100 mL
Frequency:	single administration (Inverted L block)

Below the table, there is a link: [Click for WDI...](#). At the bottom of the text box, there is a yellow banner with the text: **If the dosing information of interest is not listed, click [here](#) to submit a WDI request.**

At the bottom of the page, there is a footer with the text: © 2010 Food Animal Residue Avoidance Databank. To the right of the footer, there are social media icons for Facebook, Twitter, and YouTube.

A YouTube element has been excluded from this version of the text. You can view it online here: <https://open.lib.umn.edu/largeanimalsurgery/?p=70>

Food Animal Residue Avoidance Databank
(A component of the Food Animal Residue Avoidance & Depletion Program)

HOME SERVICES REGULATORY RESOURCES BACKGROUND CONTACT NEWS

Default Custom Search

SUBMIT A QUESTION ABOUT DRUG RESIDUE AVOIDANCE

VETERINARY MEDICINE FEED DIRECTIVE (VFD)

SPECIES SPECIFIC WEB PAGES

SEARCH FARAD

VetGRAM SEARCH FOR FDA-APPROVED ANIMAL DRUGS

RECOMMENDED DRUG WITHDRAWAL INTERVALS

PROHIBITED & RESTRICTED FOOD ANIMAL DRUGS

EXTRA-LABEL DRUG USE

ABOUT FARAD:
The Food Animal Residue Avoidance Databank (FARAD) is part of the Food Animal Residue Avoidance & Depletion Program, which has served the veterinary profession for more than 35 years. FARAD is supported by the USDA National Institute of Food and Agriculture (NIFA) and is staffed by highly-trained veterinary pharmacologists, toxicologists and food animal specialists at five colleges of veterinary medicine at the University of California-Davis, University of Florida, North Carolina State University, Virginia-Maryland and Kansas State University. The overarching goal of FARAD is to provide current and accurate scientific information to veterinary practitioners and thereby foster production of animal-derived

A YouTube element has been excluded from this version of the text. You can view it online here: <https://open.lib.umn.edu/largeanimalsurgery/?p=70>

If the drug is approved, the label should have the recommended withholding information (or a google search for the drug label should work).

See this example for [Ceftiofur](#) in swine

[Default withholding periods in New Zealand](#)

Exercise 5 MUMS Act

Exercises



An interactive or media element has been excluded from this version of the text. You can view it online here:

<https://open.lib.umn.edu/largeanimalsurgery/?p=103>

Minor Species: It is very expensive to get drugs approved; hence many drug manufacturers stop after one indication or species. Due to the limited financial gains from marketing for sheep and goats, these animals have limited to no approved drugs.

Minor Use: Similarly, it would not be financially acceptable for drug companies to test their drugs on every condition individually. The less common diseases (about everything except endotoxemia, fever, respiratory disease and footrot) don't often have approved drugs. Extra label use is required if not FDA approved drug exists.

The act was also designed to incentivize companies to actually get approval for these conditions and species but that has not worked very well.

[MUMS Act](#)

The UK uses [7 days milk/28 days meat minimum](#) withhold if the drug is not specifically licensed for goats.

Exercises



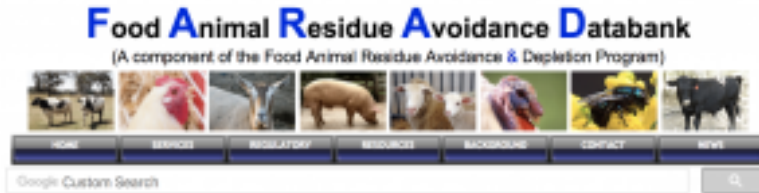An interactive or media element has been excluded from this version of the text. You can view it online here:

<https://open.lib.umn.edu/largeanimalsurgery/?p=103>

Exercise 6 Extrapolating withholding data

Particularly for minor use and minor species, you will not find a withholding time in FARAD for the particular species or route.

Google sometimes can be helpful. Other countries may consider the drug legal and have published withholding times. You can find some of these by using the search bar in FARAD:



This will result in some ads and in articles or publications that you might find useful (below the ads)

You can also search for similar species and/or routes. The closer you can get the better. Trying to extrapolate oral swine medications for subcutaneous use in an alpaca is unlikely to be close.

Exercises



An interactive or media element has been excluded from this version of the text. You can view it online here:
<https://open.lib.umn.edu/largeanimalsurgery/?p=95>

RESOURCES

amoxi-Inject (Cattle) No. **055-089** Approved Therapeutic Drug

Manufacturer: Zila, Inc.

Warnings: Each vial contains 25 g of amoxicillin activity as the trihydrate. The vial is reconstituted with sterile water for injection. USP is a combination of 200 mg/mL.

Warnings: As with all antibiotics, appropriate in vitro culturing and susceptibility testing of samples taken before treatment should be conducted.

Approved in: **Cattle, beef, all use classes; Cattle, dairy, all use classes**

Ingredient(s): amoxicillin trihydrate

Drug Class: Penicillin, amino derivatives

Drug Form: Injection, powder for solution

Identifiers: amoxicillin

Cattle, beef, all use classes

Use Withdrawal: 25 days
If administered on 3/5/2018 8:00:36 PM, DO NOT USE for meat (or by-products) before 4/0/2018 8:00:36 PM

Change Treatment Date

Indication: Intra-muscular; Subcutaneous

Directions: Use for the treatment of diseases due to amoxicillin-susceptible organisms as follows: respiratory tract infections (including fever, pneumonia) due to *Pasteurella multocida*, *P. hemolytica*, *Haemophilus agii*, *Streptococcus agalactiae*, and *Streptococcus equi*; and acute bacterial conjunctivitis (not use) due to *Pasteurella multocida*.

Precautions: Administer 3 mg per 8 mg/mL (not once daily) for up to 5 days. Continue for 48 hours to 72 hours after animal becomes afebrile or asymptomatic, but do not treat for more than 5 days.

Adverse Info: Maximum volume per injection should not exceed 30 mL/dose.

Cattle, dairy, all use classes

Use Withdrawal: 25 days
If administered on 3/5/2018 8:00:36 PM, DO NOT USE for meat (or by-products) before 4/0/2018 8:00:36 PM

Use Withdrawal: 96 hours
If administered on 3/5/2018 8:00:36 PM, DO NOT USE for milk (or by-products) before 2/19/2018 8:00:36 PM

Change Treatment Date

Indication: Intra-muscular; Subcutaneous

Directions: Use for the treatment of diseases due to amoxicillin-susceptible organisms as follows: respiratory tract infections (including fever, pneumonia) due to *Pasteurella multocida*, *P. hemolytica*, *Haemophilus agii*, *Streptococcus agalactiae*, and *Streptococcus equi*; and acute bacterial conjunctivitis (not use) due to *Pasteurella multocida*.

Adverse Info: Continue for 48 hours to 72 hours after animal

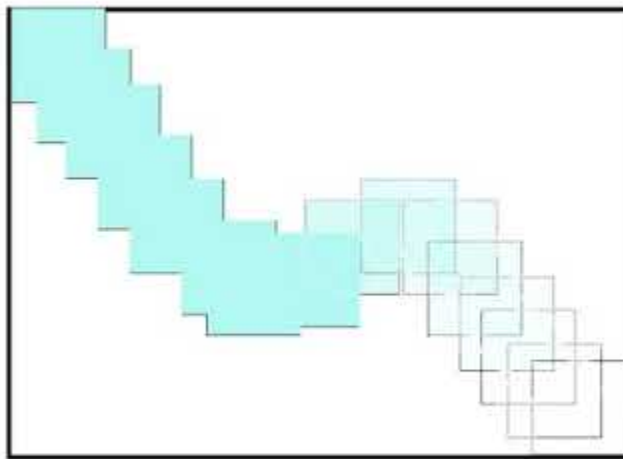
A YouTube element has been excluded from this version of the text. You can view it online here: <https://open.lib.umn.edu/largeanimalsurgery/?p=95>

[New Zealand withholding info](#)

[Neonatal adjustments](#), 2003 VCNA FA- extra information about physiological changes

Exercise 7 Understanding half lives

Adjusting withholding based on half lives can seem very complicated. However, if you can't find any reasonable estimates or what to use a different dose in a particular animal, some basic understanding can help you adjust your plans.



A YouTube element has been excluded from this version of the text. You can view it online here: <https://open.lib.umn.edu/largeanimalsurgery/?p=117>

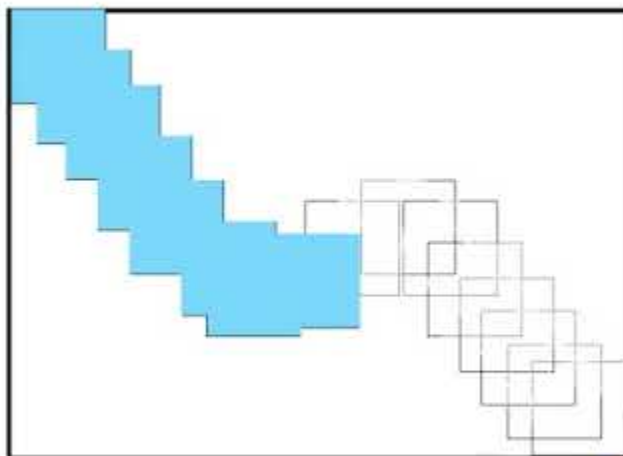
Exercises

What will need to happen to your withholding plans if you double the dose?



An interactive or media element has been excluded from this version of the text. You can view it online here: <https://open.lib.umn.edu/largeanimalsurgery/?p=117>

RESOURCES



A YouTube element has been excluded from this version of the text. You can view it online here: <https://open.lib.umn.edu/largeanimalsurgery/?p=117>

Challenge yourself!

Exercises

Challenge questions



An interactive or media element has been excluded from this version of the text. You can view it online here:
<https://open.lib.umn.edu/largeanimalsurgery/?p=180>



An interactive or media element has been excluded from this version of the text. You can view it online here:
<https://open.lib.umn.edu/largeanimalsurgery/?p=180>



An interactive or media element has been excluded from this version of the text. You can view it online here:
<https://open.lib.umn.edu/largeanimalsurgery/?p=180>

Practice Quiz



An interactive or media element has been excluded from this version of the text. You can view it online here:
<https://open.lib.umn.edu/largeanimalsurgery/?p=180>

FA Drug Regulation Summary

Food animal drugs are tricky

- Pot bellied pigs have to follow pig rules
- Camelids, sheep and goats are under MUMs rules and have more flexibility but are still food animals
- Use FARAD and VetGram to identify prohibited drugs, ELDU allowances and withholding times
 - This can be very tricky for goats etc. – try to find a cattle version
 - You can contact FARAD and ask
- Oral drugs in ruminants often don't work. Meloxicam does
 - Use of meloxicam is a bit edgy. We justify it as a better analgesic and there are no FDA approved analgesics in food animals yet

To determine withholding

- Typically count on 5 half-lives to clear a drug
- If you double the drug amount, add 1 half life
- Elimination is the same regardless of route
 - if you can figure out the difference in peak values, that can help with half life calculations
 - Iv administration -> high, fast peaks
 - IM administration -> slower peaks but generally same peak level
 - will take a bit longer to eliminate
 - PO administration – slower peaks and lower peaks
 - usually take less time to eliminate since not as much drug available

Large animal masses

This chapter is designed to support the LA masses section of LAS I

Learning Objectives

- Be able to determine if a mass is an abscess, granuloma, hematoma, hernia, tumor or cyst
- Be able to prevent abscess development from wounds
- Be able to manage abscesses in large animals and avoid common mistakes
- Know when isolation of an animal with an abscess is indicated

Differentials and diagnostics

The main differentials for masses in large animal species are:

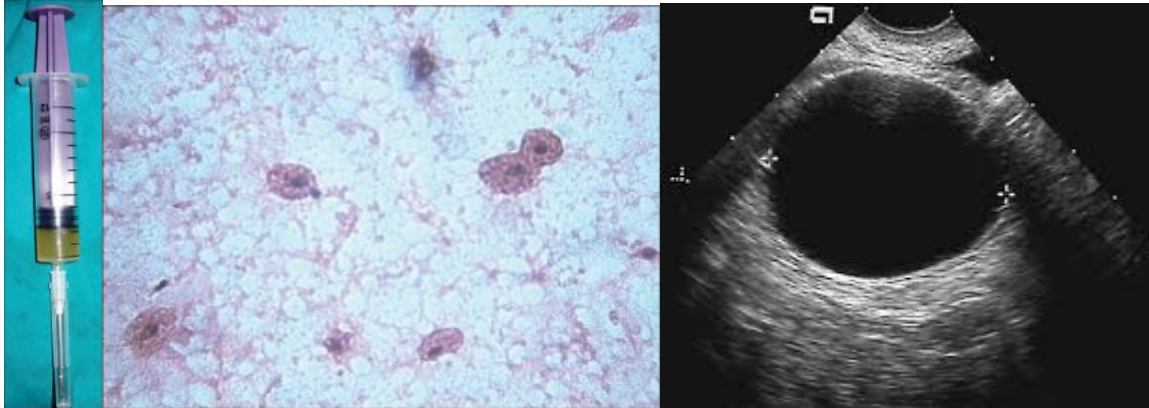
- Cyst
- Granuloma
- Hematoma
- Hernia
- Tumor
- Abscess

Diagnosis

The easiest way to determine the cause of a mass is to stick a needle in it. In most cases, this is safe and effective. There are exceptions! Needle sticks through contaminated regions (vagina, rectum, oral cavity, prepuce) or contaminated tissues (cellulitis) can easily *create* an abscess and should not be attempted. A good history and PE (any injury, fever, cardinal signs of inflammation?) can identify most. Ultrasound and other imaging studies can be useful to determine the type of tissue or cellularity of fluid.

Cysts

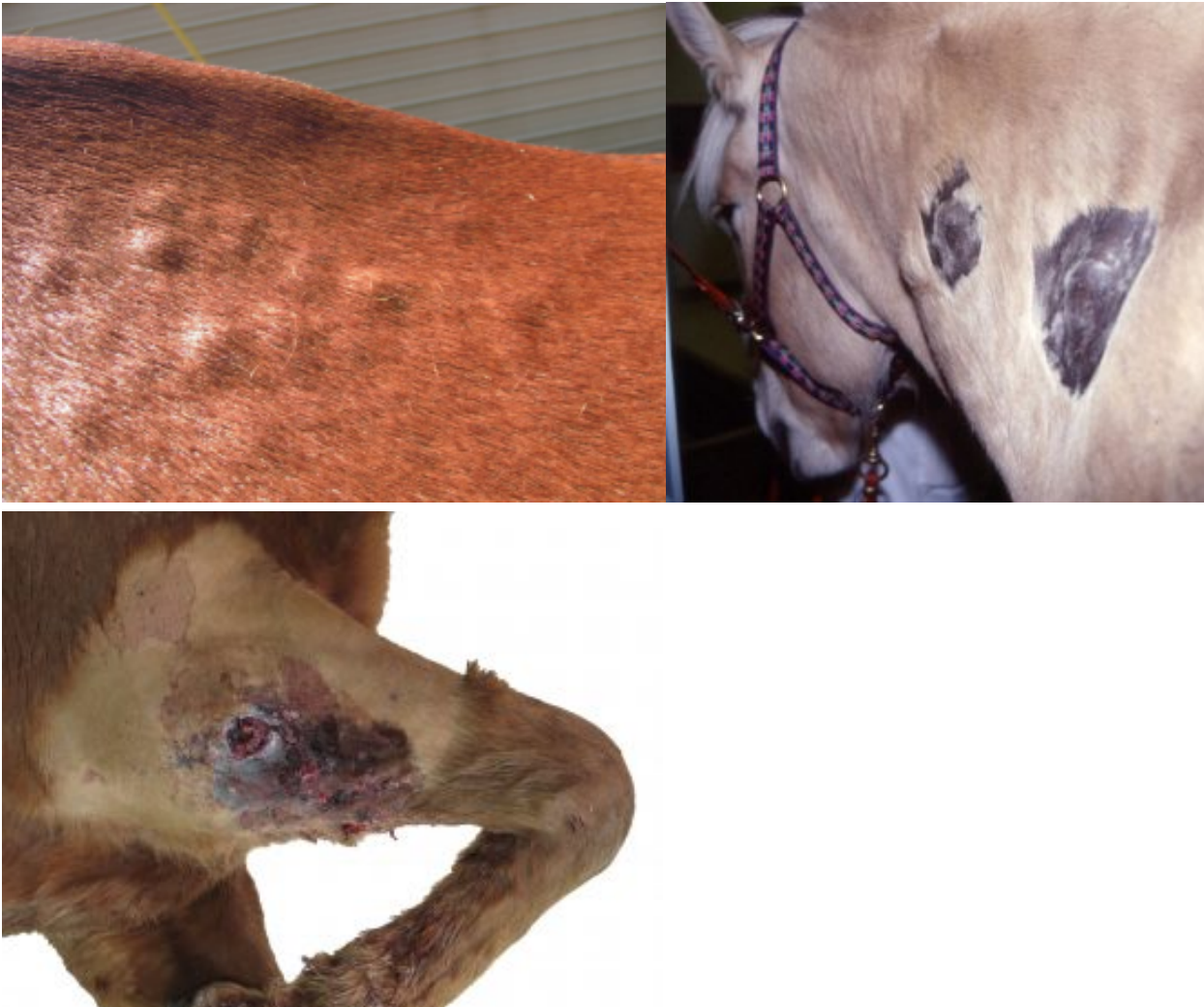Cysts are often fluctuant but can be quite turgid. Needle aspiration usually results in a clear, nonodorous fluid that is mostly acellular. Ultrasound should show a clear fluid enclosed in a thin walled capsule.



Aspiration is usually not curative as the fluid redevelops.

Formalin is commonly used in non-food animal species to stop the fluid production. The fluid in the cyst is removed and an equal volume of 10% neutral buffered formalin injected. The formalin can be re-aspirated after 5 min if desired. The formalin destroys the cells producing the fluid. If the cyst does not respond, is in a food animal, or is in an area that isn't easily injected, it can be removed surgically. It is important to remove the lining to prevent recurrence. Horses can have ectopic teeth that lead to draining wounds near the ear – these are known as dentigerous cysts. Removal can be tricky as the tooth can be solidly attached to the skull.

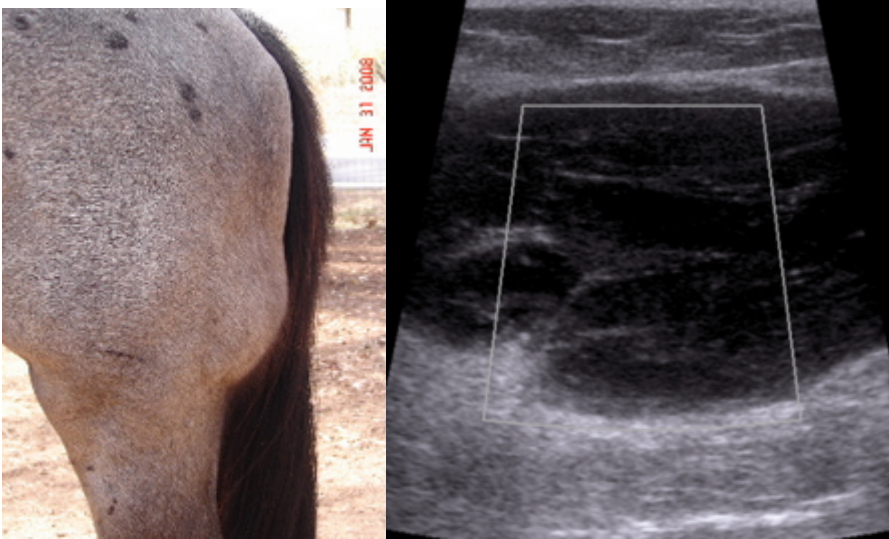
Granulomas



Granulomas form when the immune system walls off a foreign substance. Generally this is because the immune system can't eliminate it. Complexes of immune cells surround an infectious agent (bacteria, fungus, parasite) or material such as keratin or suture. Granulomas are typically composed of macrophages, often fusing to form multinucleated giant cells. The other cell types in the granuloma can be hints as to the originating problem (eg eosinophils with parasites or immune complexes). Granulomas develop as solid structures but loss of blood supply may lead to necrotic centers that appear caseated or cheesy. The entire mass may be removed and submitted for histopathology, particularly if it is in a problematic area or is enlarging. Many respond well to intralesional or systemic steroids but it is important to biopsy first to ensure there isn't an ongoing infection. Finding and removing the irritant is important for recurrent or persistent granulomas. Fungal granulomas are found in warm, tropical climates, including SE USA. Generally these are aggressive, ulcerated lesions on the ventrum and limbs of horses where the animals come in contact with swampy water. Small, hard coral-like masses called "kunkers"

are commonly found in these lesions and help with diagnosis. In our area, Blastomycosis has been identified as a cause of granulomas in horses as well as dogs.

Hematomas



Hematomas generally develop after trauma or with bleeding disorders. A good physical examination and history will help determine if a bleeding issue is present. Otherwise most hematomas resolve on their own, albeit slowly. Very big hematomas can calcify; most often this does not cause issues. If a large hematoma is in a sensitive area or is expanding, it is good to get a consultation with a specialist to determine if physical therapy or other treatment is indicated. Penile or scrotal hematomas in horses and cattle also require specialist care to prevent further complications or additional injury.

Cattle can seed hematomas with bacteria from another site. A cow with mastitis, metritis or foot rot can rapidly change a hematoma into an abscess. Just wait it out (with good monitoring) and then treat the abscess. This complication is less common in other species.

Hernias

The most common hernias are umbilical and inguinal. Often these are reducible and a hernia ring is palpable. Quarterhorse fillies are predisposed as are certain lines of Holsteins. Umbilical abscesses do develop and are generally associated with a hernia, particularly in calves. Umbilical abscesses without an associated hernia can be treated as regular abscesses.

Treatment

- Time
 - Mother Nature will resolve many
 - Wait until 4-6 mo old if no problems
- Hernia belts



Research?

A YouTube element has been excluded from this version of the text. You can view it online here: <https://open.lib.umn.edu/largeanimalsurgery/?p=1235>

Abscesses

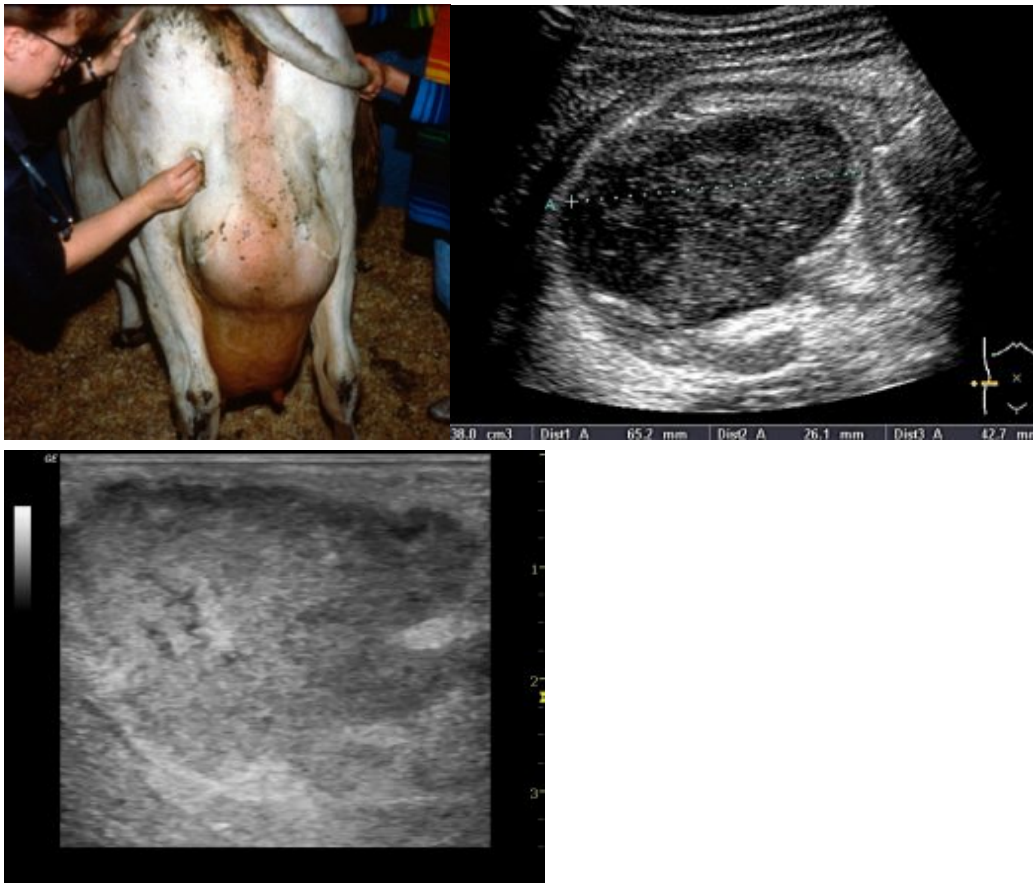These masses should show signs of inflammation: heat, pain, swelling, occasionally redness, and/or loss of use. Abscesses can result from trauma (puncture wounds, lacerations, surgery); can develop from necrotic tumor centers, bone sequestra or foreign bodies; or can be related to systemic infections.

Wounds need to close from the inside out. If the opening of the wound closes too soon, it will trap the infection inside. Similarly, contaminated or infected wounds are rarely closed or at least not closed completely so that the infection can drain.

The primary principle of abscess management is ventral drainage. If the abscess isn't opened or if the opening is above the floor of the abscess, the abscess will generally continue to exist. Antibiotics are generally not necessary if drainage can be obtained (but many graduate vets have a hard time with this). Antibiotics are indicated if the animal shows signs of systemic infection (fever, wbc changes), if ventral drainage is impossible or if vital structures are at risk (eg pleural cavity, mediastinum, abdominal cavity, joint).

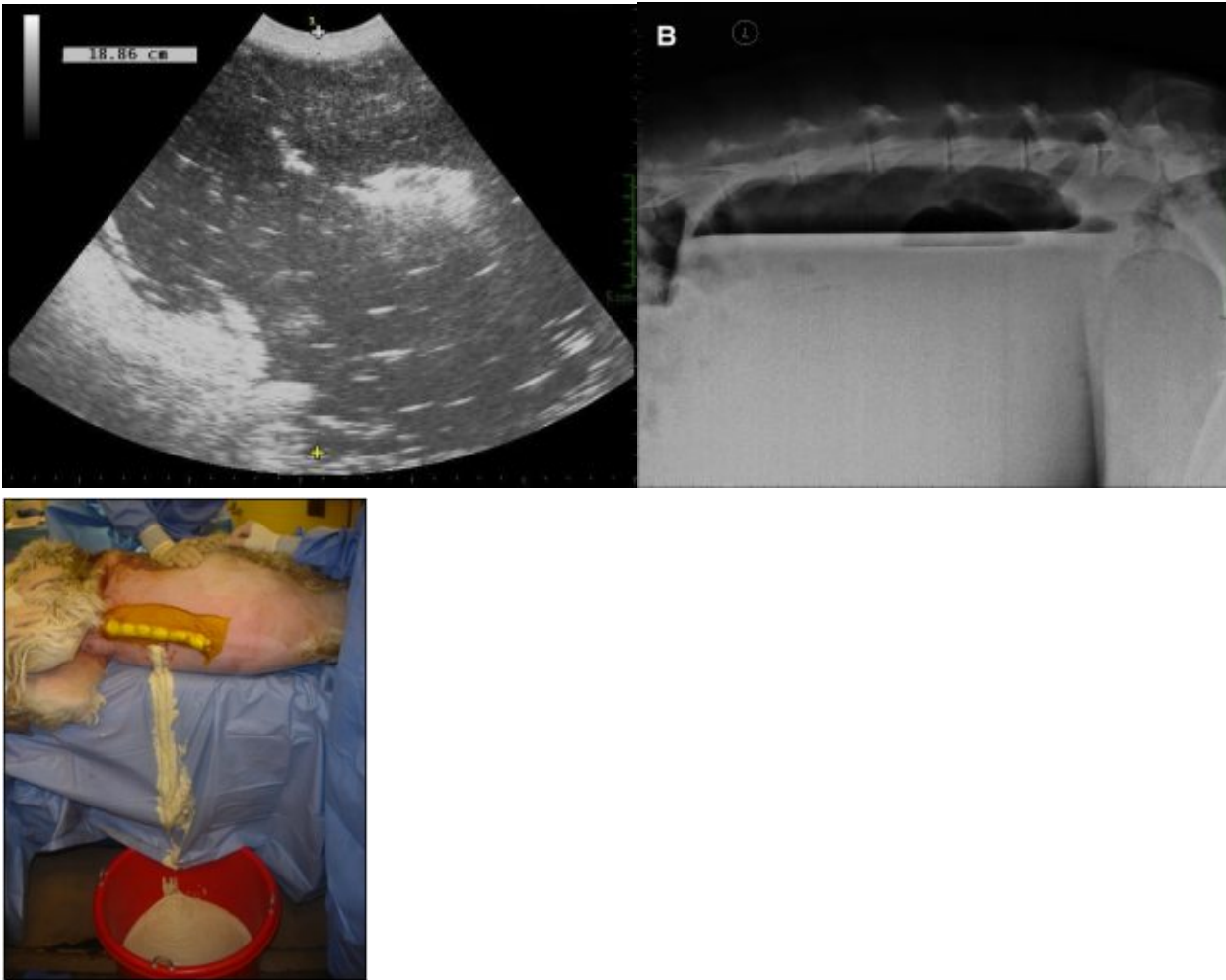
Regional antibiotics (including infusion into the abscess) tend to be more effective than systemic antibiotics. Many antibiotics cannot readily penetrate an abscess capsule and/or may not be effective in the abscess environment due to pH changes and other factors in the pus. Remember antibiotic choices are limited in food animals and require strict attention to withholding times to protect food safety. If an abscess doesn't respond, it is more often due to foreign material in the wound than it is to the bacterial infection.

Ultrasound can be very useful to identify the extent and ventral aspect of an abscess. Ultrasound also shows blood flow (which is often increased) and allows the surgeon to avoid large vessels. Abscesses usually show a mixed echogenicity and a capsule is often visible. Ultrasound can also be used to identify the depth of the abscess and permit more accurate needle selection and incision depth.



Ultrasounds of the two sections of the supramammary mass

Gas in the abscess indicates either an opening to the environment or an anaerobic infection. Ultrasound is also useful for identifying foreign bodies or bone sequestra that are preventing healing in chronic abscesses or wounds. However, ultrasound isn't useful when there is gas in the wound; do your ultrasound before making holes to enable better evaluation of the structures.



Ultrasound and radiograph images of an abdominal abscess containing gas; marsupialization of the abscess was used to create drainage in this alpaca

Radiographs are useful for gas detection; fluid appears as a soft tissue density and may not be readily differentiated from soft tissue structures; gas will usually highlight the abscess but isn't always present.

Creating ventral drainage of abscesses:

- Identify a site that is safe (not in or through an important structure) and most likely to be abscess. You can identify this through ultrasound, visual inspection (the lowest aspect) and /or palpation (feel for a soft stop). It is ideal if this is ventral but that isn't always possible. Inject lidocaine for local anesthesia.
- Insert a large gauge needle (at least 18ga for horses, at least 16 for cattle) through the local block into the abscess to confirm pus. If pus is obtained, a second needle is inserted at least a centimeter away (2-3 cm is better). If this needle also yields pus, connect the two sites via sharp incision with a scalpel blade. If no pus, try again or return to step 1.

- Collect a sample of pus for culture and sensitivity
- Explore the abscess cavity to determine if the incision is ventral enough and/or where a ventral incision should be created. Digital palpation is ideal; sterile probes can also help identify the extent of the abscess cavity and appropriate drainage sites. If needed, the original incision can also be extended to allow better inspection or drainage. Having a finger or probe evaluate the pocket makes this safer.
- Enlarge the incision if needed. Ideally, ventral drainage is created with a big enough incision made to allow the wound to heal from the inside out. ***Cattle close holes very quickly – be generous (but safe) with the size of the incision.***
- The wound can be kept open through flushing or packing (gauze, sugar, honey).
- **Common mistakes**
 - Insufficient ventral drainage – not ventral or not big enough
 - Flushing with irritating solutions that make things worse
 - Contaminating the environment

Most wound infections will be inhabited by multiple species of bacteria and should be cultured to determine antibiotic selection if antibiotics are needed (generally antibiotics aren't needed!). Abscesses relating to infectious organisms are less common but important to identify to prevent further spread.

The majority of bovine abscesses, regardless of cause, will be infected with *Truoperella pyogenes* (last known as *Arcanobacter pyogenes*). This agent is sensitive to most antibiotics but creates a thick walled abscess that makes antibiotic penetration difficult. It is also very hardy in the environment; try to collect the pus during surgery or separate the animal while the abscess is draining.

If the abscess isn't resolving:

- Is there adequate ventral drainage?
- Is there systemic disease? (the infection keeps recurring as the tissue is seeded by more bacteria)
- Is there a foreign body or sequestrum?

Camelids can develop spontaneous bone sequestra, particularly in the head. As the body tries to resolve these sequestra, sterile abscesses develop. More often, they develop abscesses in the jaw region from infected teeth. Resolving these abscesses will require removing the tooth, tooth root or bony sequestrum.

Foreign bodies can be left in wounds from the initial trauma (stick) or be added by vets (suture). Remove to resolve the problem!

Abscesses related to systemic infections

Sheep and goats with abscesses may be infected with *Corynebacterium pseudotuberculosis* and have caseous lymphadenitis (CLA). Sheep tend to develop onion like abscesses (firm, layered pus) and are prone to internal abscesses, while goats get white creamy pus filled lesions and are more likely to have external abscesses. The abscesses are generally infected lymph nodes. This organism is very infectious and very hardy. Generally culling of all infected animals and avoiding placing new animals in the environment for at least 8 months is required to control this disease. This is often unpalatable to owners. Lancing abscesses will lead to more environmental contamination. Removing abscesses surgically can become expensive due to the frequent incidence of new infections in the herd (same patient and other patients). Tulathromycin injected into the lesion or

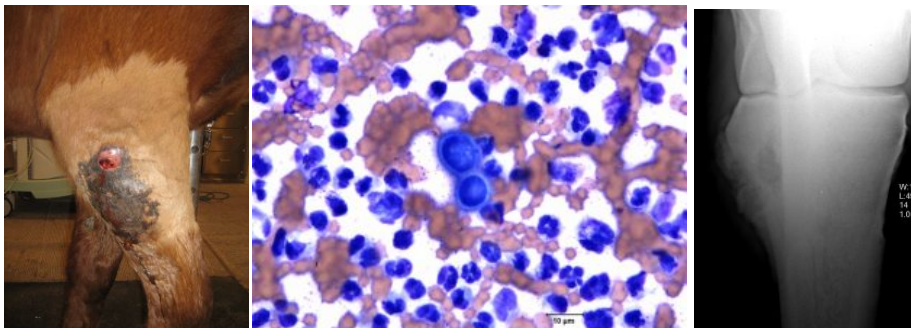
subcutaneously into the goat helped resolve lesions in one study. At the UMN, we did not find it that effective.

Culturing small ruminant abscesses is important and client education is a crucial part of therapy.

Corynebacterium pseudotuberculosis (equine serovar) is a growing problem in horses and leads to superficial and internal abscesses. This disease has been localized to California and other western states in the past but is expanding as the vectors involved in its transmission enjoy global warming (likely horn flies, stable flies and house flies). The most common presentation is abscesses in the pectoral or ventral abdominal area, leading to the name “pigeon fever”. It can also lead to ulcerative lymphangitis on the limbs of affected horses. Horses in endemic regions may have some resistance to the organism; as it enters new territory, it may be more virulent. Most cases are seen in the late summer and fall but it has been identified year round and the seasonality may be shifting to midsummer months. This version of the organism is also very hardy in the environment and can survive at least 8 months. **Affected animals should be isolated.** *Corynebacterium sp* can infect people.

Horses with abscessed lymph nodes may also have strangles (*Streptococcus equi*). The lymph nodes in the head are most commonly affected but the infection can affect any lymph node. If the horse has nasal discharge or if there is a history of strangles in the barn or the community, strangles should be at the top of your differential list and appropriate precautions taken to limit its spread. You and your vehicle can be fomites!

Other bacterial and fungal organisms can also create abscesses or masses in all species. Most of these are easily spread between animals of the same species and many have the ability to cross species lines (including humans). We have seen blastomycosis infections in horses in this area. Cytology and culture can help figure out what you are dealing with. Chronic abscesses may need a specialist.



Osteomyelitis blastomycosis in a Minnesota

574 Large Animal Surgery

horse

Resources

Large Animal Cutaneous Neoplasia

Learning Objectives

- When faced with a skin tumor on a large animal species, be able to develop a plan for diagnosis and treatment, based upon the presenting clinical signs, the likely differentials and the latest evidence

The numbers of LA tumors are limited due to the shorter lifespan of horses and cattle. The most common equine tumors are sarcoids, melanomas and squamous cell carcinomas (SCC). These can often be differentiated on appearance. The most common bovine tumors are lymphosarcoma and SCC. These present differently and in different age groups.

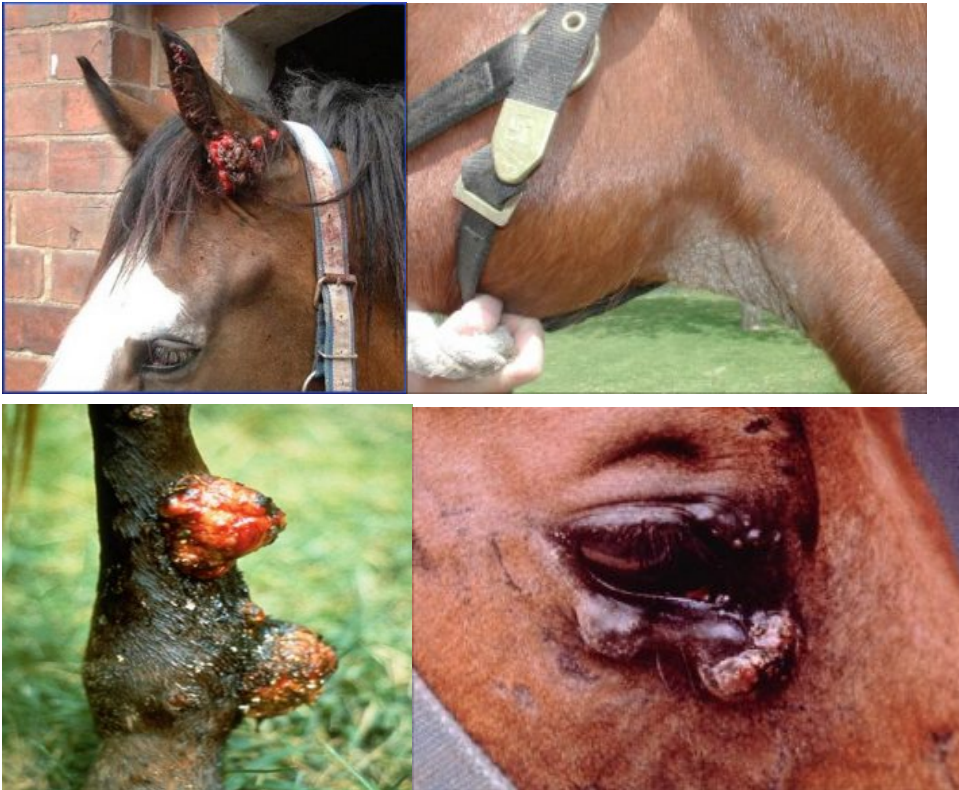Diagnostics

Options include visual identification (obviously not 100% accurate but often pretty good), fine needle aspirate, surgical biopsy or removal and submission for histopathology. Necropsy is a diagnostic tool but doesn't do much to help that animal. Because we are dealing with larger animals that permit minor procedures with standing sedation, an incisional or excisional biopsy often is the most productive. Remember to try to include some normal tissue in your biopsy so that the interaction between normal and diseased tissue can be assessed. Sedation with xylazine or detomidine and a local block is often sufficient to obtain these biopsies.

Sarcoids

Sarcoids develop in the skin and dermal tissues due to an atypical immune reaction of horse skin to a bovine papilloma virus. We assume the bovine papilloma virus is in the horse's skin and is "activated" by trauma. This seems to explain the common predilection sites: scrotal area, limbs, and head. Sarcoids are the most common skin tumor observed in horses. While not malignant, they are very resistant to treatment and can occasionally lead to severe consequences for horses, including euthanasia or retirement.

Sarcoids present in several different forms. A nodular form occurs in the dermal tissues, often with chains of nodules connected by bridges that may or may not be palpable. These can remain unchanged for many years and/or can start growing aggressively with trauma (including biopsy and fly bites). Some sites may be covered by normal skin; others can have ulcerated surfaces as the affected area does not heal well. Other forms of sarcoid develop an external "cauliflower" like appearance, growing into raised, often bumpy tumors of various shapes. These can be grayish or can look like proud flesh (exuberant granulation tissue) and can be mistaken for such. If "proud flesh" is noted above the carpus or hock, it is most likely sarcoid (or it is another tumor). Sarcoids can also be flat, hairless, gray and scaly. These areas look more like ringworm or other dermal lesions rather than tumor. They are disfiguring. Many owners complain that other horse owners worry that the lesions will be contagious. Horses cannot "catch" sarcoids from other horses but it is important to rule out a true fungal disease. Finally, mixed versions can occur.

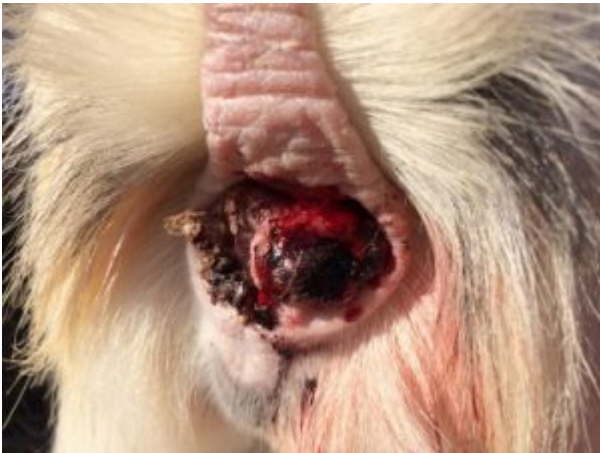

Many treatments exist for sarcoids. With such scenarios, it generally means nothing is 100% effective. The

treatments most often used at the UMN include laser debulking (CO2 laser), cryotherapy, cisplatin beads and/or topical imiquimod. Imiquimod (Aldara®) was studied at the UMN and was found to be very effective in many sarcoids (see [UMN Aldara studies](#)). Imiquimod is a topical cream that affects toll-like receptors in the region. While we used imiquimod on its own for the study, we prefer to use it after laser therapy or with cisplatin beads, particularly in larger tumors. Combination therapy minimizes the treatment frequency and seems to optimize the results. Other treatments include electroporation (new research), radiation therapy, cisplatin or 5 -fluorouracil injections, Xxterra (blood root extract), BCG injections, autogenous vaccines, skin grafting and even topical application of fluoride toothpaste (no evidence to demonstrate efficacy). Surgical removal alone is **not** usually recommended. Most sarcoids include tendrils that grow new sarcoids as they are cut. Much like the Greek Hydra, when the main tumor is removed and these tendrils are transected, you can end up with a much bigger problem. Wide margins are a necessity and generally surgical debulking is combined with other therapies. Sarcoids that aren't growing, aren't ulcerated and aren't being traumatized should be left well enough alone. As more research is done and new treatments are explored, it will be important to be able to assess study design. Most of the research on sarcoids has not been done in a controlled or blinded manner. Note : **Not all sarcoids require treatment! If they aren't ulcerated, raised or growing, we try not to treat. You may enter into a battle you can't win.**

Squamous cell carcinoma

As in other species, SCC affects light colored skin and external mucosa in older animals. Predilection sites in large animals include the eye (white faced cattle, appaloosa and paint horses), the penis (especially older geldings, potentially related to smegma buildup), the vulva and areas of trauma (eg burns or chronic wounds).



Perineal SCC in a goat

Similar to other species, SCC's are locally invasive and are slow to metastasize but can do so. It is important to assess regional lymph nodes. The nodes may be enlarged due to metastases or to inflammation. SCC areas are often ulcerated rather than raised. Nonhealing wounds should be biopsied to rule-out SCC. Horses with penile SCC are at greater risk of having ocular SCC so both areas should be checked carefully. Habronemiasis can look like SCC but isn't common in this area.

Treatment generally involves resection with wide margins. This can mean enucleation, third eyelid resection and penile amputation or ablation. The wound margins are then monitored closely for recurrence and/or treated to remove any remaining tumor cells. This can mean laser ablation, radiation treatment or cryotherapy. Penile and vulvar lesions are often treated with 5-fluorouracil (5FU) cream. Periocular tumors may be treated with imiquimod, mitomycin C, or photodynamic therapy. While vulvar lesions are treated daily and still tend to be very aggressive, penile lesions can be treated every 2 weeks with good efficacy for smaller lesions. The sheath seems to maintain effective levels of the drug between treatments. For differential lists between sarcoids, SCC and melanomas, if the tumor is:

- on skin and raised, think sarcoid
- on skin and ulcerated, think SCC
- on mucosa (eg penis), think SCC
- black -> melanoma

Melanomas

Melanomas are classically associated with gray horses and are generally black in color, raised and rounded. Most gray horses over the age of 15 will have melanomas. Common sites include the base of the tail and perineal region, the parotid salivary gland and guttural pouch area, the lips/cheeks and the prepuce. Many horses will have multiple melanomas with no related problems. Occasionally melanomas will lead to problems with defecation as they expand in the perineal region. The parotid masses can grow quite large but don't usually impinge on the airway. Parotid melanomas can be seen as black areas on the internal surface of the guttural pouch (making it pretty obvious that resection is unlikely to be an effective or safe measure). Many melanomas become more aggressive with age and rarely melanomas become metastatic to other internal organs. We have not yet identified a grading scheme that will let us identify which black melanomas will become problematic; amelanotic melanomas and melanomas on non-gray horses tend to be much more aggressive.

Treatment of melanomas is not currently very effective. Many don't require treatment. Surgical removal can be difficult as a large expanse of skin and dermis is generally removed, making closure difficult. Oral cimetidine has helped stabilize or regress a few tumors but isn't very effective and isn't frequently used. Cisplatin injections and beads, autogenous vaccines and laser therapy have also been used. More recently, interleukins, frankincense injections and the canine melanoma vaccine have been trialed but efficacy results have not been published. Imiquimod may be effective but has yet to be proven. If removal is indicated, we will usually start with laser debulking, followed by cisplatin beads or chemotherapeutic injections. We plan to trial microwave ablation techniques for tumors that are causing issues.

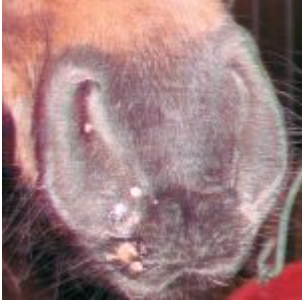Lymphosarcoma

Cutaneous lymphosarcoma is generally considered a sporadic form of lymphosarcoma and unrelated to BLV infection (cattle). LSA tends to be a problem in younger animals. Tumors can develop in lymph nodes and in various tissues including the retrobulbar area, the jaw and the subcutaneous tissues (including the prepuce) as well as internally (eg mediastinal). It is less common in horses but has a similar pattern. Lymphosarcoma does tend to metastasize. Biopsies in horses can be helpful as those with a primarily lymphocytic population do tend to spread internally while those with a combination of histiocytes and lymphocytes are related to improved horse longevity.

Diagnosis is often delayed and the disease moves quickly. Treatment is often ineffective with aggressive forms (lymphocytic). Some early cases will respond to glucocorticoid treatment and/or surgical removal. Systemic chemotherapeutic agents are generally not used in horses due to the associated costs. Microwave ablation holds some promise if the tumor has not yet metastasized. Treatment options are even more limited in cattle due to the restrictions for meat and milk (anticancer agents in the food supply is frowned upon).

Papillomatosis aka warts

This disorder can occur in horses (generally on the muzzle) but is more frequent in cattle (muzzle and penis).



Warts are usually self-limiting. Pinching one off may stimulate regression of the others. Penile papillomas may need treatment (debulking) if hemospermia or problems with penile retraction are noted.

Field treatment options

Surgical debulking

Tumors can be removed using standing sedation or general anesthesia. Remember to obtain wide margins and to submit a section for histopathology. This is the primary option available for your food animal patients. In general, most tumors will also need another form of treatment. Surgical debulking alone is considered inappropriate for sarcoids; ALWAYS plan to include another form of therapy for sarcoids.

When removing a mass, remember that circles don't heal well. Most tumors are removed using a [fusiform incision](#) (football shaped, pointy at the ends). Check out the lines of tension so that you are closing with them vs against them. If you incise parallel to the lines of tension, the incision will gap the least and the resulting scar will be the smallest. Incisions made at oblique angles to the lines of tension will become curvilinear and incisions made perpendicular to the lines of tension will gape most widely and heal with the largest scars.

Presuturing can be used to stretch the skin in advance of removing the tumor. This procedure relies on the stretch that occurs when skin is kept under tension. Edema develops after 24 hours and interferes with the stretch benefit. Presuturing for 2.5-8h has been useful.

From Auer & Stick:

The direction of suture placement is chosen according to the anticipated direction of primary closure. Wounds of the body and upper limb are generally the most amenable to presuturing. Large, nonabsorbable sutures (No. 1 or No. 2, polypropylene or nylon) are placed through the skin perpendicular and 2 to 6 cm to either side of the lesion. The sutures are then tightened to elevate and fold the skin over the lesion or wound. If presuturing is used in conjunction with tumor excision, the surgeon should be careful to place the sutures distant to the lesion to avoid iatrogenic seeding of tumor cells into healthy tissue.

See how to article: <http://veterinarymedicine.dvm360.com/skills-laboratory-reconstructive-surgery-techniques-part-1-presutures-skin-stretching>

Cryosurgery

Cryosurgery damages the tumor cells through the creation and melting of ice crystals. To get the best ice crystals, freeze the tissue quickly and let it thaw slowly. This is repeated at least once. The second and third time, the precooled tissues freeze faster, creating a better kill. Don't try to heat the tissues to speed the thaw. Let them return to normal temperature on their own. For people, they keep freezing until the tissue stays cold.

Liquid nitrogen used for cryosurgery does need to be carefully stored and transported. It is delivered to the tissue through spray guns or super chilled probes. It is important to protect surrounding tissues when using the spray guns. Vaseline and Styrofoam cups (easily torn to the right size) are commonly used. Many tumors will respond to cryotherapy and it can be used after debulking to treat the wound margins. You may need to wait until bleeding subsides in order to obtain a good ice ball as the blood is warm and keeps heating the area. While thermocouples

are nice to have, most clinicians gauge the amount of freeze by the size of the ice ball. The central 75% of the ice ball will be sufficiently cold to kill tumor cells.

After cryosurgery, the tissue will swell over the next 48 hours and will necrose in 14-21 days. Hair may turn white or may not regrow. Tissue will scar: “do not freeze where scars may squeeze”. Eg freezing a SCC on the urethra might not be a good option. Cartilage is very sensitive to freezing and may be damaged or misshapen if it becomes too cold (eg be very careful freezing tumors on ears). Repeated treatment is often necessary.

The investment cost and cost of the liquid nitrogen is relatively small making it one of the more affordable options for practices.

Cisplatin beads and chemotherapy injections

Cisplatin is often effective against tumor cells if it can be kept in the region. In horses (and non-food animals), the bead form has been the easiest and seems to be the most efficient. Commercially produced beads are inserted into the tumor through small stab incisions to cover as much of the tumor as possible. The beads release cisplatin over time and generally need to be replaced every two weeks. Cisplatin injections are cheaper but require mixing with oils to prolong their activity and can be quite messy and therefore dangerous for the user. Users should take appropriate precautions with both and avoid contact with the beads or solution. 5FU is also available in an injectable form.

Topical agents

Topical agents can be dispensed and applied by the owner. Many of these result in irritation to the horse so cleaning and reapplication may require veterinary assistance. The most common compounds are imiquimod (useful for sarcoids and probably SCC) and 5-fluorouracil (used for penile and vulvar SCC). Xxterra is also being used for tumors but is not well studied. Watch for more options to appear; always check the literature vs the website or sales rep!

Referral

Most other therapies will only be available at referral centers due to equipment cost or health/safety restrictions. Laser debulking is frequently used for tumors that come into the UMN. The CO2 laser removes cells layer by layer, making it one of the safest options to use in tricky areas. It also destroys the nerves to the tissue, giving the horse some pain relief as well.

It is often useful to get the initial treatment performed at a referral center and then rely upon the field treatments to continue the therapy and/or keep the tumor at bay.

Others

Autogenous vaccines have been tried (and given up on) for melanomas. They are currently resurfacing for sarcoids. BCG has been used to stimulate an immune response for ocular tumors but does carry a risk of death; imiquimod is safe to use around the eye and no deaths have been reported. Radiation therapy is possible but is often cost prohibitive for horses. You can always call us for the latest info on a tumor or treatment option!

Resources

Other resources

Foy JM, Rashmir-Raven AM, Brashier MK. Common equine skin tumors CCE 24:242-254, 2002.

Funicello B et al. Cutaneous blastomycosis in a horse. EVE 26:458-463, 2014.

Hubert JD and Grooters AM. Treatment of equine pythiosis. CCE Oct 812-815, 2003 (vetlearn.com)

Kilcoyne I et al. Frequency of *Corynebacterium pseudotuberculosis* infection in horses across the United States during a 10-year period. JAVMA 245:309-314, 2014

Knottenbelt DC. Integumentary disorders including cutaneous neoplasia in older horses. VCNA 32:263-281, 2016

Liang, MD, Briggs, P, Heckler, FR, et al.: Presuturing: A new technique for closing large skin defects: Clinical and experimental studies. Plast Reconstr Surg. 81, 1988, 694

McCauley CT, Hawkins JF, Adams SB et al. Use of a carbon dioxide laser for surgical management of cutaneous masses in horses: 32 cases (1993-2000). JAVMA 220:1192-1197, 2002.

Nogueira SAF, Torres SMF, Malone ED et al. Efficacy of imiquimod 5% cream in the treatment of equine sarcoids: a pilot study. Vet Derm 17:259-265, 2006.

Phillips JC and Lembcke LM. Equine melanocytic tumors. VCNA 29:673-687, 2013

Pusterla N et al. Cutaneous and ocular Habronemiasis in horses: 63 cases (1988-2002). JAVMA 222:978-982, 2003

Rousseau M et al. Osseous sequestration in alpacas and llamas: 36 cases (1999-2010). JAVMA 243:430-436, 2013.

Stewart AA, Rush B, Davis E. The efficacy of intratumoural 5-fluorouracil for the treatment of equine sarcoids. Aus Vet J 84:101-106, 2006

Van Den Top JGB, Ensink JM, Grone A et al. Penile and preputial tumours in the horse: literature review and proposal of a standardised approach. Eq Vet J 42:746-757, 2010

Washburn KE et al. Comparison of three treatment regimens for sheep and goats with caseous lymphadenitis. JAVMA 234:1162-1166, 2009.

<http://www.aaep.org/custdocs/PigeonFeverGuidelines52713.pdf>

<http://www.merckvetmanual.com/digestive-system/congenital-and-inherited-anomalies-of-the-digestive-system/cysts-and-sinuses-of-the-head-and-neck>

<http://www.slideshare.net/fuadredza/principles-of-incision-and-wound-closure>

Practice



An interactive or media element has been excluded from this version of the text. You can view it online here:
<https://open.lib.umn.edu/largeanimalsurgery/?p=2312>



An interactive or media element has been excluded from this version of the text. You can view it online here:
<https://open.lib.umn.edu/largeanimalsurgery/?p=2312>

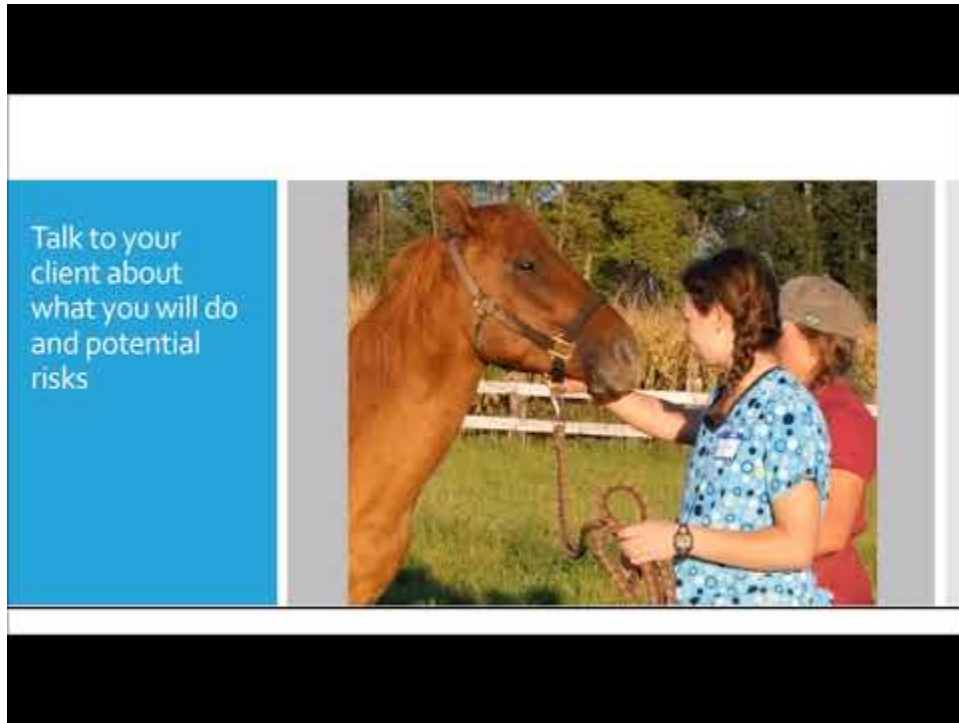
Equine Castration

This section will focus on the principles of equine and camelid castration both standing and recumbent. Equine castrations can be performed standing or recumbent and are typically performed on yearlings. This means you need to pick your option and plan well for sedation or anesthesia, the procedure and the recovery. Resources for sedative and general anesthesia protocols can be found in earlier chapters. Review these chapters to learn

- who, when and where to castrate
- how to castrate
- postoperative requirements
- how to minimize and manage complications

Castration planning

Equine castrations can be performed standing or recumbent and are typically performed on yearlings. This means you need to pick your option and plan well for sedation or anesthesia, the procedure and the recovery.



A YouTube element has been excluded from this version of the text. You can view it online here: <https://open.lib.umn.edu/largeanimalsurgery/?p=269>

After viewing the introduction above, watch the videos below to get an overall picture of recumbent equine castration. As you watch, think about:

- how old (big) is the colt?
- what season is it?
- where are they performing the castration?
- how does the colt become recumbent and stand up again (how much help does he need)?
- how do they keep the hindlimb out of the way?
- where does the surgeon stand to perform the castration?
- what level of sterility is being used? caps/gowns/masks and gloves or something else?



A YouTube element has been excluded from this version of the text. You can view it online here: <https://open.lib.umn.edu/largeanimalsurgery/?p=269>



A YouTube element has been excluded from this version of the text. You can view it online here: <https://open.lib.umn.edu/largeanimalsurgery/?p=269>

How do the videos compare with what was suggested in the intro: preop exam and anesthesia planning?

Exercises

Now work through this quiz to review a few more factors:



An interactive or media element has been excluded from this version of the text. You can view it online here: <https://open.lib.umn.edu/largeanimalsurgery/?p=269>

Key Takeaways

Why – Stallions can be dangerous and are difficult to house safely with other horses.

Who –Healthy, vaccinated, trained colts with two testicles 12-15mo of age or older. Castration is an elective procedure.

When- Spring is ideal since fewer bugs

Where – An open grassy field is the best. Avoid stalls, wooded areas and slopes

How – I prefer recumbent open castration. Castration can be performed standing.

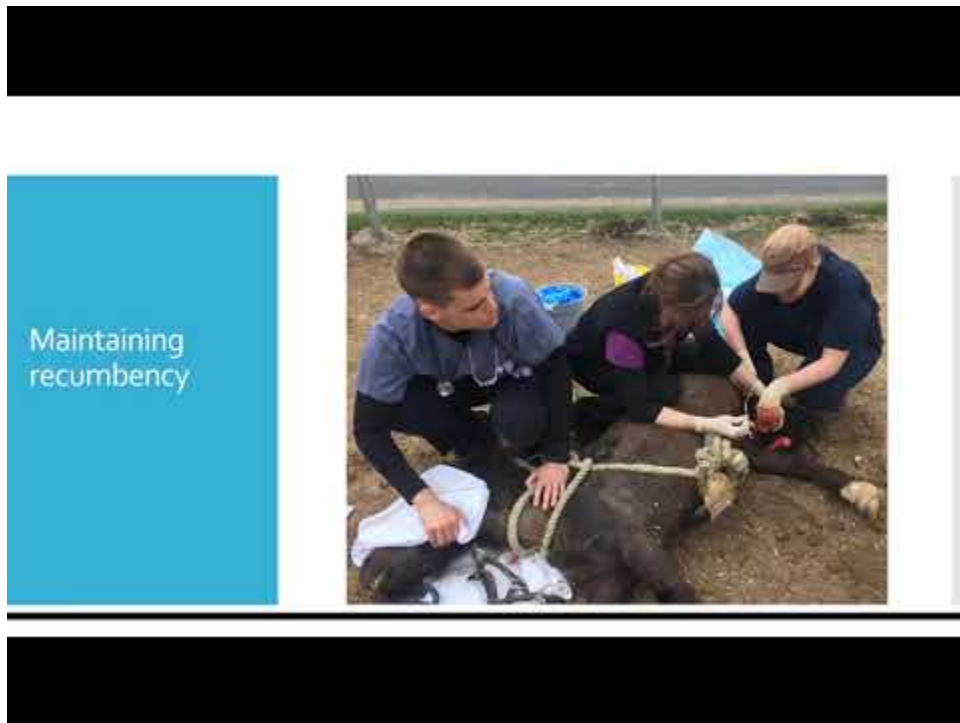
What else – [Preoperative and postoperative analgesics](#) and tetanus are necessary. [Preoperative antibiotics](#) recommended. Owners need to be prepared for the aftercare.

Resources

Haucke et al. [Two Regimes of Perioperative Antimicrobial Prophylaxis for Equine Castration](#). Journal of Equine Veterinary Science 57 (2017) 86–94

[Step by step pictures](#) -equine vet blog

Field anesthesia for equine castration



A YouTube element has been excluded from this version of the text. You can view it online here: <https://open.lib.umn.edu/largeanimalsurgery/?p=253>



A YouTube element has been excluded from this version of the text. You can view it online here: <https://open.lib.umn.edu/largeanimalsurgery/?p=253>

After reviewing the introductory documents above, watch these videos, focusing on the anesthesia and perioperative steps



A YouTube element has been excluded from this version of the text. You can view it online here: <https://open.lib.umn.edu/largeanimalsurgery/?p=253>



A YouTube element has been excluded from this version of the text. You can view it online here: <https://open.lib.umn.edu/largeanimalsurgery/?p=253>

Exercises

Now work through these quizzes to review some additional points:



An interactive or media element has been excluded from this version of the text. You can view it online here: <https://open.lib.umn.edu/largeanimalsurgery/?p=253>



An interactive or media element has been excluded from this version of the text. You can view it online here: <https://open.lib.umn.edu/largeanimalsurgery/?p=253>



An interactive or media element has been excluded from this version of the text. You can view it online here:
<https://open.lib.umn.edu/largeanimalsurgery/?p=253>

Key Takeaways

Why – I like injectable anesthesia because the recoveries are smooth. I prefer recumbent castration as I have more control over the situation.

Who – You need an assistant to help with anesthesia, recumbency and helping with any needed supplies during the procedure. The owner is not ideal.

What – Bring drugs, supplies for scrubbing and restraint and a surgery pack (emasculator, scalpel, hemostats, carnalms) and extras. Bring suture material even if you don't plan to use it. Drugs should include anesthesia, lidocaine, an NSAID, an antibiotic and tetanus toxoid.

When – Anytime typically works as long as everyone is healthy. We don't routinely hold horses off feed for castration.

Where – Grassy fields are great for anesthesia and recovery. Please stand on the back side of the horse to avoid being injured

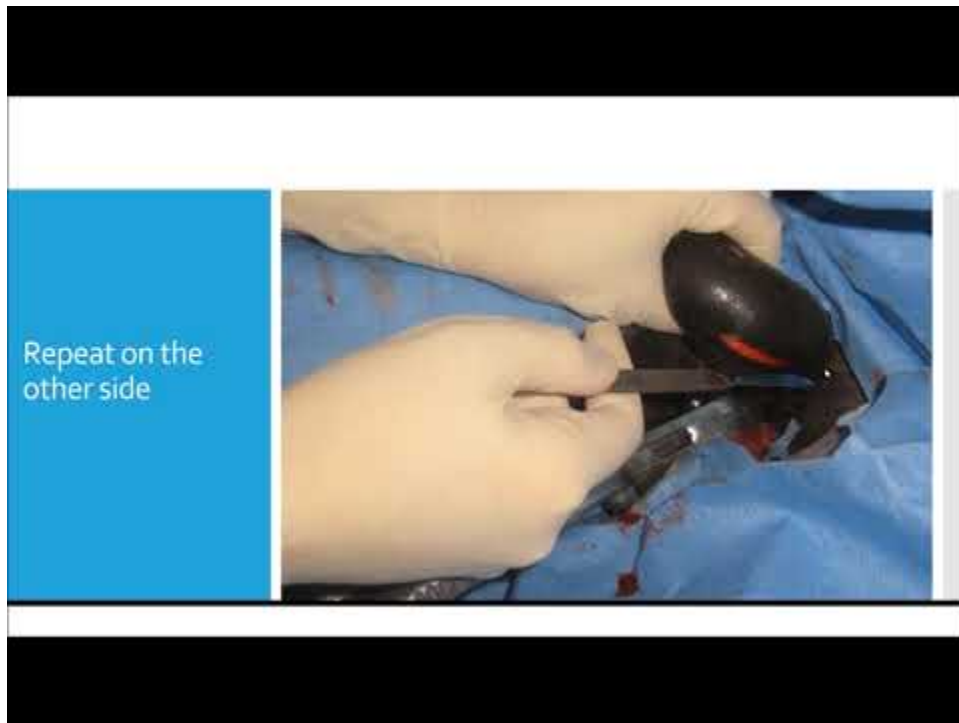
How – Drop the horse using a sedative and induction agent(s). Typically we use xylazine followed by midazolam+ketamine. Catheters and triple drip make life easier. Lidocaine block also prolong your anesthesia time and make the testicle easier to remove since no pain retraction. Protect the facial and radial nerves! Control the head to control the horse. For field recovery, just stay out of the way and make sure your last drug was a sedative, not ketamine.

RESOURCES

[Equine Drugs Chapter](#)

Recumbent equine castration

Intro: [step by step castration](#) video

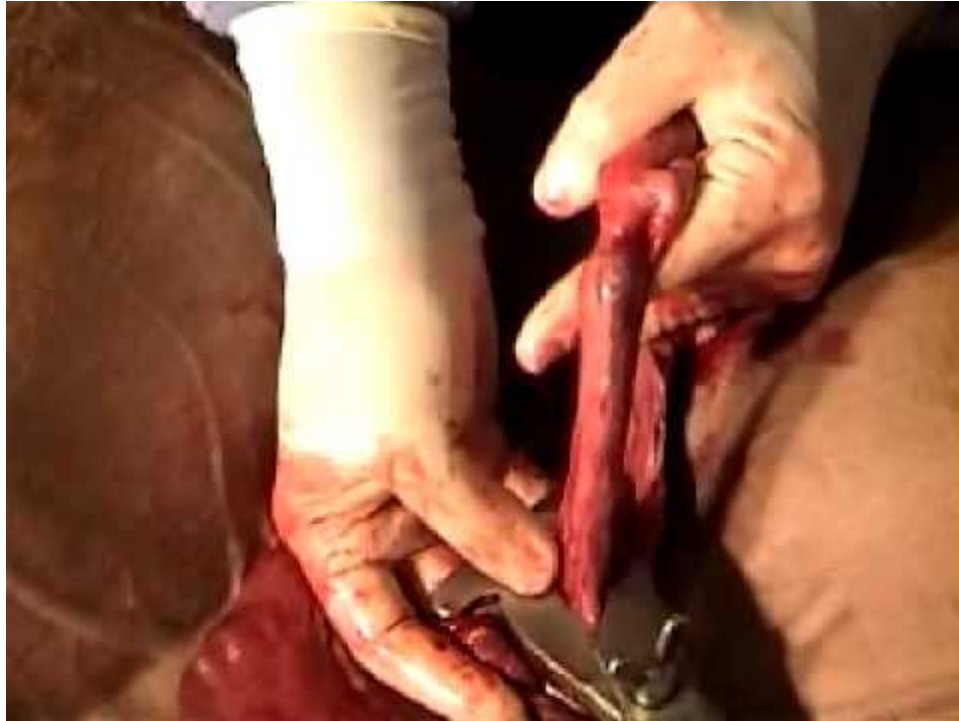

A YouTube element has been excluded from this version of the text. You can view it online here: <https://open.lib.umn.edu/largeanimalsurgery/?p=280>

Intro: [Steps to a routine castration](#) file

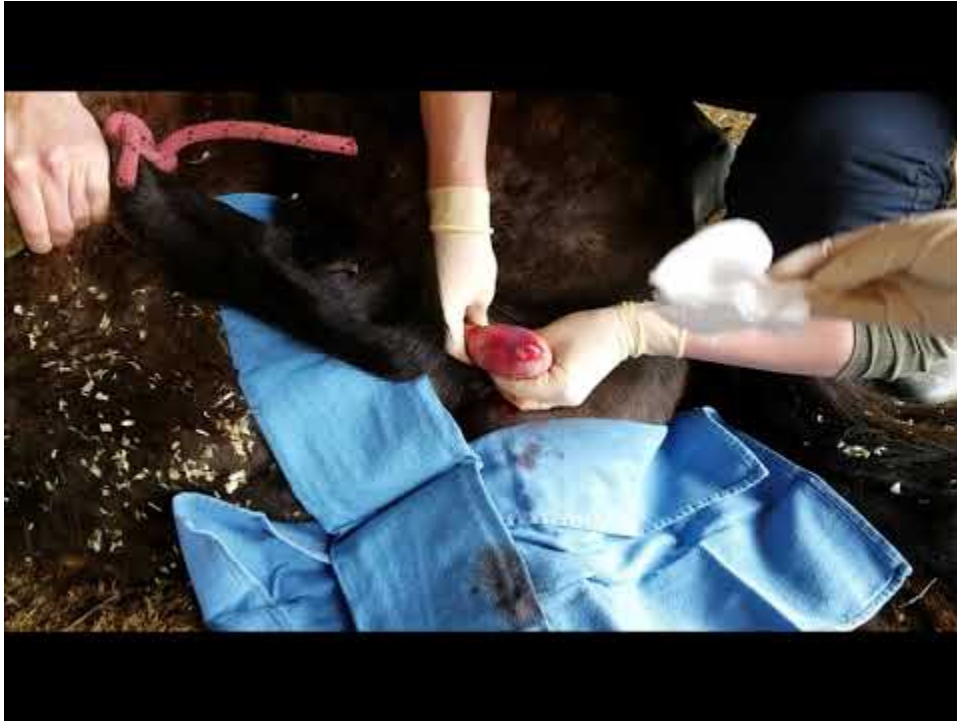After reviewing the introductory files, watch these videos:

Note his “modified closed” technique is really an open castration and a better option vs modified closed



A YouTube element has been excluded from this version of the text. You can view it online here: <https://open.lib.umn.edu/largeanimalsurgery/?p=280>

student castration lab



A YouTube element has been excluded from this version of the text. You can view it online here: <https://open.lib.umn.edu/largeanimalsurgery/?p=280>

Exercises

Now try your hand at these questions. If you are stuck, try the “i” or “link” buttons for more information



An interactive or media element has been excluded from this version of the text. You can view it online here: <https://open.lib.umn.edu/largeanimalsurgery/?p=280>

Key Takeaways

- Open castration is better for larger, older stallions since you can see the artery and crush it individually.
- Closed castration minimizes opening the peritoneal cavity but makes the procedure harder; restricted to younger patients
- Avoid modified open/ modified closed techniques.

- Large incisions are needed for drainage
- Hemostasis is by tissue trauma – crush with emasculators (nut to nut) or twist with the Henderson. Ligatures are optional but handy.
- Do not close the scrotum.
- **The epididymis does NOT produce testosterone and will NOT make a horse act like a stud.**

RESOURCES

You will find many contradictions and old wives tales in the literature, in practice and in the videos. This article “wins” as far as being the most sound and evidence based. Plus I agree with it the most. Start here for most efficient use of your time:

[Equine castration : A review of techniques, complications and their management.](#) Equine Vet Educ (2013): 25(9): 476-482

[R-Vets wild horse castration](#) website

[Equine Castration](#) UGA version

[Equitwister](#), 2015 AAEP

[Video compilation](#) : good, bad and ugly

Standing equine castration

Watch this explanation of standing castration:



A YouTube element has been excluded from this version of the text. You can view it online here: <https://open.lib.umn.edu/largeanimalsurgery/?p=305>

Did you identify the error in her explanation? Hint: It was the part about the function of the epididymis. What part of the gonad actually produces testosterone? And she gave her drugs after the fact; they are much more effective preop.

Exercises

Now work through this exercise for more on standing castrations:



An interactive or media element has been excluded from this version of the text. You can view it online here:
<https://open.lib.umn.edu/largeanimalsurgery/?p=305>

Key Takeaways

Evaluate your patient. Will he be safe if he feels pain or something funny? If he isn't safe without pain, abort plan.

Stay close to the horse and with your handler on the same side

Give your preop meds PREOP.

Do not use xylazine alone as your sedation. Xylazine+butorphanol or detomidine +butorphanol would be much safer.

Block the spermatic cords and the skin with lidocaine.

If complications (hemorrhage, evisceration), you will want to lie him down. Be prepared for that possibility.

RESOURCES

[Equine Standing Sedation](#)

[Video compilation](#)— no video is perfect!

Postoperative care for equine castration

Thinking about the processes needed for normal healing and to prevent the common complications, what postoperative care recommendations would you give to your clients?

- Medications:
- Exercise:
- Nutrition:
- Other therapies:
- Monitoring:
- Call if:

Common questions

How long should a horse be stall rested after castration?

We typically put them in a stall for 24 hours. This has no real scientific background but is most likely related to avoiding eventration and letting any bleeding subside. It would also minimize heat stress and undue activity due to pasture mates

How long are pain medications indicated? Antibiotics?

Inflammation usually lasts at least 3 days after minor surgery. It is good animal care to provide freedom from pain. Older practitioners will report that we don't want horses to "overdo" it so they avoid NSAIDs. On the other hand, people used to "break" horses right after castration as they were more amenable (ie in pain and sedated). Neither version seems reasonable these days but old habits die hard.

The ideal for antibiotic coverage is to have high levels at the same of surgery in case things go wrong. If all goes well, continued antibiotics are typically not needed for castrations. Drainage is better than antibiotics at resolving any infection. Antibiotics are considered when the animal shows systemic signs (eg fever) despite good drainage.

When after castration does the stallion-like behavior goes away? Fertility?

Residual testosterone effects can last 6 weeks. Fertility should diminish sooner. Some stallions retain stallion-like behavior despite gelding-like testosterone levels. Another old wives tale is that these stallions are "proud-cut" and the "squealer" was left behind. In other words, the epididymis was left behind. The testicle is what makes testosterone and "squealing" in intact stallions, not the epididymis. And it is actually hard to leave the epididymis behind unless the horse is a cryptorchid. In those horses, the epididymis

is often loosely attached to the testicle and may be the thing removed. Leaving the testicle behind will definitely encourage them to retain stallion like behavior.

When should they call you about swelling, hemorrhage, things coming out?

This is a great time to come up with your favorite food or sports ball references. “Orange” sized swelling is generally okay. Bigger often indicates that the incisions have sealed shut (via fibrin tags). Hemorrhage that is a drip, not a spurt is okay. Things coming out may be fat (okay), tunic (okay), omentum (attached to intestines) or intestines (really bad). Images may or may not help with “things coming out” and an emergency visit is advised.

How is swelling managed?

Exercise is key to minimize swelling. Swelling is common as the area has been traumatized and is ventral. With exercise, lymphatic flow is improved and the edema removed. NSAIDs and cold water hosing can also help. If the swelling is significant, the edges of the incision tend to seal back together, trapping in bacteria. To reopen the incision, just pull the fibrin seal apart with digital manipulation. Do NOT take a scalpel blade back in there. It isn’t needed.

Exercises

Try the quiz to see how much you have learned:



An interactive or media element has been excluded from this version of the text. You can view it online here:
<https://open.lib.umn.edu/largeanimalsurgery/?p=302>

Key Takeaways

Drainage is key for postoperative management of the surgery site. To have adequate drainage, you need large holes and minimal swelling. To get minimal swelling horses need to exercise. Horses without pain relief will not exercise well. NSAIDs help them exercise and help with swelling. Horses should get about 3 days of NSAIDs postoperatively. One day of stall rest is often recommended but isn’t required.

If the drainage stops too soon, an infection is likely to develop. Drainage needs to happen. Generally recreating drainage just means using a gloved finger (with the horse sedated and twitched) to open the fibrin seal. Antibiotics are used only if the horse still has a fever after drainage.

Arterial bleeding, large swelling and things hanging out need veterinary attention. Large swelling is important, the others can be life threatening and need immediate attention.

It takes awhile for the horse to become infertile and to lose the mounting behavior of stallions. Keep him away from mares for about 6 weeks. Proud cut is not a thing.

RESOURCES

[Equine Castration Complications Reviewed](#), The Horse 2013

[Castration in the Horse](#), The Horse 2001 (but still really good)

Donkey castration

Donkeys are not just small horses! They tend to be more resistant to handling, anesthesia drugs and hemostasis. Plan on needing more patience, more drugs and suture. This vet talks through two castrations in different situations and different attitude donkeys.



An interactive or media element has been excluded from this version of the text. You can view it online here:

<https://open.lib.umn.edu/largeanimalsurgery/?p=477>

She does a great step by step for everything from calculating doses to how to find the jugular vein. You can also admire her calm control of the situation regardless of what happens.

Key components

8:44 – Drugs

20:42 and 24:09- Rope placement and induction, how to do rope restraint of back leg

25:53 – local blocks

27:00- Surgery – open castration with ligature-

Skip to:

43:21 -outside with a nervous jack

45:19- how to make a squeeze chute with two panels and a post

51:30 -recovery of nervous jack- could just let him get up on his own but notice she mostly just tries to hold him still so he doesn't stumble

Feel free to watch the entire thing (or thru the first end of castration at about 36 min). She covers instruments, why to castrate, preop exams and more.

Exercise 1

Thoughts on the video:

1. How did her doses (1.1 mg/kg xylazine and 2.2 mg/kg ketamine) compare to a horse of the same size?
2. What does the epididymis really do? What would happen if you leave it behind?
3. Why would standing castrations be more risky in donkeys (for the donkey)?
4. How does her recommendation for restriction from jennets (3 days to be infertile, 6 weeks to be less stud-

like) compare to the restrictions from mares?

5. What tips and tricks did you take away that would apply to any equid? Standard donkey weight of 550# was one I liked.

Exercise 2

Time to try finding some answers. Use whatever you can find to explore more about jack castrations:

1. She didn't give NSAIDs. Those are really useful. When should they be given?
2. Donkeys metabolize drugs differently. Do you need a different dose or frequency of NSAID administration for donkeys?
3. Donkeys have a tendency to bleed more. Why is that? Do most people ligate as she did?
4. Donkeys may not want to exercise properly. What do people recommend to minimize swelling in donkeys?
5. Donkeys can be extremely overweight. How will this affect drug dosing and recovery from anesthesia?
6. Some people feel older donkeys are unsafe to castrate? Why is this and is it true?

Exercise 3

Test yourself.



An interactive or media element has been excluded from this version of the text. You can view it online here:

<https://open.lib.umn.edu/largeanimalsurgery/?p=477>

RESOURCES

[Clinical approach to castration in donkeys](#), 2007 In practice

[Anesthesia and analgesia of the donkey and mule](#), 2013 EVE

Cryptorchidism

Use the resources below to find the answers to these questions. Then try to quiz to verify your answers.

Study Questions

Cryptorchids come in 3 flavors – high flankers, abdominal cryptorchids and monorchids. Monorchids are very rare. What is the difference between the other two?

Could either high flankers or abdominal crypts be reasonably castrated in the field?

What is the descent path of the testicle (so where might a cryptorchid testicle be found)?

Which testicle descends last (and might be more likely to be abdominal)?

If you are attempting to find the missing testicle on a cryptorchid animal, should you remove the descended one first?

What are the possible consequences of leaving a testicle in the abdomen, particularly if you remove the other?

Exercises

Now try your hand at these questions.



An interactive or media element has been excluded from this version of the text. You can view it online here:
<https://open.lib.umn.edu/largeanimalsurgery/?p=445>

RESOURCES

[Testicular descent animation](#)

[Cryptorchidism](#), McCue CSU

[Cryptorchidism](#), ACVS

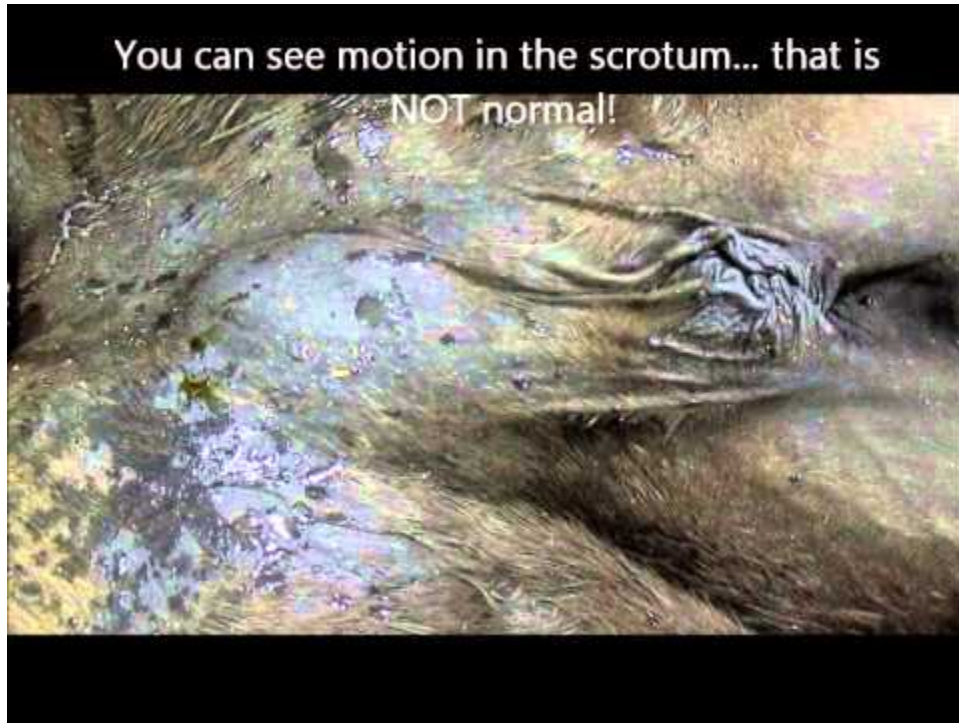[Cryptorchidism in horses](#), EVE 1999 (ignore the surgery descriptions)

[The Ambulatory Practitioner and the Referral Center](#), Vet Clin N Am 2012

[Inguinal percutaneous ultrasound of cryptorchids](#), EVE 2016

[The Cryptorchid](#), R-Vets- Note: just because you CAN do a cryptorchid surgery in the field, doesn't mean you SHOULD in most cases. Your ethical obligation is to provide the best care possible. If referral is possible, that is generally the best care.

Inguinal hernias



A YouTube element has been excluded from this version of the text. You can view it online here: <https://open.lib.umn.edu/largeanimalsurgery/?p=447>

Study Questions

Inguinal hernias in adult stallions are concerned emergencies and often require surgery to remove entrap intestines.

What about in foals? Are these emergencies? Do they need surgery?

How do you diagnose them? How are they managed? Are there breed predilections?

How would you adjust your castration plan if you knew the horse had a history of inguinal hernia? Diagnostics? Surgical approach? Postop care?

Are they considered an inherited trait?

Exercises

Try these after you do your research:



An interactive or media element has been excluded from this version of the text. You can view it online here:
<https://open.lib.umn.edu/largeanimalsurgery/?p=447>



An interactive or media element has been excluded from this version of the text. You can view it online here:
<https://open.lib.umn.edu/largeanimalsurgery/?p=447>

RESOURCES

[Management of inguinal hernias in foals](#), VetFolio, 2019

[Hernias explained](#), The Horse, 2008

[Selected pathological conditions in horses](#), AAEP 2015 page 272 (will link to the entire proceedings)

Castration complications

With any surgery, there are standard complications:

Infection

Equine castrations are generally performed in a non-sterile environment with incisions left open; contamination is ensured. As long as the incisions stay open for drainage, infection doesn't typically cause any problems. Issues with infection develop when drainage is impaired (as when the incisions close up too soon) or when chromic gut is used to ligate the vessels (since it is highly irritating). Gut is rarely used for castration now and other suture types seem much safer.

Infection at the castration site can potentially extend into the abdomen, causing peritonitis. Subclinical peritonitis definitely occurs after castration but rarely causes issues. Open castrations are potentially riskier in that they open the peritoneal cavity but closed castrations carry other risks.

Hemorrhage

The testicular arteries can bleed well. Generally hemorrhage is controlled by innate clotting mechanisms, ligation or by pressure.

It is close to impossible to apply effective pressure to the testicular arteries due to their location.

Many castrations are performed without ligation, using only crushing to stimulate natural clotting. If the crush is not effective, hemorrhage can be significant and potentially fatal. To ensure a good crush, the emasculators need to be assembled and used correctly so that the crush is proximal on the cord and the cut is distal. New emasculators can accidentally cut with the crushing part of the instrument. Many practitioners use the emasculators on rope a few times to dull the new metal in the crush section.

Ligatures can be used to control hemorrhage. Modified Miller's knots are more effective than typical surgeon's knots but both can be used successfully. Use material that will not cause long lasting irritation (eg not chromic gut).

Swelling

Swelling is always an issue with surgery and is always exacerbated in ventral locations such as the scrotal area. Swelling will occur with your surgery and is typically the most severe at 2-3 days postoperatively. After that time it should decrease gradually; continued swelling can indicate infection.

Swelling can be decreased by pressure, cold hosing, NSAIDs and exercise. As applying pressure in the area is tricky, that is typically not used.

Cold hosing can be used if tolerated by the horse. The hose should not be directed up into the incisions since that would be aiming directly into the abdomen. Some horses will not tolerate cold hosing and it is not worth the risk to the owner or to the horse.

NSAIDs should be part of your protocol both for analgesia and control of swelling.

Exercise will help to minimize and reduce swelling by encouraging blood flow and lymphatic drainage.

Hydrocoele is another complication that can lead to swelling. The tunic closes and peritoneal fluid fills the tunic giving the appearance that the horse has regrown his testicles.

Poor healing

Poor healing is generally related to the factors listed above or to foreign material in the wound. If the incision continues to drain and does not close, it is likely that there is or was a foreign body in the wound. General anesthesia and wound exploration is indicated. Persistent infection can lead to spermatic cord infection. Spermatic cord infection can extend into the abdomen and require abdominal surgery to remove the infected cord.

Tetanus

Tetanus is uncommon but is life-threatening and horses are very sensitive to the bacterium. The vaccine works well and is highly protective. A booster is required for full protection. Since castration is an elective procedure, horses should receive their initial tetanus toxoid at least two weeks prior to castration and can receive their booster shot at the time of castration. If a horse must be castrated in a shorter time frame, tetanus anti-toxin is recommended to provide immediate protection. Serum hepatitis is a risk with tetanus antitoxin.

Tetanus vaccines are widely available; however, cold storage is necessary to maintain efficacy. Clients may not be aware of the careful handling and storage needed.

Evisceration

Evisceration is a risk for any abdominal incisions or wounds. Intestines are slippery and can fit through small holes, particularly when the holes are ventral. Gravity works in most parts of the world and once the intestines start to slide out, the weight of the exposed intestines means more is likely to follow.

Challenges

Use your search powers ([see the resource page](#)), your new knowledge base and the resources below to try and find answers to the questions below.

- When is postoperative hemorrhage considered significant? What would the owner notice?
- Why is it important to not have the cord stretched out when applying the emasculators?
- What would you ligate a cord with? Hint: Gut is bad.
- If hemorrhage is significant, would you manage the colt standing or recumbent? What do you do? What if

you can't do that?

- What extra supplies should you bring with you for castrations, just in case of hemorrhage?
- *****
- When is postoperative swelling excessive? What size fruit?
- What is the association between postoperative swelling and drainage?
- When and how do you open up the swelling to allow it to drain?
- Should the horse be on antibiotics? How do you know?
- How do you prevent issues with postoperative swelling?
- What is the time frame for swelling after surgery?
- *****
- What structures could come out the scrotal incisions besides intestines? What would an owner be able to identify to tell you about?
- Are certain breeds, ages or conditions more prone to evisceration (eventeration)? What would you do to prevent issues?
- What is the time frame for risk of evisceration after castration?
- The animal stands up and is eviscerating. Do you manage him standing or recumbent? What do you do? What if you can't do that?
- What extra supplies should you bring with you for castrations, just in case of evisceration?
- *****
- What is schirrous cord/ Why does it develop?
- Are certain breeds, ages or conditions more prone to schirrous cord? What would you do to prevent it?
- What is the time frame for when schirrous cord is likely to happen after castration?
- How do you diagnose schirrous cord?
- How do you treat schirrous cord? What if you can't do that?
- What extra supplies should you bring with you for castrations, just in case?
- *****
- When does penile trauma happen and what is needed for treatment?
- When does hydrocoele happen and what is needed for treatment?
- What does peritonitis look like and what is the treatment?

Exercises

Try these cases to see if you agree with my recommendations:



An interactive or media element has been excluded from this version of the text. You can view it online here:
<https://open.lib.umn.edu/largeanimalsurgery/?p=286>

RESOURCES

[A prospective multicentre survey of complications associated with equine castration to facilitate clinical audit.](#) EVJ 2019- spoiler alert – they didn't find many complications. And the Brits are way ahead of us with proper analgesia.

[How I manage castration complications in the field.](#) AAEP 2015 p 224.

[Incidence, management and outcome castration complications.](#) JAVMA 2013

[Review of castration complications: Strategies for treatment in the field.](#) AAEP 2009

[Open standing castration in Hong Kong: prevalence and severity of complications.](#) EVJ 2018

[Surgical management of postcastration spermatic cord infection in horses.](#) Vet Surgery, 2018

Castration Summary Points

Key Takeaways

- Castration is an elective procedure. Make sure your patient is healthy, able to be handled and has 2 testicles
 - Early castration leads to delayed growth plate closure and taller, finer boned and straighter-limbed animals
 - Early castration may result in narrowed urethras
- Give analgesics preoperatively to prevent windup phenomenon. Local blocks help.
 - continue analgesics postoperatively
- Most recumbent anesthesia procedures use xylazine/detomidine/romifidine combined with ketamine. Adding butorphanol, diazepam or midazolam, or guaifenesin can increase the effective duration and smooth recovery
 - Detomidine gel is absorbed through mucous membranes and can provide some sedation (takes about 30 min to work)
 - Diazepam doesn't play well with others; can be mixed with ketamine but not xylazine
- Tetanus toxoid is required. If the horse has been vaccinated within the past 6 months, that is usually considered adequate.
 - Tetanus antitoxin has side effects.
- Preop penicillin (or ceftiofur) may decrease complication rates. Giving after the procedure is not as effective.
- Surgery and recovery is best done in an open grassy field.
 - Field recoveries are generally low risk even with wild things but finishing with xylazine or romifidine (1/4 dose) can help smooth things
 - You can keep a horse down by controlling the head and neck (sit on the neck, hold the nose up)
 - Remove the halter to avoid pressure on the facial nerve
- Closed castration is preferred in young animals; open castration in horses with large arteries
 - The more I do, the less I like closed castrations
- Don't remove any testicles unless you are sure you can see both
- Plan for complications and ensure you have needed supplies
 - Especially suture and more drugs
- If hemorrhage or evisceration develop, re-anesthetize the horse.
- Most common complication is postoperative swelling due to early closure of the wound
 - Exercise is important for minimizing swelling postop

- Make big holes and stretch the skin to make the incision as big as possible
- Leave holes open!
- If the incisions close, they can be reopened using your fingers. Twitch the horse first!
- Inguinal hernias in foals usually resolve on their own. Surgery or medical care is not needed.
- Cryptorchid stallions are not ideal breeding candidates.
- Proud cut doesn't exist despite continued beliefs from horse owners and horse vets
 - So just remove the epididymis and don't blame it
- You have less control over standing castrations

Challenge yourself!

Exercise 1

Take the castration review quiz as often as you like. Different questions will come up each time.



An interactive or media element has been excluded from this version of the text. You can view it online here:
<https://open.lib.umn.edu/largeanimalsurgery/?p=516>

Exercise 2

How does what you have learned compare to this castration:



An interactive or media element has been excluded from this version of the text. You can view it online here:
<https://open.lib.umn.edu/largeanimalsurgery/?p=516>

For Future Reference I Castration planning

Optional. Complete the study guide to review the steps BEFORE you get ready to castrate a colt.



An interactive or media element has been excluded from this version of the text. You can view it online here:
<https://open.lib.umn.edu/largeanimalsurgery/?p=259>

For Future Reference | Field Anesthesia

Optional. Complete the study guide to review the steps BEFORE you get ready to anesthetize a colt for castration or similar short procedure.



An interactive or media element has been excluded from this version of the text. You can view it online here:
<https://open.lib.umn.edu/largeanimalsurgery/?p=330>

For Future Reference I Postcastration Instructions

Optional



An interactive or media element has been excluded from this version of the text. You can view it online here:
<https://open.lib.umn.edu/largeanimalsurgery/?p=533>

Equine wounds

This section is designed to support LAS I wounds and lacerations discussions

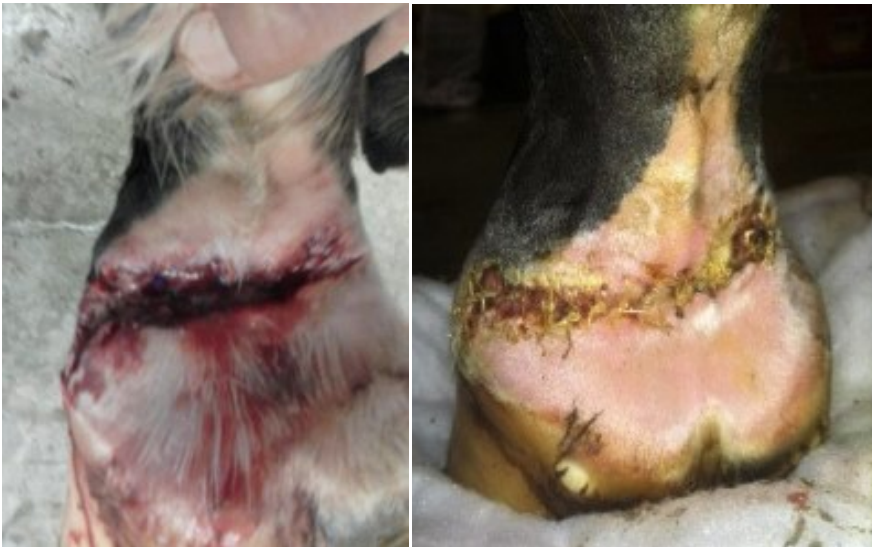Evaluation

Horses are prone to injury. The most common lacerations are on the distal limbs but head injuries are also frequent. While many factors of wound healing and management are similar across species, horse limb injuries need particular care and attention.

TYPE OF INJURY

Sharp or blunt trauma

Injuries with sharp objects (including incisions) are less traumatic than blunt trauma and ripping forces. With blunt trauma, the wound tissues continue to deteriorate over time. This may mean any initial repair falls apart. Swelling continues to increase over the first 3 days. Natural wound debridement is also occurring over this time period, sometimes leading to weaker tissue in the repair. If the wound is going to dehisce, that process usually starts between 2-3 days after wounding.



repair was starting to fail a few days later

The heel bulb laceration was sutured but the

Clean or contaminated wound

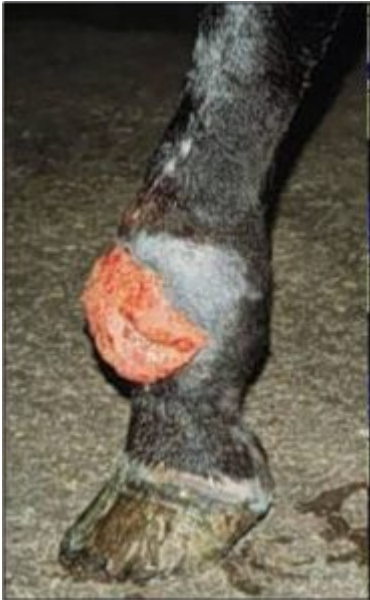Unless the wound occurs during surgery (eg an incision), most equine wounds are considered contaminated. Some are heavily contaminated with mud or manure from the start; others are minimally contaminated. As with other species, all wounds are considered to be infected after 6 hours (the golden period). Closure at this stage will often lead to abscess formation unless the wound is well debrided and/or drainage is created.

Horses are very sensitive to Clostridium bacteria and to tetanus infection. Any wounded horse should be boosted with tetanus toxoid if it has been more than 6 months since the annual vaccine. If a horse has a deep wound and no history of tetanus toxoid, the horse should also be treated with tetanus antitoxin. Tetanus antitoxin does carry the

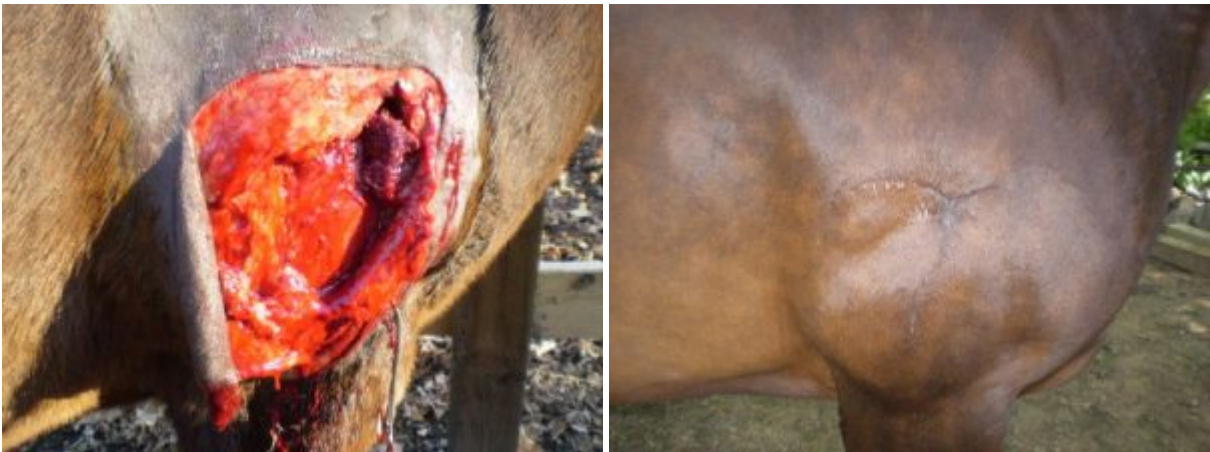risk of serum sickness (immune response to equine antibodies) and is not given if the horse has been vaccinated previously.

Wound location

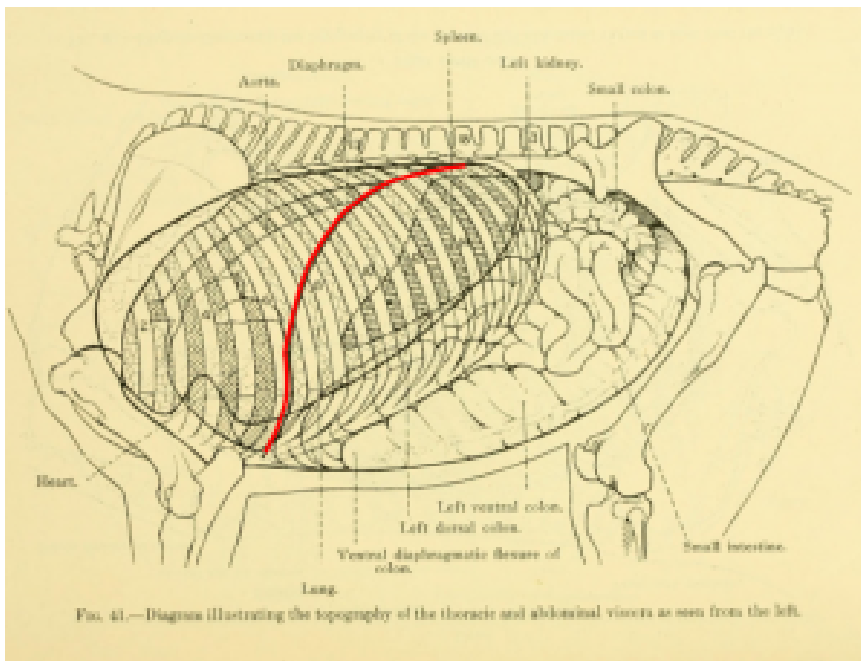
Wounds below the hock and carpus are much more challenging to manage than wounds above the hock or carpus due to the risk of damage to deeper structures and to the risk of exuberant granulation tissue.



Wounds on the upper limb tend to heal well, even with muscle damage or skin loss.



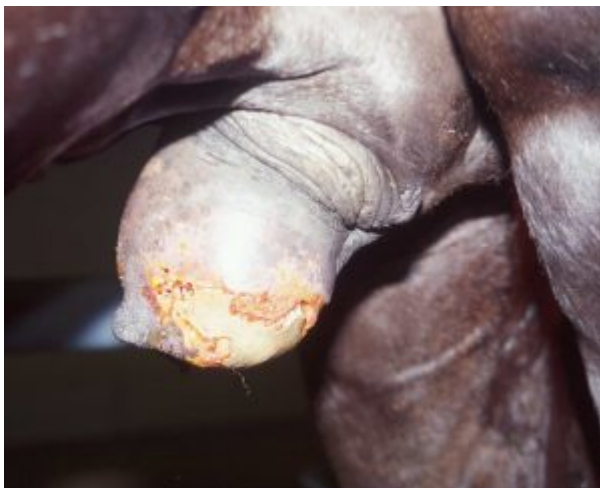Wounds over the thorax or abdomen can penetrate either the abdominal cavity, the thoracic cavity or both. Due to the shape of the diaphragm, any wound after the 6th intercostal (between rib) space can enter the abdominal cavity.



If the thoracic cavity is penetrated, the horse may develop life threatening pneumothorax. These wounds should be closed or covered with saran wrap or vaseline impregnated gauze and transported to the nearest referral hospital. If the abdominal cavity is penetrated, evisceration of intestines is common. Any exposed intestines should be rinsed and forced back into the abdominal cavity. The hole should be closed or wrapped to minimize movement of any other intestines out of the wound prior to transport to a referral hospital.

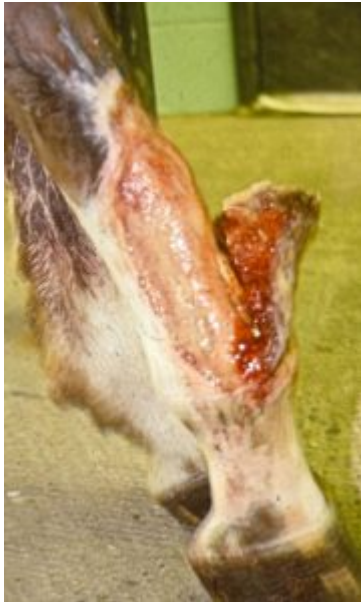Wounds of the head tend to heal well due to the high vascularity of the head structures, including bone. However, wounds of the eyelids or periocular structures should be evaluated and managed carefully to identify and prevent globe damage from incomplete lids (exposure keratitis) or uneven lids (corneal ulcers from rubbing). Wounds entering the sinuses or airways are considered contaminated.

Wounds to the urogenital structures are considered contaminated. These wounds tend to swell significantly with the swelling leading to secondary issues such as preputial prolapse, paraphimosis and urinary obstruction. These tissues do have good healing potential but the healing process should be monitored to detect issues early.



Skin flap or skin loss

Horse wounds often have missing skin or large skin flaps. Skin flaps will survive only if they have adequate blood supply. If the base of the flap is proximal (on the body side) it generally has good blood supply if it is wide enough. Flaps that have the base distal (on the foot side; away from the blood supply), often do not survive. Flaps with a thin base will often die off as will the tip of triangular flaps. These flaps can be used to “bandage” the wound but will generally need to be debrided to permit complete wound healing.



Generally the flap for distal limb wounds is based toward the foot and will have limited blood supply

Many wounds cannot be closed primarily. Horse limbs have very little loose skin to cover wounds and wound healing is often delayed or impaired by missing skin. Missing skin leads to wound desiccation (drying) and potentially to bone sequestration. Wounds below the hock and carpus that are left open to heal often develop exuberant granulation tissue.

Eyelid wounds should not be debrided; this area has good blood supply but do not tolerate missing skin. Never trim the flap of an eyelid wound; all parts should be reconnected to avoid lid margin scarring and exposure keratitis. If concerned, these cases should be referred.

Age of the wound

Not all wounds are identified immediately. Maggots and granulation tissue do not happen in the first 24 hours. Older wounds may also have been treated with various topical agents.

UNDERLYING STRUCTURES

Vascular damage

Most wounds do not lead to significant blood loss. However, if an artery is cut, blood loss can be fatal. In distal limb wounds, the palmar/plantar digital artery can be damaged. Arterial damage leads to pulsatile and audible spurts of blood. These wounds require rapid hemostasis. Tight bandages can be applied while waiting for the

veterinarian. The veterinarian may be able to ligate or clamp the bleeding artery and/or apply a fresh bandage. Tourniquets can be placed and maintained for ~30min with minimal risk.

Historical blood loss can be assessed through the physical examination. Horses with low blood volume will have elevated heart and respiratory rates and may have pale mucous membranes. The PCV and TPP will not change until the horse is rehydrated as the relative amounts of red blood cells remain stable with whole blood loss.

Horses with blood loss should be kept calm and referred to a hospital capable of plasma therapy or blood transfusions. Acepromazine should not be used to sedate the horse due to its hypotensive effects.

Synovial damage

Equine limbs have minimal protective muscle or fat. It is relatively easy for wounds to penetrate joints and tendon sheaths or to damage nerves and tendons. Knowledge of limb anatomy is crucial. Any wound over a joint or in the region of a tendon sheath should be evaluated for penetration of synovial structures. Remember the joint capsules extend beyond the bones of the joint and that the deep flexor tendon sheath runs on the palmar/plantar surfaces of the lower 1/3 of each cannon bone and down through the pastern region.

One of the easiest ways to evaluate synovial penetration is to attempt to distend the joint or tendon sheath. These structures should pressurize with added fluid, meaning the fluid shoots out of the needle or forces the syringe plunger outwards. If the structure cannot be pressurized, it is leaking. To pressure the structure, the needle should be inserted through a cleaned area with intact skin and not over the wound or disturbed tissues.

Tendon injury

The flexor tendons run on the palmar/plantar aspects of the limbs and are responsible for limb support. If the superficial tendon is damaged, the horse may have a slightly dropped fetlock. If the deep flexor tendon is disrupted, the toe will be elevated when the horse walks. Damage to the suspensory ligament (breakdown injury) is associated with a markedly dropped fetlock and often includes damage to the vascular supply from overstretching. If flexor tendons are partially damaged, weight bearing can lead to complete tears. It is important to stabilize these injuries as soon as possible to minimize further damage. The limb should be casted or splinted with the heel elevated (ballet dancer position). Prognosis is guarded for performance.



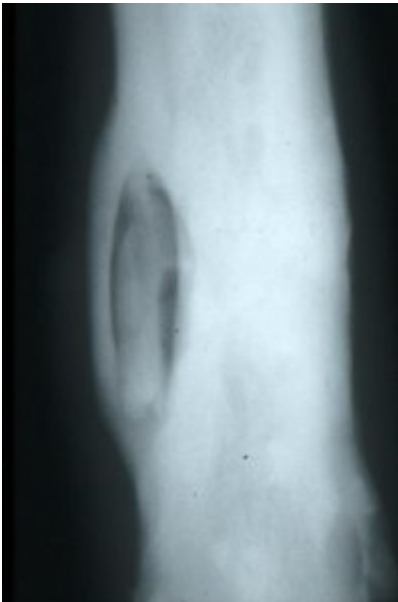
A YouTube element has been excluded from this version of the text. You can view it online here: <https://open.lib.umn.edu/largeanimalsurgery/?p=1310>

The extensor tendons run on the dorsal aspects of the limbs and are important for limb position. The extensor tendon flips the foot forward so that it lands on the solar surface. When the extensor tendon is transected, the horse will tend to knuckle forward and be unable to flip the foot into the normal position. Once the limb is flipped forward, the horse can weight bear normally. These injuries heal quickly with little residual deficits. Splinting the limb for 2-3 days is often all that is required. The damaged tendon does not need suturing.




Periosteal or bone damage

Due to limited soft tissue covering, many injuries to the equine distal limb damage the periosteum and expose the bone. This can lead to sequestrum formation. Sequestra are pieces of dead bone that develop over 2-3 weeks. These are seen as foreign bodies by the immune system. The immune system attempts to destroy the dead bone through lysosomal actions and, when that isn't successful, then tries to wall the dead bone off with additional bone formation (involucrum). Sequestration should be suspected with the wound continues to drain after 2 weeks. Radiographs are often needed to identify the bony changes. To prevent sequestrum formation, the wound should be kept moist and covered. The surface of the bone can be rasped to debride the top layer of contamination.



Limb was caught in a metal feeder. The dead bone (sequestrum) is surrounded by new bone (involucrum)



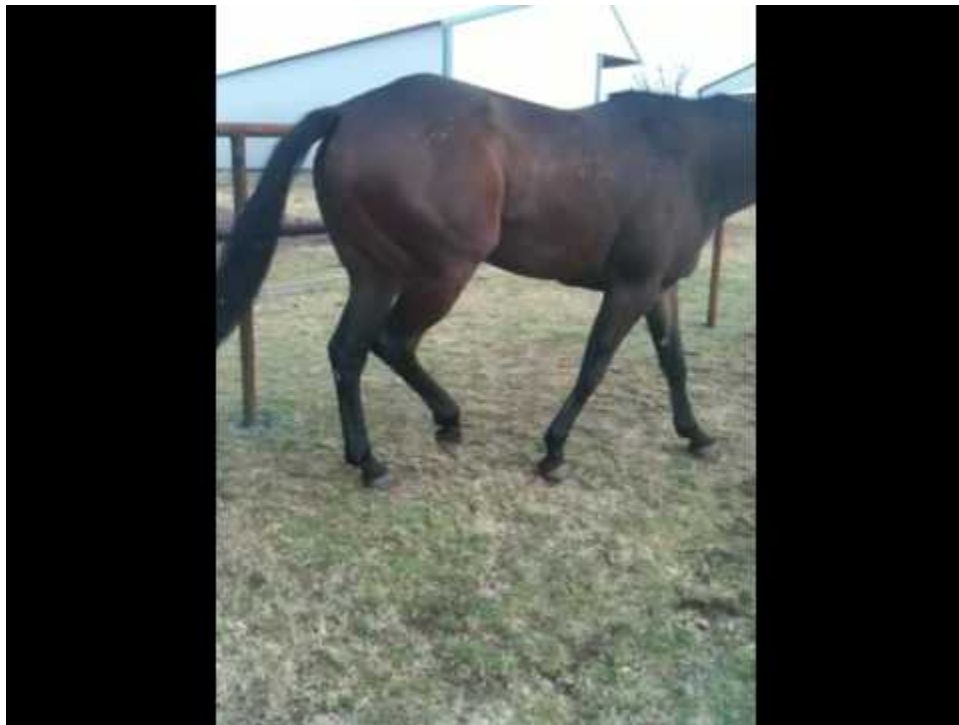A YouTube element has been excluded from this version of the text. You can view it online here: <https://open.lib.umn.edu/largeanimalsurgery/?p=1310>

Direct damage to the bones is also possible. Fractures of the splint bones (metacarpus/metatarsus II and IV)

and the fibula are relatively common with wounds. Radiographs are recommended, particularly in horses with significant lameness or wounds on the palmaro/plantarolateral or palmaro/plantaromedial aspects of the cannon bone.

Muscle injury

Muscle heals well and muscle injury does not usually complicate wound healing unless the resultant scar tissue is restrictive. This is a concern when the semitendinosus and semimembranosus muscles are damaged. Injuries in this area (caudal aspect of the hindlimb above the hock) can lead to fibrotic myopathy. Fibrotic myopathy is a gait abnormality in which the forward stride is restricted. As the limb moves forward, the muscles are designed to stretch to allow full arcing motion. However, if there is scar tissue in the muscles, they only stretch so far. The limb is then slapped down to the ground suddenly. The gait abnormality is most readily seen at a walk and is nonpainful.



A YouTube element has been excluded from this version of the text. You can view it online here: <https://open.lib.umn.edu/largeanimalsurgery/?p=1310>

Acute wound management

Wound management in the field involves balancing the three parts of the equation:

- The wound
- The horse
- The environment

Wound care can be straightforward in the appropriate environment with a well mannered horse. However, referral should be strongly considered with an ill-tempered horse or an unsafe environment even with simple wounds. Horses with significant blood loss, unstable limbs (fractures or tendon damage) and with potential synovial involvement should be referred as soon as possible. Call the hospital to determine what splints or medical therapy is needed to support the animal during the drive.

Sedation

Sedation is often necessary to evaluate equine wounds. Alpha adrenergic compounds are the most common drugs used (xylazine, romifidine, detomidine). Besides sedating the horse, these drugs change the horses weight bearing so that most of the weight is on the forelimbs. This means horses are more likely to kick and less likely to warn. Xylazine should not be used alone for hindlimb procedures. Detomidine creates a more balanced stance. Xylazine combined with butorphanol also leads to better weight bearing. Occasional horses will become xylazine aggressive (trying to bite). Add butorphanol to increase sedation and minimize the use of xylazine in the future.

Standard sedative doses for a 500kg horse –
150-250 mg xylazine +/- 5-10 mg butorphanol iv
5 mg detomidine +/- 5 mg butorphanol iv

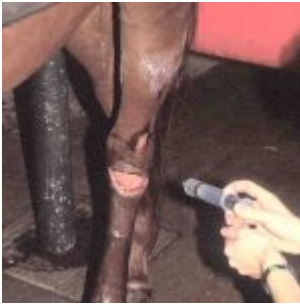
Acepromazine is a long acting sedative that is hypotensive. It should not be used in stallions, geldings with penile injuries or in horses with significant blood loss. Otherwise, a combination of xylazine, acepromazine and butorphanol (“RAT”; 10mg ace + 200 mg xylazine + 10 mg butorphanol/500kg horse) is very useful for ill-tempered horses.

Wound cleaning

The wounds should be cleaned of gross debris. Avoid soaps in the wound. The wound can be covered with sterile lube to protect it while the hair surrounding the wound is clipped and the wound margins cleaned with betadine

scrub. The soap can be removed with distilled water or alcohol. Chlorhexidine is more toxic and should be used only in very dilute concentrations. Once the wound edges are cleaned, the surface of the wound can be wiped off with sterile saline or distilled water. Sharp debridement is then used to remove the contaminated tissue surface unless the removal of tissue could lead to issues (open a synovial structure, prevent eyelid laceration closure). Exposed bone may be rasped to clean and bleeding layers.

While lavage is useful, avoid high pressure lavage that may force bacteria and debris deeper into the tissues. A 35cc syringe + 18ga needle creates a good level of force.



Hydrogen peroxide is also bad for wounds. The bubbling creates new tissue planes and it is cytotoxic.

At this stage, the wound should be evaluated for damage to deeper structures.

Wound closure

After complete evaluation and cleaning, the veterinarian must decide if the wound should be closed primarily, with delayed closure or left to heal by second intention. Many wounds cannot be closed, making the decision easy. If closure is possible, most vets will attempt it. However, it is important to avoid creating an abscess in the area. Ensure the wound can drain ventrally if needed. Often this is most readily done with an incision at the ventral aspect or by leaving the wound partially open. If the incision is made perpendicular to the lines of tension, it will stay open longer. Penrose drains can be used; these should not exit the wound or incision and should be pulled in 2-3 days as they create additional inflammation.

While delayed primary closure can be useful in small animals, in large animals it doesn't often work as wound retraction occurs, enlarging the wound surface area and making it even harder to close.

Expect dehiscence in areas of high motion or high tension. Warn owners that the wound may fall apart in 2-3 days. Managing the swelling may help.

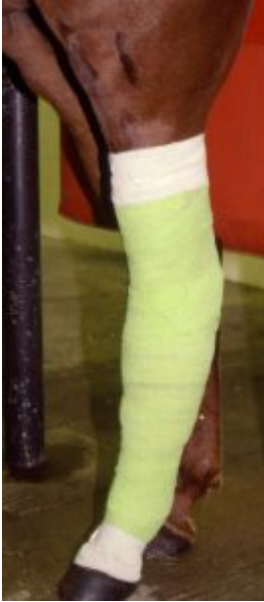Topical wound agents

If the wound cannot be closed, topical salves may help keep tissues moist and minimize wound healing delays. Water soluble ointments are preferred over oil based ointments. Agents should be safe for new epithelial cells. Avoid toxic compounds. Generally triple antibiotics (neomycin + polymyxin + bacitracin) or silver sulfadiazine are used.

Bandaging

Generally horse wounds are bandaged initially to prevent further contamination. Bandages do promote

granulation tissue formation so are generally only needed in the initial stages of wound healing unless the limb is unstable or are used to minimize motion.



Antibiotics and/or antiseptics may be applied to the wound and then the wound covered by a nonstick pad that is held in place with a soft wrap. A support wrap is then placed on the limb. This is often a manufactured bandage or sheet cottons. This layer is held in place with brown gauze or vetwrap. The brown gauze and/or vetwrap is applied snugly with even tension. Bulges or bumps in the support layer can lead to tendon damage. A bandage that is too loose will fall down, creating folds and bulges. After a vetwrap layer to hold the support wrap in place, the ends of the bandage may be taped to the limb to minimize contamination from either the top or the bottom openings.

Medications

NSAIDs will slow wound healing but so will swelling. NSAIDs (phenylbutazone, flunixin meglumine) are useful to control the initial inflammation (first 72 hours) but then should be discontinued. Most horses are not painful after the incident. Signs of pain would indicate deeper trauma to bone, tendons or ligaments.

Systemic antibiotics are generally not indicated unless deeper structures are involved. In these cases, iv antibiotics may be needed. Regional perfusion of antibiotics can help with deeper wound management in the distal limb. A tourniquet is placed on the limb and a dose of antibiotics given iv below the tourniquet, concentrating the drug in the area needed. Antibiotics may also be injected directly into the synovial structures.



Regional limb perfusion performed on a cria

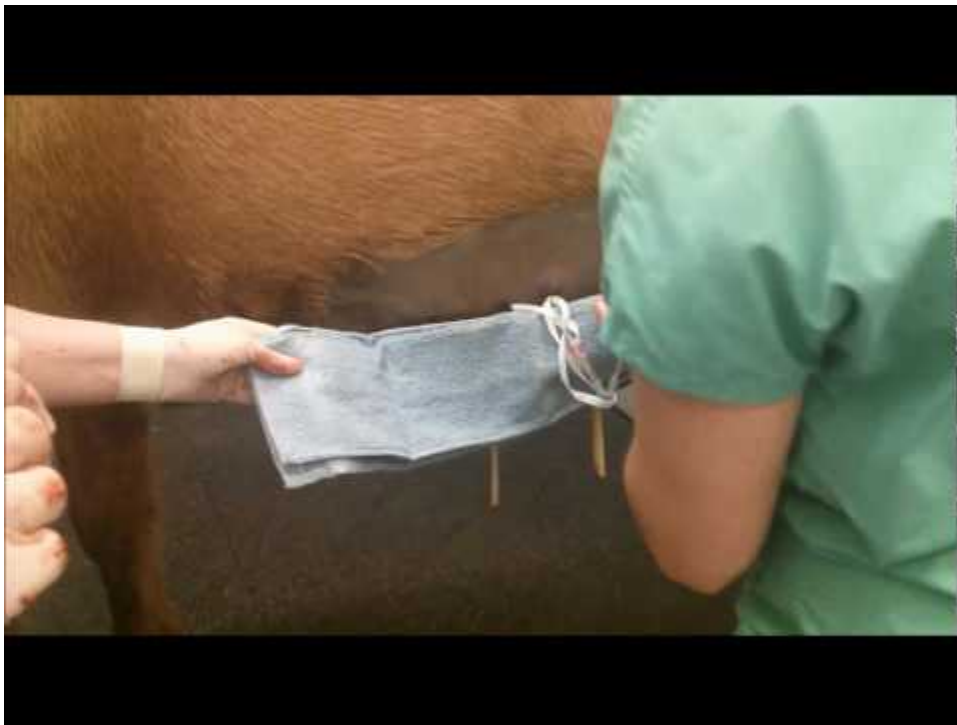Once granulation tissue has developed, it will protect the wound from outside contamination.

Restrict motion

Generally limited motion will improve healing. Stall rest without handwalking. Bandages and splints may be useful.

Chronic wound management

Wounds left to heal by second intention generally do very well, particularly those above the hock or carpus. The wounds should be kept clean and dry, potentially covered by a water based ointment to maintain tissue moisture. Lower limbs may be bandaged until granulation tissue fills the defect. Wounds on the upper limbs or torsos may be difficult to bandage. Bandages can be sutured over the wound if needed (stent bandage). Circular loops of suture are placed adjacent to the wound and a fresh towel or pad held in place by “laces” threaded through the loops.



A YouTube element has been excluded from this version of the text. You can view it online here: <https://open.lib.umn.edu/largeanimalsurgery/?p=1325>

After granulation tissue fills the defect, bandaging of lower limb wounds is generally contraindicated. Exceptions include wounds near the ground or in very contaminated environments. Occasionally horses will chew at the wounds; these may need bandaging for protection but are challenging even then.

Many horse owners will want to apply various solutions to the wound to prevent proud flesh (exuberant granulation tissue) formation. While most of these agents do control proud flesh, they also damage the new epithelial cells. If needed, corticosteroid cream can be applied in a light layer once weekly.

654 Large Animal Surgery

Activity should still be restricted if possible.

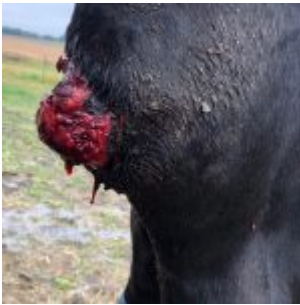Managing complications

Many equine wounds on the head, neck, upper limbs and torso heal rapidly and well. Occasionally the wounds need to be kept open to ensure they heal from the inside out or abscesses will occur. Ventral drainage is key. Packing with gauze, honey or sugar can also help encourage wound healing without premature closure.

Lower limb wounds frequently have issues.

Proud flesh (exuberant granulation tissue)

Due to the poor oxygenation levels in the lower limb, horses tend to develop exuberant proud flesh. In these horses, the new granulation tissue grows above the level of the wound, preventing epithelialization. The proud flesh must be removed so that the new skin cells can cover the surface.



Proud flesh removal can be done with a laser, sharp blade or safety razor. The tissue does not have nerve endings so the process is not painful if the skin margins are not cut accidentally. However, it will bleed profusely. After debridement of the proud flesh, a “bandaid” or short term wrap can be used to apply pressure to the surface. This should be removed after bleeding stops (or the following day) to minimize the risk of more granulation tissue. After removal, a light layer of corticosteroid ointment can be applied.

Owners can be taught to recognize the early signs of proud flesh and shown how to trim it back with a safety razor.

Sequestration

A superficial layer of cortical bone can die off with wounding. This may be related to direct damage, contamination or a combination of factors. The dead bone detaches from the parent bone but is often trapped in the wound. Due to the dead fragment, the wound does not completely fill with granulation tissue. If the wound is otherwise doing well, the skin may heal but with a persistent draining tract. In other situations, it is obvious that part of the wound is not being covered by pink granulation tissue. Radiographs are used to identify the location and size of the sequestrum. The optimum time to evaluate a wound for sequestration is 2-3 weeks after injury. Before that time, it is not radiographically apparent. After that time, it may be harder to remove as more bone is laid down over the top of the dead fragment.

Surgical removal is required. Occasionally this may be done standing; other cases may require general anesthesia. The process will set back the wound healing process but it should proceed more smoothly this time.

Foreign bodies and infected or damaged tendons and ligaments can also lead to poor granulation tissue coverage and draining tracts.

Poor epithelialization

The horse's leg does not have much loose skin. A larger wound may not be able to completely epithelialize. If wounds stop contracting before complete healing, a skin graft may be necessary. The most common forms of skin grafting are punch or pinch grafts, with donor skin being taken from the neck or ventral abdomen. Skin grafting does require strict immobilization to allow the skin plugs to attach and vascularize.

The swollen limb



An interactive or media element has been excluded from this version of the text. You can view it online here:
<https://open.lib.umn.edu/largeanimalsurgery/?p=2295>

Equine Drugs

Equine drugs are even simpler than food animal drugs due to the current lack of market for equine meat. This section discusses equine NSAIDs, analgesics, antibiotics and anesthetic agents.

Equine Analgesics

Analgesics need to be given prior to the pain stimulus to prevent [hyperalgesia](#) and [wind-up](#) phenomenon. This preemptive analgesia decreases the amount of pain produced but does not prevent pain. Analgesics should also be used after the stimulus to control the resultant pain. Pain is generally but not always related to the release of inflammatory mediators.

We don't do this well now. Often we give our perioperative antibiotics after the procedure and we offer NSAIDs as a client option. If we give NSAIDs, it is often after recovery. *And this makes no sense other than tradition..*

- Giving antibiotics preop means they are on board to fight any contaminants. Giving them afterwards means the little buggers have had time to gain a foothold and even multiply.
- Giving clients the option of NSAIDs means costs drives the discussion. Every horse deserves pain relief
- Giving NSAIDs after the procedure is NOT cost effective. Your drugs are less useful due to windup and you have to give more to get to the same effect.
- If cost is a concern, a preop dose is the most cost effective!

NSAIDs are the most commonly used analgesic and the most common nonsteroidal agents used in horses are

Phenylbutazone

“Bute” is the cheapest NSAID and is available in oral (tablet, powder, paste) and iv formulations. It is very irritating so should never be given im. Phenylbutazone is also the least safe in terms of side effects. Standard doses for 1000# horses are 2-4 grams per day. The high end of the range (4 grams per day) should be given for as few days as possible. Phenylbutazone is generally used for musculoskeletal issues.

Bute does come in smaller sizes “baby bute” and can be compounded with flavoring. It has excellent bioavailability. Higher doses increase duration vs increasing analgesia.

Flunixin meglumine

Flunixin or “Banamine” is more expensive than “Bute” but is considered safer. It is generally used for gastrointestinal or other visceral pain. It comes in oral (paste) or iv formulations. While labeled for intramuscular use, it should never be given intramuscularly as it creates a significant risk of clostridial myositis.

Bioavailability is good at 80%

Firocoxib

Firocoxib or “Previcox” is a newer NSAID that is much safer and the most expensive. It is used for long term therapy in horses that don’t tolerate phenylbutazone. Use of the small animal version is common but illegal.

A 3x initial dose is often used to more rapidly increase serum levels (FWIW).

Diclofenac sodium

Diclofenac or “Surpass” is a topical NSAID that is applied to inflamed areas. Side effects are minimized by restricting the dose to the affected site (minimal systemic absorption). It has been used rectally for postop pain.

General notes for NSAIDs

Increasing dose leads to increased duration of action rather than increased efficacy. 2 grams once a day has similar activity to 1 gram twice a day.

Blood levels are mostly irrelevant. NSAID levels at the site of action are necessary to determine appropriate dosing. *And many articles publish blood levels...* Be cognizant of their purpose in measuring blood levels. Many times blood levels are needed for regulatory purposes (eg did the horse show or perform while on NSAIDs?). This is not the same as effectiveness of the drug. And the discussion portion of the article often confuses the two.

Most common side effects are gastrointestinal (stomach ulcers, oral ulcers, right dorsal colitis) and urinary (kidney failure, hemorrhagic cystitis). Monitoring appetite, serum total protein and urine specific gravity are useful to help identify issues early. However, prostaglandins are important in most facets of physiology so NSAIDs have the potential to interfere with everything from bone healing to parturition.



An interactive or media element has been excluded from this version of the text. You can view it online here:

<https://open.lib.umn.edu/largeanimalsurgery/?p=245>

Non-NSAID drugs are used when additional pain relief is needed or when the pain isn’t caused by inflammation:

Butorphanol

Schedule IV

Butorphanol is a narcotic analgesic. It acts as a narcotic but can reverse other narcotics. It is commonly used in combination with sedatives such as xylazine or detomidine.

Typically, 0.5 -1 ml is given iv or 2 ml im (10 mg/ml). It is absorbed orally, as well.

More effective than morphine, it starts working in ~ 15 minutes and can last up to 4 hours.

Butorphanol is excitatory in healthy adult horses so should not be given alone. It is more of a sedative in neonates and tends to not cause excitement when given im to horses in pain (but use caution). Repeated doses can lead to poor motility and colic.

Butorphanol can reverse the effects of other narcotics so shouldn't be given until those have worn off.

Reversal: naloxone

<https://equimed.com/drugs-and-medications/reference/butorphanol>

Morphine

Schedule II

Morphine is a narcotic with similar effects to butorphanol but with lower level analgesia and longer duration. GI motility disturbances are more noticeable (constipation and colic). Systemic morphine caused hyperphagia but also caused gastric distension and decreased intestinal activity. This could lead to significant issues, particularly gastric rupture or impaction.

Tessier C. [Systemic morphine administration causes gastric distention and hyperphagia in healthy horses](#). Equine Veterinary Journal 51 (2019) 653–657

Fentanyl (patch)

Schedule II

Fentanyl patches are useful for pain relief in patients when NSAIDs are contradicted or not sufficient. Patches should be applied to an area with minimal hair covering and secured in place (upper forelimb).

Patches can take 4 hours provide analgesia and last 36-48 hours.

Humans can absorb the fentanyl from the patch so careful monitoring, handling and removal is indicated.

<https://www.ivis.org/proceedings/aep/2002/910102000291.PDF>

<https://www.sciencedirect.com/topics/pharmacology-toxicology-and-pharmaceutical-science/duragesic>

Gabapentin

Gabapentin is an anti-epileptic drug that has been used to treat neuropathic pain and prevent windup. It's mechanism of action is unclear but is thought to involve inhibition of neurotransmitter release.

It has been shown to be absorbed in horses when given iv but has poor oral bioavailability (16%). Studies on its efficacy are limited but it is being used to treat laminitic pain.

<https://onlinelibrary-wiley-com.ezp1.lib.umn.edu/doi/full/10.1111/j.1365-2885.2010.01161.x>

Future drugs

NMDA antagonists – Ketamine and magnesium block the development of hyperalgesia and are being investigated in multiple species for pain control.

Other drugs with potential include grapiprant, epoxide hydrolase inhibitor, and antibodies against nerve growth factor.

Non-pharmacological pain control

Acupuncture, extracorporeal shock wave therapy, chiropractic and massage may help with pain.

Local anesthesia (epidurals, local blocks, neurectomy, etc) also have a role in selected cases.

RESOURCES

[Vet Clinics North America – Equine Vol 33\(1\), 2017](#)– entire volume dedicated to NSAIDs

[Therapeutic developments in equine pain management](#), The Veterinary Journal, 2019 and [case examples](#)

[The use of phenylbutazone in the horse](#), J Vet Pharm Therap, 2012- less common complications and use in performance horses

[Controlling equine pain](#), The horse, 2016- alternative modalities

[The efficacy of preemptive analgesia for acute postoperative pain management: a meta-analysis](#). Anesth Analg 2005

[Study break](#)– it isn't all about horses

Exercises

Challenge yourself!

Exercise

Zoey, a 15 year old TB mare presents with mild signs of colic 3 days after foaling. She has been off feed and won't eat her grain and is only picking at her hay. The colt is alive and is nursing frequently but isn't putting on much weight. The mare has chronic knee (carpal) issues from being on the track and has seemed reluctant to get up so the owners have been giving her phenylbutazone. She was on 2 grams of bute once daily in the last month due to the extra weight of the foal and they have increased it to twice daily after foaling. It doesn't seem to make much difference; she still lies down a lot. She has major medical insurance.

On physical examination she is quiet and depressed. You observe small dry fecal balls in the stall. Her mucous membranes are tacky and pale. Her udder is fairly empty but not inflamed or sore on palpation.

HR : 64bpm

RR: 30 bpm

T 100.2.

GI sounds quiet. No reflux on nasogastric intubation. Vaginal exam shows bruising but you do not identify any tears. On rectal examination it seems that the intestines are higher in the abdominal cavity than normal and there is some ingesta in the pelvic flexure but not a huge amount. Her uterus seems to be involuting normally. Abdominal ultrasound shows large quantities of free fluid. Abdominal tap results in large quantities of light yellow fluid with low protein and low cellularity. Creatinine of the fluid is off the high end of your test capability (~8 mg/dL is the limit of the test).

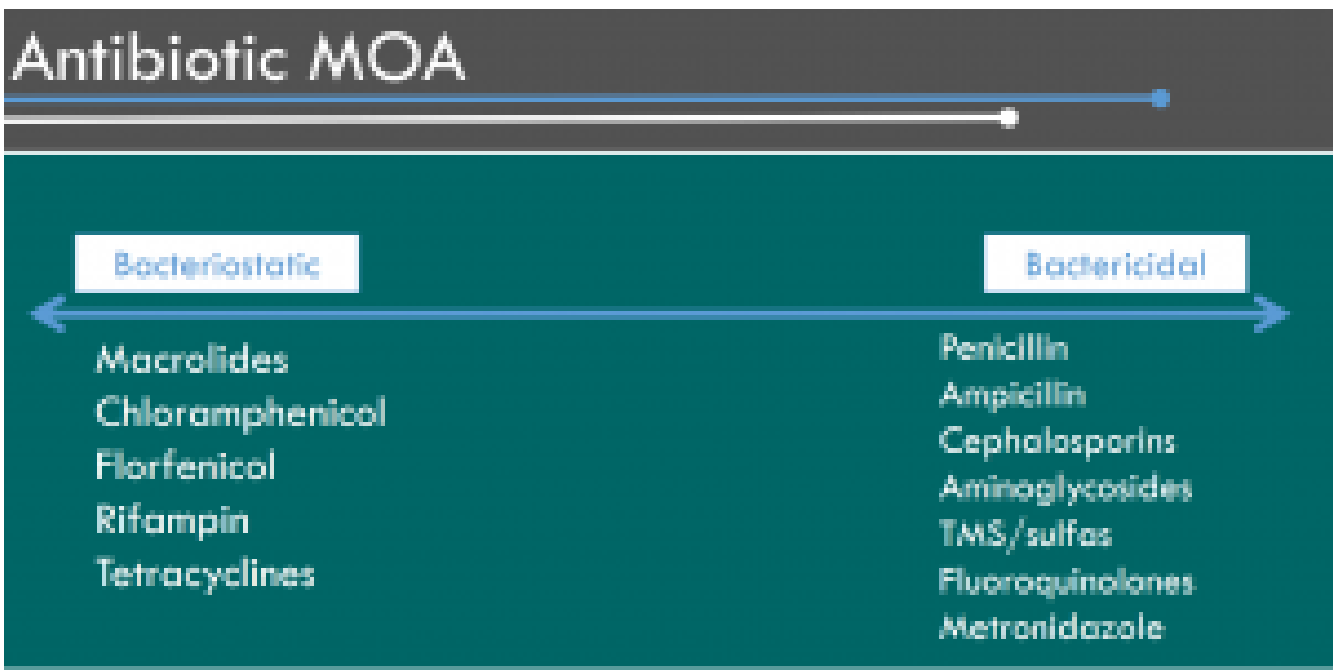
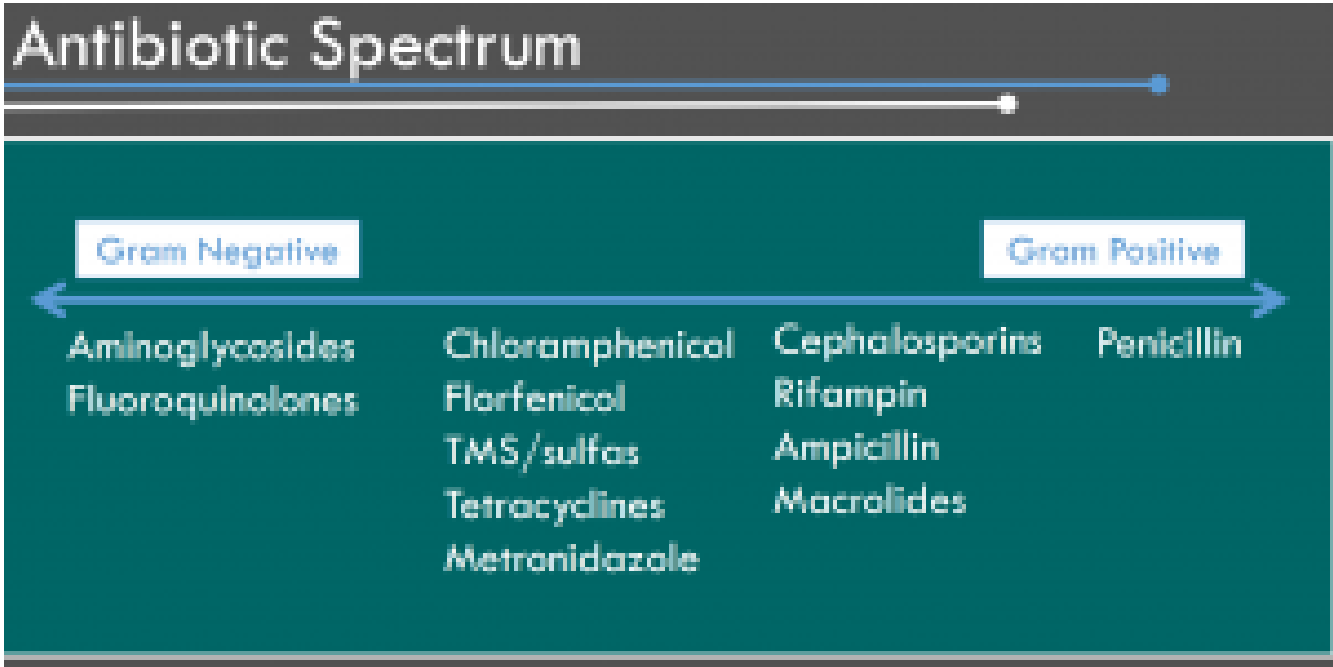


An interactive or media element has been excluded from this version of the text. You can view it online here:

<https://open.lib.umn.edu/largeanimalsurgery/?p=2260>

Equine Antibiotics

Antimicrobial overview (Dr. Alex Bianco)



Drug	IV*	IM/ SQ*	PO*	Anaerobes	Good penetration
Penicillin	x	x		x	
Ampicillin	x	x			
Cephalosporins	EQ/ SRC	x			
Aminoglycosides	x	x			
Fluoroquinolones	EQ	FA	EQ		
Macrolides		FA	FA/ foals		
TMS/sulfas			x		
Chloramphenical/ Florfenicol		FA	EQ	x	x
Rifampin			EQ		x
Tetracyclines	x	FA			
Metronidazole	foals (\$)		EQ	xx	

*US formulations

For these surgery topics, the most common systemic antibiotics are

Trimethoprim sulfonamide or sulfadiazine

Given orally, TMS has a relatively broad spectrum of action and penetrates into tissues. Side effects are rare. Doses range from 15-30 mg/kg po every 12-24 hours. Resistance patterns can help determine which formulation is best for a given population.

Enrofloxacin

“Baytril” can be administered iv or orally. It works through concentration dependent killing, meaning it works best when used at high levels less often. Enrofloxacin works best against gram negative organisms and some gram positive organisms (Staphylococcus). It is not very effective against anaerobes. Enrofloxacin can cause joint disease in young animals as well as diarrhea and neurological disease in all groups. Generally, enrofloxacin should be reserved for cases with known resistance to other drugs or for cases in which other drugs have been shown ineffective.

Procaine penicillin G

PPG is given intramuscularly and can cause anaphylactic reactions and death if given iv. It is most effective against gram positive agents and anaerobes. The label dose is ineffective. Doses start at 22,000 IU/kg.

Gentamicin

Gentamicin is generally given iv. It is effective against gram negative agents. It is not effective in acidic (pus filled) or anaerobic environments and does not penetrate into tissues. It must be carried by the vascular system. Side effects are primarily renal damage. Older references may suggest 2.2 mg/kg TID but it is safer to administer at 6.6 mg/kg SID.

Amikacin

Amikacin is primarily used as an agent for iv regional perfusion (local antibiotic therapy) and in foals. It is otherwise too expensive. As with gentamicin, it targets gram negative organisms and side effects are primarily renal damage.

Ceftiofur

“Excede” is the most common formulation used today. It has good broad spectrum coverage. A single intramuscular dose lasts 4 days. The most common side effect is diarrhea, which can be severe.

Other antimicrobials are used for specific diseases or disorders.

For prophylactic coverage (preventative), we try to have peak levels at the time of the incision. This varies by drug and route but generally

- Oral: One hour after drug is administered
- IV: 15-30 minutes after injection/infusion
- Intramuscular (IM): 30 minutes – one hour after injection

If the surgery is clean or clean-contaminated, further antibiotic therapy is generally not needed unless the animal is immunocompromised, infection would be life-threatening or an implant is used.

If antibiotics are needed, a reasonable rule of thumb is to continue them for 3 days past the resolution of clinical signs (eg fever).

RESOURCES

[Guidelines for antimicrobial use in horses](#)

[Rood & Riddle Equine Formulary](#)

[Veterinary Advances: equine drugs](#) (untested)

[Vin.com drug formulary](#) (membership is free for students)

Equine Sedatives and Tranquilizers

The most commonly used sedatives and tranquilizers in horses are:

Xylazine

Xylazine is a common equine sedative. It can be given iv, im or (less commonly) sq and acts on alpha 2 receptors. It also provides analgesia and is synergistic with opioids for both sedation and analgesia.

Doses range from 100-200 mg iv (1-2cc of 100mg/ml) for most horses. Larger horses are more sensitive and young horses generally need more per pound of bodyweight. Allow horses to sedate fully before stimulating or the sedation may not take effect.

Side effects include decreased GI motility, bradycardia, nasal congestion, and decreased thermoregulation. Sedated horses put most weight on their forelimbs, making them light behind. If startled, they are more likely to kick and less likely to give warning. Xylazine alone should not be used to sedate horses for hindlimb procedures including rectal palpation. Don't use in horses on iv TMS.

Occasional horses become xylazine aggressive and turn mean when sedated. Excessive or sudden stimulation can override the sedation.

Reversal : yohimbine

Contraindications: Be cautious in horses with heart disease. Do not use in neonates as it impairs cardiac output. Use benzodiazepenes instead.

<https://equimed.com/drugs-and-medications/reference/xylazine>

Romifidine

Romifidine is an alpha-2 agonist that is similar to xylazine but with longer duration and less associated ataxia. It is popular with equine dentists.

Sedative dose: 0.04-0.12 mg/kg slow iv (10mg/ml)

Side effects and contraindications: Side effects are similar to xylazine with occasional episodes of colic after its use. Rarely a horse will become excited rather than sedated.

<http://equimed.com/drugs-and-medications/reference/romifidine>

Detomidine

Detomidine is yet another alpha-2 agonist with even longer duration effects. Detomidine does a better job of balancing the horse's weight (4 point stance) and is safe to use when working on the hindlimbs.

Detomidine is routinely given iv or im but does come as an oral gel that can be used for fractious horses (it does take 30 min to kick in). Typical doses are 0.5-1 ml (10 mg/ml).

Detomidine has a ceiling effect so increasing doses increase duration rather than increase sedation.

Side effects are the same as for xylazine but more significant due to the longer duration.

<https://equimed.com/drugs-and-medications/reference/detomidine-hydrochloride>

<https://www.zoetisus.com/products/horses/dormosedan.aspx>

Acepromazine

Acepromazine is a tranquilizer or calming agent. It does not have analgesic properties. It can be given orally, im or iv. It does a delayed onset of action; 10-15 minutes may be required even for iv administration.

Dose iv or im: 2-4 ml (10mg/ml) for 1000# horse

Side effects: Ace is safe in most horses. Caution is needed in stallions and those horses in shock or with anemia. Ace lowers blood pressure and hematocrit. Ace can cause penile prolapse and priapism (persistent erection) in stallions and in geldings with urethral irritation. This condition can rapidly lead to fertility issues.

<https://onlinelibrary.wiley.com/doi/full/10.1111/j.1365-2885.1982.tb00495.x>

Diazepam and Midazolam

Schedule IV drugs.

Diazepam and midazolam are primarily used to relieve anxiety and enhance the sedative effects of other drugs.

Diazepam and midazolam are the preferred sedatives for neonates. Neonates cannot adjust stroke volume so have significant cardiovascular depression with the alpha-2 agents. (Cardiac output = SV * HR)

These benzodiazepenes are used interchangeably. Price variations are common so the cheapest drug is generally the one used. Diazepam must go iv, is light sensitive and cannot be stored in plastic (syringes). It generally cannot be mixed with other drugs (ketamine is okay). Midazolam can be given im and does not bind to plastic. It can be mixed with most other drugs and rectal administration may be effective.

Dose: 0.02-0.4 mg/kg

Side effects: both drugs are metabolized by the liver and the cytochrome P450 system. As such, they can be affected and can affect the metabolism of other drugs.

The drugs are also used as anticonvulsants, muscle relaxants and appetite stimulants.

<https://equimed.com/drugs-and-medications/reference/diazepam>

<https://www.sciencedirect.com/topics/neuroscience/midazolam>

RESOURCES

[Podcasts, 2019](#)

[Practical standing chemical restraint of the horse, AAEP 2009](#)

[Anesthesia and analgesia for standing equine surgery, Vet Clin N Amer 2014](#)

Plumb's Veterinary Drug Handbook and app (lots of versions out there in different formats and prices)

Equine Standing Sedation Protocols

Many procedures are performed in horses using standing sedation and local blocks. This avoids the risk of general anesthesia and can make surgery easier due to the position, height and decreased blood loss (lower flow to the head and back).

Typical protocols involve an alpha-2 agent and a narcotic, either given as repeated injections or as an infusion.

Example 1. Xylazine 1.5 ml and butorphanol 0.5 ml (“150 & 5”)

Example 2. Detomidine 0.5 ml and butorphanol 0.5 ml iv (“5 & 5”)

Example 3. Butorphanol 1ml + detomidine drip- bolus of 0.01 mg/kg iv followed by an infusion of 0.01 to 0.04 mg/kg/h

RESOURCES

[Equine sedation, anesthesia, and analgesia](#)– Seahorn, KY VMA

[Anesthesia and analgesia for standing equine surgery](#), Vet Clin N Amer 2014

[How to maximize standing chemical restraint](#), AAEP 2013

[Practical standing chemical restraint of the horse](#), AAEP 2009

[Ch 24 Sedation and Anaesthesia](#), Equine Medicine, Surgery & Reproduction 2nd edition

Equine General Anesthesia Protocols

As with other species, anesthesia involves

1. **sedation** – xylazine, romifidine, detomidine
 1. optional additional sedatives or analgesics –
butorphanol or acepromazine (given with sedatives)
diazepam or midazolam (given at induction)
2. **induction** – ketamine, telazol, guaifenesin
3. **maintenance** – repeated doses of sedatives and induction agents or infusion of drugs and drug combinations

Horse are generally **not** intubated or maintained on inhalant anesthetic agents except in specialty or referral settings.

Monitoring is typically through vital signs (pulse quality and rate, respiratory quality and rate, ocular reflexes and positioning). Pulse oximeters are portable and easy to use. Doppler blood pressure monitoring is useful particularly in foals.

Common induction and maintenance agents:

Ketamine

Schedule III

Ketamine is a dissociative anesthetic agent used to induce recumbency in horses after sedation. It is commonly combined with diazepam to prolong the anesthetic duration and to enhance relaxation.

Ketamine is a relatively safe drug with minimal cardiovascular or respiratory depressant effects. “It is hard to kill with ketamine.” However, horses will pass through an excitatory phase so it should be given iv after strong sedation and given rapidly. If redosed, ensure horses are still sedated (eg with xylazine) prior to recovery. They should not recover on ketamine alone.

Initial dose is typically 1cc/100# (100mg/ml). Eg a 1000# horse gets 10cc ketamine. A redose is typically 1/2 the original dose.

Ketamine is also used as an iv infusion and epidurally for pain relief to awake horses.

[Injectable field anesthesia](#), 2011 ACVS

Telazol

Schedule III

Telazol is a combination of tiletamine (dissociative agent like ketamine) and zolazepam (benzodiazepene like diazepam). It lasts longer than ketamine/diazepam but is more expensive.

The drug needs to be reconstituted prior to use and then has a limited shelf life.

[Ketamine, telazol, xylazine and detomidine. A comparative anesthetic drug combination study in ponies.](#) Acta Vet Scand 1992

Triple drip

Triple drip is a combination of xylazine, ketamine and guaifenesin used to maintain anesthesia.

Xylazine (500 mg), ketamine (1000 mg or 1 g), in a liter of 5% guaifenesin (50mg/ml), given at 1ml/lb/hr.

Guaifenesin (GG) is a muscle relaxant that helps counteract the rigidity associated with ketamine. The combination must be compounded and can be explosive if done incorrectly.

Side effects: Very irritating perivascularly. Use a catheter. Overdoses of GG can lead to increased muscle tone, making the horse appear too light vs too deep.

[Equine anesthesia: triple drip.](#) Int J Pharm Cmpd, 2008

http://www.r-vets.org/Anesthesia_Basics.pdf

Other

Other drugs and drug combinations are possible and used. Newer ones are being developed all the time.

Currently thiobarbiturates are not available in the US. Propofol has been used but is costly.

RESOURCES

[Podcasts](#), 2019

[Equine sedation, anesthesia, and analgesia](#)– Seahorn, KY VMA

[Injectable field anesthesia](#), 2011 ACVS

[R-vets anesthesia basics](#)– for more challenging cases

[Total intravenous anesthesia in horses](#), Vet Clin N Am 2013

[Field anesthesia in the equine](#), Clin Tech Eq Pract 2007

[How to produce 20 minutes of equine anesthesia in the field](#), AAEP, 2013

FOAL RESOURCES

[Foal sedation, anesthesia, analgesia](#), ACVS

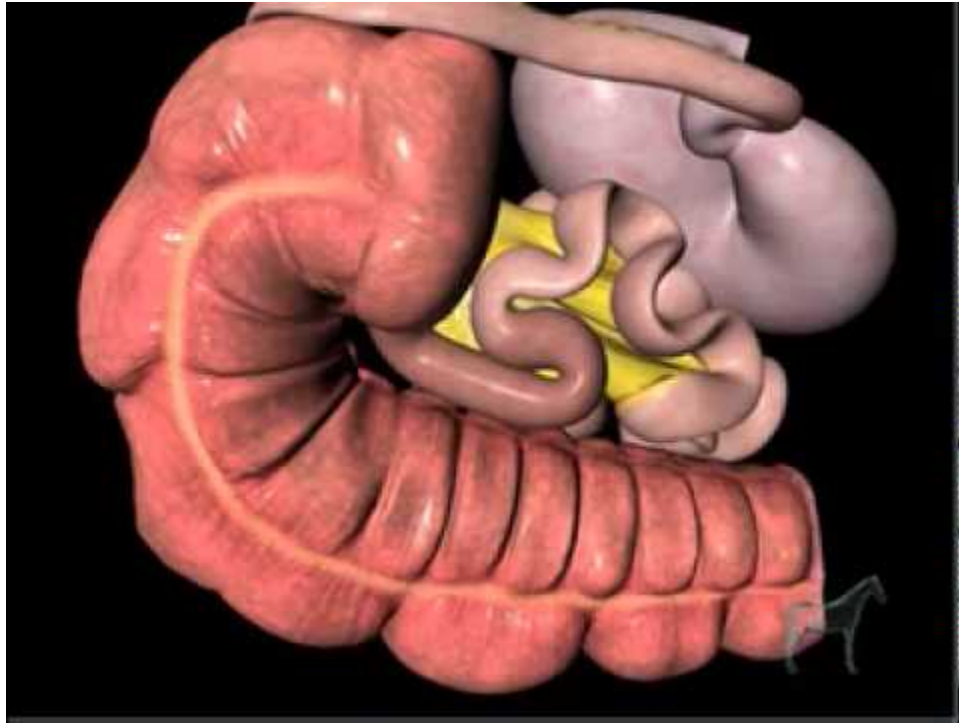
[Eq Surgery anesthesia analgesia foals highlighted](#), Auer & Stick (use the study questions in the ruptured bladder section to work through this)

Plumb's Veterinary Drug Handbook and app (lots of versions out there in different formats and prices)

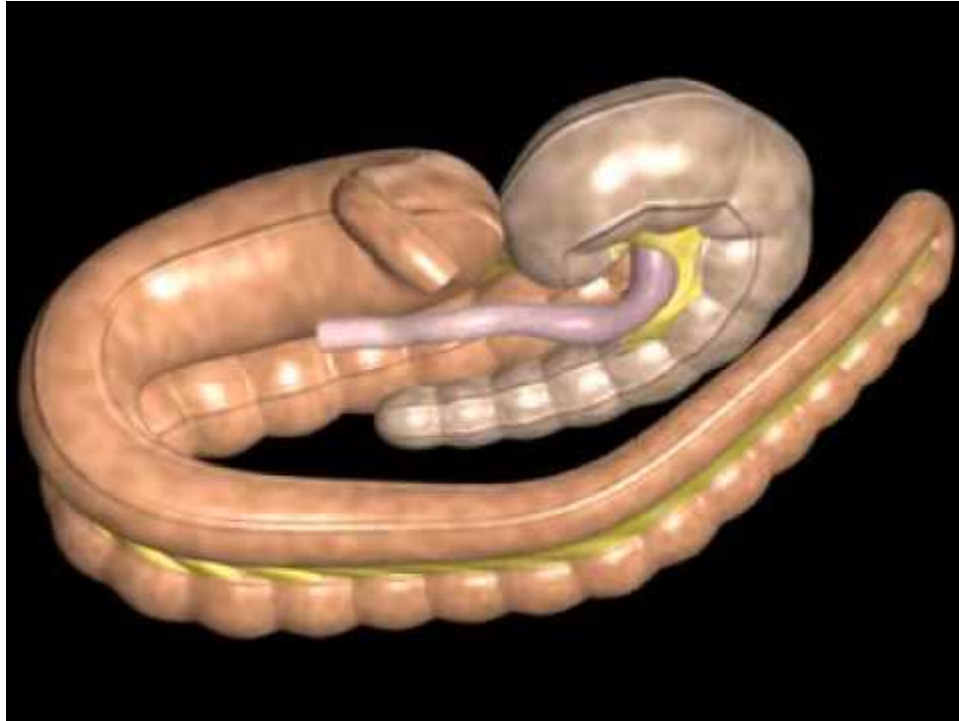
Equine (and LA) Colic

Introduction to equine colic pathophysiology

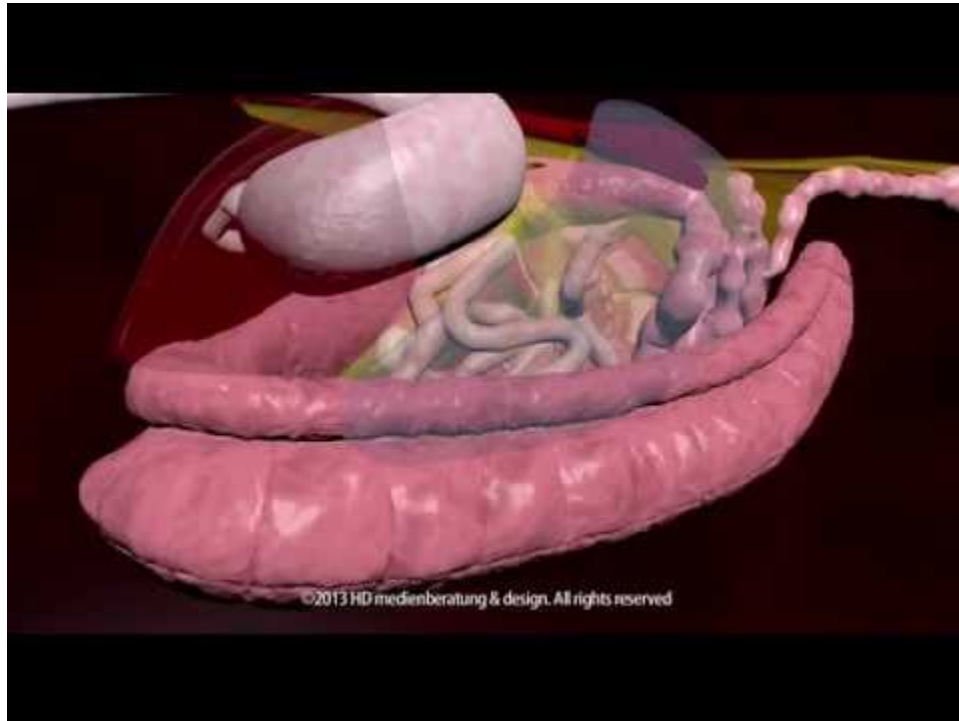Anatomy review in video



A YouTube element has been excluded from this version of the text. You can view it online here: <https://open.lib.umn.edu/largeanimalsurgery/?p=1971>



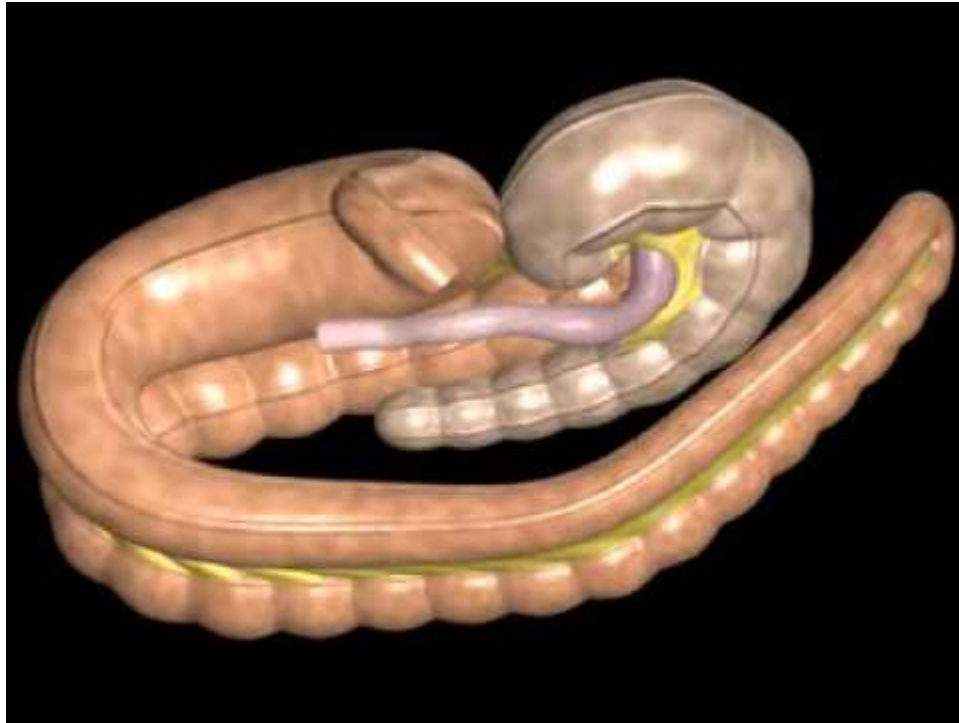
A YouTube element has been excluded from this version of the text. You can view it online here: <https://open.lib.umn.edu/largeanimalsurgery/?p=1971>



A YouTube element has been excluded from this version of the text. You can view it online here: <https://open.lib.umn.edu/largeanimalsurgery/?p=1971>

Physiology review

Pfizer gut video



A YouTube element has been excluded from this version of the text. You can view it online here: <https://open.lib.umn.edu/largeanimalsurgery/?p=1438>

Small intestine

The main function of the small intestine is to move nutrients from the non-cellulose parts of the diet into the bloodstream. This part of the GIT works similarly to that of the dog with the restriction to a vegetarian diet.

Once foodstuffs such as grasses, corn, oats, barley and fats enter the small intestine, they are mixed with enzymes and buffers from profuse pancreatic secretions to start breaking down the food products into glucose, amino acids and lipids. The intestinal wall contracts rhythmically to mix the ingesta with the enzymes. The simpler components are absorbed through capillaries and lymphatics in the intestinal wall where they can be transported to other organs for use or storage. At the same time, the ingesta is moved from the duodenum, through the jejunum and into the ileum. Gradually more and more of the ingesta is exposed to the gut lining and can be absorbed if it hits the right receptors. The downstream (aboral) movement occurs through coordinated movements of the intestine, aka peristalsis. Most of the simple sugars and proteins are absorbed in the jejunum while fats are absorbed in the ileum. The ingesta will often be held and mixed in the ileum until the fat content is minimal.

During the process, the starches (including those from oats and corn as well as from hay) are not broken down but are being hydrated by active fluid secretion. The water exchange that occurs in the SI equals about 1.5x the total extracellular fluid volume of the animal over a 24 hour period. In all species, the SI is the main site of water absorption; in the horse, the large colon also does a decent job. Eventually the remaining components are moved into the cecum where microbial digestion will start.

One major difference from dogs is the type of motility patterns. Dogs eat set meals while horses graze continuously. This means there are different electrical and contractile patterns that result in continual activity with fewer periods of mass movement.

Cecum

The cecum is sometimes called the fermentation vat. Ingesta empties into the cecum via control by the ileocecal valve. Receptors in the ileum permit emptying after the fat content is properly lowered by nutrient absorption. Microbes in the cecum start the process of digesting cellulose. The cecal contents should always be liquefied, despite the fact that a large amount of water is absorbed here. Even though the cecum is a relatively small organ, the transit time averages 5 hours to allow proper mixing of contents with microbes and fluid. Afterwards, intestinal contents are moved into the right ventral colon.

Large colon

The equine large colon has been highly modified to allow cellulose digestion. It is very elongated to allow maximal exposure of the cellulose products to the microbes. Motility is largely mixing with propulsion slowed to keep the ingesta in the colon for long periods of time (transit time is 30-50h). This maximizes the nutrition that the horse can obtain from the hay diet. The microbes use the hay (and any leftover carbohydrates) for energy and produce volatile fatty acids that are absorbed by the colon wall and used by the horse. These fatty acids supply the major portion of the horse's daily energy requirements (and is why they do well on a strictly hay diet).

The colon also buffers ingesta coming from cecum and absorbs fluid from the ingesta. A pony resorbs approximately 30 liters of fluid/day from the colon. As with the small intestine, the colon (with its microbes) is designed to handle frequent eating and continuous flow of ingesta. If horses are fed only twice daily, they will have much more extensive fluid shifts into the ingesta and out of the colon, particularly if they are fed highly fermentable carbohydrates. Increasing carbohydrates entering the cecum and colon also means happy microbes – and more gas production.

Small colon

The small colon continues to remove water from the ingesta, forming fecal balls. The fecal balls can get drier and smaller with dehydration and impactions (more water is removed). It also continues some microbial digestion and buffering. Some retention also occurs (waiting on the defecation reflex).

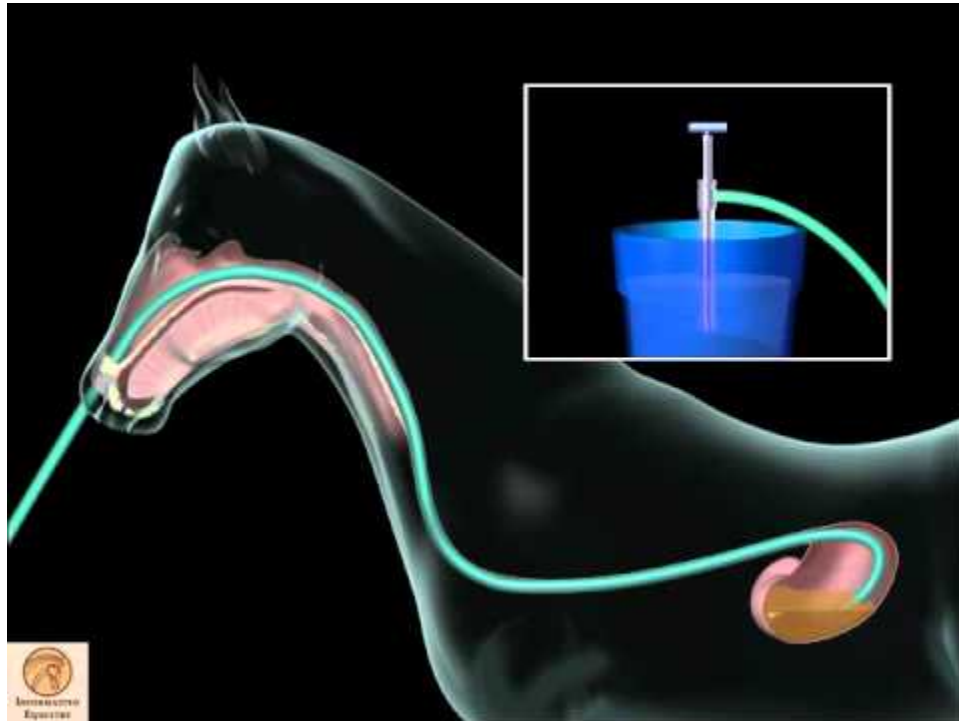
Diagnostics

Horses with colic will look at their side, kick at their belly, act agitated, lie down and/or roll. Mild cases may just not eat well.



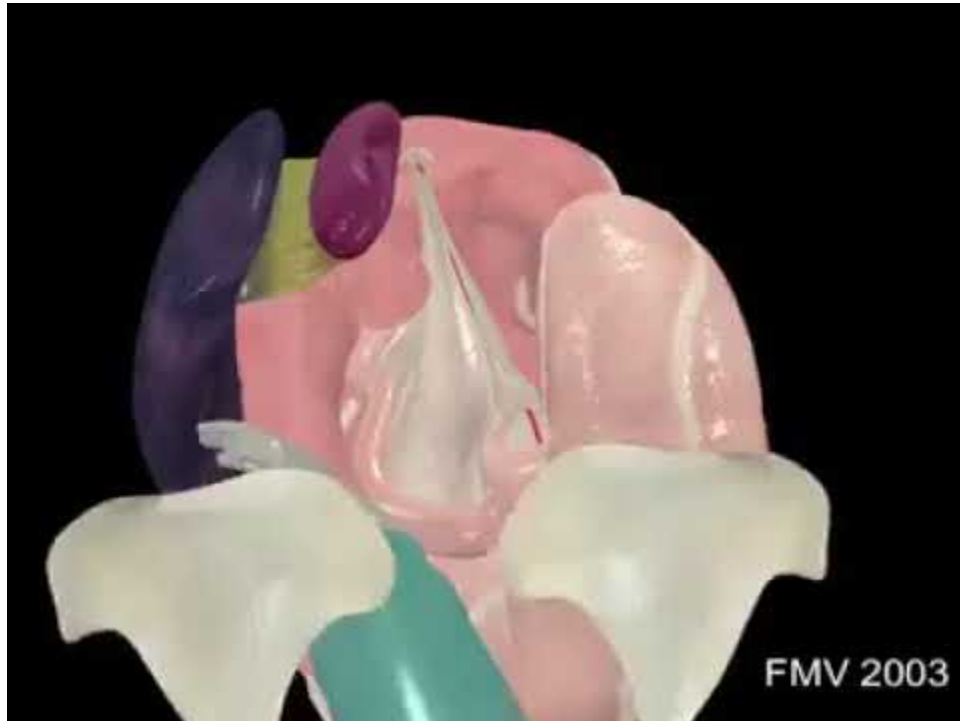
A YouTube element has been excluded from this version of the text. You can view it online here: <https://open.lib.umn.edu/largeanimalsurgery/?p=1974>

Intubation is warranted in almost all colics. Passing a stomach tube can relieve fluid build up in the stomach. Since horses cannot vomit, this can be lifesaving. Without intubation, the stomach may rupture.



A YouTube element has been excluded from this version of the text. You can view it online here: <https://open.lib.umn.edu/largeanimalsurgery/?p=1974>

Rectal palpation may be needed in cases of recurrent colic. It is risky to the palpator (kick injury) and to the horse (rectal tears)



A YouTube element has been excluded from this version of the text. You can view it online here: <https://open.lib.umn.edu/largeanimalsurgery/?p=1974>

Abdominocentesis can be used to help prognosticate. Dead bowel will often leak rbc's, leading to serosanguineous fluid. Horses can have dead bowel and normal appearing fluid too.



A YouTube element has been excluded from this version of the text. You can view it online here: <https://open.lib.umn.edu/largeanimalsurgery/?p=1974>

Small intestinal lesions

Predispositions to disease

The long jejunal mesentery allows movement; this means the jejunum can twist upon self or herniate through other spaces (inguinal rings, mesenteric rents, etc)

Horses can live without approximately 50% of SI; if >50% removed, they often have inadequate digestion of nutrients. Horses with >50% of the SI damaged are usually euthanized at surgery

Small intestinal disorders are characterized by a combination of:

1. Colic (pain) or depression (illness)

Pain is observed if there is intestinal distension, mesenteric traction, and/or inflammation.

Depression is seen if the horse has peritonitis, enteritis, and/or dead intestine.

2. Reflux (fluid build up in stomach)

If a small intestinal obstruction is present, the horse will reflux eventually. How fast this happens depends on how far downstream the obstruction is and how dehydrated the horse is.

It is possible to have functional obstructions – no physical obstruction exists but ingesta doesn't move downstream due to motility disorders. These will also reflux.

Rare large intestine disorders can lead to reflux.

3. Hypovolemic and/ or endotoxic shock

Signs include tachycardia, weak pulses and prolonged CRT. Severe tachycardia is usually due to shock and the need to move the blood back to the heart as fast as possible vs due to pain.

Horses are very sensitive to low levels of endotoxin! When toxic, they can also develop toxic (darker) lines around the teeth or purplish mucous membranes.

4. Significant electrolyte abnormalities

These are due to secretory and absorption function of the small intestine.

Secretions are usually increased if an obstruction is present– the body tries to hydrate it and break it down. These secretions carry high levels of electrolytes. If the secretions can't move downstream, they can't be reabsorbed.

Re-absorption can be hampered if the intestinal wall is swollen or contains inflammatory cells. These changes increase the distance to the capillaries and lymphatics, interfering with absorption of nutrients.

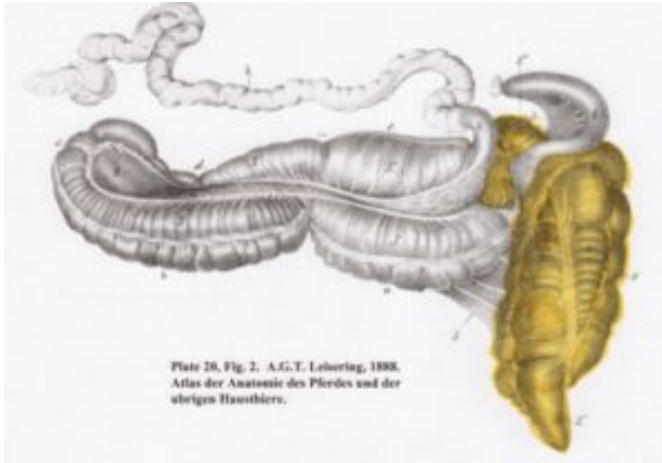
5. Minimal abdominal distension or bloat (unless foals)

The small intestine is covered by the rib cage so small intestinal distension is usually not noticeable externally

6. **Abnormal small intestine on ultrasound** (thickened wall, distension)

Small intestine is generally not visible ultrasonographically in healthy, fed horses. You can see small intestine in horses that are off feed but it should be flaccid in the inguinal area. Distended small intestine on ultrasound is never normal.

Cecal lesions



Predispositions to disease

The cecum is a blind ended sack with a single entry and exit portal. As it is a branch off of the rest of the intestines, motility disorders can lead to impactions.

Tapeworms live at the ileocecal junction and can cause motility issues and intussusceptions.

Cecal disorders are characterized by :

1. Low grade pain

Distension can take awhile

2. Difficult diagnoses

Gas distension is palpable rectally and will resemble other forms of gas colic. It will usually respond well to pain relief, antispasmodic agents, mineral oil and exercise.

Impactions will cause the cecum to sink and to be less palpable. Impactions are generally not identifiable until advanced.

Cecal impactions develop most commonly in horses that are hospitalized and on NSAID therapy. Horses with eye lesions are predisposed. The presence of NSAIDs means early signs of colic may be missed.

3. Minimal response to laxatives

Most substances bypass the cecal contents and move from the ileum, straight thru the cecum into the colon. Surgery is often necessary to empty the cecum.

Complications/Prognosis

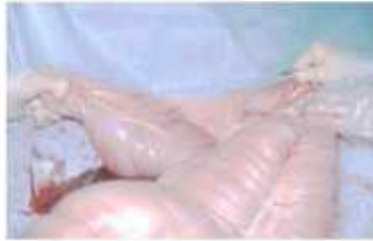- Cecal rupture
- Prognosis
 - Fair if early detection
 - Can recur if primary impaction

A YouTube element has been excluded from this version of the text. You can view it online here: <https://open.lib.umn.edu/largeanimalsurgery/?p=1436>

Cecal tympany is difficult to differentiate from large colon tympany (check for a ping on the right) but should also respond to the same therapy.

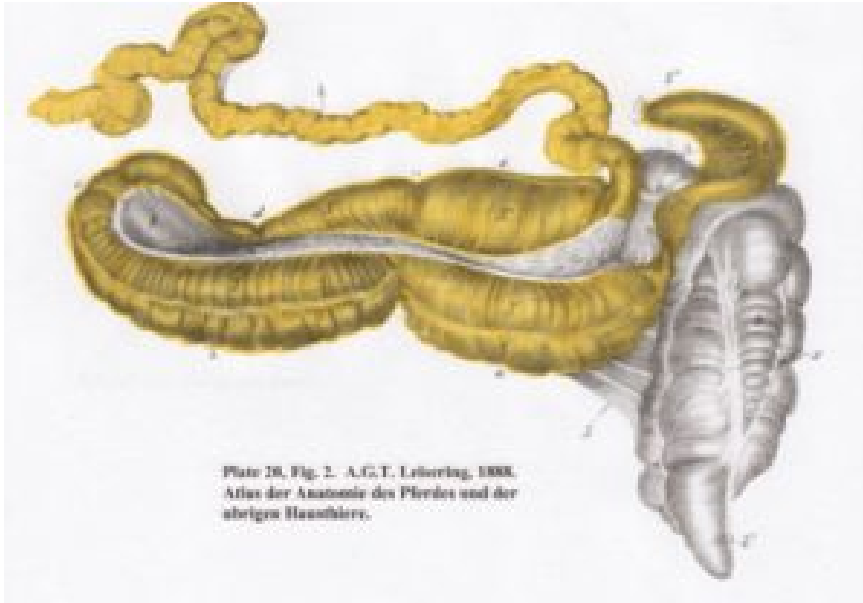
Diagnosis

- Rectal examination
 - Tight cecal bands
 - Gas distended cecum



A YouTube element has been excluded from this version of the text. You can view it online here: <https://open.lib.umn.edu/largeanimalsurgery/?p=1436>

Large colon lesions



Predispositions to disease

Minimal fixation allows movement – colonic torsions and displacements are common

Gas production during microbial digestion may cause colic (gas distension; displacement)

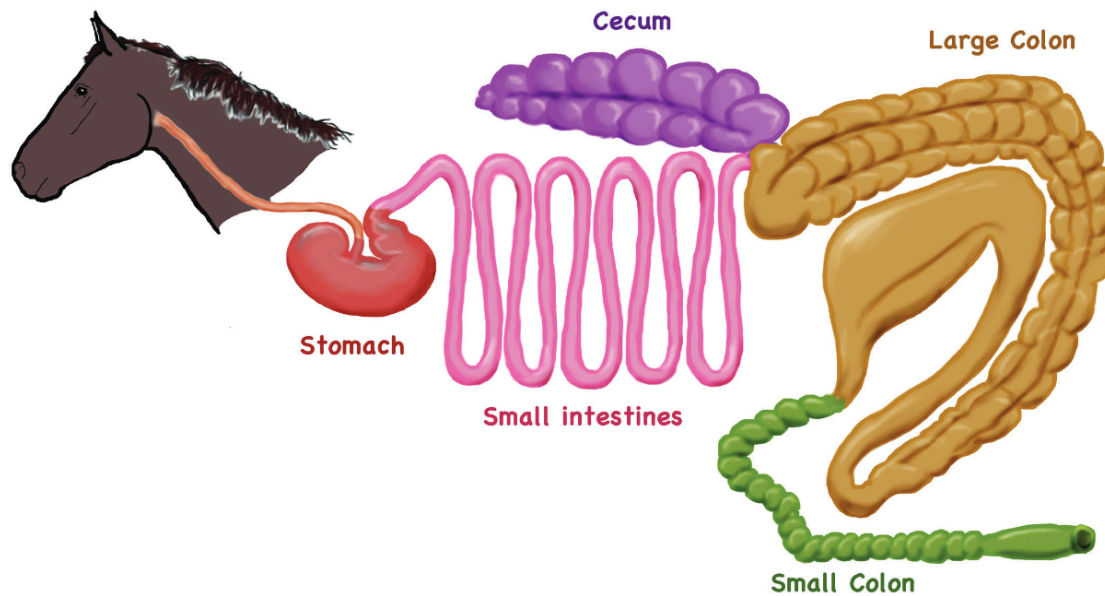
Hairpin turns and changes in diameter create sites prone to impaction

Large intestinal disorders are characterized by:

1. **Gas distension** : microbes keep producing it even if physical obstruction
2. **Mild-severe colic** : depends upon amount of gas distension
3. **Bloat** : can see rib cage and flank distension
4. **Decreased fecal production**

Two types of large colon disorders can reflux: nephrosplenic entrapments and small colon impactions. We believe the colon lesions are pinching the duodenum shut, creating a secondary SI obstruction.

Small colon lesions



Predispositions to disease

-smaller diameter than colon = site of obstruction of stones and fecoliths

-mesentery (and vascular supply) can tear off with extensive rectal prolapse ; this means the bowel dies

Small colon disorders characterized by :

1. **mild signs of pain** – usually simple obstruction; younger horses can seem pretty painful
2. **slow deterioration** in condition

Even with vascular compromise, initial transient signs of severe abdominal pain -> depression and less severe pain

3. associated with greater risk of Salmonellosis

Arabs, minis, and ponies are predisposed to small colon lesions (better able to maintain hydration by removing water from ingesta?)

Poor area for healing

- high mural collagenase
- poor blood supply
- high bacterial counts
- firm formed manure passes by

Field colics

The majority (80%) of colics are gas or impaction colics and can be readily managed in the field.

Impaction colics

Impactions may develop for 3 main reasons:

1. Foodstuffs are not easily digestible.

Examples

Poor mastication – speedy eating, painful chewing
Poor dentition – sharp points, wave mouth, worn teeth
Highly fibrous foods – poor quality hay

2. The gut isn't able to digest things well due to a change in motility or change in flora activity

Examples

Change in motility

- Atropine
- Stress
- Change in exercise
- Drugs or anesthesia

Change in microbial flora activity

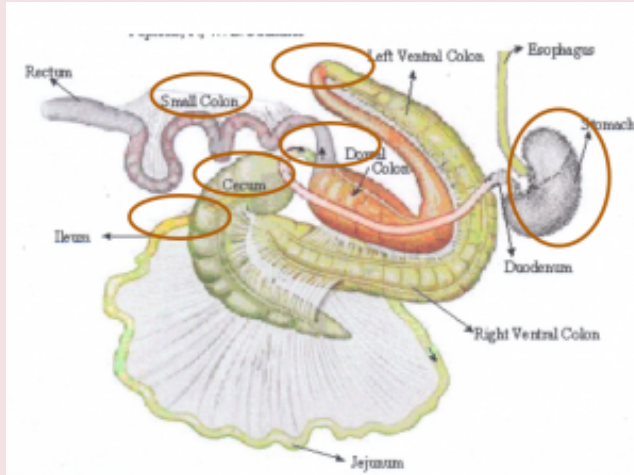
- Illness
- Feed changes
- Temperature changes

3. The ingesta doesn't slide well

Examples

Anatomical and physiological challenges

- Friesians have abnormal gastric motility
- Ileal break slows emptying
- Pelvic flexure creates a hairpin turn with narrowing
- Cecum is blind-ended
- Small colon is narrowed
- Absorption of water from the small colon



Ingesta is dry, hard or sticky

- Reduced water intake
- Dietary changes
- Enterolith formation
- Foreign body

Gas colics

Gas or tympanic colics develop when

1. Diet changes result increased gas production by the microbial flora

Examples

Diets high in fermentative feedstuffs
Sudden feed changes

2. Motility changes prevent farting and/or permit more fermentation due to delayed transit times

Examples

Atropine

Electrolyte abnormalities (endurance racing, hot weather)

Diagnostics

Both gas and impaction colics lead to mild to moderate colic signs and decreased manure production. Heart rate is generally only mildly elevated. Horses can become mildly dehydrated. Horses may look bloated with gas colics. Reflux is not generally seen.

Differentiating between gas and impaction colics requires rectal palpation and even that may be inconclusive. However, both can be managed similarly so the challenge is only in differentiating field vs referral colics.

Treatment

1. Rehydrate/overhydrate : Give fluids orally via nasogastric tube and/or iv. Oral is more effective! Generally give ½ to 1 gal total to 1000# horse

Gastric distension stimulates colonic activity through the gastrocolic reflex

If you have difficulty passing the nasogastric tube into stomach due to esophageal sphincter tone, add 25-30 ml lidocaine

2. Pain relief via flunixin meglumine or other NSAID; pain stimulates the flight response and shuts down motility

3. Buscopan (once) to help with intestinal spasms

4. Walk horses to stimulate Gi motility

5. Prevent worsening by remove hay and grain (grazing, grass okay) until the horse poops

6. Laxatives if needed (DSS, mineral oil, Epsom salts)

If sand : psyllium 0.5 kg po BID combined with 2 l oil

Psyllium and/or mineral oil can be given in place of oral water via nasogastric tube

Or could give ½ gallon water and ½ gallon oil

7. Monitor response to treatment (via rectal, signs of pain)

Most will resolve with just one visit. Refer if severe, not manageable, or not responding within 12-24h

RESOURCES


[Clinical features, diagnoses, and treatment of 120 cases of large colon impaction](#), 2014 BMC Vet Res

[Facts and myths about medical treatment of colic](#), 2017 FAEP

[Medical management of large colon impactions in horses](#), 2015 EVE

Diagnosis

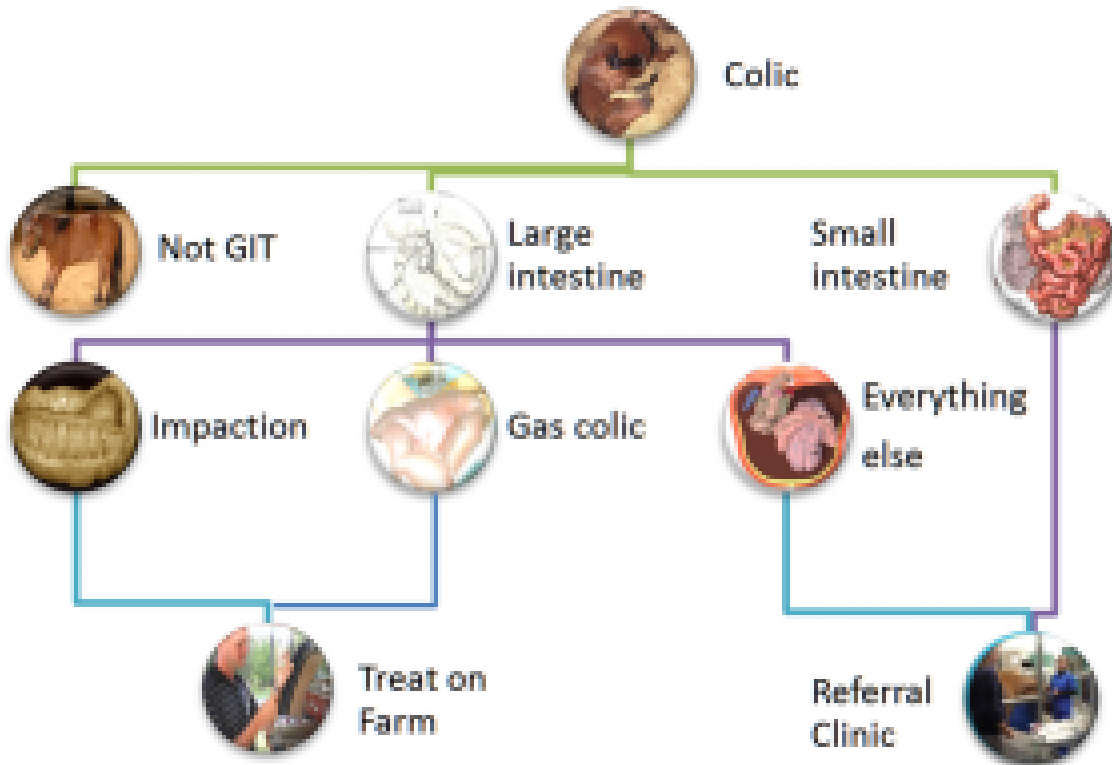
- Auscult the beach
- Sand test
- Radiographs
- Not ultrasound



The composite image consists of three parts: a hand holding a hoof, a radiograph of a hoof, and an ultrasound image of a hoof. The hand is positioned at the top right, showing the hoof being held. The radiograph is in the middle, showing the internal structure of the hoof. The ultrasound image is at the bottom left, showing a cross-section of the hoof with labels for 'CORONARY BLOOD VESSELS', 'CORONARY BLOOD VESSELS', 'CORONARY BLOOD VESSELS', and 'CORONARY BLOOD VESSELS'.

A YouTube element has been excluded from this version of the text. You can view it online here: <https://open.lib.umn.edu/largeanimalsurgery/?p=1487>

Referral colics



Small intestinal disorders should be referred.

Small intestinal disorders may need referral for surgery, reflux management, intensive therapy and/or just for maintenance of hydration.

Hints that the horse has a small intestinal lesion:

- Reflux
 - Due to small intestinal secretory activity, any type of small intestinal obstruction will eventually lead to reflux. As horses cannot vomit, the fluid buildup will lead to a gastric rupture if not removed via nasogastric intubation. Large quantities of reflux will also cause electrolyte and acid base changes. Oral fluids will not go anywhere, so IV fluids are required to manage hydration.
 - Small intestinal lesions can be differentiated from large intestinal lesions most readily if reflux is present. Very few large intestinal lesions will lead to reflux (nephrosplenic entrapments and small colon impactions can reflux). Small intestinal lesions do not generally cause bloat. If bloat is present, it is likely a large intestinal problem.

- Low protein
 - Small intestinal infiltration will lead to weight loss and low protein levels if it persists. Infiltrates increase the distance to the capillaries, making nutrient absorption less likely. Small intestinal inflammation can lead to loss of absorptive cells, also impairing nutrient absorption. When low protein leads to edema, it is definitely time for more intensive management. Steroids may be needed to control the inflammation and plasma may be needed to restore oncotic pressure.
- Metabolic derangements
 - Stomach and biliary secretions are lost in the reflux, leading to more severe changes in electrolyte and acid-base levels in horses with small intestinal lesions.

Large colon cases that are not impactions or gas colics should be referred.

Many of these cases will need ongoing monitoring, more intensive treatment and/or surgery. Some displacements and sand colics can be managed in the field; most will benefit from hospitalization. Cases that need surgery should be referred as early as possible. This may even mean referring in a case that is not yet surgical but isn't following the normal course of impactions and gas colics. Refer to the physiology/pathology section to notice how fast lesions become non-reversible.

Indications for surgery include

- poorly manageable pain
- serosanguinous or abnormal abdominocentesis
- lack of response to therapy
- a need for further evaluation

Cases that need more intensive therapy:

- Reflux, diarrhea, or low protein levels necessitate iv fluids or colloids
- Horses with fevers may indicate contagious disease, particularly Salmonellosis and/or Clostridial infections

Not all clients will let you refer. Develop a mutual plan on when it will be time to stop.

RESOURCES

[Review of Packed Cell Volume and Total Protein for Use in Equine Practice](#), 2001 AAEP

[Evaluation of the colic in horses: decision for referral](#), 2014 VCNA

[How to manage severe colic in the field](#), 2001 AAEP

[How to manage the challenging colic when referral is not an option](#), 2016 FAEP

Preventing colic

Minimize the risk of colic

Ensure fresh water always available

Feed easily digestible feedstuffs

Pasture > hay > no hay

Good dental care

Make changes gradually

Monitor closely within 2 weeks of any change in management, feeding or illness

Owners take care of horses vs barn managers or trainers

Provide postoperative pain relief

Use atropine only as needed (eg in eye cases)

Bran mashes are often used when horses may be at risk of developing an impaction and/or recovering from one. Bran is mixed with hot water to create a fiber rich laxative. Mineral oil may be added to the mix. However, these are high in phosphorus and low in calcium so are not recommended as a continual diet!

RESOURCES

[Nutritional management of recurrent colic and colonic impactions](#), 2016 EVE

[Differences in gastrointestinal lesions in different horse types](#), 2017 BMJ Vet Rec

Colic Pathophysiology

Colics can be divided into 4 main types

I. Strangulating obstructions

A twist or entrapment leads to obstruction along with a compromise to the vascular supply. The intestine is damaged or dead due to the strangulation of blood supply; obstruction occurs but is a secondary problem. Many conditions are often non-strangulating initially but rapidly lead to strangulating conditions due to swelling and fluid buildup (e.g. a loose entrapment becomes tight)

Examples : large colon volvulus, strangulating lipoma

Associated complications:

1. **Hypovolemic shock** –Fluid (SI & LI) and/or gas distension(LI) occurs proximally. Large volumes of sequestered fluid results in shock.
2. **Severe pain** due to traction on mesentery and distension of gut –pain increases rapidly until unrelenting and severe. Pain changes to depression if intestines become devitalized (pain often subsides).
3. Intestinal damage – venous occlusion leads to increased venous pressure and subsequent intestinal edema and net secretion of fluid. The occlusion also leads to decreased arterial inflow, resulting in intestinal necrosis. Necrosis starts with the mucosa as it is the most metabolically active section. See table below.
4. **RBC leakage** – Red blood cells leak out of altered capillaries, causing intramural hemorrhages and serosanguineous peritoneal fluid. Hemorrhages in mesentery can cause fibrosis, shortening of mesentery, and adhesions.
5. **Hypoproteinemia** – protein leaks out of bowel due to damage. This leads to a PCV /TPP mismatch : High PCV, low TPP. Compare this to blood loss with both low PCV and low TPP or dehydration with both values being high. The mismatch is hard to treat- if you give fluids to lower PCV and you severely lower the TPP. We usually give colloids first and then fluids.
6. **Endotoxemia**– ischemia causes progressive damage, starting with the metabolically active mucosa. Once this mucosal barrier is lost, endotoxin can leak across to the peritoneum and be absorbed into circulation. Horses may have a “toxic line” (darker line) around the teeth or have brick red mucous membranes.
7. Reperfusion injury may occur in the small intestine. The return of oxygen to previously ischemic area leads to formation of free radicals which cause further damage. Presently we have no effective means of preventing or treating reperfusion injury.

8. **Abdominal distension** if large intestinal lesion.
9. **Reflux** if small intestinal lesion.
10. **Death due to endotoxic and hypovolemic shock**

DAMAGE TIMELINE

Small intestine – Villi lost early on. Completely denuded by 3 hours

With time, the crypt cells will migrate to cover lost villi (within 12 hours), then rapid recovery occurs.

If ischemia continues for 4-5 hours, the loss of mucosa includes the crypts

By 6-7 hours of ischemia, degeneration has passed outward beyond muscle layers. This is bad news; recovery is very difficult as no mucosal cells remain. This section of the bowel needs to be removed surgically.

Large intestine -Complete ischemia induces cellular necrosis. Groups of 3-5 surface epithelial cells loosen and slough.

Cellular degeneration actually becomes irreversible before sloughing occurs. Irreversible mucosal damage occurs after 3-4 hours of complete ischemia

Sloughing of 97% of the surface epithelium and 50% of glandular epithelium is associated with death.

Strangulating lesions require surgery. General surgical complications include :

- Postoperative ileus (especially small intestinal lesions)
- Diarrhea
- Laminitis
- Adhesions
- Peritonitis
- Incisional infections
- Incisional hernias

II. Nonstrangulating obstructions

Simple obstructions may be **physical** (something in the way) or **functional** (not moving despite no physical obstruction, eg due to neurotransmitter issues or other problem). Intestinal distension occurs secondary to the obstruction or lack of motility. Gas, fluid and ingesta increase proximally to obstruction. This distension can compress intestinal veins and capillaries. Edema occurs due to increased capillary filtration. Distension pressures of 25cm H₂O for 120 minutes can cause jejunal damage with adhesions possible due to the damage. Motility initially increases proximal to obstruction. As distension increases, spasms develop causing intermittent pain. Prolonged distension leads to continuous pain due to stimulation of stretch receptors.

The specific pathology that results depends upon the site of the obstruction.

Examples : large colon impactions, enterolithiasis

Small intestinal obstruction

1. **Reflux** due to fluid buildup in the stomach. Horses do not vomit. If gastric decompression isn't performed via nasogastric intubation, the stomach will rupture.
2. **Electrolyte abnormalities and dehydration** due to increased secretions
3. **Tachycardia** due to dehydration
4. **Pain** due to intestinal distension and spasms. Pain gradually worsens.

Large intestinal obstruction

1. **Bloat** due to gas buildup.
2. **Dehydration** due to altered water resorption.
3. **Pain** due to intestinal distension and spasms. Pain is generally mild but gradually worsens.
4. **Impaction** due to buildup of ingesta and removal of water from the ingesta.

Cecal obstruction

1. **Bloat** due to gas buildup.
2. **Dehydration** due to altered water resorption.
3. **Pain** due to intestinal distension and spasms. Pain is generally mild but gradually worsens over several days.
4. **Impaction** due to buildup of ingesta and removal of water from the ingesta.

Small colon obstruction

1. **Pain** – more severe than large intestinal obstruction due to more rapid distension
2. **Reflux** is possible. Duodenal compression? Gastrocolic reflex?
3. No bloat.

Non-strangulating lesions carry a better prognosis than strangulating lesion due to less toxemia and fewer complications.

III. Inflammatory conditions

Intestinal inflammation causes hyperplasia and hypertrophy in smooth muscle. This may cause ileus due to alterations in neurotransmitter function. Infectious agents often lead to secretory response and may also damage the absorptive capabilities of the gut.

Inflammation in the small intestine often leads to **hypoproteinemia** due to leakage of protein (loss) and less absorption through the villi due to the greater diffusion distance between the nutrients and capillaries. Horses may have **weight loss and ventral edema**.

Inflammation in colon (colitis) leads to mucosal permeability and signs of endotoxemia, especially tachycardia, shock, changes in mucous membrane color, and fever. Ulcerations can cause **colic** signs.

Inflammation also alters ability of gut to protect self from intestinal contents. Overwhelming gut inflammation can lead to systemic inflammatory response syndrome (inflammation in other organs).

Examples : equine proliferative enteropathy (*Lawsonia*), right dorsal colitis, Salmonellosis

IV. Nonstrangulating infarctions

With nonstrangulating infarctions, the intestine is devitalized but no twist or entrapment is present. These conditions are less painful than those involving intestinal distension and entrapment until secondary distension develops. Toxemia leads to tachycardia and depression. These generally carry a very **poor prognosis!**

Examples : mesocolon tear, intestinal infarctions from *Streptococcus equi* infections

RESOURCES

[Lawsonia intracellularis and Equine Proliferative Enteropathy](#), 2014 VCNA

[Nonsteroidal anti-inflammatory drug associated right dorsal colitis in the horse](#), 2015 EVE

Impactions - stomach and small intestine

Impaction pathophysiology

Common sites of impaction include the pelvic flexure, the ileum, the cecum, the small colon and the stomach. Ascarid impactions are typically in the jejunum.

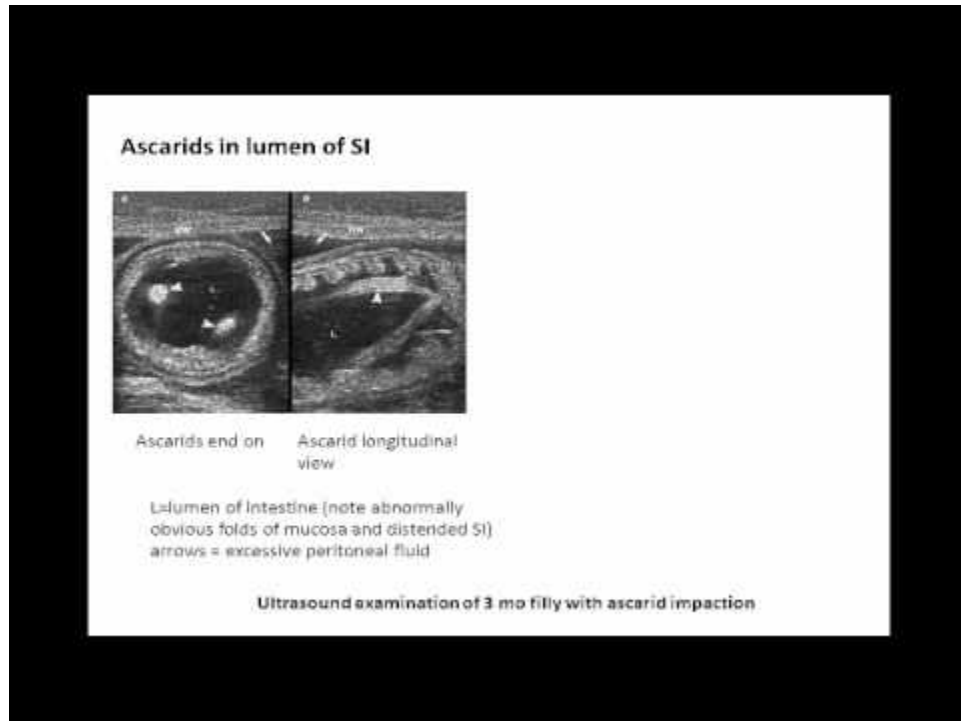
Gastric impactions

[Gastric impactions in horses, a review.](#) The Horse, 2011

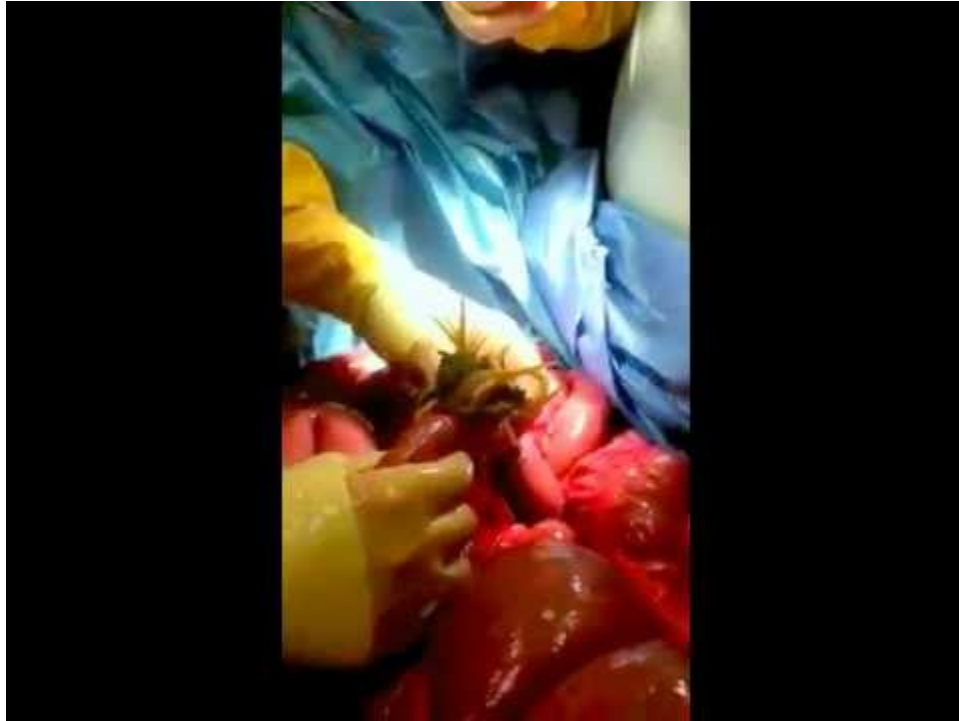She added that the condition is caused by a variety of factors including the consumption of certain feeds that swell after ingestion, dental problems that diminish the horse's ability to chew feed properly, inadequate water supply, excessively rapid eating, and pathophysiological disturbances (changes in the horse's normal mechanical, physical, and biochemical functions).

Ascarid impactions

Ascarid impactions can occur after deworming when the dead and dying worms create an obstruction.



A YouTube element has been excluded from this version of the text. You can view it online here: <https://open.lib.umn.edu/largeanimalsurgery/?p=1604>

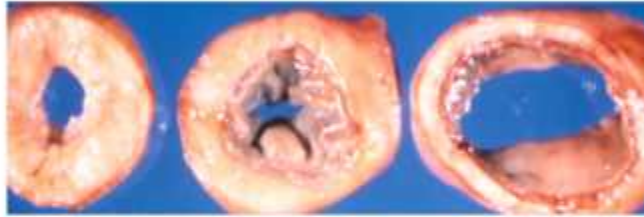


A YouTube element has been excluded from this version of the text. You can view it online here: <https://open.lib.umn.edu/largeanimalsurgery/?p=1604>

Ileal impactions and ileal hypertrophy

Ileal impactions occur most often with Bermuda grass hay and parasite issues.

Ileal hypertrophy

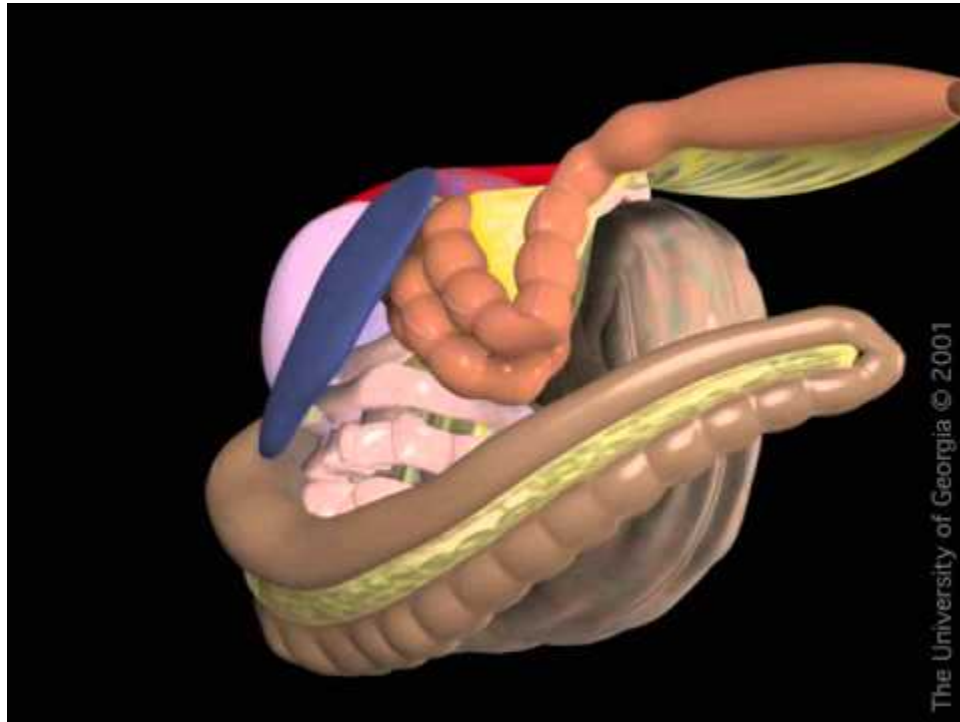


Muscular hypertrophy of the ileal wall
Leads to secondary impactions due to narrowing.

A YouTube element has been excluded from this version of the text. You can view it online here: <https://open.lib.umn.edu/largeanimalsurgery/?p=1604>

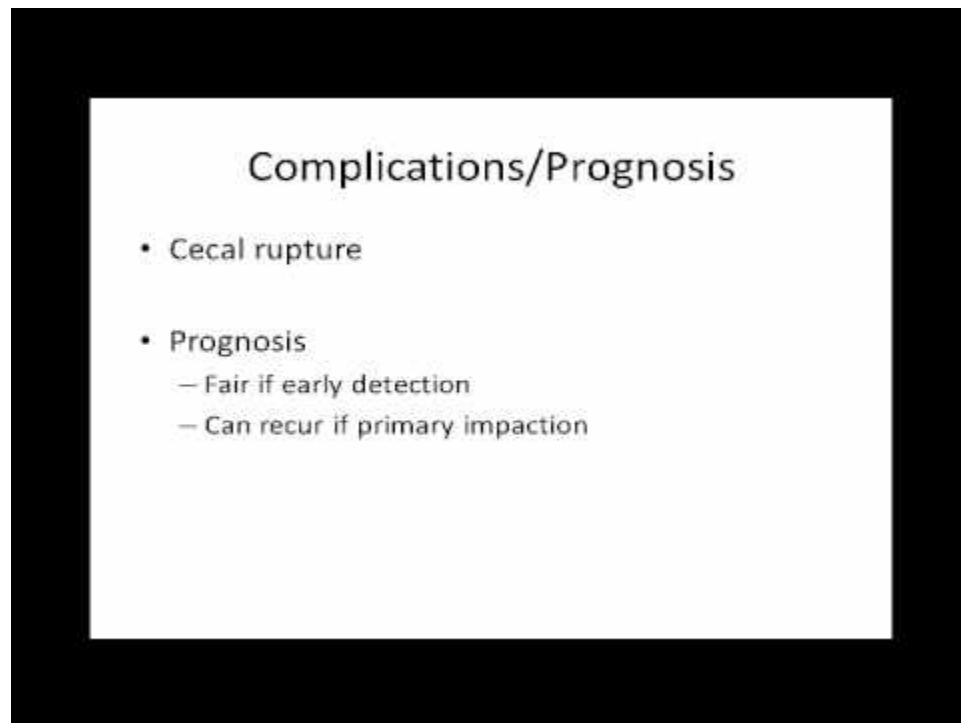
Impactions - Cecal, colon and small colon

Pelvic flexure impactions



A YouTube element has been excluded from this version of the text. You can view it online here: <https://open.lib.umn.edu/largeanimalsurgery/?p=1610>

Cecal impactions

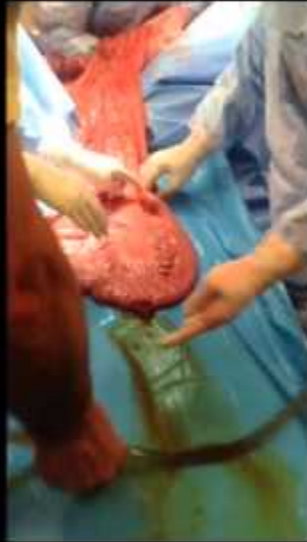

A YouTube element has been excluded from this version of the text. You can view it online here: <https://open.lib.umn.edu/largeanimalsurgery/?p=1610>

Enterolithiasis

Presenting information		
Signalment	Predisposing factors	Clinical signs
<ul style="list-style-type: none">• Esp 5-15 yo• Arabs, Morgans, Sdlibreds, donkeys, minis, mares	<ul style="list-style-type: none">• Alfalfa diet• Ltd pasture• Confinement >50% day• CA, IN, FL• Water with high Mg• Other horse on property with enteroliths	<ul style="list-style-type: none">• Intermittent mild colic• Pain after exercise• -> Acute severe pain

A YouTube element has been excluded from this version of the text. You can view it online here: <https://open.lib.umn.edu/largeanimalsurgery/?p=1610>




A YouTube element has been excluded from this version of the text. You can view it online here: <https://open.lib.umn.edu/largeanimalsurgery/?p=1610>

Sand impactions

Diagnosis

- Auscult the beach
- Sand test
- Radiographs
- Not ultrasound



The composite image illustrates three diagnostic methods for sand impaction. The top right shows a hand holding a tube, likely for a sand test. The middle left shows a radiograph of a horse's abdomen, with labels for 'LFT', 'LUNG', and 'CECUM'. The middle right shows an ultrasound image of a horse's abdomen.

A YouTube element has been excluded from this version of the text. You can view it online here: <https://open.lib.umn.edu/largeanimalsurgery/?p=1610>

Small colon impactions

Presenting information

Signalment	Predisposing factors	Clinical signs
<ul style="list-style-type: none">• Ponies• Mares• Older > 15 yo• Broodmares (last trimester)	<ul style="list-style-type: none">• Poor quality roughage• Low roughage diet• Decreased water intake• Poor dentition• Inadequate mastication• Lack of exercise• Parasites	<ul style="list-style-type: none">• Dull, anorexic• Mild colic• Decreased manure• Diarrhea• Abdominal distension• Fever• (Reflux)

What other type of colic would have similar predisposing tendencies?

A YouTube element has been excluded from this version of the text. You can view it online here: <https://open.lib.umn.edu/largeanimalsurgery/?p=1610>

Meconium impactions

Complications/Prognosis

- Colic
- Patent urachus
- Failure to nurse adequately (FPT)
- Colonic or rectal edema and inflammation
- Mini foals get very sticky impactions
 - Often need surgery

- Prognosis for most = good

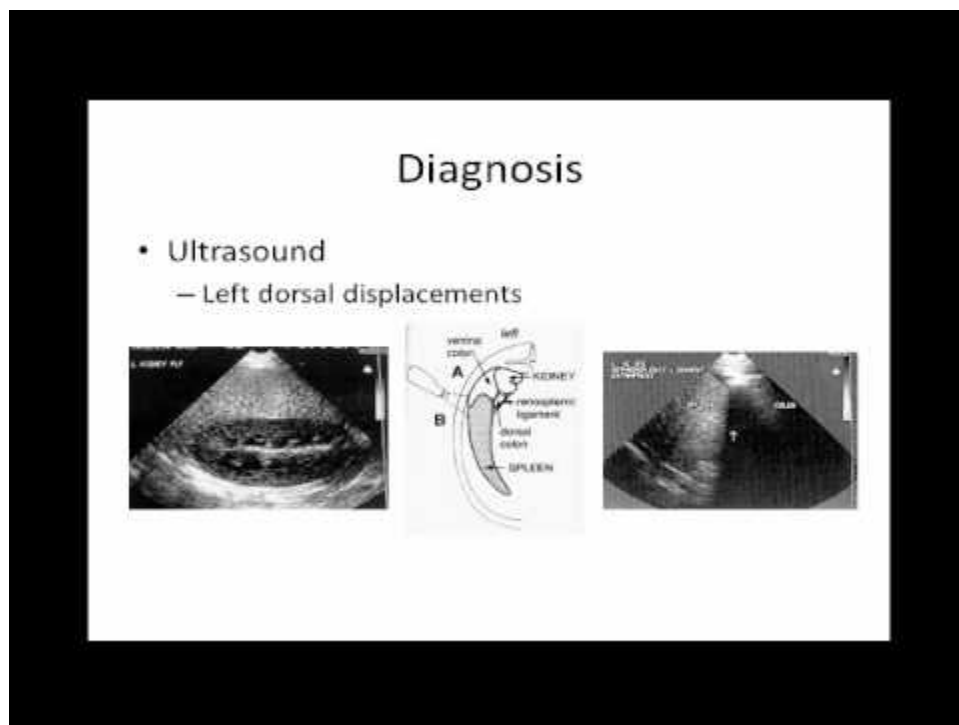
A YouTube element has been excluded from this version of the text. You can view it online here: <https://open.lib.umn.edu/largeanimalsurgery/?p=1610>

[Perirectal abscesses](#) can lead to obstipation due to pain

Gas colics and Displacements

Displacement pathophysiology

The microbes in the colon produce gas and create a balloon-like response. Since the colon is not adhered to the body, it is free to float up and down. Sometimes it floats out of position. Many simple displacements will self correct.



A YouTube element has been excluded from this version of the text. You can view it online here: <https://open.lib.umn.edu/largeanimalsurgery/?p=1482>

Nephrosplenic entrapment (left dorsal displacement)

One specific type of displacement is a nephrosplenic entrapment. The colon floats up on the outside of the spleen and ends up hooked over the ligament connecting the spleen and kidney. This ligament forms a hammock for the colon, and, like most hammocks, is difficult to get out of. Treatment can involve medical or surgical therapy:

1. Jog the horse and hope the colon slips off again – this is most useful when the colon is not heavily distended or impacted.

2. Give the horse phenylephrine to shrink the spleen and jog the horse – with the smaller spleen it may be more likely to bounce off.
 - Older horses are at risk of fatal hemorrhage due to arterial rupture.
3. Roll the horse under heavy sedation
4. Re-position the colon either through a left flank incision (may not be big enough) or ventral mid-line incision (general anesthesia)

Since this type of colic can be treated in the field, it is useful to be able to identify it. Horses will show signs typical of a gas colic with intermittent low grade pain. Manure passage will be lessened. Horses may reflux due to compression of the duodenum by the colon.

- Rectal exam – the spleen is moved centrally, away from the left body wall. It may be possible to palpate colon in the nephrosplenic space
- Ultrasound – as the colon is between the spleen and the kidney, the gas in the colon blocks visualization of the left kidney.
- Either ultrasound or repeated rectal palpation will be necessary to tell if the medical management has fixed the entrapment.

A few horses will re-entrap. The space can be obliterated laparoscopically.

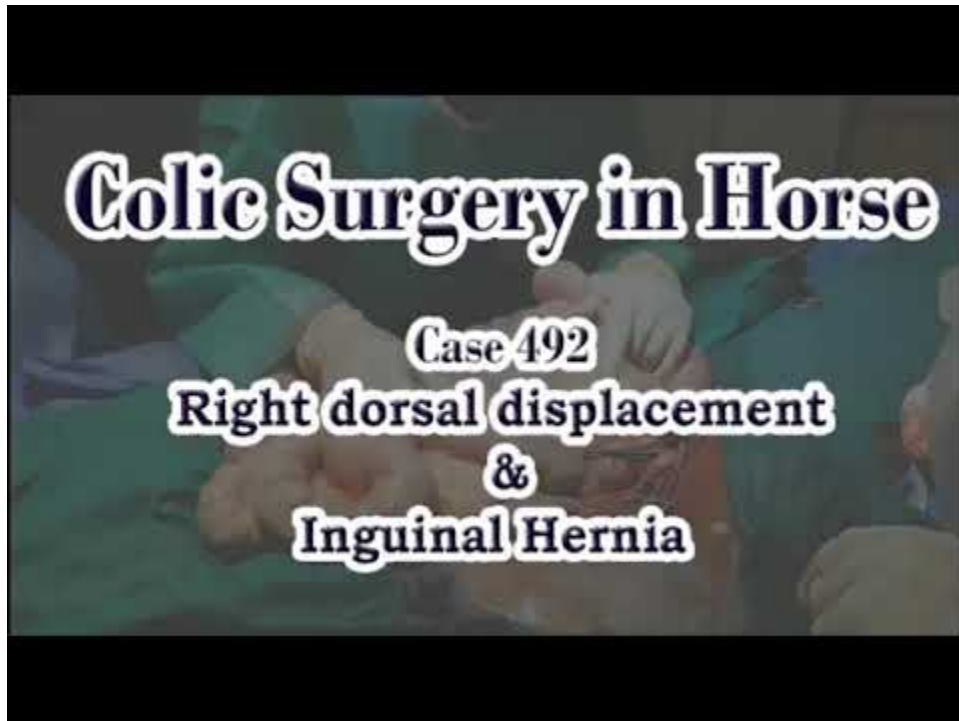[Nephrosplenic entrapment](#), J Jewell, NEEMSC

Right dorsal displacement

If the colon displaces to the right, it may not get stuck. Some of these will fix themselves and others will need surgery. Trocarization may help if the colon has a ping and if surgery isn't an option.

Vessels of the cecum may be identified in normal horse, but **colon vessels** should **not** be detectable in a horse with a **normally positioned colon**

A YouTube element has been excluded from this version of the text. You can view it online here: <https://open.lib.umn.edu/largeanimalsurgery/?p=1482>



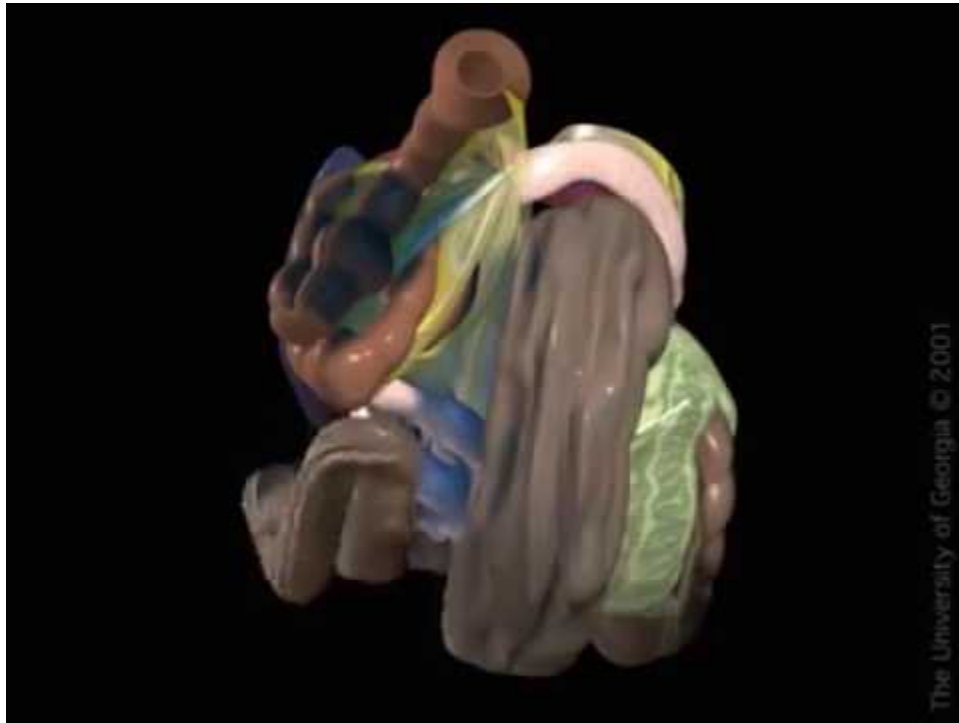
A YouTube element has been excluded from this version of the text. You can view it online here: <https://open.lib.umn.edu/largeanimalsurgery/?p=1482>

Torsions and entrapments (hernias)

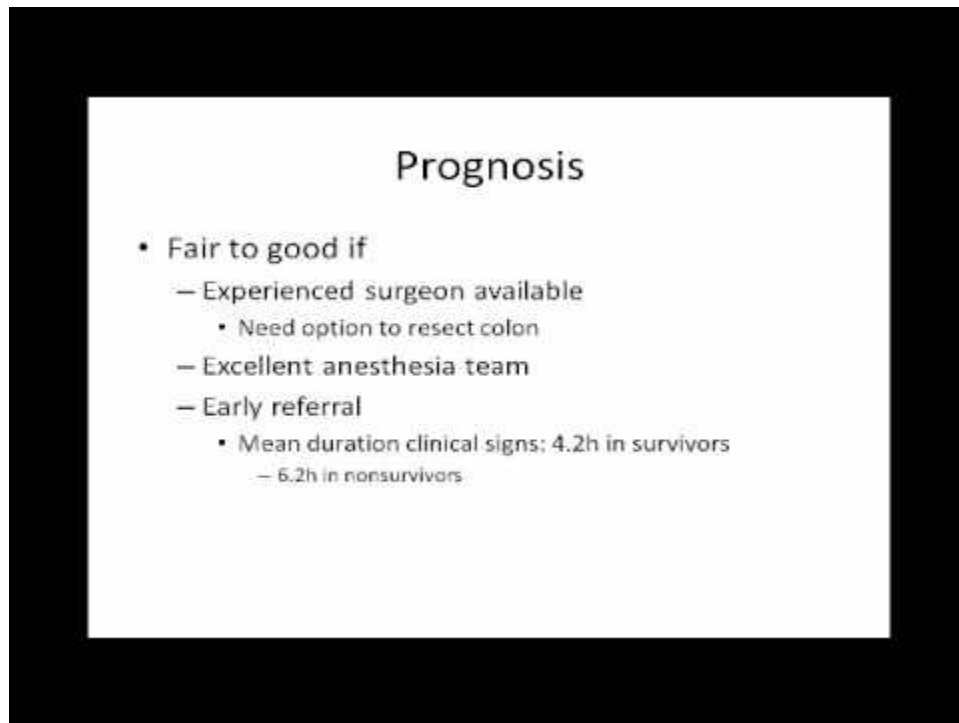
Both the small and large intestines can twist. The large colon tends to twist more often, likely related to changes in gas levels and motility. Intestines can also slide through small holes (hernias, mesenteric rents). Often they can't slide back out (particularly in small holes) and become distended and swollen, leading to even more severe entrapments and devitalization.

VOLVULUS

Large colon volvulus



A YouTube element has been excluded from this version of the text. You can view it online here: <https://open.lib.umn.edu/largeanimalsurgery/?p=1598>




A YouTube element has been excluded from this version of the text. You can view it online here: <https://open.lib.umn.edu/largeanimalsurgery/?p=1598>

These horses do require surgery and intense medical therapy. The colon may be viable enough to just be untwisted and left in the horse. Much of the colon can be removed if needed. This isn't always possible due to the location of the twist.

Small intestinal volvulus

Diagnosis


- Ultrasound
- Abdominocentesis
- Radiographs (foals)
- Surgical exploratory



A YouTube element has been excluded from this version of the text. You can view it online here: <https://open.lib.umn.edu/largeanimalsurgery/?p=1598>

Complications

- Complications :
 - Hypovolemic shock
 - Organ damage/failure
 - Stomach rupture
 - Endotoxemia
 - Laminitis
 - DIC
 - Intestinal damage
 - Peritonitis
 - Adhesions
 - Motility dysfunction
 - Postoperative ileus



A YouTube element has been excluded from this version of the text. You can view it online here: <https://open.lib.umn.edu/largeanimalsurgery/?p=1598>

Up to 50% of the small intestine can be removed if needed due to damage. These horses are more prone to postoperative ileus and adhesions.

HERNIAS

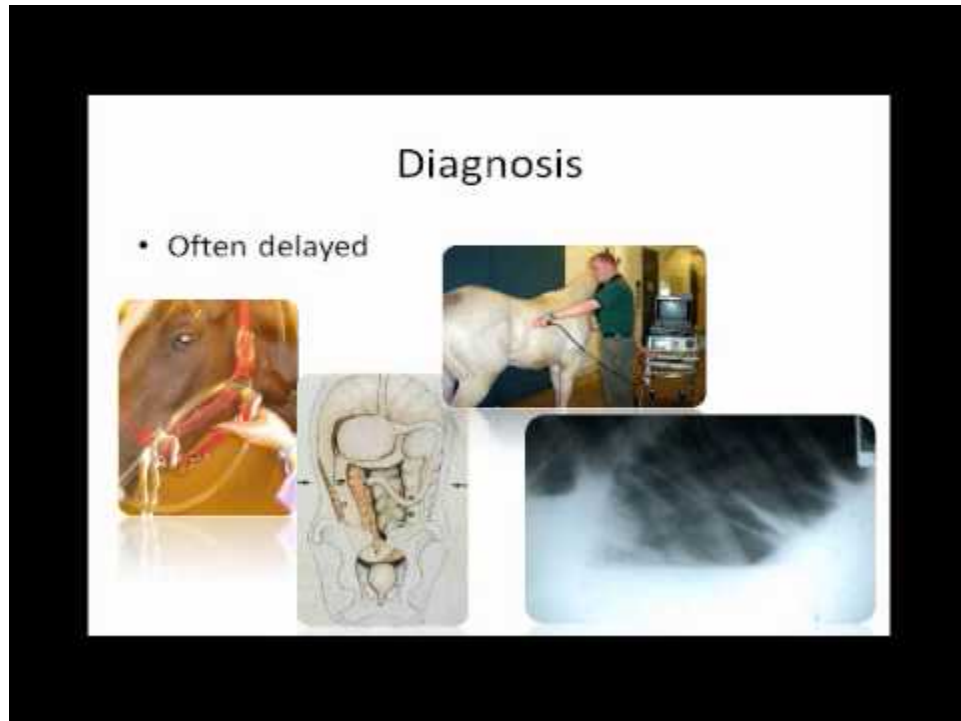Treatment

- Time
 - Mother Nature will resolve many
 - Wait until 4-6 mo old if no problems
- Hernia belts

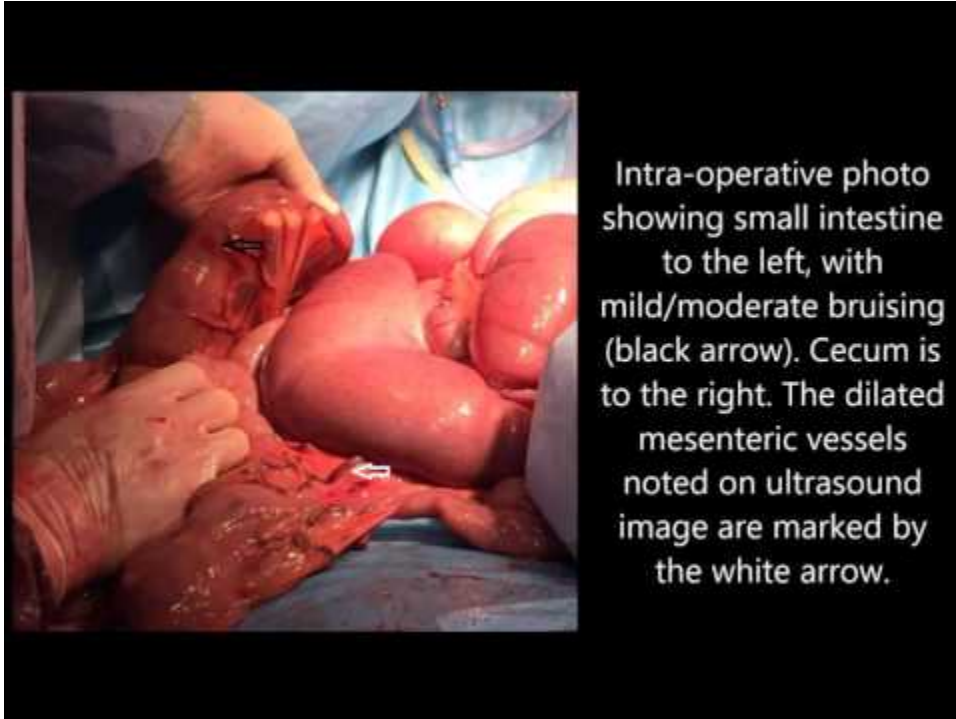

Research?

A YouTube element has been excluded from this version of the text. You can view it online here: <https://open.lib.umn.edu/largeanimalsurgery/?p=1598>



A YouTube element has been excluded from this version of the text. You can view it online here: <https://open.lib.umn.edu/largeanimalsurgery/?p=1598>



A YouTube element has been excluded from this version of the text. You can view it online here: <https://open.lib.umn.edu/largeanimalsurgery/?p=1598>

Inflammation related colics

Erosions and ulcerations can lead to significant pain. NSAIDs are a common cause of GI ulceration in horses.

Duodenal ulceration is identified in foals and in adults.

Complications

- Secondary gastric ulcers (severe)
- Secondary reflux esophagitis
- Duodenal perforation -> peritonitis, adhesions
- Duodenal stricture -> SI obstruction



A YouTube element has been excluded from this version of the text. You can view it online here: <https://open.lib.umn.edu/largeanimalsurgery/?p=1937>

Right dorsal colitis can cause severe pain and is often associated with performance horses on NSAIDs.

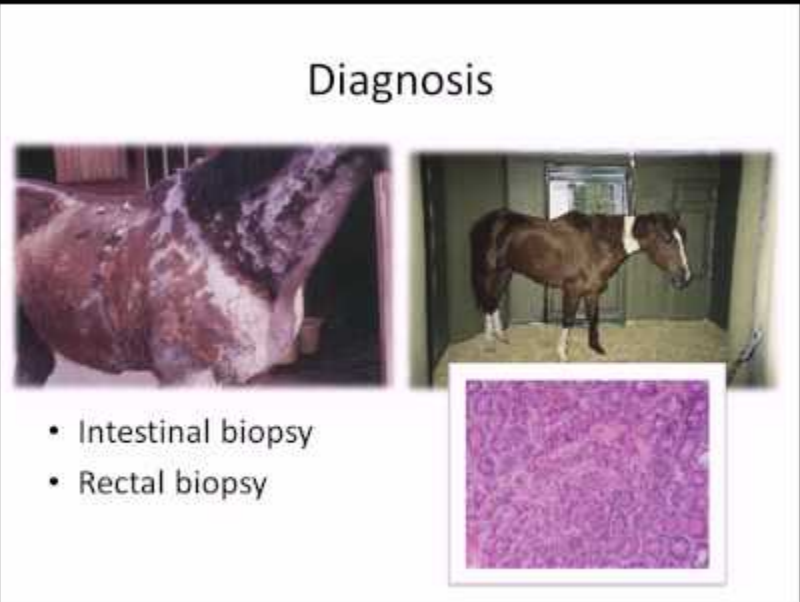
Treatment

- Referral recommended
- Discontinue NSAIDs
- Supportive fluids, colloids
- +/- misoprostol, sucralfate
- +/- antibiotics
- +/- colon resection

A YouTube element has been excluded from this version of the text. You can view it online here: <https://open.lib.umn.edu/largeanimalsurgery/?p=1937>

Inflammatory bowel disease can lead to weight loss and multiple conditions related to poor nutrition.

Diagnosis



- Intestinal biopsy
- Rectal biopsy

A YouTube element has been excluded from this version of the text. You can view it online here: <https://open.lib.umn.edu/largeanimalsurgery/?p=1937>

Proliferative enteropathy generally affects juveniles and is a growing concern.

Prognosis

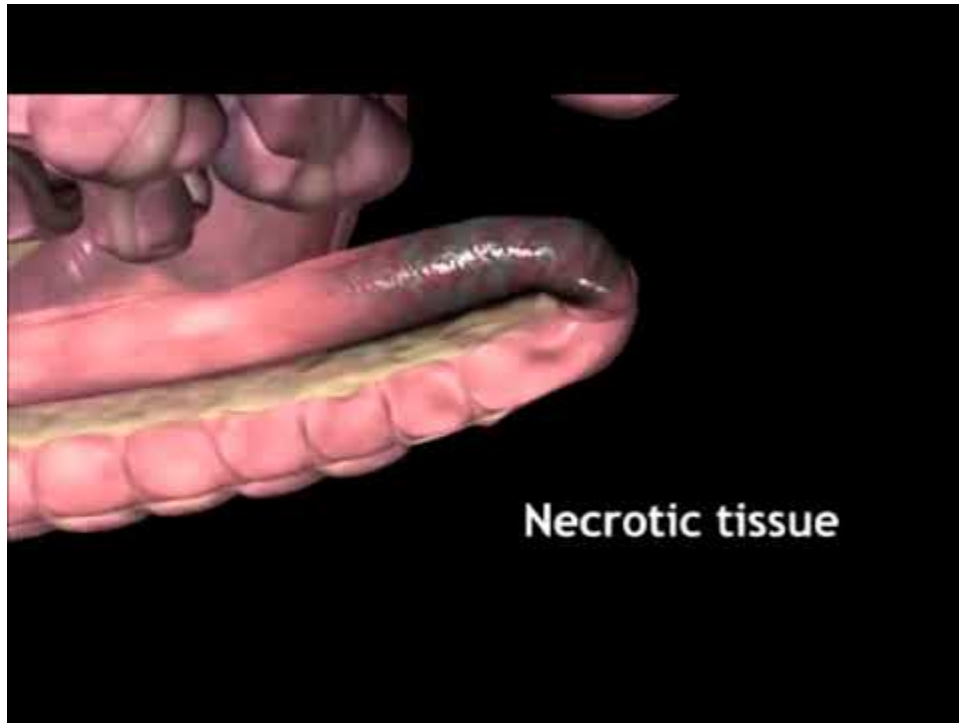
- Better with early and directed treatment
 - Good prognosis
 - No impact on future performance
- Delayed detection
 - >Severe hypoproteinemia
 - >Need intensive supportive care



A YouTube element has been excluded from this version of the text. You can view it online here: <https://open.lib.umn.edu/largeanimalsurgery/?p=1937>

Infarctions and intussusceptions

Infarctions are the rarest form of colic but are often life threatening as the damage may be multifocal, severe and/or not resectable.



A YouTube element has been excluded from this version of the text. You can view it online here: <https://open.lib.umn.edu/largeanimalsurgery/?p=1940>

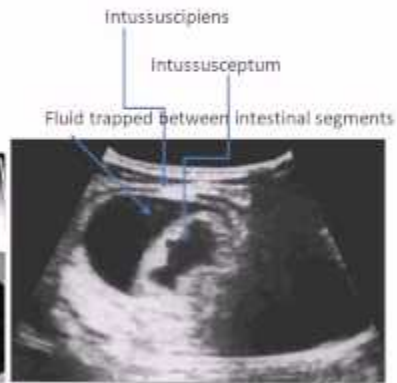
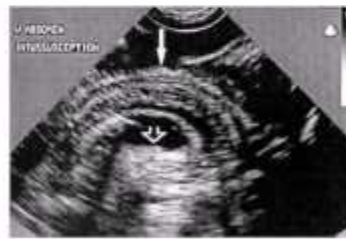Signalment	Predisposing factors	Clinical signs
<ul style="list-style-type: none">• All	<ul style="list-style-type: none">• Previous strangles• Parasites• Ineffective dewormers• Trauma	<ul style="list-style-type: none">• Colic• Depression• Anorexia• Tachycardia• Myopathy• Endotoxic shock

A YouTube element has been excluded from this version of the text. You can view it online here: <https://open.lib.umn.edu/largeanimalsurgery/?p=1940>

Intussusceptions typically occur with motility disorders (diarrhea, parasites) and with changes in the intestinal wall (neoplasia or granulomas). Brown Swiss are predisposed to intussusceptions.

Diagnosis

- Ultrasound
- Abdominocentesis, rectal examination
- Exploratory surgery



A YouTube element has been excluded from this version of the text. You can view it online here: <https://open.lib.umn.edu/largeanimalsurgery/?p=1940>

Motility disorders

Hormonal (stress, pregnancy), drugs (most sedatives) and electrolyte changes can alter motility, leading to colic.

Postoperative ileus and exertional ileus

Complications/Prognosis

- Complications
 - Gastric rupture
 - Organ failure
 - Adhesions due to lack of motility
 - Negative energy balance

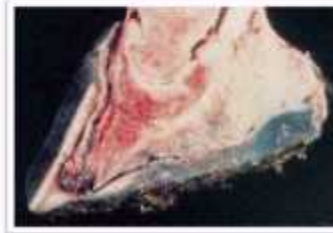
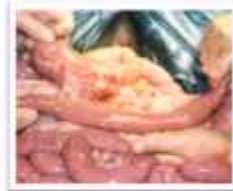- Prognosis
 - POI : Good if timely response to treatment
 - Postexertional : Good if uncomplicated

A YouTube element has been excluded from this version of the text. You can view it online here: <https://open.lib.umn.edu/largeanimalsurgery/?p=1944>

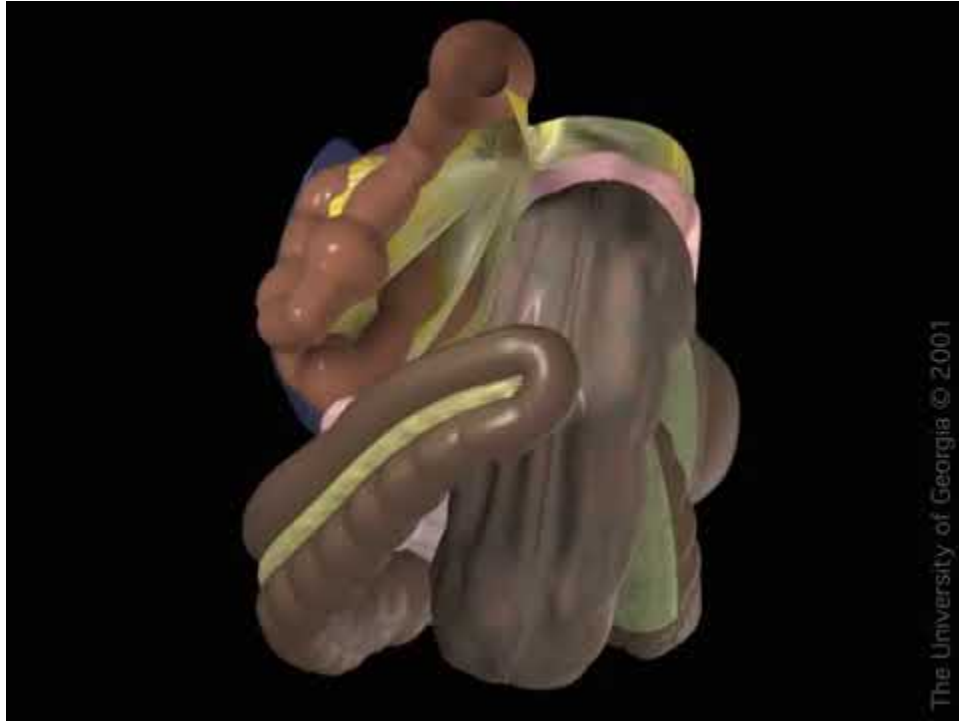
Inflammation can also lead to ileus. Proximal enteritis

Complications

- Gastric rupture
- Laminitis
- Adhesions
- Myocarditis (and arrhythmias)
- Hypovolemic shock
- Death



A YouTube element has been excluded from this version of the text. You can view it online here: <https://open.lib.umn.edu/largeanimalsurgery/?p=1944>



A YouTube element has been excluded from this version of the text. You can view it online here: <https://open.lib.umn.edu/largeanimalsurgery/?p=1944>

Neonatal colics

Foals are commonly affected by meconium impactions. These typically respond quickly to enemas. Lethal white foals, on the other hand, have defects in the myenteric ganglion and are not treatable.

Complications/Prognosis

- Colic
- Patent urachus
- Failure to nurse adequately (FPT)
- Colonic or rectal edema and inflammation
- Mini foals get very sticky impactions
 - Often need surgery
- Prognosis for most = good

A YouTube element has been excluded from this version of the text. You can view it online here: <https://open.lib.umn.edu/largeanimalsurgery/?p=1962>

Perirectal and rectal disorders

Perirectal abscesses are not common and may be secondary to trauma or lymph node disorders.

Perirectal abscess

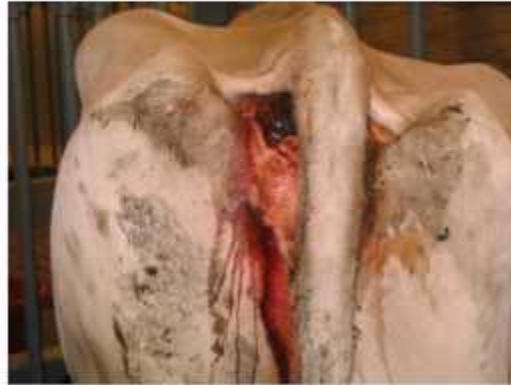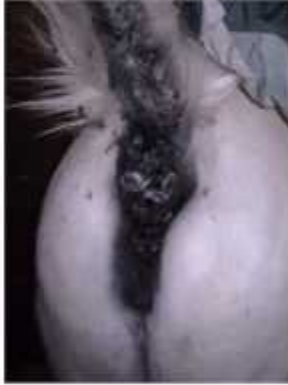- CBC
- Aspirate or tru-cut biopsy
 - Ultrasound guided
 - Thru perineal skin



A YouTube element has been excluded from this version of the text. You can view it online here: <https://open.lib.umn.edu/largeanimalsurgery/?p=1965>

Rectal atresia is considered heritable. Rectal tumors are common in gray horses (melanomas).

Other rectal lesions



A YouTube element has been excluded from this version of the text. You can view it online here: <https://open.lib.umn.edu/largeanimalsurgery/?p=1965>

Practice



An interactive or media element has been excluded from this version of the text. You can view it online here:

<https://open.lib.umn.edu/largeanimalsurgery/?p=1986>



An interactive or media element has been excluded from this version of the text. You can view it online here:

<https://open.lib.umn.edu/largeanimalsurgery/?p=1986>



An interactive or media element has been excluded from this version of the text. You can view it online here:

<https://open.lib.umn.edu/largeanimalsurgery/?p=1986>

Camelid castration

Field anesthesia for camelid castration

Find the answers to the study questions below and then try the review quiz.

Study Questions

1. How long should camelids be held off feed before an elective anesthesia?
2. What is Llama Lullaby? How does it compare to other anesthesia protocols you have learned about?
3. Can Llama Lullaby be used for alpaca and/or llama castrations?
4. Are llamas more or less sensitive to anesthetic drugs than alpacas?
5. What restraint is needed to keep the camelid in place for castration?
6. What are the positioning recommendations for camelids to prevent aspiration pneumonia?
7. What monitoring is recommended for camelid anesthesia?
8. If the animal becomes too deep, what reversal agents should you use/not use?
9. What do you have to worry about during camelid recovery?
10. How does the recovery process compare to horses?

Exercise

Try the quiz to see how much you learned:



An interactive or media element has been excluded from this version of the text. You can view it online here:
<https://open.lib.umn.edu/largeanimalsurgery/?p=284>

RESOURCES

[Camelid sedation and anesthesia protocols](#)

[Food Animal General Anesthesia Protocols](#)

[Veterinary Techniques for Llamas and Alpacas](#) Chapter 7 Sedation and Tranquilization

[Chemical restraint, anesthesia and analgesia for camelids](#), Abrahamsen, VCNA 2009

Camelid Castration

Use the resources below to find the answers to these questions regarding camelid castration. Then fill out the surgery report below and try out the quiz.

Study Questions

1. Is there a recommended age for camelid castration? Can the animal be too young or too old?
2. What NSAIDs can be given to camelids if you have venous access? What about if you don't?
3. Are antibiotics commonly used? If so, which ones?
4. Is tetanus toxoid needed?
5. How do camelid castrations compare to horse or dog castrations?
6. Is open or closed castration performed?
7. Prescrotal or scrotal incision? Local anesthetic blocks?
8. Is the surgery site closed after the testicles are removed?
9. How common is cryptorchidism and where is the testicle found?
10. What postoperative care is recommended?
11. How long do the castrated males stay fertile? Maintain behavior patterns? [FWIW- I could find no evidence on this. AntiMullerian hormone decreases about 24 hours after castration. Alpaca sites say 6 weeks separation Some males do maintain behavior patterns indefinitely. Please let me know if you find good answers.](#)

Exercise 1

Earlier today you castrated a 2 yo alpaca. Flies were bad so that affected your choice of procedures. It had been 6 months since he had his spring shots but he was otherwise healthy and there were no complications. Please fill out the following surgery report.



An interactive or media element has been excluded from this version of the text. You can view it online here:

<https://open.lib.umn.edu/largeanimalsurgery/?p=282>

Exercise 2

Take the knowledge quiz to review the other material.



An interactive or media element has been excluded from this version of the text. You can view it online here:
<https://open.lib.umn.edu/largeanimalsurgery/?p=282>

RESOURCES

[Camelid sedation and anesthesia](#)

[Routine Camelid Procedures – Part 1: Castration of Alpacas and Llamas](#), 2019 VetFolio

[Ch 62 Reproductive surgery](#) in [Llama and Alpaca Care](#)

[Ch 64 Castration](#) in [Veterinary techniques for llamas and alpacas](#)

Equine GI Topics

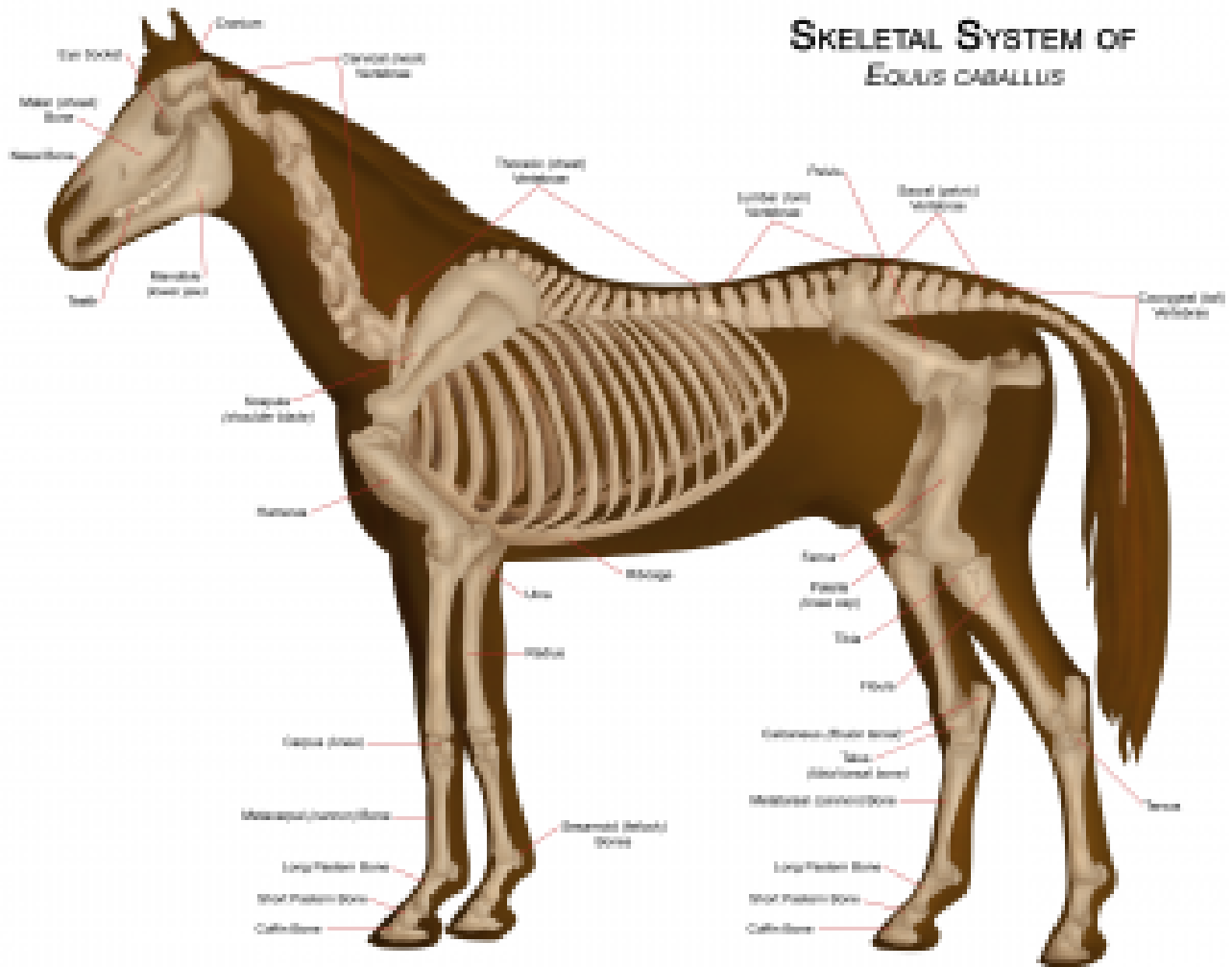
Therapeutics

Resources

[Antimicrobial therapy for GI diseases in horses](#), VCNA 2003, Vol.19(3), pp.645-663

Equine Lameness

Background information for LAS I equine lameness



Lameness diagnosis

LAMENESS EXAMINATIONS CHEAT SHEET

Straight line lameness exam

Foreleg lameness : HEAD NOD

- “Down” on the “sound”
 - The horse throws his weight to his hind limbs when he has to step on the sore leg
 - This is the equivalent of “up” on the “lame” leg.
 - Forelimb lameness is more challenging when the problem is bilateral, such as with navicular syndrome. The horse can’t decide which leg to bear more weight on and instead shows a short choppy gait.
 - Sometimes it is easier to hear the lameness better than to see it (change in force of landing)

Hind limb lameness : HIP “HIKE”

- More hip motion, either up or down, on the lame leg
 - not necessarily a hike
 - occasionally will lead to a mild head nod (the horse usually keeps his/her head higher overall – no deep nod)

Lameness grades (AAEP)

- Grade 5: non-weight bearing
- Grade 4: lame at a walk
- Grade 3: lame at a trot
- Grade 2: lame consistently under special circumstances (eg lunging)
- Grade 1: lameness difficult to observe and inconsistent, irregardless of circumstances

Lunging

- Used to exacerbate lameness (jog in a tight circle)
- In most instances, the lame leg will be worse when on the inside of the circle
- If it is more lame when the leg is on the outside of the circle, think soft tissue (pulled more)

Flexion tests

- Used to exacerbate lameness; generally signifies joint pain; can be soft tissue if pulled when limb flexed
- Distal limb flexion : flexes fetlock, pastern and coffin joint
- Carpal flexion : flexes carpus only
- Spavin test : flexes hock, stifle and hip
- Upper limb flexion, forelimb : flexes elbow or shoulder; extends other joint

Passive Lameness Exam

Palpation

- Check for asymmetry, swellings, and pain in response to palpation.
- Horses with forelimb lameness will often be sore in the shoulder region even if foot pain due to abnormal carriage of the limb
- Similarly, horses with hindlimb lameness will often have back pain

Hoof testers : around white line ; from frog to walls and across bulbs of heel

Check hoof -pastern axis and hoof balance (coronary band parallel to the ground)

Churchill hock test : tests for pain in the lower hock joints (bone spavin)

Done by trying to pull the medial splint bone around to the lateral side of the leg. If painful, horse will react by abducting the leg (not positive if he pulls back or forward; has to pull away from the source of pain on the medial aspect of the leg)

Range of motion (ROM) : amount of flexibility in joint. E.g. should be able to flex carpus so that heel touches elbow; if can't, this is restricted ROM

Local anesthesia

Used to numb an area to determine if pain is coming from that region. Generally start low and work up

Resources

aaep article

Lameness examination form

Sample form

Walk

Left Circle²⁰

Right Circle

Test:
 Heading Lameness
 CP 0 1 2 3 4 5
 KP 0 0 0 0 0 0
 LP 0 1 2 3 4 5
 XSE 0 1 2 3 4 5

Left Circle
 CP
 KP
 LP
 XSE

Right Circle
 CP
 KP
 LP
 XSE

ELBOW TESTS

Flexion Limit:

Palpated: L. _____ R. _____
 Creps: L. _____ R. _____
 Elbow/Shoulder flex: L. _____ R. _____
 Elbow/Shoulder ext: L. _____ R. _____

Flexion Limit:

Palpated: L. _____ R. _____
 Creps: L. _____ R. _____
 Hip flex: L. _____ R. _____
 Hip ext: L. _____ R. _____
 Hip abd: L. _____ R. _____

WEDGE TESTS

Flexion Limit:

Distal wedge: L. _____ R. _____
 Proximal wedge: L. _____ R. _____

Flexion Limit:

Distal wedge: L. _____ R. _____
 Proximal wedge: L. _____ R. _____

DIAGNOSTIC BLOCKS

Block:

Flex:

Block:

All performed individually unless noted otherwise

Palmar digital nerve block _____
 Distal mesothoracic joint block _____
 Nerveless femoral block _____
 Flexor tendon sheath block _____
 Flexor joint block _____

Palmar digital nerve block _____
 Distal mesothoracic joint block _____
 Nerveless femoral block _____
 Flexor tendon sheath block _____
 Flexor joint block _____

OTHER

Biomechanics for lameness evaluation

Veterinary Biomechanics Summary (Vic Cox)- optional reading

I. Statics vs. Dynamics

A. **Statics** refers to stationary support, dynamics refers to movement. Most muscle tendon systems serve both functions. Static analysis of material strength is commonly done by civil and mechanical engineers and has been applied to biological materials such as bone and tendon. The properties usually measured are:

1. **compressive strength** – how much force must be exerted to crush the test material
2. **tensile strength** – how much force must be exerted to pull the material apart
3. **shear strength** – how much force must be applied in offset directions to cause a material to split in half (to shear)

B. The **stay** apparatus of the horse is probably the best example of a structure designed for static function. That is, for support during rest.

C. **Dynamic** function requires greater muscle mass, hence the hind limb which is designed for thrust, is twice as massive as the forelimb.

D. The **check ligaments** allow the digital flexor muscles to rest during static function. During the support phase of motion the check ligaments work together with active muscle tension to withstand momentary high stress as body mass passes over the supporting fetlock.

E. **Kinesiology** is the study of animal motion. It is studied by an analysis of the geometry of limb positions or by a measurement of forces.

1. **Kinematics** is the study of the geometry of motion. Study of the moving horse spurred the initial development of motion picture technology. Until recently, quantification of cinefilm was an extremely laborious technique requiring frame by frame tracing of limb positions to provide digitized data for computer analysis. Video analysis now allows this process to be done automatically. Angle/angle diagrams usually involve a comparison of the changes in joint angle of adjacent joints. If a joint is painful its range of motion will be decreased and the angle/angle diagram will appear different than that of normal joints (shortened stride length)

2. **Kinetics** refers to the study of forces. Methods used here include force plates that measure rapid changes in the force applied to a plate as the foot strikes it. Pain will cause an animal to step softly and hence less force will be recorded by a force plate.

II. Muscle Types
A. **Antigravity muscles** serve both static and dynamic functions. The quadriceps muscle, for example, prevents collapse of the stifle joint during standing but extension of the stifle joint contributes to thrust during movement. The antigravity muscles include:

1. Extensors of proximal joints.

2. Digital flexors support the fetlock. When these tendons are stretched due to overexertion downward translation of the fetlock will occur, and if severe can result in fracture of the proximal sesamoids.

Afterwards, swelling results in bowed tendons.

B. Flexor muscles function to:

1. Lift the leg off the ground so that it can be swung forward during the protraction phase of the stride. The faster the gait the greater degree of flexion to reduce angular mass by keeping the mass close to the pivot point.
2. Withdrawal of the limb from noxious (harmful) stimuli.

III. Velocity = stride length X stride frequency. A. **Stride length** is determined by:

1. **Length of limb** – digitigrade and unguligrade modifications increase limb length.
2. **Pivot point** modification – movable shoulder with pivot point at caudal angle of scapula (serrated face) allows the limb to reach forward farther.
3. **Unsupported intervals** – the animal is momentarily flying through the air. Usually two such intervals occur per stride of carnivores but only one in the case of ungulates.
4. **Foot fall pattern** – each foot individually propels the body forward. The more the limbs act independently, the greater the effect of each. When foot falls are close together their separate effects are lost as they are merged together. Close footfalls have a large overlap time. Smaller overlap time was correlated with longer stride length in a cinefilm analysis of Secretariat.

B. **Stride frequency** (rate) is determined by:

1. **Contraction rate** of muscles – generally smaller animals have more rapidly contracting muscles due to a higher metabolic rate.
2. **Gear ratio** – like a motor vehicle, the low gear muscles deliver power while the high gear muscles deliver speed. Both types work together to provide an optimal balance of speed and power. There are various anatomical arrangements of lever arms and the pivot points (fulcrum). The output force is the ratio of the input force times the length ratio of the lever arms. The same is true of the output velocity except that the lever ratio is reversed (reciprocal). This makes intuitive sense because force (or power) must be sacrificed to get speed.

3. Angular mass (moment of inertia). This corresponds to mass in rectilinear motion, that is, it resists acceleration. As the speed of equine gaits increases, the limbs are flexed more in the protraction (advancing) phase. Flexion reduces the effective length of the limb and thereby angular mass is reduced. Angular mass is the product of mass times effective length squared.

IV. **Center of gravity** – is cranial to the intersection of diagonals drawn from forelimbs to opposite hind limbs. This is because the cranial part of the body is heavier.

A. **Stay apparatus** – the limbs form a tripod, both forelimbs are firmly fixed but only one hind limb is fixed.

B. **Head position** – the center of gravity shifts forward as the head is lowered and extended forward. It is shifted caudally when the head is raised because raising the head also makes the center of gravity more caudal.

1. Head is lowered before **kicking** – this shifts the center of gravity forward so that the body is more stable.
2. **Head nod** up when painful fore foot hits – this tends to shift center of gravity back off of the painful forelimb. The often quoted rule in the clinic is “down on sound” meaning the head goes down when the normal foot hits but up when the lame foot hits.

Distal limb bones review

Fetlock and Digit Set

1. **Distal cannon bone** (metapodium = metacarpal or metatarsus)

A. medial and lateral fossae provide attachment sites for the collateral ligaments.

B. The condyle is the distal articular surface of the cannon bone and P1 and P2. Note, however, that the distal cannon has a sagittal ridge while the condyles on the distal ends of P1 and 2 are saddle shaped.

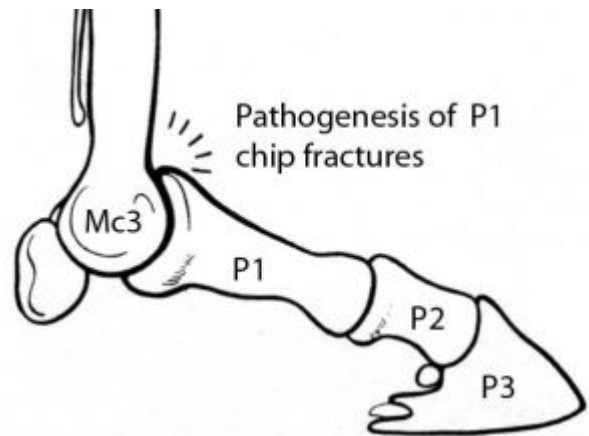
2. **Proximal sesamoids** are what make the fetlock the widest part of the distal limb (other than the hoof). Aside from their articular surfaces, the rest of the sesamoids are covered with a variety of tendons and ligaments. Therefore, even after removal of the skin and loose subcutaneous tissue, the sesamoids are hidden from view by their many attachments.

- The fibrocartilagenous intersesamoidean ligament binds the axial surfaces together to form a groove on the palmar surface for the digital flexor tendons. On the articular surface is a narrow groove that interdigitates with the sagittal ridge of the distal cannon.
- Note that the articular surface of the proximal sesamoids is the only smooth surface
- Abaxial surfaces have a roughened depression for insertion of the suspensory ligament that covers the entire abaxial surface.
- Basal surface is covered by the attachments of the distal sesamoidean ligaments.

3. Proximal phalanx (P1) is twice as long as the middle phalanx (P2).

Note the sagittal groove on the proximal end of P1. This groove interdigitates with the sagittal ridge on the end of the cannon bone. A screwdriver fracture starts at this groove and runs longitudinally to split P1 into 2 pieces. The screw driver analogy pictures the sagittal ridge of the cannon bone as the blade of a screwdriver and the proximal end of P1 as the head of a screw. According to JR Rooney, these fractures are caused by rotary motion and acceleration. Consider a screw in oak being unable to twist as rapidly as the screwdriver above it resulting in fracture of the screw.

Hold P1 and the cannon bone together as they articulate. Note that the dorsal proximal edge will butt up against the dorsal surface of the cannon bone when the fetlock joint is over extended as happens during extreme downward translation of the fetlock. This is another consequence of excessive downward translation of the fetlock region. Previously mentioned were fractures of the sesamoid bones and bowed tendons.



On the palmar/plantar surface find the triangular area where the middle distal sesamoidean ligaments are inserted. On the distal end of P1 and P2 note the shallow indentation of the articular surface to form a saddle shaped surface as described by radiologists. On the palmar surface of the distal end of P1 are facets for attachment of the SDF tendon.

4. Middle phalanx (P2), a short very compact bone.

Note the strong proximal palmar (planter) edge. This area is strengthened for insertion of the superficial distal sesamoidean ligament and the SDF tendon. Not seen is the attached complementary fibrocartilaginous ridge of P2 which is part of the insertions. On the sides of the ends of P1 and P2 there are depressions for attachment of the collateral ligaments of the PIP and DIP joints respectively.

5. Distal phalanx = P3 = coffin bone.

The extensor process on the coronary border is the place of insertion of the main extensor tendon. Just behind the extensor process note the depression on the lateral side of the coffin bone for attachment of the collateral ligaments of the coffin joint.

The palmar/plantar extensions of P3 are often referred to as the wings of P3 by radiologists. This is the site for attachment of the collateral cartilages of the coffin bone. Unfortunately these cartilages are often referred to as the hoof cartilages but this is a misleading term because the cartilages are attached to P3 and not the hoof. Instead, the collateral cartilages are inside the hoof but their upper parts are above the coronet where they can be palpated easily in the live horse. The collateral cartilages are attached to the wings of P3 just behind the depressions for the collateral ligaments and extend into the heel beyond the coffin bone.

6. Distal sesamoid bone = Navicular bone.

This bone gets the popular name from its boat shape. Note that the distal edge is rounded like the bottom of a

boat, the proximal surface is straight like the deck of a boat. Note the foramina on the distal edge. These are probably for blood vessels, but if the blood vessels recede, the foramina may contain invaginations from the distal palmar pouch of the coffin joint. The other surfaces are the flexor surface adjacent to the navicular bursa and the articular surface which forms part of the wall of the coffin joint = DIP joint.

Split limbs study. Find the following: DDFT, SDFT, pastern (PIP) joint, straight sesamoidean ligament, navicular bursa, coffin (DIP) joint pouches (dorsal, proximal and distal palmar), digital cushion and distal sesamoidean impar ligament.

Summary of synonyms

- Interosseous tendon = suspensory ligament (suspends the fetlock and sesamoids)
- Proximal phalanx = long pastern bone = P1
- Middle phalanx = short pastern bone = P2
- Distal phalanx = coffin bone = P3
- Superficial distal sesamoidean ligament = straight sesamoidean ligament (Z) [unpaired]
- Middle distal sesamoidean ligament = oblique sesamoidean ligament (Y) [paired]
- Deep distal sesamoidean ligament = cruciate sesamoidean ligament (X) [paired]
- Collateral cartilage of P3 = hoof cartilage = ungual cartilage
- Proximal interphalangeal joint = PIP joint = pastern joint
- Distal interphalangeal joint = DIP joint = coffin joint
- Podotrochlea bursa = navicular bursa
- (Podotrochliosis = navicular disease)

Palpation anatomy- forelimb



A YouTube element has been excluded from this version of the text. You can view it online here: <https://open.lib.umn.edu/largeanimalsurgery/?p=1621>

Find a horse and have fun!

Palpation Instructions – Forelimb by Vic Cox

The distal equine limb is mostly bone with some tendons, ligaments and neurovascular structures between the skin and bone. Most soft tissue structures can be palpated by pressing them against the bone. With tendons and ligaments you should press fairly hard but with vessels and nerves a softer touch will work best. The following instructions will serve as a guide but the list is not exhaustive.

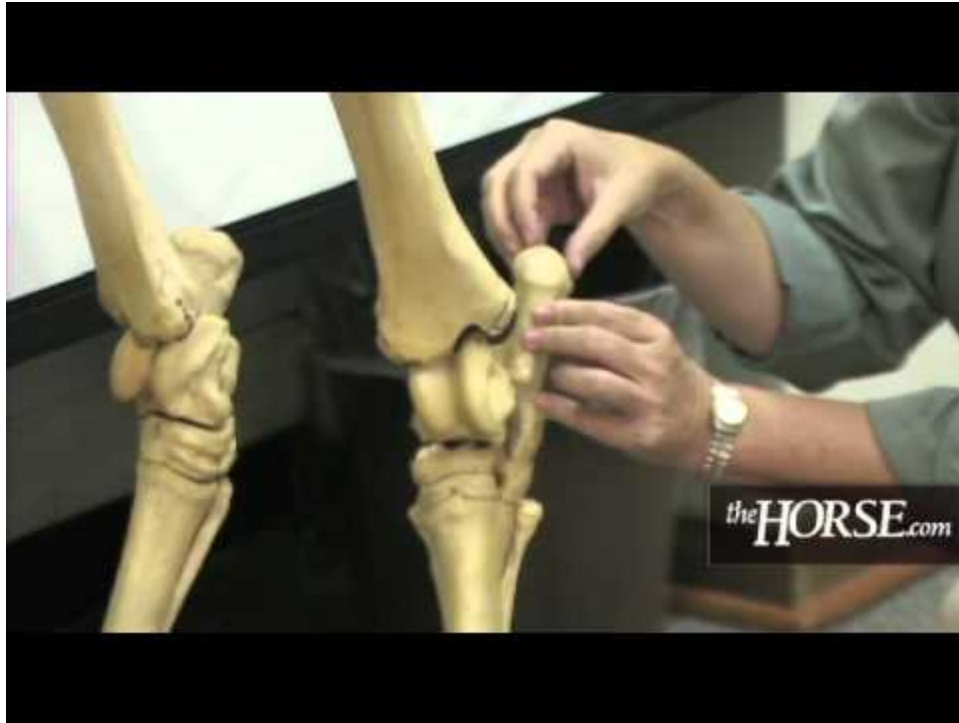1. **Extensor tendons** in cannon region – grasp the cannon region firmly and rub your thumb over the dorsal aspect of the cannon bone. You should feel two tendons. Note that the smaller one is lateral and is the lateral digital extensor. The medial one is the common digital extensor tendon.
2. **Splint bones** – while still grasping the cannon region move lateral or medial and find the groove between the cannon and splint bones. Follow the splint bones distally to find the bulbous end of each splint bone which is sometimes referred to as a button. The splint bone is slightly longer on which side

- (M v. L)? Note that the distal part is flexible. It can be broken off on the lateral side by a kick from another horse. What might cause a medial splint fracture? Fractures of the distal splint bones are treated by surgical removal as are bone chips on the edges of joints.
3. On the palmar surface of the cannon with a soft touch run your index finger up and down over the digital flexor tendons. You should find a cord like structure between the skin and the flexor tendons. This is the **communicating nerve** between the medial and lateral palmar nerves. Note the oblique course of this nerve, which side is it higher on?
 4. On the medial and lateral sides of the **cannon region** move your thumb forward and backwards while grasping the cannon with your other fingers. From dorsal to palmar you should feel the cannon bone → splint bone → suspensory ligament (lower half of cannon only) → digital flexor tendons.
 5. Continue to grasp the cannon and now move your thumb up and down the lateral side of the flexor tendons and try to find a “seam” between the **superficial and deep digital flexors**. If you can’t, don’t worry about it.
 6. Pick up the forelimb and grasp the flexor tendons between your thumb and index fingers. Slip the digital **flexor tendons** between your fingers and note that the DDFT is big and round in cross section while the SDFT is thin and flat.
 7. Put the limb down and find the **suspensory ligament** in the distal cannon using your thumb and index fingers to feel both medial and lateral sides. Note tension in the medial and lateral branches of the suspensory ligament which relaxes when the limb is not weight bearing. Follow the groove between the suspensory ligaments and the distal cannon down to the fetlock where it ends due to the strong horizontal ligaments that bind the sesamoid bones to the end of the cannon bone. The distal end of this groove is one site for injection into the fetlock joint.
 8. Distal to the fetlock find the **extensor branch** of the suspensory ligament obliquely crossing the long P1. Remember that the main part of the suspensory ligament attaches to the abaxial aspect of medial and lateral sesamoid bones but some of the fibers form the extensor branch.
 9. Using your thumb and index finger grasp the sides of the fetlock joint and with a soft touch feel the bundle of **digital vessels and nerves** which are superficial here. The pulse is difficult to palpate here unless there is inflammation in the foot, especially in laminitis. It is good to routinely attempt to feel the pulse here so that when it is easily found you will have physical evidence of inflammation in the foot.
 10. With the same two fingers slide down to the pastern region and feel the long pastern bone and the flexor tendons. Next find the groove between the bone and tendons. In this groove lies the **palmar digital nerve**. It is difficult to feel, but the groove between the pastern bone and the flexor tendons is a good landmark to block this nerve for suspected navicular disease. This is the most commonly blocked nerve in lameness exams.
 11. Palpate the palmar surface of the fetlock to find evidence of the **ergot**, which may be absent, but the ligament of the ergot will still be present. This ligament is useless to the horse, but can be confused with the palmar digital nerve which is cut for navicular or heel pain. If you pull up on the ergot area with one hand while palpating the area described in #10 above lightly, you may feel the **ligament of the ergot** as a thin cord under the skin running distal and somewhat dorsally from the ergot region on

both sides of the palmar pastern.

12. Above the coronet in the region of the quarters and heel feel the upper edge of the **collateral cartilages** of P3. “Wiggle” them and note that they are flexible. Put your thumb between them and push down on the **digital cushion** which fills the space between the collateral cartilages and is deep to the bulbs of the heel.
13. Pick up the limb and **flex the carpus** so you can palpate the radiocarpal and intercarpal joints on the dorsal aspect of the carpus. Note that both open wide when the joint is flexed and the spaces are partially covered over by the extensor carpi radialis and common digital extensor tendons. Carpal chip surgery is done between these tendons. Carpal chips, or a slab fx (fracture) in the case of C3, are found on the dorsal edge of the carpal bones.
14. Put the limb down and palpate the insertion of the extensor carpi radialis tendon on the **metacarpal tuberosity** on the upper dorsal part of the cannon bone just distal to the carpal bones. The tuberosity is a reinforcement of the bone to withstand the constant pull of the extensor carpi radialis tendon as part of the stay apparatus.
15. On the palmar side of the carpus note the prominent “bump” caused by the **accessory carpal bone** (Ca). Wrap your fingers around the medial side of the carpus and palpate Ca with your thumb. Press hard above the Ca bone and feel the vertical “seam” between the two tendons that insert on Ca. Both these tendons have ulnar in their names (ulnaris lateralis and flexor carpi ulnaris). Between these tendons the ulnar n. is found and the **dorsal branch of the ulnar n.**, a cutaneous branch emerges near the “seam” a few cm above Ca and runs laterally over the tendon of the ulnaris lateralis m.
16. On the cranial side of the cubital (elbow) joint find a vertical cord that is hard when weight bearing and soft when weight is shifted off the respective forelimb. This tendon-like structure is the **lacertus fibrosus** = long tendon of the biceps m.. The lacertus fibrosus serves to connect the biceps and extensor carpi radialis tendons making a complete tendinous “cable” from the cannon up to the scapula. This forms the main part of the forelimb stay apparatus.
17. On the cranial edge of the lacertus fibrosus feel a cord like structure that can be moved on the underlying lacertus fibrosus. This is the **cutaneous branch of the musculocutaneous nerve**. It supplies cutaneous innervation to the medial side of the antebrachium and carpus.

Palpation anatomy- hindlimb



A YouTube element has been excluded from this version of the text. You can view it online here: <https://open.lib.umn.edu/largeanimalsurgery/?p=1711>



A YouTube element has been excluded from this version of the text. You can view it online here: <https://open.lib.umn.edu/largeanimalsurgery/?p=1711>

Vic Cox

For this exercise we will start distally and then move up the leg.

Begin by grasping the upper cannon region and run your thumb over the dorsal aspect of the cannon just distal to the tarsus. You should be able to feel and roll two tendons. The larger tendon is the long digital extensor tendon and the smaller more lateral one is the **lateral digital extensor** tendon. Trace the two of them distally and note that they fuse in the midcannon region. The lateral tendon is cut in order to treat the gait defect known as stringhalt. It is important to note that only the lateral tendon is cut, never the long digital extensor tendon. For that reason, it is important to palpate both tendons to ensure that only the lateral one is cut.

More laterally, in the upper cannon region, find the groove between the cannon and splint bones. The **dorsal metatarsal artery** will lie in this groove and must be carefully avoided when cutting the lateral digital extensor tendon. The artery runs under the tendon as it passes distally over the dorsal aspect of the tarsus onto the cannon bone. Careful palpation of this artery in the bony groove will enable detection of the pulse. This artery is an important source of arterial blood for blood gas determination during surgery.

Move up the leg on the lateral side and find the lateral digital extensor tendon above the tarsus where it will be wider than it is distal to the tarsus. As you palpate the lateral digital extensor tendon above and below the hock simultaneously you may be able to feel vibrations in the distal tendon due to palpation of the tendon above the hock.

On the dorsal side of the tarsus note the large cranial branch of the **medial saphenous vein** and palpate it with a light touch. One must be careful to avoid damage to this vein when performing a cunean tendinectomy.

Medial to the vein note the prominent tuberosity which is the **medial malleolus**. This important landmark is at the distal end of the tibia. Distal to the medial malleolus follow the **medial collateral ligament** of the tarsus which attaches to the medial malleolus proximally. Dorsal to the collateral ligament find a depression that represents the medial part of the tibiotarsal joint. It is here that the joint capsule pouches out when distended with fluid that is referred to as bog spavin.

Slide your thumb distally over the medial side of the tibiotarsal joint until you feel an oblique tendon which is the **cunean tendon**. It will lie between the collateral ligament and the saphenous vein and distal to the depression that corresponds to the tibiotarsal joint. The cunean tendon is cut to lessen the pain of bone spavin.

On the distal medial side of the tarsus observe the chestnut and compare its position to the forelimb chestnut.

To palpate the stifle joint begin by locating the tibial tuberosity. The tuberosity will be hard and above it the patellar ligaments can be palpated. The **middle and medial patellar ligaments** are easier to locate than the lateral patellar ligament. This is probably due to the fact that the medial and middle ligaments are part of the loop that forms the patellar locking mechanism. Note the acute angle like the letter “V” formed by the medial and middle patellar tendons where they attach to the tibial tuberosity. Note the tension on the medial and middle tendons and then move your thumb laterally to find the softer, less distinct lateral patellar tendon.

Follow the patellar tendon proximally to the patella. If it is locked, you should be able to feel the large medial part of the femoral trochlea which will be covered with a thin layer of fat. In some cases you will be able to feel the base and then the apex of the patella. Hold the flexor surface of your fingers over the patella and move stifle joint in and out of the locked position. As you do so you will be able to feel the patella locking and “unlocking”.

Grasp the distal crus on its dorsal aspect and lift the leg in order to flex the stifle joint. As you do so note that the tarsus flexes as the leg is hiked up and the stifle joint flexes. This parallel flexing of the tarsus when the stifle is flexed is evidence of the reciprocal apparatus. With the tarsus elevated pull on the distal part of the limb and note resistance to tarsal extension due to an intact peroneus (fibularis) tertius. This is the test for rupture of the peroneus tertius.

Note that as the tarsus is hiked up and flexes, the fetlock becomes more flexed also. This is due to the action of the superficial digital flexor tendon which is stretched as it passes over the point of the hock (tuber calcis). In contrast, when the hind limb is carried forward in extension, the fetlock is in the extended position as is the hock and stifle.

Lameness skills self assessment

Evaluating equine lameness takes practice. Try your hand on youtube videos, clinic cases etc.

	Beginner	Novice	Intermediate	Advanced
Forelimb lameness	Understand what to look for; sometimes can see it	Can see a lameness at a walk	Can usually see a lameness at a trot	Can detect grade 2 lamenesses
Forelimb lameness	Can determine which leg if holding it up or pointing it	Occasionally know which leg is affected	Generally accurate at which leg is affected	Almost always accurate at which leg is affected
Hindlimb lameness	Can see if major asymmetry	Can see a lameness at a walk	Can usually see a lameness at a trot	Can detect grade 2 lamenesses
Hindlimb lameness	Can identify leg if major asymmetry	Occasionally know which leg is affected	Generally accurate at which leg is affected	Almost always accurate at which leg is affected
Head nod	Slow motion makes it visible	Can sometimes see the head nod	Can see the head nod and can often correlate with weight bearing limb	Can detect subtle head nods and can correlate with weight bearing limb
Short stride	Not sure of meaning	Can tell short stride if slow motion or lunging	Can occasionally see the short stride at regular speed	Can usually see the short stride
Foot placement (alterations in tracking)	Not sure of meaning	Understand and can see if exaggerated	Can see if watch for it	Remember to check for it and can see with little effort
Range of motion	Yeah right!	Can see changes in joint flexion if in slow motion	Can sometimes see a difference in joint flexion	Can often see a difference in joint flexion
Hip “hike”	Hip huh?	Understand but don’t often see without tape markers	Can see in many if right conditions (color of horse, background)	Can see in most
Flexion tests	Understand the principles; not sure could do on own	Know the principles behind; can identify structures affected	Understand principles; know when and how to use; could do with supervision	Comfortable doing and interpreting
Palpation skills	Can safely palpate	Could pick up asymmetries but might need a refresher on what the structure is	Can pick up abnormalities, know the larger structures	Can pick up abnormalities even if bilateral and comfortable determining the structures
Hoof testers	Understand the principles	Can apply safely	Can apply and can determine if positive	Can apply and interpret

Forelimb nerve anatomy

Vic Cox

- The medial and lateral **palmar nerves** in the cannon region are adjacent to the deep digital flexor tendon. Much deeper are the medial and lateral **palmar metacarpal nerves** that lie on the palmar side of the metacarpus deep to the suspensory ligament. These nerves emerge at the distal ends of the splint bones and are sensory to the fetlock joint.
- At the fetlock the palmar nerves split to form the small dorsal digital nerves and the larger palmar digital nerves which are the continuation of the palmar nerves. Note that the name is similar with digital inserted.

palmar digital nn. -> heel and navicular region

dorsal digital nn. -> toe and dorsum of digit

- While the palmar nerves follow the deep flexor tendon, the palmar digital nn. are attached to the palmar side of the digital arteries. The palmar digital nerve must be carefully dissected from the artery when a palmar digital neurectomy is performed.
- The **palmar digital nerves** are the most commonly blocked nerves in the horse. They are blocked bilaterally in the midpastern for navicular and heel pain diagnosis and treatment. A horse with this block still knows where its toe is and therefore is safe to ride, but if blocked higher up (5.) so that the dorsal digital nerve is included, the horse is likely to stumble on an uneven surface.
- The **ligament of the ergot** lies superficial to the palmar digital nerve and is sometimes mistaken for it during an attempted neurectomy. The ligament of the ergot crosses over the palmar digital nerve and digital vessels obliquely. While the nerve must be dissected off the digital artery, the ligament of the ergot is superficial and not attached to either of these structures.
- The **palmar sesamoid block** is at the level of the sesamoid bone and both the palmar and dorsal digital nerves are desensitized. Therefore, the entire digit will be desensitized with the possible exception of the proximal long pastern and the dorsal part of the fetlock joint.
- The **low palmar (volar)** block will block the palmar nerves below the communicating branch and also the palmar metacarpal nn. at the level of the distal ends of the splint bones.
- The **high palmar (volar)** block is performed above the communicating branch and blocks the same structures as the low palmar at a higher level. In turn, most of the suspensory ligament is blocked also.
- The distal blocks (4, 5) are usually done with the foot elevated but the upper two blocks can be done with the foot on the ground.
- Volar is a collective term meaning palmar **or** plantar. In most cases the nerve blocks are used in the forelimb but in occasional cases hind limb blocks may be needed.

Nerve and joint blocks

Coffin (DIP) joint

1. Thumbs' width above the coronet and thumbs' width off dorsal midline to either side : find a depression adjacent to the extensor tendon. Insert 20 ga needle either medial or laterally, angling to opposite corner of foot (eg if lateral stick, aim toward 2:00). The needle should sink into a "hole" and it should be easy to inject fluid
2. On the lateral or medial aspect of the foot, one thumbs' width above the coronet (dorsal to the collateral cartilages, aim toward the center of the foot (again, should sink into a hole and be easy to inject).

Try injecting in one needle and have it come out a second needle (through and through lavage)

Pastern (PIP) joint

Very similar to coffin joint but just a little higher – find widest part of long pastern bone and go just below this area. Insert 20 ga needle just under extensor tendon, superficially into joint pouch (don't need to get between bones). Can also inject with limb flexed : find "V" shaped notch at palmar distolateral aspect : aim needle just distal and dorsal

Palmar digital nerves

The neurovascular bundle is a group of structures that you can "strum" in the midpastern region. Usually blocked as low in the region as possible. A 25ga needle is used to inject local anesthetic subcutaneously around the nerve. Usually the order of the structures is vein -artery – nerve, starting dorsally (nerve is most palmar). To desensitize heel region and sole, block both medial and lateral branches.

Basisesamoid nerves:

The same neurovascular bundle is readily palpable as it courses over the sesamoid bones. Nerve remains most axial. 25ga needle used for subcutaneous injection in area of nerve. Both medial and lateral branches blocked to desensitize foot and pastern

Fetlock joint:

1. Insert 20ga needle in lowest area of rectangle formed by splint bone proximally, cannon bone dorsally, suspensory ligament palmarly (plantarly) and sesamoid bones distally. Needle should be parallel to ground if horse is weight-bearing. Injects easily.
2. Insert 20 ga needle under extensor tendon dorsally (shallow injection into joint pouch).
3. Insert 20 ga needle between cannon bone and sesamoid bones when joint flexed

Low volar nerve block

4 nerves to block : deep nerves course between the splint bones and the cannon bone on the axial surface of the splint bones-block just distal to the end of the splint bone using 25ga needle

Superficial nerves course between the suspensory ligament and the deep flexor tendon but can be on either side of a fascial reflection : need to fan needle (move it around) with sufficient local anesthetic to cover moderate sized area

High volar nerve block

very similar to low volar block but performed above communicating branch ; can also inject all but deep medial branch by injection between distal aspect of accessory carpal bone and cannon bone

Carpal joints

Flex the carpus. Note the 4 indentations. Inject above of proximal row to block radiocarpal joint; inject above the distal row to block the intercarpal (midcarpal) joint which communicates with the more distal carpometacarpal joint. The indentations lie on either side of the wide tendon of the extensor carpi radialis m. that runs vertically over the dorsal aspect of the carpal joint. When removing carpal chips the surgeon must work on either side of this tendon.

Tarsometatarsal joint

On the lateral aspect of leg, follow splint bone up until you reach a flat, thumb sized area (slight depression). This is the region above the caudolateral extension of the splint bone. This flat area is above the tarsometatarsal joint (find a skeleton). Insert a 1" 22ga needle slightly distally and slightly dorsally until it sinks its full length into a hole.

This joint can also be injected medially in a very small depression on the distal aspect of the cunean tendon.

Tibiotarsal joint

Inject on either side of saphenous vein on dorsal aspect of leg using 20 ga needle parallel to ground

Tibial/peroneal nerve block

Tibial nerve : about 4" above point of hock, insert 22ga needle from lateral side until point can be felt just under skin medially.

Peroneal (fibular) nerve : at same level, inject on lateral aspect of leg between muscle bellies; fan local anesthetic

Distal intertarsal block

On medial aspect of hock, find small depression on proximal aspect of cunean tendon; insert 22ga 1"needle

Nerve block challenge questions

1. What sort of anesthetic agent would you use to perform a lameness examination and why?

(Typically we use lidocaine, mepivacaine, or bupivacaine as local anesthetics but in different situations.)

1. How would you block out the entire foot?
2. How would you block out the fetlock ? Give 2 options.
3. How would you block the suspensory ligament?
4. How would you evaluate a horse for bone spavin?
5. How could you block the tibiotarsal joint? Give 2 options.
6. There are 3 joint pouches in the stifle. Do you need to block all three separately? What about the 3 joints of the carpus? The hock?
7. Are there any complications related to local anesthetic procedures?
8. How long will the anesthetic last (eg if you want to do a different block, how long will you have to wait)?

Nerve block challenge answers

1. What sort of anesthetic agent would you use to perform a lameness examination and why?

(We typically use lidocaine, mepivacaine, or bupivacaine as local anesthetics but in different situations.)

We typically use mepivacaine (Carbocaine) as it provides a moderate duration of activity (about 2 hours), has a relatively rapid onset of action (10 min), and is relatively nonirritating. Lidocaine is used when you want a fast response (3 min) and want it to wear off quickly (or don't care if it does). However, it can be more irritating and the duration depends upon the animal. Bupivacaine is used for long lasting blocks (eg the treatment of laminitis or pain control).

2. How would you block out the entire foot?

Basal sesamoid (abaxial) nerve block

check for sensation at the dorsal coronet to make sure the entire foot is blocked

3. How would you block out the fetlock? Give 2 options.

Low volar (4 point) nerve block or fetlock joint block. Volar = palmar **or** plantar

4. How would you block the suspensory ligament?

Regional infiltration, high volar (4 point) or modified high volar (2 point) nerve block

5. How would you evaluate a horse for bone spavin?

Inject the tarsometatarsal +/- the distal intertarsal joints

6. How could you block the tibiotarsal joint? Give 2 options.

Intraarticular injection or tibial and peroneal nerve blocks

7. There are 3 joint pouches in the stifle. Do you need to block all three separately?

What about the 3 joints of the carpus? The hock?

Stifle : usually the medial femorotibial and femoropatellar joints communicate but only one in four lateral femorotibial joints communicate with the femoropatellar joint.

Carpus : the intercarpal and carpometacarpal joints communicate

Hock : sometimes the tarsometatarsal and distal intertarsal joints communicate; the proximal intertarsal and tibiotarsal joints usually communicate

8. Are there any complications related to local anesthetic procedures?

Local irritation and swelling is possible with larger volumes (eg volar blocks)

Risk of creating a septic joint is always a possibility with intraarticular injections but is low with proper preparation of the joint

9. How long will the anesthetic last (eg if you want to do a different block, how long will you have to wait)?

It depends on if you want it to or not. With mepivacaine, count on at least 2 hours, but it may take up to 4; with lidocaine, it should be gone in 1-2 hours

Special gaits

These are not painful so will not block out.

Sweeney

Etiology: Atrophy of the shoulder muscles: this allows the shoulder to luxate since there are no collateral ligaments of the shoulder joint. Muscles such as supra- /infraspinatus, subscapularis are so called “active collateral ligaments”. In the past, this was associated with cart horses and pressure on the suprascapular nerve. Now it is most often associated with trauma to the shoulder: eg a kick or fracture that damages the nerve or running into a gate or fence post.

Clinical signs : Shoulder joint moves outward from the scapula. Can also see this with damage to the muscles : torn or stretched muscles

Treatment : rest, anti-inflammatory drugs, surgery to decompress the nerve

Surgery is not usually performed until after 3 months of rest and waiting to see if the muscles will regain tone

Prognosis : guarded to poor for return to normal function

Upward fixation of the patella

Etiology : lack of tone in the quadriceps, allowing the patella to lock in place. This is most common in young horses and those that have been out of training for awhile

Clinical signs : stiff extended leg, particularly when the horse is backed up. May be bilateral . When the stifle “unlocks” horse moves forward normally. May be able to manually move patella into locked position fairly readily

Treatment: old treatment was to cut the medial patellar ligament, thereby preventing the locking. However, normal horses that have this surgery have a strong tendency to develop arthritis in the stifle joint. Now we recommend exercise to strengthen the quads : hill work, over culverts, etc. Other treatments include tendon splitting, irritants injected around the medial patellar tendon to tighten it up, and hormone injections to change the amount of ligamentous/tendinous relaxation.

Prognosis : good if no other problems with the stifle joint

Fibrotic myopathy

Etiology : trauma to the semitendinosus muscles (injection, injury)

Clinical signs: restricted forward motion to hind limb action at a walk. Limb moves forward only so far and then is slapped to the ground due to the restricted muscle action. Cannot be seen at faster gaits

Treatment : old treatment was to resect the scar tissue but this made more scar tissue. Now most people either

ignore it, transect the tendon of insertion of the semitendinosus muscle, or cut some of the restrictive areas under local anesthesia in the standing horse.

Prognosis: there are complications associated with the treatment; If it is mild, it may be best to avoid surgery

Peroneus (fibularis) tertius rupture

Etiology: overextension of the hind limb such as when it is caught in or under something. It may also be iatrogenic during recovery from anesthesia when the leg is in a full limb cast. This occurs because the cast makes the hock more immobile than the stifle joint.

Clinical signs: loss of reciprocal apparatus — the hock can be extended when the stifle is flexed and the hock does not flex much when the horse is moving (straight leg)

Treatment: rest and anti-inflammatory drugs

Prognosis: good

Stringhalt

Etiology: thought to be neuronal dysfunction or adhesions around the lateral digital extensor tendon; plant toxin in Australia

Clinical signs: overflexion of the limb during the forward phase of the stride –the hind limb is pulled up in an exaggerated motion and may even hit the ventral abdomen; may be bilateral

Treatment : can try lateral digital extensor tenotomy If acute lesion, try anti-inflammatory drugs and physical therapy to prevent adhesion formation

Prognosis : guarded for full recovery

Shivers

Etiology : neuromuscular disease that likely involves an abnormality in the feedback loop between afferent and efferent nerve fibers

Clinical signs : involuntary jerky flexion of the pelvic limb (and testicles) as well as extension of the tail : leg is held off the ground in a flexed position and muscles of hind limb and tail may quiver. Mild cases may be intermittent. Generally noted when horse is backed, turned, or made to step over an object. Most common in draft breeds.

Treatment : none

Prognosis : slowly progressive; overall prognosis is poor;

important to determine that the signs aren't caused by PSSM (polysaccharide storage myopathy) as that disease is very treatable

Practice



An interactive or media element has been excluded from this version of the text. You can view it online here:
<https://open.lib.umn.edu/largeanimalsurgery/?p=2322>



An interactive or media element has been excluded from this version of the text. You can view it online here:
<https://open.lib.umn.edu/largeanimalsurgery/?p=2322>



An interactive or media element has been excluded from this version of the text. You can view it online here:
<https://open.lib.umn.edu/largeanimalsurgery/?p=2322>



An interactive or media element has been excluded from this version of the text. You can view it online here:
<https://open.lib.umn.edu/largeanimalsurgery/?p=2322>



An interactive or media element has been excluded from this version of the text. You can view it online here:
<https://open.lib.umn.edu/largeanimalsurgery/?p=2322>

Joint Disorders

Joints can be affected primarily by :

trauma – fractures or chips

arthritis = DJD (degenerative joint disease) = OA (osteoarthritis)

sepsis – infected due to hematogenous spread, local extension, or direct trauma

osteochondrosis – developmental abnormalities in bone/cartilage

Osteochondrosis

Osteochondrosis dissecans (OCD) refers to joint lesions that occur when the cartilage becomes separated from the underlying bone. Further separation continues until pieces of cartilage or cartilage+bone are floating free in the joint. Common sites of OCD in the horse include the lateral trochlear ridge of the distal femur, cranial intermediate ridge of the distal tibia, lateral trochlea of the talus, and caudal aspect of the humeral head.

Subchondral bone cysts are another form of osteochondrosis. However, instead of the overlying articular cartilage becoming detached from the subchondral bone, it becomes infolded. Cysts may also occur secondary to trauma. Common sites for developmental cysts include the medial femoral condyle, glenoid fossa, and distal cannon bone.

Histologically, osteochondrosis is characterized by abnormal chondrocyte differentiation and formation of defective intracellular matrix. The process of ossification is interrupted and abnormally thick cartilage develops. Associated poor vascular supply to the thickened cartilage results in inadequate chondrocyte nutrition. The abnormal cartilage is an area of focal weakness and can separate or infold.

Several factors have been proposed as the inciting factor for osteochondrosis. These include genetic predisposition, rapid growth, nutritional mismanagement, and trauma. None of these factors can be identified as most important.

Osteochondrosis often affects rapidly growing animals; however, it appears to be more closely related to a high energy diet than to rapid growth. Controlled diet studies strongly implicate excess digestible energy (often excessive carbohydrates) as a factor in the development of osteochondrosis. Excess protein did not seem to make a difference. Diets high in calcium and phosphorus may induce osteochondrosis, as can abnormal copper (low) and zinc (high) levels. In another study, mares with wobbler syndrome (probably cervical OCD) were bred to similarly affected stallions. Offspring were not wobblers but had a high incidence of developmental orthopedic disease. In Standardbreds, tarsocrural OCD has a heritability rate of 0.52 (high). Finally, trauma may precipitate disease when biomechanical forces act on structurally abnormal cartilage. This correlates with the identification of clinical signs in horses just starting training.

Osteochondrosis is most commonly diagnosed in young horses being put into work. Lameness may or may not be apparent, as may joint effusion. Diagnosis is confirmed by radiographs or arthroscopy. Nonsurgical treatment includes rest, controlled exercise, and minimizing joint inflammation. It may be successful depending upon the site of the lesion and the intended use of the horse. Surgical treatment has become the treatment of choice and involves removing loose pieces of cartilage and debriding defective subchondral bone. Prognosis is favorable for hock and stifle joints, depending upon the amount of cartilage damage at the time of surgery (up to 70-80% success rates). Prognosis is less favorable for shoulder, pastern, and fetlock joint lesions. These areas tend to develop progressive arthritis.

Osteoarthritis

Osteoarthritis is a noninflammatory disorder of joints characterized by degeneration and loss of articular cartilage and development of new bone on joint surfaces and margins. It is a common response of joints to a variety of insults. In general, it is seen as a “wear and tear” phenomenon but can also occur secondary to osteochondrosis and sepsis. Once cartilage starts to break down, several factors are released into the synovial fluid that cause further inflammation and further cartilage breakdown.

Clinical signs associated with OA include pain on movement, reduced range of motion, increased joint fluid (effusion), and changes in the synovial fluid (less viscous, lower hyaluronan content). Generally, OA affects older horses, horses with a heavy work background, those with osteochondrosis, and those with previously septic joints. Diagnosis is based upon localized lameness (joint blocks) combined with radiographs and/or arthroscopy. Because OA starts as a cartilage disorder, not all lesions will be apparent radiographically.

At the present time we cannot resurface joints with normal cartilage. (Research is ongoing, funded by the NFL...). Treatment is aimed at slowing the rate of cartilage breakdown. Arthroscopy is used not only as a diagnostic and prognostic tool but is also useful in treatment of OA. It is used to remove fragments of new bone and to clean up cartilage lesions and synovial proliferation (inflammatory response). Pastern and lower hock joints may also be “arthrodesed” or fused. This prevents motion and therefore much of the pain associated. Fetlock and carpal joints are also occasionally arthrodesed. Joint replacement is not commonly done in horses.

Medical management is more often used due to the cost of arthroscopy and arthrodesis. **NSAIDs** are used to inhibit the inflammatory reaction; however, they may also interfere with the healing process and should be used judiciously until their full effects are understood. **Corticosteroids** may be injected into joints to relieve inflammation. At low concentrations they may be chondroprotective; however, prolonged use or high concentrations will cause cartilage degeneration. **Hyaluronan (HA)** is frequently used in an attempt to provide cartilage structural materials, to increase the viscosity of the synovial fluid, and as a mild antiinflammatory agent. An intravenous form (*Legend*®) is now available and there is some experimental data to support its use. It is probably most effective in cases of acute synovitis. It may need to be given weekly for optimum effects. **Polysulfonated glycosaminoglycan (PSGAG/ Adequan**®) is composed principally of chondroitin sulfate, a component of cartilage. It is antiinflammatory and is reported to stimulate the production of HA and to interfere with degradative enzymes. It may be given into the joint but greatly increases the risk of sepsis by decreasing the number of bacteria required to overwhelm the immune system. It is more often given im, with a manufacturer’s recommendation of treatment every 4 days for 7 treatments. A number of **oral supplements** have also been developed; chondroitin sulfate and glucosamine are the two most common components. Chondroitin sulfate is similar to PSGAGs in its activity; however, many (all?) forms of chondroitin sulfate are not biologically available. Glucosamine is a precursor of cartilage proteoglycans and may have a number of antiinflammatory activities. Experimental studies on these oral products are limited. The most convincing results have been with *Cosequin*®. Other common and perhaps useful brands are *FlexFree*®, *Synoflex*®, and *MSM*®(oral form of DMSO). Other factors that increase comfort level include **free choice exercise** and keeping the **toes short** (best breakover).

Physeal disorders

Most bones have both a proximal and distal physis, but not all bones. Growth of the long bone occurs in the physis as most of the cells in the physis are cartilage. Physeal growth also adds to the width of the bone.

Wolff's Law – bone adapts to the load applied to it. More load -> bone strengthening. Less load -> bone atrophy. Generally loading is good. The bone remodels to fit the load as long as the forces are physiologic (not too much too soon).

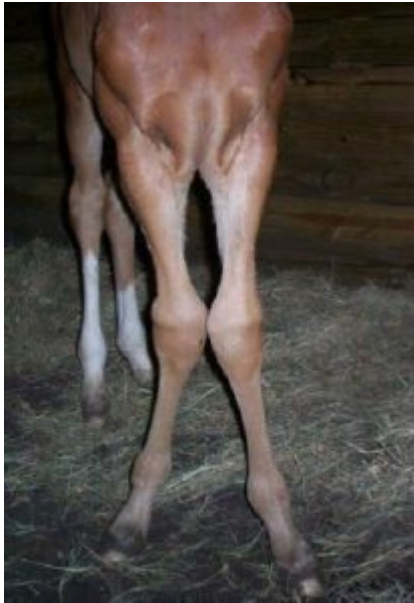Physitis = inflammation of the physis. Physitis can occur due to excessive trauma or to normal trauma on an abnormal physis. Causes include rapid growth due to genetics and/or diet, excessive exercise, uneven weight due to an ALD, or abnormal cartilage. If the cause is exercise or growth, the physitis is usually symmetrical. If the physitis is asymmetrical, look for ALDs. Affected animals show signs of pain – recumbency, knuckling, shaking. The physeal area is swollen and painful on palpation. Radiographs show mixed density in the physis – a combination of sclerosis and increased lucency. Physitis is treated with NSAIDs and removing the risk factors (ALD, decreased exercise, adjust diet).

Growth plate trauma (overload) can lead to fractures but more often impacts growth. If the physis is traumatized, it doesn't grow as well. Often the trauma is not uniformly distributed. If one side of the physis grows well but the other doesn't, the limb grows crookedly (angular limb deformities).

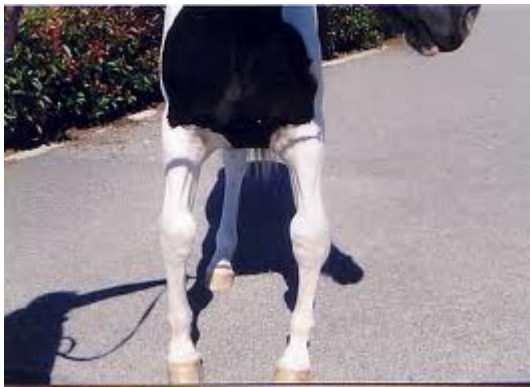In young animals, rapid growth and exuberant exercise can be enough to damage the physis. If the physis is evenly damaged, the limb is just shorter but straight. This is rare. Generally one side of the physis is affected more than the other. The leg then deviates toward the compressed side. However, ALDs can develop through several different pathways.

Angular limb deformities are changes in the frontal plane. Angular limb deformities (ALDs) are named according to the joint that is deviated and describe how the distal limb is moving compared to the proximal limb. (Stand at the shoulder or hock and look down to see what joint is deviating).

- Valgus = deviation to the lateral side
- Varus = deviation to the medial side



both forelimbs deviate at the carpus and move laterally = carpal valgus



This horse has bilateral carpal varus.

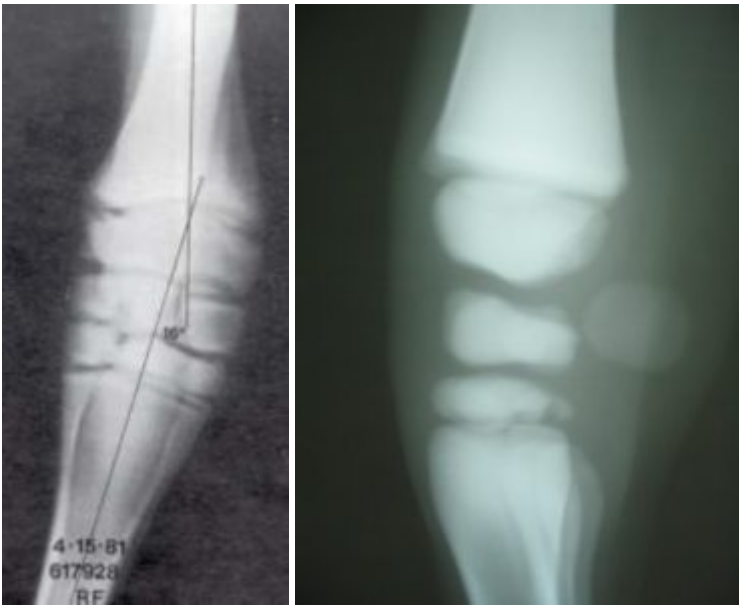
Windswept foals have both a valgus and varus deformity (blowing in the wind).

The most common versions are carpal valgus, tarsal valgus and fetlock varus. Mild carpal valgus can be protective; <5 degrees in a foal is considered normal. Varus is problematic and needs correction.

Many foals have external rotation of the forelimbs. The toes point outward. However, the limb is straight but is rotated from the shoulder. This will correct as the horse develops a broader chest. It is important to not diagnose or misdiagnose an ALD if the limb is rotated but straight. Line up with the foot and/or look down from the shoulder.

Not all ALDs come from a physeal abnormality. Other causes include ligamentous laxity and cuboidal bone abnormalities. Newborn foals can just have weak ligaments. These limbs can be straightened manually and you may be able to see changes as they move. These foals should not be lame. **Premature foals often have immature cuboidal bones (the carpal and tarsal bones are still mostly cartilage). Immature bones squash and then ossify in an abnormal shape.**

To determine the cause of the ALD, radiographs are taken using long plates. Draw a line down the middle of each long bone. Where they intersect is typically the cause of the problem (joint or physis). Radiographs also let you assess the cuboidal bone development.



Treatment

Different physes grow at different rates and for different times. If you are going to make significant progress, the physis still needs to be growing. Monitor the more distal joints closely as you have a smaller window to work in.

- Distal radial physis – most growth by 6 months; closes at 3.5 years.
- Distal tibia – most growth by 4 months; closes at 2 years
- Distal MC III/MTIII – most growth by 2 months; closes at 1.5 years

Medical management *requires active growth!*

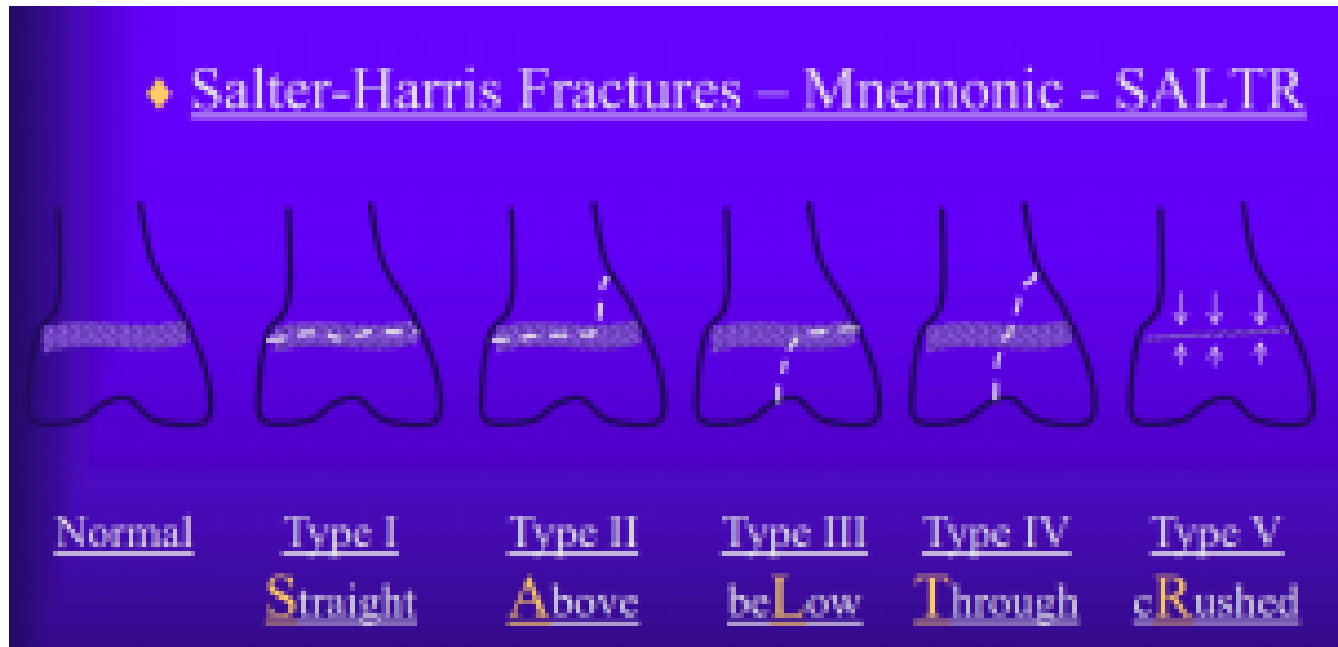
- control exercise
- adjust the load on the foot through trimming or hoof wall extensions
 - varus – trim medial aspect or add lateral extension
 - valgus – trim lateral aspect or add medial extension
 - trim to the side of the deformity or put extension on the opposite side
 - increase load on the affected side so increases bone growth
 - more effective for fetlock (whether you want it to be or not)

Surgery is needed if

- severe angulation (>15 degrees)
- not enough growth potential left
- foal is developing a secondary conformational abnormality (carpus valgus is developing a fetlock varus)
- economically important

Implants are put on the faster growing side to slow it's growth and let the other side "catch up". It is possible to overcorrect so implants need to be removed. Historically we performed periosteal stripping to stimulate the slower growing side. These may or may not have done anything (mother nature fixed them?) but overcorrection was not an issue.

Physeal fractures



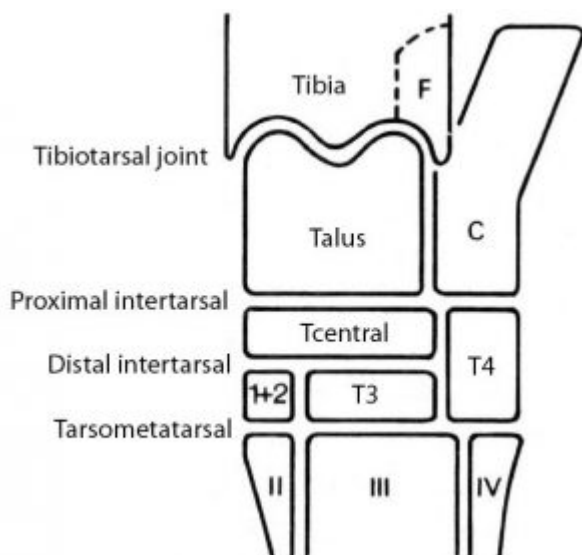
Hock joint problems

Older horses get arthritis; osteochondrosis is more likely to be diagnosed in a young horse.

Anatomy

The tarsal joint is really a collection of four joints, some of which communicate with each other but there are horse to horse differences. The sites of tarsal injection are:

1. Tarsocrural = tibiotarsal joint is where all movement occurs and has the joint capsule that is dilated in bog spavin. It always communicates with proximal intertarsal joint. Inject slightly distal to medial malleolus and more dorsal so the needle does not pass thru the medial collateral ligaments which come off the distal end of the medial maleolus. Needle should pass into the large joint space between the medial collateral ligament and the cranial branch of the medial saphenous vein.
2. Distal intertarsal joint is the most difficult due to narrow space and heavy covering with the medial collateral ligaments. An imaginary line is found between the distal (medial) tubercle of the talus and the groove between medial splint and the cannon bone. The injection point is on this line and just distal or thru the cunean tendon distal edge. The goal is to pass the needle tip into the intersection of Tc with T3 and T1+2.
3. Tarsal-Mt joint. On the lateral side pass the needle tip between T4 and edge of the head of lateral splint (Mt 4). In 10-40% of hocks this joint will communicate with the distal intertarsal so there is uncertainty of need for 2 vs. 3 joint blocks.



The tarsal joint has more complex ligaments than other joints. It has long and short collateral ligaments. **Long collateral** ligaments extend from the tibia to the metatarsus and are superficial to the short collateral ligaments. **Short collateral** ligaments extend from the tibia to the talus or calcaneus or both. Superficial, middle and deep short collateral ligaments have been described. Additionally there is a large **dorsal tarsal** ligament running from the distal (medial) tubercle of the talus to the cannon bone (Mt3), Tc and T3. The **long plantar** ligament runs from the plantar aspect of the calcaneus to the head of the lateral splint bone

(Mt 4). It is torn in curb. Other ligaments bind together individual tarsal bones.

Bone spavin is arthritis of the distal hock joints (tarsometatarsal and distal intertarsal joints). These are low motion joints but are affected by normal wear and tear due to gliding, stopping, and turning. Most older horses that have been in any degree of work will have changes in these joints. Some younger horses may also have changes, despite not being in work. The changes in younger horses are suspected of being due to cartilage abnormalities (form of osteochondrosis).

Hock joint arthritis is common in many performance horses. Standardbreds (harness horses): while a rider will shift the center of gravity towards the forelimbs, a rider in a sulky (cart) will shift the center of gravity towards the hind limbs and thereby increase stress on the tarsal joints. Rodeo horses that turn quickly stress their tarsal joints with rotary motion under a load. Jumpers stress their tarsal joints when they rear up and then propel themselves with their hind limbs. Poor conformation as in “cow hocked” individuals is another contributing factor

Horses with bone spavin will have an abnormal gait with a low foot flight because tarsal flexion is painful. Upper limb flexion will make the lameness worse. Radiographic lesions include osteophytes (new bone at the edges of joints) which make the bone edges sharp or appear to have spikes, loss of joint definition (lack of a sharp line) due to cartilage loss and bone formation in the space, and mild remodeling of the bony shapes – the joint may look fuzzy.

Because these are low motion joints, treatment is aimed at fusing the joints so that motion (and therefore pain) no longer occur. This can be done by keeping the horse in work (and on analgesics); however, it may take some time for natural fusion to occur. The process can be speeded by injecting the lower joints with steroids, injecting them with a compound that destroys cartilage (monoiodoacetate or MIA), or by removing the cartilage with a drill while the horse is anesthetized. Prognosis is favorable as long as only the lower two joints are affected. Since the proximal intertarsal joint communicates with the high motion tibiotarsal joint, changes in that joint are more serious and can lead to arthritis in the tibiotarsal joint.

Relief of pain after anesthetic injection of the cunean bursa or distal intertarsal joints. The injection sites are as follows:

- Distal intertarsal – at T-shaped junction of Tc, T3 and T1+2
- Tarsometatarsal – at junction of T3, T4 and Mt3. Remember that the collateral ligaments cover over the joints and make injection difficult.

Osteochondrosis dissecans is a developmental disorder whereby pieces of cartilage +/- bone break off. Clinical signs include joint effusion with minimal lameness. Young horses just being put into work are most commonly affected. The predominant sites in the hock are the distal intermediate ridge of the tibia and the lateral trochlear ridge of the talus. The medial malleolus can also be affected. OCD is often a bilateral condition so both hocks should be radiographed. Fragments of bone may be apparent in the joint. Arthroscopic surgery may be necessary to find cartilage fragments and is the treatment of choice. Once the fragments are removed, horses with hock OCD have a very good prognosis for future performance.

Procedures

The most common procedures are hock joint injections for osteoarthritis and arthroscopy for osteochondrosis (the most common OC lesion is DIRT – distal intermediate ridge of the tibia).

Other procedures you might encounter

1. **splint bone removal** – the entire MTIV can be removed
2. **cunean tendinectomy** to reduce the pain of bone spavin, an osteoarthritis of the distal tarsus.
3. **arthrodesis** (fusion) of the distal tarsal joints to treat hock pain more aggressively.
4. removal of a portion of the **lateral digital extensor tendon** to treat stringhalt, a mysterious spastic condition affecting the hind limb.

The **cunean tendon** is the medial branch of the cranial tibial m. tendon. The cranial tibial m. lies on the cranial surface of the tibia where it is covered by the tendinous peroneus tertius m. On the dorsal side of the hock joint the cranial tibial tendon passes through the overlying peroneus (fibularis) tertius and gives off a medial branch and continues as the dorsal branch. The medial branch is the cunean tendon. It runs across the medial side of the distal part of the hock where it is cut to relieve pressure on the underlying bone. When cutting the cunean tendon one must be careful to not injure the cranial branch of the medial saphenous vein which crosses over the cunean tendon.

Attempt to palpate the cunean tendon as it obliquely crosses the distal tarsal joint. Make a small incision over the tendon and elevate the tendon with a curved hemostat and cut it.

Stringhalt is an exaggerated flexion of the tarsal joint. It is not a lameness but a gait defect. Cause may be a plant toxin in Australia but is unknown in the US. The treatment is tendonectomy of the lateral digital extensor tendon below the hock followed by tendon exposure and removal above the hock.

On the lateral side of the upper cannon bone palpate the **lateral digital extensor tendon** and the more dorsal long digital extensor tendon which is larger. Make an incision over the lateral digital extensor tendon and elevate it with a curved hemostat. Then find the tendon above the tarsus and expose it with a second incision. Elevate the lateral digital extensor tendon in the upper incision and note that it is larger above the tarsus due to closeness to the muscle belly. Cut the tendon distally and then hold the limb firmly and pull the tendon out of the tendon sheath by traction on the upper part of the tendon. Two people should hold the limb firm on the table while another pulls on the tendon. On a live animal the operation is done on a standing horse and the weight of the horse stabilizes the joint while the tendon is pulled out.

The **dorsal metatarsal artery** passes under the lateral digital extensor tendon and care must be taken to not injure it. Before you finish make a cut down to find this artery which is used during to sample arterial blood for blood gas concentrations.

Carpal joint problems

The main problem affecting the carpus (besides sepsis) is trauma and arthritis. Racing horses, in particular, are at significant risk of developing chips or slab fractures. The most common sites for chips include the distal dorsomedial aspect of the radial carpal bone, the proximal dorsomedial aspect of C3, and the distal radius. Slab fractures (front of bone fractured off) are also found on C3 and may be preceded by sclerosis (increased bone) of C3 and/or lysis of C3. Lesions are often bilateral. Radiographs will show small spicules of bone at the joint margins or sharp corners to the bones. The flexed lateral view is useful for determining whether the intermediate carpal bone or radial carpal bone is affected since “radial drops” and “I goes high”. Treatment includes removing any chips and treating the joints for any cartilage damage.

Joint therapy

Treatment depends on

- intended use of animal- how much performance is required?
- age of animal- proven, not proven, remaining work
- size matters – eg you can amputate a limb on a mini, not an adult horse
- disposition matters – what will they let you do?
- economics matter
- owner abilities and compliance- often need follow up

Treatment options

1. Rest – Rest relieves inflammation. But what do you mean by rest? Stall rest can be challenging. Owners don't always understand.
2. Surgery – need to create biomechanical stability first. Without that, medications won't help
3. Rehabilitation/ physical therapy
 - hydrotherapy
 - ice
 - swimming
 - acupuncture
 - chiropractic
 - laser therapy
 - electrical stimulation
 - therapeutic ultrasound
 - counterirritants
 - radiation
 - shockwave
 - massage
 - heat
4. Nutrition
 - balanced diet

- supplement if needed
- weight control
- fatty acids to modulate inflammation

5. Drugs

- Nonsteroidal anti-inflammatory agents
 - phenylbutazone
 - firocoxib
 - can alter matrix
- Intra-articular steroids
 - methylprednisolone – may have more joint damage effects (or not), longer acting
 - triamcinolone – used more often in high motion joints, shorter acting
- Hyaluronan
 - anti-inflammatory
 - intra-articular actions as boundary lubricant (molecular weight matters)
- Adequan
 - PSGAG – stimulates HA secretion and acts as substrate for MMPS and aggrecanases so don't go after endogenous PSGAGs
- Tetracyclines
 - inhibitors of MMPs
- IRAP
 - competes with IL1 receptors – so less inflammation
 - don't know how long it stays bound
- Neutraceuticals
 - drugs, diet supplements, phytochemicals, etc
 - Not regulated by the FDA

6. Trimming and shoeing

- protection
- balance

Practice

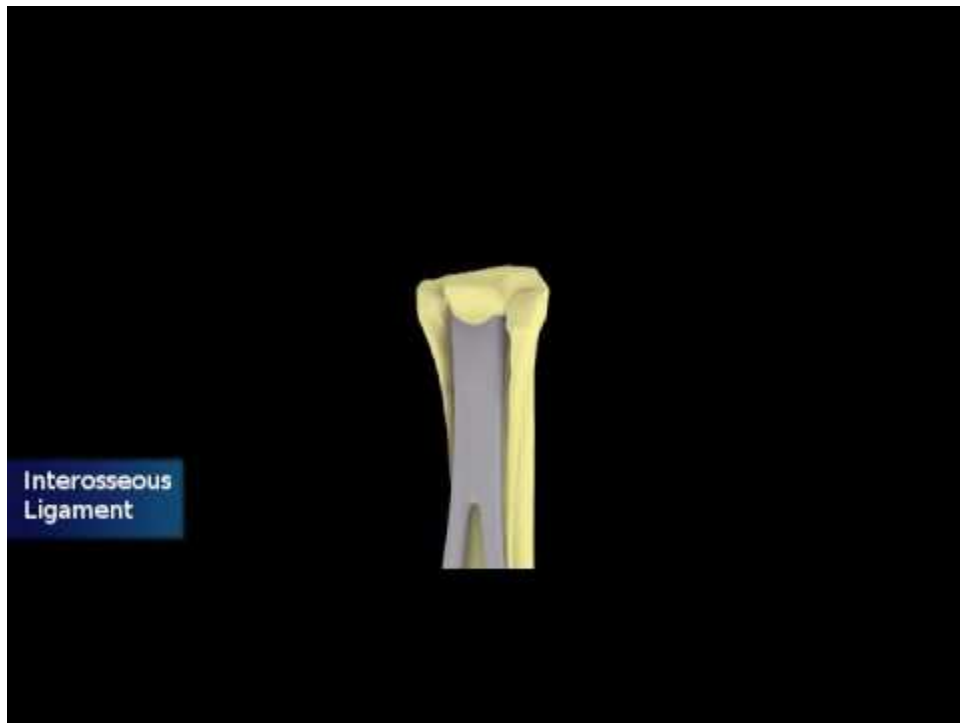


An interactive or media element has been excluded from this version of the text. You can view it online here:
<https://open.lib.umn.edu/largeanimalsurgery/?p=2453>

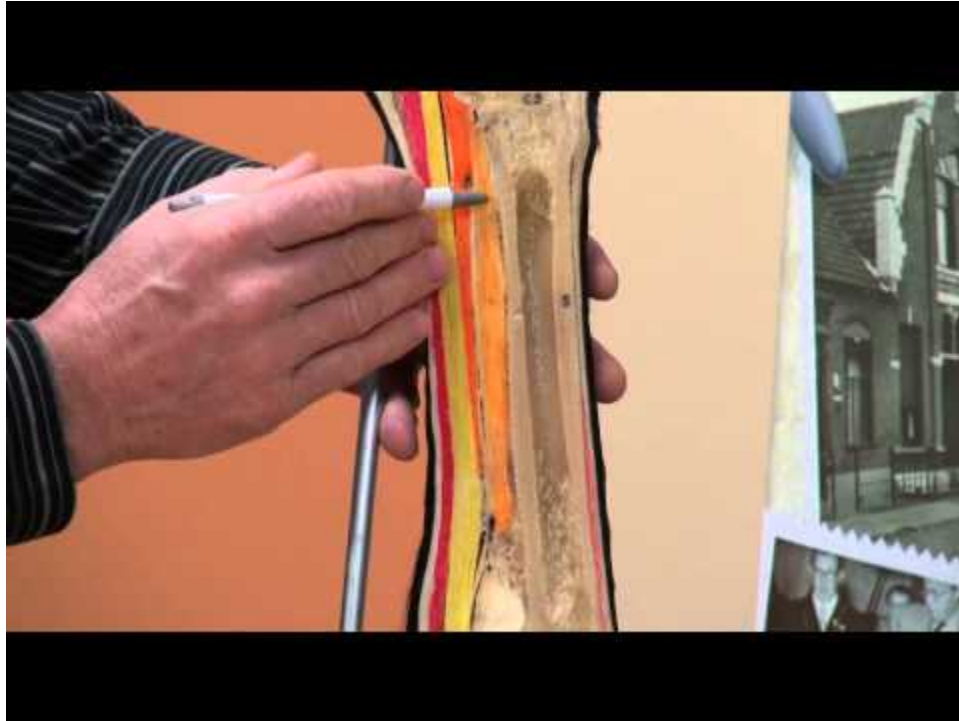Tendons and ligaments

Tendon and ligament disorders

Tendon and ligament anatomy



A YouTube element has been excluded from this version of the text. You can view it online here: <https://open.lib.umn.edu/largeanimalsurgery/?p=1644>



A YouTube element has been excluded from this version of the text. You can view it online here: <https://open.lib.umn.edu/largeanimalsurgery/?p=1644>

Tendon Notes Vic Cox

1. **Insertions:**

Superficial digital flexor tendon (SDFT) -> proximal on short pastern (P2).

Deep digital flexor tendon (DDFT) -> sole surface of coffin bone = P3

The DDFT will flex the entire digit and the fetlock joint

The SDFT will flex the fetlock and the pastern (PIP) joint but not the coffin (DIP) joint

2. **Downward translation of the fetlock** is prevented by 3 parallel tendons

- suspensory lig. (interosseous tendon) + distal sesamoidean ligaments = suspensory apparatus
- DDFT and its check ligament
- SDFT and its check ligament

But remember that only the suspensory ligament attaches to the sesamoid bones while the flexor tendons slide over them, so the suspensory lig. is the main structure supporting the fetlock. Excessive stretching of these tendons -> inflammation = swelling = bowed tendon. Excessive downward movement of the fetlock

(overextension) can cause chip fracture of the proximal dorsal edge of P1 due to being rammed against the distal end of the cannon bone.

3. **Check ligaments** act to check (prevent) downward translation of the fetlock:

- proximal = ligamentous radial head of SDF, from medial edge of distal radius
- distal check = accessory ligament of DDFT, a continuation of the palmar carpal ligament.

The distal check ligament is the one most often discussed, hence when just referred to as the check ligament the distal check is what is being referred to. The hind limb lacks significant check ligaments.

4. **Distal (inferior) check ligament is cut** (check ligament desmotomy) for:

- flexor deformity (contracted tendons) in foals (most common)
- early laminitis case to prevent rotation of P3 (uncommon), DDFT cut more commonly
- to reduce navicular pressure and hence pain (even more uncommon)

5. **The suspensory ligament mainly attaches** on the abaxial parts of the sesamoid bones and will pull up on them. Therefore, the distal sesamoidean ligaments are needed to pull “down” (distal) on the sesamoid bones. The 2 main distal sesamoidean ligaments are:

- straight = superficial ->short pastern bone (P2) proximal end between insertions of SDFT
- oblique = middle ->triangular area on palmar surface of long pastern bone (P1)

The sesamoid bones are bound to the distal end of the cannon bone by collateral sesamoidean ligaments.

6. **Sesamoid fractures** are caused by the upward and downward pull on the sesamoid bones may cause them to fracture (fx) as in a “tug of war”. Sesamoid fx can be basal, apical or sagittal.

7. A fibrocartilagenous **intersesamoidean ligament** binds the sesamoid bones together so that the proximal sesamoids form a groove for the flexor tendons. The flexor tendons are held in this groove by the **palmar annular ligament**.

8. At the fetlock the **SDFT** forms a thin sleeve (manica flexorum) around the DDFT. Mainly the SDFT is superficial to the DDFT above the fetlock but distally it inserts on P2 abaxial to the DDFT.

9. The flexor tendons also have **synovial** tendon sheaths (paratendon) that surround them in the fetlock and digital region.

10. In the digital region the flexor tendons are bound down by **proximal** and **distal digital annular ligaments**. The distal digital annular ligament is beyond the SDFT and therefore only covers the DDFT.

11. Tendons have **elastic properties** and can stretch to a certain degree but over stretching will cause damage. Stretching and rebound is a way of storing energy and then releasing it for propulsion. Transducers implanted on tendons of live horses indicate that the degree of elongation is 3% at the walk, 6-8% at the trot, and 12-16% at the gallop. Laboratory testing of isolated tendons indicates that they will rupture in the 12-16% elongation range

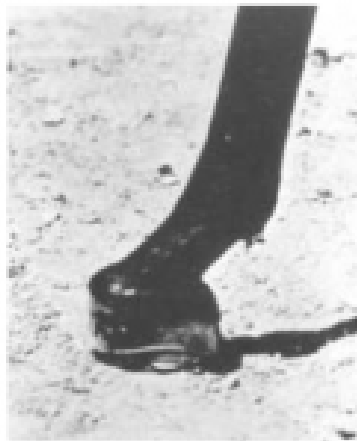indicating that the galloping horse is in the danger region but the duration of elongation during locomotion is less than a second which is much less than the time for laboratory strain testing.

12. The tendons most often **damaged** in performance horses are the superficial digital flexor (SDFT) and the suspensory ligament (SL) which is the same as the interosseous tendon. In contrast, the deep digital flexor tendon (DDFT) has a lower incidence of damage. Swelling of the SDFT results in a curvature of the flexor tendons in the cannon region. This swelling is referred to as a **bowed tendon** because the palmar surface of the tendon “bows” out. SL (interosseous tendon) damage is less obvious but lesions in both sites are best evaluated with ultrasound.

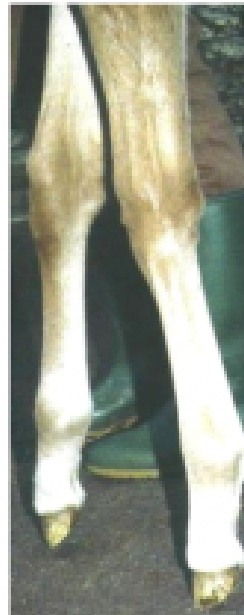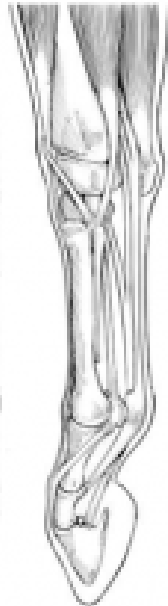
13. Tendons consist of regularly arranged fiber bundles that consist of living cells and an extracellular collagen matrix produced by the cells. The collagen fibers, not the cells, are responsible for the strength and elasticity of the tendon. The collagen fibers have a natural **wave or crimp** that allows them to stretch as the crimp is straightened out. Flattening of the crimp is not a problem but beyond that other changes due to elongation can be harmful. Mechanical stress that causes cellular or vascular damage will lead to inflammation.

14. Cyclical loading (stretching) and unloading of digital tendons results in recovery of about 90% of the energy that is put into the tendon to stretch it. As mentioned above, this is a process of storing and release of energy. The part of this energy that is lost (10%) is dissipated as heat in the tendon. When **heat** builds up in the tendon faster than it can be removed by radiation and blood circulation, the increase in heat can cause damage to the tendon. Therefore, heat, as well as mechanical strain can lead to tendon injury. During 7-10 minutes of galloping the core temperature of the SDFT can rise to 45-47 degrees Centigrade. This heat would kill fibroblast cells of dermis, but those of tendon are thermal resistant but, in some cases, their limit is exceeded. SDFT lesions often affect the core of the tendon more than the periphery suggesting that heat damage is a factor in the pathogenesis.

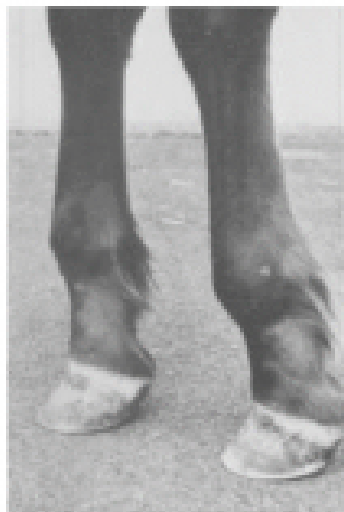Flexural limb deformities



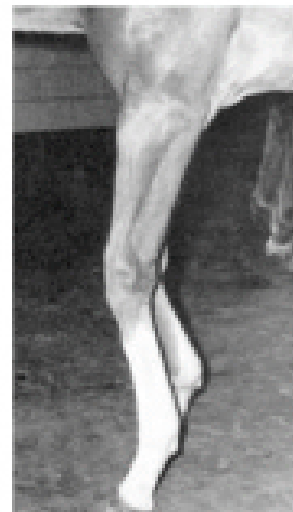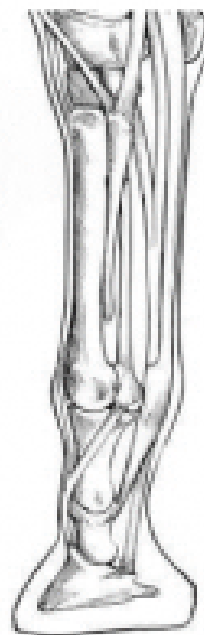
type 1 club foot



type 2 club foot



fetlock contracture



carpal contracture

These deformities may be either congenital or acquired. Congenital forms are discussed in the next chapter. Acquired deformities are believed to occur secondary to fast growth and high nutrition plane. Most occur in older foals and weanlings but can occur in 1-2 year olds. Prognosis depends on which joint is flexed (foot > fetlock > carpus) and how much contracture is present. If the foot is flexed so that the angle between P2 and P3 is > 90 degrees, these can be hard to fix.

Medical treatment of congenital forms:

Bandages or splints – these relax the tendons

Hoof trimming – if you relax the tendons but the heel is still too high, the angle stays the same; trim the heel at the same time so that it is possible for the heel to drop

Oxytetracycline – may also be given at the same time; by an unknown mechanism this leads to relaxation of the tendons; if you don't splint or bandage the leg, it will recontract afterwards

Exercise – may be enough in mildly affected foals; the exercise encourages normal function

Analgesics – they have to walk on these limbs to improve the conformation; if uncomfortable, they won't walk enough and further tendon contracture may occur (withdrawal reflex)

Surgical treatment of congenital forms

Club feet (contracture of deep digital flexor tendon; DIP joint flexion)

- The feet look like clubs because the heels grow toward the ground; this causes long heels and relatively short toes.
- DDFT is only tendon involved in most cases
- Cut the inferior (distal) check ligament to allow more stretch of the DDF tendon
- Excellent prognosis if not >90 degrees joint flexion

Fetlock flexural deformity

- Either the SDF (superficial digital flexor) or DDF or both may be involved
- Cut the proximal and distal check ligaments
- Poorer prognosis than club feet but should gain some improvement, especially in young foals

Carpal contracture

- No good surgical options although cutting the ulnaris lateralis and flexor carpi ulnaris muscles has been used occasionally
- Often the joint capsule is contracted

Treatment of acquired forms

- Include dietary management
- May be harder to correct (oxytetracycline doesn't work as well, surgery is less cosmetic in older horses)
- Pain may be a cause of contracture (withdrawal reflex). Check for hoof abscesses and fractures of P3 if the contracture is acquired. If you don't eliminate the source of pain, surgery won't help.
- Postoperative care : foot trimming, bandaging, controlled exercise.

Flexural deformity pathogenesis

The pathogenesis of flexural deformities (contracted tendons); Vic Cox

Flexural deformities are the most common congenital defect in foals. In a retrospective study of 608 cases of congenital defects in foals at the University of Kentucky, more than half were flexural deformities. When involving the coffin (DIP) joint, the condition is often referred to as club foot. In a nutshell, the most likely cause is failure to get enough “exercise” in utero. Developing bone (and to a lesser extent adult bone) is very plastic. The shape is determined by the pushes and pulls acting on bones (Wolf’s law). These forces are akin to the hands of an artist molding clay. Every mother knows from personal experience how often a fetus moves around and even “kicks” occasionally.

In the early 1950’s the embryologist Viktor Hamburger studied these movements using the convenient and inexpensive model system of developing chicks which can be observed thru a window in the egg shell. After thousands of observations he concluded that there was no pattern to the movements; they were totally random. This observation led him to hypothesize that these movements provided a wide variety of stress on bone. In contrast, if the forces on a bone were lopsided, the shape of the bone would be skewed in relation to the forces acting on it. Hamburger tested his hypothesis by applying the neuromuscular blocking agent curarie to chick “embryos”. This curtailed movement and when the chicks hatched they had widespread musculoskeletal deformities including joint ankylosis (fusion).

Contracted tendons are common in long legged species such as horses and cattle but uncommon with short legged species such as pigs or dogs. The incidence of tendon contracture is more common in oversized calves of double muscled breeds which presumably is due to insufficient intrauterine space to move. The very long legs of foals may be a predisposing factor as well.

Other factors that may reduce fetal movement are neurological deficits or delayed neurological development. Copper deficiency leads to swayback lambs. In the early 70’s three calves were born on a Missouri dairy farm with torticollis (wry neck) and were linked to earlier spraying with a chlorinated hydrocarbon insecticide, a classic neurologic toxin. Fetal positioning occurs late in gestation when a fetus turns around if needed so that the forelimbs and head are ready to exit the uterus first. Failure to do so results in breech birth and may be due to the same factors involved in contracted tendons.

In short, intrauterine “exercise” is needed to stretch out developing tendons. A principle to be learned here is to consider possibilities beyond the obvious. That is, the obvious tendon defect may be due to a hidden neurologic deficit.

Recent work in Minnesota indicates that mare hypothyroidism may be a factor also.

Crowe MW and Swerczek TW, 1985, Equine congenital defects. *AJVR* **46**,353-358.

Tendonitis and bowed tendons

Tendinitis / Bowed tendons

Tendinitis is a common debilitating injury seen in all types of performance horses. A 'bowed tendon' typically carries a guarded prognosis for return to a high level of athletic performance. The rate of recurrence is considered to be high.

The most common site for tendon injury in Thoroughbreds is the superficial digital flexor tendon (SDFT) in the mid-metacarpal region. This region has the smallest cross-sectional area and may be stressed to a greater extent at this point. The deep digital flexor tendon (DDFT) is most often affected near the insertion of the distal check ligament or within the tendon sheath adjacent to or below the fetlock. Clinical tendon injuries are associated with heat, pain and swelling of the area. Lameness varies from mild to moderate and generally resolves in a few days. Ultrasound is very useful for evaluating tendon lesions and the healing process.

There is controversy on whether degenerative changes occur in the tendon and result in tendon weakening before full-blown tendon fiber disruption or whether tendon injuries occur as a result of a single overloading episode. Degeneration may be the result of anoxia (lack of oxygen), possibly due to inherent deficiency in blood supply, or constriction due to stretching during exercise. Others have found an increase in temperature in the core of the tendon. This rise in temperature may occur due to the inability of a deficient capillary system to remove generated heat efficiently. This hyperthermia, perhaps combined with mechanical stress, could cause cellular changes that may result in depolymerization of the collagen. This heat could also destroy or interfere with the cross-linking which is required for optimum tendon strength.

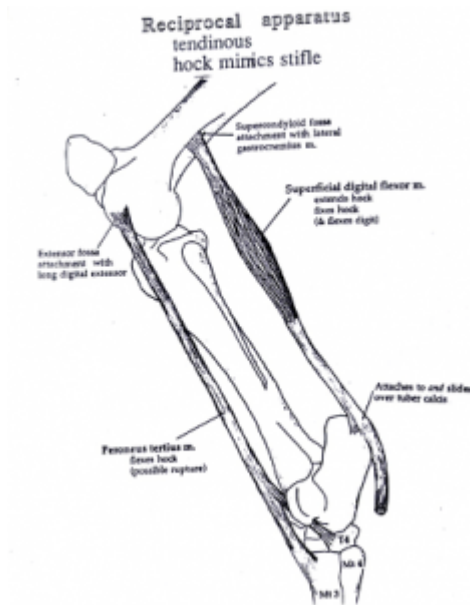
When tendon fibers are torn, capillary hemorrhage and inflammation result at the site of injury. Inflammatory products result in further damage. Healing of tendon injuries requires stopping the inflammation and then restructuring the tendon with normal collagen (type 1), with the fibers aligned along the long axis of the tendon and sufficiently cross-linked to provide strength. However, healing tends to occur by forming a knot of scar tissue : fibrous tissue (collagen type III) that is aligned in a variety of directions. Several treatment options may be used to prevent this type of scar tissue.

Medical treatment initially includes anti-inflammatory agents, cold therapy, and complete rest. Other agents may be given to increase blood supply to the area to speed healing (the rationale behind therapeutic ultrasound and the previous use of 'firing'). This is followed by techniques to minimize scar tissue and maximize collagen structure and alignment. Hyaluronic acid has been injected in the area in an attempt to prevent adhesions but has not been very effective. Polysulfonated glycosaminoglycan (PSGAGs) injections (IM) did help healing in experimental studies. Shockwave therapy is most likely useful at bone-tendon junctions and unlikely to be useful in the middle of a tendon (despite its widespread use). The latest "fad" (still to be proven) is injection of "A-cell" (manufactured from bladder mucosa) or bone marrow cells (stem cell therapy). Most protocols should be used in combination with controlled exercise to stimulate healing and realignment of fibers along the lines of stress.

Surgical treatment options include "tendon splitting". This is used to increase blood supply to the area. It is most

useful for core (central) lesions that aren't healing with medical treatment. If the tendon is swollen in the area of the fetlock, the palmar annular ligament may be cut to reduce pressure on the tendon. Finally, in one study, cutting the proximal check ligament aided in preventing recurrence of the bow, not by increasing strength of the repair but by increasing the elasticity of the entire tendon unit* (and led to more suspensory ligament damage). * Cutting the proximal check releases the pull of the inflexible ligament on the SDFT leaving only the more flexible SDF muscle belly to "pull" on the tendon.

Reciprocal apparatus



Practice



An interactive or media element has been excluded from this version of the text. You can view it online here:
<https://open.lib.umn.edu/largeanimalsurgery/?p=2310>



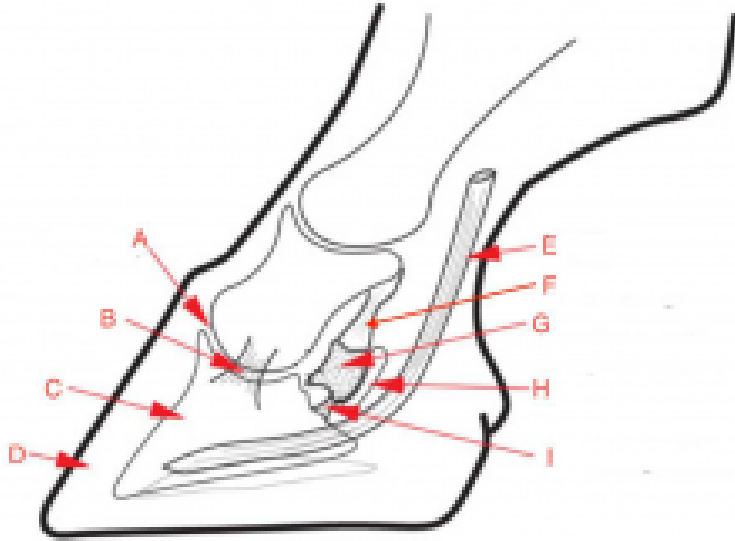
An interactive or media element has been excluded from this version of the text. You can view it online here:
<https://open.lib.umn.edu/largeanimalsurgery/?p=2310>

The foot

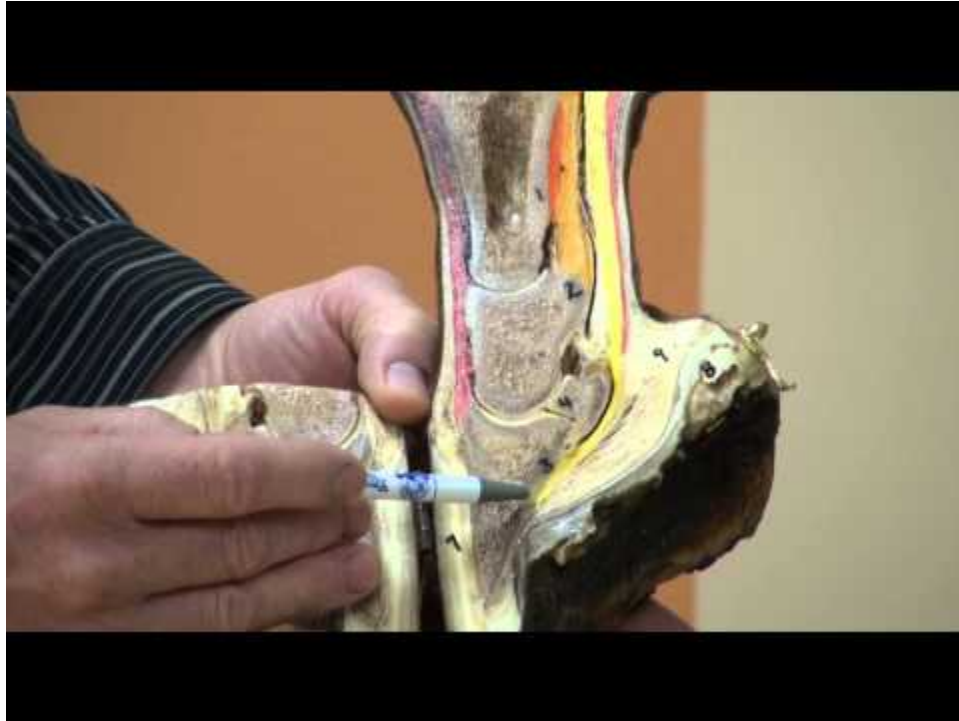Pathology in the distal limb is one of the most common etiologies of lameness and poor performance in horses

Problems in the distal limb or foot account for greater than 50% of forelimb lameness cases

Foot anatomy



A – coffin joint. B -lateral collateral ligament of the coffin joint. C -P3, pedal bone or coffin bone. D-hoof wall. E – deep digital flexor tendon. F- suspensory ligament of the navicular bone. G- navicular bone. H- navicular bursa. I- impar ligament.



A YouTube element has been excluded from this version of the text. You can view it online here: <https://open.lib.umn.edu/largeanimalsurgery/?p=1674>

Supplemental foot notes – Vic Cox

Famous quote “No Foot, No Horse”, Jeremiah Bridges, 1752, in an essay so entitled.

Definitions

The equine foot = the hoof and its contents. The problem with this definition is that if strictly interpreted, it would include only the distal parts of the collateral cartilages and P2.

Collateral cartilages are often referred to as the unguis cartilages but this is misleading because the cartilages are connected to P3 but not to the hoof (unguis = hoof). Instead, they are partially within the hoof.

Hoof balance = the object of proper trimming and shoeing. If the foot is in perfect balance a sagittal plane through the foot will not only produce symmetrical halves of the foot, but also, the digit and cannon region. Many authorities state that hoof imbalance is a common predisposing factor in lameness, especially of the foot.

Breakover = the point where the coffin (DIP) joint is flexed maximally and the foot lifts off the ground. The longer the toe, the longer the time on the ground before break over occurs. A long toe makes a smoother ride for the rider but can be harder on the horse. Toe vs. heel length is another aspect of hoof balance.

Podium = the foot, *Metapodium* = adjacent to the foot = metacarpus **or** metatarsus = cannon bone plus both splint bones.

Capsule or hoof capsule is another term for the hoof, farriers may use this term and they may refer to the collateral sulci as the *valleys* alongside the frog.

Foot structure

In theory, all the weight of the horse is borne by the hoof wall and hence the laminae. This is why laminitis (founder) is so painful. The frog and sole are soft and not made for weight bearing but will bear some weight on a soft surface, but not on a hard surface, especially if shod. This may be the reason why hard surfaces are cited as one of the causes of foot lameness. The sole is concave and may flatten some at the point of foot contact with the ground surface

600 = approximate number of laminae in a horse foot. Due to numerous secondary laminae, the surface area for connection of the laminar dermis to the hoof is large. Vessels of the laminar dermis have numerous arteriovenous anastomoses which are important in heat regulation and laminitis. Cattle lack secondary laminae and much of their weight is born by the bulbs which would be considered “under-run” if similar heels were on a horse.

Hoof growth is very slow. Therefore, the older part of the wall is, the dryer and hence harder it is. Since the toe is the longest part of the hoof, it is both thicker and less flexible than the heels. On impact the wall bends in slightly near the coronet, especially at the heels. Since the heels should remain flexible, horseshoe nails are only put in the toe and quarters, not the heels.

The collateral (ungual) cartilages are fibrocartilage and the digital cushion lies between them. The digital cushion is a mixture of collagen, elastic tissue, adipose tissue and cartilage. According to Dr. Robert Bowker at MSU, there are 2 extremes here and everything in between.

1. Thin unguis cartilage (UC) and little fibrocartilage in the digital cushion. (Vulnerable foot.)
2. Thick UC and considerable fibrocartilage and collagen in the digital cushion. (Healthy foot.)

The navicular bone acts as a trochlea (pulley) around which the DDFT bends before inserting on P3. Hence the navicular bursa = podotrochlear bursa. Structural components of the navicular syndrome (podotrochleitis) are difficult to identify due to inconsistent findings from one case to another. That is, structural changes such as seen with radiology don't consistently correlate with clinical signs of navicular pain.

The clinical term navicular is often interchanged with the anatomic term distal sesamoid as in DSI = distal sesamoidean impar ligament which attaches the distal edge of the navicular bone to the coffin bone deep to the insertion of the DDFT

While there is but one impar (unpaired) ligament, the proximal (suspensory) ligaments of the distal sesamoid bone are paired. They wrap about the pastern joint and attach to the distal end of the long pastern bone (P1).

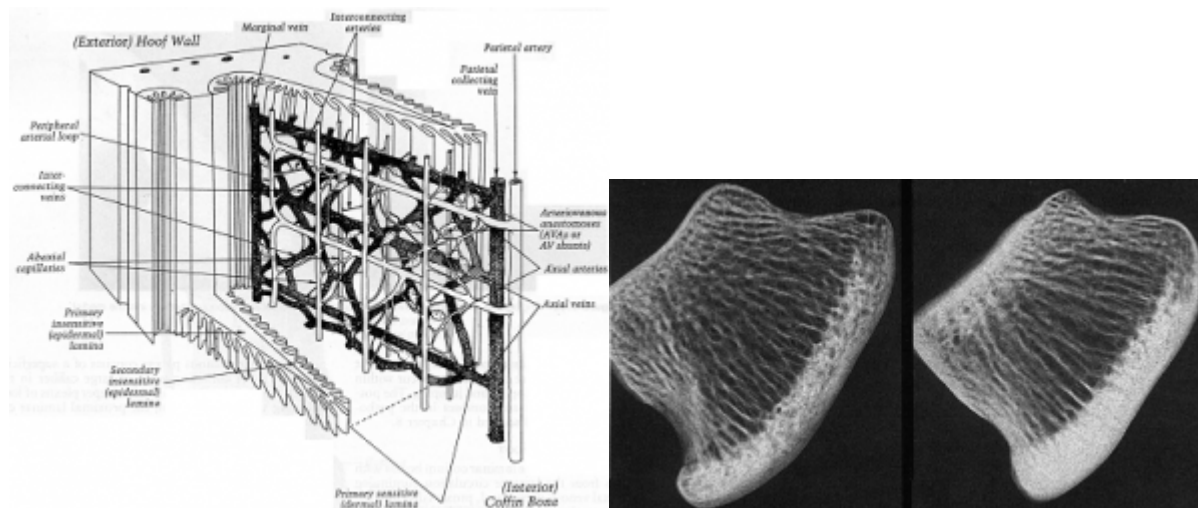
The flexor cortex of the navicular bone is strengthened to withstand the constant pressure of the DDFT on it (although separated from it by the navicular bursa which lubricates the fibrocartilage of the flexor surface. On the next page, note sections of the navicular bone showing differences in the radiodensity of the flexor cortex of the navicular bone. Pre-training 2 year old on left, and similar horse after training on the right. The flexor cortex is on the right in both images.

The distal border of the navicular bone furnishes attachment for the distal sesamoidean impar ligament. Dorsal

to this, the distal border is exposed to the coffin joint as can be seen in sagittally split feet. Since this border is frequently seen to have foramina on radiographs, the question has long been what is in the foramina. Traditionally the foramina were referred to as vascular foramina but now it is thought that they may be filled with extensions of the synovial membrane of the coffin joint. The following is the opinion of Bob Bowker, VMD, PhD at MSU, East Lansing, MI from e-mail to V. Cox, March 2000:

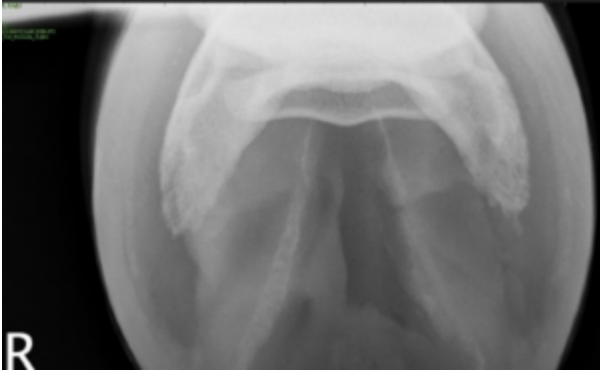
“The foraminae do contain blood vessels initially. But later I have not been able to see any. You made me think a bit as we have found that as the horses “age” (don’t think that it is related to age but rather that the stress in the region where the DDFT and the DSIL attaches onto P3 cause damage to microvessels.) I believe that with the reduction in the vasculature (others have shown in navicular horses that the blood flow changes from distal to proximal flow so that in navicular horses 75% enters proximally now versus 25% distally. (normal horse its just the reverse.) entering the distal edge of the navicular bone, there is bony remodeling within the navicular bone. Where the blood vessels are now absent there will be holes. Where they are there is no DSIL attaching to the navicular bone, which I think is the way it was before the fossae were formed. This can explain why there is a large hole on the flexor side of the bone in chronic cases (the overlap of the small arterial tree from the distal (75%) to proximal (25%) blood flow in normal horses shifts from a proximal (75%) to distal (25%) blood flow in navicular horses. I think that the synovial membrane merely is filling in the hole created by the new remodeled bone, i.e. hole. The answer is more gray than black and white.”

DDFT = deep digital flexor tendon, DSIL = distal sesamoidean impar ligament



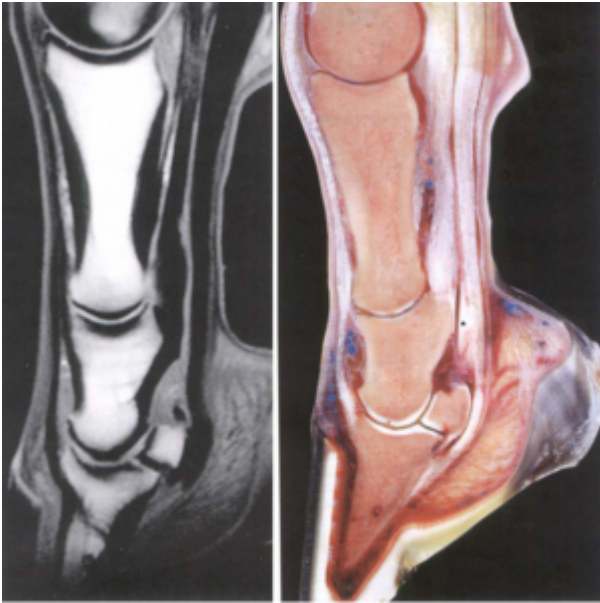
Foot anatomy and imaging

Normal navicular films



Imaging of the foot, Vic Cox

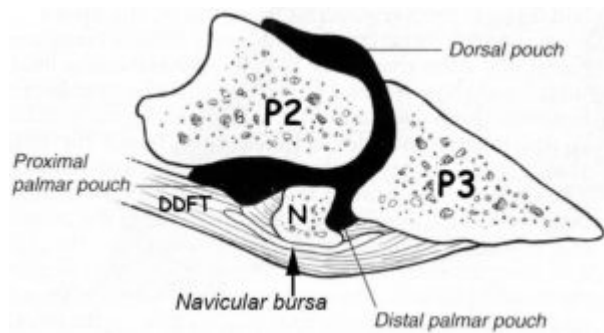
Study of 2D sections is essential for understanding CT and MR images. One weakness of conventional radiographs is that they are limited to full thickness images while CT and MR images can isolate a plane (slab) of tissue so that a small lesion is not obscured by larger structures in adjacent planes that are lumped together to form a full thickness image. Therefore, study of foot bandsaw sections is helpful for understanding CT and MR images. CT is best for mineralized tissues (like conventional radiographs) while MRI is best for soft tissue. MR images are brightest for tissues containing water or fat because MRI depends upon signals from the protons of hydrogen atoms and these are most commonly found in water and fat. For that reason, cortical bone will be dark while medullary bone will be bright (as seen below). Likewise, synovial fluid will be bright and inflammation (edema) will be brighter than normal tissue in MRI images



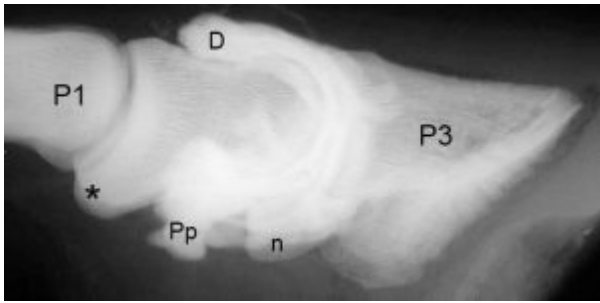
Note on P1 the bright medullary bone and dark cortical bone in MR image (left). Also note bright synovial fluid and dark articular cartilage. Likewise, the DDFT and straight distal sesamoidean ligament are dark. * = fibrocartilaginous part of DDFT on the right

We will study three types of sections:

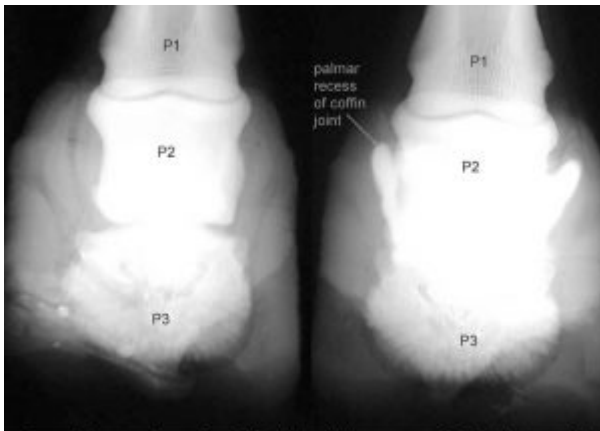
- Sagittal and parasagittal sections. A sagittal section will divide the foot into nearly symmetrical medial and lateral halves. Only one sagittal section is possible but any parallel plane is a parasagittal section.
- Transverse sections are perpendicular to the long axis of the distal limb
- Frontal (dorsal sections) are perpendicular to both sagittal and transverse planes.



. Schematic drawing of a sagittal section showing DIP (distal interphalangeal joint) with three distended pouches resulting from injection of fluid. Not labeled is the thin distal sesamoidean impar (unpaired) ligament that binds the navicular bone to P3. Because the DDFT curves around the navicular bone this bone acts as a trochlea (pulley). Therefore, the navicular bone and associated ligaments are referred to as the podotrochlea apparatus and the bursa is the podotrochlea bursa. Podo- refers to the foot and podiatry is study of the foot and disorders of it.

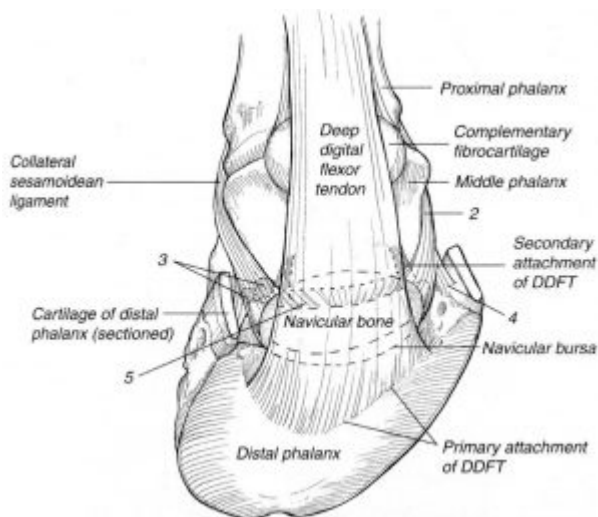


Contrast radiograph of the DIP joint, the dorsal and proximal palmar pouches are clear but the smaller distopalmar pouch is obscured because radiographs, unlike sections, are full thickness images. The asterisk marks the flexor tubercle of P2 where the SDFT and straight sesamoidean ligament attach

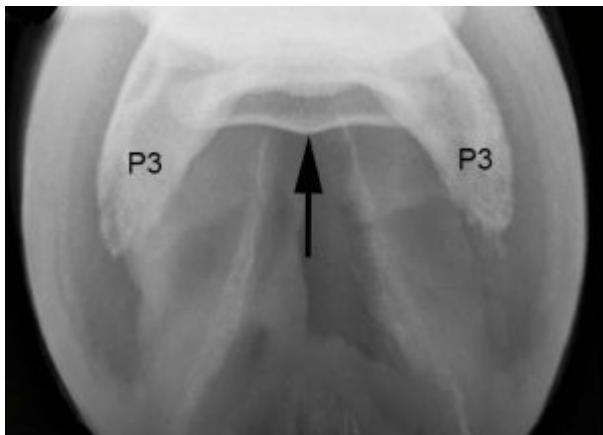

DorsoPalmar views of coffin joint. Arthrogram of DIP joint on right.

Contrast injection of coffin = DIP (distal interphalangeal) joint. The impar (unpaired) ligament attaches to the distal edge of the navicular bone while the paired collateral sesamoidean ligament attaches to the proximal edge of the navicular bone. It is a collateral ligament because there are medial and lateral parts that wrap around the pastern bones and attach to the distal part of P1 and also to the "sides" of P2. The collateral sesamoidean ligament (see Fig. 5 below) is also known as the suspensory ligament of the navicular bone. It counteracts the distal end of P2 which pushes down on the navicular bone when the foot makes contact with the ground



Drawing of digital bones, the collateral sesamoidean ligament is bilateral and attaches to both P1 and P2 (2) and the collateral cartilage (4). 3 = parts of proximal palmar recess of DIP joint. 5 = origin of the collateral sesamoidean ligament from the proximal edge of the navicular bone. Note that as the DDFT passes distally it gets wider but thinner. The wide thin part is prone to tearing, but the lesion is difficult to see because the DDFT is dark on MRI although tearing may result in enough inflammation or granulation tissue to suggest the injury. Proximal to the navicular bone the DDFT is thicker and has a fibrocartilaginous part (asterisk in fig. 1 on right) but best seen on transverse sections. In the region of the navicular bone the DDFT is divided by a groove into medial and lateral parts..



. Dorsosolar radiograph of the navicular bone showing the axial ridge (arrow) on the flexor surface of the navicular bone. The palmar parts of P3 are sometimes referred to as the “wings” of the coffin bone. This radiograph reveals good differentiation between the cortical and medullary parts of the navicular bone. Note that the navicular bone is deep to the apex of the frog. Also note that the wall is more radiodense than the sole and the frog looks like the letter “A”.

Subsolar (hoof) abscesses



A YouTube element has been excluded from this version of the text. You can view it online here: <https://open.lib.umn.edu/largeanimalsurgery/?p=1793>

Dr. F Tóth notes

Signalment

Common across all ages, sexes and breeds

Etiology

May be unidentified. May be a penetrating wound (including horseshoe nail) or deep bruise

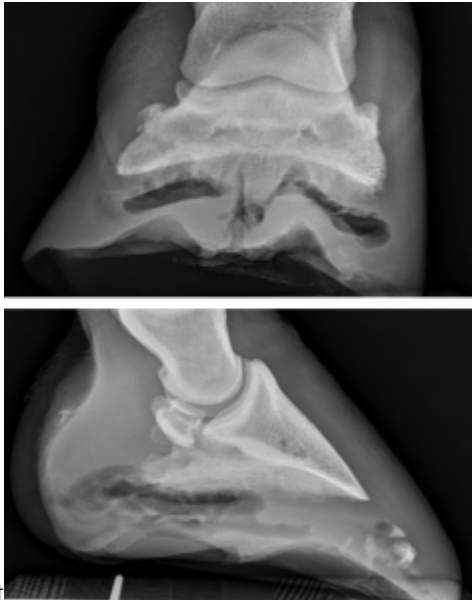
Clinical signs

1. Sudden, severe lameness
 - Varies from barely perceptible to non-weight-bearing
 - Owner may believe horse has fractured its limb
2. Bounding digital pulse

3. Affected foot is warmer than contralateral foot
4. Distal portion of limb, esp. pastern, is often swollen
5. Draining tract at the coronary band – “gravel”

Diagnosis

1. Hoof tester examination – sore on hoof testers, may squeeze out black goo
2. Hoof exam – look for a black spot that doesn't belong. If not seeing a spot:
 - Lightly pare sole and/or
 - Poultice foot
 - Warm foot baths w/ Epsom salt (softens horn, making paring easier)
3. Responds at least partially to local nerve block
4. Radiographs – may see gas within the hoof; rule out fractures and laminitis; identify bone



involvement

Treatment

- The goal is to open the abscess for drainage
 - usually done standing with or without local block
 - open tract just enough to establish drainage – minimize effects of hoof structure
 - discontinue debridement if blood or pink tissue encountered
- Tetanus prophylaxis
- bandage to minimize contamination
 - shoe with hospital plate if large defect
- Soak foot in warm Epsom salt solution to facilitate drainage

- Do not routinely need antibiotics or anti-inflammatory agents
- If distal phalanx is involved (osteitis), then bone must be curetted
 - Requires anesthesia and application of a tourniquet
 - Most easily done through a trephine hole through the hoof wall
 - +/- regional limb perfusion with antibiotics

Prognosis

- Excellent for uncomplicated solar abscesses
- Guarded to poor if synovial structures or the pedal bone is involved

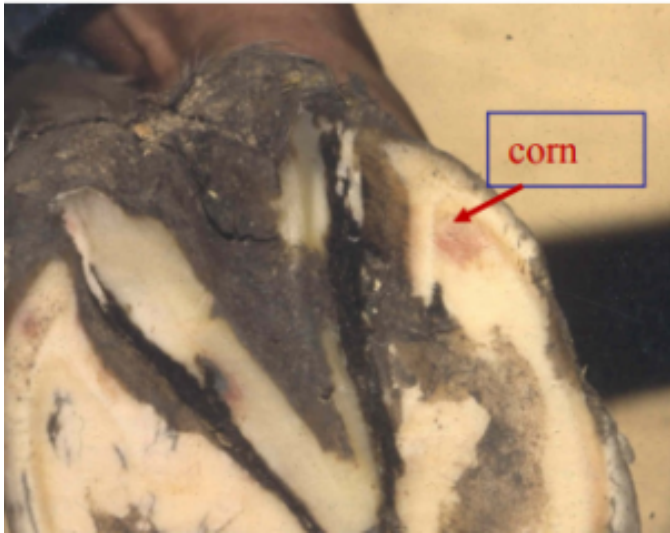Solar bruising

Dr. F Tóth notes

Definition

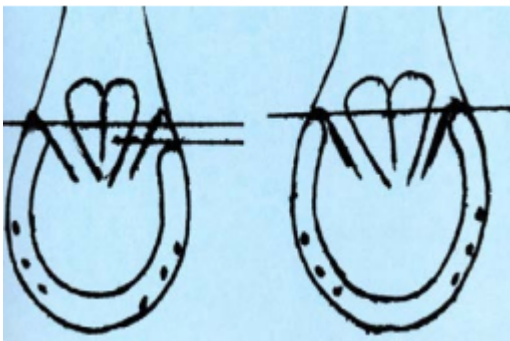
Solar bruising : Contusion caused by impact – results in hemorrhage of the solar corium. Often a “corn”

Corn : solar bruising located in the medial angle of the sole

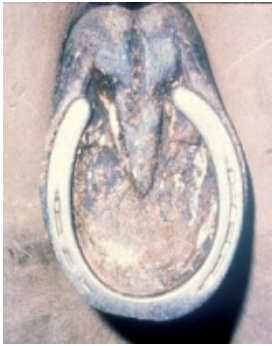

Etiology

- Shoe that is too small or does not extend far enough back under heels
- Long-toe/low-heel conformation (toe-bruising as horse tends to land on toe)
- Flat and/or thin-soled feet
- Riding on a hard or rocky ground
- Foot that has overgrown its shoe- shoe rides on sole



shoe does not extend far enough back



shoe is too small

Clinical signs

- Lameness varies from acute and severe to chronic mild or intermittent
 - Often affects several feet
- May resemble laminitis if both fore feet are affected
- Removing the shoe may increase lameness
- Increased digital pulses
- Painful response to application of hoof testers

Diagnosis

- Discoloration of sole
 - May be difficult to identify if bruise is deep or if foot is pigmented
- Should be able to alleviate lameness with palmar digital nerve anesthesia

Treatment

- Phenylbutazone
- Eliminate shoeing problems
- Apply caustic agent to toughen sole, such as:
 - Iodine, formalin, & phenol (i.e., sole paint)
- Application of a [wide-web shoe](#)

Resources

[Remedial shoes](#) – Horse and Hound

Thrush



A YouTube element has been excluded from this version of the text. You can view it online here: <https://open.lib.umn.edu/largeanimalsurgery/?p=1810>



A YouTube element has been excluded from this version of the text. You can view it online here: <https://open.lib.umn.edu/largeanimalsurgery/?p=1810>

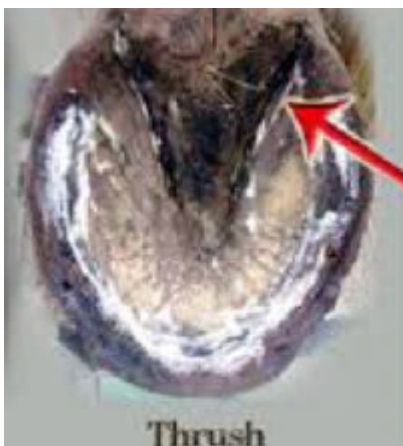Dr. F Tóth notes

Definition

Thrush -Degenerative condition of frog & surrounding tissues caused by infection w/ keratolytic organisms

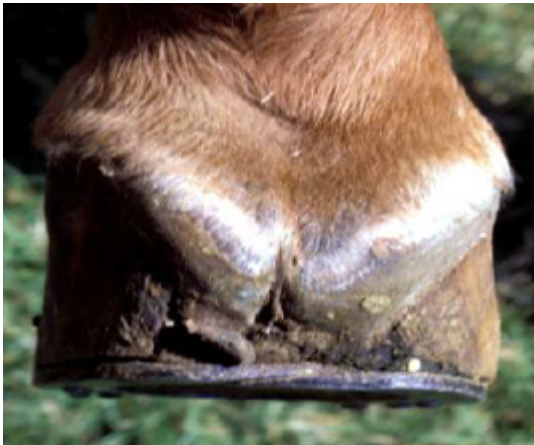- Fusobacterium necrophorum appears to be the most important
- May involve digital cushion and skin at the heel bulbs

Characterized by black, necrotic, foul-smelling material in central sulcus or collateral sulci of frog



Etiology

- Poor sanitation
- Persistent wet conditions
 - Sole pads keep the sole moist
 - Confinement
- Poor hoof conformation with deep sulci of the frog and sheared heels



Clinical signs

- Foul-smelling, black material in sulci of frog
- Sulci of frog, especially central sulcus, are deep (both a cause & a result)
- Frog may be atrophied
- Lameness, if sensitive tissues are involved

Treatment

- Clean feet daily
- Remove necrotic tissue
- Apply drying agent to foot

Drying agents
Formalin

Tincture of iodine
Tincture of iodine & formalin
Tincture of iodine, formalin, & phenol (Sole paint)
New methylene blue
2% benzoyl peroxide

- Foot soaks in chlorine bleach [30 mL (1 oz) of bleach in 5L water]
- Miconazole (Lotrimin) plus neomycin (50/50 mixture)
- May need to temporarily protect foot with a bandage
- Improve foot conformation, if indicated
- Improve sanitation

Prognosis

Good for full recovery

Laminitis

Definition: inflammation of the laminae that attach to the coffin bone and interdigitate with insensitive laminae of the hoof wall. Painful condition that results from disruption of the dermo-epidermal junction within the hoof

Sequelae: pain, rotation of P3, sinking of P3, chronic abnormal hoof growth (rings, dished foot), chronic infection due to damage to white line, recurrent episodes of laminitis

Etiology : about anything; most common following release of endotoxin — GI colic /diarrhea /enteritis, metritis/retained placenta, etc. May also see following exposure to excessive grain intake, black walnut shavings, excessive weight-bearing due to contralateral limb lameness, hormonal changes (PPID, equine metabolic syndrome), coagulopathies, etc.

The famous racehorse, Barbaro, developed laminitis of his sound hind foot due to shifting weight off his fractured hind limb. This “secondary” laminitis led to euthanasia.

Pathophysiology theories : poor blood flow, vascular thrombosis, vascular leakage -> compartment syndrome, abnormal keratinization

Signalment

Laminitis is a disease of adult horses. Foals do not usually put enough weight on the foot to cause laminitis. May be more common in older horses, particularly associated with PPID.

Ponies are also more commonly affected by chronic laminitis, likely related to their propensity towards equine metabolic syndrome and insulin resistance.

Clinical signs

Acute: increased heat near coronet, pounding digital pulses, sensitive to hoof testers around wall, reluctant to stand on that foot (have the other foot picked up), increased heart rate and signs of pain. Saw horse stance due to bilateral forelimb involvement – trying to unload front limbs. May see incessant weight shifting in the stall. “Walking on eggshells.”

Chronic: dished foot, founder rings (rings around hoof wall), widening of the white line on the solar surface, changes in position of P3 on radiographs, broken forward hoof-pastern axis, chronic pain, chronic abscessation. May present as recurrent forelimb lameness.

Diagnostics

- Sensitive to hoof testers at the toe
- Should improve with palmar digital or basisesamoid nerve block
- Radiographic changes

Radiographs

- changes in angle between hoof wall and dorsal surface of P3 (rotation)
- changes in distance between dorsal hoof wall and dorsal surface P3 and for flattening of ledge at top of coronet (sinking)
- gas around P3 (infection)

Treatment

prevention if at risk : ice, support, mineral oi/charcoal through nasogastric tube, NSAIDs, antiendotoxin treatment – pentoxifyline, polymyxin B, deep/sand bedding

acute : analgesics, antithrombotic agents (heparin, aspirin, platelet mediators), get rid of toxins (mineral oil if GI, fluids, banamine, polymyxin B, etc), restrict ambulation, support P3 (lily pads, styrofoam, wedge heels), vasodilators (acepromazine)

chronic : keep infections drained, support P3 (heartbar shoes, reverse shoes), encourage blood flow (dorsal hoof wall resection), corrective trimming to realign hoof wall and P3, DDF tenotomy (realign P3 in hoof), prevent exposure to agents likely to make founder recur, keep toe short/rockered

Prognosis

Prognosis is based on clinical signs and amount of sinking (+/- amount of rotation if severe). Sinking is bad.

If you can't pick up other foot, the horse needs continued large amounts of bute (phenylbutazone), or if you can't get rid of inciting cause, the prognosis is poor.

Laminitis cases

Case A: A 10 year old TB mare gets out of her stall and gets into the feed room.

Case B: A 4 year old show horse has had a bad abscess on his left front. That is getting better but now he is getting sore on his right front.

Case C: A 12 year old pony founders with no obvious cause. His diet has not changed, he is kept on pasture but it is not rich grass (it is August), and he isn't even ridden much. In fact, his "kids" have grown so much that he is mostly retired.

Case D: A 3 year old Warmblood mare develops colitis after antibiotic therapy

Case E: A 15 year old Morgan gelding has not shed his winter coat (it is May) and has lost muscle mass. He turns up with laminitis acutely but radiographs show rotation and P3 remodeling so he must have foundered before.

Other foot conditions



A YouTube element has been excluded from this version of the text. You can view it online here: <https://open.lib.umn.edu/largeanimalsurgery/?p=1856>

Navicular syndrome

Navicular Syndrome

Definition: A chronic forelimb lameness associated with pain arising from the navicular apparatus, which is comprised of the distal sesamoid bone (navicular bone) and closely related structures

- Likely multiple different clinical conditions that cause pain in the navicular apparatus

Function of the navicular bone

- Acts as a fulcrum to decrease the work of the DDFT
- Fibrocartilage covered flexor surface provides gliding surface for DDFT
- DDFT exerts major compressive force on the distal 1/3rd of navicular bone
- Greatest during propulsion phase of the stride (increased with low heel/long toe)

Possible forms of navicular syndrome

Exercise : poor blood flow in response to exercise; pain due to anoxia

Navicular bone pain : increased interosseous pressure and pain

Navicular bursa/DDFT : damage to the bursa or distal deep flexor tendon leads to adhesions and scarring in the region; pain due to decreased mobility

Coffin bone/sole/caudal hoof: other palmar heel structures that can be painful; includes P3 fractures, sole bruises, other soft tissues

Ligamentous injuries : strain/sprain of impar ligament, collateral ligaments of coffin joint, suspensory ligaments of navicular bone

Coffin joint pain: arthritis or synovitis leading to pain on movement

Pathological changes

Erosions of fibrocartilage of flexor surface of the navicular bone underlying the DDFT

- Often the 1st change to occur
- Often at median (sagittal) ridge

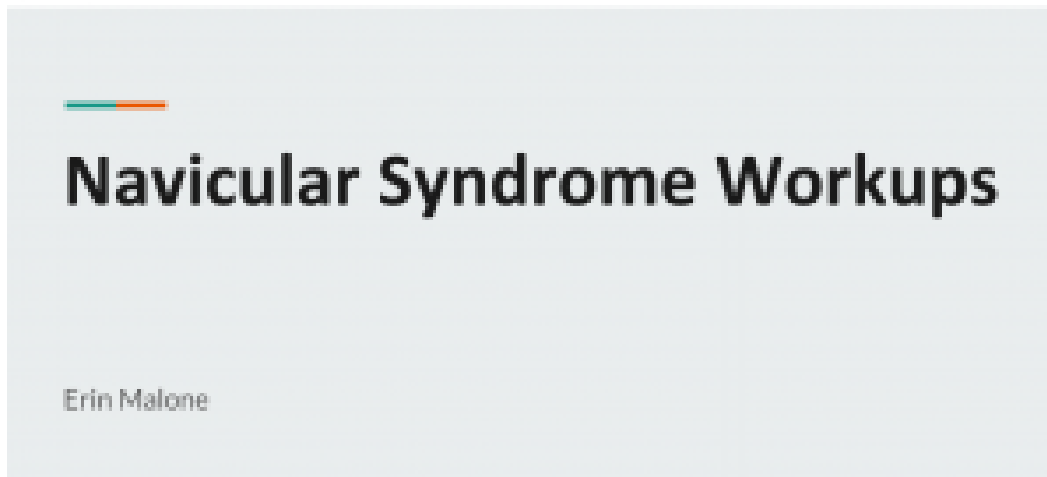
Degenerative change of the spongiosa

Chip fracture of the distal border of the navicular bone

Adhesions between the flexor surface and DDFT

Navicular bursitis (rarely seen alone)

Navicular Work up Cheat Sheet: an oversimplified explanation of tests

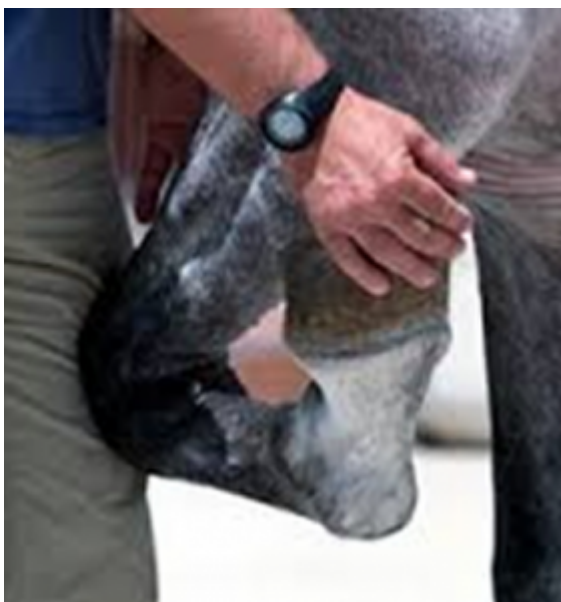

Lameness examination : straight line + lunging : often these horses are bilaterally lame and it is hard to see much lameness on a straight line because both feet hurt. Lunging makes the inside leg work harder and usually worsens the lameness on that leg. Be sure to watch for lameness on the other leg, as well.

Hoof testers : Look for pain along the white line and from the frog to each wall and across the frog. Remember the navicular bone is deep to the frog apex (see page 39).

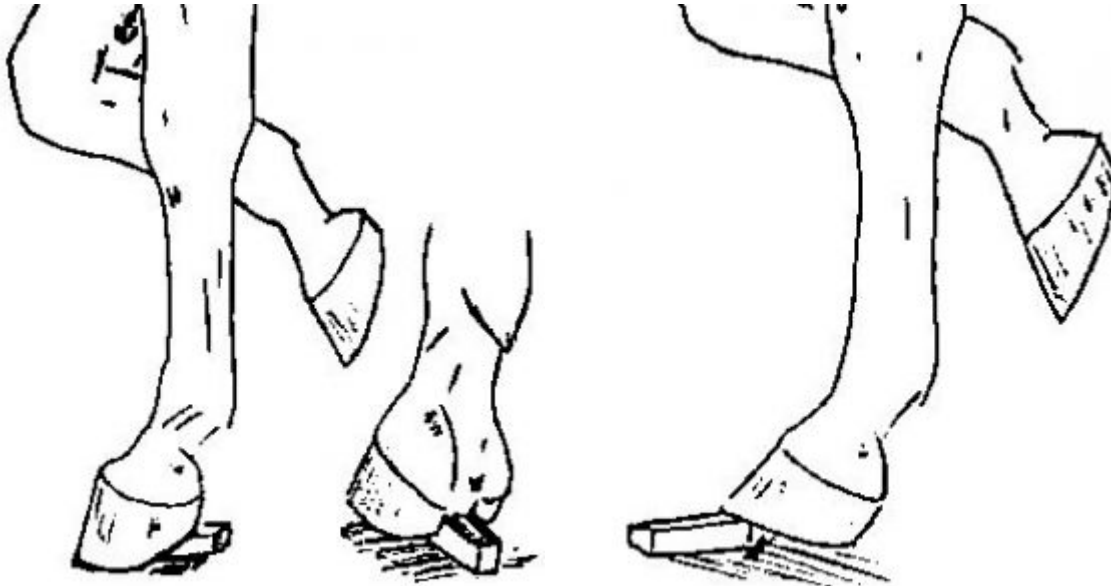
Circulation test : After 15 minutes of exercise, horses should increase the skin temperature in the heel region by at least 1°F. If they do not, this may indicate poor blood flow to the heel region. This test is subject to outside influences : do not jog the horse prior to doing the test and it may be inaccurate on very cold and very hot days.

Distal limb flexion : if this test is positive, look for coffin joint pain/ligamentous pain/navicular bone pain. Major sources of coffin joint pain include a broken forward hoof axis (mild club foot) and medial-lateral hoof imbalance



Wedge tests

- **Frog wedge** : To do this test, a board or hoof knife is placed under the frog and the horse made to stand on it for 1 minute by lifting the other foot. Consider this test a hoof tester using the horse’s entire body. If this is positive, look for pain in the navicular bone or caudal P3.



Tracy Turner,

DVM

- **Toe wedge** : To do this test, a board or hoof knife is placed under the toe at the front and the horse made to stand on it for 1 minute by lifting the other foot. This places stress on the deep digital flexor tendon. If this test is positive, look for pain in the navicular bursa, flexor cortex of the navicular bone or flexor tendons.

Coffin joint block :blocks the coffin joint, collateral ligaments of the coffin joint, bursa and blocks navicular bone pain in many cases; with enough local (>6cc) and time (>5 min) this block also blocks the sole and heel region

Bursal block : blocks the bursa and the heel regions; is a very low PDN block; usually gets the navicularbone; should not get the coffin joint

Palmar digital nerve block (PDN): blocks the navicular bone, coffin joint, bursa, caudal heel region and sole (all of the foot but dorsal laminae and the coronary band)

Test responses	Bursa +	Bursa –
Coffin joint +	bursa, navicular bone, sole, navicular ligaments/ tendons/heel	coffin jt and coffin jt collateral ligaments
Coffin joint –	(navicular bone), navicular ligaments /tendons/heel, P3	navicular ligaments /tendons/heel, P3

Navicular bone radiographic changes

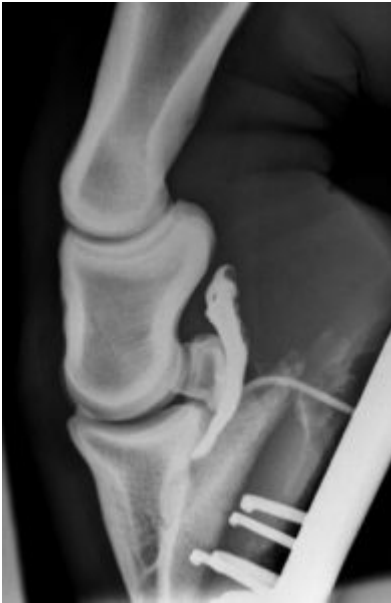Radiographic changes are not pathognomonic for navicular syndrome (false positive and negative results can both occur)

1. Remodeling : wings and dorsal surface
 - look on DP and lateral views for sawtooth borders, bump on dorsal surface, spurs on extremities
2. Synovial invaginations
 - navicular bone view; Abnormal if many lollipops evident on the base or if lollipops on the sides
3. Bone cysts
 - hole in middle of bone; seen on navicular bone view, flexor cortex view, lateral
4. Flexor cortex changes
 - flattening of flexor cortex, sclerosis of navicular bone; seen on flexor cortex view
5. Navicular bone fractures
 - chips or complete fractures

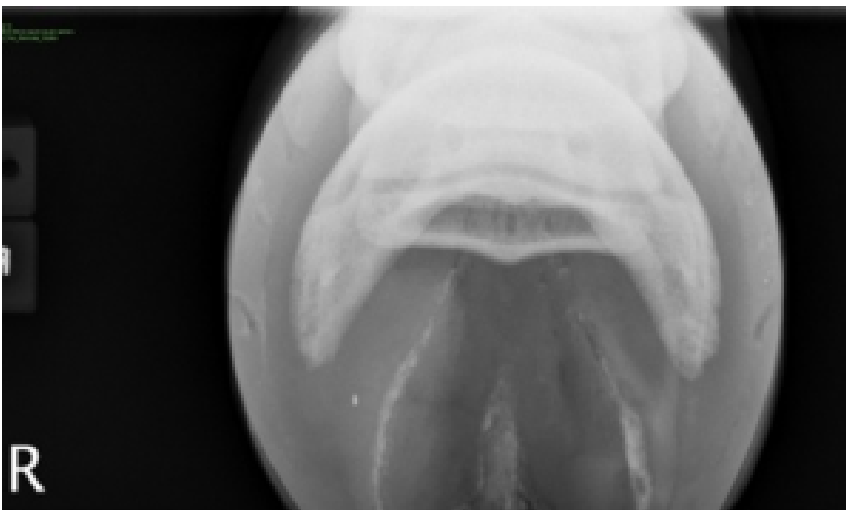
Other changes:

- check DP view for medial-lateral hoof balance
- check lateral view for pastern-coffin bone axis (broken back or broken forward)
- for heel angle (underrun?)
- for toe length/foot balance
- for evidence of previous laminitis>
- check joints for arthritis
- check coffin bone for pedal osteitis (increased irregularity to border)

Contrast study :assess cartilage on flexor cortex



Abnormal radiographs- slideshow and self quiz



Treatment

- Treat specific lesions – e.g. DDFT tear found in MRI
- Corrective shoeing
 - Encourage horse to land normally rather than on toe
 - Correct long toe, underrun heel
 - Raise the heel to decrease strain on DDFT and forces on navicular bone
 - Rolled toe to ease breakover
 - Egg bar shoe to provide support to heel area
- Medical management
 - Systemic NSAIDS

- Intrasynovial corticosteroids
 - Distal interphalangeal joint
 - Navicular bursa (tend to be the most effective)
- Bisphosphonates – alter bone metabolism by interfering with osteoclasts – controversial
- Keep the horse in regular work
- Surgical management
 - Transection of the prox. suspensory ligament of the navicular bone
 - can be done arthroscopically
 - effects are likely due to transection of sensory nerves to the navicular bone
 - Palmar digital neurectomy
 - Last resort
 - Fraught with complications (e.g., neuroma formation)

Navicular syndrome cases

Develop a case around the scenarios below. Try this on your own first and then use the articles to check your story and fill in gaps

1. A horse with damage to the collateral ligament of the coffin joint due to medial-lateral imbalance
2. A horse with coffin joint synovitis due to a mild club foot conformation (similar conformation bilaterally)
3. A horse with a vertical split in the deep digital flexor tendon at the level of the navicular bone (and some damage in the other limb, same area)
4. A horse with a fracture of the palmar process of P3 in one foot

What is the signalment ?

Quarter horse types are more prone to navicular syndrome but other breeds can be affected. Trauma may affect all breeds

Is it unilateral or bilateral?

How long as it been going on?

Has it been getting worse, better, staying the same or it varies?

How does it respond to phenylbutazone? Rest? Exercise?

What are you likely to find on physical examination?

Include hoof conformation, hoof tester responses, palpation results

What is the lameness like on a straight line? In a circle? Going the other way?

What happens if you do the various tests? (wedge tests, flexion tests)

What happens if you do the various blocks (PDN block, coffin joint block, navicular bursal block, others)

Other diagnostics? Eg if you do a bone scan?

Whiskey

You are presented with the following case. Using your knowledge of the various tests, try to determine which version of caudal heel pain is most likely :

- Navicular bone
- Navicular bursa +/- DDF tendon
- Coffin joint
- P3
- Laminitis

HISTORY: “Whiskey” is a 6 year old QH mare. She has been lame on the left foreleg for 3 weeks.

EXAMINATION: “Whiskey” was lame at a trot on the left front. She was worse on the lunge line when going to the left. She has notable medial-lateral imbalance (eg one side higher than the other),

Hoof testers: sensitive on hoof testers on medial toe of LF.

Manipulation tests:

Distal limb flexion:	RF +	LF +
Frog wedge	RF –	LF –
Toe wedge	RF –	LF –

Local anesthesia (all tests were done separately; tests on the RF were done after the LF was blocked):

Coffin joint block LF : 90% improvement at 5 min and noticed RF lameness when lunged

Palmar digital nerve block LF : 90% improvement, now lame RF

Navicular bursal block LF : no improvement

Coffin joint block RF : 90% improvement

Palmar digital nerve block RF : 90% improvement

Li'l Bit

You are presented with the following case. Using your knowledge of the various tests, try to determine which version of foot pain is most likely :

- Navicular bone
- Navicular bursa +/- DDF tendon
- Coffin joint
- P3
- Laminitis

HISTORY: “Lil Bit of Humor” is a 7 year old QH/TB gelding. Since last fall (it is now summer) he has gotten gradually more lame at the trot. He won't trot willingly and head nods when forced to trot. There has also been some soreness in his hindquarters which did not respond to chiropractic treatments. He is used for pleasure and showing. He was shown on phenylbutazone last year.

EXAMINATION:

“Lil Bit” was lame at a trot on the RF on a straight line. The lameness was exacerbated when lunged to the right and was also evident when lunged to the left. No LF lameness was seen.

Hoof testers: Sensitive across the heels, sole and middle third of the frog of both feet.

Manipulation tests:

Distal limb flexion	RF –	LF –
Frog wedge	RF +	LF +
Toe wedge	RF –	LF –

Local anesthesia (each test was done individually; the LF tests were done with the RF blocked):

Coffin joint block RF : 70% improvement at 5 min

Palmar digital nerve block RF : 95% improvement; lame on the LF when lunged to the left

Navicular bursal block RF : 80-90% improvement; lame on the LF when lunged to the left

Palmar digital nerve block LF : 90-95% improvement

Apollo

You are presented with the following case. Using your knowledge of the various tests, try to determine which version of foot pain is most likely :

- Navicular bone
- Navicular bursa +/- DDF tendon
- Coffin joint
- P3
- Laminitis

HISTORY: “Apollo” is a 17 year old Thoroughbred gelding. He has been showing intermittent left foreleg lameness for almost 1 year.

EXAMINATION:

“Apollo” was lame at a trot on the left front. He was worse when lunged with the leg on the inside.

Manipulation tests:

Hoof testers	RF : neg	LF : pos, lateral to frog
Distal limb flexion	RF : neg	LF : neg
Frog wedge	RF : neg	LF : pos
Toe wedge	RF : –	LF : +/-

Local anesthesia (each test done separately); pay attention to relative improvements:

LF coffin joint block : <50% improvement at 5 min w/ 6cc carbocaine (this means minimal improvement)

LF palmar digital n block : >90% improved

LF bursal block : >90% improved

Red

You are presented with the following case. Using your knowledge of the various tests, try to determine which version of foot pain is most likely :

- Navicular bone
- Navicular bursa +/- DDF tendon
- Coffin joint
- P3
- Laminitis

HISTORY: “Red” is a 6 year old QH gelding donated to the Minneapolis Police Mounted Patrol. He has a chronic foreleg lameness.

EXAMINATION: “Red” is lame at a walk on the RF. Due to the weather, he could not be lunged.

Hoof examination: Narrow, underrun heels bilaterally

Hoof testers: negative

Manipulation tests:

Distal limb flexion RF – LF –

Frog wedge RF – LF –

Toe wedge RF ++ LF –

Local anesthesia (all tests were done individually)

Coffin joint block RF : 70% improvement

Palmar digital nerve block RF : 90-95% improvement

Bursal block RF : 90% improvement

No lameness was seen in the LF

Buttons

You are presented with the following case. Using your knowledge of the various tests, try to determine which version of foot pain is most likely :

- Navicular bone
- Navicular bursa +/- DDF tendon
- Coffin joint
- P3
- Laminitis

HISTORY: “Buttons” is a 7 year old Trakehner gelding. He is only used intermittently but was found to be lame in the RF when pulled from the pasture.

EXAMINATION: “Buttons” is very short strided on both front. He is sorely in need of a trim with very long toes and low heels bilaterally. On both feet, the medial heel bulb is higher than the lateral heel bulb (sheared heels). When lunged to the left, he shows LF lameness. When lunged to the right, he shows RF lameness.

Hoof testers: negative

Manipulation tests:

Distal limb flexion	RF –	LF –
Frog wedge	RF +	LF +
Toe wedge	RF ++	LF ++

Local anesthesia (all tests were done individually)

Coffin joint block RF : 90% improvement; see LF lameness

Palmar digital nerve block RF : 90-95% improvement; see LF lameness

Bursal block RF : 90% improvement; see LF lameness

Practice



An interactive or media element has been excluded from this version of the text. You can view it online here:
<https://open.lib.umn.edu/largeanimalsurgery/?p=2702>

Swine and poultry lameness

Poultry



An interactive or media element has been excluded from this version of the text. You can view it online here:
<https://open.lib.umn.edu/largeanimalsurgery/?p=2300>



An interactive or media element has been excluded from this version of the text. You can view it online here:
<https://open.lib.umn.edu/largeanimalsurgery/?p=2300>

Equine female urogenital surgery

FILLIES

Uroabdomen

Fillies with uroabdomen should be checked for ruptured ureters since ruptured bladders are less common. Urine accumulates retroperitoneally, as well as intraperitoneally. While ultrasound can help in certain cases, antegrade pyelography (inject contrast into the renal pelvis and watch its exit path fluoroscopically) can be very useful in identifying any leaks in smaller patients. Scintigraphy can be used in larger animals.

Treatment involves ureteral catheterization (from the bladder) with retrograde dye infusion to identify the defect. The catheter is then advanced to the renal pelvis and the defect repaired with absorbable suture. The catheter may be left in place as a stent with distal end exited out either the urethra or via a perineal urethrotomy. In the older gelding, conservative treatment with antibiotics, NSAIDs and fluids was adequate without stenting as the ureter remained patent.

Umbilical hernias

Quarterhorse fillies are particularly prone to having umbilical hernias, likely due to a genetic component. Hernias may also develop due to excessive traction on the umbilical cord. Some foals develop hernias within the first 2 months of life; these are also assumed to be due to a genetic cause.

Smaller hernias (<5cm diameter) in foals may resolve on their own and this usually happens within the first 3 weeks of life. If a hernia is still present at 4 months of age, it probably isn't going to resolve on its own.

Treatment options include hernia clamps, belly bands and surgery. Hernia clamps are cheap and are designed to cause necrosis and scarring. Complications include sepsis and evisceration. Hernia belts may or may not work better than mother nature; research is limited to non-existent. Surgery can be performed in the field under the right conditions. A fusiform incision is made around the hernia defect and the hernia closed with #2 PDS or similar material using a simple continuous pattern. The hernia sac does not need to be opened; however, freshening of the hernia ring may help healing.

If a hernia develops due to trauma, it is important to wait until a good firm fibrous ring develops before attempting repair. This generally requires about 60 days. Most of these should be referred to a surgery facility.

Ectopic ureters Ectopic ureters are unilateral in 3/4 and bilateral in 1/4 of affected foals. Rather than inserting into the bladder, most ectopic ureters insert distal to the trigone (into the vaginal vault).

Clinical signs often include urine scalding from birth. Normal urination is possible if unilateral ectopia or if the bladder fills due to urethrovesicular reflex. (Note – colts may not be incontinent if retrograde filling of bladder can occur.

Diagnosis is made by a combination of contrast studies, ultrasound and endoscopy. Intravenous urography doesn't usually work well due to dilution of the contrast media in horses (just can't see it). Retrograde urethrocytography is performed by inserting a balloon tipped catheter into the bladder and infusing enough media to distend the bladder and hopefully fill up the ureters. Injection of contrast directly into the renal pelvis, creating an excretory urogram, was successful in a case seen at the UMN. Ultrasound may identify dilated ureters and/or a dilated renal pelvis. Using videoendoscopy, the ureters can be watched for urine flow. A papilla may be seen in the vagina that is the exit site of the ectopic ureter. Colored dyes may also be given orally that change urine color, making the ectopic site more readily identified.

- indigoermine 0.25 mg/kg
- phenolsulfonphthalein 0.01 mg/kg
- sodium fluorescein 11 mg/kg
- neoprontosil 0.05 ml/kg

It is important to evaluate for hydroureter and hydromephrosis as either will affect treatment and/or prognosis.

Treatment of ectopic ureters is by either ureterovesical anastomosis (as performed in small animals) or nephrectomy. Nephrectomy is recommended for unilaterally ectopic ureters; obviously this doesn't work well for bilateral cases. Early treatment decreases the risk of hydronephrosis and ascending infection.

Equine male urogenital surgery

Penile and preputial neoplasia

Squamous cell carcinoma

SCC is a common tumor of the penis and prepuce. The clitoris can also be affected. SCC is common in older geldings, particularly those with unpigmented preputial/penile skin (Appaloosas and Paints). SCC has been associated with chronic irritation due to smegma. Horses with ocular SCC should be checked for urogenital SCC as well and vice versa.

SCC can appear as several small lesions (papillomas), ulcers, plaques or granulomatous cauliflower-like lesions. The glans and urethral opening are often affected. Tumors tend to be locally invasive and, while slow to metastasize, can spread to regional lymph nodes. A rectal examination can be useful to detect spread to sublumbar lymph nodes. Deep palpation of the inguinal area can detect enlargement of those nodes (easiest when the horse is anesthetized).

Lymph node aspiration is recommended; enlarged nodes may be due to metastasis or inflammation.

Differential diagnoses should include papillomas and habronemiasis. Benign papillomas may progress into malignant SCC.

Treatment options are the same as for SCC at other sites. The most commonly used treatments include cryotherapy, CO₂ laser resection, topical 5-fluorouracil, and resection.

Cryotherapy: Cryotherapy can be performed in the standing horse using sedation +/- local anesthesia. After the initial freeze, the area is relatively numb and local anesthesia is not commonly used. A double to triple freeze-thaw cycle is used at a minimum, with a quick freeze and a slow thaw preferred for the most cellular damage. When you have frozen it enough, the area stays “frozen” and doesn’t thaw rapidly anymore.

Because this is a mucous membrane, the probe can “stick”. Have water ready to apply if the probe is difficult to remove.

Do not freeze where scars may squeeze. Avoid freezing the urethral opening and be careful around the glans.

Cryotherapy is most useful for small lesions or following debulking. It is often used to control recurrence and may be combined with other treatments (eg 5 FU).

5-Fluorouracil: 5-FU is a topical chemotherapeutic agent that interferes with the cell’s ability to synthesize DNA. Repeated application can lead to tumor remission. The drug is much less toxic when applied topically as opposed to systemic administration.

5-FU is applied after surgical debridement or to small lesions. In mares, daily application is necessary. Recheck mares every 2 weeks until remission and then every 6 months. In geldings/ stallions, the sheath maintains a higher drug concentration and 5FU is applied every 2 weeks. An inflammatory response is expected beginning at 5-7

days and continues through 2-4 weeks. The tumor sloughs at 6-12 weeks in many cases. Therapy often involves 3-6 treatments but should be continued until the tumor is under control.

5-FU can be obtained from most human pharmacies and comes in small tubes that aren't cheap. If a tumor is debulked, you may want to wait until bleeding stops before applying 5FU to ensure that it isn't washed away.

Many horses need continued treatment at least 1-2x a year. 5-FU can be used indefinitely but does eventually affect normal skin cells (since they are rapidly dividing). The irritation can lead to epithelial changes (and tumor formation?).

Cisplatin beads : new treatment and relatively inexpensive. One bead implanted per cm.2

CO2 Laser: The CO2 laser is useful for removing skin tumors, including urogenital lesions. The shallow cutting action and limited lateral damage of this laser make it easy to "shave" tumors off until normal tissue is apparent with minimal inflammatory response. Laser treatment can be performed in the standing animal using local anesthetic and sedation. The laser also decreases nerve sensation and seems to have less postoperative pain associated than does cryotherapy. Tumor recurrence can be more difficult to detect as it may be covered by normal skin.

Tumor resection: Besides the option of removing a local lesion (can be done standing with local anesthesia and primary closure of the defect; get wide margins), tumor resection may involve removal of the prepuce or part/all of the penis or clitoris. With clitoral SCC, extensive dissection and wide margins are required.

i. Posthioplasty or Reefing

In this procedure, the superficial mucosal layer of the prepuce is removed (and hopefully the tumor along with it) and the remaining ends reanastomosed. The procedure is most commonly done under general anesthesia but is short enough to be done under injectable anesthesia.

Circumferential incisions are made in the prepuce on either side of the lesion and connected by a longitudinal incision. Marking sutures may be placed on the outside edges of the circumferential incisions to make sure the tissues aren't twisted. A penrose drain placed proximally works well as a tourniquet. The mucosa between the circumferential incisions is peeled off underlying tissues with sharp and blunt dissection. The remaining mucosal edges of the prepuce are reanastomosed with short continuous suture patterns, usually with absorbable 2-0 suture.

Postoperative care involves NSAIDs to minimize swelling +/- oral antibiotics (not the cleanest area).

ii. Phallectomy (penile amputation)

Phallectomy can be used to remove tumors of the distal penis that have not spread to local lymph nodes (inguinal or sublumbar). Ultrasound can be useful to determine if the tumor has penetrated through the tunica albuginea (and likely entered the vascular system).

There is a limit to how much penis can be physically removed.

This procedure should not be done in intact stallions as erection can result in wound dehiscence and hemorrhage. Stallions should be castrated at least 2 weeks prior to phallectomy.

Complications include urethral swelling and obstruction (maximum at 3-4 days); dehiscence (partial usually heals okay), and tumor recurrence or incomplete removal (25.6% recurrence rate; biopsy margins at surgery; apply 5FU, etc).

Budget cases: can amputate standing using a Callicrate bander; need to perform a PU so they can urinate. Penis undergoes ischemic necrosis. Might be difficult for some owners to handle.

iii. En bloc resection and penile retroversion

Rarely done anymore due to extensive complications and aftercare required.

iv. Amputation and sheath ablation

This is a newer procedure to retain more normal orientation of the penis. A new skin opening is made in the ventral abdomen and a urethrostomy performed at the new site. Pain occurs if too much traction is present (assess likely sx site when horse is standing), hemorrhage and dehiscence are possible. Urine scald is reportedly not as severe. Lymph nodes can be removed through separate incisions. Better owner acceptability? (most commonly recommended right now)

With all of these treatments, reevaluation and sheath cleaning is recommended at least every 6 months for cases of SCC.

Sarcoids

Sarcoids can occur on the preputial skin. Treatment is the same as for treatment of sarcoids in other sites. Aldara, cryotherapy, cisplatin beads and/or laser removal are the most common recommendations at this time.

Others

Melanomas are common in the sheath of gray horses. Treatment is not usually required.

Very rarely are these tumors malignant, however, malignancy and metastasis has been reported. Lymphosarcoma can also develop in the sheath. Systemic steroids can help control the disease. Hemangiosarcoma has been reported. Papillomatosis is usually self limiting but persistent cases have been reported. May be a precursor to SCC.

Habronemiasis

Habronemiasis or “summer sore” is a result of Habronema larvae encystment. These lesions are more common in warm, humid climates. External genitalia is a frequent site due to moisture that attracts flies. Exuberant granulation tissue is present and small, yellow, hard, caseous granules can be squeezed out of the lesions.

Eosinophils are usually present in the blood and in samples from the lesion. Treatment includes ivermectin and steroids. If affected, the urethral process can be amputated in the standing horse after local anesthesia. A catheter is preplaced to minimize the risk of trauma to the urethra. The urethral mucosa is apposed to the remaining stump of the process with interrupted sutures of 2-0 absorbable suture.

References

Arnold CE et al. Use of a modified Vinsot technique for partial phallectomy in 11 standing horses. JAVMA 2010. 237:82-86.

Doles J et al. Penile amputation and sheath ablation in the horse. Vet Sx 2001. 30:327-331.

Fortier LA and MacHarg MA. Topical use of 5-fluorouracil for treatment of squamous cell carcinoma of the external genitalis of horses: 11 cases (1988-1992). JAVMA 1994. 205:1183-1185.

Knight CG et al. Persistent, widespread papilloma formation on the penis of a horse. Vet Derm 2011. 22:570-574.
Mair TS et al. Surgical treatment of 45 horses affected by squamous cell carcinoma of the penis and prepuce. EVJ 32:406-410.

May KA et al. Recognizing tumors of the equine external genitalia. CCE 2002. 24:970-976. May KA et al. Surgical treatment of external genitalia tumors in horses. CCE 2002. 24:570-576.

Rizk A et al. Surgical management of penile and preputial neoplasms in equine with special reference to partial phallectomy. Journal of Vet Med 2013. Article ID 891413.<http://dx.doi.org/10.1155/2013/891413>

Van den Top JGB et al. Penile and preputial squamous cell carcinoma in the horse and a proposal of a classification system. EVE 2011. 23:636-648.

Van den Top JGB et al. Penile and preputial tumours in the horse: Literature review and proposal of a standardized approach. EVJ 2010. 42:746-757.

Van den Top JGB et al. Penile and preputial tumours in the horse: A retrospective study of 114 affected horses. EVJ 2008. 40:528-532.

Van den Top JGB et al. Penile and preputial squamous cell carcinoma in the horse: A retrospective study of treatment of 77 affected horses. EVJ 2008. 40:533-537.

LA Orthopedic Emergencies

Limb instability – fractures, tendon lacerations, soft tissue breakdown injuries

Infected synovial structures

Hemorrhage

Arterial damage

Bleeding can be life threatening when involving arteries. Most arterial lacerations are caused by external trauma; fractures can also lacerate arteries and cause severe bleeding without an external wound. As with most bleeding, compression or vascular repair is ideal. In some situations, this can be challenging.

Blunt force or stretching arterial damage can lead to clotting and lack of blood flow without laceration or hemorrhage.

Bleeding secondary to artery laceration

Bleeding can be controlled through

- tight bandages
- temporary tourniquets
- ligation of the artery
- clamping of the artery
- patient death (obviously not ideal)

Horses may not tolerate tourniquets and tight bandages on hindlimbs and will often require sedation. Cattle and small ruminants are more amenable to treatment. Animals can be sedated and/or anesthetized if needed; fluid support is often indicated due to blood loss. Short duration anesthesia that results in hemorrhage control is generally preferable to ongoing blood loss.

Pastern injuries are one of the more common causes of arterial injury due to the limited soft tissue covering of vessels in that region. Accidental artery trauma can occur in surgery, as well. In large animal species, collateral circulation is generally sufficient to provide blood flow to an area; rarely is vascular anastomosis required or performed.

Bleeding secondary to bone fracture

Femoral fractures and radial fractures are the most likely causes. The damaged arteries are deep and not accessible without significant surgical trauma. Compression can be almost impossible. Keeping the patient quiet and calm (lowered blood pressure) is essential. Various therapies to activate clotting and/or slow bleeding are usually attempted:

- iv formalin (recipe)

- EDTA
- ice packing
- yunnan baiyao

In many cases, a blood transfusion will be required. Once the bleeding has stopped and the patient stabilized, referral to a hospital with transfusion capability is indicated.

Arterial spasm/ arterial blockage

When arteries are stretched too far or are traumatized, they tend to spasm shut. If this spasm lasts long enough for clotting to occur or causes endothelial damage, eventual loss of distal blood flow is very possible. In these situations, all blood supply to a region tends to be impacted. No blood supply to an extremity leads to necrosis and typically either amputation or loss of life.

The most common causes of this type of injury are racetrack breakdown injuries, limb entrapments, and cannon bone fractures due to dystocia management in neonatal calves. In the latter two cases, the vessels are compressed by outside forces (whatever is entrapping the limb and the calving chains). With breakdown injuries, the fetlock drops so low that the vessels are stretched almost to the breaking point. In all of these, the blood flow damage is not immediately obvious. However, within 6-12 hours, the limb is noticeably cooler and the prognosis is very poor. Healing does not occur without blood supply. Larger animals do not tolerate limb amputation and should be euthanized unless some sort of prosthesis is available (and this is rare). Small ruminants and alpacas can tolerate limb amputation and this is an option.

Occasionally, infections and endotoxemia lead to systemic clotting. Distal limbs are affected first. This can result in hoof sloughing as one of the early signs, due to the limited blood supply to the hoof as well as the small diameter vasculature.

References

Tendon and ligament lacerations



A YouTube element has been excluded from this version of the text. You can view it online here: <https://open.lib.umn.edu/largeanimalsurgery/?p=2710>

Limb fractures

Lacerations involving synovial structures

Practice

Limb changes

Swollen limb

<https://thehorse.com/181193/why-does-my-horse-have-a-fat-leg/>